

We are IntechOpen, the world's leading publisher of Open Access books Built by scientists, for scientists

6,900

Open access books available

186,000

International authors and editors

200M

Downloads

Our authors are among the

154

Countries delivered to

TOP 1%

most cited scientists

12.2%

Contributors from top 500 universities



WEB OF SCIENCE™

Selection of our books indexed in the Book Citation Index
in Web of Science™ Core Collection (BKCI)

Interested in publishing with us?
Contact book.department@intechopen.com

Numbers displayed above are based on latest data collected.
For more information visit www.intechopen.com



Laparoscopic Appendectomy

Paolo Ialongo, Giuseppe Carbotta and
Antonio Presterà

Additional information is available at the end of the chapter

<http://dx.doi.org/10.5772/intechopen.74192>

Abstract

Appendectomy represents a fundamental step in the training course of a surgeon in so much that for several decades it has been the first surgical operation assigned to a training surgeon. Yet, laparoscopic appendectomy has not spread with the same characteristics as the operation of cholecystectomy for which laparoscopy has rapidly become the gold standard. We can moreover note that nowadays, in spite of a certain initial distrust, the laparoscopic methodology is fully employed in the treatment of acute appendicitis, even though the use of such technique is controversial in cases of acute complicated appendicitis.

Keywords: appendicitis, surgery, laparoscopy

1. Introduction

Appendectomy represents a fundamental step in the training course of a surgeon in so much that for several decades it has been the first surgical operation assigned to a training surgeon. Yet, laparoscopic appendectomy has not spread with the same characteristics as the operation of cholecystectomy for which laparoscopy has rapidly become the gold standard.

In fact, before attempting their laparoscopic appendectomies, many surgeons have, first, standardised their technique of cholecystectomy. There are many reasons that justify a slower spreading of this methodology:

- Open appendectomy has been considered for decades as a rapid technical method requiring a small surgical incision.

- The operation is, moreover, generally made on an organ suffering from an inflammatory process which often causes a pathological alteration of the surrounding organs with formation of oedema, congestion and adhesions, thus making a laparoscopic appendectomy more difficult.

The open appendectomy introduced by an American surgeon Charles McBurney in 1894 is still today considered the gold standard in the surgical treatment of acute appendicitis because it is a safe surgical procedure, with a low morbidity rate, a short hospitalisation and a low discomfort for the patients. Expected intraoperative difficulties in laparoscopic appendectomy could be the management of peritonitis grade and of ectopic appendix.

The first video-assisted appendectomy seems to have been performed in 1977 by the Dutchman Hans J. De Kok, whose priority is actually unknown owing to the scanty circulation of the medical review which was published.

It was Kurt Semm, a German gynaecologist, who publicised the technique of a laparoscopic appendectomy in his two successive works (June 1982 and January 1983). Semm did not however consider the laparoscopic procedure fit for the case of acute appendicitis, as he confirmed in one of his articles published on the review "Endoscopy" in 1983. But he did not quote any personal case history or experience, thus exposing himself to much criticism.

Actually, in 1987 his countryman Jorg H. Schreiber, from Dusseldorf, published his first dense report of 70 cases in 5 years (of which 67 are made with the laparoscopic technique; 7 with a clinical picture of acute, catarrhal or phlegmonous appendicitis), claiming that he had performed his first laparoscopic appendectomy in June 1982.

The number of publications has been in constant growth since then, and more and more numerous perspective comparative studies show the validity and the safety of the laparoscopic procedure offering such significant advantages as fewer infections of the wound, reduced administration of analgesics and a faster return to normal activity, whereas some authors report that costs are increased and operative time are supposed to be longer than the open procedure.

We can moreover note that nowadays, in spite of a certain initial distrust, the laparoscopic methodology is fully employed in the treatment of acute appendicitis, even though the use of such technique is controversial in cases of acute complicated appendicitis.

Notwithstanding, of the numerous studies that have been published on this subject, there is not yet scientific evidence of the superiority of the laparoscopic technique [1] over the open surgical operation even though the laparoscopic procedure proves to be safe also in complicated case with diffuse peritonitis; in which cases it also allows to perform an accurate lavage of the abdominal cavity.

Despite each patient needs to be evaluated for the best surgical procedure, there is no absolute contraindication to laparoscopic appendectomy in cases of complicated appendicitis, especially for experienced surgeons, because it has been demonstrated that the patients in those cases gain a better postoperative outcome.

Open appendectomy presents a higher incidence of complications (wound infections, which can cause longer hospitalisation) and later postoperative hernias.

Laparoscopic procedure can assure a complete exploration of abdominal cavity, without a bigger incision and in case of ectopic or complicated appendicitis. In those cases, if conversion is needed, it could be possible that a focused incision can be practised. Mini-invasive technique is also useful to treat other associated diseases (previously referred or diagnosed during the surgery).

Among all advantages, described in literature, we must remember the reduction of wound infection incidence, of adhesion-related disorders (very important in young women because of infertility that can be caused by adhesions post appendicitis or salpingitis) and of postoperative pain, a faster hospitalisation, a quick return to daily activity and good aesthetic results.

For all these reasons, laparoscopic appendectomy seems to be destined to become unanimously the gold standard for the treatment of acute complicated appendectomy, just as it happened to laparoscopic cholecystectomy.

2. Epidemiology

Acute appendicitis manifests itself at all ages, mostly during infancy and adolescence; it mainly interests the male sex and has an annual incidence of 0.2%. About 14% of the population is estimated to get acute appendicitis during their lifetime. An early diagnosis and its urgent surgical operation are fundamentals to prevent complications and morbidity.

3. Indications

The advantages of a mini-invasive approach evidence themselves above all among women in childbearing age in whom the differential diagnosis is greatly improved. In this way the diagnosis of such pelvic pathologies which may fake an appendicitis as endometriosis, salpingitis and complications of ovarian cysts like torsions or ruptures of haemorrhagic corpus luteum is made possible, thus reducing the percentage of “innocent” appendicitis, as important meta-analyses clearly show [2]. The diagnostic advantage among children and members of the male sex seems to be less, since in this subgroup of patients the diagnosis of appendicitis and the probable differential diagnosis are simpler; anyway, a considerable percentage of cases (5.5%) is recorded where the diagnosis is modified and corrected by resorting to the laparoscopic technique [2]. In obese patients the postoperative complications of a laparoscopic appendectomy are fewer than those with an open technique. The laparoscopic methodology is applicable also to elderly patients, subject to preoperative diagnosis and in the absence of side effects in general. In literature there seems to be some advantage in favour of laparoscopic appendectomy; a more accurate preoperative diagnostic workup is anyway advised in consideration also of the greater incidence of neoplasias among elderly people [1, 3, 4]. There is no unanimous agreement

about laparoscopic appendectomy on pregnant women. The most recent studies on this topic, though they consider the second 3 months as the safest period, do not warn against it during the other periods. Anyway, considering the relative benefits, as well as the potential risks (increase of mortality of foetuses), basing on the data recorded in literature, it is not advisable to prefer laparoscopic appendectomy during all the 3 months of pregnancy [1, 5, 6]. If at the laparoscopic exploration the appendix is shown to be macroscopically undamaged and another pathology is found out as the cause of the symptomatology, there is sufficient evidence that the appendix should not be removed. The difference is the case in which the appendix is normal, but no other pathology is found out; concerning this, it is worthwhile remembering the objective at difficulty, in some cases, of performing a macroscopic diagnosis of appendicitis. In fact an appendix under an initial inflammatory process may have a normal aspect but may result pathologically in the final histological examination. In such cases the surgeon shall decide case by case, on the basis of the preoperative clinical picture. The greater number of authors is in favour of exeresis, also in consideration of the improvement of the clinic symptomatology of such cases. In case of a complicated appendicitis, resorting to the laparoscopic approach is a questionable matter. According to the data recorded in literature, laparoscopy is feasible with the same amount of morbidity as with open technique, in spite of the increase of the incidence of intra-abdominal abscesses which are, on the other hand, counterbalanced by a minor incidence of infections of the wound. The greater incidence of postoperative abscesses may depend either on the relative inexperience of the surgeon or on defects in the surgical technique. The postoperative outcome in terms of total morbidity, hospitalisation and return to work seems, however, to be significantly better among patients with complicated appendicitis treated with the laparoscopic technique. As a matter of principle, the presence of peritonitis, of an abscess, of a gangrenous appendicitis or of perforation does not represent an indication to conversion to laparotomy. Each case must be judged separately, on the basis of the surgical and laparoscopic experience of the surgeon. Conversion to laparotomy is, however, advisable; any time the surgeon does not consider it safe to carry on the surgical operation by laparoscopy, and in such cases, it appears reasonable to make use of an access sufficiently large as to allow to explore and wash the abdominal cavity in an adequate way [7–10].

4. Surgical technique

4.1. Position of the patient

The patient is laid on his back on the surgical bed, with joined and blocked limbs. The right arm is extended laterally (abduction at 90°) so as to allow the anaesthetist's easy vascular access as well as the checking of the vital parameters; the left arm, completely abducted, is fixed to the body. During the surgical operation, some changes of position may be necessary (Trendelenburg, anti-Trendelenburg, left or right lateral inclination) which imply a good anchorage of the patient to the operative table, as accurately as the gravity of the clinical picture requires. In case of serious peritonitis, in fact, washing of the peritoneal cavity is made easier by varying the position of the patient.

4.2. Positioning of the team

The surgical team is made up of the surgeon, the assistant and the instrumentalist operator. This one must stand on the left side of the patient with the surgeon on his right, while the assistant, initially on the right of the patient, shall also move to the left between the surgeon and the instrument operator, after the insertion of the trocars. The service table is laid on the feet of the patient, on the left of the instrumentalist operator.

4.3. Positioning of the trocars

Umbilical, above pubis and in the left iliac fossa are considered the best ports so as to permit an optimal triangulation (**Figure 1**).

The Italian surgical school unanimously favours the technique of three trocars centred in the left hemi-abdomen as described in the early 1990s. The strong points of this position are the easiness of vision and of triangulation, but there is no evidence in literature of an improvement

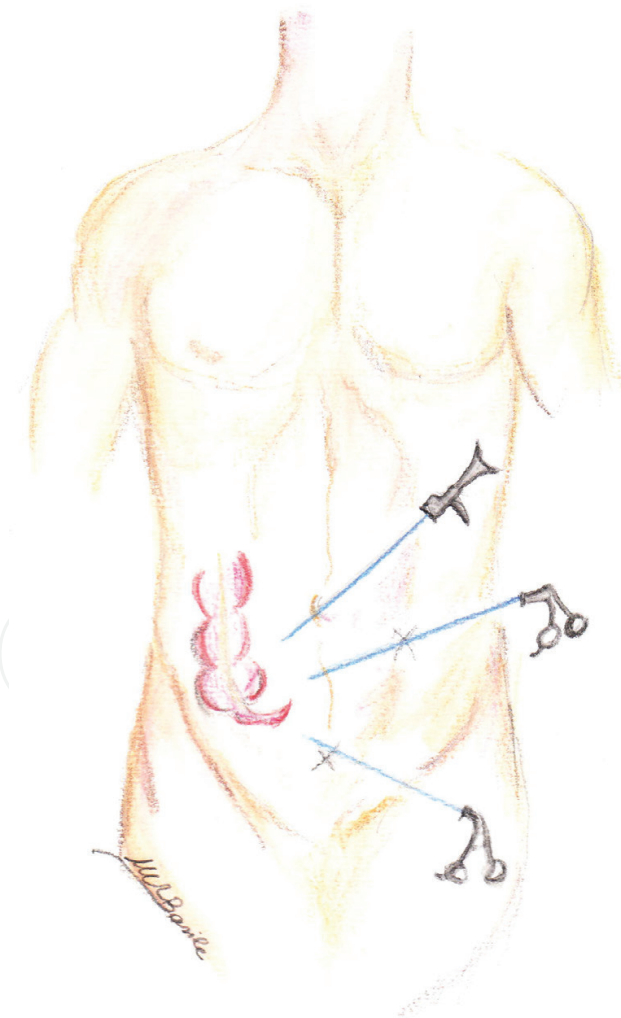


Figure 1. Positioning of the trocars.

of the outcome in comparison with other laparoscopic ports. The insertion of the second trocar in the region above pubis can sometimes present some difficulties; the parietal peritoneum may in fact easily come off the muscle planes, so the needle of the trocar does not pierce it completely but carries it into the abdominal cavity. It is therefore advisable while controlling the manoeuvre through the optical device on the first trocar to carry out the positioning of the trocar in the left iliac fossa as second positioning and not as third positioning; through the iliac trocar, a tenaculum can be introduced so as to press the parietal peritoneum outwards, thus facilitating its penetration. Some surgeons prefer to place the bladder catheter before introducing the trocar above the pubis region to empty the bladder to avoid iatrogenic damages. The use of the two trocars has been studied retrospectively, without evidencing significant advantages. The “single-port” technique has been described in some studies that have shown reduction of the surgical trauma, of the pain and of the postoperative stay in bed, as well as better aesthetic results, but there are still few evidences that it can be an adequate alternative to the standard laparoscopic technique, just as it is the case both with the micro-laparoscopic technique and with the NOTE technique (natural transluminal endoscopic surgery) which makes use of the transvaginal port.

4.4. Exploration of the abdominal cavity

As usual, in all surgical operations either laparoscopic or open, at the start, a careful exploration of the abdominal cavity is necessary with the aim of confirming the diagnosis and/or evidencing other problems. Then, with two atraumatic tenacula (Johanne type), the appendix is searched for by locating the caecum and then the terminal iliac loop. Sometimes, the appendix may take an unusual position (back to the caecum, go down into the Douglas cavity or be adherent to the abdominal wall). In such cases its finding may result difficult. Once the appendix is located, it must be isolated from possible inflammatory-type adhesions.

4.5. Coagulation and section of the meso-appendix

We take note of the great variety of possible usable devices, and we consider bipolar coagulation of the preferable method for the section of the meso-appendix because it is safer and cost-effective (**Figure 2**), even though more rapid, efficient and even more costly methods (e.g. ultrasounds) have been the subject of studies in literature. The appendix is tightened by means of Johanne-type tenacula, and with the chosen device, the meso-appendix is coagulated, starting from the free side towards the appendicular base. Much attention must be paid close to the appendicular artery which must be tied up and sectioned (either directly by means of electricity or by using two clips).

4.6. Tying up the appendicular base

The appendicular stump is closed up by positioning the loop (**Figure 3**), following the methodology already described by Semm in 1983; the mechanical endoscopic stitcher, the stapler, is an alternative approach much employed recently. When using loops, two of them are placed at the base, a few millimetres one from the other. When the stapler is employed, it must comprise the base of the appendix with a piece of caecum as large as a stamp to ensure safe



Figure 2. Coagulation and section of the meso-appendix.

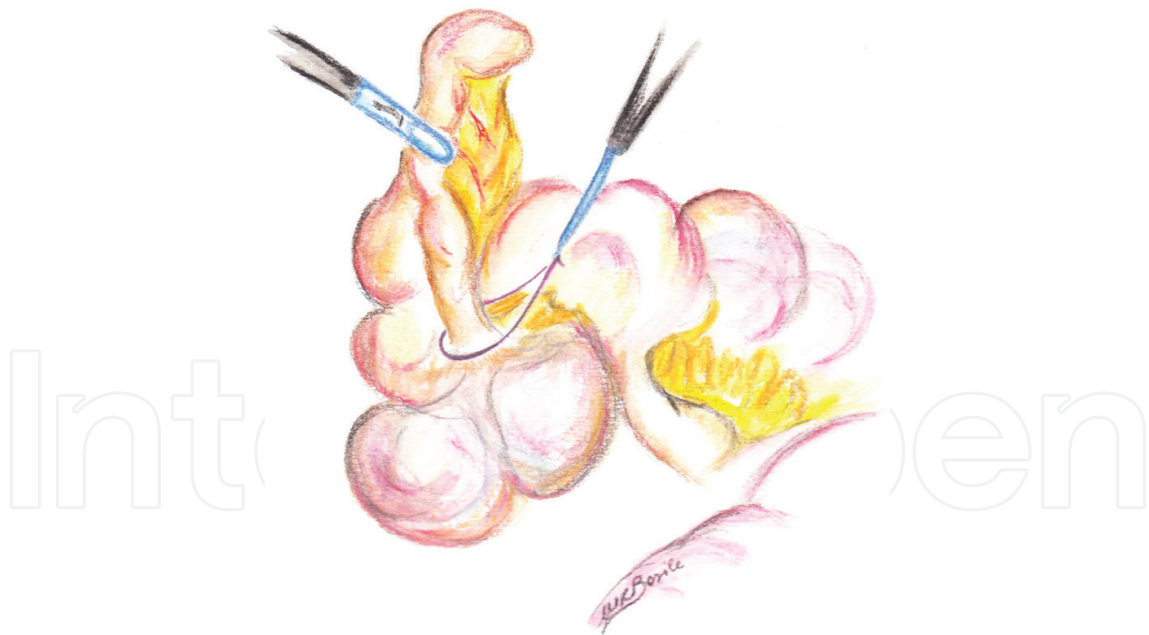

Figure 3. Tying up of the appendicular base.

closure. Numerous comparative studies have been published about these two approaches. Those in favour of the use of a stapler underline such advantages of this technique as the possibility of using it even in complicated appendicitis, reduction of the operating time and of the formation of endo-abdominal abscesses and a fast post-operation canalization of faeces

not to mention the easy use on the part of training surgeons. The authors in favour of the use of loops point out an unmeaningful difference between the two techniques, except for the operating time. The looping technique is considered also a good exercise of manual skill for young surgeons and an economic aid, differently from the stapler which, for the same reason, is not economic for a systematic use [1, 11]. The disadvantages of using the loop are, instead, represented by the large learning curve as well as by its not-yet-clear role in complicated appendicitis [1]. In sectioning the viscera, an adequate length of the residual stump is recommended, which inside must be free of coprolites. Appendicitis of the stump is a rare entity but much attention must be paid to the remaining part of the appendix to minimise such a complication [12]. To further reduce costs, some authors advise to make use of reabsorbing clips (hem-o-lok) to suture the appendix but only in the catarrhal forms.

4.7. Removal of the appendix

It is recommended in all cases to protect the abdominal wall accurately during the extraction of the viscera, either by means of endo-bags, by extraction within the trocar or by other aids which may avoid contamination. Infections of wound are remarkably reduced with the laparoscopic appendectomy thanks to the routine use of protection of the operating piece during the extraction. In those cases in which protection is not employed (e.g., in the so-called laparo-assisted one trocar technique), the incidence of postoperative infections rises up to levels which can be compared to those of the open technique [13]. In case of widespread peritonitis, abscess or perforated appendix, a complete peritoneal washing is recommended. The fact of finding postoperative intra-abdominal abscesses in noncomplicated appendix laparoscopically treated has raised the doubt that limited and aimed washing may reduce the incidence, even if only one retrospective study supports this hypothesis [14, 15]. Therefore, in cases of localised phlogosis, aspiration of the effusions by means of localised washing is considered a protective measure against spreading the septic content towards the recesses unharmed by phlogosis. The routine use of drainage is not advisable; it can, however, be useful for therapeutic purposes either in the presence of abscess cavity and of widespread peritonitis [16] or for preventive treatment in particular situations of risk (steroidal therapy, chronic pathologies) and in special patients. In the other cases, the use of drainage is not necessary and can even be harmful.

Author details

Paolo Ialongo^{1*}, Giuseppe Carbotta¹ and Antonio Prestera^{1,2}

*Address all correspondence to: ialongopaolo@gmail.com

1 General Surgery Unit, Department of Emergency and Organ Transplantation, School of Medicine, "Aldo Moro", University of Bari, Bari, Italy

2 Surgery Unit, Hospital of Gallipoli, Lecce, Italy

References

- [1] Gorter RR, Heij HA, Eker HH, Kazemier G. Laparoscopic appendectomy: State of the art. Tailored approach to the application of laparoscopic appendectomy? Best Practice & Research. Clinical Gastroenterology. February 2014;**28**(1):211-224
- [2] Tzvoras G, Liakou P, Baloyiannis I, et al. Laparoscopic appendectomy: Differences between male and female patients with suspected acute appendicitis. World Journal of Surgery. 2007;**31**:409-413
- [3] Baek HN, Jung YH, Hwang YH. Laparoscopic versus open appendectomy for appendicitis in elderly patient. Journal of the Korean Society of Coloproctology. 2011;**27**(5):241-245
- [4] Kirshtein B, Perry ZH, Mizrahi S, Lantsberg L. Value of laparoscopic appendectomy in the elderly patient. World Journal of Surgery. 2009;**33**:918-922
- [5] Jackson H, Granger S, Price R, et al. Diagnosis and laparoscopic treatment of surgical diseases during pregnancy: An evidence -based review. Surgical Endoscopy. 2008;**22**:1917-1927
- [6] Walsh CA, Tang T, Walsh SR. Laparoscopic versus open appendectomy in pregnancy: A systematic review. International Journal of Surgery. 2008;**6**:339-344
- [7] Ferranti et al. Laparoscopic versus open appendectomy for the treatment of complicated appendicitis. Il Giornale di Chirurgia. 2012;**33**(8/9):263-267
- [8] Lim SG, Jung Ahn E, Kim SY, Il YC, Park J-M, Choi S hY PKW. A clinical comparison of laparoscopic versus open appendectomy for complicated appendicitis. Journal of the Korean Society of Coloproctology. 2011;**27**(6):293-297
- [9] Yau KK, Siu WT, Tang CN, et al. Laparoscopic versus open appendectomy for complicated appendicitis. Journal of the American College of Surgeons. 2007;**205**:60-65
- [10] Cueto J, D'Allemagne B, Vazquez-Frias JA, et al. Morbidity of laparoscopic surgery for complicated appendicitis: An international study. Surgical Endoscopy. 2006;**20**:717-720
- [11] Sajid MS, Rimple J, Cheek E, Baig MK. Use of endo-GIA versus endo-loop for securing the appendicular stump in laparoscopic appendectomy: A systematic review. Surgical Laparoscopy, Endoscopy & Percutaneous Techniques. 2009;**19**:11-15
- [12] Truty MJ, Stulak JM, Utter PA, et al. Appendicitis after appendectomy. Archives of Surgery. 2008;**143**:413-415
- [13] Romy S, Eisering MC, Bettschart V, et al. Laparoscope use and surgical site infections in digestive surgery. Annals of Surgery. 2008;**247**:627-632
- [14] Gupta R, Sample C, Barnehriz F, Birch DW. Infectious complications following laparoscopic appendectomy. Canadian Journal of Surgery. 2006;**49**:397-400

- [15] Hussain A, Mhmood H, Nicholls J, El-Hasani S. Prevention of intra-abdominal abscess following laparoscopic appendectomy for perforated appendicitis: A prospective study. *International Journal of Surgery*. 2008;**6**:374-377
- [16] Petrowsky H, Demartines N, Rousson V, Clavien PA. Evidence -based value of prophylactic drainage in gastrointestinal surgery. A systematic review and meta-analyses. *Annals of Surgery*. 2004;**240**:1074-1085