

We are IntechOpen, the world's leading publisher of Open Access books Built by scientists, for scientists

6,900

Open access books available

185,000

International authors and editors

200M

Downloads

Our authors are among the

154

Countries delivered to

TOP 1%

most cited scientists

12.2%

Contributors from top 500 universities



WEB OF SCIENCE™

Selection of our books indexed in the Book Citation Index
in Web of Science™ Core Collection (BKCI)

Interested in publishing with us?
Contact book.department@intechopen.com

Numbers displayed above are based on latest data collected.
For more information visit www.intechopen.com



Endoscopic Third Ventriculostomy, Indications and Challenges

Ehab Ahmed El Refaee and Ahmed A Abdullah

Additional information is available at the end of the chapter

<http://dx.doi.org/10.5772/intechopen.73518>

Abstract

Endoscopic third ventriculostomy (ETV) allows the cerebrospinal fluid (CSF) to flow directly from the third ventricle through the fashioned ventriculostoma to the interpeduncular cistern, by passing the site of obstruction. In spite of the wide variety of indications where ETV is implemented, its success rate is still debatable especially in certain age groups, where it is most successful in adult patients with obstructive hydrocephalus and it has an identifiable failure rate in children less than 6 months of age. Several factors would affect the success rate of ETV, which are related to the patient's age, pathology, and intraoperative findings. This chapter covers most of the current debates considering ETV.

Keywords: endoscopic third ventriculostomy, obstructive hydrocephalus, choroid plexus coagulation

1. Introduction

In spite of the ongoing advances, endoscopic third ventriculostomy (ETV) remains one of the eminent developments in the history of neurosurgery. It allows the cerebrospinal fluid (CSF) to flow directly from the third ventricle through the fashioned ventriculostoma to the interpeduncular cistern, bypassing the aqueduct and the CSF pathways related to the fourth ventricle and the posterior fossa. The idea of internal visualization of the ventricular system via performing surgery through a small hole in the skull was the initiative for the development of ETV. During the last decades, ETV ran with the advances in visual and optical technologies and made an extraordinary benefit of them.

The first ever use of an optical tool to visualize the interior of the human body was performed by Bozzini in 1806 [1]. A hundred years later, Lespinasse used a cystoscope to visualize the ventricles of two hydrocephalic children [2]. In 1918, Dandy performed an endoscopic avulsion of the choroid plexus in five hydrocephalic children (where four died) [3]; he called his instrument a “ventriculoscope.” In 1922, he opened the floor of the third ventricle by sacrificing an optic nerve [3, 4]. In 1923, Mixter performed a third ventriculocisternostomy through the anterior fontanelle [5], which is considered the first ever successful ETV. In 1947, McNickle was the first to introduce a percutaneous method of performing the third ventriculostomy that led to decline of the complication rate, thus improving the success rate [6]. Afterward the endoscopic technique progressively developed to reach the current modifications in the ventriculoscope for better, clear, and safe visualization of the intraventricular anatomical structures [7].

There is still a detectable failure rate of all treatment modalities of hydrocephalus. However, ETV represents a convenient and easy mode of management. In the recent studies that evaluated the endoscopic third ventriculostomies performed for the treatment of obstructive hydrocephalus, success rates were found between 50 and 94% [8–11]. The type of hydrocephalus and age of the patient, in addition to the surgical technique, play an important role in the success of the ETV [11]. We will discuss comprehensively the surgical technique, indications, and current challenges regarding the increase of the success rate of the ETV.

2. Endoscopic anatomy

A preoperative MRI is almost always needed prior to surgery. From the frontal coronal burr hole, one reaches first the central part of the lateral ventricle near the frontal horn. The frontal horn is demarcated by the absence of choroid plexus. The lateral wall is formed by the nucleus with subependymal veins; medially is the septum pellucidum with septal veins. The choroid plexus and the foramen of Monro are very important landmarks for the central part of the lateral ventricle. The plexus is situated in the floor of the lateral ventricle, the thalamostriate vein lies laterally, and the septal vein's meeting point is on the medial wall; these three structures form the Y-shaped configuration necessary for orientation. The foramen of Monro is formed anterolaterally by the fornix, posteromedially by the anterior thalamic tubercle (**Figure 1**). On looking backwards with the endoscope, the body of the lateral ventricle back to the region of the trigone, with the body of the caudate laterally underlying the thalamostriate vein and the stria terminalis thalami. Adequate orientation of the morbid anatomy that can occur due to chronic hydrocephalus is needed [12–14].

By entering the foramen of Monro, the floor of the anterior part of the third ventricle is clearly identifiable, with the mammillary bodies and tuber cinereum as the two main structures needed for the anatomical orientation (**Figure 1**) [14].

Liliequist's membrane is an arachnoid leaflet situated in the basal cisterns and is a very important anatomical structure in the postsellar region.

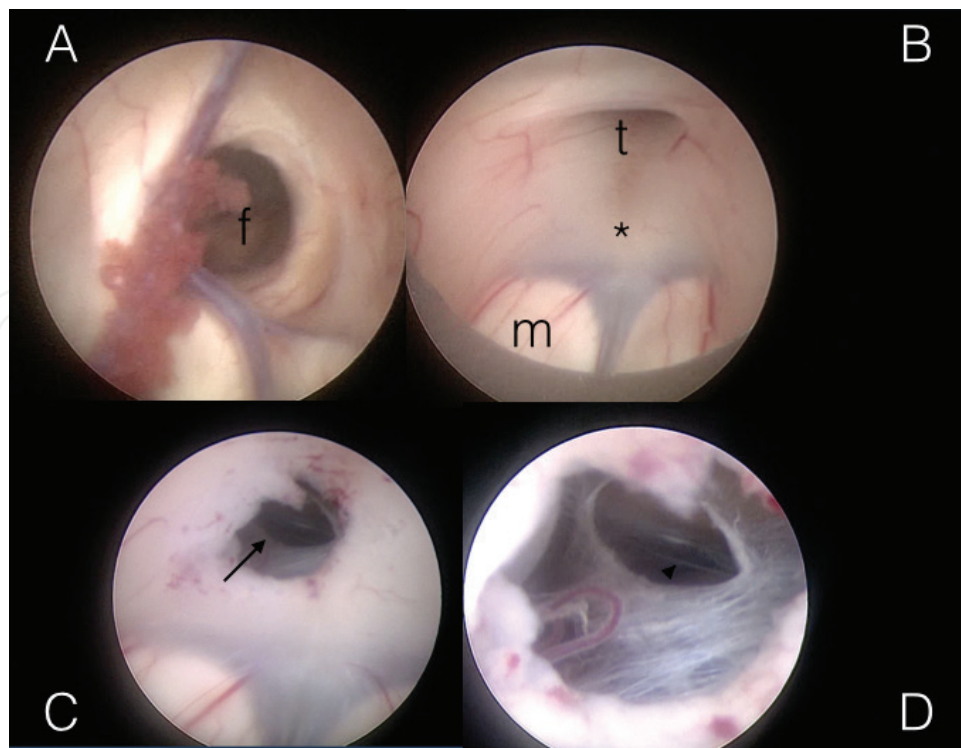


Figure 1. (A) Endoscopic view of the foramen of Monro (f) and its boundaries. (B) Endoscopic view of the floor of the third ventricle before perforation for ETV showing the planned site of perforation (asterisk) in between the tuber cinereum (t) and the mammillary bodies (m). (C) Endoscopic visualization of the membrane of Liliequist after perforation (arrow). (D) Endoscopic visualization of the basilar artery after opening the membrane of Liliequist (arrowhead).

3. Indications

ETV is considered the first management option in adult patients with obstructive hydrocephalus by many neurosurgeons. It is a reliable management option in adults with aqueductal stenosis with a success rate that reach 88% [15]. Stenosis at the aqueduct of Sylvius can be congenital or acquired. In three quarters of cases, the root cause might be unknown [16]. It is not considered as a stable condition as it can be tolerated for years, where stenosis is aggravated by trauma, subarachnoid hemorrhage, viral infection, or gradual accumulation of the CSF proximal to the aqueduct in partial obstruction [16–18]. In a previous study, clinical improvement with identifiable success of the procedure was detected in 86.4% of cases [19], where the success rate was lower in secondary ETV after VP shunt (**Figure 2**). This would be better identified in patients with previous history of multiple VP shunt revisions where the ETV failure is relatively more encountered [19, 20]. ETV is also preferred as the first-line management of hydrocephalus due to obstruction of the aqueduct of Sylvius with pineal tumors or tectal gliomas [21–23].

ETV is less successful in pediatric age groups, with the lowest success rate in children younger than 6 months of age, even in aqueductal stenosis [24, 25].

The application of the ETV has been expanded to patients with hydrocephalus associated with fourth ventricular outlet obstruction, Dandy-Walker malformation [26], Chiari malformation [27–29], communicating hydrocephalus [30], and normal pressure hydrocephalus [31, 32].

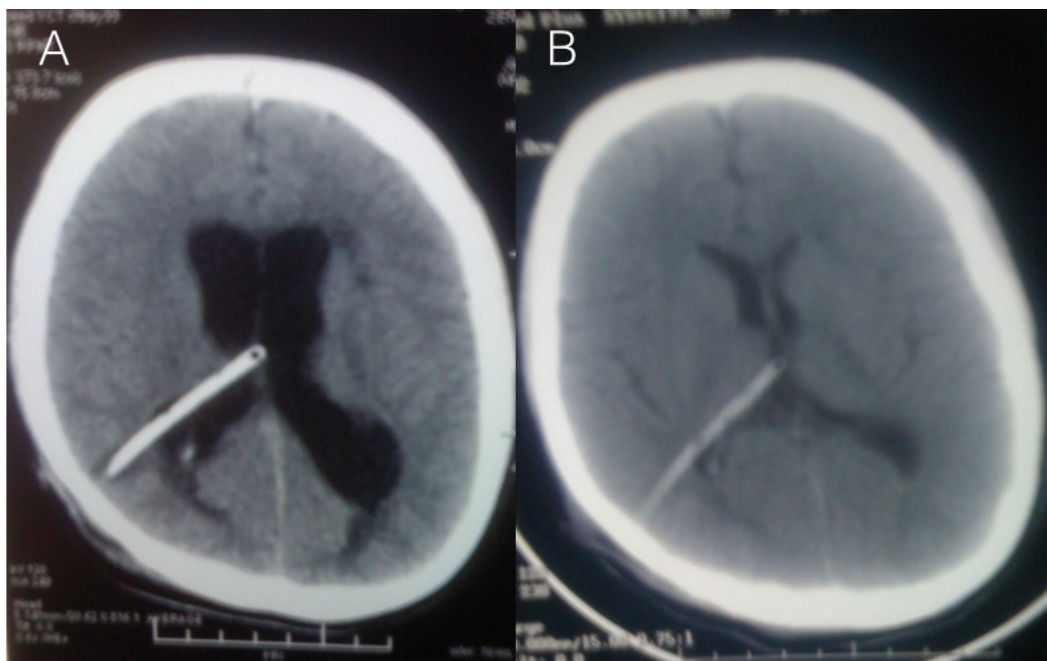


Figure 2. CT of the brain of a previously shunted 12-year-old male with aqueductal stenosis that had signs of increased tension and VP shunt failure; the CT shows enlarged ventricles (A) where ETV was performed without removing the shunt. Follow-up CT of the brain 3 months afterward showed decline in the ventricular size (B) which was accompanied by clinical improvement of the patient.

However, in exclusion to adult-type obstructive hydrocephalus, there is still a lack of strong evidence that supports the procedure.

4. Surgical technique

Under general anesthesia, the patient is restrained, disinfected, and draped as for a frontal burr hole; after opening the dura, a small corticectomy is performed, and a blunt obturator cannula is inserted, with free hands, directed medially toward the ipsilateral medial epicanthus and posteriorly toward the tragus of the ear. After insuring being in the ventricles by the outflow of CSF, the optical visualization system is inserted; we use the Lotta endoscope (Karl Storz, Tuttlingen, Germany) [7].

The first structure identified is the foramen of Monro, with the choroid plexus attached to the posterior margin (**Figure 1A**). The endoscope is introduced through the foramen to the third ventricle, and the floor is identified (**Figure 1B**). A small puncture is done using the decq forceps as posterior as possible to the infundibular recess and avoiding the mammillary bodies and the small arterioles running in this area. The endoscope is then advanced near to the puncture to visualize Lilliequist's membrane which must be opened, after which, the CSF flow should be clearly visualized through the opening (**Figure 1C,D**).

It is important to clearly visualize the fornix before introducing the endoscope to the third ventricle. Opening the floor of the third ventricle with ballooning the fenestra aiming for its

widening, with subsequent opening of the Liliequist membrane, is important for a direct visualization of a naked basilar artery (BA) [25]. A delicate surgical technique is required with experienced hands during the opening of the floor of the third ventricle till the BA is clearly visualized to avoid major vascular injury [33].

5. Outcome

5.1. Clinical evaluation and radiological evaluation

The ETV Success Score (ETVSS) has been developed and validated to predict ETV success based on certain variables [34, 35]. It depends on predicting the success according to the age of the patient, cause of hydrocephalus, and presence of the previous shunt operation. The success rate can be predicted according to these variables. However, intraoperative factors “like the presence of excessive adhesions, mobility of the stoma, excessive bleeding, and opening of Liliequist’s membrane” (**Figure 3**) should be taken into consideration in predicting the success of ETV [36]. In addition, the VP shunt independence is considered a generalized but competent method to measure the success of ETV after VP shunt failure [37, 38].

The change of the ventricular size with a deterioration of the clinical condition has been well known as one of the signs that identify hydrocephalus. In addition, the decrease of the ventricular size after management which accompanied improvement of the general condition has its additional value of success confirmation (**Figure 2**). However, the change of the ventricular size is not well supported as an accurate measurement of the effective treatment of hydrocephalus, especially when it is irrelevant to the clinical condition of the patient [39].

Specific intraoperative factors are considered significant in addition to the associated morbidity. This would include the duration of surgery, type(s) of endoscope used, and degree of intraoperative bleeding [33, 36].

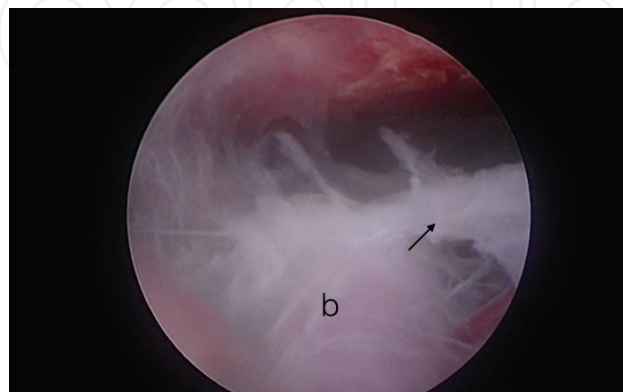


Figure 3. Another patient during ETV where thick arachnoid membranes (arrow) surrounding the basilar artery (b) denoting possibility of ETV failure.

6. Challenges and complications

ETV is considered a safe and direct procedure by a huge group of neurosurgeons, and on the contrary due to the low incidence of mortality due to vascular injury, a fatal risk in comparison to VP shunt implantation is considered by another group of neurosurgeons [33]. Insertion of a foreign hardware to the human's body is always associated with increased risk of infection and/or hardware malfunction, which favors the trial of the ETV as a primary management modality especially in adult patients with obstructive hydrocephalus [15]. On the contrary, late failure or reclosure is considered as a potential risk that can be fatal after ETV [40].

The success of the secondary ETV after ventricular shunt insertion is still debatable, where some studies identified the previous shunting procedure as a weakening factor against the ETV success [19, 41]. Other studies mentioned the success of the secondary ETV in hindering the shunt dependency [42, 43]. In our opinion, ETV is considered a competent treatment option in cases with obstructive hydrocephalus with repeated VP shunt failure. It can be easily tried and may lead to shunt independency.

Seven to ten percent of patients with Chiari type I present with hydrocephalus [44–46]. ETV has proven to be highly effective in the treatment of obstructive hydrocephalus, thus explaining its increasing use in cases of Chiari I-associated hydrocephalus [27, 47–50] with some limitations. The literature shows that most of patients may benefit from ETV. Syringomyelia shows better improvement than CIM. This is most probably due to the obvious role of hydrocephalus and increased pressure in the development of syrinx.

The large incidence of ETV failure in children leads to increased rate of shunt dependency in pediatric age groups, even in obstructive hydrocephalus [24]. The drop of the number of children where ETV is successful is thought due to the rapid formation of the arachnoid and scar membranes in children which closed the ventriculostoma rapidly [51]. On the contrary some authors support the ETV as effective management of obstructive hydrocephalus even in young children [52]. Other authors report the clear impact of age on the success rate of ETV when talking about infants, where the success rate increases gradually during the first months of life. Many studies were performed to determine the cause of failure in young children thus poor absorption of CSF and closure of the ventriculostoma or formation of new arachnoid membranes in the basal cisterns [51, 53]. In addition, reduced absorption of CSF as a cause of failure of ETV was recognized by many authors [54, 55] to be related to poor absorption from the arachnoid villi in young children and to the high compliance of the newborn skull in relation to older children leading to less CSF pressure gradient across the arachnoid villi, added to the previously mentioned probable failure due to arachnoid scarring (**Figure 3**) [56]. This was the initiative to relaunch the choroid plexus coagulation (CPC) technique to decrease the CSF production: thus, it would increase the success of ETV when performed together.

Due to repeated reports about failure in patients below 2 years old [57–59], a consideration of not doing this procedure in this age group has been implemented; however, it is now widely accepted that the etiology of the hydrocephalus rather than the age of the patient is more important in determining the efficacy of ETV even in patients less than 2 years old [60]. ETV

has been shown to be less effective in patients with myelomeningocele and intraventricular hemorrhage, while having a similar success rate to adults in cases of aqueductal stenosis [60].

6.1. Choroid plexus coagulation

Choroid plexus coagulation is the surgical ablation of the choroid plexus either endoscopic or microscopic [61]. It has recently become popular as a method of management of hydrocephalus not caused by the overproduction of CSF [62–65].

Since 2005, the combination of CPC and ETV became more popular but ever since remained a debatable issue [66]. Warf and colleagues published their results of ETV + CPC in 2005; the majority of patients were infants. The long-term outcome and neurocognitive results were reported in later studies and showed that ETV + CPC increased the success rate from 20 to 47% to 63 to 76%. In North American experience, multicentric studies proved the safety of combined ETV/CPC procedure with technical improvement [67–69].

In 2004, Morota described the technique of CPC through a parietal burr hole using a flexible endoscope and monopolar cautery [70]. Warf described the combined ETV/CPC procedure using the flexible endoscope, through a frontal burr hole. Bilateral CPC adds 15–30 minutes to the procedure; adequate coagulation is realized by the blanching of all visible parts of the choroid plexus and the associated blood vessels [61, 66, 67]. The overall mortality (within 30 days of the surgery) was 1.3%. There was no increase in mortality compared to those with ETV alone and those with ETV + CPC [61, 66].

6.2. Communicating hydrocephalus

Patients with postinfectious and posthemorrhagic hydrocephalus have not been included in ETV studies in significant numbers. Instead, such patients are considered by many authors to be prone to failure of ventriculostomy, thus contraindicating ETV [48, 71, 72].

Posthemorrhagic hydrocephalus of prematurity (PHHP) is one of the most common causes of infant hydrocephalus in developed countries; this is mainly due to the high standards of care for prematurely born babies [73].

PHHP occurs when blood in the CSF-filled spaces, together with the initial inflammatory reaction in the ependyma, would lead to obstruction of CSF outflow and hinder absorption, usually by the mechanism of posterior fossa arachnoiditis and aqueductal obstruction. In addition, a diffuse inflammatory reaction in the basal cisterns could coexist, which supports the theory that predict the ETV failure in these cases [73, 74].

On the contrary, putting these in consideration, with the fact that the use of VP shunts in these too young patients carries a high risk of failure, makes trial for an ETV a possible choice for treating this group of patients, and decreasing shunt dependency [73].

A large multicentric retrospective study showed that patients with obstructive hydrocephalus and history of hemorrhage or infection may be candidates for ETV. In this group ETV is reasonably safe, with a success rate that is comparable to the general series. ETV is highly

successful when performed in patients with intraventricular hemorrhage (IVH) and previous shunting; it is also highly successful in patients with primary aqueductal stenosis, while patients with history of both hemorrhage and infection are poor candidates for ETV [72, 73].

Some authors recommended the use of temporary CSF diversion, such as Ommaya reservoir in the acute stage of IVH, and performed the ETV when evidence of ventricular dilatation is obvious [75]. Moreover, in adult patients with IVH, studies showed that endoscopic third ventriculostomy may be an option in cases of acute intracranial hemorrhage with intraventricular extension in which there is clearly established CSF outflow obstruction, with special concern paid toward the surgeon experience [76].

6.3. Redo success rate

The question of in which cases a reclosure of the ETV opening occurs is still not answered. The recent data indicate that failure of ETV may occur immediately after the primary procedure, where the main cause is poor indication of remaining membranes or even years after where it is due to scarring [77, 78]. A redo ETV is supported before deciding to do other CSF diversion procedures whenever a failure was encountered, at which the ETVSS predicts the chance of successful redo ETV. Failure of the ETV and thus redo ETV can be also predicted by the presence of excessive prepontine arachnoid membranes in addition the use of external ventricular drain EVD [78, 79].

6.4. Dandy-Walker malformation

In such cases, hydrocephalus is caused by a large posterior fossa cyst in cases of Dandy-Walker malformation. ETV alone, with aqueductal stent, or with fenestration of the cyst can be sufficient in some cases to control hydrocephalus [80, 81].

Cystoventricular stent placement with endoscopic third ventriculostomy is a promising alternative in patients with Dandy-Walker malformation with aqueductal obstruction [26].

6.5. Normal pressure hydrocephalus

ETV has been recently introduced as a treatment option for normal pressure hydrocephalus. Gangemi et al. mentioned an overall success rate of 72%, in a series of 25 patients [31]. In a larger multicentric study, the clinical improvement reached 69.1%, where the improvement was correlated to the short clinical history, better neurological score before the operation, and the intraoperative appearance of normal cerebral pulsations [82]. Hailong et al. reported an 82.35% success rate and claimed that the preoperative Kiefer score and the patient's age are significant prognostic factors for ETV dysfunction [30]. However, the criteria of patients' selection and the small sample size in most previous literature would justify the actual deficiency of solid evidence that supports ETV as a treatment option in normal pressure hydrocephalus. Large-scale clinical studies are needed to reach better evidence and define the role of ETV in the management of INPH [83].

7. Complications

In a previous literature review, the overall complication rate was 8.5%; among the individual series, the rate ranged from 0 to 31.2%. Complications reported in the immediate postoperative period were mainly hemorrhagic, infectious, subdural collections and CSF leak [84]. These complications represent actually the same complications that can be encountered with the ventricular shunting in exclusion of the hardware-related complications with variable incidence rates that can differ according to the variable age groups.

In conclusion, although ETV is considered a reliable resort to control the hydrocephalus without implanting a shunt, the debate on its success rate is still not finalized especially in young children and communicating hydrocephalus. So that more studies covering those types are warranted.

Author details

Ehab Ahmed El Refaee^{1,2*} and Ahmed A Abdullah¹

*Address all correspondence to: e.elrefaee@googlemail.com

1 Department of Neurosurgery, Cairo University, Egypt

2 Department of Neurosurgery, University Medicine Greifswald, Germany

References

- [1] American Urological Association. Meeting. Philip Bozzini's Lichtleiter. 1971. 2 p
- [2] Fries G, Perneczky A. Intracranial endoscopy. *Advances and Technical Standards in Neurosurgery*. 1999;**25**:21-60
- [3] Dandy WE. Extirpation of the choroid plexus of the lateral ventricles in communicating hydrocephalus. *Annals of Surgery*. 1918 Dec;**68**(6):569-579
- [4] Duffner F, Freudenstein D, Wacker A, Straub-Duffner S, Grote EH. 75 years after Dandy, fay and Mixer--Looking back on the history of neuroendoscopy. *Zentralblatt für Neurochirurgie*. 1998;**59**(2):121-128
- [5] Mixer WJ. Importance of complete examination of the cerebrospinal fluid. *Journal of the American Medical Association*. 1923;**81**(26):2166
- [6] McNickle HF. The surgical treatment of hydrocephalus. A simple method of performing third ventriculostomy. *The British Journal of Surgery*. 1947;**34**(135):302-307
- [7] Schroeder HWS. A new multipurpose ventriculoscope. *Neurosurgery*. 2008 Feb;**62**(2):489-491 discussion 491-2

- [8] Jones RF, Stening WA, Brydon M. Endoscopic third ventriculostomy. *Neurosurgery*. 1990 Jan;**26**(1):86-91 discussion 91-2
- [9] Kelly PJ. Stereotactic third ventriculostomy in patients with nontumoral adolescent/adult onset aqueductal stenosis and symptomatic hydrocephalus. *Journal of Neurosurgery*. 1991 Dec;**75**(6):865-873
- [10] Oka K, Yamamoto M, Ikeda K, Tomonaga M. Flexible endoneurosurgical therapy for aqueductal stenosis. *Neurosurgery*. 1993 Aug;**33**(2) 236-42; discussion 242-3
- [11] Jallo GI, Kothbauer KF, Abbott IR. Endoscopic third ventriculostomy. *Neurosurgical Focus*. 2005 Dec 15;**19**(6) E11
- [12] Resch KDM, Perneczky A, Tschabitscher M, Kindel S. Endoscopic anatomy of the ventricles. In: *Minimally Invasive Neurosurgery II*. Vienna: Springer; 1994. pp. 57-61
- [13] Zohdi A, Elkheshin S. Endoscopic anatomy of the velum interpositum: A sequential descriptive anatomical study. *Asian Journal of Neurosurgery*. 2012 Jan;**7**(1):12-16
- [14] Riegel T, Hellwig D, Bauer BL, Mennel HD. Endoscopic anatomy of the third ventricle. *Advances in Neurosurgery*. 1994:121-125
- [15] Dusick JR, McArthur DL, Bergsneider M. Success and complication rates of endoscopic third ventriculostomy for adult hydrocephalus: A series of 108 patients. *Surgical Neurology*. 2008 Jan;**69**(1):5-15
- [16] Jellinger G. Anatomopathology of non-tumoral aqueductal stenosis. *Journal of Neurosurgical Sciences*. 1986 Jan;**30**(1-2):1-16
- [17] Kulkarni AV, Hui S, Shams I, Donnelly R. Quality of life in obstructive hydrocephalus: Endoscopic third ventriculostomy compared to cerebrospinal fluid shunt. *Child's Nervous System*. 2010 Jan;**26**(1):75-79
- [18] Lapras C, Bret P, Patet JD, Huppert J, Honorato D. Hydrocephalus and aqueduct stenosis. Direct surgical treatment by interventriculostomy (aqueduct canulation). *Journal of Neurosurgical Sciences*. 1986 Jan;**30**(1-2):47-53
- [19] Sankey EW, Goodwin CR, Jusué-Torres I, Elder BD, Hoffberger J, Lu J, et al. Lower rates of symptom recurrence and surgical revision after primary compared with secondary endoscopic third ventriculostomy for obstructive hydrocephalus secondary to aqueductal stenosis in adults. *Journal of Neurosurgery*. 2016 May;**124**(5):1413-1420
- [20] Buxton N, Ho KJ, Macarthur D, Vloeberghs M, Punt J, Robertson I. Neuroendoscopic third ventriculostomy for hydrocephalus in adults: Report of a single unit's experience with 63 cases. *Surgical Neurology*. 2001;**55**(2):74-78
- [21] Morgenstern PF, Souweidane MM. Pineal Region Tumors: Simultaneous Endoscopic Third Ventriculostomy and Tumor Biopsy. *World Neurosurgery*. 2013;**79**(2):S18.e9-S18.e13
- [22] Wellons JC, Shane Tubbs R, Banks JT, Grabb B, Blount JP, Jerry Oakes W, et al. Long-term control of hydrocephalus via endoscopic third ventriculostomy in children with tectal plate gliomas. *Neurosurgery*. 2002;**51**(1):63-68

- [23] Li KW, Roonprapunt C, Lawson HC, Rick Abbott I, Wisoff J, Epstein F, et al. Endoscopic third ventriculostomy for hydrocephalus associated with tectal gliomas. *Neurosurgical Focus*. 2005;**18**(6):1-4
- [24] Cinalli G, Sainte-Rose C, Chumas P, Zerah M, Brunelle F, Lot G, et al. Failure of third ventriculostomy in the treatment of aqueductal stenosis in children. *Journal of Neurosurgery*. 1999 Mar;**90**(3):448-454
- [25] Kulkarni AV, Riva-Cambrin J, Holubkov R, Browd SR, Cochrane DD, Drake JM, et al. Endoscopic third ventriculostomy in children: Prospective, multicenter results from the hydrocephalus clinical research network. *Journal of Neurosurgery. Pediatrics*. 2016 Oct;**18**(4):423-429
- [26] Mohanty A. Endoscopic third ventriculostomy with cystoventricular stent placement in the management of dandy-walker malformation: Technical case report of three patients. *Neurosurgery*. 2003 Nov;**53**(5):1223-1228 discussion 1228-9
- [27] Decq P, Le Guérinel C, Sol JC, Brugières P, Djindjian M, Nguyen JP. Chiari I malformation: A rare cause of noncommunicating hydrocephalus treated by third ventriculostomy. *Journal of Neurosurgery*. 2001 Nov;**95**(5):783-790
- [28] Métellus P, Dufour H, Levrier O, Grisoli F. Endoscopic third ventriculostomy for treatment of noncommunicating syringomyelia associated with a Chiari I malformation and hydrocephalus: Case report and pathophysiological considerations. *Neurosurgery*. 2002 Aug;**51**(2):500-503 discussion 503-4
- [29] Buxton N, Jaspan T, Punt J. Treatment of chiari malformation, syringomyelia and hydrocephalus by neuroendoscopic third ventriculostomy. *Minimally Invasive Neurosurgery*. 2002 Dec;**45**(4):231-234
- [30] Hailong F, Guangfu H, Haibin T, Hong P, Yong C, Weidong L, et al. Endoscopic third ventriculostomy in the management of communicating hydrocephalus: A preliminary study. *Journal of Neurosurgery*. 2008 Nov;**109**(5):923-930
- [31] Gangemi M, Maiuri F, Buonamassa S, Colella G, de Divitiis E. Endoscopic third ventriculostomy in idiopathic normal pressure hydrocephalus. *Neurosurgery*. 2004;**55**(1):129-134
- [32] Meier U, Zeilinger FS, Schönherr B. Endoscopic ventriculostomy versus shunt operation in normal pressure hydrocephalus: Diagnostics and indication. *Acta Neurochirurgica. Supplement*. 2000;**76**:563-566
- [33] Schroeder HWS, Warzok RW, Assaf JA, Gaab MR. Fatal subarachnoid hemorrhage after endoscopic third ventriculostomy. *Neurosurgical Focus*. 1999;**6**(4):E6
- [34] Weil AG, Fallah A, Chamiraju P, Ragheb J, Bhatia S. Endoscopic third ventriculostomy and choroid plexus cauterization with a rigid neuroendoscope in infants with hydrocephalus. *Journal of Neurosurgery. Pediatrics*. 2015 Oct 30:1-11
- [35] Kulkarni AV, Drake JM, Kestle JRW, Mallucci CL, Sgouros S, Constantini S, et al. Predicting who will benefit from endoscopic third ventriculostomy compared with

- shunt insertion in childhood hydrocephalus using the ETV success score. *Journal of Neurosurgery. Pediatrics*. 2010 Oct;**6**(4):310-315
- [36] Romero L, Ros B, Ibáñez G, Rius F, González L, Arráez M. Endoscopic third ventriculostomy: Can we predict success during surgery? *Neurosurgical Review*. 2014 Jan;**37**(1):89-97
- [37] Neils DM, Wang H, Lin J. Endoscopic third ventriculostomy for shunt malfunction: What to do with the shunt? *Surgical Neurology International*. 2013 Jan 15;**4**:3
- [38] Nejat F, El Khashab M. Endoscopic third ventriculostomy for shunt malfunction. *Surgical Neurology International*. 2013;**4**(1):56
- [39] Nikas DC, Post AF, Choudhri AF, Mazzola CA, Mitchell L, Flannery AM, et al. Pediatric hydrocephalus: Systematic literature review and evidence-based guidelines. Part 10: Change in ventricle size as a measurement of effective treatment of hydrocephalus. *Journal of Neurosurgery. Pediatrics*. 2014 Nov;**14**(Suppl 1):77-81
- [40] Constantini S, Siomin V. Death after late failure of endoscopic third Ventriculostomy: A potential solution. *Neurosurgery*. 2005;**56**(3):E629-E629
- [41] O'Brien DF, Javadpour M, Collins DR, Spennato P, Endoscopic MCL. Third ventriculostomy: An outcome analysis of primary cases and procedures performed after ventriculoperitoneal shunt malfunction. *Journal of Neurosurgery*. 2005 Nov;**103**(Suppl 5):393-400
- [42] Cinalli G, Salazar C, Mallucci C, Yada JZ, Zerah M, Sainte-Rose C. The role of endoscopic third ventriculostomy in the management of shunt malfunction. *Neurosurgery*. 1998 Dec;**43**(6):1323-1327 discussion 1327-9
- [43] Baldauf J, Fritsch MJ, Oertel J, Gaab MR, Schröder H. Value of endoscopic third ventriculostomy instead of shunt revision. *Minimally Invasive Neurosurgery*. 2010 Aug;**53**(4):159-163
- [44] Hayhurst C, Osman-Farah J, Das K, Mallucci C. Initial management of hydrocephalus associated with chiari malformation type I-syringomyelia complex via endoscopic third ventriculostomy: An outcome analysis. *Journal of Neurosurgery*. 2008 Jun;**108**(6):1211-1214
- [45] Milhorat TH, Chou MW, Trinidad EM, Kula RW, Mandell M, Wolpert C, et al. Chiari I malformation redefined: Clinical and radiographic findings for 364 symptomatic patients. *Neurosurgery*. 1999 May;**44**(5):1005-1017
- [46] Sinclair N, Assaad N, Johnston I. Pseudotumor cerebri occurring in association with the Chiari malformation. *Journal of Clinical Neuroscience*. 2002 Jan;**9**(1):99-101
- [47] Erşahin Y, Gökçay A. Acquired Chiari I malformation changes postendoscopic third ventriculostomy. *Pediatric Neurosurgery*. 2002;**36**(1):54-54
- [48] Fukuhara T, Vorster SJ, Luciano MG. Risk factors for failure of endoscopic third ventriculostomy for obstructive hydrocephalus. *Neurosurgery*. 2000 May;**46**(5):1100-1109 discussion 1109-11

- [49] Kandasamy J, Kneen R, Gladstone M, Newman W, Mohamed T, Mallucci C. Chiari I malformation without hydrocephalus: Acute intracranial hypertension managed with endoscopic third ventriculostomy (ETV). *Child's Nervous System*. 2008 Dec;**24**(12):1493-1497
- [50] Mohanty A, Suman R, Shankar SR, Satish S, Praharaj SS. Endoscopic third ventriculostomy in the management of Chiari I malformation and syringomyelia associated with hydrocephalus. *Clinical Neurology and Neurosurgery*. 2005 Dec;**108**(1):87-92
- [51] Wagner W, Koch D. Mechanisms of failure after endoscopic third ventriculostomy in young infants. *Journal of Neurosurgery*. 2005 Jul;**103**(Suppl 1):43-49
- [52] Fritsch MJ, Kienke S, Ankermann T, Padoin M, Mehdorn HM. Endoscopic third ventriculostomy in infants. *Journal of Neurosurgery*. 2005 Jul;**103**(Suppl 1):50-53
- [53] Cinalli G. Alternatives to shunting. *Child's Nervous System*. 1999;**15**(11-12):718-731
- [54] Grunert P, Charalampaki P, Hopf N, Filippi R. The role of third ventriculostomy in the management of obstructive hydrocephalus. *Minimally Invasive Neurosurgery*. 2003 Feb;**46**(1):16-21
- [55] Javadpour M, Mallucci C, Brodbelt A, Golash A, May P. The impact of endoscopic third ventriculostomy on the management of newly diagnosed hydrocephalus in infants. *Pediatric Neurosurgery*. 2001 Sep;**35**(3):131-135
- [56] Mohanty A, Vasudev MK, Sampath S, Radhesh S, Sastry Kolluri VR. Failed endoscopic third ventriculostomy in children: Management options. *Pediatric Neurosurgery*. 2002 Dec;**37**(6):304-309
- [57] Cohen AR. Endoscopic ventricular surgery. *Pediatric Neurosurgery*. 1993;**19**(3):127-134
- [58] Cohen AR. Ventriculoscopy surgery. *Clinical Neurosurgery*. 1994;**41**:546-562
- [59] Kunz U, Goldmann A, Bader C, Waldbaur H, Oldenkott P. Endoscopic fenestration of the 3rd ventricular floor in Aqueductal stenosis. *Minimally Invasive Neurosurgery*. 1994;**37**(02):42-47
- [60] Beems T, Grotenhuis JA. Is the success rate of endoscopic third ventriculostomy age-dependent? An analysis of the results of endoscopic third ventriculostomy in young children. *Childs Nervous System*. 2002 Nov;**18**(11):605-608
- [61] Zhu X, Di Rocco C. Reply to the letter from Drs. JA Malheiros, MM Oliveira & P Steinbok "re: Zhu X et al.: Choroid plexus coagulation for hydrocephalus not due to CSF overproduction: A review". *Child's Nervous System*. 2013 Jul;**29**(7):1059
- [62] Di Rocco C, Iannelli A. Poor outcome of bilateral congenital choroid plexus papillomas with extreme hydrocephalus. *European Neurology*. 1997;**37**(1):33-37
- [63] Philips MF, Shanno G, Duhaime AC. Treatment of villous hypertrophy of the choroid plexus by endoscopic contact coagulation. *Pediatric Neurosurgery*. 1998 May;**28**(5):252-256

- [64] Tamburrini G, Caldarelli M, Di Rocco F, Massimi L, D'Angelo L, Fasano T, et al. The role of endoscopic choroid plexus coagulation in the surgical management of bilateral choroid plexuses hyperplasia. *Child's Nervous System*. 2006;**22**(6):605-608
- [65] Warren DT, Henderson G, Cochrane DD. Bilateral choroid plexus hyperplasia: A case report and management strategies. *Child's Nervous System*. 2009 Dec;**25**(12):1617-1622
- [66] Warf BC. Comparison of endoscopic third ventriculostomy alone and combined with choroid plexus cauterization in infants younger than 1 year of age: A prospective study in 550 African children. *Journal of Neurosurgery*. 2005 Dec;**103**(Suppl 6):475-481
- [67] Warf BC, Campbell JW. Combined endoscopic third ventriculostomy and choroid plexus cauterization as primary treatment of hydrocephalus for infants with myelomeningocele: Long-term results of a prospective intent-to-treat study in 115 east African infants. *Journal of Neurosurgery. Pediatrics*. 2008 Nov;**2**(5):310-316
- [68] Warf B, Ondoma S, Kulkarni A, Donnelly R, Ampeire M, Akona J, et al. Neurocognitive outcome and ventricular volume in children with myelomeningocele treated for hydrocephalus in Uganda. *Journal of Neurosurgery. Pediatrics*. 2009 Dec;**4**(6):564-570
- [69] Kulkarni AV, Riva-Cambrin J, Browd SR, Drake JM, Holubkov R, Kestle JRW, et al. Endoscopic third ventriculostomy and choroid plexus cauterization in infants with hydrocephalus: A retrospective hydrocephalus clinical research network study. *Journal of Neurosurgery. Pediatrics*. 2014 Sep;**14**(3):224-229
- [70] Morota N, Fujiyama Y. Endoscopic coagulation of choroid plexus as treatment for hydrocephalus: Indication and surgical technique. *Child's Nervous System*. 2004 Nov;**20**(11-12):816-820
- [71] Gangemi M, Donati P, Maiuri F, Longatti P, Godano U, Mascari C. Endoscopic third ventriculostomy for hydrocephalus. *Minimally Invasive Neurosurgery*. 1999 Sep;**42**(3):128-132
- [72] Siomin V, Cinalli G, Grotenhuis A, Golash A, Oi S, Kothbauer K, et al. Endoscopic third ventriculostomy in patients with cerebrospinal fluid infection and/or hemorrhage. *Journal of Neurosurgery*. 2002;**97**(3):519-524
- [73] Warf BC, Campbell JW, Riddle E. Initial experience with combined endoscopic third ventriculostomy and choroid plexus cauterization for post-hemorrhagic hydrocephalus of prematurity: The importance of prepontine cistern status and the predictive value of FIESTA MRI imaging. *Child's Nervous System*. 2011 Jul;**27**(7):1063-1071
- [74] Boop FA. Posthemorrhagic hydrocephalus of prematurity. *Pediatric Hydrocephalus*. 2005:121-131
- [75] Peretta P, Ragazzi P, Carlino CF, Gaglini P, Cinalli G. The role of Ommaya reservoir and endoscopic third ventriculostomy in the management of post-hemorrhagic hydrocephalus of prematurity. *Child's Nervous System*. 2007 Jul;**23**(7):765-771

- [76] Oertel JMK, Mondorf Y, Baldauf J, Schroeder HWS, Gaab MR. Endoscopic third ventriculostomy for obstructive hydrocephalus due to intracranial hemorrhage with intraventricular extension. *Journal of Neurosurgery*. 2009 Dec;**111**(6):1119-1126
- [77] Siomin V, Weiner H, Wisoff J, Cinalli G, Pierre-Kahn A, Saint-Rose C, et al. Repeat endoscopic third ventriculostomy: Is it worth trying? *Child's Nervous System*. 2001;**17**(9):551-555
- [78] Hellwig D, Giordano M, Kappus C. Redo Third ventriculostomy. *World Neurosurgery*. 2013;**79**(2):S22.e13-S22.e20
- [79] Breimer GE, Dammers R, Woerdeman PA, Buis DR, Delye H, Brusse-Keizer M, et al. Endoscopic third ventriculostomy and repeat endoscopic third ventriculostomy in pediatric patients: The Dutch experience. *Journal of Neurosurgery. Pediatrics*. 2017 Oct;**20**(4):314-323
- [80] Hu C-F, Fan H-C, Chang C-F, Wang C-C, Chen S-J. Successful treatment of Dandy-Walker syndrome by endoscopic third Ventriculostomy in a 6-month-old girl with progressive hydrocephalus: A case report and literature review. *Pediatrics & Neonatology*. 2011;**52**(1):42-45
- [81] Mohanty A, Biswas A, Satish S, Praharaj SS, Sastry KVR. Treatment options for Dandy-Walker malformation. *Journal of Neurosurgery. Pediatrics*. 2006;**105**(5):348-356
- [82] Gangemi M, Maiuri F, Naddeo M, Godano U, Mascari C, Broggi G, et al. Endoscopic third ventriculostomy in idiopathic normal pressure hydrocephalus: An Italian multi-center study. *Neurosurgery*. 2008 Jul;**63**(1):62-67 discussion 67-9
- [83] Tasiou A, Brotis AG, Esposito F, Paterakis KN. Endoscopic third ventriculostomy in the treatment of idiopathic normal pressure hydrocephalus: A review study. *Neurosurgical Review*. 2016 Oct;**39**(4):557-563
- [84] Bouras T, Complications SS. Of endoscopic third Ventriculostomy: A systematic review. In: *Acta Neurochirurgica Supplementum*. 2011. pp. 149-153

