

We are IntechOpen, the world's leading publisher of Open Access books Built by scientists, for scientists

6,900

Open access books available

186,000

International authors and editors

200M

Downloads

Our authors are among the

154

Countries delivered to

TOP 1%

most cited scientists

12.2%

Contributors from top 500 universities



WEB OF SCIENCE™

Selection of our books indexed in the Book Citation Index
in Web of Science™ Core Collection (BKCI)

Interested in publishing with us?
Contact book.department@intechopen.com

Numbers displayed above are based on latest data collected.
For more information visit www.intechopen.com



Prosthetic Reconstruction of the Upper Digestive Tract

Șerban V.G. Berteșteanu, Alexandru Nicolaescu,
Bogdan Popescu and Raluca Grigore

Additional information is available at the end of the chapter

<http://dx.doi.org/10.5772/intechopen.73101>

Abstract

In cases of locally advanced cancers involving the junction between the hypopharynx and cervical oesophagus, the curative surgical treatment is total circular laryngo-pharyngectomy with resection of the upper cervical oesophagus, coupled with modified radical neck dissection. Techniques used to re-establish the continuity of the digestive tract have been pectoral transposition flap, gastric pull-up, jejunum or colon transposition and free pedicled fascial-cutaneous flap reconstruction. Prosthetic reconstruction was thought of and used only as a temporary solution. In our clinic, we adapted the Montgomery oesophageal prosthesis as more than just a temporary solution and used it in 63 patients operated from 2004 to 2014 with advanced (stages III and IV) cancer involving most of the hypopharynx or extending towards the upper cervical oesophagus. Following total circular laryngo-pharyngectomy with bilateral modified radical neck dissection, prosthetic reconstruction was performed using the Montgomery oesophageal tube. Patients were followed up on, and their status was monitored. Favourable results encouraged the authors to further develop a new active prosthesis, with advanced design and materials that better mimic the anatomy and physiology of the replaced segment. Prosthetic reconstruction of the upper digestive tract following radical oncologic surgery is a viable option, with advantages compared to other laborious plastic techniques. The new active model is under development, hopefully offering soon a safe and more cost-effective alternative to the other techniques.

Keywords: laryngo-pharyngectomy, prosthetic reconstruction, Montgomery tube, active prosthesis, Cristian Radu Popescu

1. Introduction

Cancer of the head and neck is generally a low prevalence type of malignancy, amounting to roughly 3% of all cancers in the United States [1]. This is a broad term used to address all

types of cancer in this anatomic region, but to put things in perspective, there are more than 10 different organs in the head and neck region (that is excluding the brain and the eye—each studied by a separate surgical specialty), some with more than three subsites and each with more than five types of cancer that may arise in it and, depending on the organ, subsite, extension and type of malignancy, a different treatment approach.

The central and arguably the most important aspect of the neck region is the intersection between the airway and the digestive tract. Seeing as breathing and feeding are both vital functions performed through the upper aerodigestive tract, by a complex interaction between the nose, pharynx, tongue and larynx, tumours which develop in this region will affect these essential functions.

The treatment of malignant tumours involving the pharynx and larynx depends on the subsite involved, extension of the tumour (classified using the AJCC TNM staging system), histologic type, general condition and preference of the patient.

Options include surgical resection of the tumour (referred to as treating the T—from the TNM classification) [2] coupled with excision of the lymph nodes that provide the lymphatic drainage from the respective area (called addressing the N, following the same logic), radiation therapy or chemotherapy. The more advanced the tumour, the more aggressive and complex the treatment must be, and usually a combination of surgery, radiation and chemotherapy is used.

A particular situation arises when treating locally advanced tumours that involve the whole circumference of the hypopharynx or extend to the upper cervical oesophagus. To respect the oncologic principles, the resection needs to encompass all of the hypopharynx as well as the larynx and depending on the case a portion of the upper cervical oesophagus. The result is a large defect between the base of the tongue and the rest of the cervical oesophagus. This defect needs to be repaired if oral feeding is to be re-established.

2. Relevant anatomy and physiology of deglutition

Depending on the grounds for classification (embryologic, gross anatomy, regarding bleeding—clinical basis), the upper digestive tract is defined as the anatomic area stretching from the mouth to the duodenum, colon or ileum. For the better part of our knowledge, prosthetic reconstruction has not been utilised elsewhere in the gastrointestinal tract except for the larynx, pharynx and upper oesophagus, so for simplification and to better serve our purpose, we shall further refer to the upper digestive tract as the area stretching from the mouth to the cervical oesophagus.

The major structure of the aerodigestive tract is the larynx. It is a complex cartilaginous, mobile structure, which is essential to four functions: breathing, speaking, swallowing and physical effort [3]. Around it lies the pharynx—the third and inferior part of the pharynx to be exact, called the hypopharynx (or laryngopharynx). They are connected by the three separate constrictor muscles of the pharynx: the superior, middle and inferior constrictor muscles.

These two structures are inseparable because of their role in performing the two most essential functions of the human body—breathing and eating. During breathing the larynx keeps the airway open, by pulling the vocal cords apart from each other and pushing the epiglottis in an upright position, to exert minimal resistance to the passage of air from the nose and mouth through the trachea. During deglutition (swallowing) however, the airway needs to be protected from aspiration of food and liquids into the trachea and lungs. Then the larynx is moved forwards and upwards; the epiglottis descends into a horizontal position, acting as a cover for the vocal cords. These at the same time come together to form an airtight seal of the trachea. The hypopharynx relaxes, and the upper oesophageal sphincter opens, so as to create a clear path for the food and liquids to pass through this region downwards to the stomach [4].

3. Cancer of the pharyngo-oesophageal junction

3.1. Diagnosis and treatment

Malignant tumours may affect the pharyngo-oesophageal junction area by arising at this site (rare cases of chondrosarcoma of the cricoid ring) or by extension from other neighbouring areas (most frequent: tumours of the hypopharynx—the pyriform sinuses and the posterior wall of the hypopharynx—the larynx, especially subglottic tumours; as well as tumours of the cervical oesophagus) or even as metastases from other organs. A not-so-rare occurrence is the so-called skip lesions of the oesophagus—two or more synchronous tumours at various subsites of the oesophagus—with direct contact between them [5].

Signs and symptoms of tumour extension to the pharyngo-oesophageal junction are nonspecific and for this reason are often overlooked. These include odynophagia (pain on swallowing); progressive dysphagia (difficulty swallowing), first for solid food and, later on, as the tumour grows, for liquids; and weight loss [6]. Other signs may be due to lymph node involvement—the presence of neck masses, ulceration of the tumour with infection of the necrotised tissue—fever, elevated white blood cell count and inflammatory response (elevated sedimentation rate, C reactive protein, fibrinogen).

Diagnosis is based on clinical examination, endoscopic examination, imagery (contrast enhanced CT scan or MRI—which have to include the neck and thorax—to properly evaluate the whole oesophagus as well as the lungs and liver, organs where metastases frequently occur), and the definitive diagnosis is based on the histologic findings; therefore, biopsy is compulsory [7].

After definitive diagnosis, based on the AJCC TNM classification, the disease is classified in two major categories: local disease and systemic (metastatic) disease. In the first situation, if surgically resectable (excluding T4b tumours), if the patient has a good enough general status to permit surgery and if it is desired, treatment should be surgical resection with reconstruction so as to obtain a functional outcome [7].

3.2. Methods of reconstruction

The principles that should govern how we choose a reconstructive technique are one-step procedure, low mortality, low morbidity, reduced hospital stay, shortest possible time to oral feeding, shortest time to vocal rehabilitation, minimal or no interference with subsequent radiation therapy and lowest cost [6].

Techniques used for reconstruction of the upper digestive tract following total laryngopharyngectomy are fascial-cutaneous pedicled-free grafts, local transposition flaps, gastric pull-up technique, jejunum-free transfer or colon transposition [8].

Complex interventions require trained specialists in plastic surgery and even general surgery. Performing such laborious surgery requires a multidisciplinary approach, with one team performing the excision of the larynx and pharynx as well as the neck dissection while the other harvests the ileum or colon or prepares the graft for implantation. Such surgeries are very demanding in terms of resources and time, routinely lasting more than 7 or 8 h.

The advantages of these techniques are that they use homografts, tissues from the patient's body—which are the ideal material for reconstruction. Once properly healed, the result is definitive, and a satisfactory functional outcome is achieved.

However, they are still prone to necrosis by way of vascular thrombosis, either postoperatively or at a later time, during chemo- or radiation therapy. This leads to septic complications and salivary fistulae, which if left untreated extend gradually. Complications impair oral feeding, thus the necessity for a second plastic revision surgery or a gastrostomy/jejunostomy, which in turn may lead to higher hospitalisation time and a higher mortality rate.

4. Patients and methods

Until the year 2001, most patients with tumours we would nowadays consider resectable which involved the pharyngo-oesophageal junction were either referred to radiation therapy (after tracheotomy and gastrostomy) or to specialised tertiary-care centres with both plastic and general surgery clinics where one-stage plastic reconstructions were performed. The few cases operated in our clinic had a poor quality of life after surgery—because the reconstruction was performed at a later moment (two stage surgery), meaning oral feeding was impossible for months. From 2001, Professor Popescu started using the Montgomery oesophageal prosthesis to rebuild the continuity of the digestive tract, first as a bridging solution—a temporary state—until definitive reconstruction using homografts was performed. From 2004 until 2014, 63 patients with locally advanced tumours involving the pharyngo-oesophageal junction were operated in the ENT Head and Neck Surgery Clinic of Colțea Clinical Hospital Bucharest. In all 63 cases, after total circular laryngo-pharyngectomy with bilateral cervical lymph node dissection (**Figure 1**), reconstruction was performed using the C.R. Popescu technique (using a Montgomery oesophageal tube). No other reconstruction technique was used on these

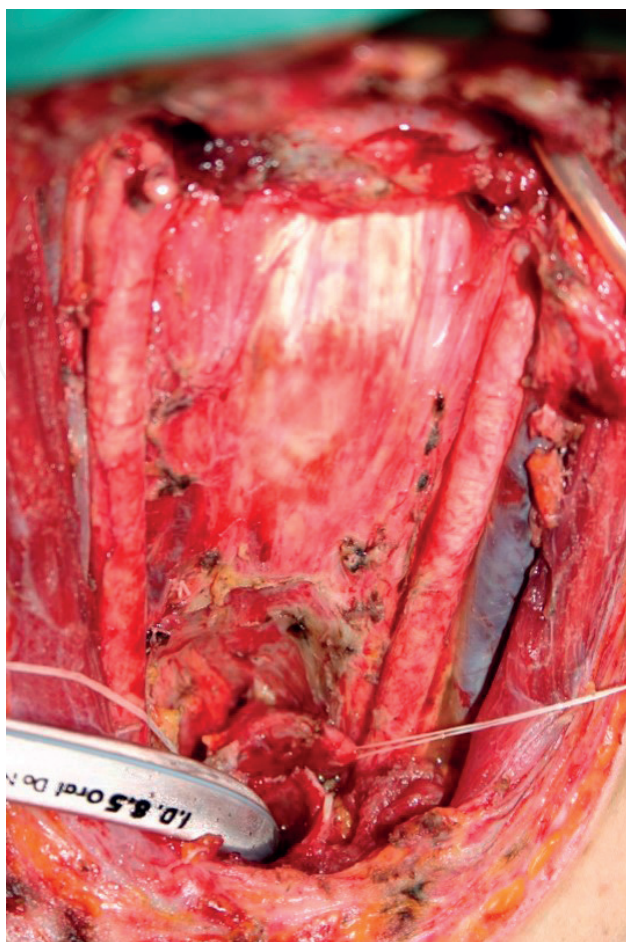


Figure 1. Intraoperative aspect after total circular laryngo-pharyngectomy—with both carotid arteries visible, as well as the trachea and cervical oesophagus.

patients, and all of them were followed up, and data was recorded regarding survival, complications and complementary oncology therapies.

5. Prosthetic reconstruction: the C.R. Popescu technique

The technique developed by Professor Cristian Radu Popescu, first used in 2004, in the ENT Clinic of “Colțea” Clinical Hospital Bucharest, is an adaptation, which uses an already existing product—the Montgomery[®] oesophageal tube (manufactured by Boston Medical Products[®] Shrewsbury, Massachusetts, USA) (**Figure 2**). This was intended as a temporary prosthesis between the first, ablative, step of surgery and the second, reconstructive, step of the total pharyngo-laryngectomy with plastic reconstruction, using one of the multiple methods described.

However, Professor Popescu observed that the health status of the patients implanted with this prosthesis was rapidly improved and that oral feeding was quickly re-established (14 days post-operatively). That this method permitted the subsequent radiation therapy and chemotherapy

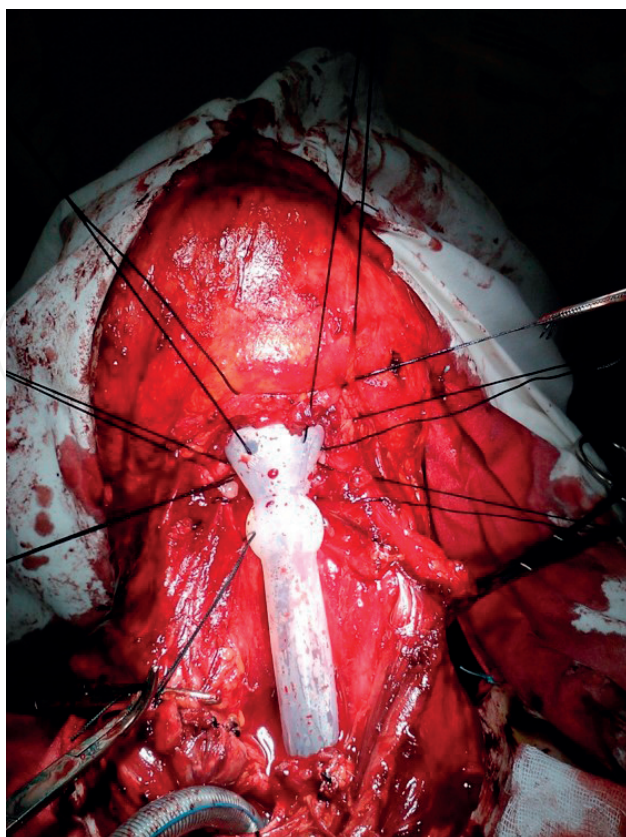


Figure 2. Montgomery oesophageal tube in place, with sutures placed along the cranial end, tying it to the tongue base and the oropharynx.

was an added advantage, and it was observed that complication rates were similar to those obtained by primary plastic reconstruction using autografts.

The procedure is straightforward, in that after total circular laryngo-pharyngectomy, the Montgomery tube is placed into position, with the wider cranial end towards the tongue base

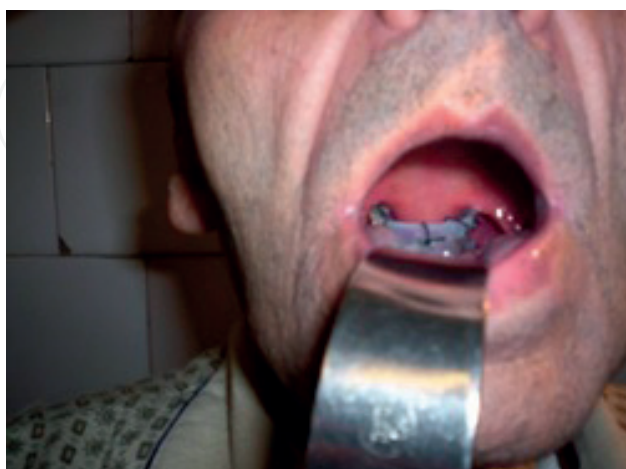

Figure 3. Initial salivary fistula which evolved to a necrosis of the skin and underlying tissues, exposing the otherwise functioning prosthesis. A sternocleidomastoid cutaneous pedicled flap was used to repair the defect, with favourable result.

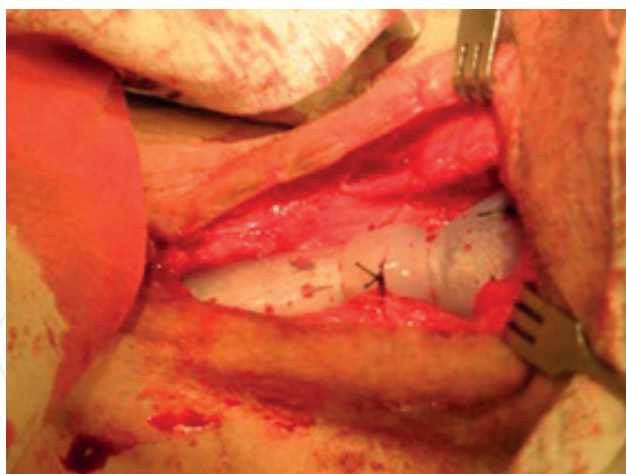


Figure 4. Design of the active pharyngo-oesophageal prosthesis—patent number A00292—developed by the team of Assoc. Professor Dr. Berteşteanu and under the guidance of Professor Cristian Radu Popescu, with support from colleagues from the Physics Faculty of the Politehnica University of Bucharest.

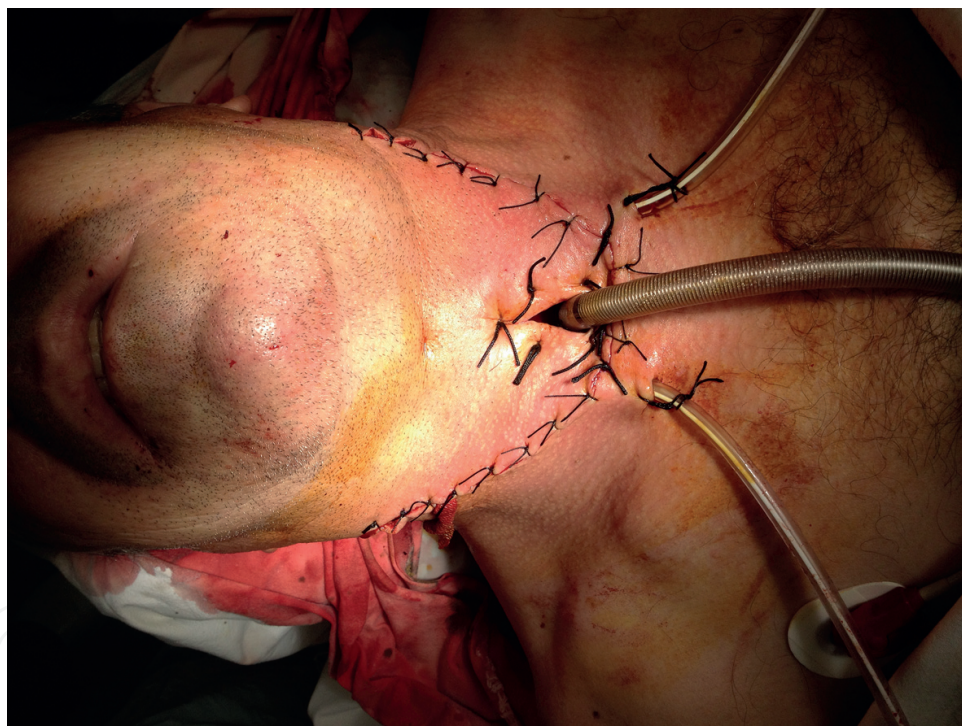

Figure 5. Prosthesis spontaneous expulsion due to improper fixation and dehiscence of the tongue base suture lines.

and the narrow distal end placed into the cervical oesophagus [6]. After approximation, the cranial end is sutured to the tongue base with non-resorbable silk 2.0 sutures (usually no more than six sutures along the whole radius of the tube) (**Figure 2**).

From our experience and the complications we encountered, two more suture lines should be placed, stabilising the prosthesis to the prevertebral fascia, so as to prevent slipping towards the tongue base (**Figures 3 and 4**).

After prosthesis placement and fixation, the prelaryngeal strap muscles are approximated to the tongue base forming a layer over the silicone tube, using slow resorbable sutures. A nasogastric feeding tube is placed through the prosthesis, to act as a protection measure. The rest of the procedure is similar to a normal laryngectomy, with the creation of the permanent tracheostoma, and wound closure (**Figure 5**).

Postoperative measures are enteral feeding through the nasogastric tube for 14 days minimum, broad spectrum antibiotics for 7 days, antisecretory medication for reducing salivary secretions (atropine) and proton-pump inhibitors for the as long as the feeding tube is in place. Ancillary measures we use in these patients are nutritional support using special enteral formulas, so as to correct malnutrition. After testing for salivary fistulae, the feeding tube is removed, and oral feeding is commenced. Barring complications, the patient is discharged around 7 days post-op [8].

6. Results

After performing an in-house analysis of this method on the 63 cases operated from 2004 to 2014 [6], data showed a higher prevalence of the disease in men 54 patients (86%) versus women 9 patients (14%). Patient age varied from 34 years to 73 years, with a mean age of 56 years. Ninety-two percent of the cases were confirmed after histopathological examination as squamous cell carcinomas. Ninety-three percent of patients were smokers, having smoked more than 20 years on average one pack of cigarettes per day. All of the cases were staged using the AJCC TNM [2] classification as III, IV A and IV B stages of disease. Biologic measurements were available in 90% of the patients (height and weight—permitting us to calculate the body mass index), and all of them had malnutrition, with less than 20 kg/m² BMI.

Survival data were obtained only in 28 patients, because of the lack of follow-up. In these patients, survival after 2 years was 56.14% and at 5 years post-op. Only 14.28% were still alive.

Complications encountered were gastro-oesophageal acid reflux (diagnosed only on clinical examination) in 33% of cases, wound infections in 20.63% of cases, salivary fistulae in 17.46% of cases and dysphagia (due to obliteration of the caudal end of the prosthesis) in 12.69% of cases.

Concerning operative time, the mean was 4 h and 20 min, (from skin opening to skin closure, including neck dissection), and hospital stay was a mean of 16 days, with a mean preoperative hospitalisation of 4 days and 13 days postoperative until discharge.

7. Advantages and limitations

The C.R. Popescu technique is a surgical method that permits tackling a difficult surgical intervention without the need for another specialist surgeon (plastic or general surgeon). It is time efficient, shortening the duration of surgery, and has a relative short ICU stay and hospitalisation period. The patient is quickly reintroduced to oral feeding, and complication rates are similar, if not lower to other techniques of plastic reconstruction [9, 10].

Its limitation is due to the prosthesis itself and the interaction with the tissues surrounding it. The shape and the simple construction mean that the lumen is always open and the only force acting on the ingested food or liquids is gravity. This, associated with a widening of the upper oesophagus (due to accommodation of the caudal tip) and the loss of the peristaltic movements and sphincter action of the hypopharynx, leads to regurgitation and acid reflux. The

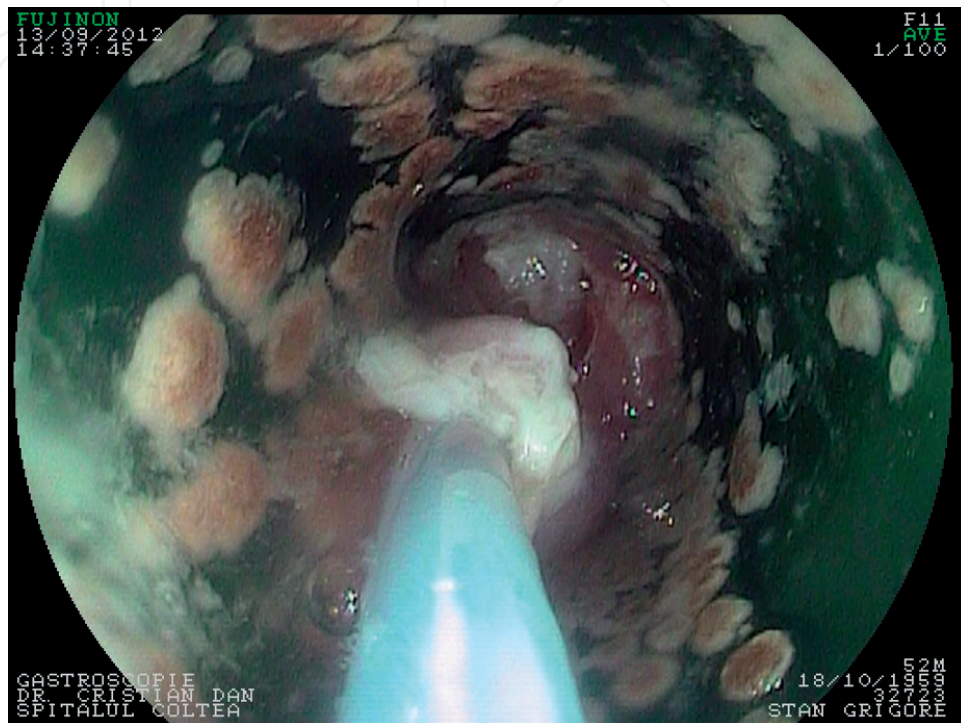


Figure 6. Stabilisation of the prosthesis with sutures to the prevertebral fascia and muscles.

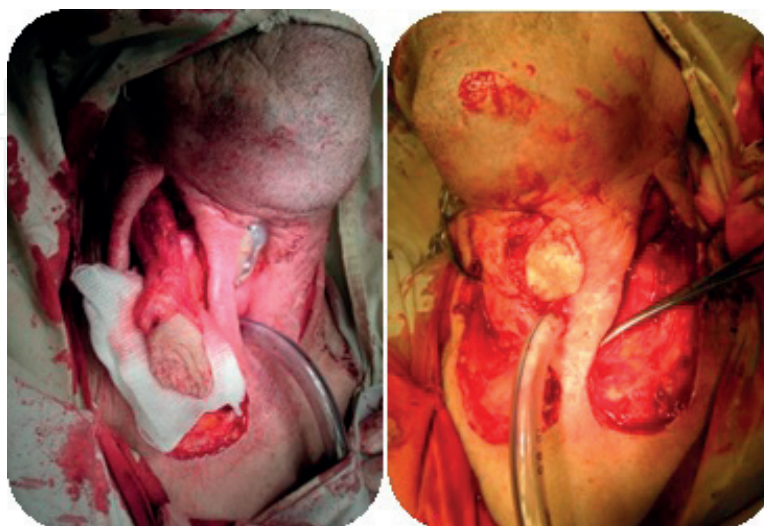


Figure 7. Endoscopic evaluation of the Montgomery prosthesis 14 days after implantation, with biofilm formation and bacterial and Candida colonies all around the circumference of the tube.

material of the prosthesis provides no defence against bacterial colonisation, and we have found that even 2 weeks after implantation, the whole length of the prosthesis is already colonised by bacterial biofilm formation (**Figure 6**).

Due to foreign body reaction, as well as the septic environment and constant acid reflux, we have found that in almost 13% of cases, dysphagia appears. Salivary fistulae appeared in 17.4% of patients. Endoscopy showed in all these cases the obliteration of the caudal end of the prosthesis with granulation tissue. Dysphagia renders the prosthesis useless; therefore, either a second plastic reconstruction using autologous tissue or a gastrostomy is necessary (**Figure 7**).

8. Active prosthesis

The shortcomings of the simple Montgomery tube, as well as the newer devices with active coatings that prevent biofilm formation and subsequent degradation (the indwelling vocal prostheses) [11], have prompted the authors to design a new model of implantable prosthesis. The goal was to create a perfect device—biocompatible, effective, with resistance to biofilm formation and, therefore, long life. This was achieved with the design of the active pharyngo-oesophageal prosthesis (patent number A00292/29.04.2015) (**Figure 8**).

The shape of the prosthesis is optimised for surgical placement and suturing to the tongue base, and it also has two widenings with holes prefabricated so as to permit stabilisation to the prevertebral fascia and to facilitate sealing of the cervical oesophagus (**Figure 5**). The materials used are biocompatible and do not interfere with CT scans and neither with radiation therapy.

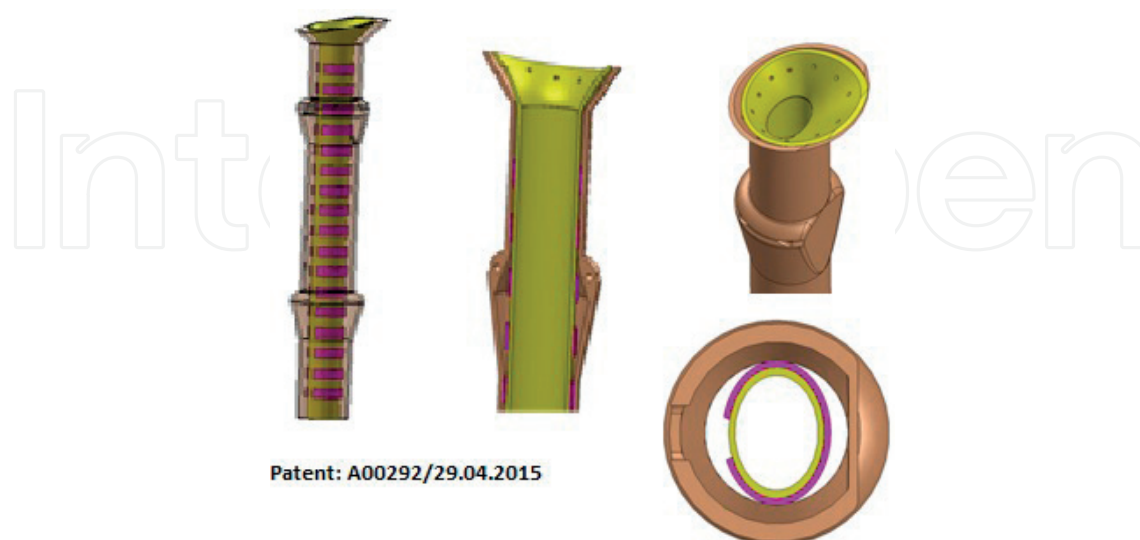


Figure 8. Immediate postoperative aspect of a patient following total circular laryngo-pharyngectomy with Montgomery oesophageal tube prosthetic reconstruction.

The design tries to replicate the anatomy of the pharynx, by having three distinct layers. The external layer represents the hard casing of the prosthesis. It is made from a high-density medical-grade silicone derivate, so as to act as an inert surface, to minimise the risk of foreign body inflammatory reaction and subsequent granulation tissue formation. The middle layer is composed of a series of incomplete rings and represents the active part of the prosthesis. These rings have the capacity to contract in a complex fashion so as to mimic the physiologic peristaltic movements of the hypopharynx and oesophagus. The compound action propels the food bolus towards the stomach, even against the force of gravity. The third and inner-most layer is a thin, flexible layer, coated with a low adherence substance, that mimics the mucosa found in the digestive tract. It hopes to defend against biofilm formation and bacterial colonisation. The swallowing movements of the active prosthesis are controlled by a microprocessor with sensors implanted in the tongue base, so as to activate the food bolus propulsion when stimulated by the base of tongue contraction.

The active prosthesis is still under development awaiting production, and clinical studies have yet to begin.

9. Discussion

Prosthetic reconstruction after total circular laryngo-pharyngectomy represents an accessible, easy-to-perform alternative to the plastic reconstructions using autologous tissues. The main disadvantage of this method, in the authors' view, is the fact that once implanted the body reacts to the prosthesis as to all foreign bodies. From this immunological response stems, the major complications were associated to this type of method.

As unnerving as they are for the surgeon, complications that may necessitate the removal of the prosthesis should be viewed as the perfect opportunity to perform a second-stage plastic reconstruction. Our experience with this method has shown a comparable complication rate to the plastic reconstruction methods (as found in existing literature data). Radiation resistance is better than all the methods that use autologous tissue for reconstruction—which in our view should advocate the use of this technique on a large scale for patients who undergo complementary radiation therapy after the surgical treatment of the tumour.

The main advantages of the C.R. Popescu prosthetic reconstruction method recommend it for primary closure of the resulting defect. The dichotomy between temporary and permanent is always a “hot potato” topic regarding this subject (as well as prosthetics in general). However, the authors' feel that because of the high mortality of this cancer type, as well as the lower morbidity associated with prosthetic reconstruction, this method should be classified as a “permanent-until-proven-otherwise” solution.

Advances in prosthetics, as shown by the authors' quest to develop a novel, safer and more effective “biomimetic” pharyngo-oesophageal prosthesis, should render the discussion even more in favour of choosing prosthetic reconstruction over laborious homologous tissue reconstruction techniques.

10. Conclusions

From our experience the C.R. Popescu method of prosthetic reconstruction of the digestive tract following total laryngo-pharyngectomy is advantageous for the ENT head and neck surgeon because it offers the best compromise between efficiency and cost-effectiveness while not compromising patient safety.

This technique permits the ENT physician to perform a one-stage surgical procedure in a reasonable amount of time, without having to rely on other specialty colleagues and schedule harmonisation. The time-effectiveness also leads to less time under general anaesthesia which is important bearing in mind that patients with advanced tumours of the hypopharynx and cervical oesophagus are malnourished and have an impaired general health status.

Patient oral intake of nutrients may commence 10–14 days after surgery, and discharge from hospital takes place around day 14 post-op, which in turn lowers the financial burden on the institution and decreases the risk of healthcare-related bacterial infections.

Long-term survival appears to be slightly positively influenced using this prosthetic reconstruction, but it still is very low, with barely 14% of patients alive at 5 years after surgery. Theoretically, the low-survival rates associated with this type of malignancy should represent more reason to choose an inexpensive and easy-to-perform technique for reconstruction.

Its main disadvantage, the foreign body reaction, is no more significant than in other prosthetic implants and should not represent a major contraindication to using this technique.

Complications associated with the use of the Montgomery oesophageal tube for reconstruction have led the authors towards developing a new active prosthesis. Hopefully, this active prosthesis will offer a facile, cost-effective and efficient solution to patients and physicians involved in the treatment of head and neck cancer.

Author details

Șerban V.G. Berteșteanu^{1,2}, Alexandru Nicolaescu^{1,3*}, Bogdan Popescu^{1,2} and Raluca Grigore^{1,2}

*Address all correspondence to: alexandru87nicolaescu@gmail.com

1 ENT Head and Neck Surgery Department, General Medicine Faculty, University of Medicine and Pharmacy “Dr. Carol Davila” Bucharest, Bucharest, Romania

2 ENT Head and Neck Surgery Clinic, “Colțea” Clinical Hospital Bucharest, Bucharest, Romania

3 ENT Head and Neck Surgery Compartment, “Professor Dr. Dimitrie Gerota” Emergency Hospital Bucharest, Bucharest, Romania

References

- [1] American Society of Clinical Oncology. 2016. [Online]. Available from: www.cancer.net/cancer-types/head-and-neck-cancer/statistics. [Accessed: Sep 23, 2017]
- [2] Edge SB, Compton CC. The American joint committee on cancer: The 7th edition of the AJCC cancer staging manual and the future of TNM. *Annals of Surgical Oncology*. 2010; **17**(6):1471-1474
- [3] Standring S et.al. *Gray's Anatomy: The Anatomical Basis of Clinical Practice*. 40th ed. Churchill Livingstone Elsevier Publishing; 2008. pp. 196-200 ISBN:978-0-8089-2371-8
- [4] Shaker R, Belafsky PC, Postma GN, Easterling C. *Principles of Deglutition: A Multidisciplinary Text for Swallowing and its Disorders*. New York: Springer-Verlag Publishing; 2013. ISBN: 978-1-4614-3794-9
- [5] Holzheimer RG, Mannick J. *Surgical Treatment: Evidence Based and Problem Oriented*. Zuckschwerdt, Munich. 2001. ISBN: 3-88603-714-2
- [6] Șerban V. Berteșteanu and C.R. Popescu, *Cancerul de jonctiune faringoesofagiană – reconstrucție protetică*. 1st ed. Bucharest: Editura Universitară Carol Davila. 2012
- [7] Pfister DG, Spencer S, Adelstein D, Adkins D, Brizel D. *NCCN Clinical Practice Guidelines in Oncology: Head and Neck Cancers*. Vol. 2. 2017
- [8] Bertesteanu SVG, Popescu CR, Grigore R, Popescu B. Pharyngoesophageal junction neoplasia–therapeutic management. *Chirurgia (Bucur)*. 2012;**107**(1):33-38
- [9] Bhathena HM. Free jejunal transfer for pharyngo-esophageal reconstruction. *Acta Chirurgiae Plasticae*. 2002;**44**(4):120-123
- [10] Archibald S, Young JEM, Thoma A. Pharyngo-cervical esophageal reconstruction. *Clinics in Plastic Surgery*. 2005;**32**(3 Spec. iss):339-346
- [11] Kress P, Schfer P, Schwerdtfeger FP, R?sler S. Are modern voice prostheses better? A lifetime comparison of 749 voice prostheses. *European Archives of Oto-Rhino-Laryngology*. Jan 2014;**271**(1):133-140

