

# We are IntechOpen, the world's leading publisher of Open Access books Built by scientists, for scientists

6,900

Open access books available

185,000

International authors and editors

200M

Downloads

Our authors are among the

154

Countries delivered to

TOP 1%

most cited scientists

12.2%

Contributors from top 500 universities



WEB OF SCIENCE™

Selection of our books indexed in the Book Citation Index  
in Web of Science™ Core Collection (BKCI)

Interested in publishing with us?  
Contact [book.department@intechopen.com](mailto:book.department@intechopen.com)

Numbers displayed above are based on latest data collected.  
For more information visit [www.intechopen.com](http://www.intechopen.com)



---

# Congenital Abnormalities of the Fetal Face

---

Maria Șorop-Florea, Roxana-Cristina Dragușin,  
Ciprian Laurențiu Pătru, Lucian George Zorilă,  
Cristian Marinaș, Virgiliu-Bogdan Șorop,  
Cristian Neamțu, Alina Veduța,  
Dominic Gabriel Iliescu and Nicolae Cernea

Additional information is available at the end of the chapter

<http://dx.doi.org/10.5772/intechopen.73072>

---

## Abstract

Even at the early stages of gestation, the fetal face can be examined. There have been observations of the normal anatomy, such as orbits and the forehead, starting with the 12th week of gestation. However, nowadays, ultrasound equipment still cannot distinguish the soft tissues of the face, which are too thin. Yet, after the age of 14 weeks, we can easily examine the forehead, orbits, nose, lips, and ears. Recently, three-dimensional ultrasound (3D) images of the fetus can also be obtained. However, two-dimensional (2D) ultrasonographic (US) images are more easily, rapidly, efficiently, and accurately obtained. At the first stage of embryogenesis, the main part in the development of the fetal face is taken by the genetic factors. Later, the influence of the environment becomes more important. It is known that the outcome of chromosomal aberrations and of teratogenic factors is the facial malformation. Therefore, examining the facial dimorphism may get us useful hints in revealing chromosomal or genetic abnormalities. This chapter focuses on the fetal face anomalies more frequently found while performing the prenatal diagnosis. It is divided into anomalies of the orbits, nose, lip, palate, and mandible.

**Keywords:** fetal face, facial malformation, ultrasound, prenatal diagnosis, congenital abnormalities

---

## 1. Introduction

The study of the fetal face may be performed during the early stages of gestation. Depending on the gestational age, we can identify various elements of anatomy, such as the orbits or the

forehead, from the 12th week. Yet, after that time, we can easily identify and study the forehead, the nose, the lips, the ears, and the orbits of the fetus [1]. Prenatal recognition of facial abnormalities during pregnancy has many benefits. It can lead to the diagnosis of multiple genotypic syndromes and chromosomal anomalies. Also, it allows more adequate counseling and preparation of the parents. Considering that the sonographic assessment of the fetal face is a major part of the anatomic survey of the fetus, sagittal, axial, and coronal planes are used when examining the fetus.

The facial anomalies are divided into nose, orbit, lip, mandible, and palate anomalies. The US method may reveal also benign and less frequent anomalies, for example, lacrimal duct cysts, hemangiomas, and so on.

### 1.1. Sagittal planes

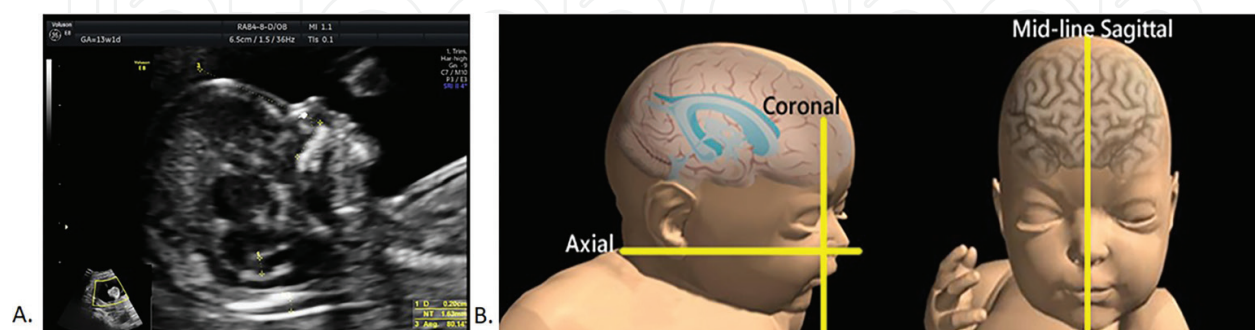
In order to assess the normality of the fetus profile, sagittal planes of the face are used (**Figure 1**).

One of the US parameters used to obtain an exact measurement of the position of the anterior end of the maxilla to the forehead is the angle between the surface of the palate and the frontal bone examined in a mid-sagittal view of the fetal face, called the frontomaxillary facial angle [2]. This angle is increased in fetuses with trisomy 21, and it is believed that the reason for this is the hypoplasia or posterior displacement of the palate [2, 3].

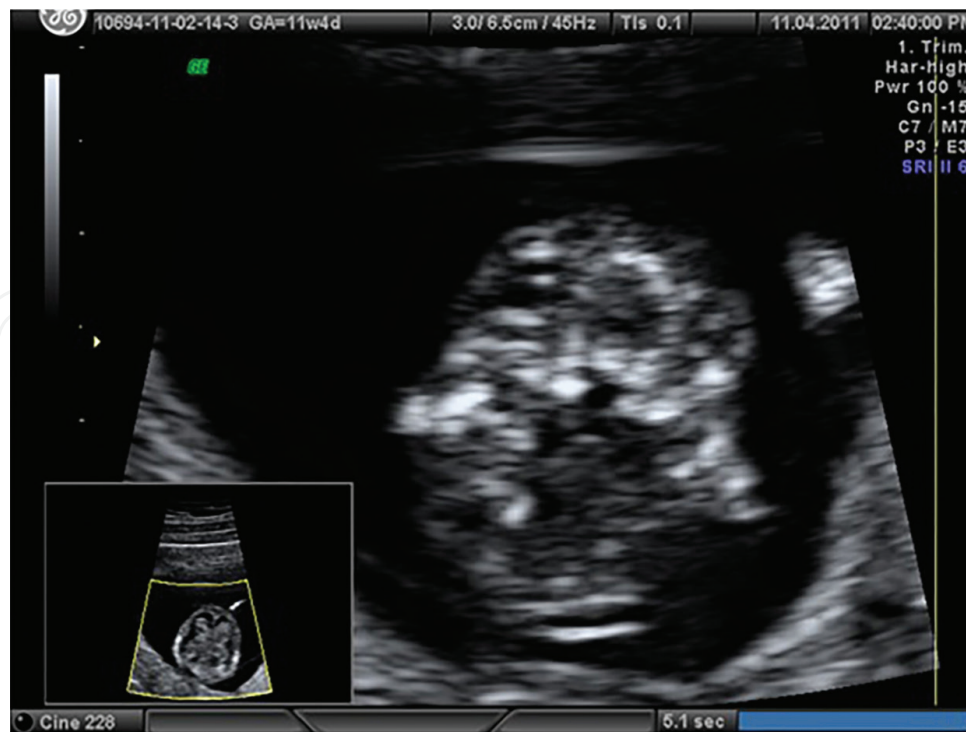Ears are well visualized in parasagittal scans tangential to the calvarium. In late gestation, significant details of the anatomy of the external ear can be seen.

### 1.2. Axial planes

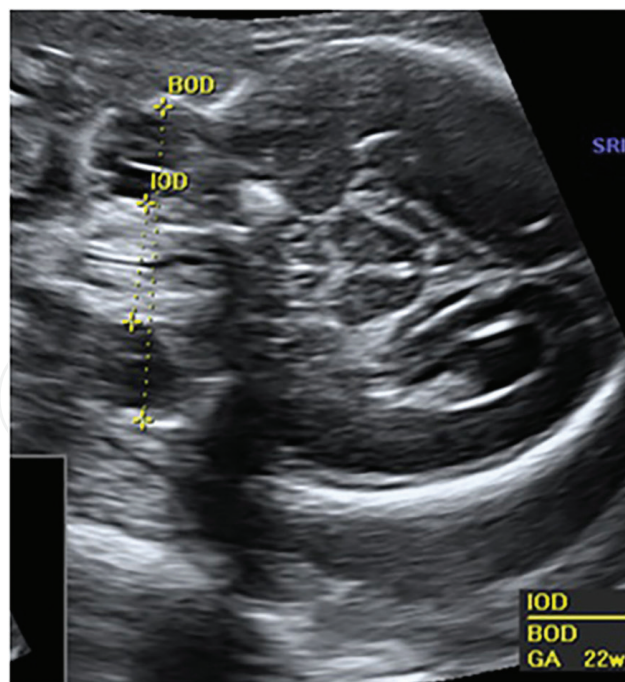
Orbits may be visualized simultaneously, by means of an axial plane, slightly caudal to the one used to measure the biparietal diameter (**Figures 2–4**) [4].



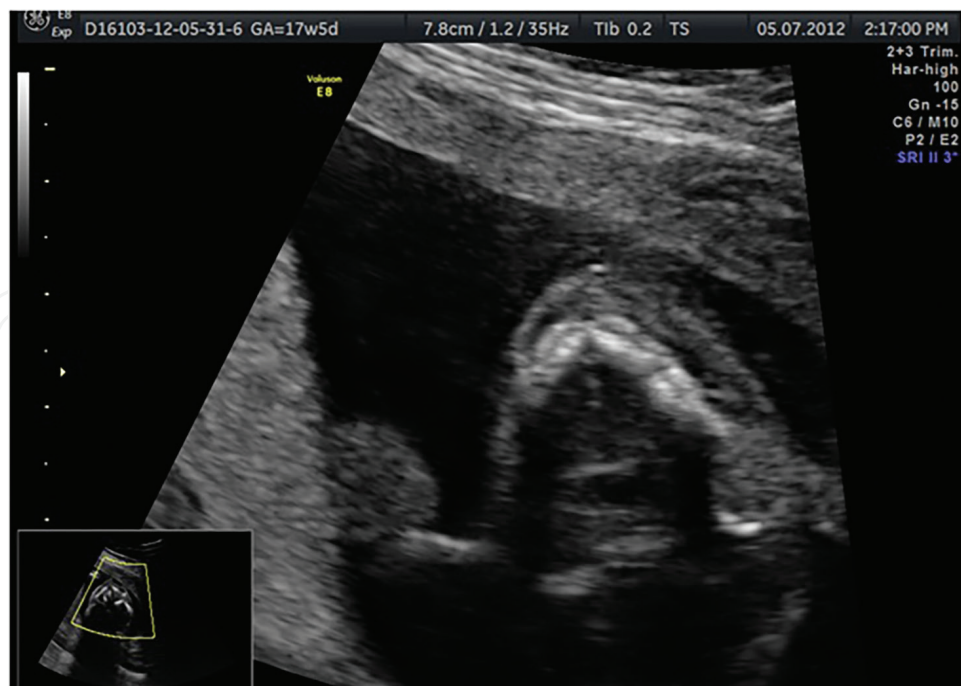
**Figure 1.** (A). Normal fetal profile at 12–13 weeks. (B). Schematic representation of the scanning planes to be used for obtaining axial and coronal views of the fetal face.



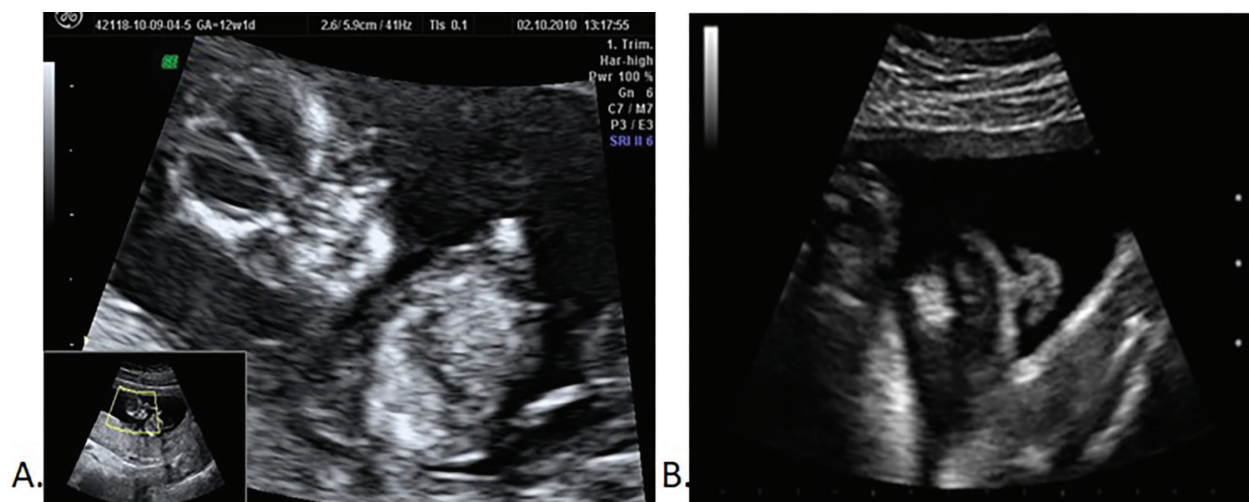
**Figure 2.** Axial scan passing through the orbits of a normal second trimester fetus.



**Figure 3.** The interocular distance (IOD) and binocular distance (BOD) are demonstrated in this scan. The lens is visible inside the orbit.



**Figure 4.** Axial scan of the lower fetal face demonstrating the upper lip and the anterior palate.



**Figure 5.** A. Coronal anterior plane in a late first trimester (FT) fetus: The lens inside the corpus vitreum B. The tip of the nose, the alae nasi, and the columna are seen above the upper lip. The nostril typically appears as two little anechoic areas.

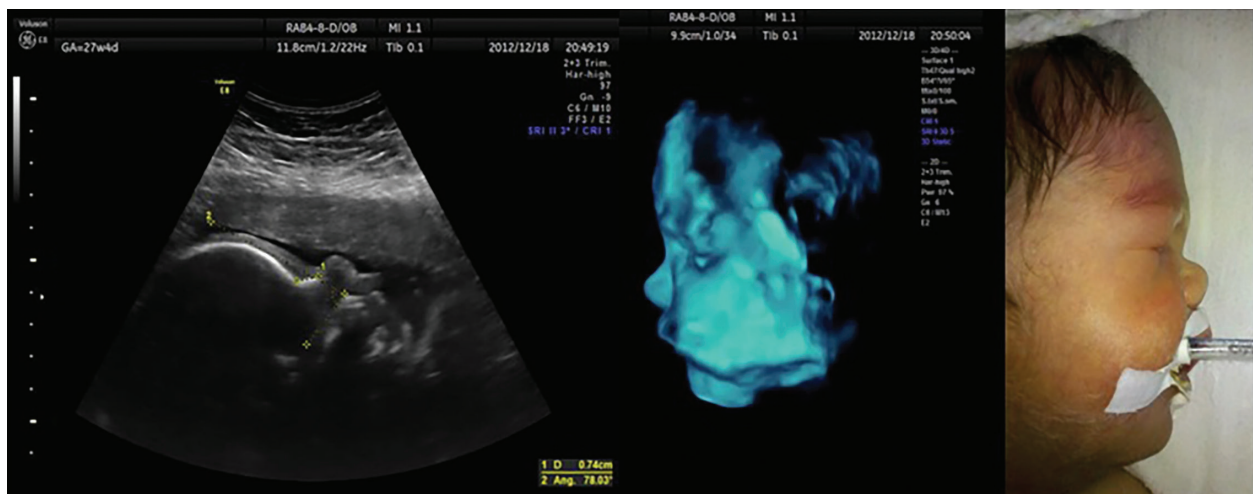
### 1.3. Coronal planes

Evaluation of the integrity of the facial anatomy is assessed by visualizing the eyelids, orbits, lips, forehead, and nose, whose nostrils usually appear as two little anechoic areas. For these features, coronal planes are more important than the previous one (**Figure 5**).

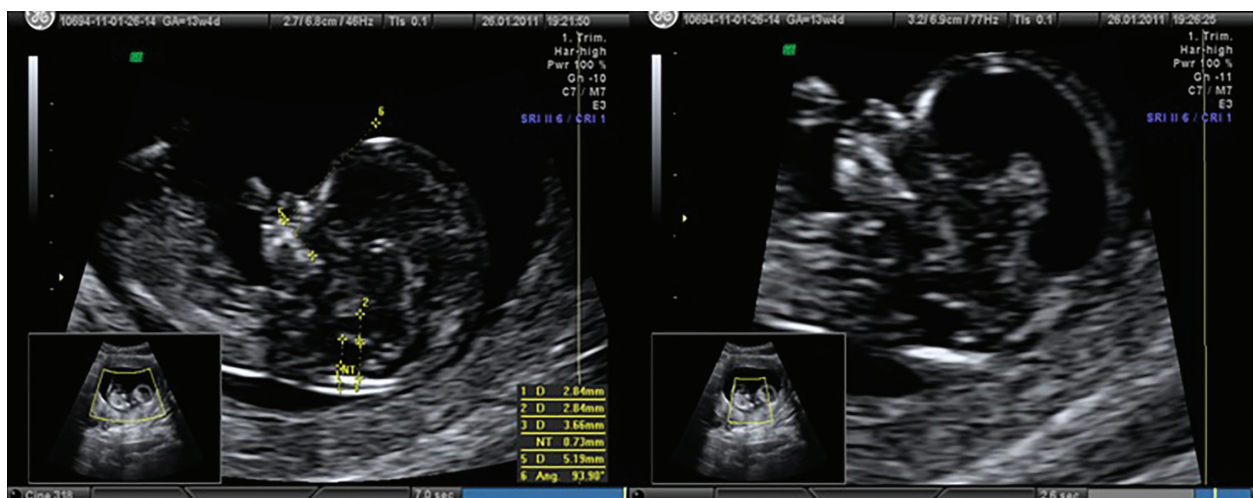
### 1.4. Fetal face profile

One of the most common “soft sonographic sings” providing essential clues of congenital syndromes [1] is the deviations from the proportions normally found during a sagittal fetal





**Figure 6.** Sonographic pictures of fetal bossing forehead at 24 weeks of gestation. The postnatal aspect of the neonates with bossing forehead.



**Figure 7.** Sagittal scan of a fetus at 13–14 weeks of gestation shows FT bossing forehead.

face examination (**Figures 6, 7**). Apert or Carpenter syndromes are ruled out by examining the bridge of the nose. [5] The cleft lip is excluded when the normal prominent lips are visible. [1]. As for micrognathia or prognathia, these can be noticed in the subjective abnormal appearance of the jaw [6].

## 2. The fetal eyes

From the late FT or in the early second trimester onward, we should consider the visualization of the fetal orbit and lens. The orbits will appear as echolucent circles on the upper fetal face, whereas the lens will be visualized inside these structures, as circular hyperechogenic rings. These images can be obtained during almost all scans, beginning with the late first trimester. Any deviation from the relative size might suggest congenital malformations of the orbits and lens. To assess them, coronal and especially axial planes of the fetal head are the best approach.

## 2.1. Anomalies of the orbits

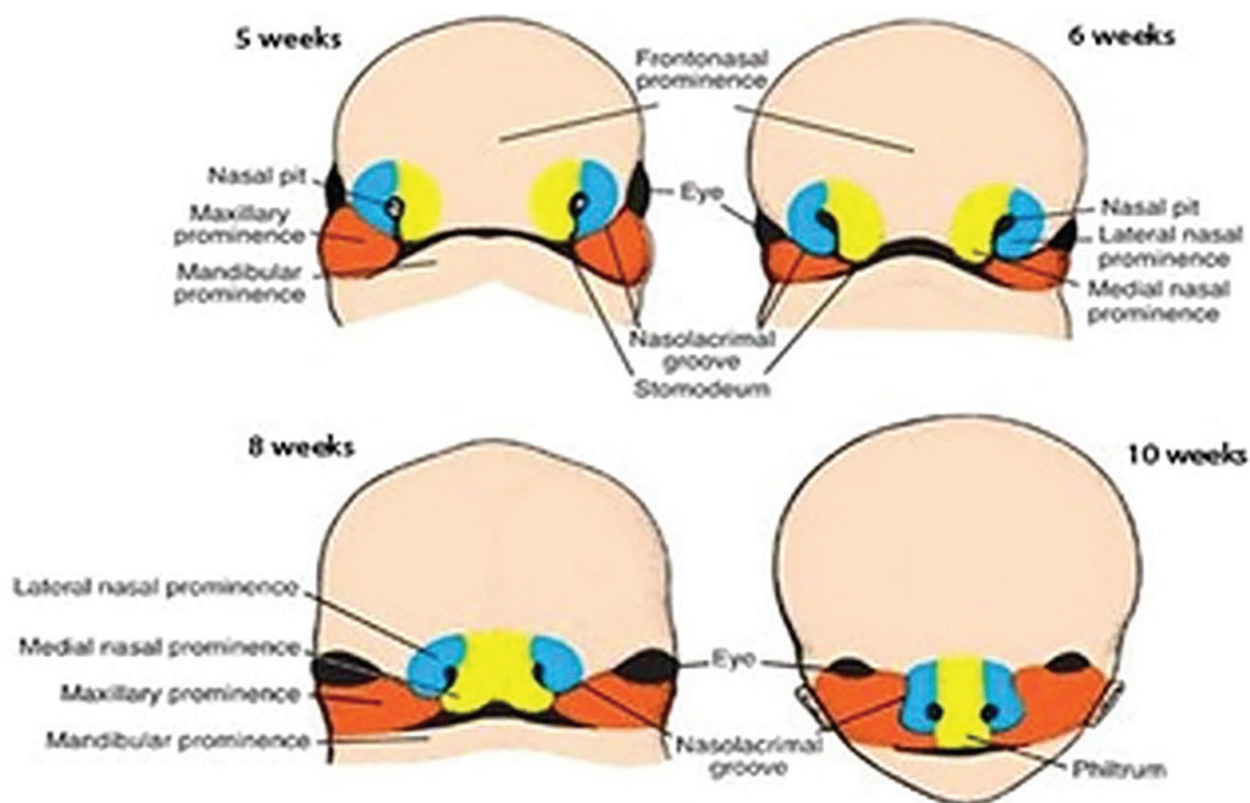
### 2.1.1. Hypertelorism

**Definition:** Hypertelorism is an increased interocular distance.

**Embryology and pathogenesis:** At the first stage of the development of the human embryo, the eyes are to be found laterally, like in animals with panoramic vision. As the pregnancy evolves, the fetal eyes migrate toward the midline, thus generating the conditions for the stereoscopic vision to develop (**Figure 8**).

There are at least two theories as to why hypertelorism may appear. The first theory states that there are several mechanisms causing it: the forward migration of the first half of the eyes, a midline tumor, meningoencephalocele for instance, causing the second half, or skull bones with abnormal growth vectors. The second theory links a splanchnocranium, which presents an abnormal growth, to the undeveloped bones which derive from the first branchial arches [8].

**Pathology:** Three parameters are used to measure the fetuses' ocular spacing: interpupillary distance, canthal distance, and interorbital distance. Hypertelorism is bilateral most of the times, with little incidents of unilateral cases associated with plagiocephaly and proboscis lateralis. Also, this condition is either isolated or accompanied by other malformations or clinical syndromes such as the median cleft syndrome and craniosynostoses. In craniosynostoses, hypertelorism syndromes such as Apert, Crouzon, and Carpenter are usually present [9].



**Figure 8.** The facial structures development, represented schematically between the 5th and the 10th week of gestation. During the early stages, we can notice the primitive eyes on both sides of the cephalic pole. However, they move toward the median line as gestation goes on [7].

**Ultrasound diagnosis:** Interorbital diameter is larger than 95th. The accuracy of ultrasound exam in the hypertelorism diagnosis has not been established.

**Investigations:** Detailed ultrasound examination for associated defects. Invasive testing for karyotyping and array.

**Follow up:** Standard follow-up in isolated cases. Any underlying syndrome antenatal care should be adjusted, considering the additional risk of the condition.

**Delivery:** Standard obstetric care and delivery.

**Isolated:** It is good, even if there might be esthetic implications in severe cases as well as impaired stereoscopic binocular vision. For these cases, there are several operative procedures such as canthoplasty, orbitoplasty, surgical positioning of the eyebrows, and rhinoplasty.

**Syndromic:** The prognosis of hypertelorism is usually poor, and it does have a risk of mental retardation. However, normal life span and normal intellect are to be expected in the case of medial facial cleft syndrome [8]. The esthetic aspect should not be underestimated.

**Recurrence:** Isolated: no increased risk of recurrence.

### *2.1.2. Hypotelorism*

**Definition:** Hypotelorism is a decreased interorbital distance.

**Prevalence:** 1 in 20,000 births.

**Etiology:** Hypertelorism is almost always associated with other severe abnormalities, especially with the sequence of holoprosencephalic abnormality.

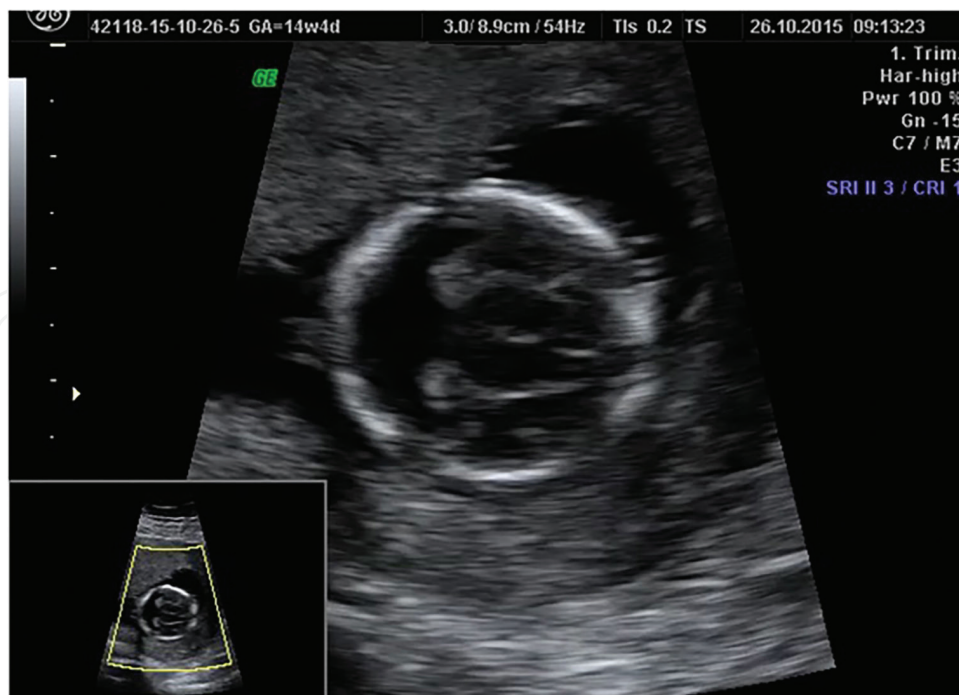**Embryology and Pathogenesis:** Out of the mesenchymal mass there comes the craniofacial skeleton. This mass has two points of origin: the mesoderm and the neural crest, the latter migrating to the region. The development of the median facial structures (forehead, nose, interorbital structures and upper lip) is closely linked to the forebrain differentiating process. It is possible that these two development steps are induced by the tissue, which lies between the prosencephalon and the stomodeum (the root of the primitive mouth), namely the pre-chordal mesenchyma. Thus, defects of the facial midline, for example, hypotelorism, are often linked to cerebral abnormalities, most often with holoprosencephaly. Hypotelorism can be found in association with trigonocephaly, microcephaly, Meckel syndrome and chromosome aberrations [10, 11].

**Ultrasound diagnosis:** It is based on the documentation of a reduced interocular distance. The interorbital diameter is lower than <5th and, together with the almost always present holoprosencephaly (**Figure 9**), is to be found among the midline migration defects; in this case, the hypotelorism can be extreme, as in cyclopia [10].

**Associated abnormalities:** In half of the cases, we encounter chromosomal defects, especially trisomy 13, as well as genetic syndromes [9].

**Investigations:** A thorough ultrasound examination should be conducted, including neurosonography, in order to find associated defects as well as invasive testing for karyotyping and array.





**Figure 9.** Axial scan a fetus at 14–15 weeks with alobar holoprosencephaly.

**Prognosis:** The prognosis and the management are decided on the accompanying malformations. Usually, the prognosis is poor, with high levels of mortality. In cases with normal karyotype, there is a high risk of mental retardation, depending on the degree of holoprosencephaly.

**Recurrence:** Isolated: no increased risk. One percentage risk of trisomy and 13.25% risk of being part of an autosomal recessive condition [11].

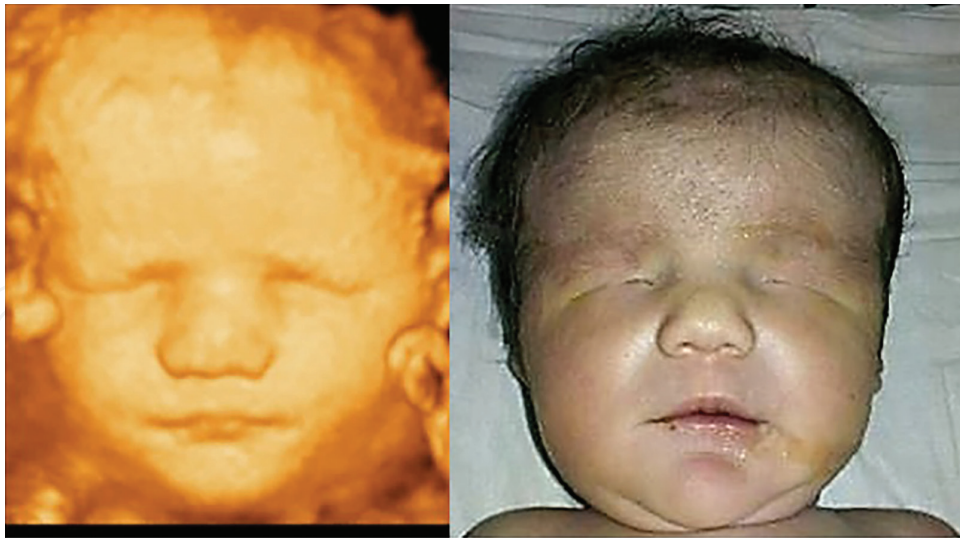### 2.1.3. Microphthalmia/Anophthalmia

**Definition:** Microphthalmia refers to the decreased size of the eyeball, whereas anophthalmia refers to absence of the eye. However, the pathologist should demonstrate not only the absence of the eye but also of the optic nerves, chiasma, and tracts.

**Prevalence:** While it is difficult to define, it accounts for 1 in 20,000 births, and for 4% of the cases of congenital inheritable blindness.

**Etiology/Pathology:** Microphthalmia is usually associated with other anomalies. Microphthalmia is either as a sporadic disorder or as a condition inherited with an autosomal dominant, recessive, or X-linked pattern. We use the term “cryptophthalmia” to define fused eyelids, a condition often associated [9, 10].

**Ultrasound diagnosis:** Microphthalmia and anophthalmia can be unilateral or bilateral. Diagnosis can be suspected by demonstrating an orbital diameter below the fifth percentile for gestational age (**Figure 10**). If the diagnosis is suspected, a thorough search for associated anomalies (microtia, micrognathia, syndactyly, camptodactyly, median cleft, feet abnormalities, such as rocker bottom and talipes, hemivertebrae, and congenital heart defects) should be performed.



**Figure 10.** This picture shows a case of anophthalmia, prenatal and postnatal aspects.

**Associated abnormalities:** Chromosomal defects, especially trisomy 13, are found in more than 50% of the cases. The most common include: Goldenhar syndrome (1:3000 births), Fraser syndrome, Fryns syndrome and Meckel-Gruber [9].

**Investigations:** Besides detailed ultrasound, karyotyping and array should be offered. Also, a fetal brain MRI may be useful to diagnose abnormalities (e.g., the absence of the optic nerve).

**Prognosis and obstetrical management:** Isolated: good, with an altered life quality because of the esthetic aspect of the lesion: plastic surgery might be considered. Syndromic: prognosis is very poor. Management depends on the specific syndrome [11].

**Recurrence:** Isolated: no increased risk. Part of an autosomal recessive condition: 25%.

#### 2.1.4. *Dacryocystocele*

**Definition:** Dacryocystocele is a congenital obstruction of the nasolacrimal duct, resulting in cystic dilatation of the proximal part of the duct. (**Figure 11**).

**Prevalence:** 1 in 4000.

**Ultrasound diagnosis:** Cyst (75% unilateral and 25% bilateral) between the lower part of the orbit and the nose. About 90% of the cases are due to delayed canalization of the lacrimal duct beyond 32 weeks gestation.

**The differential diagnosis:** includes an anterior cephalocele, hemangiomas, and dermoid cyst. Usually, hemangiomas have a solid appearance or multiple septae, and they are shown as exophytic lesions with an echogenicity, similar to the placenta. Among the complications of hemangiomas, we should include ulceration, bleeding, infection, and scar formation. The dermoid cysts have often a superolateral location. It is difficult to differentiate anterior cephaloceles from these lesions. If hydrocephaly is present, we should suspect a cephalocele [12, 13].



**Figure 11.** Ultrasonographic aspect of the congenital dacryocystocele.

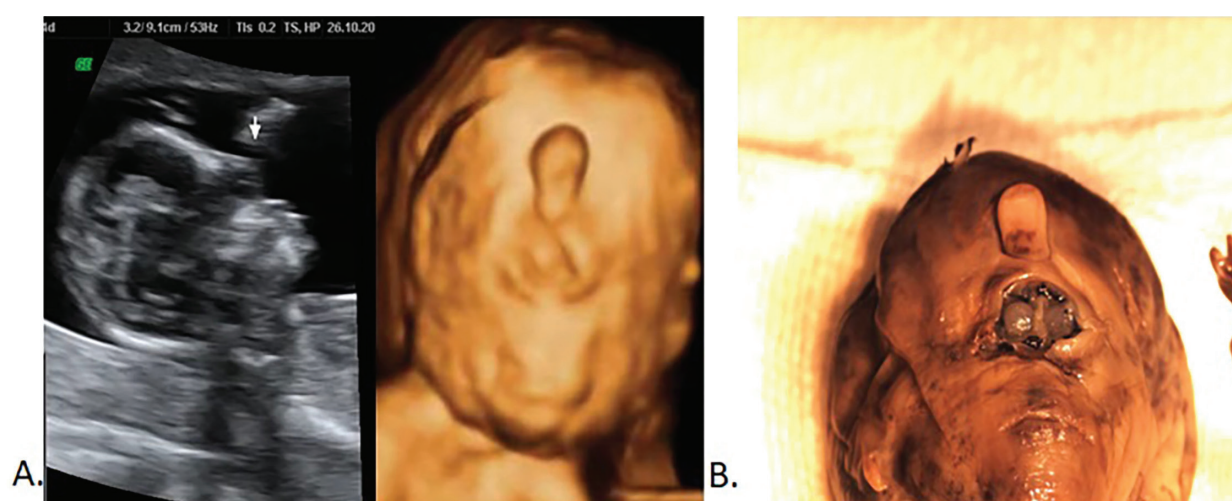
**Associated abnormalities:** Not associated with chromosomal or other abnormalities.

They resolve spontaneously in 78% of the cases by 3 months, 91% by 6 months, or during the third semester.

### 2.1.5. Cyclopia

**Definition:** Cyclopia is another type of anomaly, in which the fetus has only one single orbital fossa, with bulbs, eyelids and lacrimal apparatus fused to a variable degree. In many cases, there is one single eye or one partially divided eye, in a single orbit and arhinia with proboscis (**Figure 12**), [14, 15].

**Incidence:** Cyclopia results from the incomplete cleavage of the prosencephalon into right and left hemispheres, a process which should be occurring between the 18th and the 28th day of pregnancy, and it is a lethal human malformation, relatively complex, but also quite rare. Moreover, holoprosencephaly occurs in 1/16,000 live births [16].



**Figure 12.** A. Axial and sagittal scans of a fetus at 15 weeks of gestation show cyclopia and proboscis. B. Ethmocephaly—Postmortem demonstrating hypotelorism and proboscis.



**The etiology** of this rare syndrome incompatible with life is still not known in detail, because most cases are sporadic, even if the implication of heterogeneous risk factors has been proven. Among risk factors, we include maternal diabetes (the only formally recognized environmental factor, with a 1% risk and a 200-fold increase in fetal holoprosencephaly), infections during pregnancy (TORCHs), active drugs during pregnancy physical agents (ultraviolet light), and chromosomal (mostly trisomy 13) and genetic causes (familial occurrences in twins and in consanguineous marriages [17]).

In order to get **the differential diagnosis** of these cases, we must distinguish between ethmocephaly and cebocephaly. In other words, we must be able to trace extreme hypotelorism, arhinia and blinded proboscis located between the eyes as opposed to hypotelorism and a single nostril nose without midline cleft. In case the image shows united palatine and lacrimal bones, as well as no sign of nasal bones, maxilla and nasal septum, then the diagnosis is ethmocephaly [15].

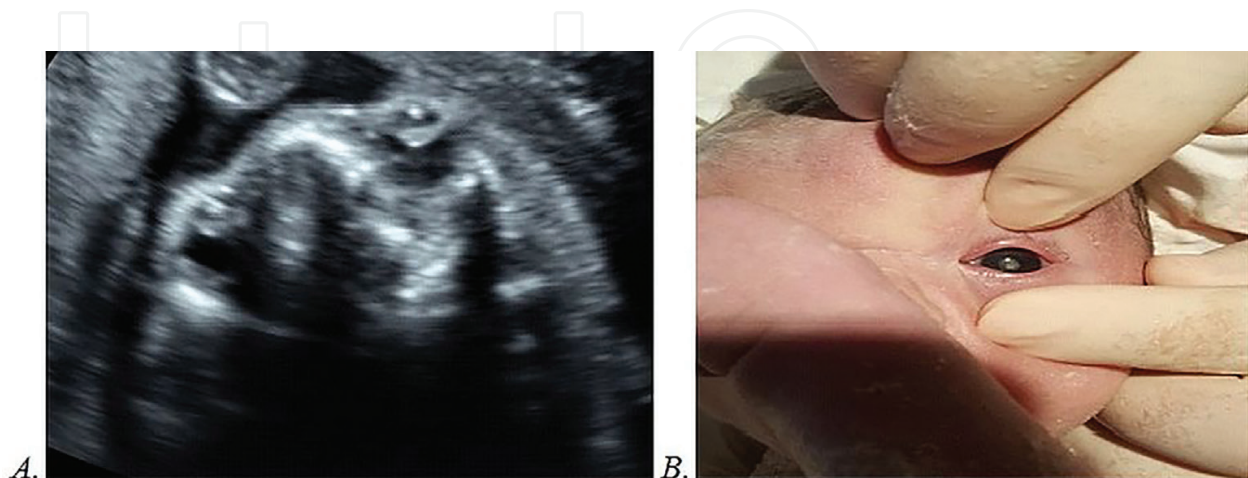
#### 2.1.6. Cataracts

**Definition:** any opacity of the eye lens.

**The incidence** of cataract is as follows: 1–6 newborn infants every 10,000 births [18] for congenital cataracts in newborn babies, whereas 8.3–25% is considered to be inherited.

**Etiology:** There are several ways in which a fetus might inherit congenital cataracts: autosomal dominant, autosomal recessive, or X-linked fashion. However, the most frequent and the strongest penetration is the autosomal dominant. A series of other complications are associated with cataracts: genetic syndromes, congenital infections, metabolic disorders, and chromosomal abnormalities. The genetic cause is present in 30% of the unilateral cataracts and in 50% of the bilateral ones [19].

During the examination of the fetal cataracts solid, either some echogenic discs or echogenicity areas within an echolucent orbit will be noticed (**Figure 13**), having either unilateral or bilateral



**Figure 13.** A. Sonographic pictures of fetal cataracts at 24 weeks of gestation. Coronal views of echogenic lens. B. The postnatal aspect of the lens.



opacity of the lens. Usually, the bilateral lesions are generally syndromic, with a poor prognosis; as for unilateral lesions, they are generally linked to a fetal infection. The genetic aspect of cataracts can be linked to microphthalmia.

**Associated abnormalities:** there is not any high risk of chromosomal abnormalities. It is in only 10% of the cases that genetic syndromes are found, and these include the chromosomal defects. In about 10% of the cases, genetic syndromes are found, and the most common include: Walker-Warburg syndrome and chondrodysplasia punctata. Only a fifth of the congenital cataracts cases are linked to infections such as rubella, toxoplasmosis, or CMV [20].

**Investigations:** ultrasound, karyotyping, array and TORCH.

**Prognosis:** Usually good for isolated cases. Postpartum ophthalmologic surgeries have good results, which do not affect the quality of life. Prognosis is quite poor for syndromic cataract, though.

### 3. The ear

The most frequent clinical characteristic in diagnosing the Down syndrome has been the short ear length. Sonographic studies implied that measurements of the short ear length could be a useful predictor of fetal anomalies. In late gestation, important details of the anatomy of the external ear became accessible. In good conditions for scanning, and using high-resolution systems, the helix, scaphoid fossa, triangular fossa, concha, antihelix, tragus, antitragus, intertragic incisure, and lobule are sometimes visualized [21].

### 4. The nasal bone and nostrils

A small nose is very commonly seen during postnatal examination of fetuses or neonates who also present trisomy 21 as well as for more than 40 other genetic problems. The nasal bone can be measured using a mid-sagittal profile for normal singleton fetuses between the 14th and 34th week of gestation. Thus, the length of the nasal bones increase from 4 mm at 14 weeks to 12 mm at 35 weeks gestation. A possible improvement in screening for trisomy 21 by examining the fetal nasal bone with ultrasound at 11–14 weeks of gestation has been considered [22].

#### 4.1. Anomalies of the nose

##### 4.1.1. *Arhinia*

**Definition:** Absence of the nose.

**Etiology:** Unknown. It can either be an isolated malformation or be part of a malformation complex, such as holoprosencephaly or mandibulofacial dysostosis (Treacher Collins syndrome) [23].

**Embryology:** Around the 6th week of gestation, the primitive nasal and oral cavities communicate freely using an opening, which will close progressively when the palate starts developing.

When the lateral palatine processes fuse with the nasal septum in the middle, the oral and the two nasal cavities are formed and separated; this takes place around the 12th week of gestation. The external nose starts at the lower portion of the frontonasal prominence, merging on both sides with the maxillary processes (**Figure 9**). If the frontonasal prominence does not fully develop, the result is partial or complete nasal aplasia. This anomaly is part of a more complex spectrum of midfacial defects, which, in the holoprosencephalic sequence, are considered to appear from a primitive defect of the prechordal mesenchyma, the tissue responsible for the induction of both facial and cerebral structures [24, 25].

**Prognosis** depends on the associated anomalies; however, isolated arhinia is not life incompatible.

#### 4.1.2. Proboscis

**Definition:** A proboscis is a trunk-like appendage, with one or two internal openings, and it is usually associated with the absence of the nose.

**Incidence:** Cyclopia and cebocephaly, two of the main conditions for a proboscis to be present, occur in 1:40,000 and 1:16,000 births, respectively [26].

**Embryology:** The presence of a proboscis is frequently associated with holoprosencephaly. Apparently, a primary disorder in the prechordal mesenchyma develops into an abnormal induction of the midfacial structures. If the nasal prominences develop abnormally, this may lead to a fusion of the olfactory placodes and to the formation of a proboscis [27].

**Pathology and associated anomalies:** Usually there is a single central opening in the proboscis, and it does not have any connection to the choanae. The ethmoid, the nasal conchae, and the nasal and lacrimal bones are absent. Usually, in cyclopia, ethmocephaly, and cebocephaly, the cleft of the lip and the palate are absent. The presence of a proboscis is seldom found in the absence of holoprosencephaly. In rare cases, a bilateral proboscis can be noticed [28].

**Diagnosis:** The diagnosis relies on the demonstration of a trunk-like structure, usually with a single central opening either occupying the normal position of the nose or hanging above the orbits [29] (**Figure 8**).

## 5. The tongue

Fetal macroglossia and microglossia are associated with several chromosomal defects.

### 5.1. Macroglossia

**Prevalence:** Depends on the underlying disorder (present in 97.5% of Beckwith-Wiedemann syndrome cases: incidence 0.73:10,000 live births, congenital hypothyroidism: incidence 2.5:10,000 live births) [30].

**Etiology:** If it is isolated, it is usually sporadic and it relates to the underlying disorder; there have been only two families with autosomal dominant transmission.

**Pathogenesis:** In cases of Beckwith-Wiedemann syndrome, it is part of the generalized visceromegaly probably secondary to fetal hyperinsulinism. The most common cause of Beckwith-Wiedemann syndrome is the uniparental paternal disomy, a result which was found using 11p15.5 markers. It is the same region in which the code for insulin-like hormones is found [30].

**Diagnosis:** Considering the imaginary line between the mandible and the maxilla on the sagittal scanning plane, the diagnosis is confirmed by the protruding tip of the tongue past that line; if we consider the axial scan, the diagnosis is confirmed by the protruding tip of the tongue past the lower lip.

**Associated anomalies:** It is diagnosed by prenatal ultrasound in cases of Beckwith-Wiedemann syndrome, in association with hydramnios (due to impaired fetal swallowing and possibly to increased urine production), omphalocele, nephromegaly, gigantism (sometimes hemihypertrophy), hepatomegaly, genital anomalies, cystic adrenal glands, and heart defects. In the absence of an omphalocele, a careful search for markers of trisomy 21 is indicated [31].

## 6. Anomalies of the lip and palate

### Facial cleft

**Synonyms:** The Cleft lip and the cleft palate.

**Definition:** This term refers to a wide spectrum of lateral clefing defects, usually involving the upper lip (**Figure 14**), the palate (**Figure 15**) or both.

**Incidence:** Facial clefing is the second most common congenital malformation, around 13% of all anomalies. It is usually encountered in 1 in 1000 live births; however, it can be higher for fetuses, many of them having other malformations as well. The occurrence of the cleft palate is 1 of 2500 white births, cleft lip being more common to boys, and cleft palate being more

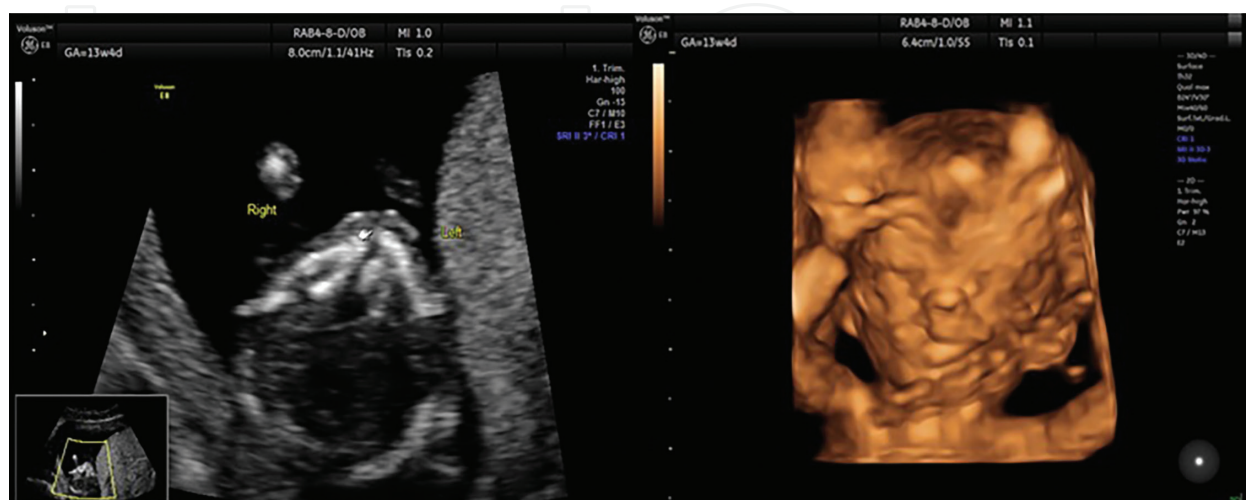
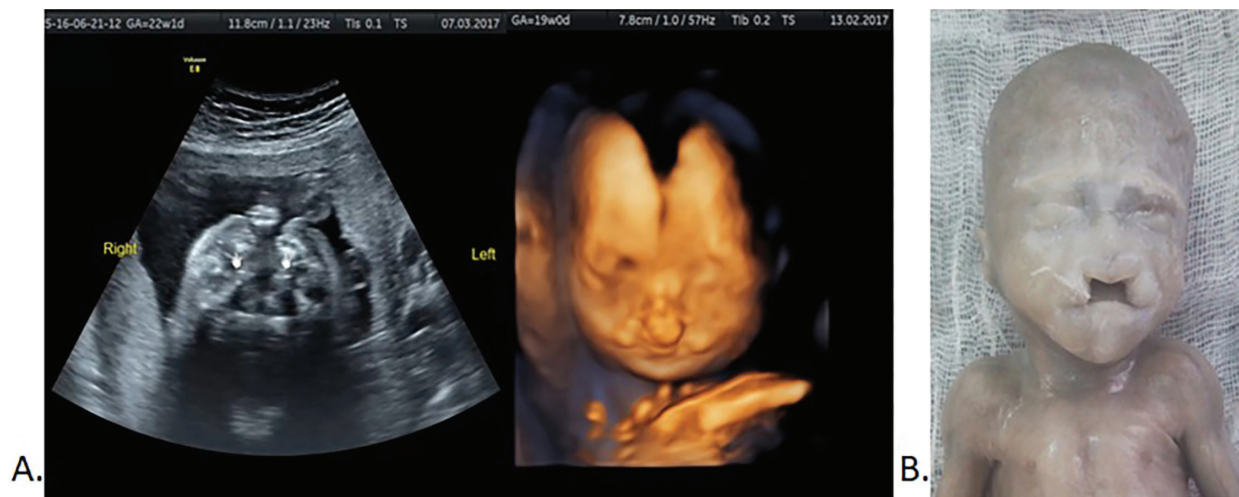
Figure 14. 2D and 3D ultrasonographic pictures of cleft lip.



**Figure 15.** A. Sonographic pictures of the bilateral cleft palate (22 weeks of gestation). B. The postnatal aspect of the cleft palate.

common to girls. In 50% of cases, both the lip and palate are affected, in 25% only the lip and in 25% only the palate. The condition is unilateral in 75% of cases (more common on the left side) and bilateral in 25% [1, 32].

**Etiology:** The cleft lip is one or more splits (clefts) in the upper lip, ranging from a small indentation in the lip to a split in the lip, which may extend up into one or both nostrils. In the clear majority of patients, the cleft lip (CL) and the cleft palate (CP) have a multifactorial etiology, including genetic and environmental factors. CL (with or without CP) and isolated CP are two different anomalies. CL-CP and isolated CP can be noticed as a component of a well-defined syndrome in 3% of the cases (syndromic) and in 97% of cases (nonsyndromic). CL-CP can develop either as a result of a multifactorial defect or the combination of an autosomal dominant with incomplete expressivity and penetrance (25%) or a sporadic disorder (75%). If the affected parent is the mother, the recurrence risk is decreased, and if it is the father, the recurrence risk is increased. The opposite is true for CL-CP. Chromosomal abnormalities are present in less than 1% of clefting abnormalities [33].

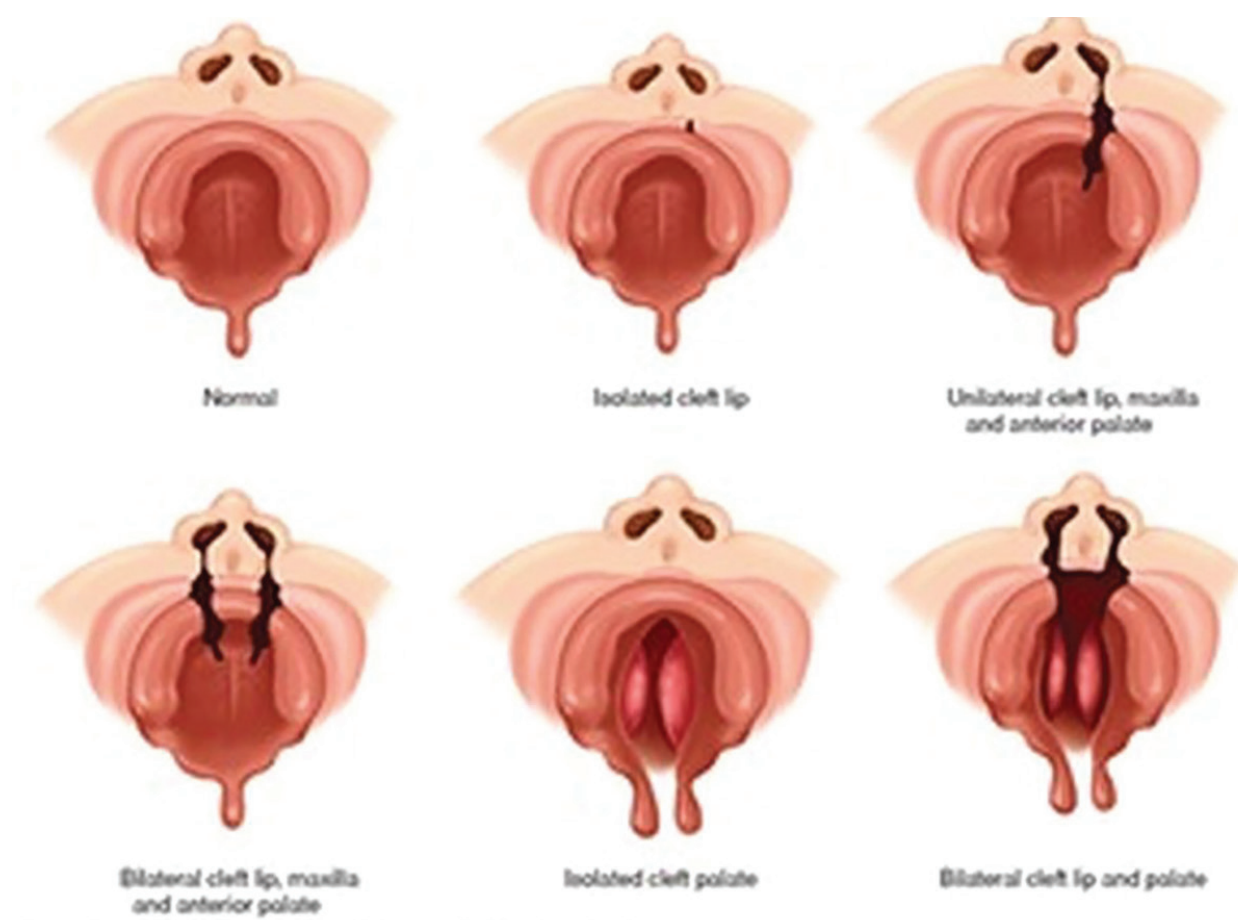
**Embryology:** The cleft lip results from the persistence of the grooves between the frontonasal, maxillary, and mandibular prominences and develops in about the 6th to 8th week of gestation, when the structures of the upper jaw do not fuse properly and the upper lip does not completely merge. The formation of the cleft is due to the collapse of the mesenchymal tissue under the groove [12]. At times, usually between the 7th and the 12th week of gestation, the cleft palate bones and tissues do not join totally during fetal growth. This leads to the nasal cavity, palate and upper teeth to be affected by the roof of the mouth that remains opened. The cleft palate varies in severity and type according to the place on the palate where the cleft occurs and whether the layers of the palate are affected completely. Sometimes, if some tissues cover the cleft, a milder form of cleft palate will not be visible. A more severe form of the cleft palate, the complete one, involves tissues from all layers of the soft palate, encompasses the hard palate as well, and it might continue to the lip and nose. From time to time, the cleft palate problems also include deformities of the nasal cavities [33].



**Pathology:** Facial clefts encompass a large spectrum of severity, from minimal defects, such as a bifid uvula, linear indentation of the lip, or submucous cleft of the soft palate, to large, deep, defects of the facial bones and soft tissues (**Figure 16**).

**Diagnosis:** To set a diagnosis, both transverse and coronal planes can be used. The accuracy of ultrasound in detecting small lesions has not been established; however, color Doppler might be useful to demonstrate the flow across the palate in the case of the cleft palate. Diagnosis of isolated cleft palate is difficult. Diagnosis of the cleft lip and palate at 11–13 weeks gestation can be obtained using axial planes at the level of the bony palate. In rare cases, the retronasal triangle in a coronal view and the maxillary gap in the standard mid-sagittal view of the face may be helpful [35].

**Associated anomalies:** There have been found associated anomalies in 50% of the patients with isolated CP and 13% of those with CL-CP. In cases of isolated CL or CP, the most frequent anomaly is clubfoot, whereas in cases of CL-CP, it is polydactyly. It is particularly important to notice the association with congenital heart disease [36].



**Figure 16.** Schematic representation of various types of the cleft lip and the cleft palate. (A) Normal, (B) Isolated cleft lip, (C) Unilateral cleft lip, maxilla and anterior palate, (D) Bilateral cleft lip, maxilla and anterior palate, (E) Isolated cleft palate, and (F) Bilateral cleft lip and palate [34].

**Prognosis:** If the defects are minimal, as is the case with the lineal indentations of the lips or submucosal cleft of the soft palate, surgical correction may not be required. If the defects are larger and cause esthetic, swallowing, and respiratory problems, then surgical correction is a must, and recent advances in surgical techniques have had good results. Anyhow, the prognosis depends primarily on the presence and type of associated anomalies [37].

The advisability of karyotype is controversial due to the low incidence of chromosomal anomalies in clefting defect. Fetuses should be delivered in a tertiary center because of the possibility of respiratory and feeding problems.

### 6.1. Median cleft lip

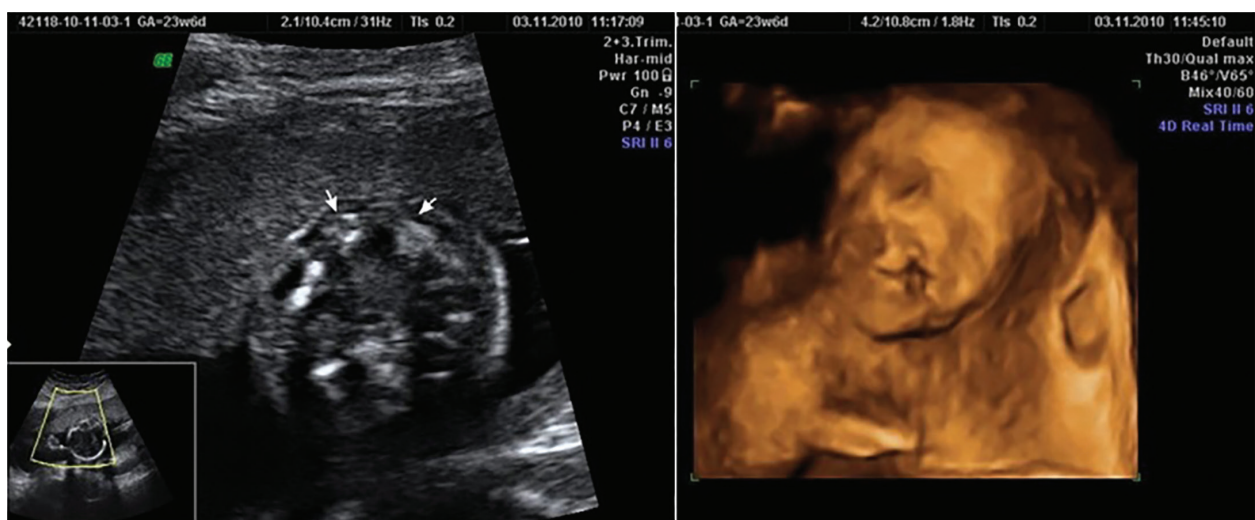**Synonyms:** Complete median cleft lip, pseudomedian cleft lip, and premaxillary agenesis.

**Definition:** A quadrangular or triangular median defect of the upper lip, which could extend to the posterior of the nose (**Figure 17**) [38].

**Incidence:** Median cleft lip (MCL) is noticed in 0.2–0.7% of all cases of the cleft lip [39].

**Embryology:** The maxillary prominences are joined by the frontonasal prominence, from where the maxilla and the median region of the upper lip start (**Figure 9**). It is the exact area which is left underdeveloped or absent in the median cleft lip cases. There is a strong link between the development of the midline facial structures and the process by which the forebrain is differentiated. The prechordal mesenchyma, the tissue interposed between the prosencephalon, and the roof of the primitiva mouth (stomodeum) are likely to induce both events [40]. Cerebral anomalies, such as holoprosencephaly, are often linked with the midline abnormalities of the face.

**Etiology and pathology:** MCL is described only as part of two distinct syndromes: MCL with orbital hypotelorism, in itself a synonym for holoprosencephaly, and MCL with orbital hypertelorism. In the former case, the premaxillary bone, nasal septum, nasal bones, and crista galli



**Figure 17.** Axial scan of the median cleft lip.

are absent. The ethmoid bone (that set the interorbital distance) is hypoplastic. The secondary palate may or may not be involved. MCL with hypertelorism (also known as “median cleft face syndrome” or “frontonasal dysplasia”) is characterized by the presence of a bifid nose and cranium bifidum occultum, as well as of the premaxilla, while the brain is normal in most cases.

**Diagnosis:** The defect, involving both the upper lip and the palate, is better seen in axial scans of the palate (**Figure 17**). A useful hint in this process is the visualization of the tongue in a position within the oral cavity, which is higher than normal. The sonographer should be alerted to a possible pitfall in the diagnosis of MCL because sometimes the defect may be masked by the tongue, giving a false impression of an intact palate [41].

**Prognosis and obstetrical management:** Prognosis depends entirely on the association with other anomalies. MCL syndrome is associated in 80% of cases with normal intelligence. Radical cosmetic surgery is required. If alobar holoprosencephaly present, it is uniformly lethal [42].

## 6.2. Epignathus

**Definition:** A teratoma that arises from the oral cavity or pharynx.

**Incidence:** 2% of all pediatric teratomas occur in the nasopharyngeal area (including oral, tonsillar, and basicranial areas). The majority of cases occur in newborn [43, 44].

**Pathology:** Tumors arise mainly from the sphenoid bone; they rarely arise from other areas (the hard and soft palate, the pharynx, the tongue, and jaw). These tumors grow into the oral or nasal cavity or intracranially. Obstruction of the mouth is responsible for polyhydramnios. Most tumors are benign, consisting histologically of tissues derived from any of the three germinal layers. They can fill the mouth and airways and lead to acute asphyxia immediately after birth [44].

**Ultrasound diagnosis:** Solid tumor arising from the sphenoid bone, hard and soft palate, the pharynx, the tongue, and the jaw. The tumor may grow into the oral or nasal cavity or intracranially. Calcifications and cystic components may also be noticed. The differential diagnosis will include neck teratomas, encephaloceles, conjoined twins, and other tumors of the facial structures. Polyhydramnios (due to pharyngeal compression) is usually present.

**Associated abnormalities:** This is a sporadic condition, with no increased incidence of chromosomal defects or genetic syndromes; only 6% of these tumors have associated anomalies, and the facial ones being attributed to the mechanical effects of the tumor on developing structures [45].

**Investigations:** Scans every 4 weeks to monitor the growth of the tumor and assess the amniotic fluid. If polyhydramnios develops, amniodrainage may be balanced. Fetal MRI is recommended at 32 weeks to assess the spatial relation of the tumor to adjacent structures.

**Prognosis:** It depends on the size of the lesion and the involvement of vital structures. The lesions are usually very large, and the polyhydramnios associates a poor prognosis. The major cause of neonatal death is asphyxia due to airway obstruction. Surgical resection is possible at times. There are no reported cases of malignancies [46–49].

Fetuses with large tumors are best delivered by cesarean section, and an expert pediatric team must be available to intubate of the infant.

## 7. Abnormalities of the mandible

### 7.1. Robin anomalad

**Synonyms:** Cleft palate, micrognathia and glossoptosis, and Pierre Robin syndrome.

**Definition:** This anomaly is associated with micrognathia and glossoptosis, with a posterior cleft palate or a high arched palate.

**Incidence:** The frequency is 1:30,000 [50].

**Etiology:** In 40% of the cases, the anomaly is isolated and mostly sporadic, although sometimes familiar cases suggest both autosomal recessives and autosomal dominant patterns of transmission. It is most frequently seen in association with other anomalies or with recognized genetic and nongenetic syndromes [51].

**Embryology:** The mandible starts at the point in which the two mandibular prominences join to delimit the inferior part of the stomodeum. The fusion of the three palatine processes forms the palate. Finally, the frontonasal prominence creates the median, and the maxillary processes create the two lateral ones. It is apparent that the three components of this defect are related to one another. Possibly, an early hypoplasia of the mandible creates this defect, as it leads to the tongue being displaced toward the posterior region, which prevents the posterior palatine processes to close as they should in a normal situation [52].

**Associated anomalies:** The Robin anomaly is found as an isolated lesion in 39% of all patients. In 36%, one or more associated anomalies are present. In 25% of patients, a known syndrome is found.

Robin anomaly is to be suspected when polyhydramnios is associated with micrognathia (**Figure 18**). Congenital heart disease occurs in 10% of affected neonates, so fetal echocardiography is recommended [53].

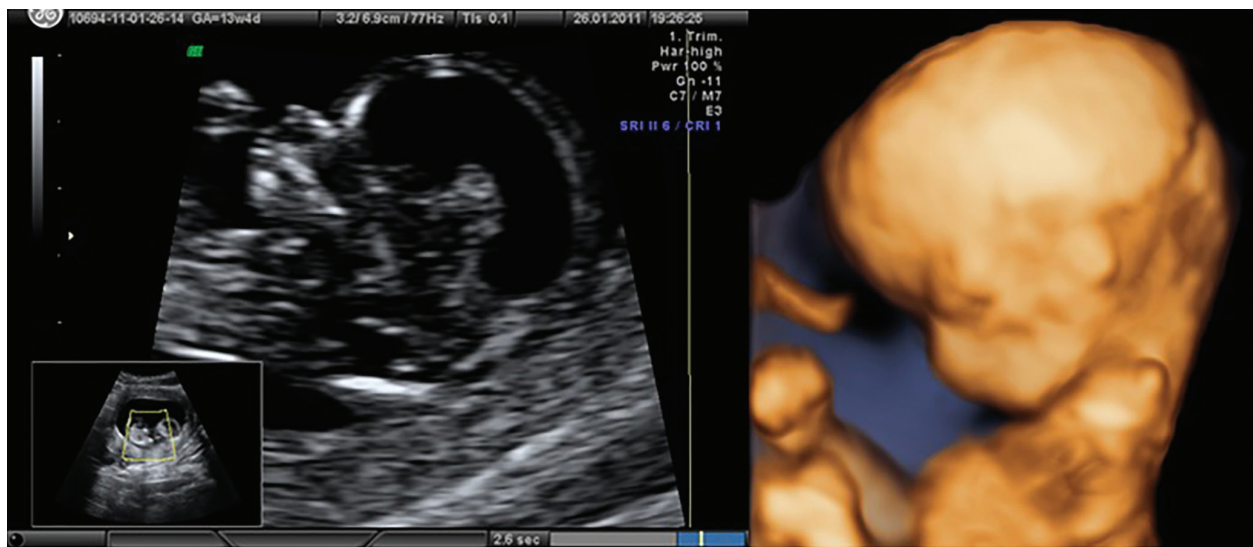**Prognosis:** The Robin anomaly is a neonatal emergency in many cases. Glossoptosis may lead to the obstruction of the airways and suffocation.

It is mandatory that a pediatrician be present in the delivery room and be prepared to intubate the infant. Karyotype should be considered [54].

### 7.2. Otocephaly

**Definition:** Otocephaly is a grotesque anomaly, characterized by the absence or hypoplasia of the mandible, proximity of the temporal bones, and abnormal horizontal position of the ears. This malformation is considered to be the result of an improper development of the mandible, probably caused by a defect in the migration of the neural crest cells. The ears position





**Figure 18.** Sagittal scan a fetus at 13 weeks of gestation shows prominent forehead and retrognathia (polyplody).

themselves horizontally, with the lobules closer to the midline, most certainly because of either absence or extreme hypoplasia of the mandible (**Figure 8**).

The anatomic lesions range from ears closely opposed to the midline (synotia), agnathia, absence of the mouth to varying degrees of micrognathia and low set ears (melotia).

Otocephaly may be part of very severe malformation complexes, such as conjoined twins and holoprosencephaly [55].

**Associated anomalies:** Holoprosencephaly, neural tube defects, cephaloceles, midline proboscis, hypoplastic tongue, tracheoesophageal fistula, cardiac anomalies, and adrenal hypoplasia [56].

**Diagnosis:** This anomaly is to be suspected when the jaw cannot be visualized and the ears are noticed in a very low position. Fetuses with extremely severe anomalies, such as anencephaly, holoprosencephaly, and cephaloceles, also present this defect. In cases of milder anomalies, it is difficult to distinguish the otocephaly from other conditions characterized by very low set ears, for instance Treacher Collins syndrome, during a prenatal ultrasound examination [57, 58].

**Prognosis and obstetrical management:** This condition is incompatible with life. Pregnancy termination could be offered any time in a pregnancy when a confident diagnosis is made [57].

## 8. The chin: Micrognathia-retrognathia or prognathia

Abnormal size of the chin, micrognathia and macrognathia, and abnormal length of the philtrum (short or long) are morphological features in numerous syndromes.

### 8.1. Micrognathia-retrognathia

Prevalence: 1: 1500 births.

**Ultrasound diagnosis:** Subjective finding of prominent upper lip and receding chin in the mid-sagittal view of the face (**Figure 18**). These findings might be due to micrognathia (short mandible) or retrognathia (backward displacement of the mandible). Severe micrognathia is associated with polyhydramnios (>25 weeks gestation), due to glossoptosis (normal tongue obstructing small oral cavity).

**Associated abnormalities:** Chromosomal abnormalities, mainly trisomy 18 and triploidy, are found in about 30% of cases. Any one of >50 genetic syndromes are found in most fetuses. Micrognathia is usually associated with >50 genetic syndromes, including Pierre-Robin anomaly, Treacher Collins syndrome, otocephaly [59].

**Investigations:** ultrasound including echocardiography, karyotyping and array.

**Follow up:** Ultrasound scans every 4 weeks to monitor growth and amniotic fluid.

**Delivery:** In hospital with facilities for neonatal intensive care, while a pediatrician is present in the delivery room and be prepared to intubate the neonate.

**Prognosis:** Neonatal mortality >80% due to associated abnormalities. In Pierre–Robin anomaly, the survival rate is good.

**Recurrence:** Genetic syndromes: 25–50%. Trisomies: 1%. Isolated: no increased risk of recurrence.

### Author details

Maria Șorop-Florea<sup>1</sup>, Roxana-Cristina Dragușin<sup>1</sup>, Ciprian Laurențiu Pătru<sup>1</sup>,  
Lucian George Zorilă<sup>1</sup>, Cristian Marinaș<sup>2</sup>, Virgiliu-Bogdan Șorop<sup>3</sup>, Cristian Neamțu<sup>4</sup>,  
Alina Veduța<sup>5</sup>, Dominic Gabriel Iliescu<sup>1\*</sup> and Nicolae Cernea<sup>1</sup>

\*Address all correspondence to: [dominic.iliescu@yahoo.com](mailto:dominic.iliescu@yahoo.com)

1 Department of Obstetrics and Gynecology, Prenatal Diagnostic Unit, University Emergency County Hospital, University of Medicine and Pharmacy Craiova, Romania

2 Department of Anatomy, University of Medicine and Pharmacy Craiova, Romania

3 Department of Obstetrics and Gynecology, University of Medicine and Pharmacy “Victor Babeș” Timișoara, Romania

4 Department of Pathophysiology, University of Medicine and Pharmacy Craiova, Romania

5 Department of Obstetrics and Gynecology, University of Medicine and Pharmacy “Carol Davila” Bucharest, Romania

## References

- [1] Benacerraf BR. Ultrasound of Fetal Syndromes. New York, London, Philadelphia, San Francisco: Churchill Livingstone.1998; pp. 83-223
- [2] Sonek J, Borenstein M, Dagklis T, Persico N, Nicolaides KH. Frontomaxillary facial angle in fetuses with trisomy 21 at 11-13(6) weeks. American Journal of Obstetrics Gynecology. 2007;**196**:271.e1-271.e4
- [3] Borenstein M, Persico N, Kagan KO, Gazzoni A, Nicolaides KH. Frontomaxillary facial angle in screening for trisomy 21 at 11+0 to 13+6 weeks. Ultrasound in Obstetrics & Gynecology. 2008;**32**:5-11
- [4] Jeanty P, Dramaix-Wilmet M, Van Gansbeke D, et al. Fetal ocular biometry by ultrasound. Radiology. 1982;**143**:513
- [5] Smith D, Jones KL. Smith's Recognizable Patterns of Human Malformation. 4th ed. Philadelphia: WB Saunders Company; 1988
- [6] Sivan E, Chan L, Mallozzi-Eberle A, Reece EA. Sonographic imaging of the fetal face and the establishment of normative dimensions for chin length and upper lip width. American Journal of Perinatology. 1997 April;**14**:191-194
- [7] Langman's Medical Embryology: 12th ed - Ch. 17 (Head & Neck). pp. 276-277
- [8] Goldstein I, Tamir A, Weiner Z, Jakobi P. Dimensions of the fetal facial profile in normal pregnancy. Ultrasound in Obstetrics & Gynecology. (February), 2010;**35**(2):191-194
- [9] Bergsma, D. Birth Defects Compendium. 2nd ed. Macmillan; 1979
- [10] Jeanty P, Cantraine F, Consaert E, Romero R, Hobbins JC. The binocular distance: A new way to estimate fetal age. Journal of Ultrasound in Medicine. 1984 June;**3**(6):241-243
- [11] Mayden KL, Totoro M, Berkowitz RL, Bracken M, Hobbins JC. Orbital diameters: A new parameter for prenatal diagnosis and dating. American Journal of Obstetrics & Gynecology. 1982;**144**(.3) October:pp. 289-297
- [12] Schlenck B, Unsinn K, Geley T, Schon A, Gassner I. Sonographic diagnosis of congenital dacryocystocele. Ultraschall in der Medizin. 2002;**23**:181-184
- [13] Shashy RG, Durairaj V, Holmes JM, Hohberger GG, Thompson DM, Kasperbauer JL. Congenital dacryocystocele associated with intranasal cysts: Diagnosis and management. Laryngoscope. 2003;**113**:37-40
- [14] Tonni G, Ventura A, Centini G, De Felice C. First trimester three-dimensional transvaginal imaging of alobar holoprosencephaly associated with proboscis and hypotelorism (ethmocephaly) in a 46, XX fetus. Cong Animal. 2008;**48**:51-55
- [15] Goldstein I, Weissman A, Brill-Zamir R, Laevsky I, Drugan A. Ethmocephaly caused by de novo translocation 18; 21 – Prenatal diagnosis. Prenatal Diagnosis. 2003 October; **23**(10):788-790

- [16] Christele D, Claude B, Laurent P, et al. Holoprosencephaly. *Orphanet J Rare Dis*. 2007;2:8. Published online 2007 February; doi: 10.1186/1750-1172-2-8
- [17] Johnson CY, Rasmussen SA. Non-genetic risk factors for holoprosencephaly. *American Journal of Medical Genetics*. 2010;154C(1):73-85
- [18] Francis PJ, Berry V, Bhattacharya SS, et al. The genetics of childhood cataract. *Journal of Medical Genetics*. 2000;37:481-488
- [19] Hejtmancik J. Congenital cataracts and their molecular genetics. *Seminars in Cell & Developmental Biology*. 2008;19:134-149
- [20] Lee JO, Jung JL, Kim MJ, et al. Prenatal ultrasonographic diagnosis of congenital cataract: A case report. *Korean Journal of Ultrasound Obstetrics Gynecology*. 2012;55:839-842
- [21] Chitkara U, Lee L, Oehlert JW, Bloch DA, Holbrook RH, El-Sayed YY, Druzin ML. Fetal ear length measurement: A useful predictor of aneuploidy? *Ultrasound in Obstetrics & Gynecology*. 2002 February;19(2):131-135
- [22] Cicero S, Curcio P, Papageorghiou A, Sonek J, Nicolaides K. Absence of nasal bone in fetuses with trisomy 21 at 11-14 weeks of gestation: An observational study. *Lancet*. 2001 November 17;358(9294):1665-1667
- [23] Olsen E, Gjelland K, Reigstad H, Rosendahl K. Congenital absence of the nose: A case report and literature review. *Pediatric Radiology*. 2001;31:225-232
- [24] McGlone L. Congenital arhinia. *Journal of Pediatric Child Health*. 2003;39:474-476
- [25] Cusick W, Sullivan CA, Rojas B, Poole AE, Poole DA. Prenatal diagnosis of total arhinia. *Ultrasound Obstetrics Gynaecology*. 2000;15:259-261
- [26] Lim AS, Lim TH, Kee SK, et al. Holoprosencephaly: An antenatally-diagnosed case series and subject review. *Annals of the Academy of Medicine, Singapore*. 2008;37:594-597
- [27] Chen CP, Shih JC, Hsu CY, Chen CY, Huang JK, Wang W. Prenatal three-dimensional/four-dimensional sonographic demonstration of facial dysmorphisms associated with holoprosencephaly. *Journal of Clinical Ultrasound*. 2005;33:312-318
- [28] Chen CP, Chern SR, Lin CJ, Lee CC, Wang WA. Comparison of maternal age, sex ratio and associated anomalies among numerically aneuploid, structurally aneuploid and euploid holoprosencephaly. *Genetic Counseling*. 2005;16:49-57
- [29] Papageorghiou AT, Avgidou K, Spencer K, Nix B, Nicolaides KH. Sonographic screening for trisomy 13 at 11 to 13 + 6 weeks of gestation. *American Journal of Obstetrics and Gynecology*. 2006;194:397-401
- [30] Eckmann-Scholz C, Jonat W. 3-D ultrasound imaging of a prenatally diagnosed Beckwith-Wiedemann syndrome. *Archives of Gynecology and Obstetrics*. 2011;284:1051-1052
- [31] O'Connor C, Levine D. Case 49: Beckwith-Wiedemann syndrome. *Radiology*. 2002;224:375-378



- [32] Walker SJ, Ball RH, Babcock CJ, Feldkamp MM. Prevalence of aneuploidy and additional anatomic abnormalities in fetuses and neonates with cleft lip with or without cleft palate: A population-based study in Utah. *Journal of Ultrasound in Medicine*. 2001; **20**:1175-1180
- [33] Sohan K, Freer M, Mercer N, Soothill P, Kyle P. Prenatal detection of facial clefts. *Fetal Diagnosis and Therapy*. 2001; **16**:196-199
- [34] Bianchi DW, Crombleholme TM, D'Alton ME, Malone FD. *Diagnosis and Management of the Fetal Patient*, 2nd ed
- [35] Campbell S, Lees CC. The three-dimensional reverse face. *Obstetrics and Gynecology*. 2003; **22**:552-554
- [36] Hanikeri M, Savundra J, Gillett D, Walters M, McBain W. Antenatal transabdominal ultrasound detection of cleft lip and palate in Western Australia from 1996 to 2003. *The Cleft Palate-Craniofacial Journal*. 2006; **43**:61-66
- [37] Cohen MM. Etiology and pathogenesis of orofacial clefting. *Oral and Maxillofacial Surgery Clinics of North America*. 2000; **12**:379-397
- [38] Mossey PA, Julian L, Mungar R, Dixon MJ, Shaw WC. Cleft lip and palate. *Lancet*. 2009; **374**:1773-1785
- [39] Saraf S. Median cleft of the lip: A rare facial anomaly. Internet. *Journal of Plastic Surgery*. 2006; **2**
- [40] Ewings EL, Carstens MH. Neuroembryology and functional anatomy of craniofacial clefts. *Indian Journal of Plastics Surgery*. 2009; **42**(Suppl):S19-S34
- [41] Collares MP, Pinto RA. False vs true media cleft lip: Report of two cases and differential management. *Brazil Journal of Cranio-Maxillo-Facial Surgery*. 2001; **4**(2):25-31
- [42] Urata MM, Kawamoto HK Jr. Median clefts of the upper lip: A review and surgical management of a minor manifestation. *The Journal of Craniofacial Surgery* 2003 Sep; **14**(5):749-755
- [43] Șorop-Florea M, Iliescu DG, Tudorache S, Simionescu C, Cernea N, Novac LV, Tanase F, Cotarcea S, Comanescu a, Dragusin R, Patru C, Carbunaru O, Zorila L, Cernea D. The importance of perinatal autopsy. Review of the literature and series of cases. *Romanian Journal of Morphology and Embryology* 2017; **58**(2):323-337
- [44] Ahmadi M, Dalband M, Shariatpanahi E. Oral teratoma (epignathus) in a newborn: A case report. *Journal of Oral and Maxillofacial Surgery, Medicine Pathology*. 2012; **24**:59-62
- [45] Shah A, Latoo S, Ahmed I, Malik A. Head and neck teratomas. *Journa of Maxillofacial and oral Surgery*. 2009; **8**(1):60-63
- [46] Tsitouridis I, Sidiropoulos D, Michaelides M. Sonographic evaluation of [12] epignathus. *The Hip*. 2009; **13**(1):55-57

- [47] Iliescu D, Tudorache S, Comanescu A, Antsaklis P, Cotarcea S, Novac L, Cernea N, Antsaklis A. Improved detection rate of structural abnormalities in the first trimester using an extended examination protocol. *Ultrasound in Obstetrics & Gynecology*. 2013 Sep;**42**(3):300-309. DOI: 10.1002/uog.12489
- [48] Tudorache Ș, Gabriel D Iliescu Parental attitude to participate in follow-up research studies of their children's development after diagnosis of fetal abnormalities in a tertiary center in Romania *Obstetrica și Ginecologia*, nr.4, 2016
- [49] Hu R, Jiang RS. The recurrence of a soft palate teratoma in a neonate: A case report. *Head & Neck Oncology*. 2013;**5**(2):16
- [50] Printzlau A, Andersen M. Pierre Robin sequence in Denmark: A retrospective population-based epidemiological study. *The Cleft Palate-Craniofacial Journal*. 2004;**41**(1):47-52
- [51] Selvi R, Mukunda Priyanka AR. Role of SOX9 in the etiology of Pierre-Robin syndrome. *Iranian Journal of Basic Medical Sciences*. 2013;**16**(5):700-704
- [52] Jakobsen LP, Knudsen MA, Lespinasse J, et al. The genetic basis of the Pierre Robin sequence. *The Cleft Palate-Craniofacial Journal*. 2006;**43**(2):155-159
- [53] Bronshtein M, Blazer S, Zalel Y, Zimmer EZ. Ultrasonographic diagnosis of glossoptosis in fetuses with Pierre Robin sequence in early and mid pregnancy. *American Journal of Obstetrics and Gynecology* 2005;**193**(4):1561-1564
- [54] Smith MC, Senders CW. Prognosis of airway obstruction and feeding difficulty in the Robin sequence. *International Journal of Pediatric Otorhinolaryngology*. 2006; **70**(2):319-324
- [55] Gekas J, Li B, Kamnasaran D. Current perspectives on the etiology of agnathia-otocephaly. *European Journal of Medicine Genetics*. 2010;**53**:358-366
- [56] Iliescu D, Cara M, Tudorache S, Antsaklis P, Ceausu I, Paulescu D, Novac L, Cernea N, Antsaklis A. Challenges in sonographic detection of fetal major structural abnormalities at the first trimester anomaly scan. *Donald School Journal of Obstetrics Gynecology*. 2015;**9**(3):239-259. DOI: 10.5005/jp-journals-10009-1411
- [57] Dragusin R, Florea M, Iliescu D, Cotarcea S, Tudorache S, Novac L, Cernea N. The contribution and the importance of modern ultrasound techniques in the diagnosis of major structural abnormalities in the first trimester. *Current Health Sciences Journal*. 2012;**38**:1
- [58] Wagner JH, Hérbene JFM, Edward AJ, Jurandir PP. Agnathia-otocephaly: Prenatal diagnosis by two- and three-dimensional ultrasound and magnetic resonance imaging. Case report. *Medical Ultrasonography*. 2014;**16**(4):377-379
- [59] Gull I, Wolman I, Merlob P, Jaffa AJ, Lessing JB, Yaron Y. Nomograms for the sonographic measurement of the fetal philtrum and chin. *Fetal Diagnosis and Therapy*. 2005 March–April;**20**(2):127-131

