

We are IntechOpen, the world's leading publisher of Open Access books Built by scientists, for scientists

6,900

Open access books available

186,000

International authors and editors

200M

Downloads

Our authors are among the

154

Countries delivered to

TOP 1%

most cited scientists

12.2%

Contributors from top 500 universities



WEB OF SCIENCE™

Selection of our books indexed in the Book Citation Index
in Web of Science™ Core Collection (BKCI)

Interested in publishing with us?
Contact book.department@intechopen.com

Numbers displayed above are based on latest data collected.
For more information visit www.intechopen.com



Current Treatment for Carpal Tunnel Syndrome

Leonel Garcia Benavides, Sylvia Elena Totsuka Sutto,
Leonel Garcia Valdes, Simon Q. Rodríguez Lara,
Guillermo Ramos Gallardo,
Ana Rosa Ambriz Plascencia and
Miriam Méndez del Villar

Additional information is available at the end of the chapter

<http://dx.doi.org/10.5772/intechopen.72946>

Abstract

The combination of surgical procedure (open or endoscopic techniques), rehabilitation and antioxidant therapy (Alpha lipoic acid, curcumin) is superior to monotherapies in the prognosis and recovery of patients with this pathology. The prescription of these medications by their mechanisms of action should be allocated prior to decompression surgery and should continue receiving medication during the rehabilitation time. Clinical and electrophysiological follow-ups are required to verify the improvement.

Keywords: carpal tunnel syndrome, median nerve entrapment, compression neuropathy

1. Definition

The American Academy of Orthopedic Surgeons (AAOS) defines the carpal tunnel syndrome (CTS) as the most common form of entrapment neuropathy of the median nerve, and the syndrome affects 3.8% of the general population [1], with an incidence in both genders of 376 per 100,000 US habitants [2] combined and with a prevalence that usually varies in relation to the risk factors of a specific population; a study among poultry processing employees reported an estimated prevalence of 42%. CTS is one of the most common clinical problems encountered by hand surgeons. Although this syndrome is widely recognized, its etiology remains largely unclear [3].

2. Anatomy

The median nerve (MN) derives from the brachial plexus as a terminal branch of the medial and lateral cord. The fibers from the lateral cord (C6–7) provide sensitivity to the thumb, the index and the middle finger, as well as the motor fibers of the proximal muscles innervated by the median nerve (palmar muscles, pronator teres muscle). The medial cord (C8–T1) supplies most of the motor fibers to the distal muscles of the forearm and the hand, as well as the sensitivity to the external part of the ring finger. The MN descends through the arm without creating any branches until it reaches the forearm, just beneath the head of the pronator teres muscle, where its most important branch originates, the anterior interosseous nerve of the forearm. This nerve supplies the flexor pollicis longus, flexor digitorum profundus and pronator quadratus. Multiple muscular branches arise from the MN during its path, which supply the pronator teres, flexor carpi radialis, palmaris longus and flexor digitorum superficialis muscles. Proximal to the wrist and the carpal tunnel (CT), the palmar branch of the median nerve emerges and innervates the skin of the thenar eminence [4] (**Figure 1**).

In the palm of the hand, the MN sends a motor branch to the lumbricals of the index and the middle finger as well as a recurrent branch to innervate the muscles of the thenar eminence (abductor pollicis brevis, flexor pollicis brevis and opponens pollicis). The proper palmar

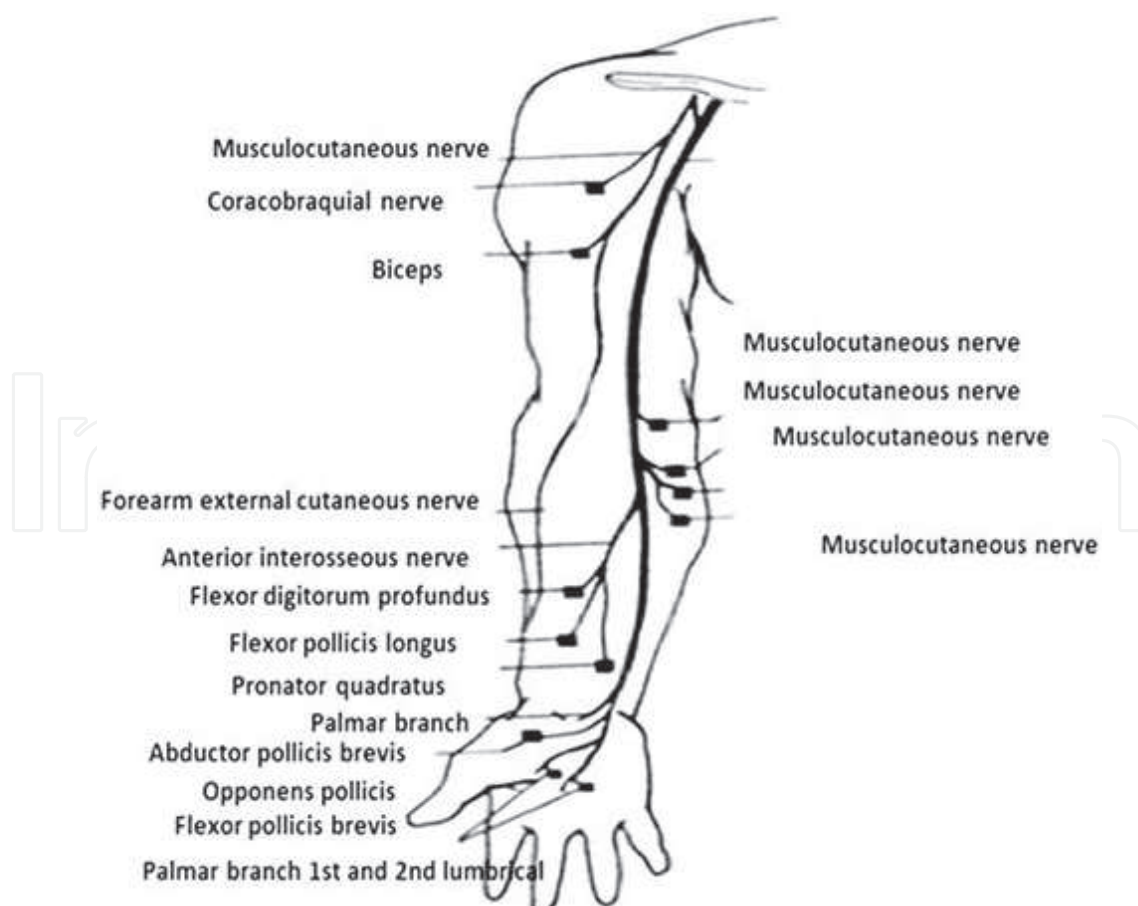


Figure 1. Median nerve pathway.

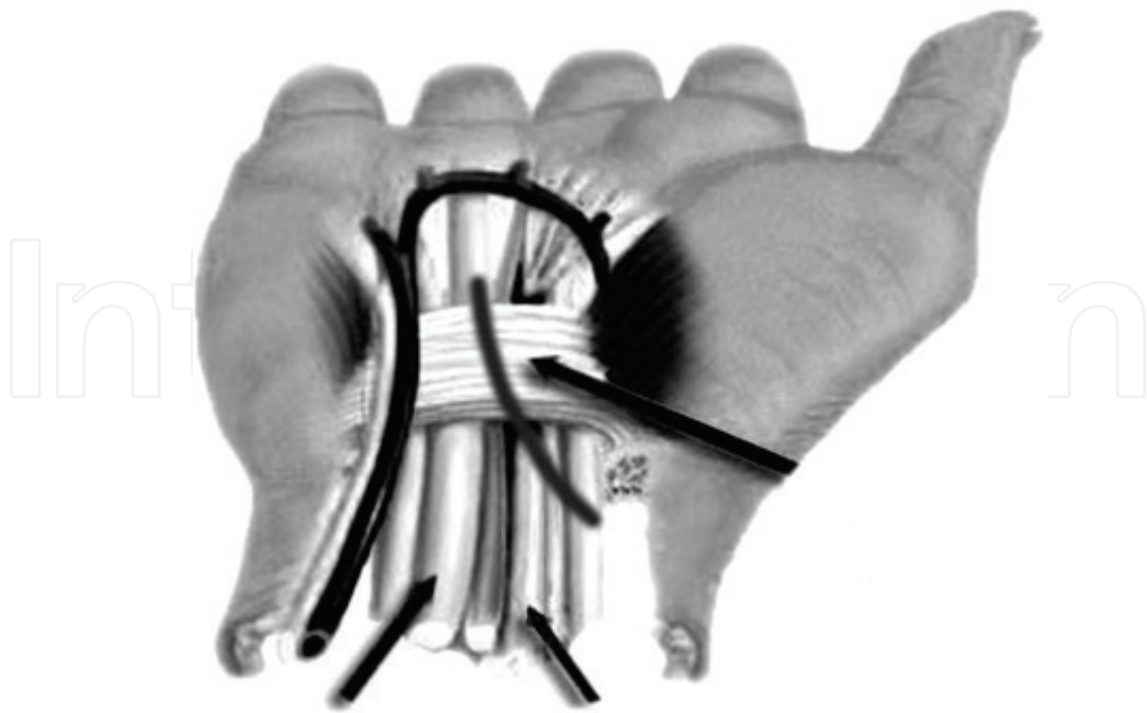

Figure 2. Anatomical elements involved in the procedure to open the transverse carpal ligament.

digital nerves are sensory fibers that supply the skin of the index and the middle fingers as well as the medial part of the ring finger and medial surface of the thumb [4] (**Figure 1**). There are multiple anatomical variants in the path and distribution of the MN, which could be present in up to 11% of the population. The most common variants are the presence of a medial residual artery, which is an embryological remnant that usually suffers a regression in the second trimester but could persist in 5% of the population, and it is also related to the presence of the CTS, and the anastomosis of Martin Gruber, which is a motor communication between the median and ulnar nerve at the forearm, which could have its origin from the union of the principal fibers of these nerves or in the anastomosis of the anterior interosseous nerve with the ulnar nerve and it is present in 5–10% of the population [5].

The carpal tunnel connects the anterior compartment of the forearm to the palm of the hand. It is delimited medially by the pisiform bone, laterally by the hamulus of the unciform bone, posteriorly by the scaphoid bone and the trapezoid bone and its roof by the transverse carpal ligament. It can be divided into three portions:

1. Proximal: it includes the volar carpal ligament, originated in the forearm.
2. Medial: the space comprehended between the pisiform bone and the unciform bone, and it has approximately 20 mm of width and a transversal area of 1.6 cm².
3. Distal: it corresponds to the origin of the palmar aponeurosis.

Many structures pass through the carpal tunnel, such as eight flexor tendons of the fingers (four superficialis and four profundus) and the flexor pollicis longus, and usually the localization of the median nerve is superficial to the tendons and medial to the flexor pollicis longus [4] (**Figure 2**).

3. Physiopathology of carpal tunnel syndrome

CTS is generally conceded as disarrangement caused by a decoupling of the size of the components of the carpal tunnel, and the space delimited by the fibrous and osseous structures. This is what conditions the compression of the median nerve, altering its irrigation. The compression of the components within the carpal tunnel induces venous congestion and epineural edema, consequently inducing fibroblast invasion in the affected tissue causing constriction and fibrosis of the endoneural compartment of the median nerve. The edema and the epineural and endoneural compression interrupt the axoplasmic flow of nutrients and ions and cause the median nerve to become enlarged [6].

Furthermore, the most common diagnosis is idiopathic CTS; nevertheless, recent studies that used magnetic resonance imaging (MRI), histological and biomechanical techniques have strongly suggested that abnormalities of the synovial tissue within the carpal tunnel are closely related to the development of idiopathic CTS, which means that subsynovial connective tissue may be predisposed to shear injury from activity done in 60° of wrist flexion [7].

4. New components to be highlighted in physiopathology of CTS

4.1. Effect of ischemia/reperfusion in the progression of the nervous injury in the carpal tunnel syndrome

The symptoms of CTS are caused by increased pressure within the carpal tunnel, and therefore, a decreased function of the median nerve. Nerve damage is attributed to restriction of blood flow in the endoneural capillary system, leading to alterations in the blood-nerve barrier structure and resulting in endoneural edema, venous congestion, ischemia and subsequent metabolic abnormalities. The ischemia-reperfusion injury of the median nerve results in oxidative stress and inflammation of the subsynovial connective tissue, and it has been proposed that this could have major contribution in the evolution of idiopathic CTS.

The intermittent compression of the vascular-nervous plexus due to a reduction of lumen of the carpal tunnel is one of the pathophysiological processes that is suspected to be the cause of development of CTS [1–6]. Nervous tissue has a very small capacity to tolerate ischemia (<20 min), which makes this tissue very vulnerable to be damaged [2–4, 6–10]; the component of narrowing of the carpal tunnel is intermittent, but persistent, which means that the injury is not presented acutely but rather progresses chronically [8–10].

The ischemia/reperfusion (I/R) phenomenon begins with an occlusion of arterial or venous blood flow to a tissue or an organ (ischemia); this interruption in the perfusion to the tissue will develop a direct injury in a limited area due to the ischemia, and this occurs in a specific time and depends on the affected organ (musculoskeletal, cardiac, renal, neuronal, adipose, tendinous, etc.). When the blood flow is restored (reperfusion), multiple local and systemic mechanisms will be activated in the affected area, which implies an increase of injury, known as I/R injury. The extension of this depend on the perfusion area of the affected vessel, the

time of ischemia and the repeated number of I/R events. Initially, it leads to an acute lesion proper of the phenomenon, then a major extension of the damage secondary to the repetition of I/R events, since in the CTS, it occurs in an intermittent and prolonged way [7, 10–12].

4.2. Components of the I/R injury in the carpal tunnel syndrome

There are multiple components in the I/R phenomenon [10, 12]; however, the most important components in the pathological development of the carpal tunnel are as follows: (1) increase in the cytosolic cations' concentration (change in the permeability of the membrane), (2) mitochondrial lesion (alteration of the ATP production and oxidative stress), (3) oxidative stress (production of reactive oxygen and nitrogen species coupled by disruption of redox reaction), (4) immunity-mediated lesion and (5) transcriptional reprogramming [11, 12] (**Figure 3**).

4.3. Alteration of the cellular membrane permeability

The activation of multiple transporters in the cellular membrane during the I/R phenomenon will lead to major changes (related to cellular microenvironment) in the calcium (Ca^{2+}) and

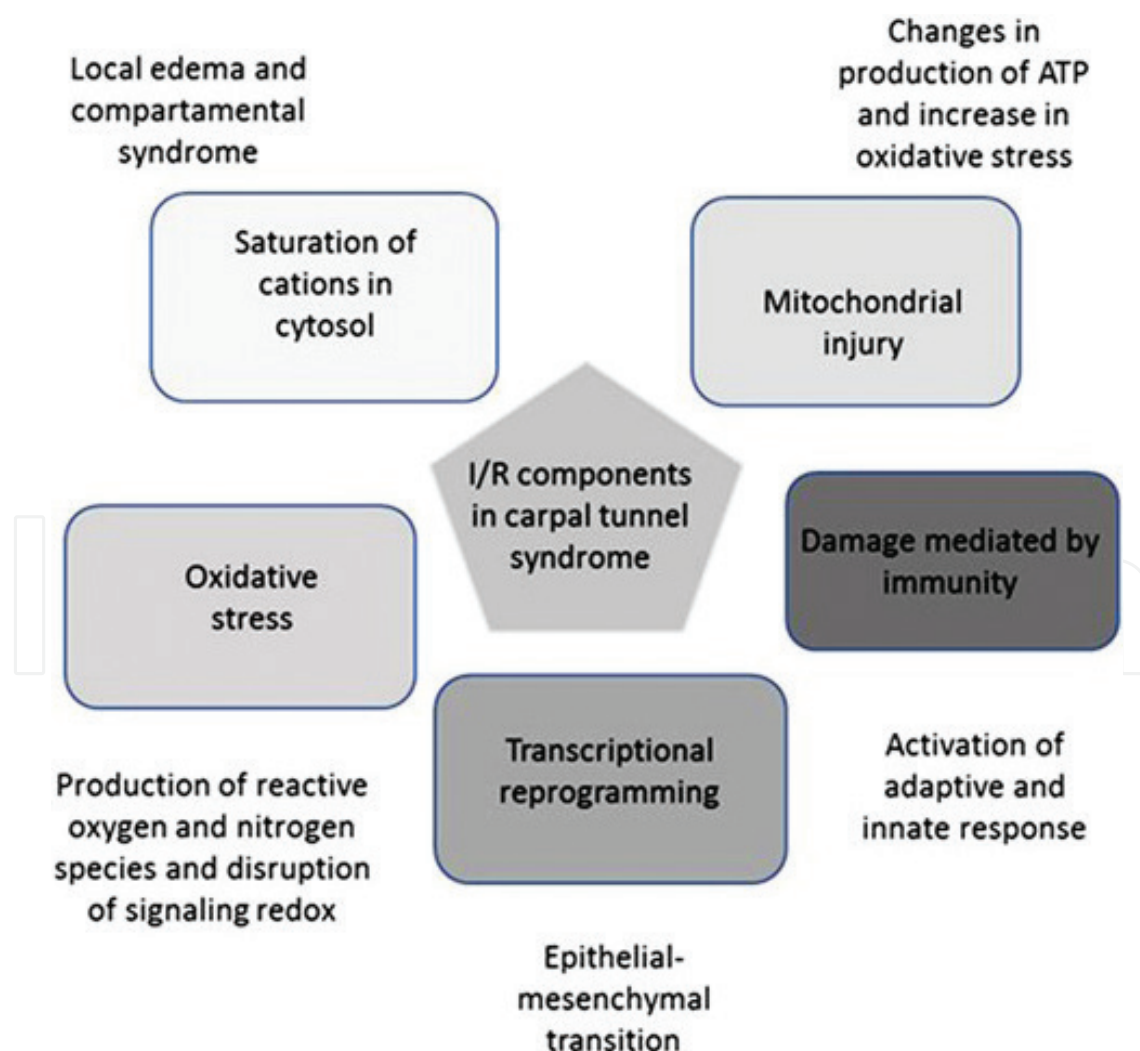


Figure 3. I/R components in carpal tunnel syndrome and pathophysiological events in the damage of local tissues.

sodium (Na^+) concentration. The movement of these cations through the membrane will be accompanied by water molecules that migrate from the extracellular space into intracellular and vice versa, making changes in the cellular volume leading to cellular and interstitial edema [9, 13, 14]. This edema expressed exclusively by the affected tissue will impact all the cellular groups in the adjacency such as nervous, adipose, muscular and endothelial cells from the structure of the carpal tunnel, and it can be accompanied by nervous or endothelial injury that will manifest with changes in the volumes of water in different compartments. These changes will produce secondary and interstitial compartment syndrome followed by edema, extended ischemia and local necrosis [9, 13–15].

4.4. Mitochondrial lesion

The mitochondria participate in multiple cellular activities such as ATP production and modulation of the redox state of the cell. The ATP production over the injury process is interrupted by a blocked complex in the respiratory chain (complexes III and IV), depletion of metabolic substrates (ADP, P_i , pyruvate, etc.) and high production of nitric oxide (NO^*) [15, 16]. The mitochondrial injury translates as a failure to adapt to the deprivation of oxygen and an OS overload to the enzymatic scavenger of the mitochondria in the affected cells by I/R phenomenon [16, 17]. If the lesion is substantial, it will be followed by fission processes of the mitochondria (fragmentation), loss of function and loss of the membrane potential [16, 17].

4.5. Oxidative stress and signaling redox

The blockage of the respiratory chain in the mitochondria increases the amount of oxidative stress (OS), leading to a production of reactive oxygen species (ROS) such as superoxide anion (O_2^*) and mainly, hydrogen peroxide (H_2O_2). The increase in the production of NO^* combined with the overproduction of ROS (in the phase of reperfusion) and the overload of scavenger systems in the mitochondria will magnify the production of reactive nitrogen species (RNS), primarily peroxynitrite (ONOO^*) [18–20].

The cells that present mitochondrial injury coupled with loss of mitochondrial membrane potential, “point of safe return” (PSR), will cause opening of mitochondrial permeability transitional pores (mPTP). The opening of these pores will liberate all mitochondrial ROS and RNS gathered in the matrix that will subsequently interact with cellular components (mostly lipids, proteins, nucleic acids), corrupting the function and triggering mechanisms of cellular apoptosis and autophagy [19–21].

The ROS and RNS production (OS) alters the function of the cell and make changes in the signaling redox of the adjacent survivor cells [22, 23], as some species of free radicals have the capacity to travel up to 400 nm in distance (ONOO^*) causing disturbance in the function and the configuration of membrane components and organelles in other healthy cells. By modifying redox signaling, the affected cells that survived the initial lesion can trigger a transcriptional reprogramming that will lead them to gene expressions of cellular injury such as pro-inflammatory cytokine receptors, making them susceptible to apoptosis induced by immunity-mediated cells [23].

4.6. Immunity-mediated lesion

The I/R lesion will activate three types of inflammatory responses such as sterile, adaptive and innate [11, 24]. The three kinds of immunity are activated by the OS activity generated in the mitochondria of affected cells by the initial lesion and the liberation of cellular material of necrotic cells (DNA, RNA, lysosomes, proteases, glucosidases, ATP, ADP, etc.), and this will secondarily result in the activation and differentiation of inflammatory cells, producing an adaptive response. In the lesion by IR, the toll-like receptors (TLRs) will be expressed in the cellular membrane, principally TLR2 and TLR4 [25]. Sterile immunity is characterized by the recruitment of neutrophils and macrophages and also by the production of pro-inflammatory and anti-inflammatory cytokines such as IL-1 β , IL-6, TNF- α and IL-10 liberated by the damaged cells. The expression of pro-inflammatory cytokines will induce the local activation of the immune system causing necrosis of the previously injured cells and increasing the extension of the lesion [26].

The activation of multiple inflammatory systems due to the I/R phenomenon will involve a continuous inflammation that will persist while compression exists, increasing the damage; therefore, the recovery of this process will also depend on the chronicity of the injury. The transcriptional reprogramming of injured tissues will produce a change in some cellular groups, causing the expansion not only of acute but also of chronic and permanent lesion by the presence of fibrosis in the damaged area [27].

4.7. Transcriptional reprogramming

During the process of increased OS, disruption of signaling redox and inflammation will develop and result in transcriptional reprogramming, which involves a specific injured cell groups that will suffer a change in their structure and function, which is called epithelial mesenchymal transition. This produces cell mutation into pro-fibrotic phenotype cells, promoting permanent lesion of tissue and dysfunction of the limb [28, 29].

4.8. Clinical evaluation in CTS

In an individual with classical carpal tunnel syndrome, the most common symptom is pain accompanied by fingerprint weakness and numbness of the hand in the median nerve domain. The pain in CTS is characterized by two main pathophysiological processes: (1) acute ischemic pain due to compression and (2) chronic pain due to inflammation; the nervous tissue is the most susceptible tissue to the changes of oxygen and metabolic substrates [30]. The secondary lesion or death will manifest in sensation alterations and dysfunction, and the chronic lesion will lead to the formation of fibrosis and permanent lesion [31].

Two clinical provocation tests are useful to demonstrate severity and monitoring the progression. Phalen's test is applied by tapping over the median nerve as it passes through the carpal tunnel; a positive response is defined as a sensation of tingling in the distribution of the median nerve in the hand. Tinel's test is performed by hyperextending the wrist for 60 s; a positive response is defined as a sensation of tingling in the distribution of the median nerve in the hand [32].

The Boston Carpal Tunnel Questionnaire (BCTQ) is an easy, brief, self-administered questionnaire developed by Levine et al. for the assessment of symptom severity and functional status of patients with CTS. A validated version of the 11-item Boston Questionnaire for CTS (score range 11–55) is an evaluation instrument that was recognized as reproducible, valid, with internal consistency and able to respond to clinical changes, accepted in many countries for the assessment of severity of symptoms and functional status of patients, evaluating how the syndrome affects daily life [33] and the follow-up of progression (**Table 1**).

The severity of CTS is divided into three stages are as follows:

1. The symptoms presented during the first stage are as follows: waking up with the sensation of stiffness, numbness and weakness of the hand, perceiving the hand as swollen even though an increase in volume is not visible, pain with variable intensity that irradiates to the shoulder also called brachialgia paresthetica nocturna. The pain mitigates by shaking or flicking the hand.
2. In the second stage, the symptoms progress to being constant all day. Repeated hand or wrist motion and immobility of the hand for long periods of time may exacerbate the symptoms. At the moment of gripping objects, patients may also feel clumsiness or awkwardness.
3. The third stage is characterized by hypotrophy or atrophy of the thenar eminence, with a variable loss in the sensibility [31].

4.9. Electrophysiology

Nerve conduction studies (NCS) have to be performed immediately before the conservative treatment to follow-up progression and, in case surgery is required, evaluation before surgery and monitoring during recovery for at least after 3 months. Electrophysiology recordings from the median nerve could be analyzed in the context of Dumitru's reference values: distal sensory latency 3.0 ± 0.3 ms, distal sensory amplitude 15–50 μ V, distal motor latency 4.2 ms and distal motor amplitude 13.2 ± 5 mV [34].

4.10. Treatments of CTS

Patients with mild or moderate CTS may first be offered conservative treatment. Options include splinting [35], corticosteroid therapy [36], physical therapy and therapeutic ultrasound [37, 38]. Patients with severe CTS and those whose symptoms have not improved after 4–6 months of conservative therapy should undergo surgical decompression. Endoscopic or open techniques are equally effective [39]. Clinical and neurophysiological improvements can be observed within the first 3 months of surgery, but up to 20% of patients may experience persistent postoperative sensory symptoms [40, 41].

4.11. Surgical procedure

The standard technique of open carpal tunnel release has proven to be effective and safe [42, 43]. The classical technique consists of a 7-cm curved incision just ulnar to the thenar crease and

Boston Questionnaire Score

Name: _____

Evaluation date: ____/____/____ Surgery date: ____/____/____

Hand: (____) Right (____) Left

The following questions refer to your symptoms within a typical period of 24 h during the last 2 weeks.

- (1) How strong is the pain in your hand or wrist at night?
1. I feel no pain in hand or wrist at night.
 2. Little pain
 3. Moderate pain
 4. Intense pain
 5. Severe pain
- (2) How many times did your hand or wrist pain wake you up in a typical night for the last 2 weeks?
1. Never
 2. Once
 3. Twice or thrice
 4. Four to five times
 5. More than five times
- (3) Do you usually feel hand or wrist pain during the day?
1. I never feel pain during the day
 2. I feel little pain during the day
 3. I feel moderate pain during the day
 4. I feel intense pain during the day
 5. I feel severe pain during the day
- (4) How often do you feel hand or wrist pain during the day?
1. Never
 2. Once or twice a day
 3. Three to five times a day
 4. More than five times a day
 5. Constant pain
- (5) On average, how long do daytime pain episodes last?
1. I never feel pain during the day
 2. Less than 10 min
 3. From 10 to 60 min
 4. More than 60 min
 5. I feel constant pain during the day
- (6) Do you feel your hand dormant (lost sensitiveness)?
1. No
 2. I feel little dormancy
 3. I feel moderate dormancy
 4. I feel intense dormancy
 5. I feel severe dormancy
- (7) Do you feel weakness on your hand or wrist?
1. No weakness
 2. Little weakness
 3. Moderate weakness
 4. Intense weakness
 5. Severe weakness

Boston Questionnaire Score	
(8) Do you feel a tingling sensation on your hand?	<div><div>1. No tingling sensation</div><div>2. Little tingling sensation</div><div>3. Moderate tingling sensation</div><div>4. Intense tingling sensation</div><div>5. Severe tingling sensation</div></div>
(9) How strong is dormancy (lost sensitivity) or tingling sensation at night?	<div><div>1. I never feel dormancy or tingling sensation at night</div><div>2. Little</div><div>3. Moderate</div><div>4. Intense</div><div>5. Severe</div></div>
(10) How often did dormancy or tingling sensation wake you up during a typical night for the last 2 weeks?	<div><div>1. Never</div><div>2. Once</div><div>3. Two to three times</div><div>4. Four to five times</div><div>5. More than five times</div></div>
(11) How difficult do you feel in taking and using small objects such as keys or pens?	<div><div>1. Not difficult</div><div>2. A little difficult</div><div>3. Moderately difficult</div><div>4. Very difficult</div><div>5. Severely difficult</div></div>
Functional status of patients evaluates how the syndrome affects daily life	
In a typical day for the last 2 weeks, have your hand or wrist symptoms brought any difficulty in performing the activities listed below?	
Activity degree of difficulty	<div><div>1. No difficulty</div><div>2. Little difficulty</div><div>3. Moderate difficulty</div><div>4. Intense difficulty</div><div>5. Cannot perform the activity at all due to hands and wrists symptoms</div></div>
Writing	<div><div>1</div><div>2</div><div>3</div><div>4</div><div>5</div></div>
Buttoning clothes	<div><div>1</div><div>2</div><div>3</div><div>4</div><div>5</div></div>
Holding a book while reading	<div><div>1</div><div>2</div><div>3</div><div>4</div><div>5</div></div>
Holding the telephone hang	<div><div>1</div><div>2</div><div>3</div><div>4</div><div>5</div></div>
Housekeeping	<div><div>1</div><div>2</div><div>3</div><div>4</div><div>5</div></div>
Opening a glass vial cap	<div><div>1</div><div>2</div><div>3</div><div>4</div><div>5</div></div>
Carrying market bags	<div><div>1</div><div>2</div><div>3</div><div>4</div><div>5</div></div>
Bathing and dressing	<div><div>1</div><div>2</div><div>3</div><div>4</div><div>5</div></div>

Table 1. Boston questionnaire score (self-evaluation).

angulated over the flexion crease of the wrist in order to release the flexor retinaculum and antebrachial fascia under direct vision (**Figure 2**). Other options for an open technique consist of performing a short incision of 3 cm long in the mid-palm distal to the flexion crease of the wrist to dissect the flexor retinaculum under a deep plane to avoid subcutaneous fat and skin, then carefully sectioning the transverse carpal ligament using scissors. Although open release techniques have proven effectiveness and safety, some studies have associated minor complications with open release such as scar tenderness and pillar pain in the thenar and hypothenar eminences [43, 44]. There is no major advantage of short incision in the palm according to various studies; the major advantage is the size of the scar, which is shorter when compared to the classical incision. The time of return to work in comparing endoscopic, short incision and a classical incision do not show any significant differences between these techniques according to some studies [43, 44].

Endoscopic techniques to release the carpal tunnel, either single [44] or double-portal [45], reduce the morbidity and have a faster recovery period. Even though it offers theoretical advantages of reduced postoperative pain, quicker recovery of grip strength, fewer complications and faster return to everyday activities, endoscopic carpal tunnel release has not been widely adopted as the open techniques. It's worth pointing out that the risk of nerve injury increases with these types of techniques [46]. Actually, there is no sufficient consensus to support that the endoscopic technique overcomes open technique regarding clinical or electrophysiological recovery. The decision to perform endoscopic technique versus the classical or mini-open carpal tunnel release technique is most likely left to surgeons rather than patients, considering factors such as experience and resources.

4.12. From the pathophysiology to the therapeutic

The chronic lesion process will depend on the induction of I/R phenomenon on a repetitive pattern, in which the main pharmacological therapeutic target for regression or stopping the progression of the lesion would be OS modulation and inflammation.

The increase in OS production by the mitochondria in the I/R phenomenon is a key point to explore in the therapeutical approach to CTS, since the overproduction of ROS and RNS is involved in the activation of the inflammatory response and injury in the nervous cell [10, 16, 23]. The stimulation of the inflammation secondarily increases the production of OS; consequently, the therapy with antioxidants will be indicated in the acute and chronic phases of CTS.

The use of different antioxidants has been widely explored in the I/R phenomenon; however, there have only been made few investigations, which have had ambiguous results. From the point of view of evidence-based medicine, the use of antioxidants in the CTS treatment can produce a beneficial effect, accompanied by the decompression surgery, due to the impact in the pathophysiological process with the removal of the intermittent ischemic compression determined by the adjacent tissues in the walls and the reduction and modulation of the OS in the I/R phenomenon.

Nowadays, the most frequented phytodrugs that have shown positive results in CTS management and are focused on OS are as follows:

1. Alpha lipoic acid
2. Curcumin

4.12.1. Alpha lipoic acid

It is an essential substance for the function of different enzymatic components of the cells. It acts as a metal chelate, reducing free radicals, inflammation and modulating redox signaling. What stand out of this agent is the antioxidant, neuroprotective and neurotrophic properties, which exist in two isomeric forms such as R and S, where R plays a significant role in the pyruvate metabolism process and it is used in the mitochondria for the ATP generation. Its quality as metallic chelate is based on the interaction with divalent transitory metals (Mn , Cu^{+2} , Pb^{+2} and Zn^{+2}), and the ALA reduced form, which is dihydrolipoic acid (DHLA) (**Figure 4**), has the capacity to interact with Hg^{+2} and Fe^{+2} ; the inflammatory modulation is through the nuclear factor kappa-B (NF- κ B) path, it has been reported that degradation of I κ B inhibitor can be suppressed by multiples mechanisms, supporting the reduction in pro-inflammatory cytokines production. The therapeutic doses that have been used for different pathologies range between 100 and 1200 mg/day and at least 2 weeks of treatment are needed for positive results and have been safely used for up to 4 years in clinical trials [47] (**Figure 4**).

4.12.2. Curcumin

It is an herbal polyphenol component with potent anti-inflammatory and antioxidant properties, extracted from the *Curcuma longa*, which has multiple therapeutic effects in different pathologies (cancer, autoimmunity, inflammation, metabolism, etc.). It has great distribution and favorable therapeutic range; however, its absorption rate and plasma half-life are short. The new formulation has given this phytodrug the capacity to achieve higher plasmatic concentrations, absorption and distribution, but more clinical studies are needed to be performed to confirm the information [48] (**Figure 5**).

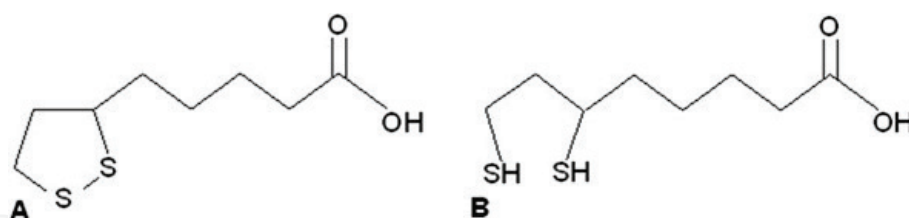


Figure 4. Structure of: (A) alpha lipoic acid structure and (B) dihydrolipoic acid.

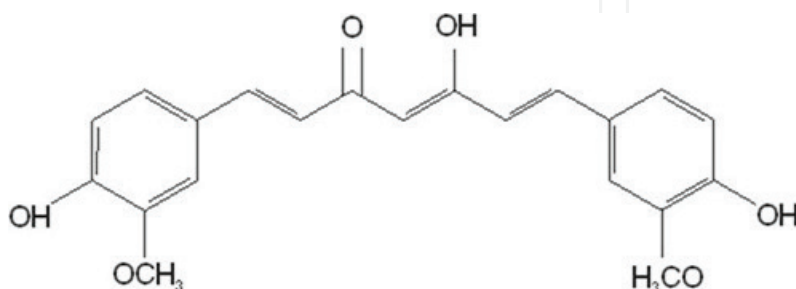


Figure 5. Curcumin structure.

4.12.2.1. Antioxidant mechanism of ALA and curcumin

The alpha lipoic acid and curcumin substances are OS scavengers through four mechanisms: (1) radical adduct formation (RAF), (2) hydrogen transfer (HT), (3) single electron transfer (SET) and (4) environments of different polarity. All these activities contribute to an exogenous reduction of ROS and RNS, modulating redox signaling, decreasing inflammation and mitochondrial lesion and modulating epithelial mesenchymal transition, which play a key role in the instauration of permanent lesion and progressive pain in the patient [49].

4.12.2.2. Clinical studies using antioxidants in CTS

Several investigators have reported favorable results with ALA as monotherapy or in combination with other antioxidants in CTS; the clinical trial conducted by Pajardi et al. [50] reported satisfactory clinical recovery from CTS with a combination of ALA, curcumin and vitamin B complex. Di Geronimo et al. [51] showed that clinical symptoms and neurophysiological outcomes were superior in a group that took a combination of ALA and gamma-linoleic acid compared with the group that took vitamin B complex. Notarnicola et al. [52] verified the efficiency of shock wave therapy versus nutraceutical therapy composed of ALA, linoleic acid, quercetin and Echinacea in CTS. Both groups showed clinical and electrodiagnostic improvement. Boriani et al. [53] recently published the effect of ALA in carpal tunnel syndrome, they used ALA as a monotherapy after surgery for 40 days, they showed good electrophysiological and clinical response; however, treatments with a longer period of time are necessary to observe the recovery of the nerve because during the first 30 days after surgery, the healing progress induces an immature and intense fibrosis; however, the recovery of the nerve does not occur.

Disclosure statement

The authors report no conflict of interests.

Author details

Leonel Garcia Benavides^{1,2*}, Sylvia Elena Totsuka Sutto¹, Leonel Garcia Valdes¹, Simon Q. Rodríguez Lara¹, Guillermo Ramos Gallardo¹, Ana Rosa Ambriz Plascencia² and Miriam Méndez del Villar¹

*Address all correspondence to: drleonelgb@hotmail.com

1 Universidad de Guadalajara, México

2 Hospital Civil de Guadalajara "Fray Antonio Alcalde", Guadalajara, Jalisco, México

References

- [1] American Academy of Orthopedic Surgeons. Clinical Practice Guidelines on Diagnosis of Carpal Tunnel Syndrome. 1st ed. Rosemont: American Academy of Orthopedic Surgeons; 2007. p. 5
- [2] Gelfman R, Melton LJ, Yawn BP, Wollan PC, Amadio PC, Stevens JC. Long-term trends in carpal tunnel syndrome. *Neurology*. 2009;**72**(1):33-41. DOI: 10.1212/01.wnl.0000338533.88960.b9
- [3] Musolin K, Ramsey JG, Wassell JT, Hard DL. Prevalence of carpal tunnel syndrome among employees at a poultry processing plant. *Applied Ergonomics*. 2014;**45**(6):1377-1383. DOI: 10.1016/j.apergo.2014.03.005
- [4] Ghasemi-rad M, Nosair E, Vegh A, Mohammadi A, Akkad A, Lesha E, Mohammadi MH, Sayed D, Davarian A, Maleki-Miyandoab T, Hasan A. Handy review of carpal tunnel syndrome: From anatomy to diagnosis and treatment. *World Journal of Radiology*. 2014;**6**(6):284-300. DOI: 10.4329/wjr.v6.i6.284
- [5] Beris AE, Lykissas MG, Kontogeorgakos VA, Vekris MD, Korompilias AV. Anatomic variations of the median nerve in carpal tunnel release. *Clinical Anatomy*. 2008;**21**:514-518
- [6] Lundborg G, editor. Nerve entrapment. In: *Nerve Injury and Repair*. New York: Churchill Livingstone; 1988. pp. 102-148
- [7] Yoshii Y, Zhao C, Zhao KD, Zobitz ME, An KN, Amadio PC. The effect of wrist position on the relative motion of tendon, nerve, and subsynovial connective tissue within the carpal tunnel in a human cadaver model. *Journal of Orthopaedic Research*. 2008;**26**(8):1153-1158. DOI: 10.1002/jor.20640
- [8] Ettema AM, Amadio PC, Zhao C, Wold LE, An KN. A histological and immunohistochemical study of the subsynovial connective tissue in idiopathic carpal tunnel syndrome. *Journal of Bone and Joint Surgery*. 2004;**86**(7):1458-1466
- [9] Werner RA, Andary M. Carpal tunnel syndrome: Pathophysiology and clinical neurophysiology. *Clinical Neurophysiology*. 2002;**113**(9):1373-1381
- [10] Gelberman R, Rydevik B, Pess G, Szabo R, Lundborg G. Carpal tunnel syndrome. A scientific basis for clinical care. *The Orthopedic Clinics of North America*. 1988;**19**(1): 115-124
- [11] Rodríguez-Lara SQ, Cardona-Muñoz EG, Ramírez-Lizardo EJ, Totsuka-Sutto SE, Castillo-Romero A, García-Cobián TA, et al. Alternative interventions to prevent oxidative damage following ischemia/reperfusion. *Oxidative Medicine and Cellular Longevity*. 2016;**2016**:7190943
- [12] Kalogeris T, Baines CP, Krenz M, Korthuis RJ. Cell biology of ischemia/reperfusion injury. *International Review Cell and Molecular Biology*. 2012;**298**:229-317

- [13] Armstrong TJ, Castelli WA, Evans FG, Diaz-Perez R. Some histological changes in carpal tunnel contents and their biomechanical implications. *Journal of Occupational and Environmental Medicine*. 1984;**26**(3):197-201
- [14] Carmo-Araujo EM, Dal-Pai-Silva M, Dal-Pai V, Cecchini R, Anjos Ferreira AL. Ischaemia and reperfusion effects on skeletal muscle tissue: Morphological and histochemical studies. *International Journal of Experimental Pathology*. 2007;**88**(3):147-154
- [15] Kalogeris T, Baines CP, Krenz M, Korthuis RJ. Cell biology of ischemia/reperfusion injury. *International Review of Cell and Molecular Biology*. 2012;**298**:229-317
- [16] Turrens JF. Mitochondrial formation of reactive oxygen species. *The Journal of Physiology*. 2003;**552**(2):335-344
- [17] Gateau-Roesch O, Argaud L, Ovize M. Mitochondrial permeability transition pore and postconditioning. *Cardiovascular Research*. 2006;**70**(2):264-273
- [18] Ghafourifar P, Cadenas E. Mitochondrial nitric oxide synthase. *Trends in Pharmacological Science*. 2005;**26**(4):190-195
- [19] Andreyev AY, Kushnareva YE, Starkov AA. Mitochondrial metabolism of reactive oxygen species. *Biochemistry (Mosc)*. 2005;**70**(2):200-214
- [20] Brookes P, Darley-Usmar VM. Hypothesis: The mitochondrial NO• signaling pathway, and the transduction of nitrosative to oxidative cell signals: An alternative function for cytochrome C oxidase. *Free Radical Biology and Medicine*. 2002;**32**(4):370-374
- [21] Xie Z, Klionsky DJ. Autophagosome formation: Core machinery and adaptations. *Nature Cell Biology*. 2007;**9**(10):1102-1109
- [22] Kalogeris T, Bao Y, Korthuis RJ. Mitochondrial reactive oxygen species: A double-edged sword in ischemia/reperfusion vs preconditioning. *Redox Biology*. 2014;**2**:702-714
- [23] Zhai Y, Busuttil RW, Kupiec-Weglinski JW. Liver ischemia and reperfusion injury: New insights into mechanisms of innate-adaptive immune-mediated tissue inflammation. *American Journal of Transplantation*. 2011;**11**(8):1563-1569
- [24] Iwasaki A, Medzhitov R. Regulation of adaptive immunity by the innate immune system. *Science*. 2010;**327**(5963):291-295
- [25] Ha T, Liu L, Kelley J, Kao R, Williams D, Li C. Toll-like receptors: New players in myocardial ischemia/reperfusion injury. *Antioxidant & Redox Signaling*. 2011;**15**(7):1875-1893
- [26] Chen GY, Nuñez G. Sterile inflammation: Sensing and reacting to damage. *Nature Reviews Immunology*. 2010;**10**(12):826
- [27] Li L, Okusa MD. Macrophages, dendritic cells, and kidney ischemia-reperfusion injury. *Seminars in Nephrology*. 2010;**30**(3):268-277
- [28] Abdellatif M. Differential expression of microRNAs in different disease states. *Circulation Research*. 2012;**110**(4):638-650

- [29] Godwin JG, Ge X, Stephan K, Jurisch A, Tullius SG, Iacomini J. Identification of a microRNA signature of renal ischemia reperfusion injury. *Proceedings of the National Academic Science of the United States of America*. 2010;**107**(32):14339-14344
- [30] Sunderland S. The nerve lesion in the carpal tunnel syndrome. *Journal of Neurology, Neurosurgery & Psychiatry*. 1976;**39**(7):615-626
- [31] Alfonso C, Jann S, Massa R, Torreggiani A. Diagnosis, treatment and follow-up of the carpal tunnel syndrome: A review. *Neurological Science*. 2010;**31**:243-252. DOI: 10.1007/s10072-009-0213-9
- [32] Le Blanc K, Cestia W. Carpal tunnel syndrome. *American Family Physician*. 2011;**83**(8):952-958
- [33] Oteo-Álvaro Á, Marín MT, Matas JA, et al. Spanish validation of the Boston carpal tunnel questionnaire. *Medicina Clinica*. 2016;**146**(6):247-253
- [34] Dumitru D, Amato AA, Zwartz MJ, editors. Nerve conduction studies. In: *Electrodiagnostic Medicine*. 2nd ed. Philadelphia: Hanley & Belfus; 2002. p. 201
- [35] Werner RA, Franzblau A, Gell N. Randomized controlled trial of nocturnal splinting for active workers with symptoms of carpal tunnel syndrome. *Archives of Physical Medicine and Rehabilitation*. 2005;**86**(1):1-7
- [36] Agarwal V, Singh R, Sachdev A, et al. A prospective study of the long-term efficacy of local methyl prednisolone acetate injection in the management of mild carpal tunnel syndrome. *Rheumatology*. 2005;**44**(5):647-650
- [37] Huisstede BM, Hoogvliet P, Randsdorp MS, et al. Carpal tunnel syndrome. Part I: Effectiveness of nonsurgical treatments—A systematic review. *Archives of Physical Medicine and Rehabilitation*. 2010;**91**(7):981-1004
- [38] Huisstede BM, Randsdorp MS, Coert JH, et al. Carpal tunnel syndrome. Part II: Effectiveness of surgical treatments—A systematic review. *Archives of Physical Medicine and Rehabilitation*. 2010;**91**(7):1005-1024
- [39] Sayegh ET, Strauch RJ. Open versus endoscopic carpal tunnel release: A meta-analysis of randomized controlled trials. *Clinical Orthopaedics and Related Research*. 2015;**473**(3):1120-1132. DOI: 10.1007/s11999-014-3835-z
- [40] Basiri K, Katirji B. Practical approach to electrodiagnosis of the carpal tunnel syndrome: A review. *Advances in Biomedical Research*. 2015;**4**:50
- [41] Tahririan MA, Moghtaderi A, Aran F. Changes in electrophysiological parameters after open carpal tunnel release. *Advances in Biomedical Research*. 2012;**1**:46
- [42] Larsen MB, Sørensen AI, Crone KL, Weis T, Boeckstyns MEH. Carpal tunnel release: A randomized comparison of three surgical methods. *The Journal of Hand Surgery*. 2013;**38E**(6):646-650. DOI: org/10.1177/1753193412475247

- [43] Richter VM, Bruser P. Surgical treatment of carpal tunnel syndrome: A comparison between long and short incision and endoscopic release. *Handchirurgie, Mikrochirurgie, Plastische Chirurgie*. 1996;**28**:160-166
- [44] Agee JM, McCarroll HR, Tortosa RD, Berry DA, Szabo RM, Peimer CA. Endoscopic release of the carpal tunnel: A randomized prospective multicenter study. *Journal of Hand Surgery American*. 1992;**17**:987-995
- [45] Aslani HR, Alizadeh K, Ejazi A, Karimi A, Karimi MH, Zaferani Z, Hosseini Khameneh SM. Comparison of carpal tunnel release with three different techniques. *Clinical Neurology and Neurosurgery*. 2012;**114**:965-968
- [46] Atroshi I, Hofer M, Larsson GU, Ornstein E, Johnsson R, Ranstam J. Open compared with 2-portal endoscopic carpal tunnel release: A 5-year follow-up of a randomized controlled trial. *Journal of Hand Surgery American*. 2009;**34**:266-272
- [47] Gomes MB, Negrato CA. Alpha-lipoic acid as a pleiotropic compound with potential therapeutic use in diabetes and other chronic diseases. *Diabetology & Metabolic Syndrome*. 2014;**6**(1):80
- [48] Mirzaei H, Shakeri A, Rashidi B, Jalili A, Banikazemi Z, Sahebkar A. Phytosomal curcumin: A review of pharmacokinetic, experimental and clinical studies. *Biomedicine & Pharmacotherapy*. 2017;**85**:102-112
- [49] Nimse SB, Pal D. Free radicals, natural antioxidants, and their reaction mechanisms. *RSC Advances*. 2015;**5**(35):27986-28006
- [50] Pajardi G, Bortot P, Ponti V. Clinical usefulness of oral supplementation with alpha-lipoic acid, curcumin phytosome, and B-group vitamins in patients with carpal tunnel syndrome undergoing surgical treatment. *Evidence-Based Complementary Alternative Medicine*. 2014;**2014**(891310):1-7
- [51] Di Geronimo G, Caccese AF, Caruso L, et al. Treatment of carpal tunnel syndrome with alpha-lipoic acid. *European Review for Medical and Pharmacological Sciences*. 2009;**13**(2):133-139
- [52] Notarnicola A, Maccagnano G, Tafuri S, Fiore A, Pesce V, Moretti B. Comparison of shock wave therapy and nutraceutical composed of *Echinacea angustifolia*, alpha lipoic acid, conjugated linoleic acid and quercetin (perinerv) in patients with carpal tunnel syndrome. *International Journal of Immunopathology and Pharmacology*. 2015;**28**(2): 256-262. DOI: 10.1177/0394632015584501
- [53] Boriani F, Granchi D, Roatti G, Merlini L, Sabattini T, Baldini N. Alpha-lipoic acid after median nerve decompression at the carpal tunnel: A randomized controlled trial. *Journal of Hand Surgery American*. 2017;**42**(4):236-242. DOI: 10.1016/j.jhsa.2017.01.011

