

# We are IntechOpen, the world's leading publisher of Open Access books Built by scientists, for scientists

6,900

Open access books available

185,000

International authors and editors

200M

Downloads

Our authors are among the

154

Countries delivered to

TOP 1%

most cited scientists

12.2%

Contributors from top 500 universities



WEB OF SCIENCE™

Selection of our books indexed in the Book Citation Index  
in Web of Science™ Core Collection (BKCI)

Interested in publishing with us?  
Contact [book.department@intechopen.com](mailto:book.department@intechopen.com)

Numbers displayed above are based on latest data collected.  
For more information visit [www.intechopen.com](http://www.intechopen.com)



---

# Dupuytren's Disease

---

Jeremiah D. Johnson, Colin Pavano and  
Craig Rodner

Additional information is available at the end of the chapter

<http://dx.doi.org/10.5772/intechopen.72759>

---

## Abstract

Dupuytren's disease is a fibroproliferative disease affecting the palmar fascia of the hand and leading to flexion contractures of the digits. It was first described in Northern European populations and derived its namesake from Dr. Baron Dupuytren, a French surgeon, who was one of the first to lecture on the disease. The etiology of Dupuytren's disease is unclear but is likely influenced by both genetic and environmental factors. Older individuals and men are most at risk of developing the disease. Dupuytren's disease is a clinical diagnosis and patients often present with gradually worsening flexion contractures. Mild disease is usually observed, but surgical treatment is preferred for debilitating contractures. A variety of surgical techniques have been described involving either incising or excising diseased fascia. Overall, surgery is effective in correcting contractures and improving function, but despite successful treatment some patients still experience recurrence. More recently, collagenase injections and percutaneous procedures have been utilized to treat Dupuytren's disease and have yielded promising results in select patients.

**Keywords:** Dupuytren's disease, collagenase, flexion contractures, palmar fascia, limited fasciectomy, percutaneous needle fasciotomy, fibroproliferative disease

---

## 1. Introduction

Dupuytren's disease is one of the most common pathologies diagnosed in the field of hand surgery. It is a fibroproliferative disease of the palmar fascia characterized by flexion contractures of the digits and involves an abnormal production of type III collagen. The disease has a unique history with origins dating back to the Vikings and has been studied extensively since. However, despite ongoing research the etiology of the disease remains unclear but likely results from a complex interaction between genetics and environmental risk factors. Patients classically present with palpable palmar nodules and cords leading to gradual, progressive loss of function. The disease can potentially lead to debilitating flexion contractures of the digits

and affect activities of daily living. The disease is a clinical diagnosis and only requires further testing to exclude other pathologies. There is no cure for Dupuytren's disease and treatment methods remain palliative. Patients with mild disease can be observed for disease progression while patients with more severe disease may be treated with a variety of procedures or surgeries. Recently, clinical procedures including collagenase injections and percutaneous needle fasciotomy (PNF) have been utilized to successfully treat select patients. Still, surgery remains the preferred method of treating Dupuytren's contractures for most surgeons. A variety of surgical techniques have been described utilizing different types of incisions to either incise or excise disease fascia and correct contractures. Surgery has yielded successful outcomes in regaining extension of the involved digits and improving function of the hand, however, it is not without risks. Complications related to infection, wound healing, and neurovascular injuries have been reported. In addition, despite successful treatment following surgery some patients experience recurrence of their contracture. Further research has focused on methods of successfully treating Dupuytren's disease while reducing complications and recurrence. This chapter will provide a thorough description of Dupuytren disease from its history and pathophysiology to clinical management as well as highlight research related to patient outcomes.

## 2. History

Dupuytren's disease is a condition of the hand with a unique history. Its origin is linked to the Viking population and likely spread throughout Northern Europe as the Vikings conquered and acquired lands in the ninth through thirteenth century. For this reason, it has since been given the colloquial name, "Viking disease." The Viking's 300-year conquest lead to many settlements in which their descendants lived and bred with native populations, leading to the spread of Dupuytren's disease to many northern European nationalities [1, 2]. Naturally, as time progressed and more conquests occurred, the disease spread to the shores of North America, and is now found throughout the world.

Early evidence of diseases mimicking Dupuytren's has been noted in historical texts. The "Curse of the MacCrimmons" is a tale of seventeenth century Scotland in which Clan MacCrimmons was cursed with a "bent finger," leaving them unable to play their bagpipes [2, 3]. The Catholic Church sign of benediction has even been postulated to depict an early church priest with Dupuytren's disease [2, 4]. Whaley and Elliot describe early Icelandic stories of the twelfth and thirteenth century possibly describing accounts of Dupuytren's disease dating back to the ninth century and include the treatment of one case by a procedure resembling a palmar fasciotomy [5].

In 1831, the French surgeon and namesake to the disease Baron Guillaume Dupuytren gave a lecture on the "permanent retractions of the flexed fingers" [6]. Other surgeons have also been credited with describing conditions believed to be caused by Dupuytren's disease, including: Felix Platter in 1680, Henry Cline, Jr. in 1808, and Sir Astley Cooper in 1818 [2]. Elliot discusses a "Cline's contracture" as an earlier description of Dupuytren's disease [7]. MacFarlane reports Platter may have been the first to publish a description of Dupuytren's disease as early

as 1614 [2]. Despite possible earlier accounts, Dupuytren maintains the namesake of the disease to this day. Dupuytren finished his career as chief surgeon at the Hôtel de Dieu in Paris, and his name appears in at least 12 other diseases and instruments, cementing his legacy in the medical field [1].

Dupuytren's disease is often considered a "disease of the north," in to its northern European origins. Various studies into the prevalence of Dupuytren's disease demonstrate its northern roots, showing Norway, Scotland, and Iceland with some of the highest prevalence when compared to more southern nations [8–10]. Today, Dupuytren's disease can be seen in all types of patients; however, there are specific subsets of the population at increased risk of developing the disease.

### 3. Epidemiology and risk factors

#### 3.1. Prevalence

Dupuytren's disease is most prominent in Northern European white males, especially greater than 40 years old. A study in the Netherlands reports a prevalence as high as 22% in the general population [11]. The study also demonstrated a propensity for older populations with ages 50–55 displaying a 4.9% prevalence, while those 76–80 years old having a prevalence of 52.6%. Men were also affected disproportionately more than women (26.4 vs. 18.6%). The prevalence in the US has been shown to approach 7.3% when including self-reported symptoms [12]. Other epidemiological studies show a male to female ratio in the US of 1.7:1 which approaches 1:1 with increasing age [13]. Dupuytren's disease has been linked to both genetic and environmental factors, both of which contribute to the prevalence in patient populations throughout the world.

#### 3.2. Genetics

The genetic component of Dupuytren's disease has been a topic of interest for many years. A study by Burge et al. found that the prevalence of Dupuytren's in Norwegian individuals over 60 years old reaches 30%, indicating a familial component in like populations [14]. They also suggested an autosomal dominant inheritance pattern with variable penetrance based on pedigree analysis. Multiple heritable patterns have been hypothesized, but there is no clear consensus on a mode of transmission. It is possible the disease does not carry a simple inheritance pattern, but rather follows a more complex method similar to heart disease and diabetes. Ling et al. performed a study examining the family members of patients with Dupuytren's disease, and found that 53% of men and 33% of women over the age of 60 in the family had signs of the disease [15]. In a clinical study, patients with a family history of Dupuytren's disease had a 6-year earlier onset of disease compared to patients without a family history [16]. There was also increased disease severity in terms of the number of affected digits and degree of contracture in patients with a family history. Both of these findings suggest patients with a family history of Dupuytren's disease develop a more severe and earlier onset of disease. Research has also investigated specific genes linked to the development of Dupuytren's, including the gene for TGF- $\beta$ 1. However, studies implicating TGF- $\beta$ 1 with

Dupuytren's disease have been inconclusive [17]. The genetic predisposition of Dupuytren's disease is complex and further research is needed to elicit a clear relationship between genetics and disease manifestation.

### 3.3. Environmental factors

Despite Dupuytren's genetic tendencies, multiple patients with no familial history of the disease are affected every year. Certain environmental factors have been associated with the development of Dupuytren's disease including smoking, alcohol use, diabetes, manual labor, and previous trauma. Hindocha et al. identified additional risk factors in developing Dupuytren's and included frozen shoulder, epilepsy, and a high lipid profile [16]. There are many environmental risk factors associated with Dupuytren's disease; however, smoking, alcohol, diabetes mellitus, and previous trauma are the most well-established factors cited in current literature.

#### 3.3.1. Smoking

There is a high prevalence of patients with Dupuytren's disease who smoke cigarettes. A study found 76.5% of Dupuytren's patients were smokers, while only 37.2% of the control group were smokers [18]. Another study examined 222 patients undergoing surgery to treat a Dupuytren's contracture and found smoking was strongly associated with Dupuytren's requiring surgical intervention (OR 2.8, 95% CI 1.5–5.2) [19]. The pathogenesis of Dupuytren's disease from smoking is likely related to its impact on circulation. Cigarette smoking affects the small blood vessels causing microangiopathies, resulting in reduced blood flow to the distal extremities including the hands. The microvascular impairment from smoking is believed to contribute to the development of the Dupuytren's disease. Smoking induced hypoxia of distal extremities leads to PDGF release, triggering endothelial and fibroblast activation resulting in increased collagen synthesis [8]. These vascular changes associated with smoking and collagen synthesis may contribute to the pathogenesis of Dupuytren's. Overall, smoking is a modifiable risk factor that likely increases one's risk of developing Dupuytren's disease.

#### 3.3.2. Alcohol

Though the role of alcohol is not clearly identified, it has been shown to be a risk factor for the development of Dupuytren's disease. One study suggested alcoholic consumption leads to impaired liver function, and in turn altered palmar fat composition which could as a trigger for developing Dupuytren's [20]. Heavy drinking was found to be more common in a study of Dupuytren's patients awaiting surgery, and another study reported alcohol was the second most important risk factor after age in developing the disease [20, 21]. Additional studies suggest that alcoholics have a higher prevalence of Dupuytren's disease compared to non-alcoholics (28 vs. 22%, respectively) [22]. Though associations have been documented, further research is needed in identifying the role of alcohol as a modifiable risk factor for developing Dupuytren's disease.

#### 3.3.3. Diabetes mellitus

Multiple studies have identified a relationship between Dupuytren's disease and diabetes, but there is no clear evidence its pathophysiology. Noble et al. reported a 42% incidence of

Dupuytren's disease in adult diabetics and suggested Dupuytren's severity is usually more mild and affecting the middle finger in diabetics [23]. In addition, 13% of 134 patients with Dupuytren's disease were found to have elevated glucose levels, suggesting elevated blood glucose levels may influence development of Dupuytren's disease. In another study, the proportion of German diabetics with Dupuytren's disease was only slightly higher than that of the normal population (11% compared to about 7%) [24]. Another study however, showed the prevalence of the disease in diabetic patients was as high as 32% [25]. Though the prevalence of DD in diabetics has been studied in various subpopulations, a consensus on the relationship between Dupuytren's disease and diabetes mellitus has not been reached. Further research is needed to demonstrate a true mechanism of pathogenesis between Dupuytren's disease and diabetes.

#### 3.3.4. *Trauma*

Dupuytren himself first proposed previous trauma as a risk factor for developing the disease [26]. The progression of Dupuytren's disease resembles normal physiologic healing and based on a patient's risk factors, trauma may initiate a cascade of events leading to an aberrant healing response. It is unclear whether the development of disease is related to a single injury or rather multiple insults over time, but studies have reported the development of Dupuytren's near the site of previous penetrating injuries [27]. Other studies have linked previous hand surgery such as carpal tunnel and trigger finger release to the development of Dupuytren's disease [22, 25, 28, 29].

#### 3.3.5. *Other risk factors*

The association between Dupuytren's disease and epilepsy or anticonvulsants and has been reported. Lund et al. recorded a 50% prevalence of Dupuytren's in male patients with epilepsy and 25% in females [30]. Another study identified an overall prevalence of Dupuytren's disease in 37% of epileptics [31]. Critchley et al. reported a 56% incidence of Dupuytren's disease in chronic epileptic patients and an associated increased in disease with duration of epilepsy and possibly related to the administration of the anticonvulsant phenobarbital [32]. The effect of phenobarbital on DD was analyzed in a 2011 study, in which a dose-dependent fibrotic effect was seen with phenobarbital use. Though these studies demonstrate a relationship between epilepsy and phenobarbital use in DD, other studies have found no direct correlation to antiepileptic drugs [33, 34].

Manual labor consisting of continued and repetitive hand use has also been proposed as a risk factor for developing Dupuytren's disease. Lucas et al. reported the effect of personal and occupation exposures on the development of the disease and reported men who developed the disease had the highest exposure to biomechanical, vibration, and manual work [35]. After adjusting for personal risk factors, manual labor and the handling of vibratory tools had the strongest association with Dupuytren's disease. Another study examining the effect of weekly hand transmitted vibration on the development of Dupuytren's disease concluded the risk of developing Dupuytren's contracture is more than double in men with increasing amounts of hand-transmitted vibration [34]. In addition, handwork for at least 30 years has also been reported as a possible risk factor in the development of Dupuytren's disease [35].

## 4. Anatomy and pathophysiology

### 4.1. Anatomy

A thorough understanding of anatomy is crucial to understanding Dupuytren's disease and its progression. Dupuytren's disease is a fibroproliferative disorder affecting the palmar aponeurosis, one of the three zones within the palmar fascial complex. The subcutaneous palmar aponeurosis is a continuation of the palmaris longus tendon, extending superficially to the palmaris brevis muscle and into the palmar surface. The palmar aponeurosis can be divided into three layers according to orientation: longitudinal, vertical, and transverse. The longitudinal fibers extend to the phalanges where they bifurcate and terminate as three separate insertions. The superficial layer inserts into the dermis and the deep layer inserts into the flexor and extensor mechanisms. The middle layer of the longitudinal fibers travel vertically next to the metacarpophalangeal (MCP) joint capsule forming spiral bands. Vertical fibers of the palmar aponeurosis include the superficial Grapow fibers, which anchor the skin to the aponeurosis, and the septa of Legueu and Juvara, which create fibro-osseous compartments to allow passage of flexor tendons, neurovascular bundles, and lumbrical muscles. Transverse fibers of the palmar aponeurosis include the transverse ligament and the natatory ligament.

Dupuytren's disease is characterized by the transformation of normal, palmar fascial bands into fibrotic, contracted tissue called cords. Different manifestations and stages of the disease are dependent on the anatomical bands that are affected. Early disease often affects the superficial Grapow fibers, forming thickened skin in the affected area. Pretendinous cords are the most common and result in skin dimpling and MCP contracture. The spiral cord consists of the middle pretendinous band, spiral band, lateral digital sheet, and Grayson ligament result in MCP and proximal interphalangeal (PIP) contracture and can also be accompanied with a medially displaced neurovascular bundle [36]. Other cords that can form include the central and lateral cords which can lead to a combination of PIP or distal inter-phalangeal (DIP) contractures while natatory cords can lead to web space contractures.

### 4.2. Pathophysiology

The pathophysiology of Dupuytren's is similar to the normal connective tissue healing process. However, there are aspects of the Dupuytren's process that differ and contribute to its pathogenesis. In Dupuytren's there is an increased number of myofibroblasts producing type 3 collagen, a change in biochemical composition of the fascia, as well as an abundance of cytokines and prostaglandins contribute to the pathogenesis. An immune mediated component of the disease has also been proposed and researched. Luck et al. describes three distinct microscopic phases of Dupuytren's disease [37]. The first stage is called the proliferative phase, and is characterized by increased fibroblast presence and proliferation in fascial bands, forming a nodule. On a cellular level, these nodules represent the accumulation of myofibroblasts, collagen, and extracellular matrix components within the palmar fascia, resulting in fibrotic, adherent lesions that decrease mobility of the joint. In this stage, there can be as high as a fortyfold increase in the amount of proliferating fibroblasts [38]. The active or "involutional" phase is dominated by myofibroblasts, which contain myofibrillar bundles in the cytoplasm,

allowing them to contract and draw tissue together. These muscle-like fibers align in the direction of stress [38, 39]. The residual phase is characterized by the disappearance of a nodule, and appearance of cords. The acellular cord causes shortening of the metacarpophalangeal (MCP) and proximal interphalangeal (PIP) joint and producing the classic contracted appearance of Dupuytren's disease. In the late phase, there is commonly impaired range of motion of the effected digit, and nerve damage and vascular insufficiency can occasionally be seen.

#### 4.2.1. *Myofibroblasts*

Myofibroblasts are contractile cells that are  $\alpha$ -smooth muscle actin positive and contribute to the contracture present in Dupuytren's disease. During the early phase of disease, myofibroblasts become densely packed in the palmar aponeurosis and produce an increased type 3/type 1 collagen ratio. The accumulation of fibroblasts and type III collagen creates the characteristic early nodule. This abundant type 3 collagen production is similar to connective tissue scar formation, and may or may not contribute to the pathophysiology of Dupuytren's disease [40]. The source of myofibroblasts in Dupuytren's disease remains unclear. Some argue that the fibroblast-myofibroblasts transformation is induced by local ischemia and hypoxia.

#### 4.2.2. *Biochemical changes*

Biochemical changes to the palmar fascia may contribute to the development of Dupuytren's disease. These changes include increased glycosaminoglycan content, increased hydroxylysine content, and increased reducible crosslinks found in affected palmar aponeuroses [40]. Myofibroblasts found in the palmar fascia produce fibronectin, a glycoprotein thought to encourage cell-cell and cell-extracellular matrix adherence [41, 42]. This contributes to the thickening of the palmar fascia seen in the disease. Dermatan sulfate has been found to be two fold greater in tissue affecting by Dupuytren's and is known to affect collagen organization, deposition rate, and maintenance of fibers [43]. The same study also demonstrated an increased heparin sulfate composition in patients with Dupuytren's, which has been shown to play a role in cell recognition, adhesion, growth control, and angiogenesis. Research has also shown a change in the architecture of the palmar fascia in Dupuytren's patients. Compared to normal fascia, fascia in Dupuytren's patients has more hydroxyl-lysino-hydroxy-norleucine crosslinking which was absent in normal tissue [44, 45]. It is unclear how this increased crosslinking component contributes to the severity of disease.

#### 4.2.3. *Cytokines and prostaglandins*

Many studies have pointed to the role of growth factors and cytokines in the pathogenesis of Dupuytren's disease. An increased production of IL-1 $\alpha$  and IL-1 $\beta$  is seen in Dupuytren's palmar fascia. These cytokines are involved in proinflammatory processes including local fibroblast proliferation, which can potentially contribute to the active stage of Dupuytren's disease [46]. There is also an increase in bFGF which contributes to fibroblast growth and proliferation, and increased TGF- $\beta$ , which contributes to collagen synthesis and fibroblast chemotaxis [46]. The study concluded that increased release of cytokines and growth factors relative to normal reparative tissue may suggest a locally driven fibroblast proliferation contributing to the

development of Dupuytren's disease. Research has also demonstrated prostaglandins PGE<sub>2</sub> and PGF<sub>2</sub> $\alpha$  play a role in contractility of smooth muscle associated with myofibroblasts [44, 47]. This contractile influence on myofibroblasts is thought to contribute to the contraction of tissue late in the disease. The source of these prostaglandins are possibly from microcirculation and perinodular fat, as nodules are highly vascularized and fatty.

#### 4.2.4. Immune mediated

Studies have suggested an immune mediated response in the pathophysiology of Dupuytren's disease. Mayerl et al. describe abundant accumulation of immune cells in Dupuytren's tissue, including mononuclear CD3+, CD4+ > CD8+, and primarily a Th1 mediated response [39]. These clusters of immune cells were found around blood vessels in the area, suggesting the fibroproliferation exists in Dupuytren's may be due to microvascular damage mediated by the immune system. Further research is required to determine the relationship of Dupuytren's to an immune mediated response.

## 5. Clinical presentation and physical exam

A thorough history and physical exam is necessary to accurately diagnose Dupuytren's disease, which has a classic presentation. It is important to assess risk factors including family history, northern European descent, smoking, alcohol use, history of diabetes mellitus, or previous trauma to the hand in order to gain a broader picture of the patients' presentation. In many cases, disease is bilateral with one hand affected more than the other so it is important to evaluate both hands. The ring finger is the most commonly affected digit followed by the small, middle, index, and thumb [48]. Other fibroproliferative diseases have been associated with Dupuytren's disease and include Garrod's nodes, Ledderhose disease, and Peyronie's disease. Garrod's nodes, also called knuckle pads, can be visualized on the dorsal PIP joints and are subcutaneous nodules that histologically portray myofibroblasts proliferation. Ledderhose is a fibrosis of the plantar fascia and Peyronie's disease is an inflammation and scarring of the tunica albuginea of the penis. Rayan et al. described three phases to Dupuytren's disease clinical presentation: the early, intermediate, and late phases [49]. These three phases provide a good framework to assess the patient's disease status, and each phase is characterized by distinct aspects of the disease.

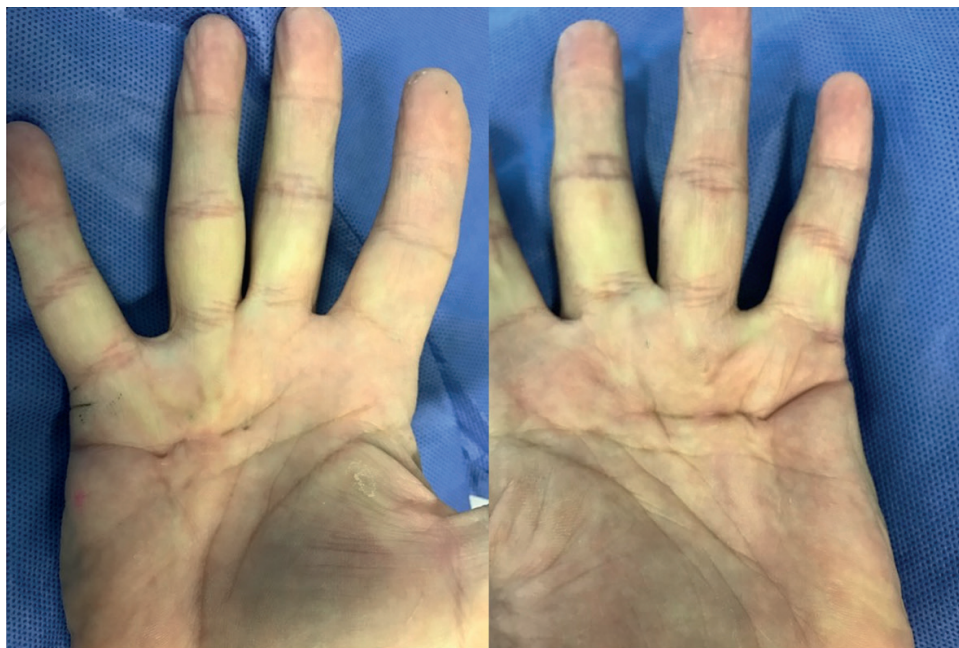
### 5.1. Early phase

Early disease is characterized by skin dimpling, puckering, and pitting, usually on the medial aspect of the palm. These changes can lead to the patient seeking medical attention, however are also easily ignored by some patients. A Dupuytren's patient population study suggests that approximately 11% of Dupuytren's disease patients seek attention from their physician with a chief complaint of skin changes on the palm [12]. Physical exam during the early phase of disease can confirm these skin changes upon inspection. Pitting of skin on the medial palm of the hand is a good indication of developing Dupuytren's disease. Palpation reveals thickening and

dimpling of the skin around the effected joint. The underlying fat on the medial palm becomes fibrotic near the distal palmar crease. Active range of motion (ROM) and strength testing in early disease will reveal no limitations, though more severe skin adhesions can lead to a slight decrease in mobility and function of the affected digits in some patients.

## 5.2. Intermediate phase

The appearance of Dupuytren's nodules and cords signifies the intermediate phase of disease. Nodule formation is often one of the first patient complaints and occurs during intermediate stages of the disease. Approximately 42% of patients with Dupuytren's disease present to the office due to a nodule [12]. Nodules most commonly form proximal to the palmar crease overlying the metacarpophalangeal joint of the affected digit, and encompass the superficial layers of the palmar and digital fascia. Sometimes digital nodules are seen at the base of the proximal interphalangeal joint. Though often painless, larger nodules can cause pain when they exert pressure on underlying flexor tendons. Painful, chronic nodules are more indicative of intrinsic joint disease and rheumatoid arthritis, and must be differentiated from a Dupuytren's disease nodule. After the appearance of a nodule, a pathologic cord may form within the palmar fascia. Approximately 12% of patients seek will seek care following development of a cord [12]. Nodules often regresses, but in some cases can be present simultaneously with Dupuytren's cords. Initial cords are often unnoticeable and blend in with the underlying connective tissue, but over time, they become thick and resemble subcutaneous tendon-like structures upon inspection (**Figure 1**). Palpation reveals an immobile, thickened cord. Cord formation is extremely variable in terms of location. The most common cords arise in the palm, and include peritendinous, natatory, and vertical cords arising from their respective bands in the palmar

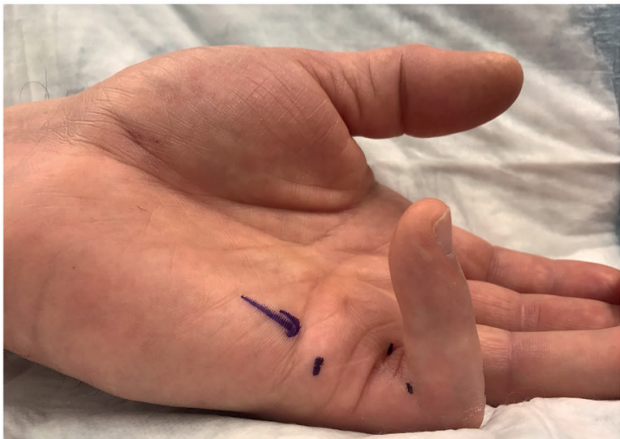


**Figure 1.** A patient with Dupuytren's cords leading to contractures and affecting the bilateral small and ring fingers.

fascia. Digital cords frequently seen include central and spiral cords. Active and passive ROM testing during the intermediate disease will often reveal no limitations in patients with nodules, but as cords form patients will begin to lose extension of the involved joint.

5.3. Late phase

Late disease is defined by contraction of cords and the classic “bent finger” appearance of Dupuytren’s disease (**Figure 2**). Approximately 10% of Dupuytren’s disease patients will present during the late stage of the disease complaining of a permanent bent finger [12]. Contracture of the MCP joint often occurs before the PCP joint. Contractures often lead to difficulties in activities of daily living and patients will report difficulties with chores, washing, putting a hand in a pocket, and handshakes. Inspection and palpation will reveal a contracted, fibrotic cord. Both active and passive finger extension of the effected finger will likely be impaired, the extent of which is determined by severity of disease. Pain with ROM is rarely reported and if present should prompt further evaluation. The table top test was described in 1982 by Hueston and is specific to a Dupuytren’s diagnosis and has been used to stage disease progression [50]. The test involves placing the patient’s hand on a tabletop with the palmar side down. The test is positive if the patient cannot flatten the hand against the table and is indicative of the late phase of the disease.



**Figure 2.** A patient with Dupuytren’s PIP joint contracture with a flexion contracture of approximately 100°.

Tubiana stage	Degrees of extension deficit
0	0, No disease
N	0, Nodules present
I	1–45
II	46–90
III	91–135
IV	>136

**Table 1.** Tubiana staging system based on a digit’s total extension deficit [51, 52].

The degree of extension deficit is taken into account when staging Dupuytren's disease. The adapted Tubiana staging system is the most common method of classifying the progression of Dupuytren's disease (**Table 1**) [51, 52].

## 6. Diagnosis

Dupuytren's disease is a clinical diagnosis based on a patient's history and physical exam. Its hallmark features consist of an indolent, progressive course characterized by palmar skin changes, painless nodules, and fibrotic cords leading to flexion contractures of the digits. Patients presenting with later findings of the disease consisting of fibrotic cords and contracted digits are more clearly diagnosed. Conversely, patients presenting with earlier features of Dupuytren's disease such as painless nodules may not be as easily distinguished from other diseases. Stenosing tenosynovitis, also known as a trigger finger, and soft tissue tumors may be mistaken for Dupuytren's disease. Stenosing tenosynovitis can be differentiated from Dupuytren's by tenderness over the A1 pulley with symptomatic locking or triggering of the digit and often no ROM deficit. Soft tissue masses typically do not present with skin thickening and pitting as seen in Dupuytren's disease. In addition, Dupuytren's nodules are often fixed to the skin and palmar fascia. Early Dupuytren's disease may be difficult to distinguish from diabetic cheiroarthropathy, however, involvement of multiple digits and a waxy appearance of the skin are clues to distinguish diabetic cheiroarthropathy. Other pathologies that may present with some features similar to Dupuytren's disease include: ulnar claw, rheumatoid arthritis, Volkmann's contracture, and camptodactyly. Radiographs should be considered in patients presenting with a history of trauma to rule out a fracture or dislocation. Further diagnostic imaging such as MRI may be considered in special cases to rule out suspicion of other disease processes, but is not required to diagnose Dupuytren's disease. A thorough history and physical exam is key to accurately diagnosing Dupuytren's disease.

## 7. Nonoperative treatment

Despite the recent advances in understanding the pathophysiology of Dupuytren's disease the treatment options remain palliative and not curative. Non-operative treatment is recommended in patients with isolated disease without contractures and in patients with mild contractures without significant interference with activities of daily living. Observation is a reasonable non-operative option for many patients with early disease and minimal symptoms. Studies have estimated about 50.8% of patients with palpable nodules will progress to developing cords after 8 years from diagnosis, and of these only 17% will develop contractures meeting criteria for surgical intervention [53].

Surgery is the mainstay treatment for Dupuytren's contractures. However, non-operative interventions continue to be pursued as an alternative option to surgical intervention. Splinting and physical therapy have mostly been utilized as a post-operative intervention to prevent recurrence. Critics of splinting and physical therapy often express concern it may worsen the contracture if the contractile tissue is not first removed. In vitro studies have reported

mechanical loads increase TGF-beta expression and thus enhance fibroblast contraction [54]. Few clinical studies have investigated orthosis or therapy as a non-operative intervention. Larocerie-Salgado et al. reported patients with mild PIP joint contractures had an average improvement of 14.6° (SD 5.1°) after wearing a volar hand-based extension splint at night and utilizing hand exercises and massage [55]. Another study comparing tension and compression orthosis worn for 20 hours per day reported significant improvement in the total active extension (TAE) of a digit in both groups compared to baseline TAE [56]. Overall there is minimal evidence regarding therapy and orthosis usage. There may be some benefit in preventing progression of a contracture in an isolated digit, but the possible benefit may be minimal and outweighed by interference of the splint and necessity for prolonged periods of daily use.

Intralesional triamcinolone injections have also been proposed to deter the progression of Dupuytren's disease. Steroid treatment in Dupuytren's is linked to its effectiveness in reducing hypertrophic scars and keloids by degrading insoluble collagen. Ketchum and Donahue reported resolution of Dupuytren nodules in patients with mild disease (<15° joint contracture) after an average of three 60-120 mg triamcinolone injections spaced out over 6 weeks [57]. However, 50% experienced recurrence of disease and either underwent further injections or surgery. Other studies have utilized triamcinolone in patients with nodules but without flexion contractures and have demonstrated better outcomes with only a 6% recurrence at 5 years [58]. The high recurrence rates and complications including skin atrophy, transient erythema, depigmentation and tendon rupture have minimized the use of steroid injections in Dupuytren's disease [57, 58].

Non-operative treatment has recently expanded to include office-based procedures to provide patients with Dupuytren's contractures an alternative to surgery or treat patients unable to tolerate surgery. Percutaneous needle fasciotomy and collagenase injections are two clinic procedures that have recently gained popularity. Zhao et al. reported these two minimally invasive techniques comprised 14% of all procedures for Dupuytren's in 2007, but have more recently risen to 39% of all procedures [59].

### **7.1. Percutaneous needle fasciotomy**

Percutaneous needle fasciotomy (PNF) utilizes a 25-gauge needle as a scalpel to incise the contracted cord at different levels while the digit is manually straightened. Prior to the procedure the dermis is injected with a local anesthetic to reduce pain and is followed by range of motion (ROM) exercises aimed at preventing recurrence of the cord. As described by Eaton, needle fasciotomy has four requirements including a contracture caused by a palpable cord, redundant skin, and a cooperative patient [60]. The benefits of the procedure include a low complication rate, early return of motion, and avoidance of surgery. Zhou et al. reported a complication rate of 5.2% after fasciotomy compared with 24.3% in a group undergoing limited fasciectomy [61]. However, PNF had a higher rate of recurrence at long-term follow-up. Van Rijssen et al. have reported recurrence rates following PNF as high as 63% at 3 years and 84.9% at 5-year follow-up [62]. Patients older than 75 years old with mild disease had the lowest rate of recurrence at 5 years. In general, PNF is a reasonable option for older patients who have developed a mild contracture due to a palpable cord and are well-informed of the recurrence risk but prefer a minimally invasive option.

## 7.2. Collagenase injections

Collagenase injections were first approved for Dupuytren's contractures in 2010 by the United States Food and Drug Administration and are currently approved for the treatment of two Dupuytren's contracted joints in the same hand. Collagenase injections deliver an enzyme isolated from *Clostridium histolyticum* which is responsible for lysing the collagen in a contracted cord. After injection, the patient returns within 1–3 days for manipulation to straighten the digit. Hurst et al. reported good results following up to 3 injections with 64% of patients experiencing 0–5° of full flexion with no recurrence 90 days after treatment [63]. Common adverse events of collagenase included swelling, pain, bruising, tenderness, and pruritis. Complications related to tendon ruptures, skin atrophy, and complex regional pain syndrome (CRPS) are rare and have been reported in less 1% of patients [63, 64]. Recurrence rates following collagenase have been closely studied as well. Van beek et al. reported 2-year recurrence rates (>20-degree worsening) following one or more injections were 28.2 and 62.1% for MCP and PIP joints, respectively [65]. Peimer et al. reported 47% of successfully treated patients experience recurrence (>20° worsening) within 5-years following collagenase injections with PIP joints having a higher degree of recurrence at 66 versus 39% among MCP joints [64]. Collagenase injections provide a good treatment option for patients with a palpable cord causing a contracture.

## 8. Operative treatment

Operative treatment of Dupuytren's disease is offered in patient with contractures of >30° at the MCP joint and any functionally bothersome PIP contracture. The goal of surgical treatment is to return full extension of the involved digits via various surgical techniques involving either incising or excising the diseased fascia. Dupuytren originally described an open palmar fasciotomy technique in 1831 and this was later popularized in 1964 by McCash et al. as the open-palm technique [6, 66]. The open-palm technique involved a transverse incision across the distal palmar crease followed by incising any Dupuytren cords. Multiple surgical methods have since been described and include open fasciotomy, segmental fasciectomy, limited fasciectomy, and dermofasciectomy. These techniques range from being minimally invasive to radical excision of the diseased tissue. It is important to consider the severity of contractures, extent of correction, and risk factors for recurrence in addition to protecting soft tissues when choosing the optimal surgical treatment. Surgery is ultimately an elective form of treatment and should prompt a conversation with patients regarding the risk and benefits of surgery as well as their functional goals.

### 8.1. Soft tissues

Proper handling of soft tissue is a key principle of surgical treatment of Dupuytren's contractures. Adequate exposure of the cord must be balanced with protecting the neurovascular bundles, providing adequate wound coverage, limiting the risk of skin necrosis, and avoiding secondary contractures from longitudinal scarring. Multiple skin incisions have been described to address these issues and include: transverse incisions in the palm and digit, a

Bruner incision, a Bruner incision with V-Y advancement flaps, curved incisions, and a longitudinal incision closed with z-plasties (**Figure 3**). Midline incisions provide the benefit of potentially avoiding the neurovascular bundles, however, Dupuytren's disease distorts regular anatomy and can tether the cord toward the midline. Curved or zig-zag incisions help avoid secondary contractures from longitudinal scars. Despite the many variations in incisions, the Bruner incision seems to be the most commonly used.

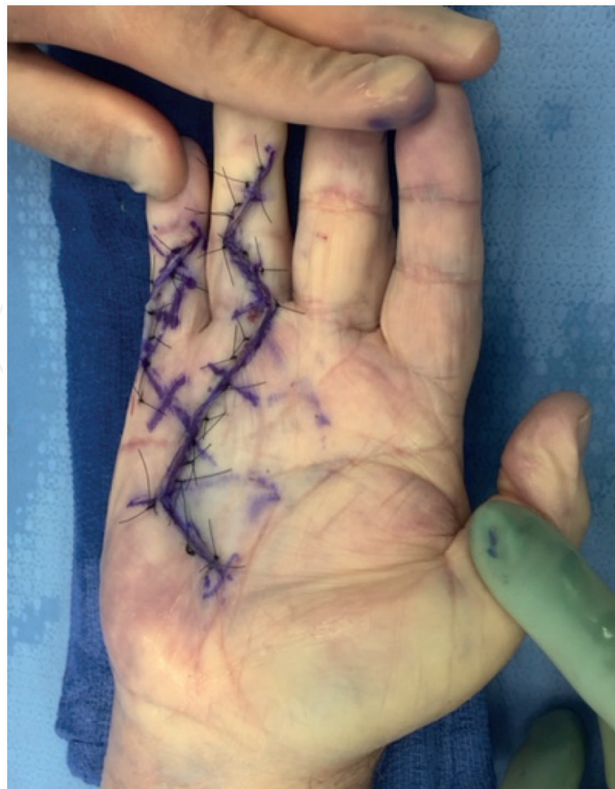Skin closure is another important aspect of treating Dupuytren's disease. The open-palm technique described by McCash left the skin incisions open to decrease hematoma formation and allowed for secondary healing with good results [66]. Today, most incisions are closed primarily, however, increased skin tension after closure has been correlated with elevated recurrence rate (**Figure 4**). Citron and Hearnden randomized patients undergoing fasciotomies and reported a 50% recurrence rate in the group with transverse incisions closed primarily compared with a 15% rate in patients with longitudinal incisions with a z-plasty closure [67]. Another study compared Bruner's incision with direct closure to a longitudinal incision with a z-plasty closure for fasciectomy and reported no difference between the two methods [68]. Special attention should be given to skin tension during closure and a transpositional flap such as a z-plasty should be utilized if needed.

## 8.2. Open fasciotomy

Open fasciotomy includes a variety of surgical techniques for treating Dupuytren's contractures by incising the contracted cord without removing the diseased fascia. Many of the modern fasciotomy techniques are modifications of the methods originally described by Dupuytren and



**Figure 3.** The figure outlines types of incisions and closures options for treating Dupuytren's disease. Thumb: longitudinal incision with z-plasty closure. Index finger: Bruner incision. Middle finger: curvilinear incision. Ring finger: V-Y incision. Small finger: transverse incisions utilized in the McCash open palm technique.



**Figure 4.** A post-operative image of a patient after a limited fasciectomy for a Dupuytren's contracture of the small and ring finger. The Brunner's incision was closed primarily with nylon sutures.

McCash et al. [6, 66]. Various types of incisions may be utilized to access the cord, but once the cord is visualized and incised, the digit is extended until straight. In some cases, additional incisions may be required at different levels along the cord in order to fully extend the digit. Unlike PNF, an open fasciotomy procedure provides the benefit of direct visualization to protect neurovascular structures and can often be accomplished through small incisions. In addition, it minimizes the potential morbidity sometimes seen in other techniques which excise the diseased fascia. Still, excision techniques are often preferred over an open fasciotomy for their ability to remove the diseased fascia which may aid in preventing regrowth of the cord and recurrence. This may be particularly true in patients with severe contractures. Stewart et al. retrospectively reviewed a series of patients who had open fasciotomies and reported a reoperation rate of 13.2% at 46 months with patients who initially required three level fasciotomies having worse recurrence [69]. Another study assessed 16 patients with Tubiana stage III and IV contractures and reported a higher recurrence rate of 37.5% at 5–8 year follow-up [70].

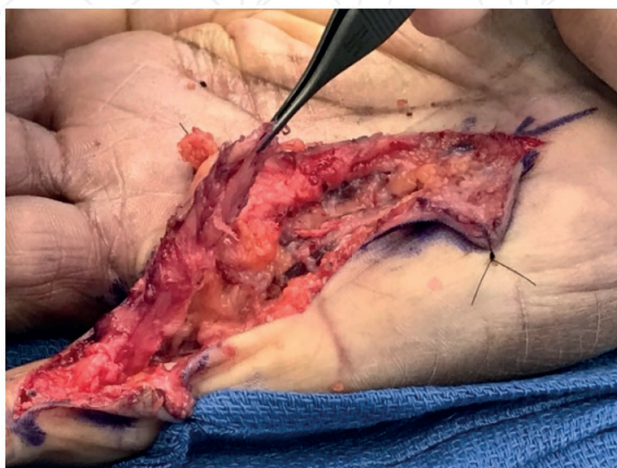### 8.3. Fasciectomy

Fasciectomy is the most common surgical treatment for Dupuytren's contractures. The technique is based on the concept that the remaining diseased fascia may proliferate and lead to recurrence. Multiple methods of fasciectomies have been described and range from a segmental fasciectomy, where a portion of the fascial cord is removed, to a radical fasciectomy where skin and diseased fascia are excised. A segmental fasciectomy is usually completed through small incisions where segments of the cord are excised until the finger straightens. No attempt

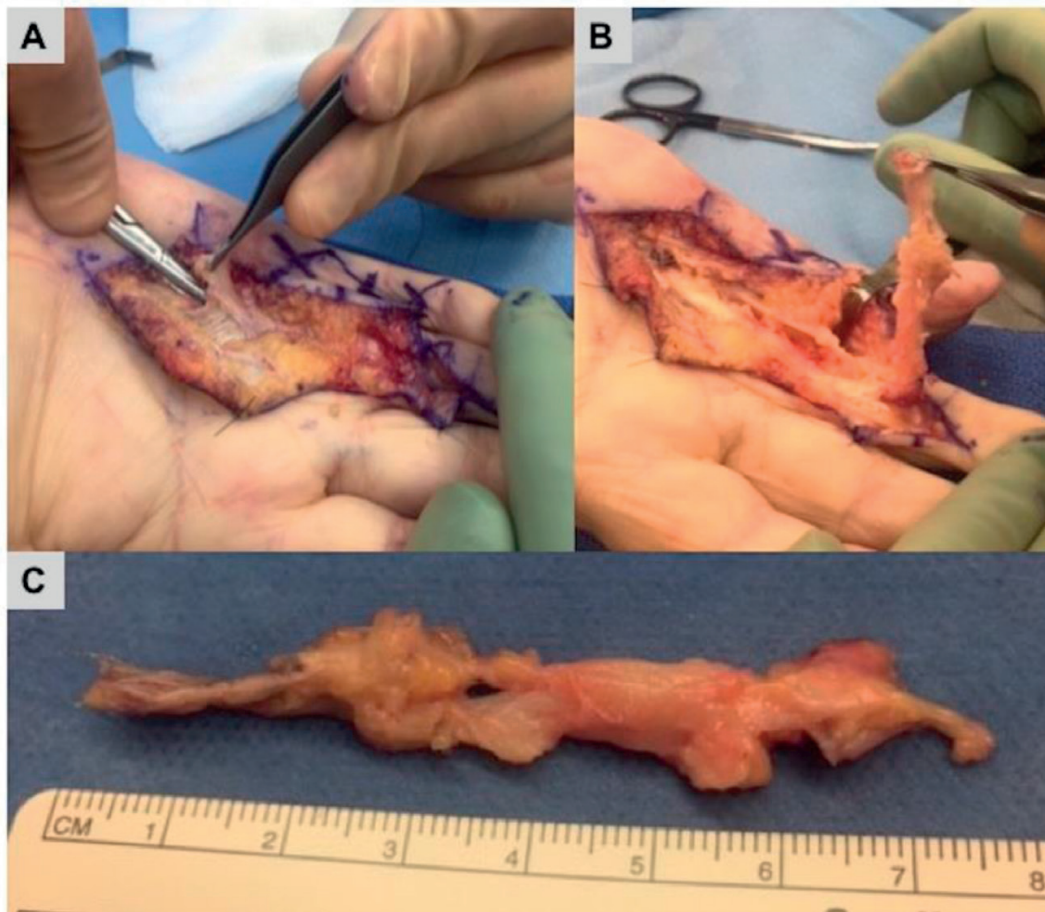
is made to removal the complete cord. The most widely used technique is a limited fasciectomy and is considered the gold standard in the operative treatment of Dupuytren's contractures (**Figure 5**). The technique involves carefully exposing the diseased fascia from its proximal to distal end and excising it from the surrounding soft tissue (**Figure 6**). It differs from a radical fasciectomy by removing only the diseased fascia and leaving normal fascia, subcutaneous tissue, and the dermis intact. Radical fasciectomy advocated by McIndie and Beare involved extensive removal of nearby tissue and skin and required a skin graft [71]. However, the technique largely fell out of favor due to a higher complication rate without a reduction in recurrence. A dermatofasciectomy is similar to a limited fasciectomy but involves excising the overlying skin and often requires a skin graft for coverage. Advocates of this technique report disease-forming cells may be left in the overlying soft tissue leading to recurrence and selectively use it in patients at higher risk for recurrence. Despite the variety of techniques, fasciectomies require meticulous dissection to avoid injuring neurovascular bundles which may be displaced by a contracted cord. In addition, maintaining hemostasis is important to prevent hematoma formation which can compromise healing. Overall, fasciectomies offer the benefit of removing more diseased fascia but are accompanied by increased morbidity related to a more extensive exposure.

#### 8.4. Post-operative protocol

Most surgeons utilize some form of rehabilitation to prevent further contractures and maintain ROM. After surgery, patients are typically immobilized in an extension-based splint for 2–3 days. Wounds are closely monitored following surgery to ensure adequate healing and to identify any barriers to healing such as infection, hematoma, or skin necrosis. Patients are often referred to a hand therapist within the first week of surgery for wound care, scar management, range of motion exercises, and splinting techniques to prevent contracture formation. A variety of splinting protocols and types of orthoses have been described. In general, protocols may involve static or dynamic splinting and be utilized at different periods of the day. Despite the widespread use of post-operative splinting, studies have found no strong evidence they are effecting in preventing loss of extension or recurrence. Collis et al. randomized patients to night



**Figure 5.** An intraoperative image of a patient undergoing a limited fasciectomy for a Dupuytren's contracture of the small finger. A Brunner's incision was utilized to exposed the disease tissue. The Dupuytren's cord is being elevated by the forceps.



**Figure 6.** An intraoperative image of a patient undergoing a limited fasciectomy for a Dupuytren's contracture of the ring finger. (A) A Brunner's incision was utilized to exposed the disease tissue. The longitudinal band of the palmar aponeurosis is being elevated. (B) The diseased fascia was meticulously elevated from proximal to distal. (C) The diseased fascia after removal from the digit.

time extension orthoses and hand therapy or hand therapy alone and reported no differences between the two groups in terms of active ROM or hand function [72]. A similar study found night time splinting offered no benefit in terms of ROM and function at 1 year after surgery and recommended splinting should only be utilized when extension deficits occur [73]. Overall, less invasive procedures allow for earlier rehabilitation and a shorter recovery period. In addition, wound healing often dictates how fast a patient can progress following surgery. A segmental aponeuroectomy may involve a 2–3 week recovery period whereas a fasciectomy may involve a much longer recovery period.

## 9. Patient outcomes

Overall, surgery is an effective method of treating Dupuytren's contractures and improving patients' hand function. In a survey of over 1100 patients who underwent surgical treatment 75% reported almost full or full correction of their contracture [74]. Zyluk et al. reported patients had significantly improved hand function as measured by the Disabilities of the Arm, Shoulder, and Hand (DASH) questionnaire after undergoing a subtotal fasciectomy [75]. In

addition, patient's experienced a significant improvement in the total loss of extension from an average of 80 to 10°. Another study prospectively evaluated 90 patients undergoing a fasciectomy for a 60-degree or more deficit in total active extension and reported 81% patient satisfaction with function, 87% reaching functional ROM, and significantly improved DASH scores at 1 year follow up [76].

Further analysis of surgical treatment has lead authors to identify certain characteristic associated with better outcomes. Patients with MCP contractures are more likely to achieve full intra-operative correction (Donaldson). However, correction of PIP contractures has a stronger correlation to improved hand function when compared with correction of the MCP joint [77]. Surgical treatment has focused on PIP contractures to maximize intra-operative correction and improve functional outcomes. Surgeons have tried releasing the PIP capsule with a fasciectomy to improve PIP correction, but there is no strong data to support whether it is effective [78]. Zyluk et al. reported younger patients had a significantly greater functional improvement after surgery as measured by the DASH score [75]. Studies have also cited the extent of preoperative deformity, incomplete correction, and multiple involved digits as factors affecting post-operative functional outcomes [75, 78–80].

Despite multiple studies reporting good outcomes after surgery, there are limited randomized studies comparing outcomes after different operative techniques. Ullah et al. found no difference in ROM or recurrence in 79 patients randomized to either direct closure with z-plasty or firebreak skin grafting after a fasciectomy, however, patients with skin grafting had an increased incidence of hypoesthesia [81]. Van Rijssen et al. randomized patients to percutaneous needle fasciotomy and limited fasciectomy and reported the PNF group was significantly higher recurrence rate (76.8 vs. 20.9%,  $p < 0.001$ ) and lower VAS satisfaction scores (6.2 vs. 8.3,  $p < 0.001$ ) [62]. Further prospective, randomized studies reporting functional outcomes, complications, and recurrence rates are necessary to recommend any surgical procedure.

## 10. Recurrence

Recurrence of a Dupuytren's contracture is a common event even after successful initial treatment. A systematic review analyzed 51 studies and reported recurrence rates ranged from 0 to 71% [82]. Furthermore, recurrence rates are difficult to assess as there is considerable variation in the criteria used to define recurrence. Some authors report the presence of any diseased tissue after treatment while others include only contractures necessitating re-operation. More recently, studies have tended to define recurrence as a 20–30° loss of extension in a successfully treated digit. A recent randomized study defined recurrence as a 20° reduction of total passive extension in a successfully treated digit and reported a 20.9% 5-year recurrence rate after limited fasciectomy [62].

Multiple studies have focused on identifying factors which may predispose patients to recurrence. The dramatic variability of recurrence rates may be due to the heterogeneity of the presentation of Dupuytren's itself, as many patients may have more aggressive biology associated with "Dupuytren's diathesis", whereas others may have more mild disease. Dupuytren

diathesis is a term coined by Hueston describing certain characteristics related to severe disease and increased recurrence [83]. Hindocha modified the criteria to include the following features within a Northern European population: male sex, <50 years old, bilateral disease, affected parent or sibling, and presence of Garrod's nodes and reported patients with all 5 features had a recurrence rate of 71% [84]. However, other studies have failed to demonstrate a significant correlation with recurrence among all 5 diathesis criteria. Van Rijssen reported only older age was found to delay recurrence after PNF and limited fasciectomy [62]. PIP joint contractures have an elevated recurrence rate after surgery compared to the MCP joint. Donaldson et al. reported 34.2% of fully corrected PIP joints experienced at least some loss of correction compared with 12.2% of MCP joints [80]. Patients with severe preoperative PIP contractures greater than 60°, incomplete correction, and poor post-operative compliance had significantly worse recurrence [78].

Surgical management of recurrent disease is challenging as anatomic landmarks and tissue plans become difficult to distinguish. There is currently limited data regarding the preferred surgical treatment. Roush and Stern compared dermatofasciectomy with a skin graft, interphalangeal joint arthrodesis, and fasciectomy with local flaps among 19 patients with recurrence after a prior surgery [85]. The fasciectomy cohort was the only group to significantly maintain total active motion at final follow-up, but all three groups had similar patient reported outcomes. It is important patients are aware of the risk of recurrence prior to their initial surgery and personal factors which may increase their likelihood of recurrence.

## 11. Complications

Despite good outcomes after surgical treatment of Dupuytren's contractures surgery is not without complications. A 20 year systematic review of complications by Denkler et al. reported an average major complication risk of 15% with complication rates ranging from 3.6 to 39.1% [86]. Specific complications after limited fasciectomy included the following: wound healing problems, 22.9%; flare reaction, 9.9%; complex region pain syndrome, 5.5%; nerve injury, 3.4%; infection, 2.4%; hematoma, 2.1%; and digit artery injury, 2%. Severe complications include tendon rupture or loss of the digit but are extremely rare. Patients with severe flexion contractures are more at risk of experiencing a complication [87]. Smoking and diabetes, however, has not been identified as an increased risk factor for wound healing problems after surgery [88]. Patients undergoing revision surgery for recurrence are most at risk for complications, especially neurovascular injuries due to scar tissue and loss of anatomic landmarks. Neurovascular injuries have been reported as high as 10 times more common in revision surgeries for recurrence [86].

## 12. Conclusion

Dupuytren's disease is a unique fibroproliferative disorder of palmar fascia likely resulting from a complex interplay of genetic and environmental factors. Despite extensive research,

its etiology remains unclear and treatment methods remain palliative. Observation is an acceptable form of treatment for mild disease and patients with low functional status. Collagenase injections and percutaneous fasciectomy are becoming more common as an initial treatment method for patients with isolated disease and a palpable cord. Surgical indications typically include a flexion contracture of  $>30^\circ$  at the MCP joint and  $10\text{--}15^\circ$  at the PIP joint but are also influenced by patients' functional goals. Limited fasciectomy is the preferred method of surgical treatment by most surgeons. However, there is insufficient high quality evidence comparing different methods of treatment. In general, starting with a less invasive treatment is a reasonable approach; the recurrence rate may be higher, but patients will benefit from a quicker rehabilitation and a lower complication rate. Limited fasciectomy can then be reserved for more severe disease, initial treatment failures, or recurrence. PIP contractures, however, may benefit from earlier intervention due to their impact on function, increased likelihood of incomplete correction, and higher recurrence rate. Overall, surgery is an effective treatment for Dupuytren's contractures but complications can occur especially related to wound healing, and many patients experience recurrence. Further research is still needed to compare treatment modalities and determine appropriate indications.

## Author details

Jeremiah D. Johnson, Colin Pavano and Craig Rodner\*

\*Address all correspondence to: rodner@uchc.edu

Department of Orthopaedic Surgery, University of Connecticut, Farmington, Connecticut, USA

## References

- [1] Flatt AE. The Vikings and baron Dupuytren's disease. *Proceedings (Baylor University Medical Center)*. 2001;**14**(4):378-384
- [2] McFarlane RM. On the origin and spread of Dupuytren's disease. *Journal of Hand Surgery*. 2002;**27**(3):385-390
- [3] Thurston AJ. Dupuytren's disease. *Journal of Bone and Joint Surgery. British Volume (London)*. 2003;**85**(4):469-477
- [4] Bruner JM. The dynamics of dupuytren's disease. *The Hand*. 1970;**2**(2):172-177
- [5] Whaley DC, Elliot D. Dupuytren's disease: A legacy of the north? *Journal of Hand Surgery (British)*. 1993;**18**(3):363-367
- [6] Dupuytren G. De la retraction des doigts par suite d'une affection de l'aponeurose palmaire Description de la maladie. Operation Chirurgicale Equiconvient dans de Cas. *Journal*

Universel Hebdomadaire de Medecine et de Chirurgie Pratiques et des institutions medicales. 1831;**5**:352e365

- [7] Elliot D. The early history of contracture of the palmar fascia. Part 1: The origin of the disease: The curse of the MacCrimmons: The hand of benediction: Cline's contracture. *Journal of Hand Surgery (British)*. 1988;**13**(3):246-253
- [8] Gudmundsson KG, Arngrímsson R, Sigfússon N, Björnsson A, Jónsson T. Epidemiology of Dupuytren's disease: Clinical, serological, and social assessment. The Reykjavik study. *Journal of Clinical Epidemiology*. 2000;**53**(3):291-296
- [9] Lennox IAC, Murali SR, Porter R. A study of the repeatability of the diagnosis of dupuytren's contracture and its prevalence in the grampian region. *The Journal of Hand Surgery: British & European Volume*. 1993;**18**:2, 258-261. DOI: 10.1016/0266-7681(93)90124-X
- [10] Mikkelsen OA. The prevalence of Dupuytren's disease in Norway. A study in a representative population sample of the municipality of Haugesund. *Acta Chirurgica Scandinavica*. 1972;**138**(7):695-700
- [11] Lanting R, van den Heuvel ER, Westerink B, Werker PMN. Prevalence of Dupuytren disease in The Netherlands. *Plastic and Reconstructive Surgery*. 2013;**132**(2):394-403. DOI: 10.1097/PRS.0b013e3182958a33
- [12] DiBenedetti DB, Nguyen D, Zografos L, Ziemiecki R, Zhou X. Prevalence, incidence, and treatments of Dupuytren's disease in the United States: Results from a population-based study. *The Hand*. 2011;**6**(2):149-158. DOI: 10.1007/s11552-010-9306-4
- [13] Anthony SG, Lozano-Calderon SA, Simmons BP, Jupiter JB. Gender ratio of Dupuytren's disease in the modern U.S. population. *Hand (N Y)*. 2008;**3**(2):87-90. DOI: 10.1007/s11552-007-9076-9
- [14] Burge P. Genetics of Dupuytren's disease. *Hand Clinics*. 1999;**15**(1):63-71
- [15] Ling RS. The genetic factor in Dupuytren's disease. *Journal of Bone and Joint Surgery. British Volume (London)*. 1963;**45**(4):709-718
- [16] Hindocha S, John S, Stanley JK, Watson SJ, Bayat A. The heritability of Dupuytren's disease: Familial aggregation and its clinical significance. *Journal of Hand Surgery*. 2006;**31**(2):204-210. DOI: 10.1016/j.jhsa.2005.09.018
- [17] Bayat A, Stanley JK, Watson JS, Ferguson MWJ, Ollier WER. Genetic susceptibility to Dupuytren's disease: Transforming growth factor beta receptor (TGFbetaR) gene polymorphisms and Dupuytren's disease. *British Journal of Plastic Surgery*. 2003;**56**(4):328-333
- [18] An HS, Southworth SR, Jackson WT, Russ B. Cigarette smoking and Dupuytren's contracture of the hand. *Journal of Hand Surgery*. 1988;**13**(6):872-874
- [19] Burge P, Hoy G, Regan P, Milne R. Smoking, alcohol and the risk of Dupuytren's contracture. *Journal of Bone and Joint Surgery. British Volume (London)*. 1997;**79**(2):206-210

- [20] Bradlow A, Mowat AG. Dupuytren's contracture and alcohol. *Annals of the Rheumatic Diseases*. 1986;**45**(4):304-307. DOI: 10.1136/ard.45.4.304
- [21] Attali P, Ink O, Pelletier G, et al. Dupuytren's contracture, alcohol consumption, and chronic liver disease. *Archives of Internal Medicine*. 1987;**147**(6):1065-1067
- [22] Noble J, Arafa M, Royle SG, McGeorge G, Crank S. The association between alcohol, hepatic pathology and Dupuytren's disease. *Journal of Hand Surgery (British)*. 1992;**17**(1):71-74
- [23] Noble J, Heathcote J, Cohen H. Diabetes mellitus in the aetiology of Dupuytren's disease. *The Journal of Bone and Joint Surgery*. 1984;**66-B**(3):322-325
- [24] Loos B, Puschkin V, Horch RE. 50 years experience with Dupuytren's contracture in the Erlangen University hospital—A retrospective analysis of 2919 operated hands from 1956 to 2006. *BMC Musculoskeletal Disorders*. 2007;**8**:60. DOI: 10.1186/1471-2474-8-60
- [25] Arkkila PE, Kantola IM, Viikari JS. Dupuytren's disease: Association with chronic diabetic complications. *The Journal of Rheumatology*. 1997;**24**(1):153-159
- [26] Dupuytren G. Permanent retraction of the fingers, produced by an affection of the palmer fascia. *Lancet*. 1834:222-225
- [27] Hueston JT. Dupuytren's contracture and specific injury. *The Medical Journal of Australia*. 1968:1084-1085
- [28] Auld T, Werntz JR. Dupuytren's disease: How to recognize its early signs. *The Journal of Family Practice*. 2017;**66**(3):E5-E10
- [29] Mikkelsen OA. Dupuytren's disease--initial symptoms, age of onset and spontaneous course. *The Hand*. 1977;**9**(1):11-15
- [30] Lund M. Dupuytren's contracture and epilepsy. *Acta Psychiatrica et Neurologica*. 1941;**16**:465-492
- [31] Thieme WT. Incidence of Dupuytren's contracture in Edinburgh. *The Journal of Bone and Joint Surgery*. 1968;**52B**:14-28
- [32] Critchley EM, Vakil SD, Hayward HW, Owen VM. Dupuytren's disease in epilepsy: Result of prolonged administration of anticonvulsants. *Journal of Neurology, Neurosurgery, and Psychiatry*. 1976;**39**(5):498-503
- [33] Arafa M, Noble J, Royle SG, Trail IA, Allen J. Dupuytren's and epilepsy revisited. *Journal of Hand Surgery (British)*. 1992;**17**(2):221-224
- [34] Palmer KT, D'Angelo S, Syddall H, Griffin MJ, Cooper C, Coggon D. Dupuytren's contracture and occupational exposure to hand-transmitted vibration. *Occupational and Environmental Medicine*. 2014;**71**(4):241-245. DOI: 10.1136/oemed-2013-101981
- [35] Haines A, Levis C, Goldsmith CH, et al. Dupuytren's contracture and handwork: A case-control study. *American Journal of Industrial Medicine*. 2017;**60**(8):724-733. DOI: 10.1002/ajim.22736

- [36] Black EM, Blazar PE. Review Dupuytren disease: An evolving understanding of an age-old disease. *The Journal of the American Academy of Orthopaedic Surgeons*. 2011;**19**:746-757
- [37] Luck JV. Dupuytren's contracture; a new concept of the pathogenesis correlated with surgical management. *The Journal of Bone and Joint Surgery. American Volume*. 1959; **41-A**(4):635-664
- [38] Murrell GA. An insight into Dupuytren's contracture. *Annals of the Royal College of Surgeons of England*. 1992;**74**(3):156-160; discussion 161
- [39] Mayerl C, Del Frari B, Parson W, et al. Characterisation of the inflammatory response in Dupuytren's disease. *Journal of Plastic Surgery and Hand Surgery*. 2016;**118**(August 2015):1-9. DOI: 10.3109/2000656X.2016.1140054
- [40] Brickley-Parsons D, Glimcher MJ, Smith RJ, Albin R, Adams JP. Biochemical changes in the collagen of the palmar fascia in patients with Dupuytren's disease. *The Journal of Bone and Joint Surgery. American Volume*. 1981;**63**(5):787-797
- [41] Tomasek JJ, Haaksma CJ. Fibronectin filaments and actin microfilaments are organized into a fibronexus in Dupuytren's diseased tissue. *The Anatomical Record*. 1991;**230**(2):175-182. DOI: 10.1002/ar.1092300205
- [42] Halliday NL, Rayan GM, Zardi L, Tomasek JJ. Distribution of ED-A and ED-B containing fibronectin isoforms in Dupuytren's disease. *Journal of Hand Surgery*. 1994;**19**(3):428-434. DOI: 10.1016/0363-5023(94)90057-4
- [43] Nascimento PCH, Kobayashi EY, Lenzi LG de S, Dos Santos JBG, Nader HB, Faloppa F. Glycosaminoglycans and proteoglycans in palmar fascia of patients with Dupuytren. *Acta Ortopédica Brasileira*. 2016;**24**(2):98-101. DOI: 10.1590/1413-785220162402154342
- [44] Hurst LC, Badalamente MA, Makowski J. The pathobiology of Dupuytren's contracture: Effects of prostaglandins on myofibroblasts. *Journal of Hand Surgery America*. 1986; **11**(1):18-23. DOI: 10.1016/S0363-5023(86)80093-4
- [45] Hanyu T, Tajima T, Takagi T, et al. Biochemical studies on the collagen of the palmar aponeurosis affected with Dupuytren's disease. *The Tohoku Journal of Experimental Medicine*. 1984;**142**(4):437-443. DOI: 10.1620/tjem.142.437
- [46] Baird KS, Crossan JF, Ralston SH. Abnormal growth factor and cytokine expression in Dupuytren's contracture. *Journal of Clinical Pathology*. 1993;**46**(5):425-428. DOI: 10.1136/jcp.46.5.425
- [47] Badalamente MA, Hurst LC, Sampson SP. Prostaglandins influence myofibroblast contractility in Dupuytren's disease. *Journal of Hand Surgery*. 1988;**13**(6):867-871. DOI: 10.1016/0363-5023(88)90261-4
- [48] Ross DC. Epidemiology of Dupuytren's disease. *Hand Clinics*. 1999;**15**(1):53-62, vi
- [49] Rayan GM. Dupuytren disease: Anatomy, pathology, presentation, and treatment. *The Journal of Bone and Joint Surgery. American Volume*. 2007;**89**(1):189-198. DOI: 10.1016/j.jhse.2007.02.052

- [50] Hueston JT. The table top test. *The Hand*. 1982;**14**(1):100-103
- [51] Tubiana R. Evaluation of deformities in Dupuytren's disease. *Annales de Chirurgie de la Main*. 1986;**5**(1):5-11
- [52] Broekstra DC, Lanting R, Werker PMN, van den Heuvel ER. Intra- and inter-observer agreement on diagnosis of Dupuytren disease, measurements of severity of contracture, and disease extent. *Manual Therapy*. 2015;**20**(4):580-586. DOI: 10.1016/j.math.2015.01.010
- [53] Reilly RM, Stern PJ, Goldfarb CA. A retrospective review of the management of Dupuytren's nodules. *Journal of Hand Surgery*. 2005 Sep;**30**(5):1014-1018
- [54] Bisson MA, Beckett KS, Mc Grouther DA, Grobbelaar AO, Mudera V. Transforming growth factor beta1 stimulation enhances Dupuytren's fibroblast contraction in response to uniaxial mechanical load within a 3-dimensional collagen gel. *Journal of Hand Surgery*. 2009;**4**(6):1102e1110
- [55] Larocerie-Salgado J, Davidson J. Nonoperative treatment of PIPJ flexion contractures associated with Dupuytren's disease. *The Journal of Hand Surgery, European Volume*. 2012 Oct;**37**(8):722-727
- [56] Brauns A, Van Nuffel M, De Smet L, Degreef I. A clinical trial of tension and compression orthoses for Dupuytren contractures. *Journal of Hand Therapy*. 2017 Jul-Sep;**30**(3):253-261
- [57] Ketchum LD, Donahue TK. The injection of nodules of Dupuytren's disease with triamcinolone acetonide. *Journal of Hand Surgery*. 2000 Nov;**25**(6):1157-1162
- [58] Yin CY, HM Y, Wang JP, Huang YC, Huang TF, Chang MC. Long-term follow-up of Dupuytren disease after injection of triamcinolone acetonide in Chinese patients in Taiwan. *The Journal of Hand Surgery, European Volume*. 2017 Sep;**42**(7):678-682
- [59] Zhao JZ, Hadley S, Floyd E, Earp BE, Blazar PE. The impact of collagenase clostridium histolyticum introduction on Dupuytren treatment patterns in the United States. *Journal of Hand Surgery*. 2016 Oct;**41**(10):963-968
- [60] Eaton C. Percutaneous fasciotomy for Dupuytren's contracture. *Journal of Hand Surgery*. 2011;**36**:910-915
- [61] Zhou C, Selles RW, Slijper HP, Feitz R, van Kooij Y, Moojen TM, Hovius SE. Comparative effectiveness of percutaneous needle aponeurotomy and limited fasciectomy for Dupuytren's contracture: A Multicenter observational study. *Plastic and Reconstructive Surgery*. 2016 Oct;**138**(4):837-846
- [62] van Rijssen AL, ter Linden H, Werker PM. Five-year results of a randomized clinical trial on treatment in Dupuytren's disease: Percutaneous needle fasciotomy versus limited fasciectomy. *Plastic and Reconstructive Surgery*. 2012 Feb;**129**(2):469-477
- [63] Hurst LC, Badalamente MA, Hentz VR, Hotchkiss RN, Kaplan FT, Meals RA, Smith TM, Rodzvilla J, CORD I Study Group. Injectable collagenase clostridium histolyticum for Dupuytren's contracture. *The New England Journal of Medicine*. 2009 Sep 3;**361**(10):968-979

- [64] Peimer CA, Blazar P, Coleman S, Kaplan FT, Smith T, Lindau T. Dupuytren contracture recurrence following treatment with collagenase clostridium histolyticum (CORDLESS [collagenase option for reduction of Dupuytren long-term evaluation of safety study]): 5-year data. *Journal of Hand Surgery*. 2015 Aug;**40**(8):1597-1605
- [65] Van Beeck A, Van den Broek M, Michielsen M, Didden K, Vuylsteke K, Verstreken F. Efficacy and safety of collagenase treatment for Dupuytren's disease: 2-year follow-up results. *Hand Surgery & Rehabilitation*. 2017 Oct;**36**(5):346-349
- [66] McCash CR. The open palm technique in Dupuytren's contracture. *British Journal of Plastic Surgery*. 1964;**17**:271e280
- [67] Citron N, Hearnden A. Skin tension in the aetiology of Dupuytren's disease; a prospective trial. *Journal of Hand Surgery*. 2003;**28B**:528-530
- [68] Citron N, Nunez V. Recurrence after surgery for Dupuytren's disease: A randomized trial of two skin incisions. *Journal of Hand Surgery*. 2005;**30B**:563-566
- [69] Stewart CJ, Davidson DM, Hooper G. Re-operation after open fasciotomy for Dupuytren's disease in a series of 1,077 consecutive operations. *The Journal of Hand Surgery, European Volume*. 2014 Jun;**39**(5):553-554
- [70] Guilhen TA, Vieira AB, de Castro MC, Hirata HH, Machado IR. Evaluation of surgical treatment of Dupuytren's disease by modified open palm technique. *Revista Brasileira de Ortopedia*. 2014 Feb 12;**49**(1):31-36
- [71] McIndoe A, Beare R. The surgical management of Dupuytren's contracture. *American Journal of Surgery*. 1958;**95**:197-203
- [72] Collis J, Collocott S, Hing W, Kelly E. The effect of night extension orthoses following surgical release of Dupuytren contracture: a single-center, randomized, controlled trial. *Journal of Hand Surgery (American Volume)*. 2013 Jul;**38**(7):1285-1294.e2
- [73] Jerosch-Herold C, Shepstone L, Chojnowski AJ, Larson D, Barrett E, Vaughan SP. Night-time splinting after fasciectomy or dermo-fasciectomy for Dupuytren's contracture: A pragmatic, multi-centre, randomised controlled trial. *BMC Musculoskeletal Disorders*. 2011 Jun 21;**12**:136
- [74] Dias J, Braybrooke J. Dupuytren's contracture: An audit of the outcomes of surgery. *Journal of Hand Surgery*. 2006;**31B**:514-521
- [75] Zyluk A, Jagielski W. The effect of the severity of the Dupuytren's contracture on the function of the hand before and after surgery. *The Journal of Hand Surgery, European Volume*. 2007 Jun;**32**(3):326-329
- [76] Engstrand C, Krevers B, Nylander G, Kvist J. Hand function and quality of life before and after fasciectomy for Dupuytren contracture. *Journal of Hand Surgery (American Volume)*. 2014 Jul;**39**(7):1333-1343.e2
- [77] Draviaraj KP, Chakrabarti I. Functional outcome after surgery for Dupuytren's contracture: A prospective study. *Journal of Hand Surgery*. 2004 Sep;**29**(5):804-808

- [78] Misra A, Jain A, Ghazanfar R, Johnston T, Nanchahal J. Predicting the outcome of surgery for the proximal interphalangeal joint in Dupuytren's disease. *Journal of Hand Surgery*. 2007 Feb;**32**(2):240-245
- [79] Sinha R, Cresswell TR, Mason R, Chakrabarti I. Functional benefit of Dupuytren's surgery. *Journal of Hand Surgery (British)*. 2002;**27**:378-381
- [80] Donaldson OW, Pearson D, Reynolds R, Bhatia RK. The association between intraoperative correction of Dupuytren's disease and residual postoperative contracture. *The Journal of Hand Surgery, European Volume*. 2010 Mar;**35**(3):220-223
- [81] Ullah A, Dias J, Bhowal B. Does a 'firebreak' full-thickness skin graft prevent recurrence after surgery for Dupuytren's contracture? *Journal of Bone and Joint Surgery*. 2009;**91B**:374-378
- [82] Becker G, Davis T. The outcome of surgical treatments for primary Dupuytren's disease—A systemic review. *Journal of Hand Surgery*. 2010;**35B**:623-626. Epub 2010 Jul 9
- [83] Hueston JT. Dupuytren's contracture. Edinburgh: E&S Livingstone; 1963. pp. 51-120
- [84] Hindocha S, Stanley J, Watson S, Ardeshir B. Dupuytren's diathesis revisited: Evaluation of prognostic indicators for risk of disease recurrence. *Journal of Hand Surgery*. 2006;**31A**:1626-1634
- [85] Roush T, Stern P. Results following surgery for recurrent Dupuytren's disease. *Journal of Hand Surgery*. 2000;**25A**:291-296
- [86] Denkler K. Surgical complications associated with fasciectomy for dupuytren's disease: A 20-year review of the English literature. *Eplasty*. 2010 Jan 27;**10**:e15
- [87] Bulstrode N, Jemec B, Smith P. The complications of Dupuytren's contracture surgery. *Journal of Hand Surgery*. 2005;**30A**:1021-1025
- [88] Eckerdal D, Nivestam A, Dahlin LB. Surgical treatment of Dupuytren's disease: Outcome and health economy in relation to smoking and diabetes. *BMC Musculoskeletal Disorders*. 2014;**15**:117