

We are IntechOpen, the world's leading publisher of Open Access books Built by scientists, for scientists

6,900

Open access books available

185,000

International authors and editors

200M

Downloads

Our authors are among the

154

Countries delivered to

TOP 1%

most cited scientists

12.2%

Contributors from top 500 universities



WEB OF SCIENCE™

Selection of our books indexed in the Book Citation Index
in Web of Science™ Core Collection (BKCI)

Interested in publishing with us?
Contact book.department@intechopen.com

Numbers displayed above are based on latest data collected.
For more information visit www.intechopen.com



Breast Imaging and Translation into Targeted Oncoplastic Breast Surgery

Michael Friedrich and Stefan Kraemer

Additional information is available at the end of the chapter

<http://dx.doi.org/10.5772/intechopen.72254>

Abstract

Preoperative staging of breast cancer based on breast imaging is mandatory. Breast imaging encompasses mammography, breast sonography and MR-mammography. Earlier diagnosis of breast cancer results in a favourable oncological outcome. Limitations and influences on operative procedures of MR-mammography in diagnosis and staging of breast cancer have to be discussed. Different interventional procedures have been developed. The histological results of interventional procedures guided by ultrasound, stereotactic mammography or magnetic resonance have to be integrated in planning surgical resection margins in oncoplastic breast-conserving surgery. Image-guided wire markings are an important tool for planning these surgical resection margins. This chapter summarises the results of breast imaging, interventional procedures and wire markings for the breast-conserving therapy of breast cancer. Breast imaging and interventional procedures are the basis for a concept of targeted oncoplastic breast surgery.

Keywords: breast cancer, breast imaging, mammography, breast ultrasound, magnetic resonance mammography, oncoplastic surgery, interventional breast diagnostics

1. Breast imaging

Earlier diagnosis of breast cancer results in a favourable outcome. Tumour size at diagnosis and the lymph node stage are the best predictive factors of outcome. As a result, the current strategy for reducing breast cancer mortality is to diagnose the disease as early as possible. Breast imaging is fundamental for the early diagnosis of breast cancer when symptoms occur or during screening programs.

Breast imaging is a general term that encompasses mammography, breast sonography, breast magnetic resonance imaging (MRI) and other technologies. To provide uniformity in the

assessment of breast imaging findings, the American College of Radiologists (ACR) established final assessment classifications [Breast Imaging Reporting and Data System (BI-RADS)] [1–3]. The final assessment categories are as follows: BI-RADS 1, negative; BI-RADS 2, benign; BI-RADS 3, probably benign (risk of malignancy <2%); BI-RADS 4, suspicious abnormality (biopsy should be considered); BI-RADS 5, highly suggestive of malignancy.

BI-RADS 4 and 5 assessments indicate abnormalities that require tissue biopsy for diagnosis. These categories represent a wide range (3–100%) of breast cancer risk.

2. Mammography

Mammography has been the basis of breast imaging for more than 30 years. The sensitivity of mammography for breast cancer is age dependent. The denser the breast, the less effective this method is for detecting early signs of breast cancer. In younger women, breast density tends to be higher, and increased density inhibits the detection of early signs of breast cancer [4]. The sensitivity of mammography for breast cancer in women over 60 years of age is about 95%, while mammography can be expected to detect less than 50% of breast cancers in women under 40 years of age [5]. Mammography is based on X-rays. Consensus is that the benefits of mammography in women over the age of 40 years are likely to far outweigh any oncogenic effects of repeated exposure. Screening of women over the age of 50 by mammography is accepted practice. However, in symptomatic patients with a palpable nodule in the breast, there is even an indication for performing mammography in women under the age of 35 when there is a strong clinical suspicion of malignancy. Practice is changing, and ultrasound is being increasingly used for the assessment of women with focal breast symptoms in this age range. Mammography is performed every 2 years in all women in the screening age group (50 years of age – 69 years of age) attending symptomatic patients who have not had a screening mammogram in the past year. Film/screen mammography has been refined over the years and has now reached the limits of this technology [6]. Film/screen mammography is a difficult technique to maintain at the quality levels required for optimal diagnosis because labour-intensive quality control measures are necessary to maintain the diagnostic standards. Today, digital mammography is the new standard. Major benefits have been predicted from acquiring mammograms in a direct digital format [7]. Compared with conventional mammography, the predicted benefits of full-field digital mammography include better imaging of the dense breast, the application of computer-aided detection and a number of logistical advantages providing potential for more efficient mammography services. The much wider dynamic range of digital mammography means that visualization of the entire breast density range on a single image is easily achievable. In the clinical setting, comparative studies have shown that digital mammography performs as well as film/screen mammography [8–11].

Recent preoperative mammographic evaluation is necessary to determine patient's eligibility for breast-conserving therapy. Mammography defines the extent of a patient's disease, the presence or absence of multicentricity and other factors (extent of microcalcifications) that might influence the treatment decision, and evaluates the contralateral breast. If the mass is associated with microcalcifications, an assessment of the extent of the calcifications

is performed. Magnification mammography is important for further characterisation of microcalcifications.

Mammography is the basis for stereotactic-guided breast biopsy. Stereotactic biopsy can be carried out using a prone biopsy table or by using an add-on device to a conventional upright mammography unit. This technique is used for biopsy of clinically occult lesions that are not detectable by ultrasound (e.g. microcalcifications) [12].

3. Ultrasound

High-frequency (≥ 7.5 MHz) ultrasound is a very effective diagnostic tool for the investigation of focal breast symptoms. It has a high sensitivity for breast lesions and also a very high negative predictive value. High-resolution ultrasound easily distinguishes between most solid and cystic lesions and can differentiate benign from malignant lesions with a high accuracy. Ultrasound is the technique of choice for the further investigation of focal symptomatic breast lesions at all ages. Under 35 years of age, when the risk of breast cancer is very low, it is usually the preferred imaging technique. Over 35 years of age, when the risk of breast cancer begins to increase, it is often used in conjunction with mammography. Ultrasound is less sensitive than mammography for the early signs of breast cancer and is therefore not used for population-based screening. However, ultrasound increases the detection of small breast cancer in women with a dense background tissue on mammography [13–15]. In the screening setting, there is currently insufficient evidence of any mortality benefit even in women with dense mammograms. Ultrasound is the preferred technique to guide biopsy of both palpable and impalpable breast lesions visible on scanning [16]. Ultrasound is being increasingly used to assess the axilla in women with breast cancer. Axillary nodes that show abnormal morphology can be accurately sampled by needle core biopsy.

Doppler ultrasound adds additional accuracy to breast diagnosis and is widely used. Three-dimensional ultrasound of the breast also increases the accuracy of biopsy and the detection of multifocal disease but is not widely available [17, 18]. Elastography is a new application of ultrasound technology that allows the accurate assessment of the stiffness of the breast tissue. It is being evaluated at present and may prove to be a useful tool in excluding significant abnormalities, for instance, in assessment of asymptomatic abnormalities detected by ultrasound.

4. Magnetic resonance mammography

Magnetic resonance imaging (MRI) is widely available and used in breast cancer diagnosis. Magnetic resonance mammography (MRM) requires dedicated breast coils. In order to image the breast, the patient is scanned prone, and injection of intravenous contrast (Gd-DTPA) is required. A variety of possible clinical indications for contrast-enhanced MRM have been reported. These include screening for breast cancer, determining the local extent of malignant

disease, identifying an occult primary, assessing response to neoadjuvant chemotherapy, identifying local recurrences after breast-conserving therapy, breast imaging after implant reconstruction or breast augmentation, and the detection of ipsilateral breast cancer in patients presented with axillary lymph node metastases (CUP-syndrome) [19–23].

MRM is the most sensitive technique for detection of breast cancer, approaching 100% for invasive cancer and 60–70% for ductal carcinoma in situ (DCIS), but it has a high false-positive rate [24–28]. Rapid acquisition of images facilitates assessment of signal enhancement curves that can be helpful in distinguishing benign and malignant disease. Breast lesions seen on MRM that are larger than 10 mm can be seen on ultrasound if they are clinically significant (second-look ultrasound). MRM is likely to prove the best method for screening younger women (under 40 years) at increased risk of breast cancer but it is unlikely to be used for general population screening. MRM is the best technique for imaging women with breast implants. It is also of benefit in identifying recurrent breast cancer after breast-conserving therapy where conventional imaging has failed to exclude recurrence. Performed more than 12 months after surgery, MRM will accurately distinguish between tumour recurrence and scars [29, 30]. MRM is being increasingly used to examine women for multifocal or multicentric disease prior to conservation surgery, especially in patients with invasive lobular breast cancer. MRI of the axilla will demonstrate axillary metastatic disease but its sensitivity is not sufficient for it to replace surgical staging of the axilla.

Many questions surrounding the use of MRM of the breast in patients with breast cancer remain unanswered. Just because MRM can detect additional areas of cancer, does it really matter clinically? Should surgical treatment be altered because MRM detects additional foci of cancer, especially in those cases when these areas represent foci of DCIS? Would these additional areas of cancer identified on MRM be successfully treated with postoperative radiation therapy? The rate of MRM-detected multifocal disease, which ranges from 16–37%, is clearly much higher than the rate of in-breast recurrence after breast-conserving therapy, with reported rates in two studies with a 20-year follow-up of 8.8% and 14.3%, respectively [31, 32]. This strongly suggests that in some, and perhaps many cases, the additional foci of cancer identified only on MRM, especially those that prove to be in situ disease, would likely be successfully treated with postoperative radiation. Which MRM-detected multifocal or multicentric cancer would be successfully treated with postoperative radiation and which would not, later presenting as a local “recurrence”? In those cases when MRM detects an invasive cancer that is clearly separate from the primary cancer, either in the same or a different quadrant, should mastectomy be recommended, based on the historical treatment of clinically or mammographically detected multifocal or multicentric cancer, or is the patient still eligible for breast-conserving therapy if the lesion can be successfully excised with negative margins [33]? There are additional questions concerning patient selection. Which are the patients at the highest risk for having multifocal or multicentric cancer who would benefit most from MRM (young patients, patients with dense breasts, patients with lobular cancer)? Based on the current success of breast-conserving surgery, it is unlikely that MRM of the breast is warranted in all patients with newly diagnosed breast cancer [20, 34]. Clinical investigation continues in an effort to find answers to these questions (**Figure 1**).

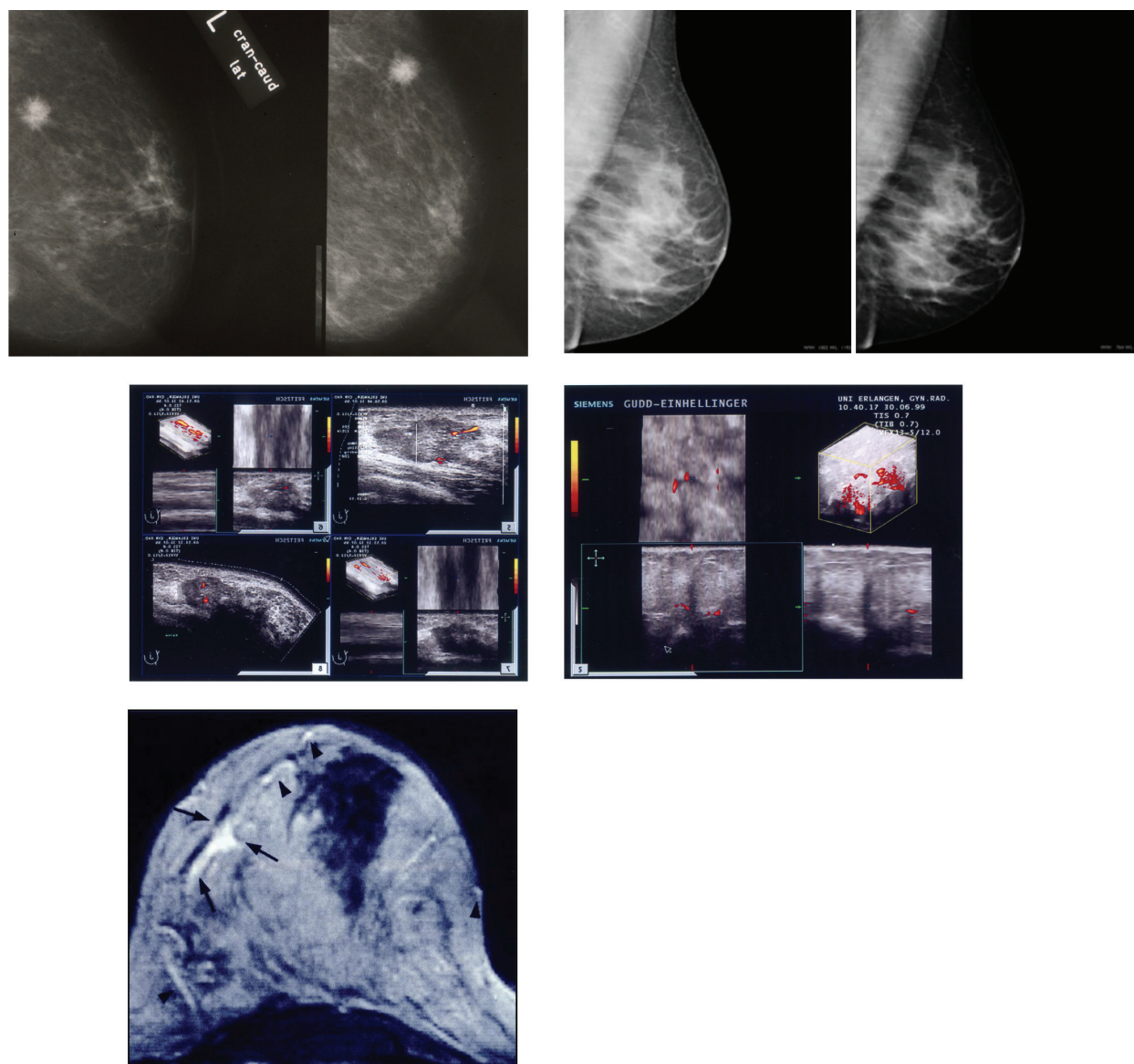


Figure 1. Complementary breast imaging.

5. Breast cancer screening

The aim of breast cancer screening is to reduce mortality through early detection. Randomised controlled trials and case-control studies demonstrated that population screening by mammography can be expected to reduce overall breast cancer mortality by around 25%. [35, 36]. The validity of these trials was questioned, but subsequent reviews have reaffirmed the mortality benefit of mammographic screening and determined that criticisms of the mammographic screening trials were unjustified [37, 38]. The mortality benefit of screening is greatest in women aged 50–70 years. Screening of women under the age of 40 has not been shown to provide any mortality benefit [39–41].

The screening method is two-view mammography. Clinical examination of the breast and breast self-examination have not been shown to contribute to mortality reduction through early detection.

Women at increased risk of developing breast cancer due to a proven inherited predisposing genetic mutation, family history, previous radiotherapy or benign risk lesions may be selected for screening at young age [42, 43]. There is evidence that MRM is the most sensitive method of imaging young women [44]. The specificity of MRM is low and the rate of false-positive results is high—these circumstances have been extensively discussed. Second-look and targeted ultrasound and preoperative MRI-guided biopsy can increase the low specificity of MRM.

6. Image-guided breast biopsy

Needle biopsy is highly accurate in determining the nature of most breast lesions classified as BI-RADS 4 or 5. Patients with benign conditions avoid unnecessary surgery. Carrying out open surgical biopsy for diagnosis should be regarded as a failure of the diagnostic process. For patients who prove to have breast cancer, needle biopsy provides accurate understanding of the type and extent of disease, so ensuring that patients and the doctors treating them are able to make informed treatment choice. Needle biopsy not only provides information on the nature of malignant disease, such as histological type and grade, but also enables pretreatment analyses of prognostic and predictive factors to characterise the immunohistochemical phenotype and the tumour biology (hormone-receptors, HER-2 receptor, genetic profiling, etc.) [45, 46].

Breast needle biopsies of nonpalpable lesions require imaging to guide needle placement. Imaging guidance can be performed with ultrasonography, stereotactic mammography or MRM. Ultrasound guidance is the technique of choice; it is less costly and easy to perform. Ultrasound provides real-time visualisation of the biopsy procedure and visual confirmation of adequate sampling. Between 80 and 90% of breast abnormalities will be clearly visible on ultrasound [47]. For impalpable abnormalities not visible on ultrasound, stereotactic-guided biopsy is required. A few lesions are only visible on MRM and require magnetic resonance-guided biopsy.

Most lesions selected for ultrasound-guided biopsy are solid masses that can be sampled with 14-gauge core needles. The technical aspects involved in performing ultrasound-guided procedures with a free-hand approach have been described previously [48]. The technique used consists of the following steps: imaging the lesion, finding the needle in the longitudinal plane through the breast, maximally visualising the needle tip and placing the needle in the lesion. Development of good hand-eye coordination is crucial to a successful lesion sampling (**Figure 2**) [49].

Using the 14-gauge needle, multiple core biopsy samples are necessary to ensure accurate sampling of different areas of the lesion. In most cases, accurate lesion sampling can be achieved by obtaining 3–5 core samples for masses and 5–10 core samples for microcalcifications [50, 51].

To improve sampling of microcalcifications using digital, stereotactic mammography guidance, the vacuum-assisted biopsy instrument with probes coming in 11-gauge size has been developed [12]. In contrast to the automated biopsy gun devices, the directional, vacuum-assisted biopsy instrument is inserted once and rotated while in the breast to obtain samples from different areas of the lesion. A vacuum is used to pull tissue samples into the sample notch, where it is cut and transported back through the needle and out to the collection chamber. Multiple tissue samples are collected without removing the needle from the breast (Figure 3).

Studies have shown improved sampling of microcalcifications with the vacuum-assisted biopsy instrument [52, 53]. For calcifications, it is imperative that there is a proof of representative

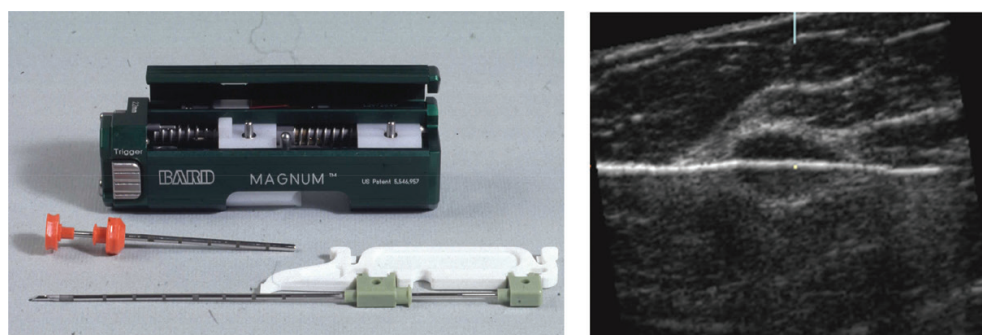


Figure 2. US-guided breast core biopsy (14-gauge).

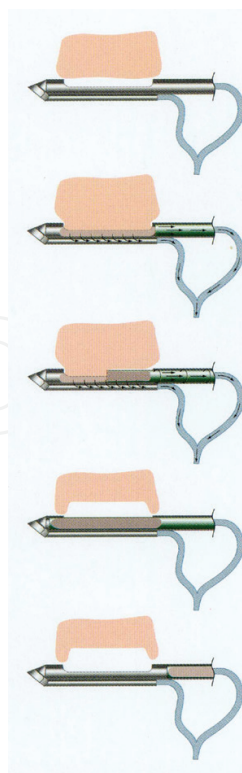


Figure 3. Vacuum-assisted core biopsy (11-gauge).

sampling with specimen radiography. If calcification is not demonstrated on the specimen radiography and the histology is benign, then management cannot be based on this result as there is a high risk of sampling error; the procedure must either be repeated or open surgical biopsy carried out [54–60].

An 8-gauge vacuum-assisted biopsy probe is preferred for therapeutic removal of breast lesions such as fibroadenomas [61–64].

The low specificity of MRM requires the ability to perform MRI-guided biopsies, which require an additional specialised MRI biopsy coil and MRI-compatible wires and needles for localisation and core biopsies [65–67]. Centres that cannot perform MRI-guided localisation and biopsy lack the ability to manage lesions visible only with MRI and are at a clear disadvantage.

The technical aspects of MRI-guided localisation and biopsy are similar to those for stereotactic biopsies in that the patient is prone during the procedure, the breast is held in compression, and the needle plane is guided into the tissue parallel to the chest wall. Needle placement is performed with the patient outside the bore of the magnet using an MRI-compatible needle, often made of titanium. The patient is then returned to the magnet, and confirmation of adequate needle placement is obtained. After sufficient core samples are obtained outside of the bore of the magnet, a clip is placed marking the biopsy cavity. In our practice, patients with MRM-detected indeterminate or suspect lesions are first scheduled for targeted second-look ultrasonography because often these lesions can be visualised after discovery on MRM.

In cases of complete radiological removal of small occult breast lesions with needle biopsies, clip marking with the possibility for re-localisation in cases of necessary therapeutic open surgical resection is mandatory. Core needle and vacuum-assisted biopsy is extremely useful in the evaluation of patients with multiple suspect lesions.

It is important that the result of needle breast biopsy is always correlated with the clinical and imaging findings before clinical management is discussed with the patient. This is best achieved by reviewing each case at prospective multidisciplinary meetings. The results of image-guided breast biopsies are translated in the planning process of targeted oncoplastic breast surgery when malignancy is diagnosed. Breast surgery is directly based on breast imaging and interventional diagnosis. Multidisciplinary coworking between radiology, pathology and breast surgery is mandatory.

7. Wire-guided surgical excision

The number of impalpable, clinically occult breast lesions is increasing. Accurate localisation techniques are required to facilitate their surgical excision as the therapeutic part of a planned oncoplastic breast-conserving procedure [68]. The hooked wire is the most commonly employed technique and has proved very reliable. There are various designs of localisation wire in common use. All have some form of anchoring device such as a hook with a splayed

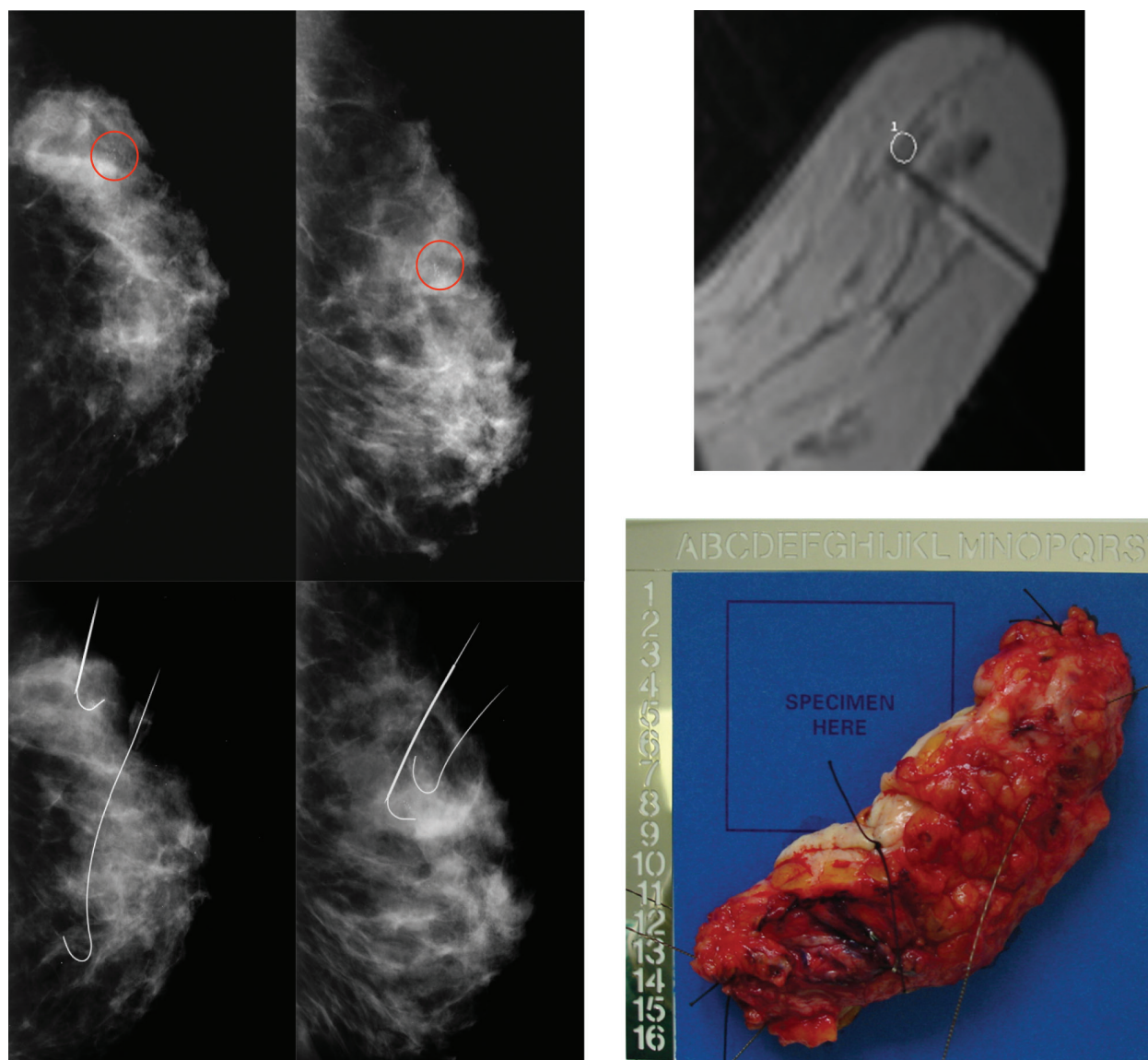


Figure 4. Wire-guided (mammography and MRI) segmental excision.

or barbed tip. The wire is placed under ultrasound, stereotactic or MRI guidance (for MRM lesions only) within a rigid over-sheath cannula, which is then removed once positioning is satisfactory. Most wires are very flexible, and when the cannula is removed, the wire may assume a quite circuitous course. Care must be taken to avoid displacing the wire.

Procedures that can be surgically more challenging are wide local excisions (segmental resection) for DCIS with no mass lesion. In such cases, where the distribution of disease is often more eccentric, careful three-dimensional excision planning especially in oncoplastic procedures is necessary. Inserting more than one wire and even bracketing and framing the lesion with two or three can occasionally be useful (**Figure 4**).

If the procedure is being performed to establish a diagnosis (diagnostic segmentectomy), a representative portion of the lesion is excised through a small incision, thus leaving a satisfactory

cosmetic result if the lesion proves to be benign. In the therapeutic situation, the marked lesion should be completely excised. Intraoperative specimen radiography is essential, both to check that the lesion has been removed and, if cancer has been diagnosed, to ensure that adequate radiological resection margins have been achieved. We have to consider that especially in DCIS, the proved radiological resection margin (specimen radiography) sometimes differs from the histological resection margin [68–71].

8. Translation of breast imaging into targeted breast surgery

Advances in breast imaging have led some to question whether whole-breast ultrasound or MRM should be part of the standard preoperative evaluation of a patient with breast cancer. Golshan et al. [72] reviewed the impact of ipsilateral whole-breast ultrasound on the surgical management of 426 patients with clinical stage I and II cancer. Seventy-five of the 426 patients (18%) had additional lesions identified by ultrasound, but only 12 were malignant. The role of ultrasound as a diagnostic tool for the evaluation of breast masses is well established (as is its role in defining lesions that are poorly seen on mammogram or are mammographically occult), and the available data support its use as a routine tool when evaluating patients for breast-conserving therapy.

Tillmann et al. [73] reported the results of a similar study of the impact of MRM on the management of 207 women with DCIS and stage I and II breast cancer. The MRM findings affected clinical management in 20% of cases. In 6%, MRM had an unfavourable effect due to false-positive findings that resulted in unnecessary mastectomy or additional breast biopsies.

The work of Holland et al. [33] indicated that microscopic foci of invasive and non-invasive cancer are present at a distance from apparently localised primary tumours in a significant number of patients. Only 39% of specimens showed no evidence of cancer beyond the reference tumour, while in 20%, additional cancer was found within 2 cm of the reference tumour. Forty-one per cent of patients had residual cancer more than 2 cm from the reference tumour. The percentage of patients with residual cancer more than 2 cm from the reference tumour corresponds well to the rate of local recurrences reported in patients treated with breast-conserving surgery alone without postoperative radiotherapy. Radiotherapy is effective in controlling the majority of these occult foci of carcinoma.

The ability of MRM and ultrasound to identify these tumour foci raises the possibility that significant numbers of women who could be treated with breast-conserving therapy will be subject to unnecessary mastectomy. Histologic subtype other than invasive ductal carcinoma does not appear to be associated with an increased risk of recurrence. If the tumour is not diffuse in the breast and can be completely excised with negative margins, patients with invasive lobular carcinoma are candidates for breast-conserving therapy. However, because of the increased incidence of multicentricity, invasive lobular cancer associated with increased mammographic density is an accepted indication for preoperative MRM before breast-conserving therapy.

9. Conclusion

The translation of breast imaging, interventional procedures and wire-guided surgical excision into a concept of targeted oncoplastic breast-conserving surgery is mandatory, and an interdisciplinary task for the breast radiologist and the breast surgeon to achieve the best oncological and aesthetic outcomes for patients with breast cancer is also mandatory.

Acknowledgements

Version 2.0 after incorporation of the mentioned comments of the review. Dr. Krämer was senior author and writing author of the article in Breast Care, He is a well-known co-developer of the translation concept of breast imaging into Targeted Oncoplastic Breast Surgery.

Author details

Michael Friedrich^{1*} and Stefan Kraemer^{1,2}

*Address all correspondence to: michael.friedrich@helios-kliniken.de

1 Department of Obstetrics and Gynecology, HELIOS Medical Center, Krefeld, Germany

2 Breast Unit, HELIOS Hospital, Lutherplatz, Krefeld, Germany

References

- [1] Balleyguier C, Ayadi S, Van Nguyen K, Banel D, Dromain C, Sigal RBIRADS. Classification in mammography. *European Journal of Radiology*. 2007;**61**:192-194
- [2] Levy L, Suissa M, Chiche JF, Teman G, Martin B. BIRADS ultrasonography. *European Journal of Radiology*. 2007;**61**:202-211
- [3] Tardivon AA, Athansiou A, Thibault F, El Khoury C. Breast imaging and reporting data system (BIRADS): Magnetic resonance imaging. *European Journal of Radiology*. 2007;**61**:212-215
- [4] Fasching PA, Heusinger K, Loehberg CR, Wenkel E, Lux MP, Schrauder M, Koscheck T, Bautz W, Schulz-Wendtland R, Beckmann MW, Bani MR. influence of mammographic density on the diagnostic accuracy of tumor size – Assessment and association with breast cancer tumor characteristics. *European Journal of Radiology*. 2006;**60**:398-404
- [5] Kopans DB. The positive predictive value of mammography. *American Journal of Roentgenology*. 1992;**158**:521-526

- [6] Kopans DB. The accuracy of mammographic interpretation. The New England Journal of Medicine. 1994;**331**:1521-1522
- [7] Schulz-Wendtland R, Hermann KP, Bautz W. Clinical results of digital mammography. Radiologe. 2005;**45**:255-263
- [8] James JJ. The current status of digital mammography. Clinical Radiology. 2004;**59**:1-10
- [9] Säbel M, Aichinger U, Schulz-Wendtland R, Bautz W. Digital full field mammography. Röntgenpraxis. 1999;**52**:171-177
- [10] Lewin JM, D'Orsi CJ, Hendrick RE. Clinical comparison of full-field digital mammography with screen-film mammography for detection of breast cancer. American Journal of Roentgenology. 2002;**179**:671-677
- [11] Schulz-Wendtland R, Lell M, Wenkel E, Aichinger U, Imhoff K, Bautz W. Experimental investigations at the new digital mammographic system. RöFo Journal. 2003;**175**:1564-1566
- [12] Schulz-Wendtland R, Aichinger U, Krämer S. Interventionelle mammographisch gestützte Techniken. In: Duda V, Schulz-Wendtland R, editors. Mammadiagnostik – Komplementärer Einsatz aller Verfahren. Springer Verlag; 2004
- [13] Stavros AT, Thickman D, Rapp CL. Solid breast nodules: Use of sonography to distinguish between benign and malignant lesions. Radiology. 1995;**196**:123-134
- [14] Madjar H, Mundinger A, Degenhardt F, Duda V, Hackelöer BJ, Osmer R. Qualitätskontrolle in der Mamma-Sonographie. Ultraschall in der Medizin. 2003;**24**:190-194
- [15] Duda VF, Bock K, Ipsen A, Schulz KD. Sonographisches Mehrstufenkonzept in der Mammadiagnostik. RöFo Journal. 2001;**173**:54-55
- [16] Schulz-Wendtland R, Krämer S, Döinghaus K, Mitze M, Lang N. Sonographisch gesteuerte Mikrobiopsie der Brust: Eine neue interventionelle Technik. Gynäkologie. 1997;**2**:50-56
- [17] Krämer S, Schulz-Wendtland R, Aichinger U, Bautz W, Lang N. Panorama-Sonographie (Siescape 3D) der Brust – Planung der brusterhaltenden Therapie beim Mammakarzinom. Ultraschall in der Medizin. 1999;**20**:104
- [18] Watermann DO, Földi M, Hanjalic-Beck A, Hasenburg A, Lüghausen A, Prömpeler H, Gitsch G, Stickeler E. Three-dimensional ultrasound for the assessment of breast lesions. Ultrasound in Obstetrics & Gynecology. 2005;**25**:592-598
- [19] Liberman L, Morris EA, Kim CMMR. Imaging findings in the contralateral breast of women with recently diagnosed breast cancer. American Journal of Roentgenology. 2003;**180**:333-341
- [20] Krämer S, Schulz-Wendtland R, Hagedorn K, Bautz W, Lang N. Magnetic resonance imaging and its role in the diagnosis of multicentric breast cancer. Anticancer Research. 1998;**18**:2163-2164

- [21] Krämer S, Schulz-Wendtland R, Hagedorn K. Magnetic resonance imaging in the diagnosis of local recurrences in breast cancer. *Anticancer Research*. 1998;**18**:2159
- [22] Rieber A, Brambs HJ, Gabelmann A, Breast MRI. For monitoring response of primary breast cancer to neo-adjuvant chemotherapy. *European Radiology*. 2002;**12**:1711
- [23] Schulz-Wendtland R, Aichinger U, Krämer S, Lang N, Bautz W. Scars and local recurrences – The role of the MRI. *European Radiology*. 2000;**10**:41-43
- [24] Kaiser WA, Zeitler EMR. Imaging of the breast: Fast imaging sequences with and without Gd-DTPA: Preliminary observations. *Radiology*. 1989;**170**:681-686
- [25] Heywang SH, Wolf A, Pruss EMR. Imaging of the breast with Gd-DTPA: Use and limitations. *Radiology*. 1989;**171**:95-103
- [26] Sittek H, Kessler M, Bredl T, Lebeau A, Bohmert H, Reiser MF. Breast malignancies: Dynamic FLASH3D MR-mammography versus mammography. *Radiology*. 1994;**193**:121
- [27] Orel SG, Schnall MD, LiVolsi VA. MR imaging of the breast with rotating delivery of excitation off resonance: Clinical experience with pathologic correlation. *Radiology*. 1993;**187**:493-501
- [28] Orel SG, Mendonca MH, Reynolds C. MR imaging of ductal carcinoma in situ. *Radiology*. 1997;**202**:413-420
- [29] Schulz-Wendtland R, Aichinger U, Krämer S, Wilhelmi U, Lell M, Lang N, Bautz W. Follow-up after breast-conserving therapy: Comparison of conventional imaging methods with MRI. *Geburtsh Frauenheilk*. 2001;**61**:396-399
- [30] Aichinger U, Schulz-Wendtland R, Dobritz M, Lell M, Krämer S, Lang N, Bautz W. Scar or recurrence – Comparison of MRI and color-coded ultrasound with echo signal amplifiers. *Fortschr Röntgenstr*. 2002;**174**:395-1401
- [31] Veronesi U, Cascinelli N, Mariani L. Twenty-year follow-up of a randomized study comparing breast-conserving surgery with radical mastectomy for early breast cancer. *The New England Journal of Medicine*. 2002;**347**:1227-1232
- [32] Fisher B, Anderson S, Bryant J. Twenty-year follow-up of a randomized trial comparing total mastectomy, lumpectomy, and lumpectomy plus irradiation for the treatment of invasive breast cancer. *The New England Journal of Medicine*. 2002;**347**:1233-1241
- [33] Holland R, Connolly J, Gelman R. Histologic multifocality of Tis, T1-2 breast carcinomas: Implications for clinical trials of breast-conserving treatment. *Cancer*. 1985;**56**:979
- [34] Fischer U, Kopka L, Grabbe E. Breast carcinoma: Effect of preoperative contrast-enhanced MR imaging on the therapeutic approach. *Radiology*. 1999;**213**:881-888
- [35] Skaane P, Young K, Skjennald A. Comparison of film-screen mammography and full-field mammography with soft-copy reading in a population-based screening program: The Oslo II study. *Radiology*. 2002;**225**:267

- [36] Tabar L, Fagerberg CJ, Gad A, Baldetorp I, Holmberg LH, Grontoft O, Ljungquist U, Lundstrom B, Manson JC, Eklund G. Reduction in mortality from breast cancer after mass screening with mammography. *Lancet* 1985;**I**:829-832
- [37] Olsen O, Gotzsche PC. Cochrane review on screening for breast cancer with mammography. *Lancet*. 2001;**358**:1340-1342
- [38] Nystrom L, Andersson I, Bjurstam N. Long-term effects of mammographic screening: Update overview of the Swedish randomised trials. *Lancet*. 2002;**359**:909-919
- [39] Schulz-Wendtland R, Becker N, Bock K, Anders K, Bautz W. Mammography screening. *Radiologe*. 2007;**47**:359-369
- [40] Schulz-Wendtland R, Krämer S, Döinghaus K, Säbel M, Lang N, Bautz W, Die Bedeutung d. Röntgen-Mammographie für das Mammakarzinomscreening. *Röntgenpraxis*. 1997;**50**: 103-109
- [41] Tabar L, Vitak B, Tony HH. Beyond randomised controlled trials: Organised mammographic screening substantially reduces breast carcinoma mortality. *Cancer*. 2001;**91**:1724-1731
- [42] Beckmann MW, Fasching RA, Gall C, Bani M, Brumm C, Krämer S. Genetic risk factors in breast cancer. *Gynakologe*. 2002;**35**:527-536
- [43] Beckmann MW, Bani MR, Fasching PA, Strick R, Lux MP. Risk and risk assessment for breast cancer: Molecular and clinical aspects. *Maturitas*. 2007;**57**:56-60
- [44] Kuhl CK, Schmutzler RK, Leutner CC, Breast MR. Imaging screening in 192 women proved or suspected to be carriers of a breast cancer susceptibility gene: Preliminary results. *Radiology*. 2000;**215**:267-279
- [45] Fersis N, Smyczek-Gargya B, Krainick U, Mielke G, Müller-Schimpfle M, Kiesel L, Wallwiener D. Clinical experience with large-core needle biopsies of the breast and evaluation of histopathology. *Zentralbl Gynäkol*. 2001;**123**:132-135
- [46] Schulz-Wendtland R, Krämer S, Lang N, Bautz W. Ultrasonic guided microbiopsy in mammary diagnosis: Indications, technique and results. *Anticancer Research*. 1998;**18**: 2145-2146
- [47] Parker SH, Jobe WE, Dennis MA. US-guided automated large-core breast biopsy. *Radiology*. 1993;**187**:507
- [48] Schulz-Wendtland R, Krämer S, Döinghaus K, Mitze M, Lang N. Interventionelle Techniken in der Mammadiagnostik: sonographisch gezielte Stanzbiopsie. *Akt Radiology*. 1997;**7**:30-34
- [49] Sickles EA, Parker SH. Appropriate role of core biopsy in the management of probably benign lesions. *Radiology*. 1994;**190**:313
- [50] Schulz-Wendtland R, Aichinger U, Krämer S, Tartsch M, Kuchar I, Magener A, Bautz W. Sonographical breast biopsy: How many core biopsy specimens are needed ? *Fortschr Röntgenstr* 2003;**173**:94-98

- [51] Liberman L, Feng TL, Dershaw DD. US-guided core breast biopsy: Use and cost-effectiveness. *Radiology*. 1998;**208**:717-723
- [52] Kettritz U, Rotter K, Muraier M. Stereotaxic vacuum biopsy in 2874 patients: A multi-center study. *Cancer*. 2004;**100**:245-251
- [53] Heywang-Koebrunner SH, Schaumloeffel U, Viehweg P. Minimally invasive stereotaxic vacuum core breast biopsy. *European Radiology*. 1998;**8**:377-338
- [54] Azavedo E, Svane G, Auer G. Stereotaxic fine needle biopsy in 2594 mammographically detected nonpalpable lesions. *Lancet*. 1989;**1**:1033
- [55] Parker SH, Lovin JD, Jobe WE. Nonpalpable breast lesions: Stereotactic automated large core biopsies. *Radiology*. 1991;**180**:403
- [56] Liberman L, Dershaw DD, Rosen PP. Stereotaxic 14-gauge breast biopsy: How many core biopsy specimens are needed? *Radiology*. 1994;**192**:793
- [57] Burbank F. Mammographic findings after 14 gauge automated needle and 14 gauge directional vacuum assisted stereotactic breast biopsy. *Radiology*. 1997;**204**:153
- [58] Liberman L, Dershaw D, Morris EA. Clip placement after stereotactic vacuum-assisted breast biopsy. *Radiology*. 1997;**205**:417
- [59] Krämer S, Schulz-Wendtland R, Lang N. Qualitätssicherung bei der stereotaktischen Stanzbiopsie durch Einsatz eines Phantoms. *Akt Radiology*. 1996;**6**:153-155
- [60] Schulz-Wendtland R, Heywang-Köbrunner S, Aichinger U, Krämer S, Wenkel E, Bautz W. Do tissue marker clips after sonographically or stereotactically guided breast biopsy improve follow-up of small breast lesions and localisation of breast cancer after chemotherapy ? *Fortschr Röntgenstr*. 2002;**174**:620-624
- [61] Parker SH, Klaus AJ, McWey M. Sonographically guided directional vacuum-assisted breast biopsy using a handheld device. *American Journal of Roentgenology*. 2001;**177**:405-408
- [62] Schulz-Wendtland R, Krämer S, Bautz W. First experiences with a new vacuum-assisted device for breast biopsy. *Fortschr Röntgenstr*. 2003;**173**:1496-1499
- [63] Krainick-Strobel U, Majer I, Huber B, Gall C, Krämer B, Gruber I, Fehm T, Huober J, Hierlemann H, Doser M, Meyberg-Solomayer G, Hoffmann J, Wallwiener D, Hahn M. Development of a gel-simulation model and generation of standard tables for the complete extirpation of benign breast lesions with vacuum assisted biopsy under ultrasound guidance. *Ultrasound in Medicine & Biology*. 2006;**32**:1539-1544
- [64] Krämer S, Schulz-Wendtland R, Bautz W, Lang N. Neue Aspekte in der interventionellen Mammdiagnostik und Brustchirurgie – ABBI (Advanced Breast Biopsy Instrumentation) in der Diagnostik und minimal invasiven Mammachirurgie. In: Waclawiczek HW, editor. *Die interdisziplinäre kurative Behandlung des Mammakarzinoms*. Heidelberg: Johann Ambrosius Barth Verlag; 1998

- [65] Kuhl CK, Elevelt A, Leutner CC. Interventional breast MR imaging: Clinical use of stereotactic localization and biopsy device. *Radiology*. 1997;**204**:667-675
- [66] Heywang-Koebrunner SH, Schaumlöffel-Schulze U, Heinig A. MR-guided percutaneous vacuum biopsy of breast lesions: Experience with 100 lesions. *Radiology*. 1999;**213**:289
- [67] Fischer U, Vosschenrich R, Döler W, Hamadeh A, Oestmann JW, Grabbe E. MR-imaging-guided breast intervention: Experience with two systems. *Radiology*. 1995;**195**:533-538
- [68] Krämer S, Jäger W, Lang N, Beckmann MW. Surgical treatment of breast cancer in the elderly. *Journal of Menopausal Medicine*. 2004;**2**:9-15
- [69] Meyer JE, Kopans DB, Stomper PC. Occult breast abnormalities: Percutaneous preoperative needle localization. *Radiology*. 1984;**150**:335-337
- [70] Schulz-Wendtland R, Bauer M, Krämer S, Büttner A, Lang N. Stereotaxie – Eine Methode zur Punktion, Stanzbiopsie und Markierung kleinster mammographischer Herdbefunde. *Chirurgische Praxis*. 1995;**49**:123-136
- [71] Orel SG, Schnall MD, Newman RW. MR imaging-guided localization and biopsy of breast lesions: Initial experience. *Radiology*. 1994;**193**:97-102
- [72] Golshan M, Fung BB, Wolfman J. The effect of ipsilateral whole breast ultrasound on the surgical management of breast carcinoma. *American Journal of Surgery*. 2003;**186**:391
- [73] Tillman GF, Orel SG, Schnall MD. Effect of breast magnetic resonance imaging on the clinical management of women with early-stage breast carcinoma. *Journal of Clinical Oncology*. 2002;**20**:3413