

We are IntechOpen, the world's leading publisher of Open Access books Built by scientists, for scientists

6,900

Open access books available

186,000

International authors and editors

200M

Downloads

Our authors are among the

154

Countries delivered to

TOP 1%

most cited scientists

12.2%

Contributors from top 500 universities



WEB OF SCIENCE™

Selection of our books indexed in the Book Citation Index
in Web of Science™ Core Collection (BKCI)

Interested in publishing with us?
Contact book.department@intechopen.com

Numbers displayed above are based on latest data collected.
For more information visit www.intechopen.com



Germ Cell Tumors and their Association with Pregnancy

Mamta Gupta and Vandana Saini

Additional information is available at the end of the chapter

<http://dx.doi.org/10.5772/intechopen.72556>

Abstract

Ovarian germ cell tumors (OGCTs) comprise 20–25% of all ovarian cancers arising from germ cells of ovary. Mature teratoma (dermoid) is the only benign and commonest germ cell tumor. Only 3–5% germ cell tumors are malignant, dysgerminomas being the most common. These tumors occur in adolescents and reproductive age group. Hence, its association with pregnancy is not uncommon. They can be reliably diagnosed with ultrasound imaging. Raised levels of tumor markers in pregnancy should be interpreted with caution. Cystectomy can be done for benign germ cell tumors. However, fertility sparing surgery with surgical staging with or without adjunctive therapy is recommended for malignant germ cell tumors (MOGTs). Surgery is safe in the second trimester of pregnancy. MOGTs are quite sensitive to chemo and radiotherapy. Three to four courses of chemotherapy with bleomycin, etoposide, and platinum is recommended. Prognosis of these germ cell tumors is excellent.

Keywords: germ cell, germ cell tumors, dermoid cyst in pregnancy, dysgerminoma in pregnancy, immature teratoma, BEP therapy

1. Introduction

Germ cells are the cells in the body that develop into sperms and eggs or oogonia, the gametes. The precursors of germ cells are termed primordial germ cells (PGCs). Like all other somatic cells, the primordial germ cells are diploid. They are present in yolk sac during early embryonic life, and migrate from the yolk sac to its destination, gonadal ridges in the developing gonads. These PGCs proliferate and finally differentiate into oogonia in females. The development and differentiation of PGCs is crucial for assuring normal fertility and the genomic transmission to the next generation [1]. These germ cells are mainly

found in the gonads. But, they can sometimes be left behind in other parts of the body during intrauterine development of the individual (extragonadal germ cells).

2. Germ cell tumors

Germ cell tumors (GCTs) are derived from primitive germ cells. More than 90% of GCTs develop in the gonads; ovary or testicle, the remainder is extragonadal, and distributed along the midline of the body, i.e., mediastinum, CNS, retroperitoneum, and sacrococcygeal region [2]. Deregulation of imprinted genes can be associated with tumorigenesis and altered cell differentiation capacity. Ovarian germ cell tumors may be distinguished by their line of differentiation. These tumors can arise from:

1. Primitive totipotent germ cells, i.e., dysgerminoma
2. Primordial germ cells which differentiate into embryonal or extraembryonal cells.
 - a. Embryonal cells from which mature and immature teratoma can arise.
 - b. Extraembryonal cells i.e., trophoblast and yolk sac from which choriocarcinoma and endodermal sinus tumor can arise respectively.

Ovarian germ cell tumors differ in clinical presentation, histology and biology, and include both benign (predominantly) and malignant subtypes. They constitute about 20–25% of all ovarian neoplasms. Only 5% of germ cell tumors are malignant, with most (95%) being benign mature cystic teratomas. Ovarian malignant germ cell tumors (OMGCTs) include, in order of frequency, dysgerminomas, immature teratomas, yolk sac tumors, and mixed germ cell tumors. Other less common OMGCTs include embryonal carcinomas, choriocarcinomas, and malignant struma ovarii tumors. OMGCTs constitute about 5% of all malignant ovarian neoplasms [3].

A review of the Surveillance, Epidemiology, and End Results (SEER) data taken between 1973 and 2002 reported an incidence of OMGCTs of 3.4/1,000,000 women in the USA [4] and a survey of GCTs in England between 1979 and 2003 [4] reported an incidence of 2.34/1,000,000 women [5]. Data from other countries have reported higher incidence of 5% [3].

The incidence of OGCT is not variable throughout the world. In contrast to epithelial ovarian cancers, there appears to be no racial predisposition; however, incidence of OMGCTs in the Saudi Arabian population (13.8%) was reported approximately three times the incidence of Western populations (5%) and roughly matched the incidence of Asian and African populations (15%) [6].

OMGCTs predominantly occur in young women, but can occur in various other age groups, with the highest incidence in 15–19 years age. The incidence of OGCT increases from the age 8–9 years and peaks at 18 years (20 per million). The mean age of presentation is 19 years. In the first two decades of life, more than 60% of ovarian tumors are of germ cell origin, and one-third of these are malignant. The incidence of OGCT is much lower than testicular tumors; 10.4 per million in females compared to 44.5 per million in males at [7].

3. WHO classification (three categories)

- a. Primitive germ cell tumors:
 - i. Dysgerminomas
 - ii. Nondysgerminomas (yolk sac tumors, embryonal carcinoma, polyembryoma, nongestational carcinoma, and mixed tumors)
- b. Biphasic and triphasic germ cell tumors—teratomas
- c. Monodermal teratoma and somatic type tumors associated with dermoid cyst

4. Etiology of germ cell tumors

Etiological factors for GCT are ill-understood, apart from an increased incidence associated with dysgenetic gonads. Five percent of patients with dysgerminomas are associated with abnormalities involving the entire or part of the Y chromosome, 46 XY (testicular feminisation), gonadal dysgenesis and mixed gonadal dysgenesis (45 X, 46 XY). However, 95% of females with dysgerminomas are cytogenetically normal [7].

Chromosome 12p abnormalities are frequent in dysgerminoma of the ovary. FISH analysis for chromosome 12p abnormalities may be used for confirming the diagnosis of dysgerminoma and for differential diagnosis from nongerminoma cell malignancies [9].

Reduced expression of p16 protein due to INK4A promoter methylation is one of the principal factors that promote cell proliferation in OMGCTs. Thus, p16 may be a novel target for gene therapies to treat OMGCTs [10].

Increased and prolonged expression of stem cell-related proteins (OCT3/4, KIT, and NANOG) in the gonadal tissues of trisomy 21 patients suggests that a delay in fetal germ cell differentiation is a key factor in the development of GCTs [11].

Each of the histological subtype of germ cell cancers show recurrent molecular characteristics of ploidy indices, DNA copy number changes, and specific expression patterns of mRNA, miRNA, and proteins [12].

A familial predisposition has been observed by some with more than one family member or sibling affected. Screening of family members is debatable; however, a discussion regarding these reports with the affected family may be worthwhile [13].

5. Staging of ovarian tumors

Staging of germ cell tumors is as for other ovarian tumors. The FIGO 2014 staging is given in Table 1 [14].

Stage	Tumor involvement
I	Confined to ovaries
IA	Confined to 1 ovary without capsular/surface involvement, cytology from peritoneal washings or ascitis –ve
IB	Confined to both ovaries without capsular/surface involvement, cytology from peritoneal washings or ascitis –ve
IC	Confined to 1 or both ovary with capsular/surface involvement, cytology from peritoneal washings or ascitis +ve
II	Extends beyond ovaries but limited to pelvis
IIA	Extension/implants to uterus/tubes, cytology from peritoneal washings or ascitis –ve
IIB	Extension to other pelvic tissues, cytology from peritoneal washings or ascitis –ve
III	Involves one or both ovaries/fallopian tubes/primary peritoneal cancer, with cytologically or histologically confirmed spread to the peritoneum outside the pelvis and/or metastasis to the retroperitoneal lymph nodes
IIIA	Metastasis to the retroperitoneal LN with or without microscopic peritoneal involvement beyond the pelvis
IIIA1	Positive retroperitoneal lymph nodes only (cytologically or histologically proven)
IIIA2	Microscopic extrapelvic (above the pelvic brim) peritoneal involvement with or without positive retroperitoneal lymph nodes
IIIB	Macroscopic peritoneal metastases beyond the pelvic brim ≤ 2 cm in greatest dimension, with or without metastasis to the retroperitoneal LN
IIIC	Macroscopic peritoneal metastases beyond the pelvic brim > 2 cm in greatest dimension, with or without metastases to the retroperitoneal LN. 1. Includes extension of tumor to capsule of liver and spleen without parenchymal involvement of either organ.
IV	Distant metastases
IVA	Pleural effusion with positive cytology
IVB	Metastases to extra-abdominal organs (including inguinal LN and LN outside abdominal cavity); parenchymal metastases of liver and spleen.

Table 1. FIGO 2014 staging.

6. Germ cell tumors in pregnancy

The incidence of ovarian cancer in pregnancy is quite low, 1 in 12,500–25,000 pregnancies. The estimated incidence of ovarian tumors is approximately 1 in 1000 pregnancies of which approximately 3–6% are malignant [15, 16]. However, a higher incidence of 1 in 143 to 1 in 556 of ovarian tumors in pregnancy has been reported [17, 18]. The incidence of ovarian tumor in pregnant woman requiring surgery was 1 in 1693 (0.025%) [19].

These tumors are relatively asymptomatic; however, the routine use of USG has led to more frequent finding of adnexal masses making diagnosis and management more challenging.

Pregnancy associated with ovarian malignancies present significant challenges and need balancing between optimal maternal therapy and fetal well-being. In addition, cancer diagnosis may be delayed because of difficulties in distinguishing symptomatology from physiologic changes in pregnancy and the difficulty in applying the standard diagnostic work-up in a pregnant

woman. Finally, the lack of prospective randomized treatment studies, and therefore, objective data has prevented the development of clinical guidelines for most of the issues complicating the treatment of pregnancy associated ovarian cancer.

6.1. Clinical features

These tumors may be asymptomatic, diagnosed as adnexal mass during routine antenatal ultrasound imaging. The overall estimated incidence of adnexal masses in pregnancy ranges from 2 to 10% [20]. With the use of ultrasound in the first trimester, the reported incidence of adnexal masses has increased. The incidence gradually decreases due to spontaneous resolution of many of these masses as gestation advances. These tumors may present with pain, mass or distension of abdomen, urinary or bowel symptoms. It can be misdiagnosed as fibroid [21]. It can present with acute abdomen, misdiagnosed as acute appendicitis or ectopic pregnancy or with bleeding per vaginum [22]. It is difficult to diagnose ovarian malignancies from functional cysts or benign ovarian tumors. The differentials of such an adnexal mass in pregnancy include ectopic pregnancy, corpus luteal cyst, functional cyst, paraovarian cyst, endometrioma, leiomyoma, and ovarian neoplasms.

6.1.1. Tumor markers in germ cell tumors

The important markers of germ cell tumors are serum alpha feto protein (AFP), human chorionic gonadotropin (hCG), and lactic dehydrogenase (LDH).

Alpha-fetoprotein—it is a normal fetal serum protein synthesized by the liver, yolk sac, and gastrointestinal tract. Almost all endodermal sinus tumors of the ovary express AFP. AFP is also expressed by immature teratomas, ovarian embryonal cell carcinoma, and polyembryomas. It is present in the cytoplasm of tumor cells and in the characteristic hyaline globules observed in the endodermal sinus tumor. It is raised in 85% of patients with these tumors but in only 20% of patients with stage I disease. Hence, this marker has limited role in screening. Typical values seen in normal pregnancy for AFP is 1000 to 10,000 ng/mL, >9 multiples of median [23].

AFP is present in 100% women with yolk sac tumor, 61.9% in immature teratoma, and 11.8% in dysgerminoma, but no positive case for AFP in mature cystic teratoma and mature cystic teratoma with malignant transformation is seen [24].

Pregnancy normal and abnormal, hepatocellular carcinoma, cirrhosis, and hepatitis also may be associated with increased levels of serum AFP. Nevertheless, an extremely raised AFP in a normal pregnancy may be associated with endodermal sinus tumor, an aggressive malignant germ cell tumor.

Human chorionic gonadotropin—it is a glycoprotein produced by syncytiotrophoblast and is made of alpha and beta subunits. Choriocarcinoma gestational and nongestational (ovarian) both express hCG.

LDH-dysgerminomas are commonly associated with elevations in LDH, although it is not elevated in all dysgerminomas. Occasionally, dysgerminomas may become infiltrated with

syncytiotrophoblastic giant cells, which produce beta-hCG. Elevations in AFP are less common with dysgerminomas. Many scientists contend that AFP/hCG secreting dysgerminomas are misdiagnosed as pure lesions, and that they actually represent mixed tumors containing other malignant germ cell components.

Mixed lesions may secrete AFP, hCG, or both or neither of these markers, depending on the components.

Therefore, useful tumor markers for the workup of germ cell tumors include-hCG, AFP, LDH, Inhibin A and B to rule out sex cord stromal tumors, Cancer antigen 125 (CA-125) to rule out epithelial tumors.

These serologic elevations of tumor markers readily resolve following surgical excision; and may be used as tumor markers to monitor for recurrence.

6.1.2. Limitation of tumor markers in pregnancy

Some established tumor markers are synthesized and secreted physiologically during fetal development, i.e., hCG, AFP, inhibin, making them less useful during pregnancy [20]. CA125 increases in early pregnancy and post-partum period having limited diagnostic utility. HCG also peaks during the first trimester. The values of tumor markers therefore, should be interpreted with caution during pregnancy and treatment strategies should not be based on levels of these markers alone.

6.2. Imaging

6.2.1. Imaging in malignant and benign tumors

There are numerous ultrasound features of adnexal masses that have been associated with increased risk of malignancy including size, solid components or heterogeneous/complex appearance, excrescences/papillary structures, internal septations, bilaterality, irregular borders, increased vascularity, low resistance blood flow, and presence of ascites [20]. Finding of ascites by ultrasound may be closely related with advanced stage malignancy and bad prognosis [25]. Some germ cell tumors have characteristic imaging features, i.e., dysgerminoma, mature, and immature teratomas can be diagnosed with high accuracy.

MRI may provide additional information. CT is not recommended in pregnancy due to ionization risk to the developing fetus.

6.2.2. Imaging in torsion of tumors

Sonographically ovarian torsion is demonstrated by visualizing an enlarged, edematous ovary along with a mass or cyst. Doppler imaging may fail to demonstrate arterial and/or venous blood flow to the ovary. Ovarian torsion is a clinical diagnosis and ultrasound should only be used to provide additional supportive diagnostic information. A recent study showed that 19% of patients with torsion had normal preoperative Doppler flow to the affected adnexa [26]. The risk of torsion among pregnant patients with adnexal tumors >4 cm increases, 51% of torsions occurred in tumors measuring 6–8 cm in diameter. The highest rate of torsion occurred between 15 and 16 weeks of gestation. Sixty percent of the torsion happened between the 10th and 17th weeks of gestation [27].

6.3. Effect of pregnancy on ovarian tumor

Increased risk of torsion, incarceration, rupture, and hemorrhage can occur during pregnancy and vaginal delivery.

6.4. Effect of ovarian tumors on pregnancy

Spontaneous successful pregnancy with no fetomaternal compromise has been reported [21]. Fetal demise has been reported to be in 25% of cases [28].

6.5. Management in pregnancy

Majority of adnexal masses in pregnancy are benign and a good percentage will spontaneously resolve. About 55% of masses resolve completely or significantly decrease in size [29, 30]. Best predictors of persistence are complex appearance and size greater than 5 cm.

Observation: Patients with simple or functional appearing small adnexal masses should have surveillance with ultrasound every trimester [30, 31].

Surgery: Surgical intervention is required in situations: if malignancy is suspected; if an acute complication, i.e., torsion or rupture develops; if any suspicious mass (complex cyst with solid components or thick septa) more than 5 cm in size persists near 18 weeks, demonstrates a 30–50% increase in size at any time during the pregnancy or exceeds 8 cm in size.

The goals of surgery include: removal of the mass to avoid complications during pregnancy, obtain a diagnosis, and to stage or debulk ovarian cancer if malignancy is identified. Laparotomy for an adnexal mass is done by a midline incision and begins with obtaining peritoneal washings and a complete exploration of the abdomen and contralateral ovary. Manipulation of the uterus should be minimized, as this could increase the risk of placental abruption, premature labor, or fetal loss. If the clinical suspicion for malignancy is low and it seems technically feasible, a cystectomy rather than salpingo-oophorectomy is performed. If, however, the clinical suspicion for cancer is high (excrescences, ascites, etc.) or the mass is solid, the tube and ovary should be removed. In either case, a frozen section should be obtained.

If a malignancy is confirmed and seems to be confined to the ovary, then a full staging surgery including peritoneal biopsies, omentectomy, and lymphadenectomy should be considered; however, the benefit gained from the more extensive surgery must be balanced against potential fetomaternal morbidity. Conservative surgical management for most malignant ovarian germ cell tumors diagnosed during pregnancy should be considered as the proper initial treatment [32]. Staging is critical as adjuvant therapy during pregnancy, is only initiated for those with advanced-stage disease. Routine biopsy or wedge-resection of the contralateral ovary is not necessary unless it seems to be involved with disease.

If metastatic disease is detected, an attempt at cytoreduction should be undertaken. The fetomaternal risk of an extended and radical debulking should be weighed with the potential maternal benefit, realizing that interval cytoreduction after chemotherapy and completion of the pregnancy is a reasonable approach [33]. However, the majority of ovarian cancers associated with pregnancy are diagnosed at an early stage, when disease is still confined to the ovary [34, 35].

In recent years, laparoscopy has been used to manage benign looking adnexal masses with minimal morbidity.

6.6. Timing of intervention

The ideal time for intervention is 14–22 weeks gestational age. It avoids the period of greatest risk of drug-induced teratogenicity; spontaneous fetal losses due to intrinsic fetal abnormalities have already occurred; the function of corpus luteum has been replaced by the placenta; most functional cysts have disappeared; an acceptable operative field is still available, allowing minimal uterine manipulation and low risk of obstetric complications. A later surgery in pregnancy, at the end of second trimester or at third trimester, may be technically more difficult and may result in an adverse obstetric outcome [36].

When indicated for other reasons, cesarean section may also be an opportunity for the surgical management of adnexal masses. In patients who undergo vaginal delivery, and in whom surgery was not indicated antenatally, a repeat imaging should be performed 6–8 weeks post-partum [37].

6.7. Pregnancy outcome after surgical intervention during pregnancy

Surgery is considered safe in second trimester [38] before 23 weeks, yet the decision to proceed with surgical management should outweigh the risks of adverse perinatal outcomes. The incidences of congenital malformations and stillbirths were not increased in the offspring of women having surgery. The incidences of abortions; very-low and low birth weight infants were increased due to increase in the risk of prematurity and intrauterine growth retardation. [39]. The incidence of infants dying within 168 h was increased. No specific types of anesthesia or operation were associated with adverse outcomes [40].

6.8. Oncologic outcome after surgical intervention in pregnancy

Majority of women at the time of diagnosis of ovarian tumors during pregnancy, have favorable results as most have low grade and early stage disease. It is appropriate to consider fertility sparing surgery in these young women. However, there are reports about the rapid growth and recurrence of ovarian germ cell tumors during pregnancy [28]. Hence, patients should undergo comprehensive surgical staging at the time of diagnosis.

6.9. Adjuvant therapy

Germ cell tumors are quite sensitive to chemo and radiotherapy. Chemotherapy usually is the adjuvant of choice to spare fertility. BEP (bleomycin, cisplatin, etoposide) is the standard adjuvant chemotherapy for 3–4 cycles [41]. Recommendations for chemotherapy are:

- Recurrence during observation (for stage IA dysgerminoma and stage IA grade 1 immature teratoma).
- Stage II–IV dysgerminoma.
- Stage II–IV teratoma or stage I grade 2–3.
- Embryonal or endodermal sinus tumor irrespective of stage [42].

6.9.1. Chemotherapy

Chemotherapy should not be given during the first trimester due to high risk of fetal malformations. Fetal congenital malformation risk is 10% for single agent and 25% for combination chemotherapy in first trimester.

Bleomycin—it is a copper-chelating glycoprotein capable of inducing DNA strand scission breaks via oxidative processes. This drug is eliminated by the kidneys. Pulmonary function tests are recommended if bleomycin is considered.

Cisplatin—it inhibits DNA synthesis and, thus, cell proliferation, by causing DNA cross-links and denaturation of the double helix. Cisplatin is excreted by kidneys; those with impaired renal function should postpone therapy.

Carboplatin—carboplatin is an analog of cisplatin. Carboplatin has the same efficacy as cisplatin but with a better toxicity profile. Its main advantages over cisplatin include less nephrotoxicity and ototoxicity not requiring extensive pre-hydration and less likelihood of inducing nausea and vomiting, but it is more likely to induce myelotoxicity.

Etoposide—etoposide inhibits topoisomerase II and causes DNA strand breakage, causing cell proliferation to arrest in the late S or early G2 portion of the cell cycle.

BEP therapy: bleomycin 30 units/week IV on days 1, 8, and 15 plus etoposide 100 mg/m²/day IV and cisplatin 20 mg/m²/day IV on days 1 to 5. BEP is given every 21 days for three cycles (or four cycles if the patient had bulky residual disease after surgery).

In women with recurrence, confirmed residual disease, or raised tumor markers after first-line chemotherapy, recommended treatment consists of paclitaxel-ifosfamide-cisplatin (TIP) or another acceptable regimen. TIP is given as follows: paclitaxel 250 mg/m² IV infused over 24 h on day 1 plus ifosfamide 1500 mg/m²/day IV and cisplatin 25 mg/m²/day IV on days 2 to 6. TIP is given every 21 days for four cycles [42].

6.9.1.1. Complications of chemotherapy

The most common medical complications from chemotherapy are bone marrow abnormalities and renal toxicity. Care should be taken to monitor for signs of pulmonary toxicity in patients receiving bleomycin-containing regimens. Secondary malignancies are rare, but leukemias may occur in patients receiving etoposide, especially if doses exceed 2000 mg/m² (i.e., >4 cycles of standard BEP (bleomycin, etoposide, platinum) regimen. BEP treatment has been associated with ventriculomegaly, transient neonatal neutropenia and bilateral sensorineural hearing loss in few cases [43].

6.9.2. Radiation

Loss of fertility is a problem with radiation. Primary therapy with radiation is reserved for patients who are incapable of tolerating chemotherapy or surgical resection. It can be used in stage IB to stage III. Radiation is mostly used to treat periaortic and pelvic lymph node metastases [44].

6.10. Follow up

Recurrence of dysgerminomas is most often seen in the first 2–3 years after treatment. Therefore, follow-up observation and a physical examination every 3–4 months for the first 3 years, every 6 months during the fourth and fifth years, and annual surveillance thereafter is recommended [44].

CT imaging should be considered during months 6 and 12, especially if tumor markers were negative at the time of diagnosis [44].

Patients should be observed for up to 10 years, for late recurrences, although they are rare.

6.11. Prognosis

- The prognosis of OGCT is excellent, as most cases are benign. When malignant they are very aggressive, but the prognosis is still good provided it is treated without delay with combination chemotherapy [8].
- Most patients with mature teratomas show long survival times.
- The prognosis of immature teratomas is governed by grade and stage. Stage 1, grade 1 have 100% survival rate, whereas stage III, grade 1 have only a 50% chance of survival.
- The survival rates for dysgerminomas presenting at early and advanced stages are 95 and >80%, respectively. In dysgerminoma stage 1a tumor after unilateral salpingo-oophorectomy as a fertility preserving surgery has a relapse rate ranging from 10 to 20%; the overall survival rate is 90–100% [45]. Patients who suffer relapses and undergo chemotherapy; the survival rate for such patients is greater than 90%.
- Endodermal sinus tumors of the ovary are particularly aggressive. The survival rates for stage I and II ESTs are reported to be 60–100%, whereas for those with stage III or IV disease the prognosis is less favorable (50–75%).
- Survival rates for embryonal carcinoma are slightly higher than those for ESTs.
- Prognosis is better for gestational choriocarcinoma than nongestational carcinoma.
- For mixed GCT, size and histology are the major factors determining prognosis for patients. Prognosis is poor for patients with large tumors when more than one-third of the tumor is composed of endodermal sinus elements, grade 3 immature teratoma or choriocarcinoma. When the tumor is smaller than 10 cm in diameter, the prognosis is good regardless of the composition of the tumor [46].
- Data from the Surveillance, Epidemiology and End Results program (1978–2010), investigators found a 97%, 5-year cause specific survival in those with ovarian dysgerminoma compared with a 92% for those with nondysgerminoma. Significant prognostic factors included age older than 40 years at diagnosis and metastatic disease. A second cancer occurred in 10% of all patients who survived 10 years and had received radiotherapy compared to 2% of those who had not received radiation treatment [47].

7. Dysgerminoma

The most commonly occurring malignant GCT is dysgerminoma, which accounts for approximately 2% of all ovarian cancers. It is the most common ovarian germ cell tumor coexisting with pregnancy, and constitutes 25–35% of all reported ovarian cancers. Mostly, it is diagnosed at an early stage, when disease is still confined to the ovary.

7.1. Etiology

The exact etiology of dysgerminomas is not identified, though recent molecular studies have implicated loss of function with potential tumor suppressor gene *TRC8/RNF139* as a possible etiology [48]. Cytogenetics reveals 12p abnormalities in 81% of cases [9].

7.2. Pathology

Dysgerminomas are mostly unilateral (15% of dysgerminomas are bilateral), solid, nodular. They have a smooth, bosselated (knobby) external surface, is soft, fleshy, either cream-colored, gray, pink or tan when cut. Hemorrhage and necrosis is common, but less prominent than other malignant tumors.

Histological examination of dysgerminomas show a proliferation of epithelioid cells admixed with mature lymphocytes arranged in sheets or small clusters which are separated by thin, fibrous septae resembling alveoli. The neoplastic cells are large and have moderate to high nucleus-to-cytoplasm ratios. Other features are round nuclei; vesicular chromatin; prominent nucleoli; clear to eosinophilic cytoplasm rich in glycogen and lipid; and distinct cell borders (**Figure 1**) [49].

Multinucleated forms may be present. Mitotic activity may be significant and may vary greatly, even within the same tumor; atypical mitoses may be seen. Noncaseating granulomas, syncytiotrophoblast-like giant cells and germinal center formation are not uncommon. Additionally, foci of hemorrhage, necrosis, and small microcalcifications may also be identified [49, 50].

The neoplastic cells of dysgerminomas express placental alkaline phosphatase (PLAP), CD117 (*c-kit*), OCT 3/4, SALL4, and, variably, cytokeratin [49]. Positive stain for OCT4 (strong nuclear staining) in 90%+ cells is seen.

They do not express epithelial membrane antigen (EMA), S100 protein, CD45 (LCA), or alpha-fetoprotein (AFP) [49]. Syncytiotrophoblast-like giant cells are the source of beta-hCG production. A negative stain for CK7, CK20, HMW keratin, CD30 and vimentin is also found [51].

7.3. Imaging in dysgerminomas

In dysgerminoma, characteristic imaging findings include multilobulated solid masses with prominent fibrovascular septa. The anechoic, low-signal-intensity, or low-attenuation

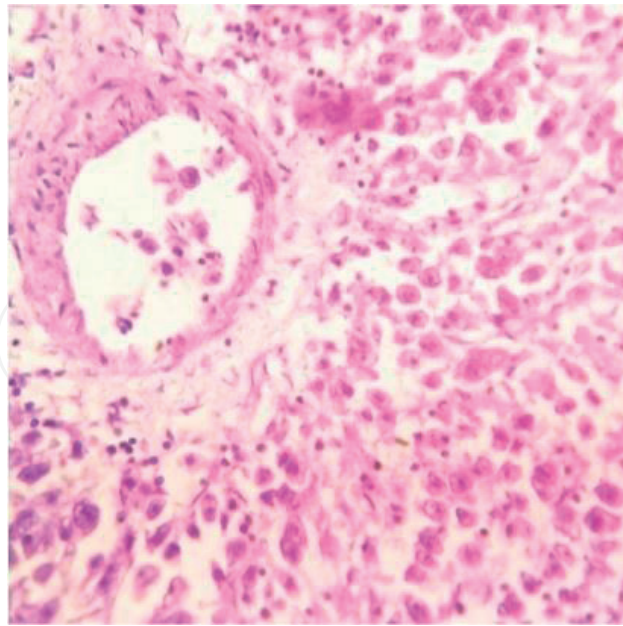


Figure 1. Dysgerminoma: Microsection showing tumor cells with vesicular nuclei. Fibrous septa showing lymphocytic infiltrate (400×, H&E stain). (With permission from [21]).

area of the tumor represents necrosis and hemorrhage. Lobules are richly vascularized at color/power Doppler examination which show prominent arterial flow within the fibrovascular septa with a resistive index value ranging from 0.44 to 0.70 [52]. On MRI, dysgerminomas are often seen divided into lobules by septa. Reported signal characteristics are hypointense or isointense septae on T2 weighted images. In T1 C+ (Gd) weighted images, the septae often show marked enhancement.

8. Teratoma

They represent 20% of all ovarian tumors, 75%, occur in first two decades of life, 12–15% are bilateral and 60–70% are diagnosed in stage 1.

Teratomas range from benign, well-differentiated (mature) cystic lesions to those that are solid and malignant (immature). Additionally, teratomas may be monodermal and highly specialized (struma ovarii, carcinoid). Rarely, in some mature teratomas containing certain elements (most commonly squamous components) undergo malignant transformation.

8.1. Mature cystic teratoma

Ovarian mature cystic teratomas, also called dermoid cysts, are the most common germ cell tumor, accounting for up to 70% of benign ovarian masses in the reproductive years and 20% in postmenopausal women [53, 54]. They maintain rather orderly arrangements, with well-differentiated ectodermal and mesodermal tissues surrounding endodermal components, resembling any tissue of the body. Examples include hair, teeth, fat, skin, muscle, and endocrine tissue (**Figure 2**).

Monodermal teratoma comprise of mainly one tissue element. For example, the most common type of monodermal teratoma, Struma ovarii, is comprised of at least 50% mature thyroid tissue (**Figures 3** and **4**). Argentaffin cells in dermoid cysts are usually the site of origin for ovarian carcinoid tumor, although this is rare (**Figure 5**).

Tumor markers-Mature teratomas rarely produce alpha feto protein and CA125. Elevated AFP and HCG levels may be indicative of malignancy.

8.1.1. Imaging

In mature cystic teratoma, transvaginal ultrasound scan (TVS) has 85–98% accuracy [55, 56]. Sonographic features includes: diffusely or partially echogenic mass with posterior sound attenuation owing to sebaceous material and hair within the cyst cavity, an echogenic interface at the edge of mass that obscures deep structures: the tip of the iceberg sign, mural hyperechoic Rokitansky nodule: dermoid plug, echogenic shadowing, calcific or dental

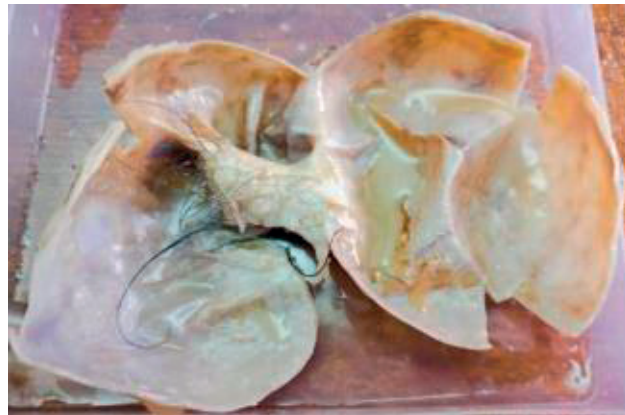

Figure 2. Dermoid cyst: cut section of dermoid cyst of ovary showing hairs and pultaceous material.

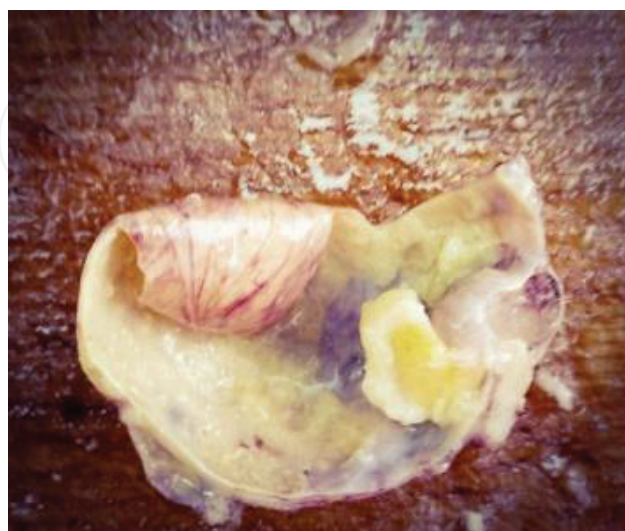

Figure 3. Struma ovarii: cut section of ovary containing pultaceous material along with gray white nodule measuring 2.5 × 2 cm.

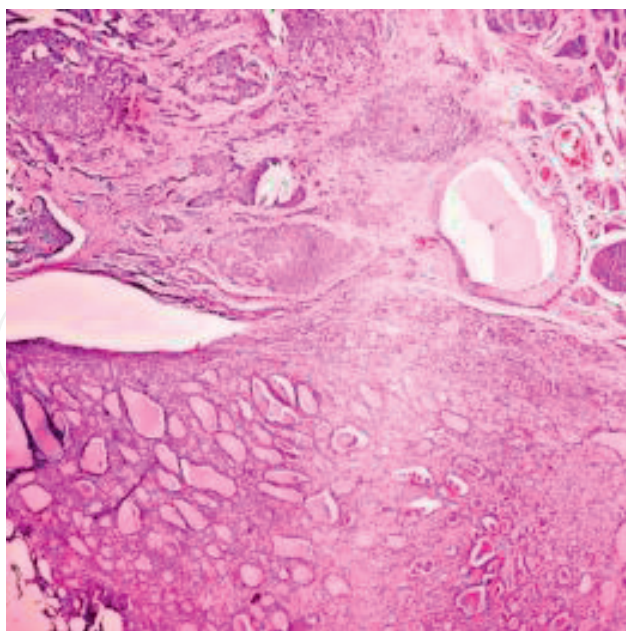


Figure 4. Struma ovarii: microsection showing thyroid tubules containing colloid in lower part of image. Upper part shows carcinoid element in which tumor cells are arranged in nests (4× H&E).

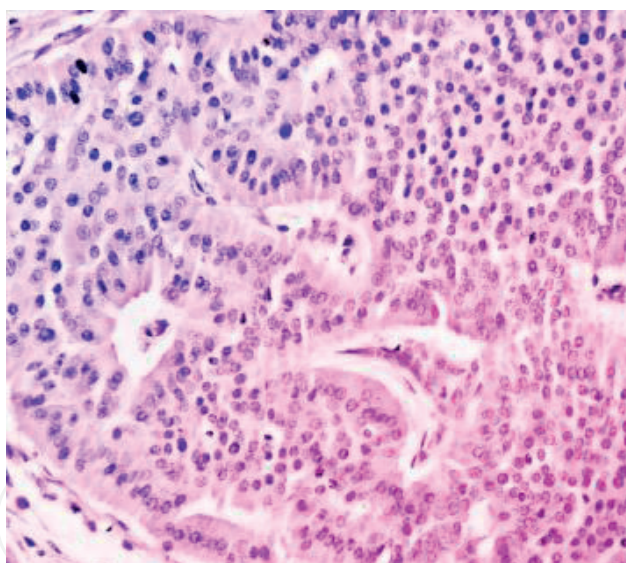


Figure 5. Carcinoid tumor: cells arranged in parallel ribbon like manner. Nuclei have characteristic salt and pepper like chromatin (40× H&E).

(tooth) components, the presence of fluid levels, multiple thin echogenic bands caused by the hair in the cyst cavity: the dot-dash pattern. In color Doppler, no internal vascularity is seen [57].

Further workup is required if internal vascularity is found to exclude a malignant lesion. When ruptured, the characteristic hypoattenuating fatty fluid can be found in antidependant pockets, typically below the right hemidiaphragm, a pathognomonic finding [58].

MR imaging is reported to have 99% accuracy. The sebaceous component of dermoid cysts has very high signal intensity on T1-weighted images similar to that of retroperitoneal fat. The signal intensity of the sebaceous component on T2-weighted images is variable, usually near that of fat [59].

8.1.2. Histology

Cyst cavity is often lined with keratinized squamous epithelium and usually contains abundant sebaceous and sweat glands (**Figure 6**). There is usually a raised protuberance projecting into the cyst cavity known as the Rokitansky nodule. Most of the hair typically arises from this protuberance. When bone or teeth are present, they tend to be located within this nodule. Occasionally, the cyst wall is lined with bronchial or gastrointestinal epithelium. Foreign body giant cell reactions may be seen in various parts of the tumor and may, in the case of intraperitoneal teratomas, lead to formation of extensive adhesions if the tumor contents are spilled. Ectodermal tissue may include brain, glia, neural tissue, retina, choroids, and ganglia. Mesodermal tissue is represented by bone, cartilage, smooth muscle, and fibrous tissue (**Figure 7**) [60].

8.1.3. Complications in teratoma

Torsion is the most significant cause of morbidity, occurring in 3–11% of cases [61, 62]. Rupture may occur suddenly in 2.5% [63] leading to shock or hemorrhage with acute chemical peritonitis. Chronic leakage also may occur, with resultant granulomatous peritonitis. Infection is uncommon and occurs in less than 1–2% of cases [63].

Malignant transformation: seen in 1–2%, usually into squamous cell carcinoma [64, 65].

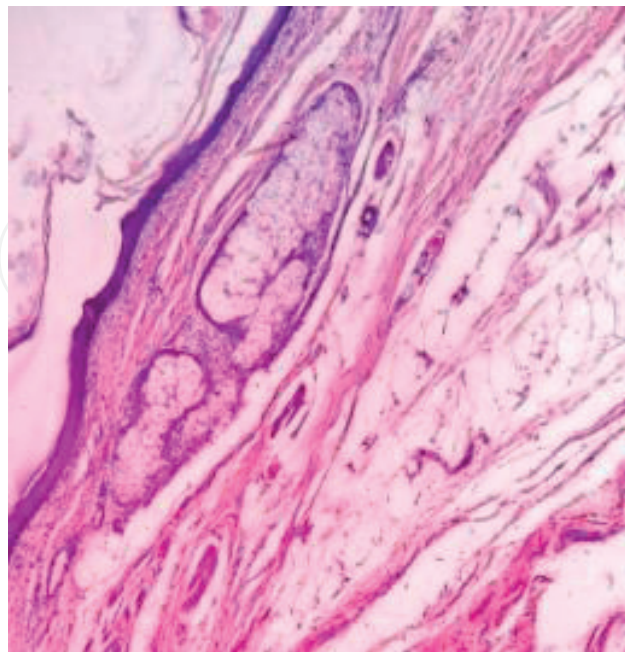


Figure 6. Mature cystic teratoma: microsection showing cystic lining with underlying sebaceous glands (40× H&E).

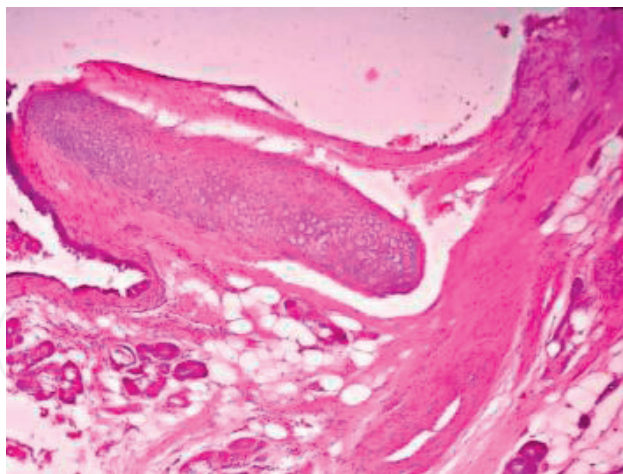


Figure 7. Dermoid cyst: microsection showing cartilaginous element (10× H&E).

In less than 1% autoimmune hemolytic anemia has been associated with mature cystic teratomas [66, 67]. Recently recognized encephalitis associated with antibodies against the *N*-methyl-D-aspartate receptor (NMDAR) is associated with ovarian mature teratomas. Substantial recovery is usually seen with tumor resection and immunotherapy [68].

8.1.4. Treatment

Mature ovarian teratomas are slow growing (1–2 mm a year) and, therefore, some advocate non-surgical management. Larger lesions are often surgically removed. Many recommend annual follow-up for lesions <7 cm to monitor growth, beyond which resection is advised. Mature cystic teratomas of the ovaries may be removed by simple cystectomy rather than salpingo-oophorectomy.

Although malignant degeneration is quite rare, the cyst should be removed in its entirety, and if immature elements are found, the patient should undergo a standard staging procedure.

Spillage is associated with increased risk of chemical peritonitis (estimated incidence of 0.2%) and increased risk of adhesion formation. The risks of recurrence (4%), as well as malignant degeneration (0.2–2%), should be discussed.

8.2. Immature teratoma

Immature cystic teratomas are rare (<3%) and usually occur in the postmenopausal age group [69]. Teratomas, specifically solid teratomas, are essentially devoid of organization. Immature teratomas account for approximately 20% of all malignant GCT. Immature teratomas are solid tumors containing immature or embryonal tissues (**Figure 8**). It is found either in pure form or as a component of a mixed germ cell tumor.

Immature neuroepithelium is the predominant immature tissue found. Grade is based upon the proportion of tissue containing immature neural elements and is considered an important prognostic factor that predicts extra ovarian spread and overall survival. They are classified as Grade I, II, or III if they have 0 or 1, 3 or less, or 4 or more low-power fields (x-40) containing immature neuroepithelium per slide, respectively [50].

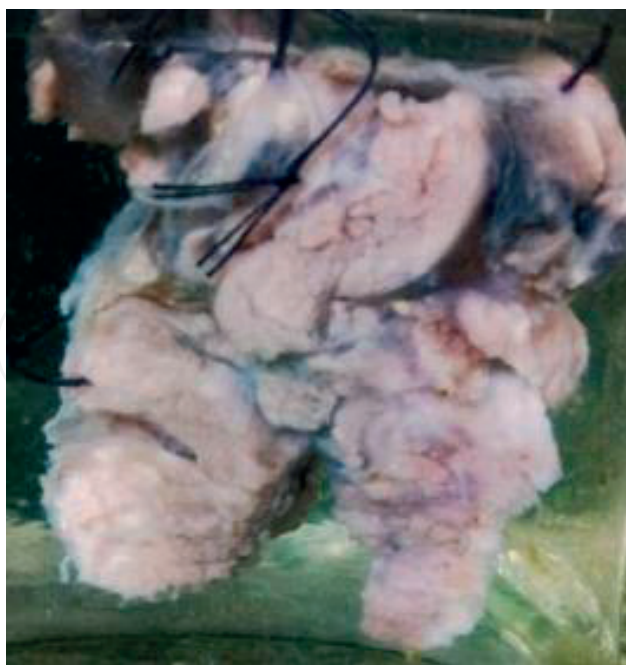

Figure 8. Immature teratoma of ovary: Irregular, partially encapsulated, solid tumor measuring $9 \times 6 \times 4$ cm. Cut surface is grayish white with areas of hemorrhage and foci of necrosis.

8.2.1. *Imaging*

Immature teratomas have prominent solid components and may demonstrate internal necrosis or hemorrhage. Mature tissue elements similar to those seen in mature cystic teratoma are invariably present. Radiologic examination reveals a large, complex mass with cystic, solid components, and scattered calcifications; in contrast, calcification in mature teratomas is localized to mural nodules. Small foci of fat are also seen in immature teratomas. These tumors grow rapidly and frequently demonstrate perforation of the capsule. The tumor capsule is not always well defined.

8.2.2. *Management of immature teratoma*

Fertility-sparing surgery should be offered when detected during pregnancy with surgical staging. Thus unilateral salpingo-oophorectomy with preservation of contralateral ovary with uterus is the appropriate treatment in most cases. If metastatic disease is found during surgery, cytoreductive surgery is recommended. Stage 1a/G1 does not require adjunct treatment and can be observed. Chemotherapy is recommended when extra-ovarian disease exists, stage I grade 2–3. BEP is the most commonly used combination every 3 weeks for 3–4 courses.

8.2.3. *Prognosis*

The prognosis of immature teratomas is governed by grade and stage. Cases of grade 1 in stage I might have up to a 94% survival rate, whereas cases of grade 2 or 3 in stage I might drop to an 82% chance of survival. Grade also contributes to the recurrence rate, with higher grades having a higher recurrence rate [70, 71].

9. Endodermal sinus tumor or yolk sac tumor

Endodermal sinus tumor (EST), also known as yolk sac tumor, is a rare malignant ovarian tumor that usually occurs in the second decade of life. The tumor manifests as a large, complex pelvic mass that extends into the abdomen and contains both solid and cystic components. The cystic areas are composed of epithelial line cysts produced by the tumor or of co-existing mature teratomas. These tumors grow rapidly and have a poor prognosis. Affected patients have an elevated serum α -fetoprotein level, alpha 1 antitrypsin.

Gross examination of EST demonstrates smooth, glistening, hemorrhagic, and necrotic surfaces. Histology reveals a wide range of patterns (microcystic endodermal sinus, solid, alveolar-glandular, papillary, macrocystic, hepatoid, and primitive endodermal). On microscopic examination, it contains Schiller-Duval bodies (central capillary surrounded by simple papillae) and eosinophilic globules containing AFP (**Figure 9**). Intracellular and extracellular hyaline droplets (periodic acid-Schiff positive) are also seen in EST.

When diagnosed during pregnancy, it is often possible to continue the pregnancy after surgical staging and tumor debulking. For metastatic disease, the principles of cytoreductive surgery also apply, and the goal is the resection of all lesions to a minimal residual volume.

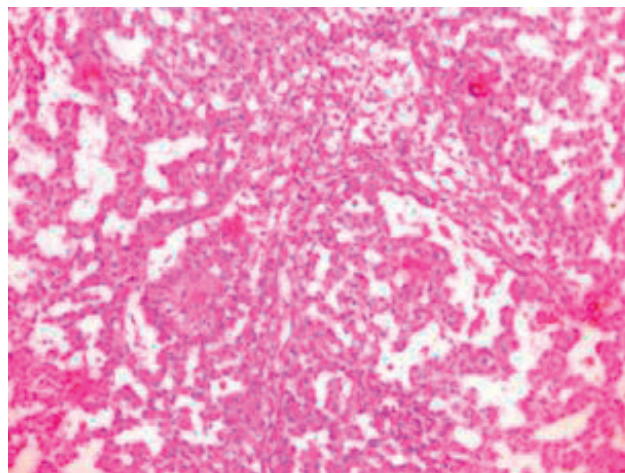


Figure 9. Yolk sac tumor: microsection showing Schiller-Duval bodies (40× H&E).

10. Non-gestational choriocarcinoma

In reproductive age group, the symptoms could resemble pregnancy with amenorrhoea and positive urine pregnancy test. The predominant presenting symptoms are lower abdominal pain, genital bleeding, amenorrhea, nausea and vomiting because of high levels of hCG. Choriocarcinoma is often diagnosed by finding an elevated hCG level in association with metastatic lesion detected radiographically. The levels of serum/urine beta hCG are good tumor marker for the progression or remission of disease. Paternal contribution present in the genome of the tumor is necessary to differentiate gestational from nongestational

tumors. Serum $\beta 2$ microglobulin may be used as a marker for non-gestational choriocarcinoma, though the cause of $\beta 2$ microglobulin expression in non-gestational choriocarcinoma is unknown [72].

11. Pure embryonal carcinoma

It is rare in the ovary, may secrete estrogen, with patient exhibiting symptoms and signs of precocious puberty or irregular vaginal bleeding. Embryonal cell carcinoma has more nuclear hyperchromasia and nuclear pleomorphism, amphophilic cytoplasm, high mitotic index, and necrosis. Often, a glandular or papillary architecture is present. The cells of embryonal carcinoma express CD30 and cytokeratin (strong, diffuse), whereas those of dysgerminoma do not.

12. Mixed germ cell tumors

These are rare germ cell tumors. A mixture of dysgerminoma and endodermal sinus tumor is the most common combination accounting for one-third of mixed germ cell tumors [73]. Combination of embryonal carcinoma and choriocarcinoma is very rare. The prognosis of patients with a mixed MGCT usually reflects that of its most malignant component. Therefore, it is important to sample these tumors extensively, particularly areas with different gross appearance. One section per every centimeter in tumor diameter is recommended [74].

Acknowledgements

We acknowledge the contribution made by Dr. Namrata, Head of Pathology Deptt. Hindu Rao Hospital & NDMC Medical College for providing photographs for Figures 2-9.

Author details

Mamta Gupta* and Vandana Saini

*Address all correspondence to: hodgynaehrh@gmail.com

Hindu Rao Hospital & NDMC Medical College, New Delhi, India

References

- [1] De Felici M 2013 Origin, migration, and proliferation of human primordial germ cells. In: Coticchio G, Albertini DF, De Santis L (eds) Oogenesis. London: Springer; Ch. 2. pp. 19-37. DOI 10.1007/978-0-85729-826-3_2

- [2] Schmoll HJ. Extragenadal germ cell tumors. *Annals of Oncology*. 2002;**13**(Suppl. 14):265-272
- [3] Low JJH, Ilancheran A, Joseph SN. Malignant ovarian germ cell tumors. *Best Practice and Research. Clinical Obstetrics & Gynaecology*. 2012;**26**(3):347-355
- [4] Smith HO, Berwick M, Verschraegen CF, Wiggins C, Lansing L, Muller CY, et al. Incidence and survival rates for female malignant germ cell tumors. *Obstetrics and Gynecology*. 2006;**107**(5):1075-1085
- [5] Arora RS, Alston RD, Eden TO, Geraci M, Birch JM. Comparative incidence patterns and trends of gonadal and extragonadal germ cell tumors in England between 1979-2003. *Cancer*. 2012;**118**(17):4290-4297
- [6] Abuzaid A, Nazer A, Alomar O, Azzam A, Al-Eid HS, Elhassan, TA et al. Incidence of Malignant Germ Cell Tumors (MOGCTs) in Saudi Arabia. *Hematology/Oncology & Stem Cell Therapy*. 2014;**7**(1):41-43
- [7] Lee-Jones L. Ovary: Germ Cell Tumors. *Atlas of Genetics and Cytogenetics in Oncology and Haematology*. 2003-2008;**7**(4):282-288. <http://atlasgeneticsoncology.org/Tumors/OvarianGermCellID5067.html>
- [8] Nogales F, Talerman A, Kubik-Huch RA, Tavassoli FA, Devouassoux-Shisheboran M. Germ cell tumours. In: Tavassoli FA, Deville P, editors. *World Health Organization Classification of Tumours: Pathology and Genetics of Tumours of the Breast and Female Genital Organs*. Lyon, France: IARC Press; 2003. pp. 163-175
- [9] Cossu-Rocca P, Zhang S, Roth LM, Eble JN, Zheng W, Karim FW, et al. Chromosome 12p abnormalities in dysgerminoma of the ovary: A FISH analysis. *Modern Pathology*. 2006;**19**(4):611-615
- [10] Kawauchi S, Liu XP, Kawasaki K, Hirakawa T, Amada S, Furuya T, et al. Significance of beta-catenin and pRB pathway components in malignant ovarian germ cell tumours: INK4A promoter CpG island methylation is associated with cell proliferation. *The Journal of Pathology*. 2004;**204**(3):268-276
- [11] Giambartolomei C, Mueller CM, Greene MH, Korde LAA. Mini-review of familial ovarian germ cell tumors: An additional manifestation of the familial testicular germ cell tumor syndrome. *Cancer Epidemiology*. 2009;**33**(1):31-36
- [12] Kraggerud SM, Hoei-Hansen CE, Alagaratnam S, Skotheim RI, Abeler VM, Rajpert-De Meyts E, et al. Molecular characteristics of malignant ovarian germ cell tumors and comparison with testicular counterparts: Implications for pathogenesis. *Endocrine Reviews*. 2013;**34**(3):339-376
- [13] Cyriac S, Rajendranath R, Louis AR, Sagar TG. Familial germ cell tumor. *Indian Journal of Human Genetics*. 2012;**18**(1):119-121
- [14] Prat J. FIGO committee on gynecologic oncology. FIGO's staging classification for cancer of ovary, fallopian tube and peritoneum: A bridged publication. *Journal of Gynecologic Oncology*. 2015;**26**(2):87-89

- [15] Sayedur Rahman M, Al-Sibai MH, Rahman J. Ovarian carcinoma associate with pregnancy. A review of 9 cases. *Acta Obstetricia et Gynecologica Scandinavica*. 2002;**81**:260-264
- [16] Zhao XY, Huang HF, Lian LJ, Lang JH. Ovarian cancer in pregnancy: A clinicopathologic analysis of 22 cases and review of the literature. *International Journal of Gynecological Cancer*. 2006;**16**:8-15
- [17] Agarwal N, Parul, Kriplani A, Bhatla N, Gupta A. Management and outcome of pregnancies complicated with adnexal masses. *Archives of Gynecology and Obstetrics*. 2003;**267**(3):148-152
- [18] Hopkins MP, Duchon MA. Adnexal surgery in pregnancy. *The Journal of Reproductive Medicine*. 1986;**31**:1035-1037
- [19] Sunanda N, Akhila MV. Ovarian tumours associated with pregnancy: A five year retrospective study in a tertiary care hospital. *International Journal of Reproduction, Contraception, Obstetrics and Gynecology*. 2015;**4**(6):1965-1969
- [20] Nick AM, Schmeler K. Adnexal masses in pregnancy. *Perinatology*. 2010;**2**:13-21
- [21] Gupta M, Jindal R, Saini V. An incidental finding of bilateral dysgerminoma during cesarean section: Dilemmas in management. *Journal of Clinical and Diagnostic Research*. 2016;**10**(8):QD04-QD05
- [22] Jain M, Budhwani C, Jain AK, Hazari RA. Pregnancy with ovarian dysgerminoma: An unusual diagnosis. *Journal of Dental and Medical Sciences*. 2013;**11**(5):53-57
- [23] Hussain F. In: Huh WK, editor. *Gynecologic Tumor Markers Overview*. Medscape; 2015
- [24] Kawai M, Kano T, Kikkawa F, Morikawa Y, Oguchi H, Nakashima N, et al. Seven tumor markers in benign and malignant germ cell tumors of the ovary. *Gynecologic Oncology*. 1992;**45**(3):248-253
- [25] Behtash N, Karimi Zarchi M, Modares Gilani M, Ghaemmaghami F, Mousavi A, Ghotbizadeh F. Ovarian carcinoma associated with pregnancy: A clinicopathologic analysis of 23 cases and review of the literature. *BMC Pregnancy and Childbirth*. 2008;**20**(8):3. DOI: 10.1186/1471-2393-8-3
- [26] Chiou SY, Lev-Toaff AS, Masuda E, Feld RI, Bergin D. Adnexal torsion: New clinical and imaging observations by sonography, computed tomography, and magnetic resonance imaging. *Journal of Ultrasound in Medicine*. 2007;**26**(10):1289-1301 PMID: 17901133
- [27] Yen CF, Lin SL, Murk W, Wang CJ, Lee CL, Soong YK, et al. Risk analysis of torsion and malignancy for adnexal masses during pregnancy. *Fertility and Sterility*. 2009;**91**(5):1895-1902
- [28] Karlen JR, Akbari A, Cook WA. Dysgerminoma associated with pregnancy. *Obstetrics and Gynecology*. 1979;**53**(3):330-335
- [29] Zanetta G, Mariani E, Lissoni A, Ceruti P, Trio D, Strobelt N, Mariani S. A Prospective study of the role of ultrasound in the management of adnexal masses in pregnancy. *BJOG: An International Journal of Obstetrics & Gynaecology*. 2003;**110**(6):578-583

- [30] Bernhard LM, Klebba PK, Gray DL, Mutch DG. Predictors of persistence of adnexal masses in pregnancy. *Obstetrics and Gynecology*. 1999;**93**(4):585-589
- [31] Schmeler KM, Mayo-Smith WW, Peipert JF, Weitzen S, Manuel MD, Gordinier ME. Adnexal masses in pregnancy: Surgery compared with observation. *Obstetrics and Gynecology*. 2005;**105**(5 Pt 1):1098-1103
- [32] Kwon YS, Mok JE, Lim KT, Lee IH, Kim TJ, Lee KH, Shim JU. Ovarian cancer during pregnancy: Clinical and pregnancy outcome. *Journal of Korean Medical Science*. 2010;**25**(2):230-234
- [33] Horowitz NS. Management of adnexal masses in pregnancy. *Clinical Obstetrics and Gynecology*. 2011;**54**(4):519-527
- [34] Zanotti KS, Belinson JL, Kennedy AW. Treatment of gynecologic cancers in pregnancy. *Seminars in Oncology*. 2000;**27**:686-698
- [35] Partridge EE, Phillips JL, Menck HR. The National Cancer Data Base report on ovarian cancer treatment in United States hospitals. *Cancer*. 1996;**78**:2236-2246
- [36] Cavaco-Gomes J, Moreira CJ, Rocha A, Mota R, Paiva V, Costa A. Investigation and management of adnexal masses in pregnancy. *Scientifica*. 2016;**2016**:3012802. DOI: 10.1155/2016/3012802
- [37] Wang PH, Chang WH, Cheng MH, Horng HC. Management of adnexal masses during pregnancy. *The Journal of Obstetrics and Gynaecology Research*. 2009;**35**(3):597-598
- [38] Whitecar MP, Turner S, Higby MK. Adnexal masses in pregnancy: A review of 130 cases undergoing surgical management. *American Journal of Obstetrics and Gynecology*. 1999;**181**:19-24
- [39] Usui R, Minakami H, Kosuge S, Iwasaki R, Ohwada M, Sato I. A retrospective survey of clinical, pathologic, and prognostic features of adnexal masses operated on during pregnancy. *The Journal of Obstetrics and Gynaecology Research*. 2000;**26**(2):89-93
- [40] Mazze RI, Kallén B. Reproductive outcome after anesthesia and operation during pregnancy: A registry study of 5405 cases. *American Journal of Obstetrics and Gynecology*. 1989;**161**(5):1178-1185
- [41] Williams S, Blessing JA, Liao SY, Ball H, Hanjani P. Adjuvant therapy of ovarian germ cell tumors with cisplatin, etoposide, and bleomycin: a trial of the Gynecologic Oncology Group. *Journal of Clinical Oncology*. 1994 Apr;**12**(4):701-706
- [42] Jewell EL. Germ Cell Tumor Treatment Protocols. In: Sonoda Y, editor. Medscape; 2015. Available at: <https://emedicine.medscape.com/article/2156882-overview>
- [43] Hasdemir PS, Guvenal T, Meneske S, Solmaz U, Kandiloglu AR, Koyuncu FM, et al. Ovarian immature teratoma detected during pregnancy. *Medical Science and Discovery*. 2016;**3**(1):1-6
- [44] Michener CM, Wu AY. Ovarian Dysgerminomas Follow-Up. In: Huh WK, editor. Medscape; 2015. Available at: <https://emedicine.medscape.com/article/253701-followup>

- [45] Pectasides D, Pectasides E, Kassanos D. Germ cell tumors of the ovary. *Cancer Treatment Reviews*. 2008;**34**(5):427-441
- [46] Murugaesu N, Schmid P, Dancey G, et al. Malignant ovarian germ cell tumors: Identification of novel prognostic markers and long-term outcome after multimodality treatment. *Journal of Clinical Oncology*. 2006;**24**(30):4862-4866
- [47] Solheim O, Gershenson DM, Trope CG, Rokkones E, Sun CC, Weedon-Fekjaer H, et al. Prognostic factors in malignant ovarian germ cell tumours (the surveillance, epidemiology and end results experience 1978-2010). *European Journal of Cancer*. 2014;**50**(11):1942-1950
- [48] Gimelli S, Beri S, Drabkin HA, Gambini C, Gregorio A, Fiorio P, et al. The tumor suppressor gene TRC8/RNF139 is disrupted by a constitutional balanced translocation t(8;22)(q24.13;q11.21) in a young girl with dysgerminoma. *Molecular Cancer*. 2009;**8**:52
- [49] Hazard FKG. Ovarian Dysgerminomas Pathology Overview of Ovarian Dysgerminomas. Masand R. Medscape; 2015 available at <https://emedicine.medscape.com/article/1951026-overview>
- [50] Sharma I, Chaliha T. Histopathological patterns of germ cell tumours of ovary in a tertiary level hospital. *International Journal of Pharmaceutical Science Inventions*. 2014;**3**(10):14-24
- [51] Ehdaivand S. Ovary Tumor, Germ Cell Tumors, Dysgerminoma. 2016. Pathology outlines.com
- [52] Kim HS, Kang BS. Ovarian dysgerminoma: Color Doppler ultrasonographic findings and comparison with CT and MR imaging findings. *Journal of Ultrasound in Medicine*. 1995;**14**:843-848
- [53] Pfeifer SM, Gosman GG. Evaluation of adnexal masses in adolescents. *Pediatric Clinics of North America*. 1999;**46**(3):573-592
- [54] Canis M, Mage G, Pouly JL, Wattiez A, Manhes H, Bruhat MA. Laparoscopic diagnosis of adnexal cystic masses: A 12-year experience with long-term follow-up. *Obstetrics & Gynecology*. 1994;**83**(5):707-712 Part 1
- [55] Mais V, Guerriero S, Ajossa S, Angiolucci M, Paoletti AM, Melis GB. Transvaginal ultrasonography in the diagnosis of cystic teratoma. *Obstetrics and Gynecology*. 1995;**85**(1):48-52
- [56] Patel MD, Feldstein VA, Lipson SD, Chen DC, Filly RA. Cystic teratomas of the ovary: Diagnostic value of sonography. *AJR. American Journal of Roentgenology*. 1998;**171**:1061-1065
- [57] Kite L, Uppal T. Ultrasound of ovarian dermoids—Sonographic findings of a dermoid cyst in a 41-year-old woman with an elevated serum hCG. *Australasian Journal of Ultrasound in Medicine*. 2011;**14**(3):19-21
- [58] Fibus TF. Intraperitoneal rupture of a benign cystic ovarian teratoma: Findings at CT and MR imaging. *AJR. American Journal of Roentgenology*. 2000;**174**(1):261-262
- [59] Scoutt LM, McCarthy SM, Lange R, Bourque A, Schwartz PE. MR evaluation of clinically suspected adnexal masses. *Journal of Computer Assisted Tomography*. 1994;**18**(4):609-618

- [60] Talerman A. Germ cell tumors of the ovary. In: Kurman RJ, editor. *Blaustein's Pathology of the Female Genital Tract*. 5th ed. New York, NY: Springer-Verlag; 2002 Chap. 20
- [61] Comerci JT Jr, Licciardi F, Bergh PA, Gregori C, Breen JL. Mature cystic teratoma: a clinicopathologic evaluation of 517 cases and review of the literature. *Obstetrics and Gynecology*. 1994;**84**(1):22-28
- [62] Benjapibal M, Boriboonhirunsarn D, Suphanit I, Sangkarat S. Benign cystic teratoma of the ovary: A review of 608 patients. *Journal of The Medical Association of Thailand*. 2000;**83**(9):1016-1020
- [63] Ayhan A, Bukulmez O, Genc C, Karamursel BS, Ayhan A. Mature cystic teratomas of the ovary: Case series from one institution over 34 years. *European Journal of Obstetrics, Gynecology, and Reproductive Biology*. 2000;**88**(2):153-157
- [64] Hosokawa T, Sato Y, Seki T, Maebara M, Ito K, Kuribayashi S. Malignant transformation of a mature cystic teratoma of the ovary with rupture. *Japanese Journal of Radiology*. 2010;**28**(5):372-375
- [65] Dos Santos L, Mok E, Iasonos A, et al. Squamous cell carcinoma arising in mature cystic teratoma of the ovary: A case series and review of the literature. *Gynecologic Oncology*. 2007;**105**(2):321-324
- [66] Buchwalter CL, Miller D, Jenison EL. Hemolytic anemia and benign pelvic tumors. A case report. *The Journal of Reproductive Medicine*. 2001;**46**(4):401-404
- [67] Kim I, Lee JY, Kwon JH, et al. A case of autoimmune hemolytic anemia associated with an ovarian teratoma. *Journal of Korean Medical Science*. 2006;**21**(2):365-367
- [68] Dalmau J, Lancaster E, Martinez-Hernandez E, Rosenfeld MR, Balice-Gordon R. Clinical experience and laboratory investigations in patients with anti-NMDAR encephalitis. *Lancet Neurology*. 2011;**10**(1):63-74
- [69] Christopherson WA, Councell RB. Malignant degeneration of amatureovarian teratoma. *International Journal of Gynecology & Obstetrics*. 1989;**30**(4):379-384
- [70] O'Connor DM, Norris HJ. The influence of grade on the outcome of stage I ovarian immature (malignant) teratomas and the reproducibility of grading. *International Journal of Gynecological Pathology*. 1994;**13**:283-289
- [71] Norris HJ, Zirkin HJ, Benson WL. Immature (malignant) teratoma of the ovary: A clinical and pathologic study of 58 cases. *Cancer*. 1976;**37**:2359-2372
- [72] Hayashi S, Abe Y, Tomita S, Nakanishi Y, Miwa S, Nakajima T, et al. Primary non-gestational pure choriocarcinoma arising in the ovary: A case report and literature review. *Oncology Letters*. 2015;**9**(5):2109-2111
- [73] Kurman RJ, Norris HJ. Embryonal carcinoma of the ovary: A clinicopathological entity distinct from endodermal sinus tumour resembling embryonal carcinoma of adult testes. *Cancer*. 1976;**38**(6):2420-2433
- [74] Prat J. Ovarian Germ Cell Tumors in *Pathology of the Female Reproductive Tract*. 2015. <https://clinicalgate.com/ovarian-germ-cell-tumors/>