

# We are IntechOpen, the world's leading publisher of Open Access books Built by scientists, for scientists

6,900

Open access books available

186,000

International authors and editors

200M

Downloads

Our authors are among the

154

Countries delivered to

TOP 1%

most cited scientists

12.2%

Contributors from top 500 universities



WEB OF SCIENCE™

Selection of our books indexed in the Book Citation Index  
in Web of Science™ Core Collection (BKCI)

Interested in publishing with us?  
Contact [book.department@intechopen.com](mailto:book.department@intechopen.com)

Numbers displayed above are based on latest data collected.  
For more information visit [www.intechopen.com](http://www.intechopen.com)



---

# Thoracic Anomalies

---

Cringu Ionescu

Additional information is available at the end of the chapter

<http://dx.doi.org/10.5772/intechopen.71959>

---

## Abstract

The antenatal and postnatal prognosis for fetuses with chest noncardiac anomalies varies widely, depending of the type of lesion present. An important issue is to establish an accurate prenatal diagnosis, which allows an appropriate counseling of the couple, fetal karyotyping and eventually in utero fetal therapy, if possible. Also, another important feature is preparation for delivery in a tertiary center or an appropriate perinatal institution, able to provide care to the immediate neonatal consequences in such cases. The ultrasound exam is not only crucial in the diagnosis of such lesions, but also important in the serial antenatal follow up, some of them being progressive, and having the potential to lead to compromise of cardiac function and eventually to fetal death. Thus, the sonographer has an important role in the management of such difficult cases. Currently, perinatal centers provide multidisciplinary teams, with maternal fetal specialists, neonatologists, pediatric surgeons, all involved in counseling parents about the outcome and the management options for a fetus with a diagnosis of thoracic anomalies. Although the precise prenatal diagnosis is often possible, this does not necessarily ensure improvement of the postnatal outcome, due to associated pulmonary hypoplasia.

**Keywords:** thoracic anomalies, congenital cystic adenomatoid malformation (CCAM), bronchopulmonary sequestration (BPS), CCAM-BPS hybrid form, congenital diaphragmatic hernia (CDH), bronchogenic cyst, congenital high airway obstruction syndrome (CHAOS)

---

## 1. Introduction

The thoracic anomalies represent a group of abnormalities that can be found either in the lung parenchyma or mediastinum. The thoracic cavity has a conical shape and is delimited at the posterior level by the sternum, at the superior level by the clavicle, at the lower level by the diaphragm, and at the lateral level by the ribs. In the thorax, the organs that are examined by the

ultrasound are: the lungs, the heart and the mediastinum. The thoracic anomalies chapter refers to pulmonary and mediastinal fetal abnormalities, the cardiac abnormalities being a separate chapter. Congenital bronchopulmonary malformation comprises a group of abnormalities that are represented by the following entities: congenital cystic adenomatoid malformation (CCAM), bronchopulmonary sequestration (BPS), CCAM-BPS hybrid form, congenital diaphragmatic hernia (CDH), bronchogenic cyst, congenital high airway obstruction syndrome (CHAOS) and pulmonary hypoplasia/aplasia. Currently, it is recommended for the term bronchopulmonary anomalies to be used instead of congenital cystic adenomatoid malformation (CCAM) or bronchopulmonary sequestration (BPS), because it includes better the diagnosis given by the ultrasound, the prognosis and the therapeutic attitude. However, for teaching purposes, we will continue to keep the separate terms for each entity in part. The thoracic-pulmonary anomalies incidence is the following: CCAM—BPS around 40%, CDH around 40% and hydrothorax and other anomalies around 10% [1, 2].

The ultrasound investigation of the thorax is based on emphasizing of the following parameters:

- The size and shape of the rib cage,
- The aspect of the ribs, the pulmonary echogenicity,
- The mediastinal shift absence/presence,
- The diaphragm curvature.

The standard echographic image for assessing the fetal thoracic anatomy is represented by the four-chamber view image of the fetal heart. If a thoracic lesion is evident in this section, then it is necessary to subsequently use the midsagittal, parasagittal and coronal sections. In the midsagittal and parasagittal view, the presence of the diaphragm and the net delimitation between the thorax and the abdomen can be identified. The objectives, in case a congenital bronchopulmonary malformation is detected, are as follows:

- The description of the pulmonary anomaly
- The exclusion of other associated anomalies
- Establishing the prognosis
- Determining the effectiveness of the fetal therapy

According to the European Respiratory Society, we need to keep in mind the following aspects [1]:

- The bilaterality/unilaterality of the lesion,
- The localization (lateral or central),
- The cystic or hyperechoic characteristic,
- Cysts (number size, content), the presence or absence of a nutritive vessel,

- Presence of hydrothorax,
- Mediastinal shift.

Thus, taking all these elements into account, we can classify the various thoracic anomalies as following:

- Unilateral hyperechoic lesions: CDH right sided, CCAM type III, BPS
- Unilateral anechoic lesions: CDH left sided, CCAM type I, unilateral fetal hydrothorax, bronchogenic cyst.
- Bilateral hyperechoic lesions: laryngeal atresia-CHAOS (congenital airway obstruction syndrome)
- Bilateral anechoic lesions: bilateral fetal hydrothorax
- Median hyperechoic lesions: mediastinal teratoma or hemangioma
- Median anechoic lesion: CDH

Depending on the location of the chest masses, we should consider the following possibilities:

- Left hemithorax: CCAM, CDH, BPS
- Right hemithorax: CDH, CCAM, BPS bronchogenic cyst, teratoma, hamartoma
- Anterior mediastinum: teratoma, thymoma
- Posterior mediastinum: teratoma, neuroblastoma, esophageal duplication
- Diaphragm: CDH

With the advantage of three-dimensional ultrasound (3D-US), we often can clarify the diagnosis of lung abnormalities. We can use 3D rendering, or reconstruction of the coronal plane, or minimal rendering mode, 3D with TUI (tomographic ultrasound image). With these ultrasound applications, it is possible to establish: liver position, liver outline, diaphragm outline, relationship between liver, pulmonary tissue and heart, presence of thoracic hypoplasia.

## **2. Congenital cystic adenomatoid malformation of the lung (CCAM)**

### **2.1. Definition and incidence**

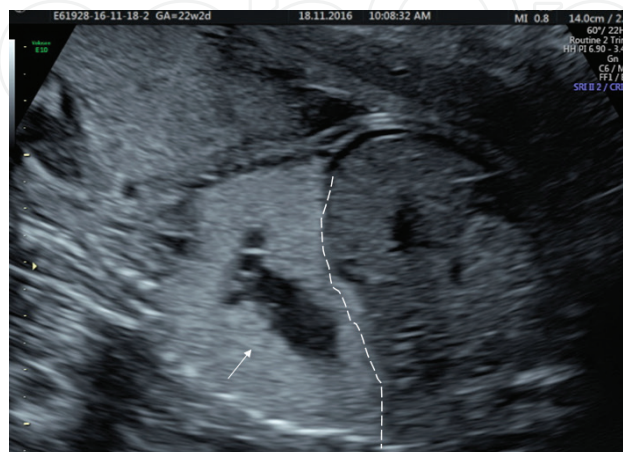
Congenital cystic adenomatoid malformation of the lung (CCAM) is a lesion that is characterized by the presence of a mass of multicystic pulmonary tissue and is accompanied by bronchial proliferation. Its occurrence can be explained by:

- The lack of maturation of the bronchial tissue during the pseudoglandular stage of pulmonary development, which is between the 5th and 6th week of gestation [2]
- Focal pulmonary dysplasia with hamartomatous development at the terminal bronchioles [2]
- Secondary to the airway obstruction [3]

The estimated incidence is of 1 in 25,000 births, up to 1 in 30,000 births [4]. Most ultrasound detected CCAM lesions are unilateral and only 2–3% of them are bilateral and they are more frequently encountered in male fetuses [5]. In the case of unilateral lesions, a single lobe is usually involved and in rare situation it is the whole lung. Vascularization of the multicystic mass comes from a branch of the pulmonary artery. Recently, Stocker has classified CCAM in 5 types, depending on the group of airways involved: Type 0, the lesion is bronchial. Type 1, the lesion is bronchial/bronchiolar. Type 2, the lesion is bronchiolar. Type 3, the lesion is bronchiolar/alveolar. Type 4, the lesion is peripheral [6, 7]. A more practical classification is that which considers the ultrasound antenatal aspect, proposed by Adzick [8] and which describes the lesions as macrocystic or microcystic. Thus, CCAM has the following classification: Macrocystic type I with single or multiple cysts larger than 2 cm in diameter, CCAM type 2 with multiple cysts smaller than 2 cm and larger than 0.5 cm in diameter and type 3 with multiple cysts, less than 5 mm in size and with a hyperechogenic aspect. By advancing Adzick's classification, a simpler ultrasound classification was established by Wilson [9]. Thus, the ultrasound appearance is a cystic variant and a solid (or microcystic) variant. The cystic variant is multilocular lesions with cysts of various sizes from a few millimeters to 10 cm. The solid microcystic variant comprises a hyperechogenic mass.

## 2.2. Ultrasound diagnosis

CCAM ultrasound diagnosis is used for pointing out a cystic or solid lung tumor growth with the absence of systemic Doppler vasculature (**Figure 1**).



**Figure 1.** CCAM microcystic, parasagittal view: arrow—lung mass, line—diaphragm.

It is possible to highlight the vascular flow of the lesion that comes from a branch of the pulmonary artery. The use of color Doppler is mandatory to highlight the absence of systemic vasculature and the presence of pulmonary vasculature for CCAM. From the ultrasound point of view, CCAM will be classified in macrocystic and microcystic (**Figures 2–4**).

Both the macrocystic form and the microcystic form can cause fetal hydrops and mediastinal shift (**Figure 5**).

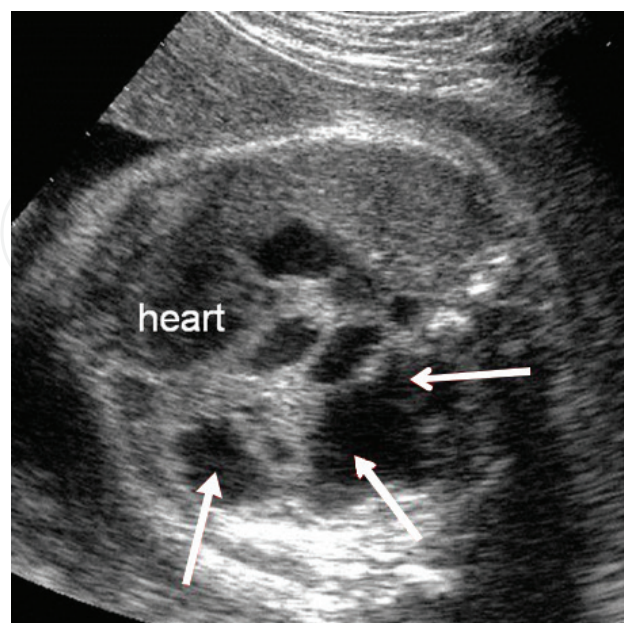
The macrocystic types are rarely accompanied by fetal hydrops. The size of the lesion determines whether a fetus will develop hydrops or not [9]. Large scale macrocystic lesions cause mediastinal shift and cardiac decompensation, accompanied by increased venous central pressure, followed by the appearance of the fetal hydrops (**Figure 6**).

What is important to emphasize, is that the degree of the mediastinal shift has no predictive value for the appearance of the hydrops.

It should be underlined that there are CCAM hybrid lesions which refer to the presence of both pulmonary and systemic circulation that originates directly from the descending aorta [10].

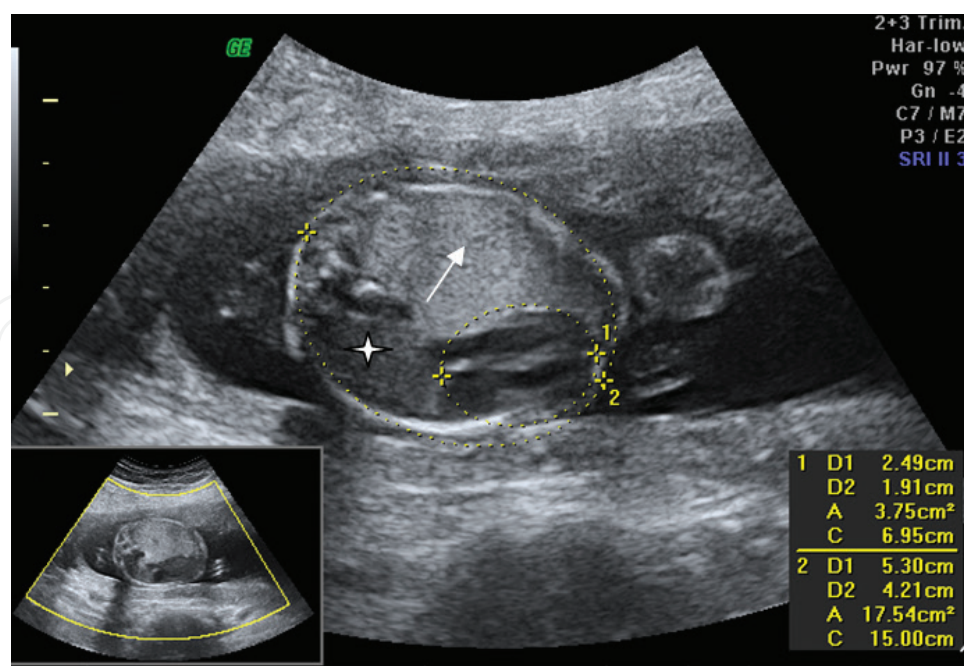
The ultrasound differential diagnosis will consider the following: congenital diaphragmatic hernia (CDH), bronchopulmonary sequestration (BS), pericardial teratoma, enteric or bronchogenic cysts, bronchial atresia, esophageal duplication, neuroblastoma, brain heterotopia.

The differential diagnosis from CDH is not easy. The macrocystic form of CCAM can be confused with CDH left-sided; the intrathoracic stomach may resemble the macrocystic form. Highlighting intestinal peristalsis or emptying the herniated stomach can yield the diagnosis in favor of CDH. In addition, the size of the abdomen is normal, and the abdominal organs are in the normal position in case of CCAM (**Figures 7 and 8**).



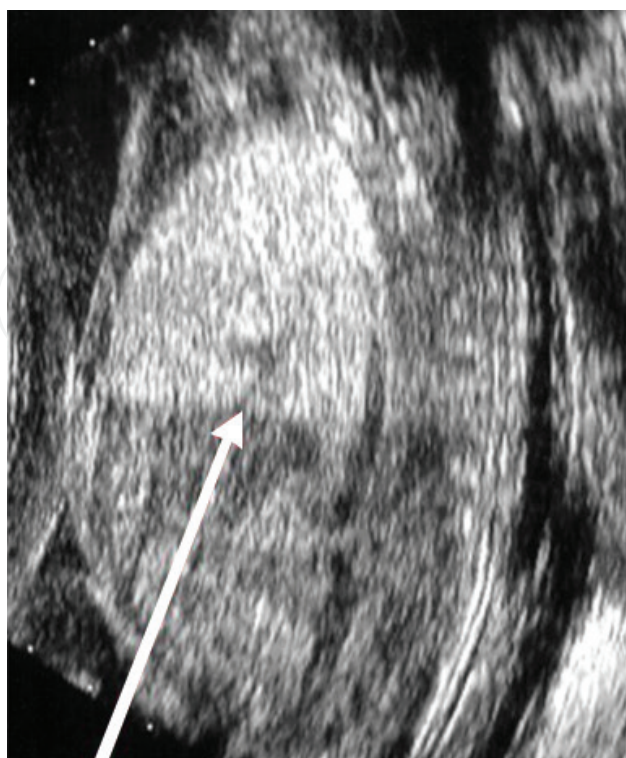
**Figure 2.** CCAM macrocystic: white arrow—lung cyst.



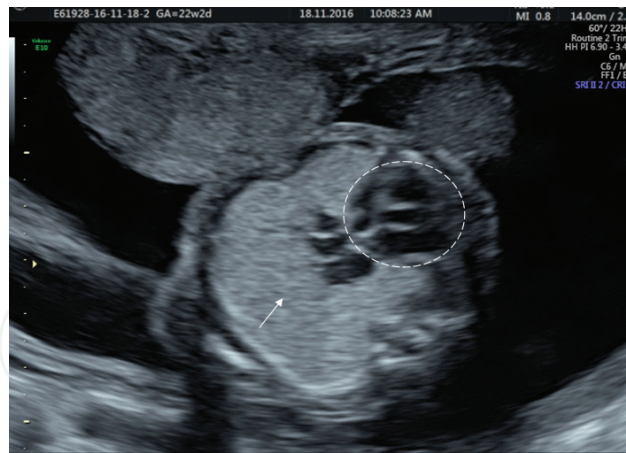

**Figure 3.** CCAM microcystic: arrow—lung mass, star—normal lung.

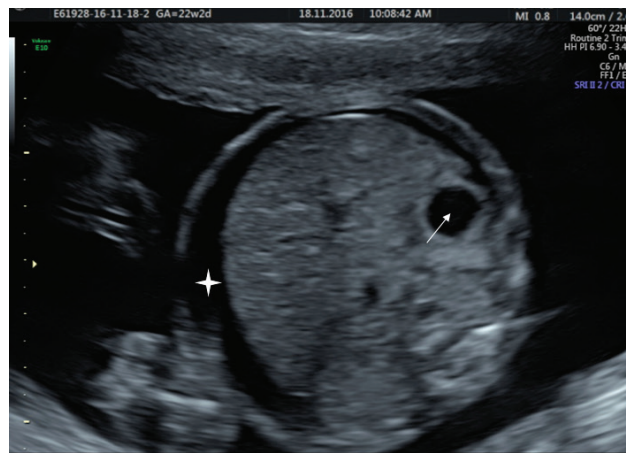Bronchogenic cysts are uniloculated, rarely multicystic, located adjacent to the bronchus, but difficult to distinguish from the macrocystic form of CCAM. Pericardial teratoma may contain large cysts but they are usually associated with the pericardial fluid. The main differential diagnosis of microcystic form of CCAM is with BPS and CDH right



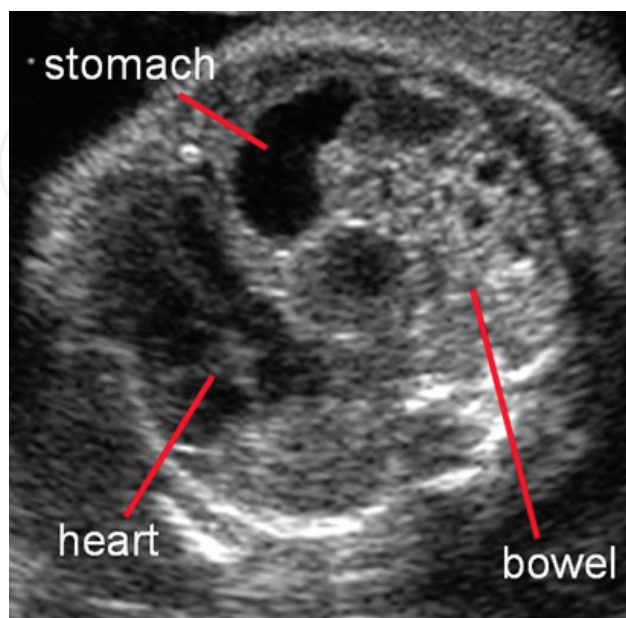
**Figure 4.** CCAM microcystic: white line—enhancement of diaphragm.



**Figure 5.** CCAM microcystic: arrow—lung mass, circle—cardiac shift.

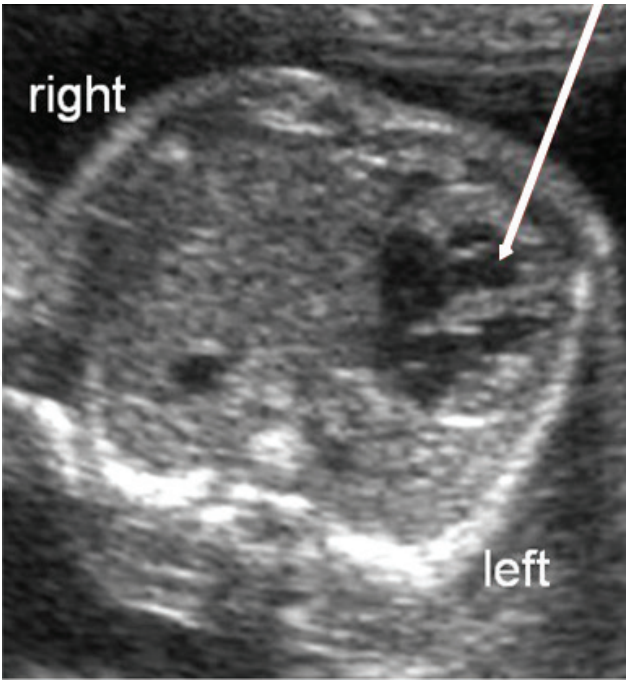


**Figure 6.** Fetal hydrops: arrow—stomach and star—ascites.



**Figure 7.** Differential diagnosis CCAM versus CDH left.





**Figure 8.** Differential diagnosis CCAM versus CDH right: white line—heart shift.

associated with liver herniation. Basically, the main distinguishing ultrasound element is that in BPS, vascularization originates from the systemic circulation, primarily the direct branch from the descending aorta, which can be easily demonstrated with Doppler color or HD-flow Color Doppler [9, 10]. The differentiation criteria between CCAM and BPS are shown in **Table 1**.

Therefore, the identification of the systemic circulation for a lung tumor mass is pathognomonic for BPS. Recently, Cass described 6 cases of CCAM that also had systemic vasculature and specific histological elements for BPS and CCAM, so these lesions were called hybrid lesions [10]. CDH right with hernia of the liver determines a significant mediastinal shift and secondary pulmonary compression. The highly hyperechogenic aspect of the CCAM microcystic form requires the differentiation from neuroblastoma as well. The association of CCAM with extrapulmonary abnormalities ranges from 0 to 26%, renal agenesis or dysgenesis being the most common associations [11, 12].

	CCAM	BPS
Location	Any lobes	Inferior left
Vascularization	Pulmonary	Systemic
Airway communication	Yes	No
Cysts	Yes	No

**Table 1.** Differential diagnosis CCAM versus BPS.

### 2.3. Prognostic

CCAM is not associated with syndromes, the risk of chromosomal anomalies being extremely low. In the absence of hydrops, the long-term outcome of the fetuses with CCAM is good. The incidence of hydrops is 10% in cases of a large cystic mass [12]. Termination of pregnancy before 24-week gestation remains an option for the couple. In cases of prenatal diagnosis of CCAM, the parents should be counseled about the good prognosis even though the CCAM could need a surgical postnatal resection.

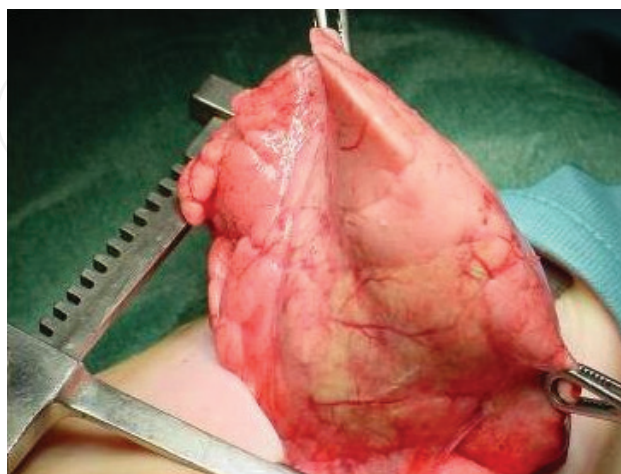
The most important factor for prognosis is the presence of hydrops, which is the most important predictor of poor prognosis. If hydrops is present, the chances of survival are very low, perinatal demise being the most frequent outcome, around 100%.

Another prognostic factor has been established with the use of 3D ultrasound, in determining the CAM volume ratio, (CVR) [13]. This parameter is calculated by dividing the volume of CCAM by the HC (head circumference). That is diameter  $(L \times AP \times T) \times 0.52$  divided by the HC. If CVR is more than 1.6 the incidence of hydrops is 75%.

### 2.4. Prenatal management

It is important to emphasize that the mass has an important potential growth between 20 and 26-week gestation, then there is a plateau, and afterwards the mass tends to regress. Thus, since the volume of a mass is not expected to increase after 26 weeks, and if there is no hydrops, then it is unlikely for the hydrops to appear after 26-week gestation. In cases of large masses, it is recommended to plan delivery in a tertiary center because of the risk of lung hypoplasia, cardiovascular decompensation and high mortality. The postnatal risk is high for large masses and low for small-medium masses (**Figure 9**).

Prenatal fetal therapy is indicated in cases that develop hydrops or cardiac failure.



**Figure 9.** CCAM microcystic intraoperator view.

Karyotyping is not an indication if other anomalies are not present. However, amniocentesis for karyotyping is appropriate if fetal treatment is balanced or when the parents request it [14]. The attitude in CCAM associated with hydrops depends on the CVR value. Thus, if the CVR is less than 1.6 and we do not have a dominant cyst, then weekly fetal monitoring is indicated to identify early signs of hydrops. If we are dealing with a dominant cyst, even if CVR is less than 1.6, the fetus has a major risk of developing hydrops and a thoracoamniotic shunt should be considered at first signs of hydrops appearance. If CVR is above 1.6, the likelihood of developing hydrops is very high and monitoring is required 2 times a week.

The fetal therapy available nowadays is as follows: corticotherapy, in utero fine needle aspiration of macrocysts or thoracoamniotic shunt, laser vascular ablation and, finally, sclerotherapy [15]. A fetus with hydrops below 32-week gestation with a macrocystic lesion of CCAM will benefit from thoracoamniotic shunt. Also, the surgical resection is an option.

Corticosteroid treatment can be followed by the regression of the mass and it is especially indicated in cases of microcystic lesions. If CVR is equal to 1.6, corticosteroid therapy is indicated. Either fine needle aspiration or thoracoamniotic shunt improve the outcome of fetuses with macrocystic CCAM complicated with hydrops/hydrothorax. Microcystic lesions resulting in fetal hydrops of CCAM may need laser ablation of the feeding vessel, to improve survival and with regression of the lesion. The sclerotherapy is also indicated in microcystic cases and it is used Ethanolamine. But it must be emphasized that in most cases fetal CCAM needs only serial fetal surveillance, every 2 or 3 weeks, to confirm regression in size or the remaining at the same size.

### 3. Bronchopulmonary sequestration

#### 3.1. Definition and incidence

Bronchopulmonary sequestration (BPS) represents a cystic mass of nonfunctioning pulmonary tissue with the blood supply from the systemic vessels and not from the pulmonary arteries.

The incidence reported is 0.5–6.0% of all prenatally diagnosed pulmonary lesions [16].

Pulmonary sequestration can be: intrapulmonary and extrapulmonary. Intrapulmonary sequestration (IPS) represents almost 75% of the cases, but this form is rarely diagnosed in utero. The abnormal lung tissue lies within the normal lung tissue. This variety is produced by the bronchial obstruction.

Extrapulmonary sequestration (EPS) is the most commonly form diagnosed in the prenatal life. The abnormal lung tissue has its own pleural covering, so the abnormal pulmonary tissue is separated from the normal pulmonary tissue and the pathologic tissue drains in the systemic circulation. The extrapulmonary sequestration is considered to be an abnormal pulmonary tissue that has no connection with the bronchial tree. The vascularization is provided by arteries emerging from the aorta.

### 3.2. Ultrasound diagnosis

The prenatal ultrasound diagnosis of bronchopulmonary sequestration is based on the following elements:

- hyperechoic mass
- a mass with triangular shape, with a paraspinal localization, usually in the base of the left fetal chest.
- small or moderate size
- the large size can cause fetal hydrops
- color Doppler confirm the origin of the tumoral vessels as belonging to systemic vessels

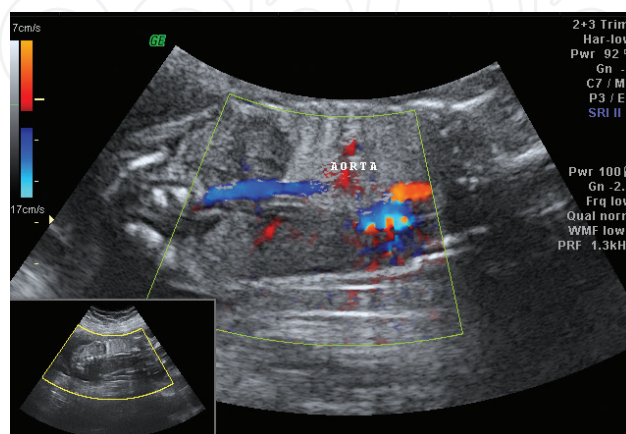
Typically, BPS vascularization, and more specifically EPS, is supplied by a single artery, originating from the aorta (**Figure 10**).

The veins of the BPS drain in the azygos system and hemiazygos. At the opposite end, the venous drainage of the IPS is achieved through the pulmonary veins [17]. The hydrothorax can be associated with BPS, usually ipsilateral, and if it is important, it can cause a mediastinal shift.

Differential diagnosis includes the following: CCAM, bronchial atresia, lobar emphysema, CDH-particularly when the liver or spleen is the only component of herniation, mediastinal teratoma, neuroblastoma, mesoblastic nephroma, segmental thoracic obstruction, and thoracic kidney.

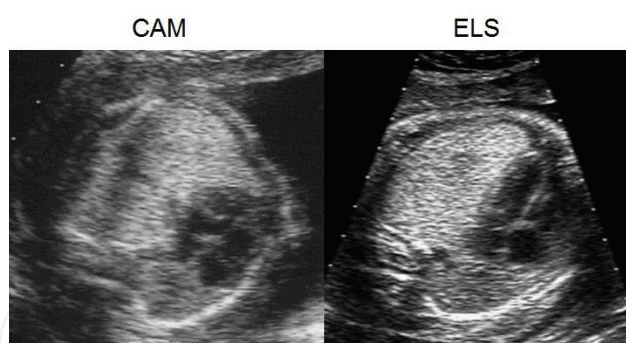
The differential diagnosis between CCAM and BPS, when no systemic feeding vessel is evident, is based on the echogenicity of the mass: the presence of cyst suggests CCAM, while the presence of a hyperechogenic triangular mass suggests BPS (**Figure 11**).

For extrapulmonary BPS, the differential diagnosis includes: mesoblastic nephroma, and neuroblastoma.



**Figure 10.** Bronchopulmonary sequestration: systemic vascularization.





**Figure 11.** Differential diagnosis CCAM versus BPS.

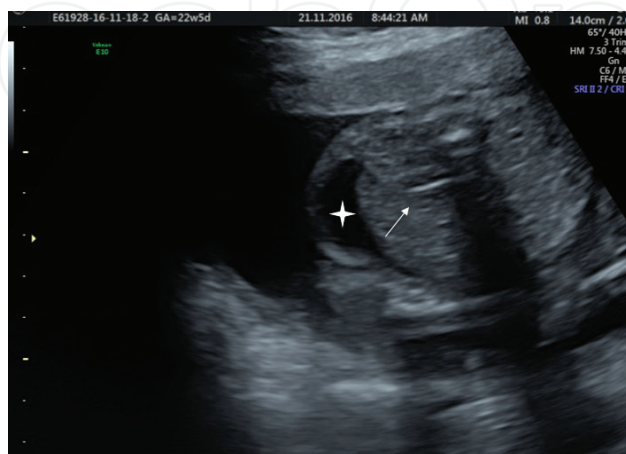
### 3.3. Prognosis

The prognosis of BPS is favorable in the absence of other associated abnormalities. In many case series it was found that, similar to CCAM evolution and in BPS cases, there is often present a regression of the lesion [18, 19]. However, in fetuses with BPS associated with fetal hydrops, the prognosis is poor (**Figure 12**).

Fetal hydrops occurs only if a tension hydrothorax develops. The cause of unilateral hydrothorax associated with BPS is not well-defined. The torsion of a vascular pedicle or abnormal pressure gradient between the systemic artery and the pulmonary vein may be the cause [19]. Regardless the etiology, the persistence of the hydrothorax causes pulmonary compression with pulmonary hypoplasia and the impairment of the caval venous drainage due to mediastinal shift.

### 3.4. Prenatal management

In isolated BPS karyotyping is not mandatory, but it is recommended if any other abnormality is associated. Fetal MRI may be useful for differential diagnosis. The family may choose to terminate the pregnancy if the diagnosis is established before 24 weeks and it is associated with other abnormalities such as: esophageal atresia, neurenteric cyst, CDH, pulmonary hypoplasia, cardiac



**Figure 12.** Fetal hydrops and BPS: arrow—BPS mass, star—hydrothorax.

anomalies and bronchogenic cyst. Fetal monitoring is required in the prenatal period, to identify the appearance of the hydrothorax. A fetus with isolated BPS has good chances of survival in the absence of hydrops, polyhydramnios or pleural effusion, because it can regress in 80% of cases. Fetuses over 30-week gestation should be considered for preterm delivery and ex-utero surgical resection. In the presence of hydrops before 30 weeks, placing a thoracoamniotic shunt may be offered. In hydrothorax, installing the thoraco-amniotic shunt may prevent the development of fetal hydrops. The postnatal therapy consists of the endoscopic removal of the pulmonary mass and alternatively the selective embolization of the artery that feeds the tumor [20–22].

In brief, for the two main anomalies CCAM and BPS, we can apply the following therapeutic scheme:

- CCAM/BPS stable as dimensions and stationary as evolution: near-term birth and ex-utero resection
- Regressive CCAM/BPS: term delivery and evaluation
- Progressive CCAM/BPS towards hydrops and mediastinal shift: it depends on the gestational age of the fetus. Thus, if it is less than 32 weeks, then a thoraco-amniotic shunt or resection in utero and cesarean delivery is recommended near term. After 32 weeks' gestational age, the iatrogenic preterm birth and resection ex utero are recommended.

## 4. Pulmonary hypoplasia and pulmonary agenesis

### 4.1. Definition and incidence

Congenital pulmonary hypoplasia consists of the lowering of the lung volume in comparison to the lung volume corresponding to the gestational age. The causes of pulmonary hypoplasia are represented by: congenital diaphragmatic hernia (CDH), oligohydramnios, skeletal dysplasia, chest tumors, neuromuscular disorders that obstruct fetal respiratory movements. A rare cause is represented by the obstructive cardiac abnormalities of the right-sided heart, which may be accompanied either by the absence of the development of a single lung or the absence of the development of both lungs. Regardless the mechanism, pulmonary hypoplasia is responsible for the neonatal mortality, of 10–15% [23]. Pulmonary agenesis can be classified into three groups [23, 24]: in group 1, there are bronchial and lung agenesis, in group 2 there is a rudimentary bronchus without bronchial tissue and in group 3 it is a bronchial hypoplasia and a hypoplasia of lung tissue. Pulmonary agenesis is usually unilateral, and occurs at 4 weeks of gestation. The etiology of this anomaly is unknown. The incidence of pulmonary agenesis, either unilateral or bilateral, is very low, 0.0097% or 1 at 10,000 pregnancy [22]. More than half of the fetuses with pulmonary agenesis have other associated abnormalities: gastrointestinal, cardiovascular and genitourinary. Unilateral pulmonary agenesis may be associated with numerous other abnormalities: patent ductus arteriosus (PDA), atrial and ventricular septal defects, anomalous pulmonary venous drainage, tracheoesophageal fistula and duodenal atresia, hemivertebrae with scoliosis, facial abnormalities and limb abnormalities.

## 4.2. Ultrasound diagnosis

The ultrasound diagnosis is established on the axial section of 4 chambers of the heart. Unilateral pulmonary hypoplasia determines the mediastinal shift to the hemithorax where the lung is absent and the existing lung is highly hyperechogenic. Usually, unilateral pulmonary hypoplasia (especially the right one) is part of the scimitar syndrome, which is an abnormal venous return in the inferior vena cava (both pulmonary veins are absent and replaced with a collecting vein that drains into the inferior vena cava and which at 3D ultrasound resembles a scimitar). In the case of unilateral pulmonary agenesis, the ultrasound aspect is somewhat similar to the one made in case of CDH, by the mediastinal shift, but there is no abdominal viscera noticed inside the rib cage. The color Doppler can be used to highlight the absence of the pulmonary vascular system. Pay attention to differential diagnosis of CDH with pulmonary compression and CCAM, for unilateral lung agenesis advocates the mediastinal shift to the agenesis side and the enlarged hyperechogenic lung herniated in the contralateral chest through the mediastinum.

Bilateral pulmonary hypoplasia is caused by a skeletal dysplasia that is associated with a significant reduction in thoracic volume. Quite rarely, bilateral pulmonary hypoplasia is primary, and it is more commonly secondary to a prolonged oligohydramnios after a long lasting very premature rupture of membrane. The ultrasound diagnosis is also done on the axial section of four chambers view of the heart. The aspect is that the heart fills all the thorax, there is no lung tissue and the rib cage is extremely small. There are nomograms in the literature for thoracic circumference versus gestational age or cardiothoracic ratio.

There is an association of unilateral/bilateral pulmonary agenesis with facial, radial anomalies, genitourinary anomalies, polyhydramnios or oligohydramnios.

The differential diagnosis of unilateral agenesis is done with CDH, CCAM and BPS.

## 4.3. Prognosis

Bilateral pulmonary hypoplasia is fatal. The risk of chromosomal anomalies is rare, but the risk of association with non-chromosomal syndromes is high. A study comparing eight echographic parameters for the prediction of lethal pulmonary hypoplasia showed that the use of the pulmonary area/abdominal circumference and thoracic circumference/abdominal circumference ratio are the most clinically useful in the prediction of bilateral pulmonary hypoplasia [23]. In the case of unilateral pulmonary agenesis, the duration of neonatal survival is higher for the left one in comparison to right one, probably due to the cardiac and mediastinal shift which is with less distortion of the blood vessels and bronchi. The fetuses with unilateral agenesis have a neonatal risk for repeated bronchopulmonary infections and respiratory distress syndrome. The cause of high neonatal mortality is the pulmonary infection and the association with cardiac abnormalities.

## 4.4. Prenatal management

In the case of unilateral hypoplasia, no karyotyping is required, but the birth is recommended to occur in a tertiary center because of the risk of orotracheal intubation immediately after the

delivery. Bilateral lung agenesis is incompatible with life. In the case of the primary bilateral pulmonary hypoplasia or associated with skeletal dysplasia, the importance of a correct diagnosis is not only for the current pregnancy that will evolve to the exitus of the fetus but also for a future pregnancy because skeletal dysplasia may not occur sporadically but exhibit recessive inheritance. In unilateral pulmonary hypoplasia associated with the scimitar syndrome, neonatal ventilation may be required. Fetal MRI may be useful in distinguishing between the pulmonary agenesis and CCAM [23, 24]. At the same time, the exclusion of associated fetal abnormalities can be done by MRI, in particular: ipsilateral upper extremities, mandible, face, or kidneys. There is no fetal intervention available in pulmonary agenesis.

## 5. Bronchogenic cysts

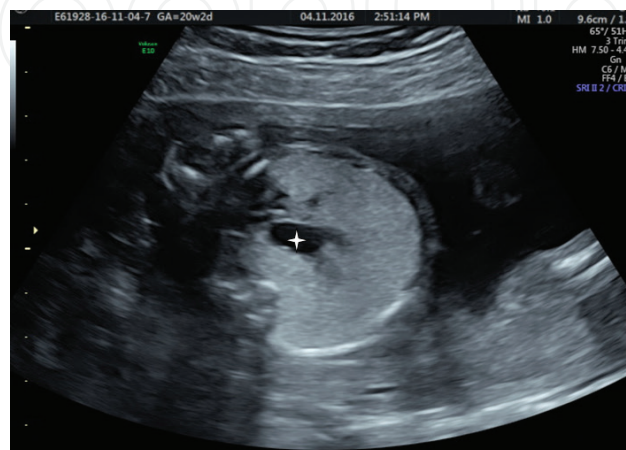
### 5.1. Definition and incidence

It comes from the primitive foregut early in the embryogenesis. It contains the columnar ciliary epithelium and the cartridges. They are usually located intrapulmonary but may also be mediastinal [25], or intrapericardial. They may also be located cervical or infradiaphragmatic. They can basically be located anywhere on the tracheoesophageal tract. It is extremely rare.

### 5.2. Ultrasound diagnosis

The diagnosis of bronchogenic cysts can be established on the axial section of the four chambers of the heart. It appears as a unilateral, circumscribed, thin wall lesion (**Figure 13**).

They may rarely be multilocular. The bronchogenic mediastinal cyst can compress the trachea or bronchi so that the distal lung becomes dense and expansive, in this way lending the specific echographic aspect for the cystic adenomatoid malformation [26]. The differential diagnosis includes: CCAM, esophageal duplication cyst, pericardial cyst, duplication cyst and lymphangioma. In CCAM, the tissue surrounding the cyst is hyperechogenic.



**Figure 13.** Bronchogenic cyst: star—lung mass.



### 5.3. Prognosis

One of the few negative prognostic factors is the size of the mass.

### 5.4. Prenatal management

The presence of bronchogenic cysts does not cause the death of the fetus in utero [25, 26]. It is not recommended to perform karyotyping because the risk of associated chromosomal abnormalities is extremely low. There is, however, the risk of an emergency intubation at birth, so birth is recommended to take place in a tertiary center.

## 6. Congenital high airway obstruction syndrome (CHAOS—laryngeal atresia)

### 6.1. Definition and incidence

Congenital high airway obstruction syndrome (CHAOS) occurs due to laryngeal atresia, tracheal atresia, or laryngeal cyst [27]. There are three types of laryngeal atresia: type I-agenesis of glottis, Type II agenesis of larynx, type III-agenesis of both [28]. The laryngeal atresia is difficult to differentiate using ultrasound from tracheal atresia and both are diagnosed based on intrathoracic signs. The exact incidence of this syndrome is unknown, but it is an extremely rare abnormality. The cause of tracheal/laryngeal atresia is not clear, but it appears to be a vascularization deficit during the embryogenic period [29, 30].

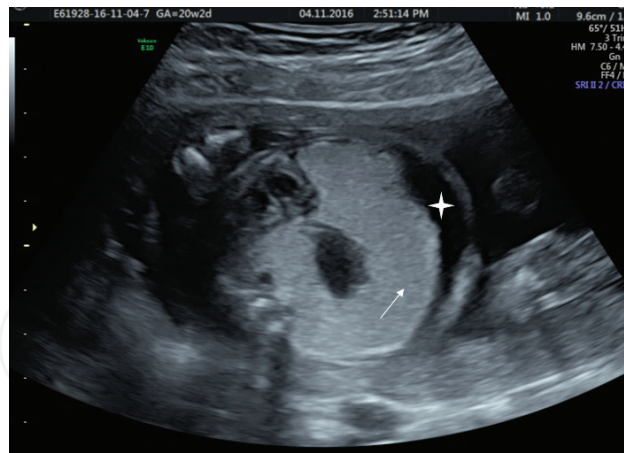
### 6.2. Ultrasound diagnosis

The ultrasound diagnosis is done on the four-chamber axial section. It is noted that both lungs are hyperechogenic, large in size, flattening the diaphragm due to the large volume of the lungs, the heart appears smaller due to the compression exerted by the lungs, the axis of the heart is zero, the dilatation of the tracheobronchial tree can be seen by the accumulation of liquid at its level (**Figure 14**).

On the coronal section, the dilated trachea and bifurcation of this, as well as the diaphragmatic flattening, can be better emphasized. The differential diagnosis of CHAOS does not have what entity to do, because it is a unique anomaly. At most, bilateral CCAM can be considered in the differential diagnosis, but bilateral CCAM is very rare and it does not present a severely increased volume of both lungs.

### 6.3. Prognosis

This anomaly is fatal. It may be part of the Fraser syndrome [29, 30], which includes: laryngeal atresia, renal agenesis, oligoamnios, microphthalmia, syndactyly, polydactyly. The prognosis is even more severe because the recessive autosomal is transmitted. The risk of chromosomal anomalies is low.



**Figure 14.** CHAOS: dilatation of tracheobronchial tree.

## 6.4. Prenatal management

Karyotyping is not indicated because the risk of chromosomal abnormalities is low. The ultrasound should also focus on the exclusion of structural heart or kidney abnormalities. Delivery should take place in a tertiary center. The only option that exists to save a fetus with CHAOS is the EXIT procedure (ex utero intrapartum treatment). So far, only 9 cases have survived through this procedure [29].

## 7. Fetal hydrothorax

### 7.1. Definition and incidence

Fetal hydrothorax (FHT) represents the accumulation of fluid in the pleural cavity, between the parietal and the visceral pleura. It can be unilateral or bilateral. It can be isolated or in the context of a generalized hydrops, or associated with other fetal abnormalities.

The incidence is not specified given the variability of the causes, but in the antenatal period, the secondary causes of hydrothorax are more common [31]. The causes that can lead to the occurrence of fetal hydrothorax are multiple: congenital infection (parvovirus, TORCH), isoimmunization, congestive heart failure, Down syndrome, Turner syndrome. Primary FHT is called chylothorax. Secondary FHT usually appears secondary to chromosomal, cardiac, gastrointestinal and infectious abnormalities. FHT generally precedes the installation of fetal hydrops. The appearance of primary FHT is due to a structural defect in the lymphatic system: the obstruction of bronchomediastinal trunks to the venous system, congenital absence of the thoracic duct, congenital hypoplasia of the pulmonary lymphatic vessel [31, 32]. It is a diagnostic of exclusion. In general, primary FHT occurs as a result of the obstruction of secondary lymphatic drainage to a heterogeneous group of developmental defects of the lymphatic system. Unilateral FHT may happen due to a unilateral pathological process such as: congenital diaphragmatic hernia, cystic adenomatoid malformation, pulmonary hypoplasia.

## 7.2. Ultrasound diagnosis

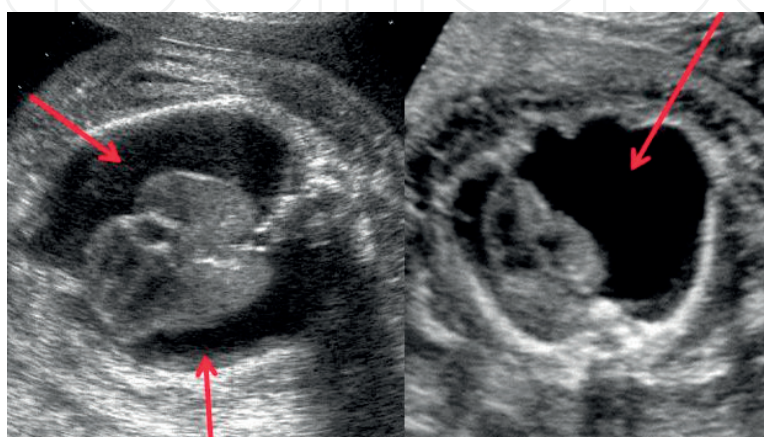
The diagnosis of fetal hydrothorax is established on the axial image of the four chambers of the heart, as an anechoic area around the pulmonary tissue which limits the mediastinum. Effusions can be unilateral or bilateral (**Figure 15**).

The hydrothorax aspect is that of a peripheral anechoic space in the thorax, compressing the lung tissue. In the case of large bilateral effusions, the aspect is that of the lungs balloting in the rib cage. At the same time, mediastinal shift and the eversion of the diaphragm occur with the displacement of the heart to the contralateral side and they can cause the disruption of the hemodynamic function and the installation of nonimmune hydrops. If the pleural effusion is part of the nonimmune hydrops, then it is also possible to see the edema of the thoracic subcutaneous tissue. It is important to note that FHT associates with the polyhydramnios in over 50% of cases, either due to a mediastinal shift that causes the compression of the esophagus or because of an alteration in the production of amniotic fluid by the compressed lungs.

The differential diagnosis is important because it should be determined whether FHT is primary or secondary. Primary hydrothorax is usually a chylothorax and it is unilateral and is a diagnostic of exclusion. However, the fetus with trisomy 21, Noonan syndrome, and Turner syndrome, may present either unilaterally or bilaterally hydrothorax [31]. For secondary hydrothorax, evidence of specific echographic elements for CDH, CCAM, BPS determines the diagnosis. In the case of the fetuses with hydrops, the presence of fetal anemia should be excluded.

## 7.3. Prognosis

The most important element of prognosis is whether fetal hydrothorax is associated with non-immune fetal hydrops, because in this situation the fetal mortality is increased. Other negative prognostic factors are FHT associated with cardiac abnormalities or with central nervous system anomalies. The only positive prognostic factor is the presence of FHT without another associated anomaly or other fluid effusion with another location. Isolated small FHT at the fetus without any other abnormalities, without hydrops or abnormal karyotype, has a favorable prognosis, because the fetus usually tolerates well small effusions [31, 32]. What is important to remember is that 10–25% of the cases of chylothorax can regress spontaneously



**Figure 15.** Bilateral hydrothorax: arrow—hydrothorax.

or after only a single drainage [32]. Delivery by vaginal route is an option although there is an increase incidence of the rate of cesarean section [33].

#### 7.4. Prenatal management

It is mandatory to determine the karyotype in FHT due to the increased risk of association with chromosomal anomalies. Even if the fetus tolerates small isolated effusions, a serial echographic surveillance is required because small hydrothorax can progress rapidly to large effusions that may have negative hemodynamic consequences. Therefore, ultrasound monitoring is recommended every 1 or 2 weeks, due to the risk of polyhydramnios and preterm delivery. Birth in a tertiary center is recommended.

If FHT was diagnosed before 24 weeks, the therapeutic interruption of the pregnancy is an option. If the fetus with FHT has more than 32 weeks, then the serial ultrasound at one or 2 weeks distance is recommended, but we can also consider thoraco-amniotic shunt. If the fetus has less than 32 weeks we have three options: thoracocentesis, thoracoamniotic shunt, thoracomaternal cutaneous drainage. The initial step is the thoracocentesis and diagnosis for cell count, culture, or the viral culture. In general, thoracocentesis other than for diagnosis is ineffective because after it is done a re-accumulation of the pleural fluid occurs. The rapidity with which the effusion accumulates after the initial puncture is an indicator of the pleural effusion severity. For this reason, pleural cavity decompression is done through thoracoamniotic shunt. Large FHT is drained through thoracoamniotic shunt especially if hydrops is present. Shunting is especially effective if the fetus has less than 32 weeks of gestation [34]. The failure rate for thoracoamniotic shunt is of 26% [34, 35]. Shunt complications are: blockage, migration, fetal death. If a thoracoamniotic shunt is mounted the incidence of survival increases from 10 to 60%.

## 8. Fetal mediastinal cysts

### 8.1. Definition and incidence

Fetal mediastinal cysts are represented by: pericardial cyst, thymic cyst, esophageal duplication cyst, neurenteric cyst. The incidence of these masses is not known because they are rare pathological entities and only case reports are reported. The pericardial cyst is located at the costophrenic right angle level. The pericardial cyst is covered by mesothelium and has fluid content, and is usually asymptomatic. If the size of the cyst is important, then it can be associated with fetal hydrops, or with the change in heart function at birth [17]. If the pericardial cyst size is reduced in size, it can also regress.

The thymic cyst is very rare, representing 4% of postnatal mediastinal cystic masses [17, 35]. Thymic cysts are asymptomatic, but the prenatal diagnosis is possible.

The esophageal duplication cyst exhibits ectopic gastric mucosa, communicating with the gastrointestinal lumen. Sometimes they may not communicate with the gastrointestinal lumen [17, 36]. The communication with the gastrointestinal lumen is located either above the diaphragm or below the diaphragm.

The neurenteric cyst has a connection with the meninges and the spinal cord and it is usually associated with congenital scoliosis or spina bifida.



## 8.2. Ultrasound diagnosis

The prenatal diagnosis of esophageal duplication cysts is based on the spherical aspect of the cyst, rarely on the tubular aspect, but with a thick, hyperechogenic wall determined by the presence of the gastric mucosa. Usually, the cyst is connected to the esophagus. If the dimensions of the esophageal duplication cyst are large due to the compression effect on the esophagus, the appearance of polyhydramnios may occur [37, 38]. The thymic cyst is formed from remnants of the thymopharangeal duct; they are usually very small and localized to the anterior mediastinum [38]. The ultrasound aspect is of a transonic mass surrounded by the thymic tissue and located in the previous mediastinum.

Pericardial cyst, originating from the pericardium, appears at ultrasound examination as a thin walled, unilocular, fluid-filled transonic mass in the left or the right of the cardiophrenic angle. The cyst wall may communicate with the pericardial space.

Neurenteric cysts are very rare; only eight cases have been diagnosed in the prenatal stage by the ultrasound [37–39]. If the size of the cyst is large, it can exert cardiac compression with the subsequent appearance of the hydrops. It can also exert compressive phenomena on the bronchi, which causes neonatal respiratory distress. Association with anomalies of the membrane can be encountered [40].

The differential diagnosis among the described mediastinal masses is sometimes difficult. Several elements should be considered: pericardial cyst is located in the cardiophrenic angle of the right hemothorax, thymic cysts are located in the anterior mediastinum and are surrounded by thymic tissue, and the enteric duplication cyst is in close contact with the esophagus [41, 42]. For differential diagnosis, we can also use fetal MRI. The origin of the mass can be established sometimes only after perinatal autopsy [43].

## 8.3. Prognosis

The prognostic thymic cyst is favorable without affecting the condition of the fetus. The pericardial cyst can determine hydrops due to the compression on the heart. However, sometimes even in the case of reduced size, the pericardial cyst can be resorbed. The neurenteric cyst can cause cardiac compression and the appearance of hydrops as secondary effect. The esophageal duplication cyst determines polyhydramnios due to compression on the esophagus. The risk of chromosomal anomalies is absent, so karyotyping is not recommended.

## 8.4. Prenatal management

The indication of in utero treatment is represented by the presence of hydrops and the presence of compression of the tracheobronchial tree [44]. Puncture with cyst aspiration or the EXIT techniques are the treatment options in such cases.

## Acknowledgements

We would like to thank Rahimian Hadi MD, PhD, Regina Maria Hospital, Bucharest, for **Figures 3 and 4**.

## Author details

Cringu Ionescu

Address all correspondence to: antoniuginec@yahoo.com

Department of Obstetrics and Gynecology, Clinical Emergency Hospital St Pantelimon,  
Carol Davila University of Medicine and Pharmacy, Bucharest, Romania

## References

- [1] Guidelines of the European Respiratory Society and the European Society of Thoracic Surgeons for the management of malignant pleural mesothelioma. *The European Respiratory Journal*. 2010;**35**:479-495
- [2] Stoecker JT, Madewell JER, Drake RM. Congenital cystic adenomatoid malformation of the lung – Classification and morphologic spectrum. *Human Pathology*. 1977;**8**:155-171
- [3] Leninger BJ, Haight C. Congenital cystic adenomatoid malformation of the left lobe lower with compression of remaining lung. *Clinical Pediatrics*. 1973;**12**:182-186
- [4] Langston C. New concepts in the pathology of congenital lung malformations. *Seminars in Pediatric Surgery*. 2003;**12**:17-37
- [5] Laberge JM, Flageole H, Pugash D, et al. Outcome of the prenatally diagnosed congenital cystic malformation: A Canadian experience. *Fetal Diagnosis and Therapy*. 2001;**16**:178-186
- [6] Hernanz Schulman M. Cystic and cystic like lesions of the lung. *Radiologic Clinics of North America*. 1993;**31**:631-649
- [7] Stoecker JT. Congenital airway obstruction malformation: A new name and expanded classification of congenital cystic adenomatoid malformation of the lung. *Histopathology*. 2002;**41**:144-149
- [8] Adzick NS, Harroson MR, Click PL, et al. Fetal cystic adenomatoid malformation prenatal diagnosis and natural history. *Journal of Pediatric Surgery*. 1985;**20**:483-488
- [9] Wilson RD, Hedrick HL, Liechty KW. Cystic adenomatoid malformation of the lung – Review of genetics, prenatal diagnosis and in utero treatment. *American Journal of Medical Genetics. Part A*. 2006;**140 A**:151-155
- [10] Mahle WT, Ryschick J, Tian Z, et al. Echocardiographic evaluation of the fetus with congenital cystic adenomatoid malformations. *Ultrasound in Obstetrics & Gynecology*. 2000;**16**:620-624
- [11] Cass DL, Crombleholme TM, Howello LJ. Cystic lung lesions with systemic arterial blood supply: A hybrid of congenital cystic adenomatoid malformation and bronchopulmonary sequestration. *Journal of Pediatric Surgery*. 1997;**32**:986-990

- [12] Morin L, Crombleholme TM, Lewis F. Bronchopulmonary sequestration: Prenatal diagnosis with clinicopathologic correlation. *Current Opinion in Obstetrics & Gynecology*. 1994;**6**:479-481
- [13] Cameron HM. Fetal thoracic lesions. *Fetal and Maternal Medicine Review*. 2003;**14**:23-46
- [14] Ionescu C, Calin D, Ples L, Dimitriu M, Bohiltea R, Banacu M. Cystic adenomatoid malformation of the lung associated with trisomy 18. *Gineco.eu*. Mar 2016;**12**(45):109-112
- [15] Crombleholme TM, Coleman B, Hedrick H, et al. Cystic adenomatoid malformation volume ratio predicts outcome in prenatally diagnosed cystic adenomatoid malformation of the lung. *Journal of Pediatric Surgery*. 2002;**37**:331-338
- [16] Dommergues M, Louis-Sylvester C, Mandelbrot, et al. Cystic adenomatoid malformation of the lung: When it is active fetal therapy indicated? *American Journal of Obstetrics and Gynecology*. 1997;**177**:953-958
- [17] Tsao KJ, Albanese CT, Harrison MR. Prenatal therapy for thoracic and mediastinal lesions. *World Journal of Surgery*. 2003;**27**:77-83
- [18] Sauerbei E. Lung sequestration: Duplex Doppler diagnosis at 19 weeks gestation. *Journal of Ultrasound in Medicine*. 1991;**10**:101-105
- [19] Sintzoff SA, Avni EF, Rocmans P, et al. Pulmonary sequestration like anomaly presenting as a spontaneously resolving mass. *Pediatric Radiology*. 1991;**21**:143-144
- [20] Meizner I, Rosenak D. The vanishing fetal intrathoracic mass: Consider an obstructing mucous plug. *Ultrasound in Obstetrics & Gynecology*. 1995;**5**:275-277
- [21] Lee BS, Kim JT, et al. Neonatal pulmonary sequestration: Clinical experience with transumbilical arterial embolization. *Pediatric Pulmonology*. 2008;**43**:404-413
- [22] Sohaey R, Zwiebel W. The fetal thorax: Non cardiac chest anomalies. *Seminars in Ultrasound, CT, and MR*. 1996;**17**:34-50
- [23] Schneider P, Schwalbe E. Die morphologie der missbildungen des menschen und der thiere. Jena: Fischer. 1912;**3**:812-822
- [24] Yoshimura S, Masuzaki H, Gotoh H. Ultrasonographic prediction of lethal pulmonary hypoplasia – Comparison of eight different sonographic parameters. *American Journal of Obstetrics and Gynecology*. 1996;**175**:477-483
- [25] Albright EB, Crane JP, Shackelford GD. Prenatal diagnosis of a bronchogenic cyst. *Journal of Ultrasound in Medicine*. 1988;**7**:91-95
- [26] Bagolan P, Bilancioni E, Nahom A. Prenatal diagnosis of a bronchogenic cyst in an unusual site. *Ultrasound in Obstetrics & Gynecology*. 2000;**15**:66-68
- [27] Lim FY, Crombleholme TM, Hedrick HL, et al. Congenital high airway obstruction syndrome: Natural history and management. *Journal of Pediatric Surgery*. 2003;**38**:940-945
- [28] Kalache K, Chaoui R, Tennstedt C, et al. Prenatal diagnosis of laryngeal atresia in cases of CHAOS. *Prenatal Diagnosis*. 1997;**17**:577-581

- [29] Paladini D, Volpe P. Thoracic anomalies. In: Paladini D, Volpe P, editors. *Ultrasound of Congenital Fetal Anomalies*. CRC Press, Taylor Francis Group; 2014. pp. 253-254
- [30] Saadai P, Jelin F, Nijsyndrome EB, et al. Long term outcome after fetal therapy for congenital airway obstruction. *Journal of Pediatric Surgery*. 2012;**47**:1095-1100
- [31] Weber AM, Philipson EH. Fetal pleural effusion: A review and meta-analysis for prognostic indicators. *Obstetrics and Gynecology*. 1992;**79**:281-286
- [32] Moerman P, Vandenberghe K, Devlieger H, et al. Congenital pulmonary lymphangiectasis with chylothorax: A heterogeneous lymphatic vessel abnormality. *American Journal of Medical Genetics*. 1993;**47**:54-58
- [33] Ionescu C, Ples L, Banacu M, Poenaru E, Panaitescu E, Dimitriu M. Present tendencies of elective cesarean delivery in Romania: Geographic, social and economic factors. *Journal of the Pakistan Medical Association*. Aug 2017;**67**(8):1248-1253
- [34] Yaghoobian J, Comrie M. Transitory bilateral isolated fetal pleural effusions. *Journal of Ultrasound in Medicine*. 1988;**7**:231-232
- [35] Paladini D, Chita SD, Allan LD. Prenatal measurement of cardiothoracic ratio in the evaluation of congenital heart disease. *Archives of Disease in Childhood*. 1990;**65**:20-23
- [36] Jung E, Won HS, Lee PR, et al. The progression of mediastinal lymphangiomas in utero. *Ultrasound in Obstetrics & Gynecology*. 2000;**16**:663-666
- [37] Tollefson I, Yoo M, Bland JD. Thymic cysts: Is a correct preoperative diagnosis possible? Report of a case series and review of the literature. *European Journal of Pediatrics*. 2001;**160**:620-622
- [38] Jagers J, Balsara K. Mediastinal masses in children. *Seminars in Thoracic and Cardiovascular Surgery*. 2004;**16**:201-208
- [39] Gul A, Tekoglu G, Aslan H, et al. Prenatal sonographic features of esophageal and ileal duplication cyst at 18 weeks of gestation. *Prenatal Diagnosis*. 2004;**24**:969-971
- [40] Pleş L, Sima RM, Moisei C, Moga M, Dracea L. Abnormal ultrasound appearance of the amniotic membranes – Diagnostic and significance: A pictorial essay. *Medical Ultrasonography*. 2017;**19**(2):1-5. ISSN: 2066-864
- [41] Bianchi D, Crombleholme TT, D'Alton M, Malone F. *Cystic Lesions of the Chest in Fetology Diagnosis and Fetal Patient*. 2nd ed. McGraw Hill; 2010. pp. 273-276
- [42] Maccaulay KE, Winter TC, Shields L. Neurenteric cyst shown by prenatal sonography. *AJR. American Journal of Roentgenology*. 1997;**169**:563-565
- [43] Şorop-Florea M, Ciurea RN, Ioana M, Stepan AE, Stoica GA, Tănase F, Comănescu MC, Novac MB, Drăgan I, Pătru CL, Drăguşin RC, Zorilă GL, Cărbunaru OM, Oprescu ND, Ceauşu I, Vlădăreanu S, Tudorache Ş, Iliescu DG. The importance of perinatal autopsy. Review of the literature and series of cases. *Romanian Journal of Morphology and Embryology*. 2017;**58**(2):323-337
- [44] Wilkinson K, Albanese CT, Jennings RW. Fetal neurenteric cyst causing hydrops: Case report and literature review. *Prenatal Diagnosis*. 1999;**19**:118-121



