

We are IntechOpen, the world's leading publisher of Open Access books Built by scientists, for scientists

6,900

Open access books available

185,000

International authors and editors

200M

Downloads

Our authors are among the

154

Countries delivered to

TOP 1%

most cited scientists

12.2%

Contributors from top 500 universities



WEB OF SCIENCE™

Selection of our books indexed in the Book Citation Index
in Web of Science™ Core Collection (BKCI)

Interested in publishing with us?
Contact book.department@intechopen.com

Numbers displayed above are based on latest data collected.
For more information visit www.intechopen.com



CO₂ Laser-Assisted Otoplasty: A New Dermatosurgical Procedure

Hector Leal Silva

Additional information is available at the end of the chapter

<http://dx.doi.org/10.5772/intechopen.71992>

Abstract

Otoplasty is the surgical procedure characteristically performed to improve the appearance of unpleasant, protruding auricles. An incision in the back of the ear with or without excision of cartilage is the usual approach. A novel technique performed with CO₂ laser is presented. The objective of CO₂ laser-assisted otoplasty is to decrease the mastoid-scapula angle up to approximately 30°; also, the conchal-scapula angle should be reduced to its usual of approximately 90°. The aims of this procedure are to restructure the scapula and the antihelix fold, to diminish the size of the concha (hinge effect), and to relocate the reshaped ear closer to the head in esthetically desired angles, not only horizontally (lateral angle), but also (and of extreme importance for most patients) vertically (superior angle).

Keywords: CO₂ laser, otoplasty, cosmetic surgery, correction of the angle of the ears, reduction of the ears

1. Introduction

Protuberant ears (apostasies, Otis) are one of the most common physical aesthetical variations (grade I abnormalities according to Weerda) of the head and neck regions, occasionally called otocleisis [1]. Actually the most frequent causes of this undesired condition are a disproportionately shaped cavity of the concha and an underdeveloped antihelical fold.

A large diversity of otoplasty methods have been described and all of them have the goal of recreating the normal facade of the ear and achieving symmetry. Current developments in otoplasty methods have steadily progressed in the direction of less to noninvasive procedures, from nonsurgical newborn ear molding to cartilage-sparing surgical techniques and even incisionless, office-based procedures [2].

2. Candidates and psychological specifics

Prominent ears are present in approximately 5% of the general population and can encompass a considerable psychological effect on individuals [2]. Children with protruding ears are often exposed to significant psychological stress, such as being bullied at school. Otoplasty can in general be implemented in patients aged 5 years and older (prior to the start of schooling), from the time when no significant growth or modification of the shape of the pinna can be expected. Otoplasty in pediatric patients has no significant influence on later auricular growth [3].

Kalcioglu et al. compared the growth ratios of the auricle in 1552 subjects from birth until age 18 years, assessing the longitudinal length (upper rim of the helix-lobule), the external transverse length (lateral rim of the helix-tragus), and the internal transverse length (outer rim of the antihelix-tragus), additionally measuring the conchal depth [4]. The development of the pinna regarding the transverse growth and the growth of the conchal depth was entirely completed by the age of 6 years. The length of the auricle increases during chronologic aging process because of the skin and soft tissue expected elasticity.

Schwentner et al. interrogated subjects pre- and postotoplasty concerning their emotional state, by means of a standardized questionnaire. The results of this retrospective revision demonstrated a significant enhancement in attitude toward life, greater than before courage to face life, and healthier self-confidence [5].

3. Anatomical aspects

The auricle anatomy is complex, by means of thin skin surrounding resilient cartilage. These fundamental characteristics make the ears prone to the unconcealed flaunt of surgical correction [6]. Multiple anthropometric studies have been carried out to determine the distance or to calculate the angles between the ear and the head (cephalo-auricular angles). The angle between the mastoid and the helix of a normal shaped auricle should not exceed 30° [7]. Numerous additional criteria for a suitably formed ear have been recommended by various authors: (1) the axis of the ear should be almost parallel to the bridge of the nose; (2) the position of the auricle should be approx. One auricular length behind the lateral orbital margin (55–70 mm); (3) the width of the auricle should be 50–60% of the auricular length (width: 30–45 mm, length 55–70 mm); (4) the anterolateral angle should be 21–30°; and (5) the lobule should be positioned parallel to the antihelical fold in the same plane [8]. In protruding ears, deviations from the normal shape are especially apparent at the antihelix, the concha, the mastoid-helix angle, and the lobule [9]. The angle between the mastoid and the helical rim should be between 20° and 30° according to Vargas [10]. In protruding ears, this angle can be up to 90°, due mainly to hyperplasia of the conchal bowl (**Figure 1**).

Subsequent to a detailed medical history, a thorough physical examination is performed to leave out potential treatable causes of prominent ears, for instance, retroauricular space-occupying lesions or traumatic deformity of the cartilage [11]. A meticulous examination of the antihelix fold, helix-mastoid angle, helix-head distance, position of the lobule, and depth,

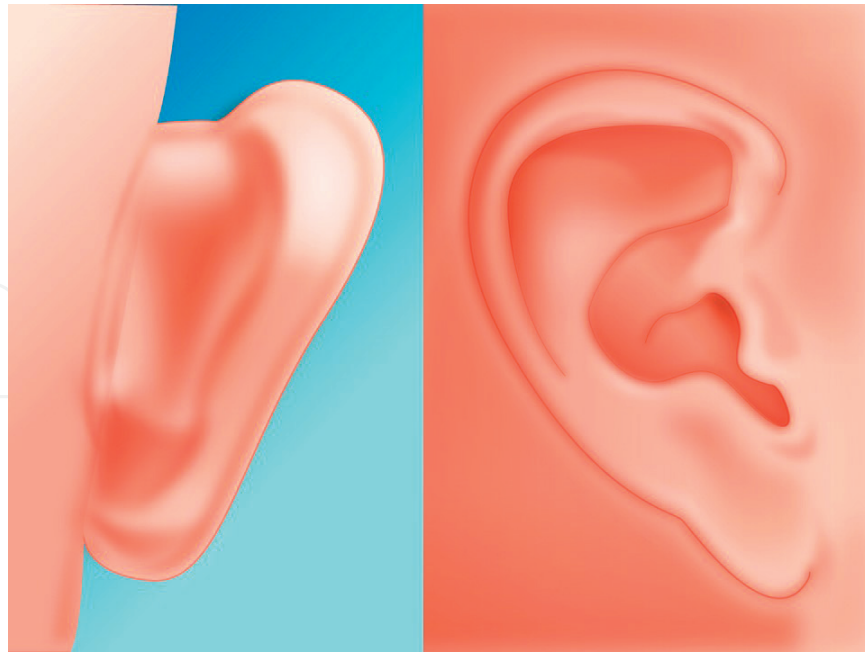


Figure 1. The aim of CO₂ laser otoplasty is to decrease the mastoid-scapha angle, and the conchal-scapha angle should be reduced.

size, and shape of the cavum conchae, is crucial (**Figure 2**). One more feature vital on procedure planning is the evaluation of the consistency of the cartilage and particularly its stiffness and thickness; the cartilage consistency is typically evaluated by palpation and careful bending. Additional abnormalities of the external ear, including auricular appendages or the existence of a Darwin tubercle, can also be discarded merely by physical inspection.

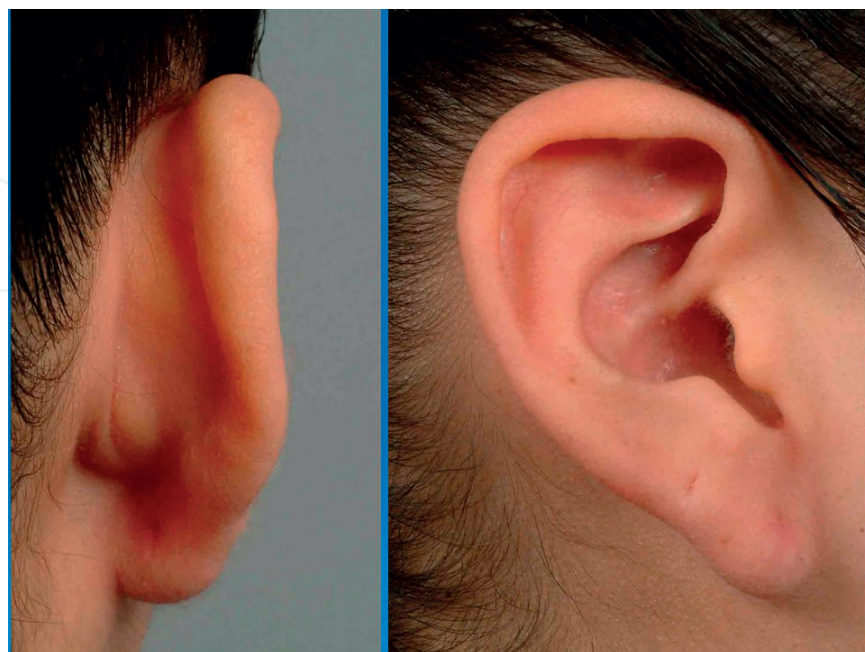

Figure 2. Cosmetically pleasing appearance of the ear.

4. History

During the nineteenth century, reports on surgical techniques described to improve prominent ears for esthetic purposes were published. Dieffenbach, in 1845, was among the first, describing a surgical technique to correct a posttraumatic prominent auricle in a patient. He excised retroauricular skin and used a concho-mastoidal suture for the fixation of the ear [12].

Following Dieffenbach, Ely published in 1881 a crescentic continuous resection of a cartilage strip in combination with a concho-mastoidal fixation suture. To correct bilateral prominent ears, Ely performed otoplasty as a two-step procedure [13].

A review article published by Weerda, including 94 publications on otoplasty techniques, makes it clear that the choice on the suitable procedure to improve protruding auricles can only be selected on an individual basis, taking in consideration all the variants associated with prominent ears [14].

In 1955, Converse published an excision surgical procedure with retroauricular access, supporting a spindle-shaped excision of a cartilage strip, sparing the anterior perichondrium, to reduce the concha [15]. Ultimately, of the numerous different surgical methods and their adaptations, three procedures, alone or combined, have demonstrated their efficacy in the amendment of protruding ears: Converse's incision-suture technique [15], Stenström's incision technique [16], and Mustardé's suture technique [17]. Beasley and Jones cut out the lower conchal bowl segment via a posterior access to diminish the height of the antitragus [18].

In 2007, during the 28th Annual Meeting of the International Society of Dermatologic Surgery in Venice, Italy, the author presented his initial experience using a proprietary surgical technique in 17 patients treated with CO₂ laser-assisted otoplasty with a follow-up of at least 6 months with very good to excellent outcomes in 15 of the 17 patients as reported by the subjects in a satisfaction questionnaire [19].

Holden et al. in 2009 published a minimally invasive ear reshaping with a 1450-nm diode laser using cryogen spray cooling in New Zealand white rabbits [20]. Next year Leclere et al. introduced a noninvasive laser-assisted cartilage reshaping (LACR) technique as an alternative to invasive surgical otoplasty using a 1540-nm laser. They concluded it was a safe and reproducible method for the treatment of protruding ears [21]. In the same year, Ragab described a new technique for prominent ears: carbon dioxide laser-assisted cartilage reshaping otoplasty in subjects with ages ranging from 4 to 7 years (mean 5.5 years), and an average follow-up of 2.4 years [22]. Leclere et al. later published a prospective long-term follow-up of 32 procedures of LACR [23].

Mehta and Gantous published a laser-assisted incisionless otoplasty, a technique for the correction of prominauris. In their article, complications were reported in 10 of 70 patients [24]. The enormous quantity of ever-evolving otoplasty surgical and nonsurgical procedures evidenced its complexity.

5. Method

Our approach to this procedure is centered on the antihelix, particularly on the antihelical fold, the concha, and the scapha of the auricle, where usually the disproportion and excessive angulations of the ear reside. In order to attain a cosmetically pleasing appearance, the proportions of the ear ought to be carefully observed as a whole in the midst of the face and head shape. Asymmetries should also be carefully considered in surgical planning. Asymmetries and individual characteristics should be discussed with the patient, documented, and considered at this point. Planning includes determination of the shape, size, and position of both auricles, from every possible angle.

Naumann [25] described a useful algorithm preotoplasty for the evaluation of the ear and the planning of the procedure, recommending that attention should be paid to the following parameters:

1. Helix-mastoid angle ($>30^\circ$)
2. Helix-mastoid distance:
 - a. Cranial helical rim;
 - b. Helical rim at the level of the cavum conchae;
 - c. Lobule ($>18\text{--}20\text{ mm}$)
3. Hypoplastic antihelix, antihelical folding
4. Conchal hyperplasia, cavum conchae
5. Position of the lobule
6. Isolated changes at the ear: coloboma, Darwin tubercle, auricular appendage
7. Cartilage consistency:
 - a. Soft, easily pliable cartilage;
 - b. Thick, stiff, poorly pliable cartilage
8. First intervention or revision
9. Tendency to develop keloids
10. Age of patient

Prior to the laser-assisted procedure, patients or parents of the child are informed about the different surgical techniques available and the potential risks and complications, including hematoma and infections or necrosis of skin or cartilage, and also regarding the possibility of an unsatisfactory cosmetic result, or latent abnormal scarring.

Pre- and postoperative photographic documentation in frontal, lateral, oblique, and dorsal views for further assessment is an absolute requirement for the procedure. The uses of photographic documentation are to document preoperative condition and can also be used to outline problematic areas or phases of the laser-assisted procedure. Postoperative photos at intervals of 6 and 12 months help assessing postoperative outcome and are also recommended for medicolegal reasons [26].

The first step of the procedure is to mark unmistakably where the incisions are going to be made. To diminish the cavum-mastoid angle is necessary to bring back the ear closer to the cranial bone. A retroauricular incision parallel to the helical rim should be performed, and usually only a single incision is required, although in some cases a secondary incision is mandatory. The marks are made in of the posterior face of the ear; the main mark should be done following the posterior auriculocranial fold starting right behind the upper insertion of the ear, up to midportion of the auricular lobule. This mark should stay as close as possible to the fold, unless the patient has some excess skin in that area, and then, the mark can be made 2 or 3 mm further back, directly on the cephalic skin; then, the line for auricular incision is calculated and marked, observing how much excess of skin would have to be removed to complete the desired correction. This can be done manually by simulating the position of the ear that is to be achieved, outlining the ideal extension of the incision and the skin fold to be removed with the laser (**Figure 3**). Marking planning usually compensates previously assessed asymmetries.

When needed, the marking of a secondary incision is made on the dorsal face of the scapha, close to the tip of the ear following the curve of the antihelix. Its dimensions should be proportional to the desired degree of correction for that particular area. The reason for a secondary incision is if the patient has a disproportion in the shape and size of the scapha and an

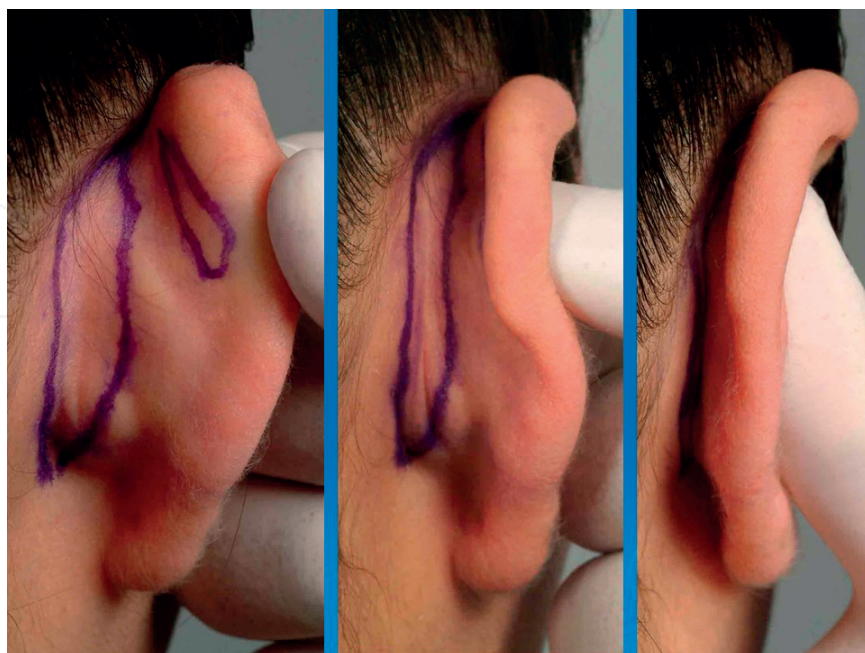


Figure 3. Manual simulation of the corrected position of the ear is used to correctly mark the incisions.

underdeveloped helix and antihelix fold (**Figure 4**), leading to a drooping and forward tilting of the tip of the ear. In some cases, this secondary incision may be unilateral.

Marking includes not only the dorsal side of the ear where the main and secondary incisions will be placed, but also the ventral side of the ear to be infiltrated in the concha and the scapha. A careful planning on the incision will lead to a full correction of the position, angles, and size of the ears, without tension and with an excellent esthetical outcome (**Figure 5**).

After marking, antisepsis is applied to the entire area and adhesive separators are placed to keep the area clear of hair. Sterile tape can be used to delimit the area around the sterile fields to later apply the local anesthetic.

The surgical correction of protruding ears in older children starting from 8 years of age, or adults with adequate compliance can be performed under local anesthesia alone; in smaller children or noncompliant adults, IV sedation is the preferred anesthetic method to complement local anesthesia. General anesthesia can also be used [27].

The local anesthesia employed usually consists of a dose of approximately 5 ml of lidocaine 2% with epinephrine 1:200,000; it is infiltrated subcutaneously in a fan-shaped pattern on the dorsal surface of each ear, directly on the retroauricular fold.

Additional infiltration in the ventral surface of the ears, always on the concha and sometimes on the scapha, is essential for this procedure (**Figures 6 and 7**). It is required that infiltration results in a precise separation of the skin and the perichondrium (hydro-dissection). Since CO₂ laser's chromophore is water, this infiltration will later serve as a natural block for the laser beam to prevent or reduce the incidence of accidental injuries on the ventral skin of the auricle.

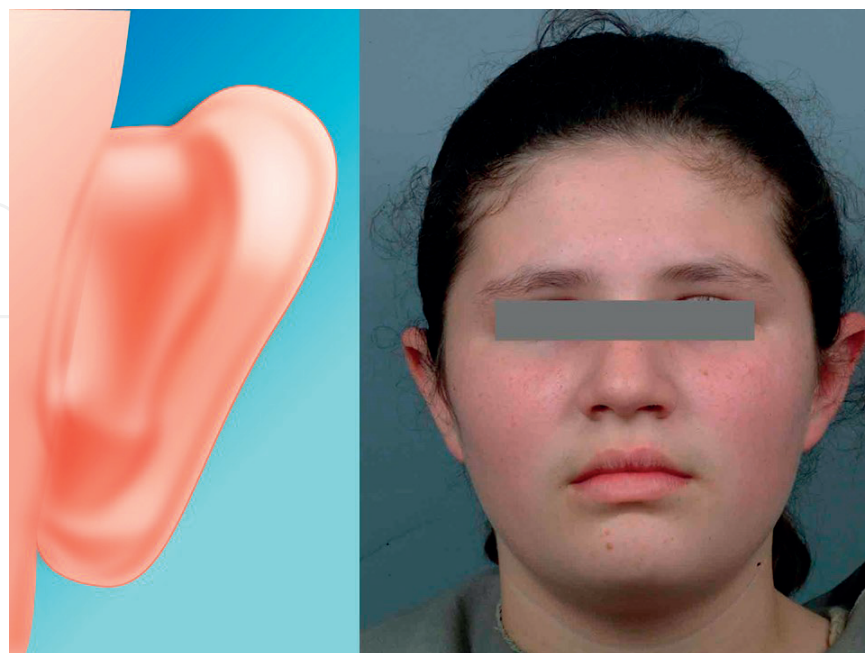

Figure 4. Drooping and protruding tip of the ear and asymmetry.

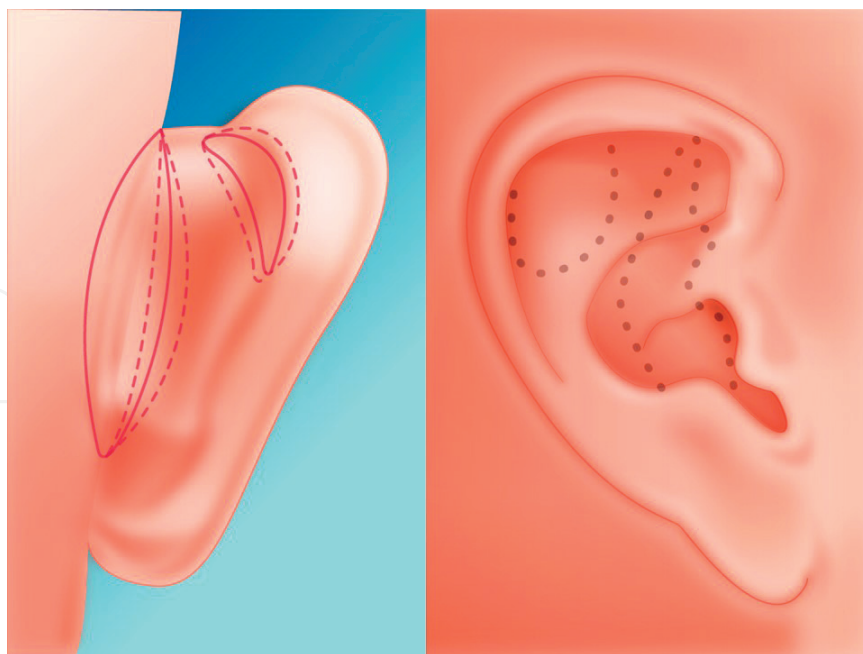


Figure 5. Examples of possible markings for the primary and secondary incisions in the dorsal face of the ear, and areas of infiltration for hydrodissection of ventral face of ear.

The retroauricular skin incisions can be extended from the upper insertion of the ear to the middle of the lobule (depending on the lobule shape), and skin excisions are then performed to the extent needed in each case [28]. The shape and extension of the incisions is directly proportional to the extent to which the auricle protrudes. The main incision is placed directly on the retroauricular fold, and it must extend superiorly as much as the superior angle needs to be fully corrected (if not carefully considered, patient's expectations may not be fulfilled; the degree the ears face downwards is usually more important to the patient than what they face forwardly). A secondary incision in the dorsal side of the scapha is sometimes required to fully correct the shape and angle of the ear.

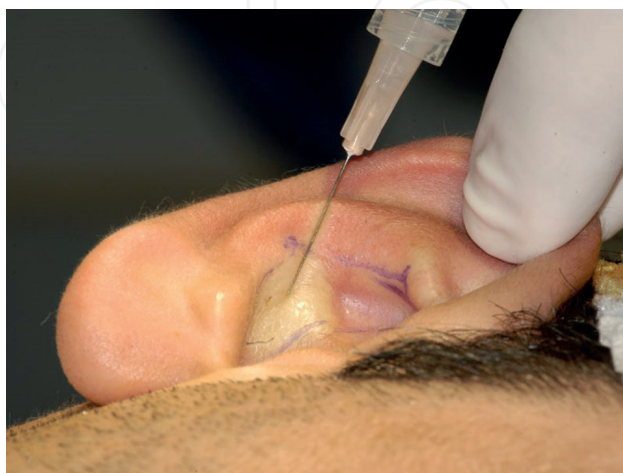

Figure 6. Infiltration of lidocaine 2% with epinephrine 1:200,000 is infiltrated subcutaneously in the concha.

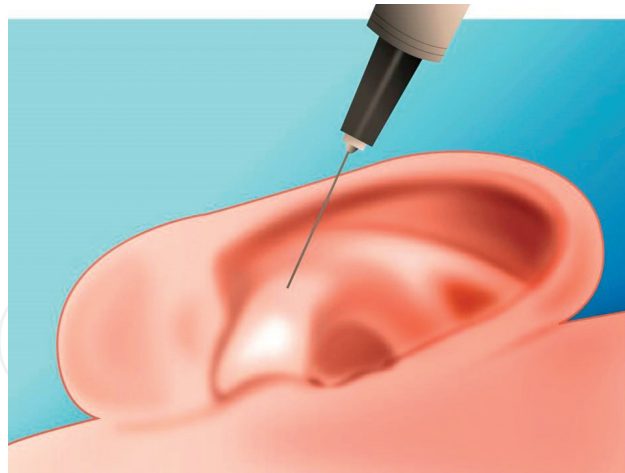


Figure 7. Schematic infiltration of the concha.

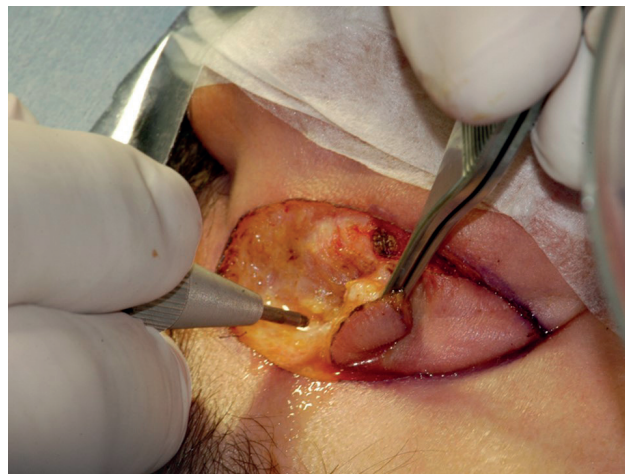


Figure 8. Incision is made directly with the CO₂ laser, layer by layer, up to a complete epiperichondral mobilization of skin and subcutaneous tissues on the dorsal side of the ear.

Incision is made directly with a high-fluence surgical narrow beam CO₂ laser (10,600 nm wavelength), layer by layer; the posterior auricular muscle is transected, and excessive retro-auricular subcutaneous fat and connective tissue is removed up to an epi-perichondral level, completely sparing the temporal fascial, and the posterior aspect of the cartilage in a caudal direction up to the mastoid plane is prepared (**Figure 8**) [29].

The amount of cartilage that is to be removed from the concha (usually 4–9 mm width), medial to the antihelix, depends on the incision that was planned, based on the amount of skin that is to be removed as well as the amount of pressure required to bend the ear properly (hinge effect). For precise marking of the perichondrium, as reference to limit the angles of the cartilage cut, two 30 G × ½ inch needles are inserted at the edges and mid-depth of the concha, transecting the auricle from the ventral side.

The marked window of cartilage is slightly incised with the laser (**Figure 9**) then blunt dissection of the cartilage is performed using tenotomy scissors with blunt tip, the cartilage

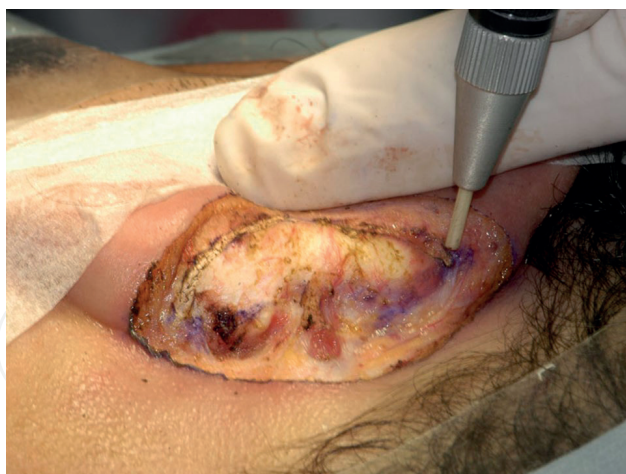

Figure 9. The cartilage is slightly incised with the laser.

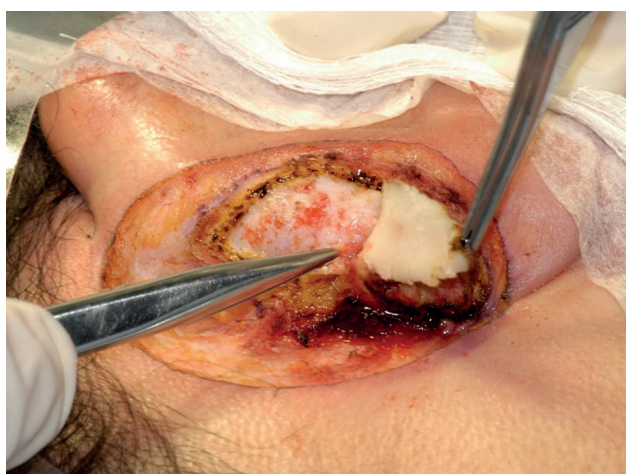

Figure 10. A window of cartilage is excised after blunt dissection.

window is then removed (**Figure 10**); adequate hemostasis of the area is key to a successful outcome; carbonized tissue should be removed (it interferes and retards wound healing process).

The same procedure is made on the dorsal side of the scapha if required. The shape of this secondary incision is determined by the degree of disproportion of the scapha and the need of correction of the conchal-scapha angle.

Then, the auricle is bent dorsally and fixed between the conchal cartilage and the dorsal mastoid periosteum, by means of mattress sutures. The wound must be closed with vicryl or monocryl, 3–0 or 4–0 sutures, depending on the strength of the cartilage and the width of the wound. The first stitch should join both edges of the posterior auricular muscle, from the perichondrium to the mastoid periosteum (**Figures 11** and **12**). After this first buried mattress suture, the desired back angle of the ear should have been achieved; if at this point the angle of the ear has not been corrected properly, then the surgeon should go back and

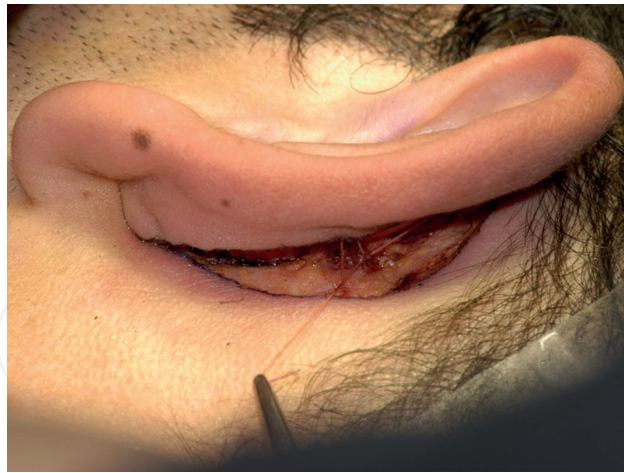

Figure 11. Surgical wound closure is made in two layers subcutaneously using a 4–0 vicryl absorbable suture starting at the posterior retroauricular muscle.

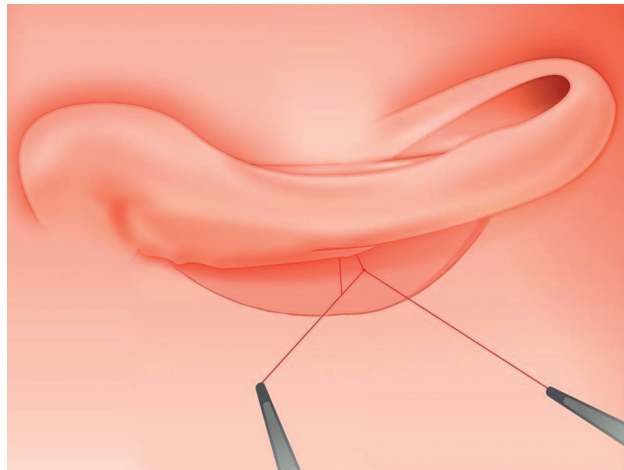


Figure 12. Buried mattress sutures are used to close the wound.

remove more skin and/or subcutaneous tissue or even cartilage as required (**Figure 13**). The same applies for the superior area of the incision, where one or two mattress sutures should correct adequately the lateral dropping of the superior portion of the ear (**Figure 14**). Once the subcutaneous suture is completed, cyanoacrylate glue is applied to the skin or a closed continuous intracutaneous suture (5–0 monocryl) is used to close the skin. No difference has been observed than our previous approach, which was to use continuous intracutaneous 5–0 prolene suture, with the inconvenience of the suture removal after 10 days.

No dressing is used after this outpatient procedure. One of the advantages of this technique is that there is no need to use any type of bandage or patches, nor does it depend on permanent sutures or bandages to force the fold of the cartilage to hold in place. A broad spectrum antibiotic can be used as prophylactic (the author usually prescribes azithromycin orally for 3 days postoperatively). Usually no postoperative analgesics are required. The patient is assessed in a week.

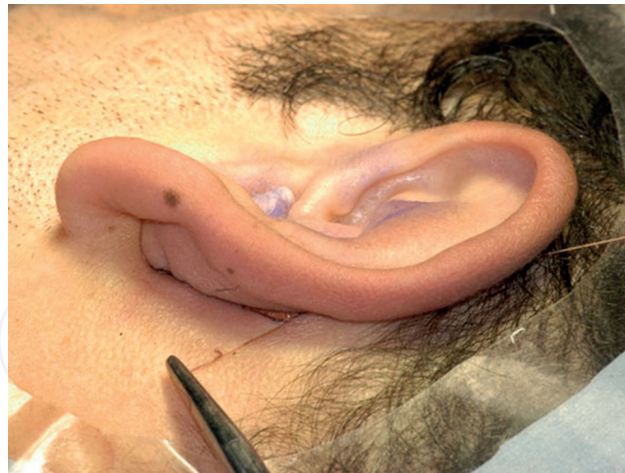

Figure 13. Complete correction of the angle with the initial suture.

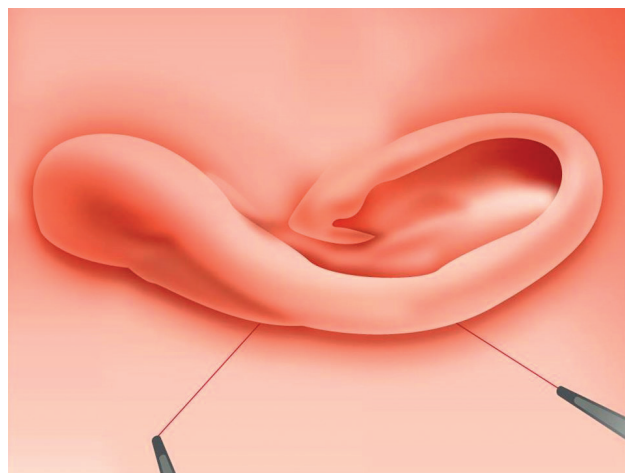


Figure 14. Additional mattress sutures are used to complete the stitching of the wound.

Early and late complications of otoplasty can be distinguished. Early complications include hematomas, and wound infection, which may be associated with perichondritis, pain, postoperative bleeding, allergic reactions, and cartilage or skin necrosis. In contrast, hypertrophic scars, keloids, suture material rejection, hypoesthesia or paresthesia, auricular deformities, or recurrence arise as late complications. Regular examination follow-up visits are strongly suggested, for early detection of complications [8, 14, 30]. With the previously described surgical CO₂ laser procedure, none of the published or any other complications has been observed nor reported by the patients. Postoperative indications include sleep in a Low Fowler's position the first 3–5 days, limit physical exercise, and the use of a travel pillow for neck support, avoiding pressure on the ears for approximately 10 days.

Swelling and bruising are expected side effects that usually last about 10 days. Moderate inflammation will usually persist for 3 weeks, and a very mild inflammation can persist up to 4 months. The final result is reached, as in most procedures, between the 5th and 6th months, although some changes may continue to develop up to 12 months postoperatively.

6. Commentaries

We did re-intervene a couple of the first patients, and due to inexperience, we considered important only the lateral back angle and did not take into account the superior angle of the ear. These patients were treated afterward, and esthetic expectations were met using secondary incision

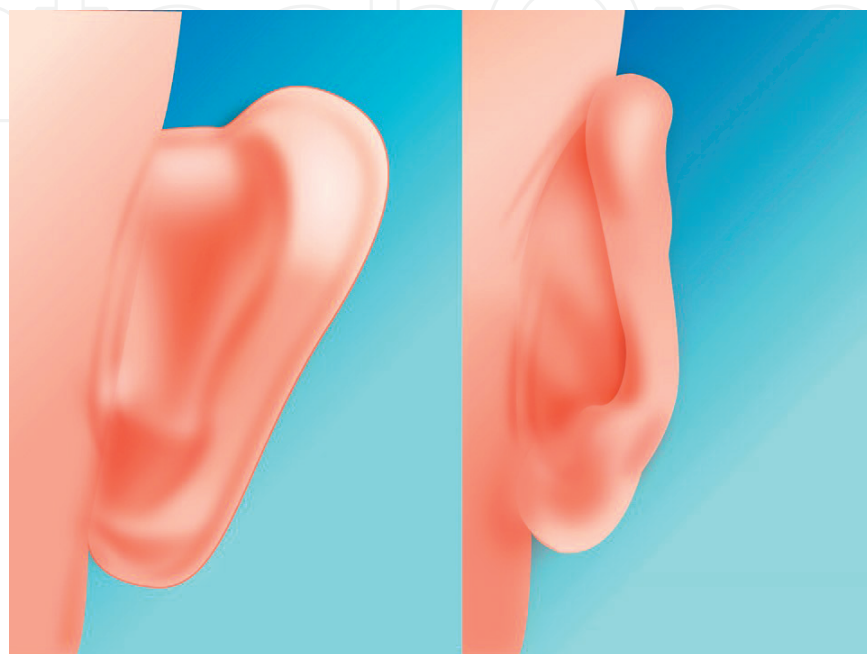


Figure 15. Schematic correction of a protruding ear from a dorsal view.

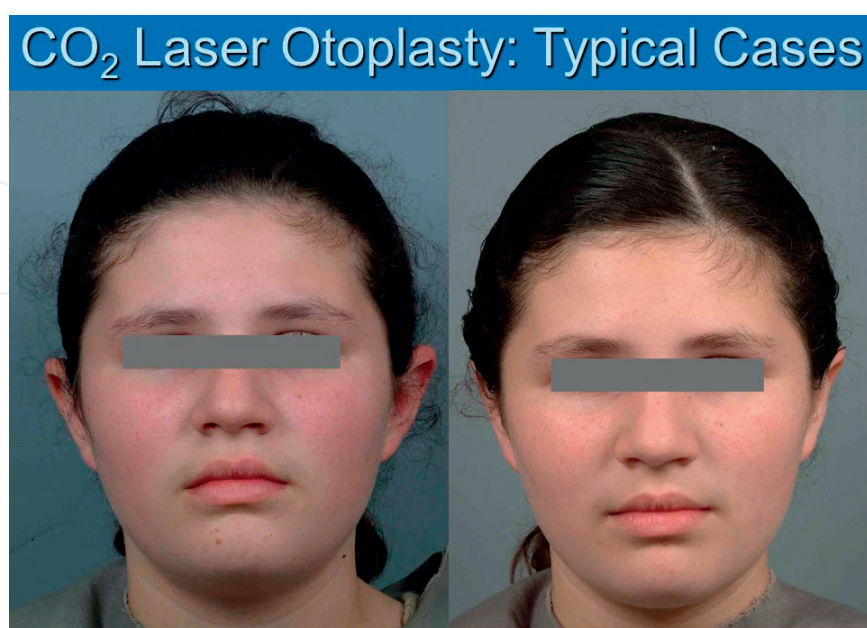


Figure 16. Before and 12 months after a CO₂ laser-assisted otoplasty.

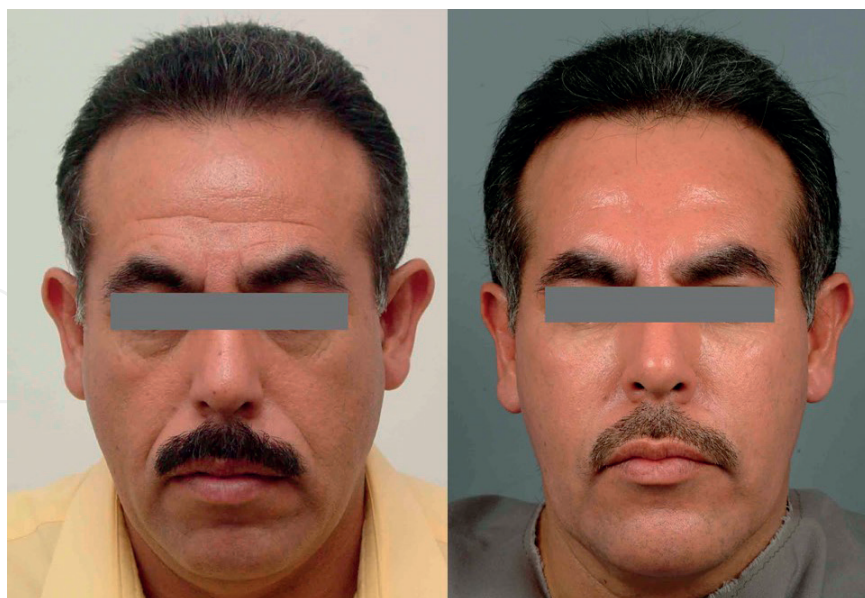


Figure 17. Before and 12 months after a CO₂ laser-assisted otoplasty.

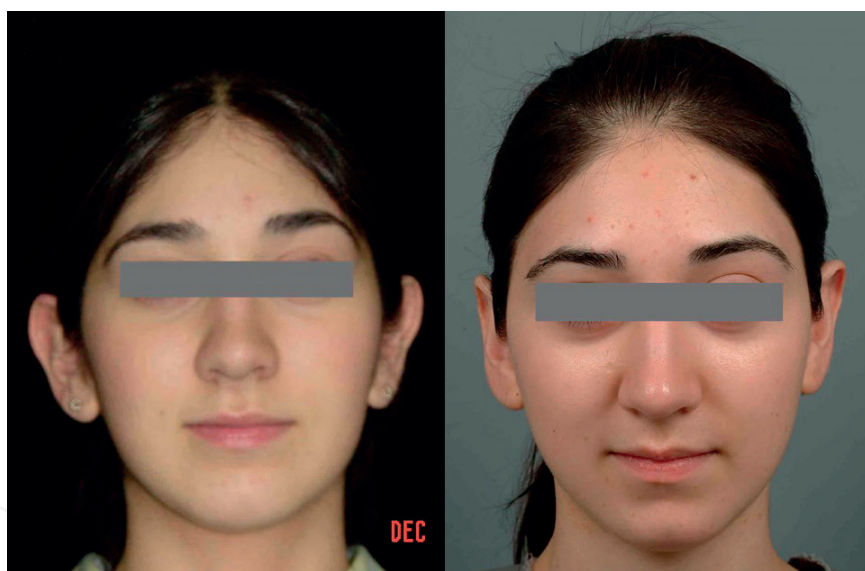

Figure 18. Before and 12 months after a CO₂ laser-assisted otoplasty.

in the back of the scapha. With time we learned that in most cases, there was no need for a secondary incision to correct a drooping ear due to the fact that more skin can be easily removed from the dorsal face of the ear in the superior area of the main incision (usually 1–1.5 cm). This can, in most cases, correct a drop or forward tilt of the superior area of the ear (**Figure 15**).

The secondary semilunar incision, parallel to the helix, is now reserved for cases where clearly there is a disproportional growth of the scapha or an almost absolute lack of the

superior aspect of the antihelical fold and an underdeveloped helix. Per each case's particular needs, a second incision can be performed and a part of the cartilage removed to create a crease or fold to reduce the ear's tip size and force a posterior displacement (Figures 16–22).

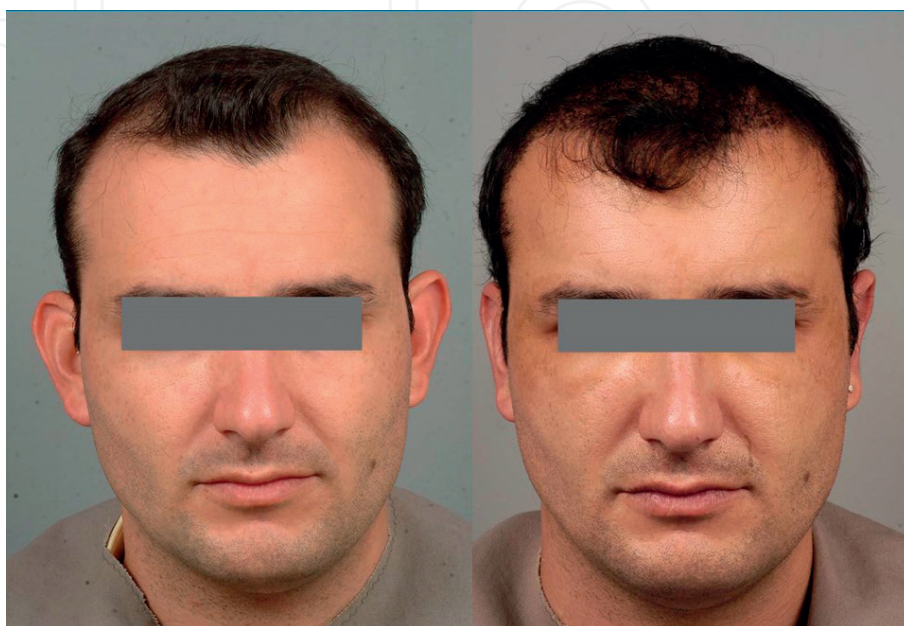

Figure 19. Before and 12 months after a CO₂ laser-assisted otoplasty.

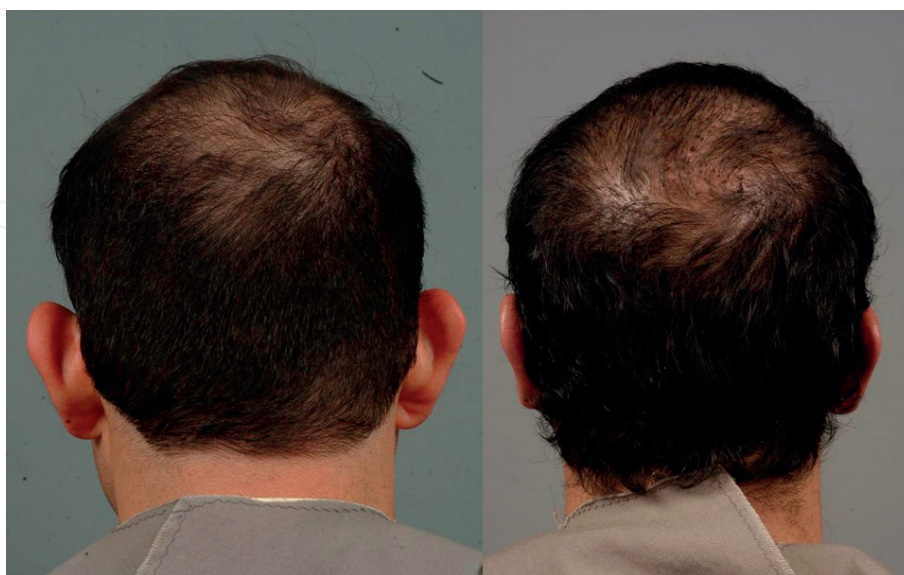

Figure 20. Before and 12 months after a CO₂ laser-assisted otoplasty.

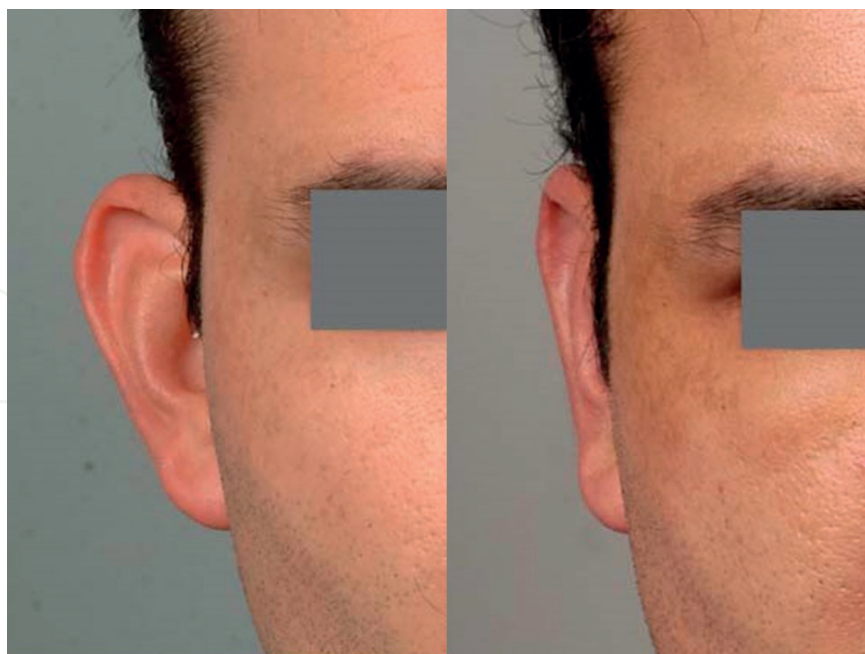


Figure 21. Before and 12 months after a CO₂ laser-assisted otoplasty.

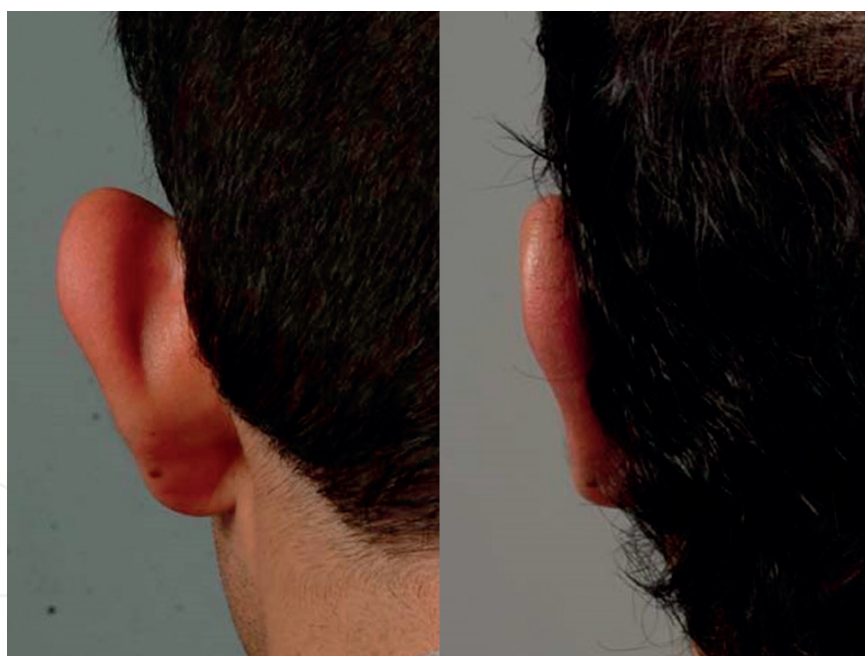

Figure 22. Before and 12 months after a CO₂ laser-assisted otoplasty.

7. Conclusion

Surgical CO₂ laser-assisted otoplasty is presented as a simple, effective, and highly safe novel approach to enhance ear cosmetics for the treatment of esthetically displeasing protruding and/or prominent ears.

Author details

Hector Leal Silva

Address all correspondence to: hleal@ultralaser.com.mx

University of Monterrey, San Pedro Garza García, Mexico

References

- [1] Weerda H. Remarks about otoplasty and avulsion of the auricle. *Laryngo-Rhino-Otologie*. 1979;**58**(3):242-251
- [2] Pawar SS, Koch CA, Murakami C. Treatment of prominent ears and otoplasty: A contemporary review. *JAMA Facial Plastic Surgery*. 2015;**17**(6):449-454
- [3] Balogh B, Millesi H. Are growth alterations a consequence of surgery for prominent ears? *Plastic and Reconstructive Surgery*. 1992;**90**(2):192-199
- [4] Kalcioğlu MT, Toplu Y, Özturan O, Yakinci C. Anthropometric growth study of normal human auricle. *International Journal of Pediatric Otorhinolaryngology*. 2003;**67**:1169-1177
- [5] Schwentner I, Schmutzhard J, Deibl M, Sprinzl GM. Health-related quality of life outcome of adult patients after otoplasty. *Journal of Craniofacial Surgery*. 2006;**17**:629-635
- [6] Handler EB, Song T, Shih C. Complications of otoplasty. *Facial Plastic Surgery Clinics of North America*. 2013;**21**(4):653-662
- [7] Farkas LG. Anthropometry of the normal and defective ear. *Clinics in Plastic Surgery*. 1990;**17**:213-218
- [8] Janis JE, Rohrich RJ, Gutowski KA. Otoplasty. *Plastic and Reconstructive Surgery*. 2005;**115**(4):60e-72e
- [9] Siegert R, Krappen S, Kaesemann L, Weerda H. Computer assisted anthropometry of the auricle. *Faces*. 1998;**6**:1-6
- [10] Wodak E. On the position and shape of the human auricle. *Archiv für Klinische und Experimentelle Ohren-, Nasen- und Kehlkopfheilkunde*. 1967;**188**:331-335
- [11] Payasli C, Babuccu O, Kargi E, Hosnutter M, Tekerekoglu B. Traumatic prominent ear secondary to cartilage fracture without skin laceration or hematoma. *Plastic and Reconstructive Surgery*. 2006;**117**(3):1052-1053
- [12] Dieffenbach JE. *Die Operative Chirurgie*. Leipzig: Brockhaus FA; 1845
- [13] Ely ET. An operation for prominent auricles. *Archives of Otolaryngology*. 1881;**10**:97
Reprinted in *Plastic and Reconstructive Surgery*. 1968;**42**:582
- [14] Weerda H. *Chirurgie der Ohrmuschel*. Vol. Bd. 1. Stuttgart: Thieme; 2004

- [15] Converse JM, Nigro A, Wilson FA, Johnson N. A technique for surgical correction of lop ears. *Plastic and Reconstructive Surgery*. 1955;**15**:411
- [16] Stenström SJ. A “natural” technique for correction of congenitally prominent ears. *Plastic and Reconstructive Surgery*. 1963;**32**:509
- [17] Mustardé JC. The treatment of prominent ears by buried mattress sutures: A ten-year survey. *Plastic and Reconstructive Surgery*. 1967;**39**:382
- [18] Beasley NJ, Jones NS. Otoplasty: The problem of the deep conchal bowl. *Journal of Laryngology & Otology*. 1996;**110**(9):864-868
- [19] Leal H. 28th Annual Meeting. Venice, Italy. ISDS. 26-10-2007
- [20] Holden PK, Chlebicki C, Wong BJ. Minimally invasive ear reshaping with a 1450-nm diode laser using cryogen spray cooling in New Zealand white rabbits. *Archives of Facial Plastic Surgery*. 2009;**11**(6):399-404
- [21] Leclere FM, Petropoulos I, Mordon S. Laser-assisted cartilage reshaping (LACR) for treating ear protrusions: A clinical study in 24 patients. *Aesthetic Plastic Surgery*. 2010;**34**(2):141-146
- [22] Ragab A. Carbon dioxide laser-assisted cartilage reshaping otoplasty: A new technique for prominent ears. *The Laryngoscope*. 2010;**120**(7):1312-1318
- [23] Leclere FM, Trelles M, Mordon SR. Cartilage reshaping for protruding ears: A prospective long term follow-up of 32 procedures. *Lasers in Surgery and Medicine*. 2011;**43**(9):875-880
- [24] Mehta S, Gantous A. Incisionless otoplasty: A reliable and replicable technique for the correction of prominauris. *JAMA Facial Plastic Surgery*. 2014;**16**(6):414-418
- [25] Naumann A. Otoplasty—techniques, characteristics and risks. *GMS Current Topics in Otorhinolaryngology, Head and Neck Surgery*. 2007;**6**:Doc04
- [26] Spira M. Otoplasty: What I do now — A 30-year perspective. *Plastic and Reconstructive Surgery*. 1999;**104**(3):834-841
- [27] Ganzer U. Leitlinien “Ohrplastik” online. 2003. Konsensusbericht der Deutschen Gesellschaft für Hals-Nasen-Ohren-Heilkunde, Kopf- und Hals-Chirurgie: Plastisch-rekonstruktive und ästhetische Operationen in der Hals-Nasen-Ohren-Heilkunde, Kopf-Hals-Chirurgie
- [28] Kelley P, Hollier L, Stal S. Otoplasty: Evaluation, technique, and review. *Journal of Craniofacial Surgery*. 2003;**14**(5):643-653
- [29] Furnas DW. Correction of prominent ears by conchamastoid sutures. *Plastic and Reconstructive Surgery*. 1968;**42**:189
- [30] Elliott RA Jr. Otoplasty: A combined approach. *Clinics in Plastic Surger*. 1990;**17**(2):373-381