

We are IntechOpen, the world's leading publisher of Open Access books Built by scientists, for scientists

6,900

Open access books available

186,000

International authors and editors

200M

Downloads

Our authors are among the

154

Countries delivered to

TOP 1%

most cited scientists

12.2%

Contributors from top 500 universities



WEB OF SCIENCE™

Selection of our books indexed in the Book Citation Index
in Web of Science™ Core Collection (BKCI)

Interested in publishing with us?
Contact book.department@intechopen.com

Numbers displayed above are based on latest data collected.
For more information visit www.intechopen.com



Dental Anatomical Features and Caries: A Relationship to be Investigated

Marcel Alves Avelino de Paiva,
Dayane Franco Barros Manguiera Leite,
Isabela Albuquerque Passos Farias,
Antônio de Pádua Cavalcante Costa and
Fábio Correia Sampaio

Additional information is available at the end of the chapter

<http://dx.doi.org/10.5772/intechopen.71337>

Abstract

Dental caries is a multifactor disease affecting a significant number of people throughout the world. However, in recent decades the widespread availability of fluoride and other preventive measures have resulted in a decline in the prevalence of caries among children and young adults. Currently, it is accepted that most carious dental lesions are restricted to specific anatomical sites. The aim of this chapter is to review the influence of dental anatomy on dental caries development while taking into account recent findings in cariology. Occlusal fissures in the first permanent molar are generally the first sites in the permanent dentition to develop caries. An increased risk of caries is also found in proximal contacting surfaces between two adjacent teeth. Moreover, a partially erupted tooth, which does not participate in mastication, is also at risk for caries since it may provide a more favorable environment for bacterial accumulation than a fully erupted tooth. Bacterial biofilm on the tooth is frequently a high risk caries environment. Understanding anatomical dental features is of great importance for guiding oral health hygiene and preventive measures. Finally, the development of dental disorders plays an important role in dental caries risk.

Keywords: bacterial biofilm, dental anatomy, dental caries, dental morphology, tooth surfaces

1. Introduction

Dental caries affects a significant number of populations throughout the world as a multifactor disease that is by and large regarded as the most common chronic disease worldwide [1]. It is estimated that 90% of dental problems are due to caries. However, the prevalence of dental caries is variable and may be linked to cultural aspects, education level, income, and dietary habits.

The disease known as dental caries is generally defined as a “localized destruction of susceptible dental hard tissues by acidic by-products from bacterial fermentation of dietary carbohydrates” [1]. In this definition, two important etiological factors are presented: dietary carbohydrates and bacterial fermentation both need clarification concerning their *modus operandi*, and “localized destruction” of dental hard tissues is also a matter to be studied.

A remarkable study on diet and prevalence involving dental caries is performed 60 years ago by Gustafsson and co-workers [2]. Apart from the present perspectives concerning ethical issues when conducting clinical trials, the Vipeholm study clearly showed that dental caries are strongly tied to the availability of refined sugar. This was particularly evident for sugar intake between meals. It is important to point out that at the time, the scientific community was skeptical concerning the preventive effects of reductions of sugar intake on the formation of caries [3]. The idea that caries is not only a sugar-driven disease, but actually is a sugar-disease, has been strongly defended [4]. Assuming this hypothesis, certain researchers regard dietary sugars as the main cause for the development and establishment of caries.

In addition to sugar, the development of caries is clearly dependent on dental plaque activity. Recent advances regarding the process of dental decay have indicated that so-called “dental plaque” is in fact a “dental biofilm” [5]. The dental biofilm concept supports the idea of an organized microbial community. Thus, a change in nomenclature is not just toward a new name, but represents true conceptual modifications in several aspects. Today, bacterial biofilm is regarded as a sort of microcosm of bacteria and fungi both living and competing within a complex matrix. In order to support this point of view, caries is no longer seen as related to a single bacterium species. For many years, *Streptococcus mutans* the most relevant sugar-fermenting, acidogenic species was regarded as the main causative agent of dental caries. However, recent investigations have shown that dental caries are related to a significant and diverse ecosystem and surprisingly, *S. mutans* is just a small fraction of the bacterial community [5]. It is also important to consider that in most situations, the microorganisms of the dental biofilm are not pathogenic. In fact, certain bacteria are necessary since a “healthy” biofilm forms naturally on teeth and helps to avoid colonization by exogenous species. If refined sugar is available, bacterial acid production increases resulting in an immediate pH drop. Demineralization takes place in an acidic environment. Frequent cariogenic challenges result in mineral loss and development of carious lesions. Bacterial acid production and its consequences for the delicate balance between de- and re-mineralization had generally been assumed to be ecological phenomena [5, 6]. However, as already noted, it is the communal life itself as formed by these multiple microorganisms that collectively promotes carious lesion development.

Though dental caries is ubiquitous in many populations of the world, there is an evident decline in the prevalence of caries in many countries. This was quickly observed in industrialized and developing nations. The main reasons for this decline in caries is related to two factors: (a) the widespread use of fluoridated products, particularly through the effective introduction of fluoride in toothpastes and (b) individual commitment to oral hygiene habits, in other words, more people maintain reasonably good levels of oral hygiene throughout their lives [7, 8]. Yet surprisingly, in many countries where declines in caries were observed, sugar intake remained stable [9, 10].

The prevalence of dental caries is frequently measured by epidemiological indexes such as the DMFT. This index quantifies dental caries based on the number of carious or decayed (D), missing (M), or filled (F), teeth (T). The DMFT index does not provide information regarding carious attack severity, nor does it provide useful information concerning the surfaces of teeth where carious lesions occur. Therefore, the epidemiological index DMFS (decayed, missing, and filled by surface), and other forms of measurement have been proposed [11].

This decline in caries has raised certain interesting challenges for dental professionals. For many individuals of the same age, the progression of carious lesions is no longer as fast as previously recorded. Thus, simply recording caries as a cavitated lesion is no longer the study or clinical assessment end point. Further, there is now confusion in the terminology used in many studies dealing with caries (e.g., “caries diagnosis” versus “caries lesions detection”) [11, 12].

Dental caries can be scored in various levels of severity ranging from white spot lesions to full cavitation. Caries diagnosis can be considered a multiple step procedure, starting with identification of the candidate lesion (caries detection), followed by assessment of lesion severity, and finally, determination of lesion activity [12]. These are the main components guiding the establishment of an appropriate treatment plan (operative or non-operative) for contemporary primary or secondary caries management. Caries risk assessment, diagnosis, and synthesis (combining and interpreting findings) are considered to be the chief domains in Cariology, and the basis of clinical decision-making [13].

Currently, all research in dental caries prevention, development or treatment should on one hand, consider the influence of fluoride on the general decline in caries, and on the other hand evaluate the most relevant etiological factors. A third point concerning preventing dental caries must also be considered: a good understanding of dental anatomy. Complete recovery of tooth function can only be achieved if a good knowledge of dental anatomy is applied. In addition, the science of dental anatomy is also important for understanding carious risk to a specific tooth, or to specific areas within the mouth [14].

Dental caries is a disease mediated by biofilm and pH that affects people from all over the world. Sugar intake patterns are also important and may explain why some people have more caries than others. Caries may also affect socially vulnerable individuals more than those who can afford to maintain oral hygiene habits. As caries disproportionately affect certain groups of individuals, the same is true for certain groups of teeth. Why do caries affect molars more than incisors? Why are caries more prevalent in occlusal surfaces as compared to free and smooth surfaces? This is where dental anatomy and caries meet. The aim of this chapter is to review certain features of dental anatomy and their influence on the progression of dental caries.

2. Principles of cariology: dental caries reviewed

Cariology is generally known as the study of dental caries or tooth decay. Yet for many dental students, cariology is not a true clinical science, since it is (at least in most cases) presented only at the beginning of the undergraduate course, or merely as a research project. However, recent developments provide new perspectives to this field. Cariology is not confined to dental caries alone. Cariology includes research in dental hard tissues, dental wear (erosive/non-erosive), and dental hard tissue disorders [13]. This wider view of cariology opens new perspectives in dental education and research, being a strong motive for improving diagnostic skills, while treating and preventing carious lesions in more effective ways [15, 16].

2.1. Dental caries

Dental caries is ubiquitous worldwide. It is a sugar-driven, biofilm-dependent, multifactor disease, and in many aspects a dynamic process. The continuous presence of pathogenic oral biofilms is the main etiological factor for demineralization and as stated before, certain reports give emphasis to dietary sugars as the main cause for dental caries [4, 17–19]. However, other etiological factors cannot be neglected [20]. For instance, the presence of sugar alone on a free biofilm dental surface will not result in dental caries. Dental caries results from a shift in local environment acidity promoted by microbial metabolism on a tooth surface. Mineral loss on a tooth surface is so subtle in the beginning that even very sensitive techniques are unable to indicate when a carious dental lesion has started. Frequent mineral losses eventually become a pit or a small cavitation [21].

The major factors involved in the dental caries mechanism are well understood. Presently, it is accepted that dental biofilms play a central role in dental caries. Dental caries appear on the tooth only where dental biofilms are found. It is also true that demineralization is provoked by microorganism produced acids, and the degree of mineral loss is directly modulated by both the presence and activity of these dental biofilms. Demineralization can be interrupted or reverted toward remineralization (a mineral recovery process) when the biofilm is either partial or totally removed [22]. This is a time-dependent complex process not a single event. Dental caries is always described as a chronic and progressive demineralization of hard tissues that occurs in tooth surfaces underneath a microorganism layer.

The pathogenesis of dental caries is driven by the establishment of a dental biofilm and formation of an acidogenic environment [20–24]. Frequent de-mineralization events due to repeated cycles of lactic acid production will eventually cause severe dissolution of the tooth enamel or dentin. As a result, white spots begin to appear underneath pathogenic biofilms. In most cases, the process takes several months, but it can occur in few weeks if the tooth surface is exposed to extreme cariogenic challenges. Interestingly, just as the microbial composition of dental biofilms can shift as driven by diet, or through biofilm removal (oral hygiene), the microbial community can also vary from site-to-site within the mouth, as between individuals.

Clinical microbiology studies have demonstrated that Mutans streptococci, especially *S. mutans*, are more prevalent in children who have experienced dental caries during childhood [21]. Yet not all children who develop caries are colonized with Mutans streptococci. The observations provide a clear indication that dental caries are a result of a very complex

process influenced by the interplay of many variables such as oral microbiota, saliva, dietary patterns, and oral hygiene habits [25, 26]. The most recent consensus is that microbial diversity appears to be lower in diseased than in healthy individuals and may reflect the ecological pressure of lowered environmental pH [27].

In addition to the differences in microbial patterns between healthy and disease individuals, a recent observation in children showed that biofilms also differ according to the site of the tooth [28]. In other words, the environmental pH within dental biofilms can differ according to its location on the tooth. This scenario supports observations that dental morphology contributes to pathogenic biofilm development at certain tooth sites, and since salivary enzymes reach free-surface biofilms more easily than those located in dental fissures; the relationship becomes even more complex. Yet, it can be concluded that for dental caries there are predilection sites.

3. Dental morphology

Human dental anatomy presents many instances of biologic variation, and for future dental educational planning a greater number of examples of dental morphology variation should be used. The use of natural teeth for teaching is very important, but natural images can also help [29]. A simple investigation into the external morphology of the human tooth clearly shows three distinct parts:

- a. Crown: the top part of the tooth covered in its external layer with enamel tissue. It is the only part you can normally see when someone is smiling, though a small part of it may be covered by the gums. The shape of the tooth's crown determines its function. The incisors and canine teeth are very sharp and chisel-shaped for cutting; premolars and molars have two or more cusps for grinding. The coronal part of the human tooth is composed of two hard tissues: enamel and dentin, this includes the dental pulp, located in the crown.
- b. Gumline: this is the part of the tooth between the crown and the root. It is where the gums meet the crown and the cemento-enamel junction is located. This line (also known as the cervical line) is easily visible to the naked eye due to the color difference between enamel and cementum.
- c. Root: this is the part of the tooth that is embedded in the bone. The root of a tooth makes up about two-third of its whole structure. It is covered with cementum.

These three parts of human teeth play distinct functions within the oral cavity (**Figure 1**). Their anatomical features, size, and shapes are directly related to their ability to tear and crush the food. Incisor and canine crowns have four surfaces and a ridge (a linear elevation on the surface of a tooth), whereas premolar and molar crowns have five surfaces. The surfaces are named according to their positions and functions. Interestingly, teeth exposed to very strong masticatory forces require greater support area. This explains why molars have three roots, whereas incisors have only one. In the oral environment, biting and chewing are very complex phenomena which are also connected to the form, size, and shape of the teeth [30, 31].

Human teeth present anatomical details related to their specific function during mastication, with depressions, elevations, concavities, and convexities. From the perspective of anatomical features, the crown of a tooth can be classified as having retentive and non-retentive areas.

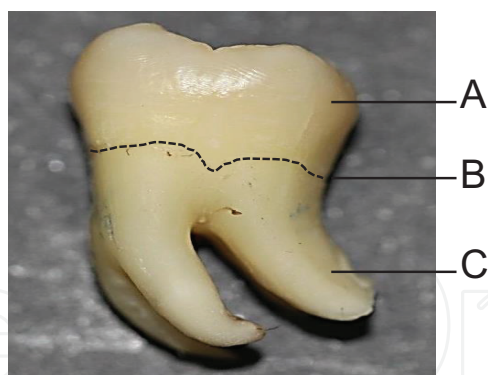


Figure 1. Dental tooth major anatomical parts. (A) Crown; (B) cervical line; (C) root.

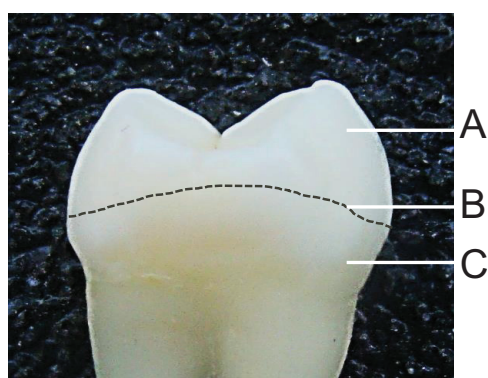

Figure 2. The equatorial line of a tooth. (A) Non-retentive area; (B) equatorial line; (C) retentive area.

The line that separates these areas is called the equatorial line. This is an imaginary line that can be drawn by circling the most convex surfaces of a tooth: the lingual, buccal, and proximal (**Figure 2**).

Considering homologous teeth, the equatorial and occlusal molar areas (surfaces close to equatorial lines) are on average larger in males than in females, though equatorial and occlusal outlines of homologous left and right molars within both sex, and arch (maxillary and mandibular) are similar, being without size and shape differences [32].

The vestibular (buccal) and lingual contour heights (curvature crest) are important to divert and prevent food from getting stuck in the gingival sulcus. The crest curvature is the anatomical point on tooth crown where a parallel line drawn toward the middle-root axis line touches the greatest convexity (protuberance). Contact areas between two teeth are known as proximal contour heights. The possibility of food impaction at these points is a matter of concern. In healthy individuals or in most cases, points of contact between any tooth and any adjacent tooth change with time. In young persons, the contact points of recently erupted teeth are true contact points. In adults, after many years of small and frequent movements, the tooth surfaces can be flattered because of mastication. It has been estimated that in an adult mouth of 40 years of age, approximately 10 mm of enamel have been worn off due to the contact area wear [30, 31].

Certain major anatomical features encountered when studying dental morphology are presented in **Table 1**.

Anatomical features	Definition
Cusp	Elevation or mound on the crown that makes up a divisional part of the occlusal surface of the tooth
Tubercle	Smaller elevation on some portion of the crown produced by an extra formation of enamel
Cingulum	Also known as “girdle” (Latim) is the lingual lobe of an anterior tooth. It makes up the bulk of the cervical third of the lingual surface. Its convexity mesiodistally resembles a girdle encircling the lingual surface at the cervical third
Ridge	Linear elevation on the surface of a tooth and is named according to its location (e.g., buccal ridge, incisal ridge, marginal ridge). Marginal ridges are those rounded borders of the enamel that form the mesial and distal margins of the occlusal surfaces of premolars and molars and the mesial and distal margins of the lingual surfaces of the incisors and canines
Sulcus	Long depression or valley in the surface of a tooth between ridges and cusps. A sulcus has a developmental groove at the junction of its inclines
Groove	Linear channel or sulcus
Fossa	Depression on the tooth surface
Embrasures	Open spaces between teeth and around a contact (e.g., occlusal (incisal) embrasures, buccal and lingual embrasures and gingival embrasures)

Source: Adapted from Scheid and Weiss [30] and Stanley and Major [29].

Table 1. Some major anatomical characteristics and features of human dental teeth.

A complete description of dental features can be found in publications specifically concerning tooth anatomy. The difference between teeth groups, differences in nomenclature and detailed descriptions for each human tooth type are beyond the scope of this chapter. Further information on this topic can be found elsewhere [30, 31].

4. Dental anatomy and caries

Klein and Palmer were the first investigators to clearly describe relationships between dental caries and the various morphological tooth types [32, 33]. Their work provided the very useful information that mandibular molars were much more susceptible to carious attack than mandibular canines and incisors. Although it seems obvious currently, this information was collected when most American cities had a high prevalence of caries, and the upper incisors were frequently affected by carious lesions. For that time, these relationships were somewhat obscure. Today, it seems evident that occlusal surface irregularities can facilitate biofilm development and eventually result in carious lesions.

Depressions and grooves in the teeth are always anatomical points of concern for dental caries (**Figure 3**). For the clinician, great individual variation is found in the occlusal areas of the teeth, yet these occlusal areas and proximal contact points are generally the main focus of clinical examinations. The sulci of human teeth are generally V-shaped, and though in most cases, the toothbrush bristles can remove a good portion of biofilms in this area, certain debris and microbial biofilm will remain attached to the deeper parts of the sulcus.

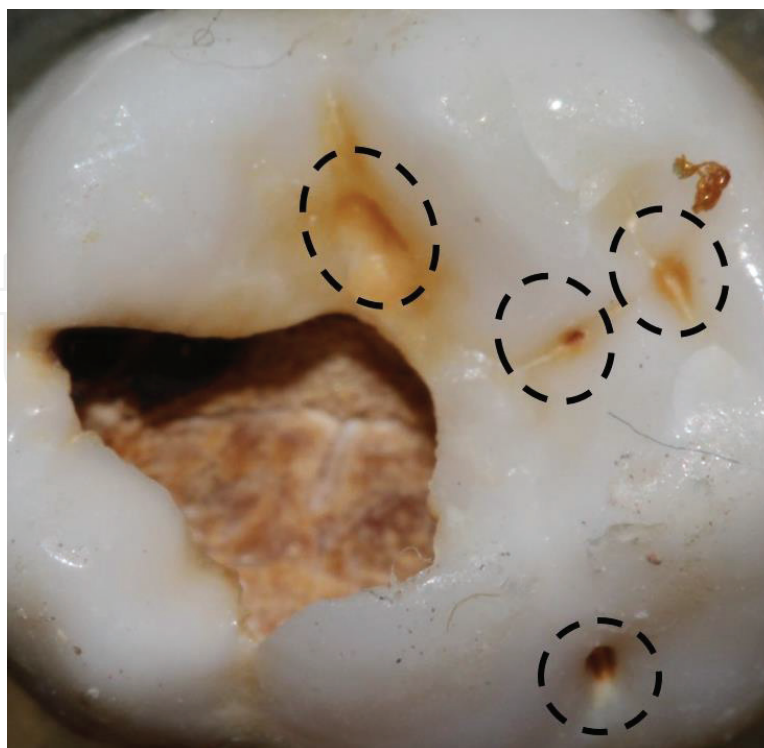

Figure 3. Tooth depressions are always anatomical points for dental caries.

Certain researchers use the term “groove-fossa system” (**Figure 4A**) when describing depressions in the occlusal part of a tooth that is vulnerable to dental caries [34]. This is of particular importance in Pedodontics for identifying risk areas for caries in deciduous teeth and first permanent molars. The pit formed by junction of developmental grooves is a very interesting anatomical feature in the molar occlusal surface; a very “tricky” area for dental caries on the occlusal surface.

Hidden caries is a term used to describe occlusal dentine caries that are missed upon visual examination [35]. In most hidden caries cases, a tiny open cavity is located between grooves. Basically, the point occurs at the convergence of occlusal surface ridges that terminate at a central point in the bottom of the depression. It is a junction of grooves, also regarded as a small physiological-anatomical depression, and easy to verify as an attractive location for bacterial growth. As a result of constant deep demineralization, a cavity can appear below the resistant enamel. In general, its opening (aperture of the lesion) corresponds to a small pit formed in the central fossa between the triangular ridge and the transverse ridge [35].

The fifth cusp in the upper molars (also known as the Carabelli trait) is frequently observed during dental examination. It has received many different names such as: Carabelli trait, Carabelli tubercle, molar tubercle, enamel elevation, fifth cusp, accessory cusp, mesiopalatal prominence, and tuberculum anomalum [36]. It is less prevalent in Asians, but is most common in Europeans 85% or White Caucasians. Carious lesions are also frequently observed at this site (**Figure 4B**).

A very special landmark on mandibular first molars is the mesiobuccal groove. It is a sort of sulcus that stretches from the occlusal surface to the buccal surface, and is frequently

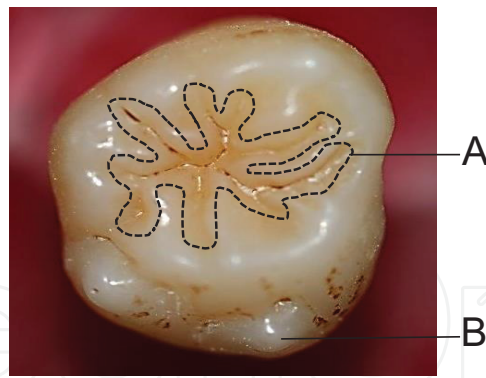


Figure 4. (A) The “groove-fossa system” of a posterior tooth. (B) The accessory cusp in an upper molar tooth.

neglected during dental exams. Although sometimes rather shallow, this narrow groove can harbor a small but active bacterial community which can easily provoke cavitation.

Microbial colonization is expected in areas where food impaction is frequent. Thus, all proximal areas below the contact point are favorable sites for food retention, biofilm development and caries. The truth is that together, all of the teeth groups (incisors, canines, premolars and molars) work harmonically toward breaking down food. After a good meal, it is evident that the anatomical features of the teeth have worked together harmonically for biting, crushing, and chewing foodstuffs. However, the shapes of the teeth and their position in the oral cavity may reveal certain gaps where food can accumulate. Other variables must also be considered such as the health status of the gums and the period of tooth eruption.

Normal tooth eruption, development and dental occlusion patterns reveal broad variations. However, certain common events are expected such as slow and irregular eruption of first molars in children and third molar eruption in adolescents and adults. The morphology of a tooth and its eruption time may carry a certain importance for the development of dental caries. Due to favorable conditions for plaque accumulation (biofilm formation), erupting teeth are more likely to develop dental caries. Further, there is also strong evidence that tooth anatomy may affect the likelihood of caries formation. Yet, how deep is the connection between these variables?

A very interesting study investigated the morphology of erupting third mandibular human molars including histological caries features and whether the morphology of interlobal grooves influences specific microorganism viability [37]. A total of 116 buccolingual sections of 22 teeth were examined, and the mesiodistal interlobal groove was classified as either “fissure-like” or “groove-like”. “Fissures” were less prone to caries than “grooves”. Viable microorganisms were seen at the entrance as well as in the interiors of the “grooves”. In “fissures” viable microorganisms were primarily observed at the entrance, while in the interiors microorganisms were less viable or dead. The authors concluded that the internal morphology of interlobal grooves influences bacterial growth conditions, and determines locations for caries progression within a groove-fossa system.

The formation of a microbial biofilms on teeth is enhanced by natural retention factors, which can also render removal by means of oral hygiene more difficult. Certain relevant retention

factors for biofilms on the cervical third and roots include: supra- and subgingival calculi; cementoenamel junctions and enamel projections; furcation entrances and irregularities; cervical and root surface caries; and tooth crowding in the arch. [38].

Without proper brushing and flossing, microbial biofilms and tartar can build up at the gum-line, leading to gingivitis and gum disease. If the margin of the gum tissue that surrounds the teeth wears away, the root surface is exposed and caries are likely to develop. This is called gum recession, a complex process where the gums pull back and the gum line changes. When gum recession occurs, “pockets” or gaps form between the teeth and the gum line. Under this influence, the teeth can be severely damaged, and may ultimately result in tooth loss.

Human teeth present a varied and complex morphology with bases in the innumerable anatomical characteristics provided for by their grooves, fissures, and sulci. Certain teeth unexpectedly reveal risk areas in subtle and hidden structures. For instance, the lingual pit in lateral upper incisors must often be restored due to caries, for in addition to its own morphology; the tooth has its neighboring tooth creating the embrasures and contact points; an antagonist tooth that can force food and debris toward the grooves, fissures, and sulci. Finally, the cervical third of the proximal surface is surrounded by the gums. This is a very special area where open smooth surfaces may also present dental caries, a spot where biofilms are not linked to any specific anatomical feature. Microbial biofilms can form and develop in many anatomical tooth sites or even on free smooth surfaces (cervical third) when conditions are favorable. **Table 2** presents the predilection sites for dental caries by tooth group.

For an experienced dentist, the most common locations of dental caries, presented in **Table 2** are obvious. Nevertheless, the examination process for detecting dental caries needs to be carefully performed even by experienced professionals. It is not rare that a white spot (demineralization area indicating initial caries) is neglected during dental examination. This is the reason for removal of all dental plaque (biofilms) prior any dental examination. Dental caries forms in sites of biofilm

Tooth groups	Risk areas for dental caries
Incisors	All cervical third (particularly free smooth surfaces close to the gum line)Mesial and distal surfaces (below contact point) Lingual pit (lingual surface of lateral incisors)
Canines	All cervical third (particularly free smooth surfaces close to the gum line) Mesial and distal surfaces
Pre molars	All cervical third (particularly free smooth surfaces close to the gum line) Mesial and distal surfaces (below contact point) Sulci Fissures and grooves Triangular fossa (occlusal surface)
Molars	All cervical third (particularly free smooth surfaces close to the gum line) Mesial and distal surfaces (below contact point) Sulci (including sulcus close to Carabelli trait) Fissures and grooves (including the mesio-buccal groove) Triangular fossa (buccal and occlusal surfaces) Central fossa

Table 2. Risk areas for dental caries at each tooth group.

stagnation and these sites can frequently remain hidden from sight. Another fundamental condition is the proper light source and the aid of compressed air for dehydrating the tooth surface.

Factors affecting caries detection can vary if the dental examination is in a child, an adolescent or an adult. First, carious lesions can either be visualized at early stages or as a cavitated lesion; second, during childhood, mixed dentition can be a confounding factor; a third variable is related to the different diagnostic tools (e.g., probes, radiographs). Finally, carious locations can also vary with age, for instance, carious lesions can be found in unexpected sites. In young children, dental plaque (biofilm) can easily accumulate underneath and close to the gum line of upper incisors due to extensive bottlefeeding.

When comparing differences between deciduous and permanent teeth, dental caries progression is faster in deciduous teeth because deciduous tooth enamel is less mineralized than permanent tooth enamel. The chemical composition of the enamel is another factor in rapid deciduous caries progression because the total carbonate content is significantly higher in deciduous teeth [77].

In the following sections, classification of dental caries based on their locations is presented. It is important to point out that this approach is only a general guideline for a better understanding of this topic. The limitation of such an approach is related to the lack of clinical information, which would provide even better comprehension about the development of the carious lesions.

4.1. Occlusal caries

In the permanent dentition, occlusal fissures and grooves on the first permanent molar are generally the first sites to develop caries [39]. In fact, all depressions in the occlusal surface can be regarded as predilection sites for dental caries. The same is not true for primary dentition since early childhood caries (ECC), a typical condition of deciduous incisor smooth surfaces often occurs. It is estimated that occlusal caries account for most of the carious lesions in children aged 8–15 years. The general distribution of occlusal lesions seems to be concentrated in the first and second permanent molars, prevalent in all age groups. Since 1965, certain investigations have supported the view that occlusal molars surfaces are the most caries susceptible [40–42]. A good listing by rank shows the most susceptible surfaces for caries (from the most susceptible to the less susceptible), distributed as follows: occlusal surface of the four first molars > occlusal surface of the lower second molars > occlusal surface of the upper second molars > mesial surface of the upper first molars [41].

Since occlusal surfaces are present only in pre-molars and molars, the development of biofilms on these sites is related to pressed and packed debris and biofilms upon fissures, grooves, and sulci. The clinical appearance of carious lesions varies significantly, and discoloration in these occlusal depressions may be either white or dark [43, 44]. These discolorations can remain even after the tooth is extracted.

As to dental treatment for occlusal caries, the threshold for operative treatment is still a matter of debate [39]. A recent study supports the view that younger dentists are more reluctant to remove hard tooth tissues. Types of dental material are also converging; composites are replacing amalgams or other filling materials [40]. It must be noted that on the whole, development

of carious lesions has lessened due to both fluoride exposure and accessibility to oral hygiene procedures. Caries risk assessment may help determine whether drilling of an occlusal fissure or choosing a non-invasive treatment is more appropriate. In both cases, a good understanding of premolar and molar occlusal morphology is needed (**Figure 5**).

4.2. Interproximal caries

Different from occlusal surfaces, the process for detecting proximal carious lesions is hampered by natural variations in dental morphology and their relations to the adjacent teeth. Proximal lesions develop between contacting proximal surfaces (just below the contacting point) of two adjacent teeth. Proximal lesions are hard to visualize during the clinical exam, and if not detected during the initial stages, radiographs and tooth separation often reveal their presence. Evidence of a proximal lesion in one tooth raises significant concerns since the neighboring tooth in most cases is also affected. Proximal lesions do eventually appear clinically as opaque areas on buccal and lingual surfaces [45–47].

It is estimated that at least 40% of proximal carious lesions are missed during dental examinations and are allowed to continue growing. Tightly contacting proximal surfaces between teeth create detection and treatment difficulties, even for experienced clinicians. Recent techniques have been developed to facilitate penetration of low-viscosity resins into the porous lesion body of enamel caries. Infusion of a highly fluid unfilled light-cured resin known as “resin infiltration system” is particularly useful for treating incipient proximal lesions [48].

Many dental professionals do not consider single tooth proximal surface dental morphology by itself as a predilection for caries. However, a recent study concluded that morphologies

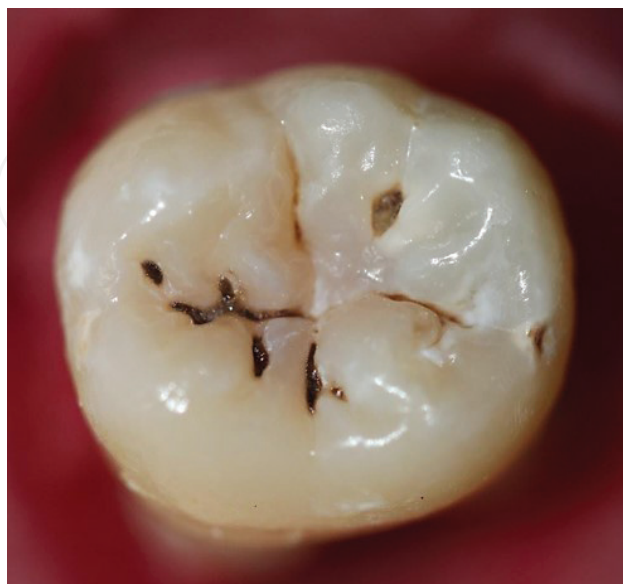

Figure 5. Occlusal caries.

of proximal surfaces are important for primary molar teeth [49]. In this study, 52 young children (3–4 year-olds) were followed for 1 year. The morphology of the distal surfaces of the first molar teeth and the mesial surfaces of the second molar teeth ($n = 208$) were scored in four categories: concave-concave; concave-convex; convex-concave; and convex-convex. Radiographs were used to monitor proximal caries, and the results showed risk of developing caries is increased if both surfaces are concave. It is important to point out that proximal surfaces of permanent and primary molar teeth may be convex or concave in the buccolingual direction as well as in the occluso-cervical direction [49, 50].

When teaching dental anatomy, apart from the fact that two neighboring teeth can create a favorable site for caries development, proximal surfaces are generally presented without any special anatomical characteristic. In addition to shape (convex or concave) another point to consider is how wide is the space between teeth if any? If the contact point is actually an open space between the teeth (broad contact area), a significant drop in the likelihood of caries formation is expected. Researchers have evaluated whether the risk of proximal caries in posterior primary teeth is higher when interproximal contact points are closed, or if they are open [51]. Data concerning known risk factors and indicators for caries were also investigated. The findings for young children (24–72 months) showed the odds for caries were significantly increased when such contact points were closed.

For detection of proximal caries, and as adjuncts in the process, bitewing radiographs remain state-of-the-art. However, a good number of caries detected by radiographs (lesions extended to the outer dentine) can be intact on enamel surfaces [52]. Since carious lesions are directly dependent on the continuous presence of active microorganisms, a reasonable approach is to monitor caries using a series of bitewing radiographies [53] (**Figure 6**).

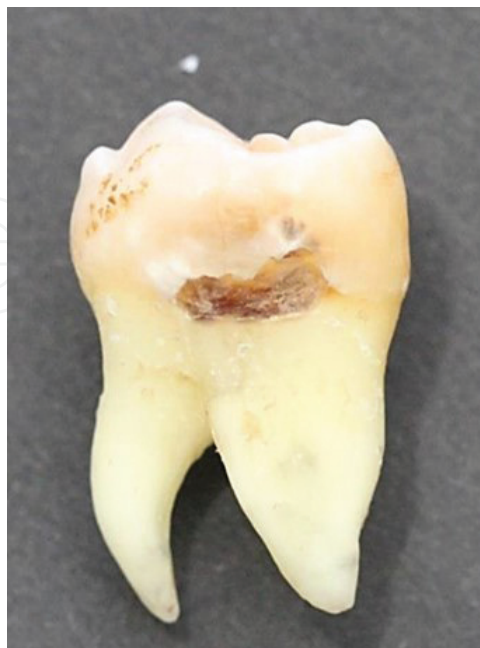

Figure 6. Interproximal caries below the contacting point.

4.3. Buccal and lingual caries

In opposition to occlusal surfaces that are rich in fissures and grooves, there is no favorable anatomical environment for complex organized microorganism microcosms on the smooth tooth surface, dental biofilms on free smooth surfaces have a different evolution as compared to occlusal surfaces, and carious lesions on smooth surfaces of the teeth and can be detected in early stages. The challenge for “early colonizing microorganisms” is high since the morphology does not help, and shear forces are constantly taking cells away. It has been observed that during the first few hours of biofilm formation, early colonizers of the tooth surface predominantly consist of beneficial microorganisms (*Actinomyces* and *Streptococci* species) [54, 55]. Later, the first subsequent proliferation is largely due to microbial mass increase during early plaque formation which is modulated by nutrition and the impact of serum proteins that emanate from gingival sulcus [55]. Thus, any free smooth surfaces prone to caries are mainly restricted to areas below the equatorial line, in other words, restricted to the cervical third and close to the gum line (**Table 1**).

Normal tooth contours provide constant protection from the influence of direct salivary flow and from the masticatory function of the cervical third. Thus certain stagnation of mass may take place and demineralization can create surface roughness providing more attachment points. Further, certain surface characteristics such as hydrophobicity and chemical charge can modulate the number of microorganisms in “mature” biofilm [56]. It must be pointed out that if over-contouring of the tooth is present more food retention is likely to occur, and as a result, a more pathogenic biofilm will be established.

In summary, microbial adherence to rough surfaces takes place easily due to occlusal surface pits and grooves. Though on free smooth surfaces, the reduced influence of shear forces creates difficulties for microbial adherence; initial attachment and subsequent development of a biofilm cannot generally be avoided altogether. Tiny irregularities in the surface caused by the demineralization enhance the development of the biofilms in these areas, particularly on the cervical third close to the gum line and on root surfaces [57].

Dental caries in early childhood are a challenge for many dentists since dental caries often begin during the first year of life. Early childhood caries (ECC) begins soon after dental eruption, developing on smooth surfaces, and progressing rapidly; having a lasting detrimental impact on dentition. Carious lesions in children may be found on either the buccal or lingual surfaces of the teeth and, in certain cases, on both [58].

Clinically, dental caries on smooth surfaces appear as white spots (opaque areas) in the enamel, reflecting demineralization or loss of minerals in the tissue subsurface. Oral prophylaxis and drying the tooth surface are crucial procedures for detecting the lesion. Their appearance can be characterized by several factors such as the depth of the lesion. Yet the carious lesion on a free smooth surface is easily observed extending in a half-moon shape following the gum line [38, 59, 60] (**Figure 7**).

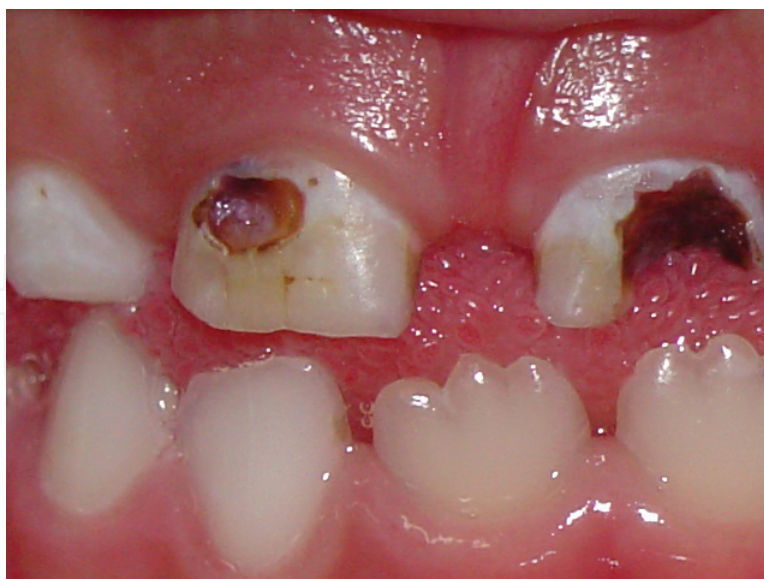

Figure 7. Severe buccal caries in upper incisors.

5. Dental caries and other conditions

5.1. Dental caries in partially erupted tooth

Dental cariologists have placed great efforts into identifying the human tooth surfaces at risk. Since susceptibility of a tooth surface to caries can vary over time, the task is not simple. In general, it is accepted that the period of peak susceptibility for caries occurs at about 4 years from eruption of the tooth. Carlos and Gittelsohn [40] found that the probability of a carious lesion is greatest during the second post-eruptive year (in the second permanent molars), but for other teeth the period of maximum carious attack is reached about 2 years afterwards. Another study recently concluded that carious susceptibility variations do exist, and the most vulnerable sites are those surfaces with pits and fissures, followed by proximal surfaces [42].

There is no doubt that susceptibility to caries is partially influenced by the period of tooth eruption, information particularly relevant if the patient is a child with mixed dentition. When the tooth is partially erupted, the so-called “groove-fossa system” is under greater attack. There is also great evidence that oral hygiene of the occlusal surface of partially erupted teeth is fundamental for a proper prevention of dental caries [12, 34, 61].

Partially erupted teeth do not participate fully in mastication and for this reason offer more favorable environments for bacterial accumulation than fully erupted teeth [34]. As might be expected, it has been observed that the amount of biofilm accumulated on the occlusal surfaces in partially erupted molars is higher than in fully erupted molars [62]. Due to the fact that the lower and upper third molars are the most commonly enclosed teeth; pericoronitis associated with bad oral hygiene and smaller self-cleansing area, leads to accumulation of food and microorganisms that cannot be cleaned with normal brushing and flossing, causing

the development of caries [61]. Removing dental biofilm in partially erupted molars is more difficult than in fully erupted molars [62, 63].

Eventually, the tooth reaches the occlusal plan and masticatory forces help remove parts of the biofilm. This phenomenon can partially explain why most occlusal lesions tend to cease when teeth reach the occlusal plan. However, for certain individuals, a significant proportion of their carious lesions remain active and in need of proper management [64].

The presence of a partially erupted third molar can also create risks for caries. It is estimated that the prevalence of carious lesions on mandibular second molars due to the presence of a third partially erupted molar can reach up to 39% [65]. Mandibular third molars are the most frequently impacted teeth, a condition that is defined when the tooth does not reach the occlusal plane, even after root formation reaches two-thirds. Impacted third molars tend to accumulate biofilm against the distal surfaces of second molars, thereby creating the risk of distal cervical caries. A recent study has shown that second molars adjacent to absent third molars are at the lowest risk of developing caries and periodontal disease; whereas, second molars adjacent to soft tissue impacted third molars are at the greatest risk [66]. Thus, when a partially erupted mandibular third molar is not removed, good oral hygiene becomes essential to avoid caries [67]. The most important variables when considering caries risk in the second mandibular molar due to a partially erupted third molar are eruption status, type of angulation, and the nature of tooth contact between the molars. Such factors can be used as predictors to indicate the likelihood of developing caries on the second mandibular molar [67]. Otherwise, if recurrent dental caries occur on the second molar, the third molar must be prophylactically removed [68] (**Figure 8**).

5.2. Dental disorders and caries

Dental disorders in hard tissues are seldom presented and discussed during classes teaching dental anatomy. Most instructors are concerned solely with teaching the normal morphology

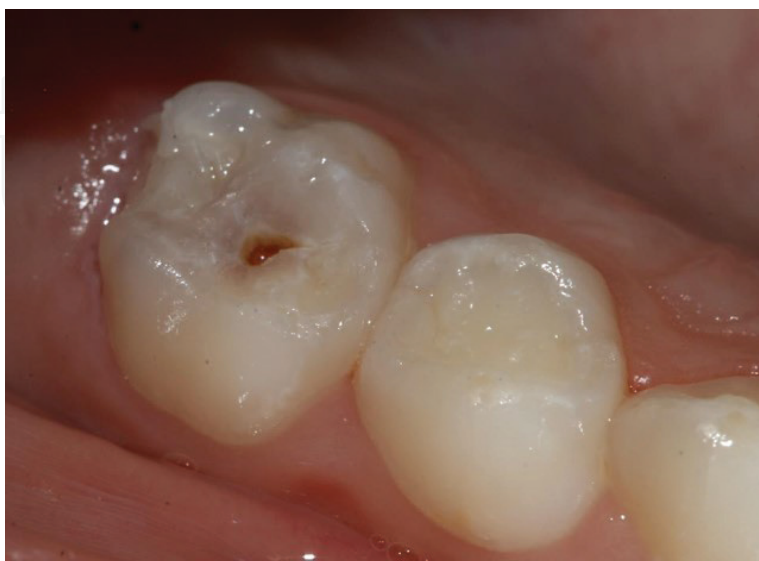

Figure 8. Dental caries developed during eruption process in second deciduous molar.

of the teeth. However, observation of dental abnormalities may lure students to acquire problem-solving skills. For instance, first molar and incisor morphologies can be explored together, in spite of the fact that they belong to different groups of teeth. With these teeth, the reason for a combined lecture comes from a common and frequently encountered condition observed by pediatric dentists: molar incisor hypomineralization (MIH). MIH is defined as a qualitative enamel defect of systemic origin. The terminology of MIH was introduced 16 years ago (2001) in order to describe enamel hypomineralization of systemic origin affecting one or more of the first permanent molars that are frequently associated with affected incisors [69].

In certain countries, the prevalence of MIH is regarded as very low (~2%), yet it has reached almost 40% in others. The high variance in recording MIH reflects difficulties in detecting and defining potential etiological factors [70–72]. The treatment for MIH is mainly restoration using Glass Ionomer Cement, and monitoring for defect associated caries. The probability of success is found to be high, mainly in single-surface tooth restorations. Complete removal of the affected areas (occlusal surfaces in molars and buccal surfaces in incisors) should generally be postponed. The reason for such delay in more invasive treatments is related to awaiting better conditions or when a child understands enough to cooperate with complex rehabilitation and treatment procedures [73].

MIH is just one of many tooth disorders that can be explored in dental anatomy courses. Developmental dental disorders may range from abnormalities in dental lamina demarcation to tooth germ anomalies (numbers, size, and shape), to abnormalities in the growth of the dental hard tissues (structure). Restricted to the enamel, certain developmental defects may manifest in two major conditions: enamel hypoplasia or opacity. The etiologies for dental anomalies vary substantially; they can be congenital or idiopathic, inherited or acquired [74]. A deeper understanding of dental anomalies is important because they can affect color, shape, and tooth structure. As a result, dental morphology can also be affected, which may increase the risk for dental caries [75]. Taking all dental anomalies into account, most of them have clinical significance: as to esthetics, malocclusion, and to the more costly development of dental decay and oral diseases [76]. Further, most dental anomalies such as germination, fusion, and dens invaginatus lead to clinical problems, and thus remain relevant to investigations regarding potential changes in dental morphology, potentially causing difficulties in speech and mastication, temporomandibular joint pain and/or dysfunction, malocclusion, periodontal problems and increased susceptibility to caries [74].

6. Conclusions

It is widely recognized that knowledge of dental anatomy is fundamental to any branch of dentistry. Dental anatomy is primarily concerned with the shape, morphology, and appearance of teeth. Teaching dental anatomy comprises studies of crown contours, roots, and pulp chambers together in their relationships with other structures in the oral cavity [77–80]. Thus, dental anatomy is directly and easily linked to dental occlusion, forensic dentistry, and cariology. Yet the link between dental morphology and cariology is seldom explored.

There is constant concern to provide dental anatomy courses which are more relevant to clinical practice. Dental caries are certainly an important topic linking these fields, and topics in cariology can easily be introduced during dental anatomy sessions. Problem-based learning (PBL) is likely a good pedagogical approach for attracting students with a more active and enthusiastic learning path.

There are many reasons to avoid conventional lecture-based courses in dental anatomy. When learning dental anatomy, clinical expertise is probably the main goal for most students, and dental caries when integrated together with dental morphology is certainly an intellectually stimulating topic.

Reviewing the influence of dental anatomy on the development dental caries and taking into account recent findings in Cariology is beneficial for dental clinicians and anatomists.

Author details

Marcel Alves Avelino de Paiva, Dayane Franco Barros Mangueira Leite,
Isabela Albuquerque Passos Farias, Antônio de Pádua Cavalcante Costa and
Fábio Correia Sampaio*

*Address all correspondence to: fcsampa@gmail.com

Federal University of Paraíba, João Pessoa, Brazil

References

- [1] Selwitz RH, Ismail AI, Pitts NB. Dental caries. *Lancet*. 2007;**396**:51-59. DOI: 10.1016/S0140-6736(07)60031-2
- [2] Gustafsson BE, Quensel C-E, Swenander Lanke L, Lundqvist C, Grahnen H, Bonow BE, Krasse B, The Vipeholm Dental Caries Study. The effects of different levels of carbohydrate intake in 436 individuals observed for five years. *Acta Odontologica Scandinavica*. 1954;**11**:232-364
- [3] Krasse B. The Vipeholm dental caries study: Recollections and reflections 50 years later. *Journal of Dental Research*. 2001;**80**:1785-1788. DOI: 10.1177/00220345010800090201
- [4] Sheiham A, James WPT. Diet and dental caries the pivotal role of free sugars reemphasized. *Journal of Dental Research*. 2015;**94**:1341-1347. DOI: 10.1177/0022034515590377
- [5] Marsh PD. Microbial ecology of dental plaque and its significance in health and disease. *Advances in Dental Research*. 1994;**8**:263-271. DOI: 10.1177/08959374940080022001
- [6] Takahashi N, Nyvad B. Ecological hypothesis of dentin and root caries. *Caries Research*. 2016;**50**:422-431. DOI: 10.1159/000447309
- [7] Baelum V, Fejerskov O. How big is the problem? Epidemiological features of dental caries. In: Fejerskov O, Nyvad B, Kidd E, editors. *Dental Caries: The Disease and its Clinical Management*. 3rd ed. Oxford: Wiley-Blackwell; 2015. p. 21-45

- [8] Bratthall D, Hänsel-Petersson G, Sundberg H. Reasons for the caries decline: What do the experts believe? *Journal of Oral Science*. 1996;**104**:416-425. DOI: 10.1111/j.1600-0722.1996.tb00104.x
- [9] Roncalli AG, Sheiham A, Tsakos G, de Araújo-Souza GC, Watt RG. Social factors associated with the decline in caries in Brazilian children between 1996 and 2010. *Caries Research*. 2016;**50**:551-559. DOI : 10.1159/000442899
- [10] Lagerweij MD, van Loveren C. Declining caries trends: Are we satisfied? *Current Oral Health Reports*. 2015;**2**:212-217. DOI: 10.1007/s40496-015-0064-9
- [11] Topping GV, Pitts NB. Clinical visual caries detection. *Monographs in Oral Science*. 2009;**21**:15-41. DOI: 10.1159/000224210
- [12] Pitts NB, Zero DT, Marsh PD, Ekstrand K, Weintraub JA, Ramos-Gomez F, Tagami J, Twetman S, Tsakos G, Ismail A. Dental caries. *Nature Reviews Disease Primers*. 2017;**25**:17030. DOI: 10.1038/nrdp.2017.30
- [13] Schulte AG, Buchalla W, Huysmans MC, Amaechi BT, Sampaio F, Vougiouklakis G, Pitts NB. A survey on education in cariology for undergraduate dental students in Europe. *European Journal of Dental Education*. 2011;**15**:3-8. DOI: 10.1111/j.1600-0579.2011.00708.x
- [14] Çolak H, Dülgergil ÇT, Dalli M, Hamidi MM. Early childhood caries update: A review of causes, diagnoses, and treatments. *Journal of Natural Science, Biology, and Medicine*. 2013;**4**:29-38. DOI: 10.4103/0976-9668.107257
- [15] Sampaio FC, Rodrigues JA, Bönecker M, Groisman S. Reflection on the teaching of cari-ology in Brazil. *Brazilian Oral Research*. 2013;**27**:195-196. DOI: 10.1590/S1806-83242013000300001
- [16] Perry S, Burrow MF, Leung WK, Bridges SM. Simulation and curriculum design: A global survey in dental education. *Australian Dental Journal*. 2017;**19**:1-11. DOI: 10.1111/adj.12522
- [17] Sheiham A, James WP. A new understanding of the relationship between sugar, dental caries and fluoride use: Implications for limits on sugars consumption. *Public Health Nutrition*. 2014;**17**:2176-2184. DOI: 10.1017/S136898001400113X
- [18] Moynihan P, Kelly S. Effect on caries of restricting sugars intake: Systematic review to update WHO guidelines. *Journal of Dental Research*. 2014;**93**:8-18. DOI: 10.1177/0022034513508954
- [19] Sheiham A, James WP. A reappraisal of the quantitative relationship between sugar intake and dental caries: The need for new criteria for developing goals for sugar intake. *BMC Public Health*. 2014;**14**:863. DOI: 10.1186/1471-2458-14-863
- [20] Zero DT. Sugars— The arch criminal? *Caries Research*. 2004;**38**:277-285. DOI: 10.1159/000077767
- [21] Kidd EAM, Fejerskov O. What constitutes dental caries? Histopathology of cari-ous enamel and dentin related to the action of cariogenic biofilms. *Journal of Dental Research*. 2004;**83**:C35. DOI: 10.1177/154405910408301S07

- [22] Fejerskov O. Concepts of dental caries and their consequences for understanding the disease. *Community Dentistry and Oral Epidemiology*. 1997;**25**:5-12. DOI: 10.1111/j.1600-0528.1997.tb00894.x
- [23] Fejerskov O. Changing paradigms in concepts on dental caries: Consequences for oral health care. *Caries Research*. 2004;**38**:182-191. DOI: 10.1159/000077753
- [24] Simón-Soro A, Mira A. Solving the etiology of dental caries. *Trends in Microbiology*. 2015;**23**:76-82. DOI: 10.1016/j.tim.2014.10.010
- [25] Nyvad B, Crielaard W, Mira A, Takahashi N, Beighton D. Dental caries from a molecular microbiological perspective. *Caries Research*. 2013;**47**:89-102. DOI: 10.1159/000345367
- [26] Benítez-Páez A, Belda-Ferre P, Simón-Soro A, Mira A. Microbiota diversity and gene expression dynamics in human oral biofilms. *BioMed Central Genomics*. 2014;**15**:311. DOI: 10.1186/1471-2164-15-311
- [27] Sanz M, Beighton D, Curtis MA, Cury J, Dige I, Dommisch H, Ellwood R, Giacaman R, Herrera D, Herzberg MC, Konen E, Marsh PD, Meyle J, Mira A, Molina A, Mombelli A, Quirynen M, Reynolds E, Shapira L, Zaura E. Role of microbial biofilms in the maintenance of oral health and in the development of dental caries and periodontal diseases. Consensus report of group 1 of the Joint EFP/ORCA workshop on the boundaries between caries and periodontal disease. *Journal of Clinical Periodontology*. 2017;**44**:S5-S11. DOI: 10.1111/jcpe.12682
- [28] Richards VP, Alvarez AJ, Luce AR, Bedenbaugh M, Mitchell ML, Burne RA, Nascimento MM. The microbiome of site-specific dental plaque of children with different caries status. *Infection and Immunity*. 2017;**19**:1-11. DOI: 10.1128/IAI.00106-17
- [29] Stanley JN, Major A Jr. *Wheeler's Dental Anatomy, Physiology, and Occlusion*. 9th ed. St. Louis: Elsevier; 2010; 368 p
- [30] Scheid RC, Weiss G. *Woelfel's Dental Anatomy*. 8th ed. Philadelphia: Lippincott Williams & Wilkins; 2012; 504 p
- [31] Ferrario VF, Sforza C, Tartaglia GM, Colombo A, Serrao G. Size and shape of the human first permanent molar: a Fourier analysis of the occlusal and equatorial outlines. *American Journal of Physical Anthropology*. 1999;**108**:281-294. DOI: 10.1002/(SICI)1096-8644(199903)108: 3<281:: AID-AJPA4>3.0.CO;2-#
- [32] Macek MD, Beltrán-Aguilar ED, Lockwood SA, Malvitz DM. Updated comparison of the caries susceptibility of various morphological types of permanent teeth. *Journal of Public Health Dentistry*. 2003;**63**:174-182. DOI: 10.1111/j.1752-7325.2003.tb03496.x
- [33] Klein H, Palmer CE. Studies on dental caries. XI. Comparison of the caries susceptibility of the various morphological types of permanent teeth. *Journal of Dental Research*. 1941;**20**:203-216
- [34] Carvalho JC, Thylstrup A, Ekstrand KR. Results after 3 years of non-operative occlusal caries treatment of erupting permanent first molars. *Community Dentistry and Oral Epidemiology*. 1992;**20**:187-192. DOI: 10.1111/j.1600-0528.1992.tb01713.x

- [35] Ricketts D, Kidd E, Weerheijm K, de Soet H. Hidden caries: What is it? Does it exist? Does it matter? *International Dental Journal*. 1997;**47**:259-265. DOI: 10.1002/j.1875-595X.1997.tb00786.x
- [36] Sadatullah S, Odusanya SA, Mustafa A, Abdul Razak P, Abdul Wahab M, Meer Z. The prevalence of fifth cusp (Cusp of Carabelli) in the upper molars in Saudi Arabian School Students. *International Journal of Morphology* 2012;**30**:757-760. DOI: <http://dx.doi.org/10.4067/S0717-95022012000200066>
- [37] Ekstrand KR, Bjørndal L. Structural analyses of plaque and caries in relation to the morphology of the groove-fossa system on erupting mandibular third molars. *Caries Research*. 1997;**31**:336-348. DOI: 10.1159/000262416
- [38] Wolf HF, Hassell TM. *Color Atlas of Dental Hygiene*. 15th ed. Stuttgart: Thieme; 2006; 351 p
- [39] Ekstrand KR, Ricketts DN, Kidd EA. Occlusal caries: Pathology, diagnosis and logical management. *Dent Update*. 2001;**28**:380-387. DOI: 10.12968/denu.2001.28.8.380
- [40] Carlos JP, Gittelsohn AM. Longitudinal studies of the natural history of caries. II. A life-table study of caries incidence in the permanent teeth. *Archives of Oral Biology*. 1965;**10**:739-751
- [41] Hannigan A, O'Mullane DM, Barry D, Schäfer F, Roberts AJ. A caries susceptibility classification of tooth surfaces by survival time. *Caries Res*. 2000;**34**:103-108. DOI: 16576
- [42] Batchelor PA, Sheiham A. Grouping of tooth surfaces by susceptibility to caries: A study in 5-16 year-old children. *BMC Oral Health*. 2004;**28**:1-6. DOI: 10.1186/1472-6831-4-2
- [43] Kakudate N, Sumida F, Matsumoto Y, Yokoyama Y, Gilbert GH, Gordan VV. Patient age and Dentists' decisions about occlusal caries treatment thresholds. *Operative Dentistry*. 2014;**39**:473-480. DOI: 10.2341/13-141-C
- [44] Kopperud SE, Tveit AB, Opdam NJ, Espelid I. Occlusal caries management: Preferences among dentists in Norway. *Caries Research*. 2016;**50**:40-47. DOI: 10.1159/000442796
- [45] Abu El-Ela WH, Farid MM, Mostafa MSE-D. Intraoral versus extraoral bitewing radiography in detection of enamel proximal caries: An ex vivo study. *Dento Maxillo Facial Radiology*. 2016;**45**:20150326. DOI: 10.1259/dmfr.20150326
- [46] Haak R, Wicht MJ, Noack MJ. Conventional, digital and contrast-enhanced bitewing radiographs in the decision to restore approximal carious lesions. *Caries Research*. 2001;**35**:193-199. DOI: 10.1159/000047455
- [47] Hintze H, Wenzel A, Danielsen B. Behaviour of approximal carious lesions assessed by clinical examination after tooth separation and radiography: a 2.5-year longitudinal study in young adults. *Caries Research*. 1999;**33**:415-422. DOI: 16545
- [48] Meyer-Lueckel H, Bitter K, Paris S. Randomized controlled clinical trial on proximal caries infiltration: Three-year follow-up. *Caries Research*. 2012;**46**:544-548. DOI: 10.1159/000341807

- [49] Cortes A, Martignon S, Qvist V, Ekstrand KR. Approximal morphology as predictor of approximal caries in primary molar teeth. *Clinical Oral Investigations*. 2017;**22**:1-9. DOI: 10.1007/s00784-017-2174-3
- [50] Almer Nielsen L, Madsen DB. Selektiv brug af bitewingundersøgelse til diagnostik af approksimal caries i primære molarer. *Tandlægebladet*. 2005;**109**:370-374
- [51] Allison PJ, Schwartz S. Interproximal contact points and proximal caries in posterior primary teeth. *Pediatric Dentistry*. 2003;**25**:334-340
- [52] Pitts NB, Rimmer PA. An in vivo comparison of radiographic and directly assessed clinical caries status of posterior approximal surfaces in primary and permanent teeth. *Caries Research*. 1992;**26**:146-152. DOI: 10.1159/000261500
- [53] Pretty IA, Ekstrand KR. Detection and monitoring of early caries lesions: A review. *European Archives of Paediatric Dentistry*. 2016;**17**:13-25. DOI: 10.1007/s40368-015-0208-6
- [54] Heller D, Helmerhorst EJ, Gower AC, Siqueira WL, Paster BJ, Oppenheim FG. Microbial diversity in the early in vivo-formed dental biofilm. *Applied and Environmental Microbiology*. 2016;**82**:1881-1888. DOI: 10.1128/AEM.03984-15
- [55] Kolenbrander PE, London J. Adhere today, here tomorrow: Oral bacterial adherence. *Journal of Bacteriology*. 1993;**175**:3247-3252
- [56] Whittaker CJ, Klier CM, Kolenbrander PE. Mechanisms of adhesion by oral bacteria. *Annual Review of Microbiology*. 1996;**50**:513-552. DOI: 10.1146/annurev.micro.50.1.513
- [57] Nyvad B, Fejerskov O. Scanning electron microscopy of early microbial colonization of human enamel and root surfaces in vivo. *Scandinavian Journal of Dental Research*. 1987;**95**:287-296
- [58] American Academy on Pediatric Dentistry. American Academy of Pediatrics. Policy on early childhood caries (ECC): Classifications, consequences, and preventive strategies. *Pediatric Dentistry*. 2008;**38**:40-43
- [59] Roopa KB, Pathak S, Poornima P, Neena IE. White spot lesions: A literature review. *Journal of Pediatric Dentistry*. 2015;**3**:1-7. DOI: 10.4103/2321-6646.151839
- [60] Denis M, Atlan A, Vennat E, Tirlet G, Attal JP. White defects on enamel: Diagnosis and anatomopathology: Two essential factors for proper treatment (part 1). *International Orthodontics*. 2013;**11**:139-165. DOI: 10.1016/j.ortho.2013.02.014
- [61] Carvalho JC. Caries process on occlusal surfaces: Evolving evidence and understanding. *Caries Research*. 2014;**48**:339-346. DOI: 10.1159/000356307
- [62] Zenkner JE, Alves LS, de Oliveira RS, Bica RH, Wagner MB, Maltz M. Influence of eruption stage and biofilm accumulation on occlusal caries in permanent molars: A generalized estimating equations logistic approach. *Caries Research*. 2013;**47**:177-182. DOI: 10.1159/000345076
- [63] Oliveira RS, Zenkner JEDA, Maltz M, Rodrigues JA. Effectiveness of a standardized treatment protocol for children with active non-cavitated occlusal lesions on erupting

- permanent molars. *International Journal of Paediatric Dentistry*. 2015;**25**:393-398. DOI: 10.1111/ipd.12141
- [64] Alves LS, Zenkner JEA, Wagner MB, Damé-Teixeira N, Susin C, Maltz M. Eruption stage of permanent molars and occlusal caries activity/ arrest. *Journal of Dental Research*. 2014;**93**:114S-119S. DOI: 10.1177/0022034514537646
- [65] Syed KB, Alshahrani FS, Alabsi WS, Alqahtani ZA, Hameed MS, Mustafa AB, Alam T. Prevalence of distal caries in mandibular second molar due to impacted third molar. *Journal of Clinical and Diagnostic Research: JCDR*. 2017;**11**:ZC28. DOI: 10.7860/JCDR/2017/18582.9509
- [66] Nunn ME, Fish MD, Garcia RI, Kaye EK, Figueroa R, Gohel A, et al. Impacted third molars increase the risk for caries and periodontal pathology in neighboring second molars. *Journal of Evidence-Based Dental Practice*. 2014;**14**:89-90. DOI: 10.1016/j.jebdp.2014.04.026
- [67] Toedtling V, Coulthard P, Thackray G. Distal caries of the second molar in the presence of a mandibular third molar—A prevention protocol. *British Dental Journal*. 2016;**221**:297-302. DOI: 10.1038/sj.bdj.2016.677
- [68] McArdle LW, Fraser MD, Judith J. Distal cervical caries in the mandibular second molar: An indication for the prophylactic removal of third molar teeth? Update. *The British Journal of Oral & Maxillofacial Surgery*. 2014;**52**:185-189. DOI: 10.1016/j.bjoms.2013.11.007
- [69] Weerheijm KL, Jälevik B, Alaluusua S. Molar-incisor hypomineralisation. *Caries Research*. 2001;**35**:390-391. DOI: 47479
- [70] Wogelius P, Haubek D, Poulsen S. Prevalence and distribution of demarcated opacities in permanent 1st molars and incisors in 6 to 8-year-old Danish children. *Acta Odontologica Scandinavica*. 2008;**66**:58-64. DOI: 10.1080/00016350801926941
- [71] Silva MJ, Scurrah KJ, Craig JM, Manton DJ, Kilpatrick N. Etiology of molar incisor hypomineralization—A systematic review. *Community Dentistry and Oral Epidemiology*. 2016;**44**:342-353. DOI: 10.1111/cdoe.12229
- [72] Allazzam SM, Alaki SM, El Meligy OA. Molar incisor hypomineralization, prevalence, and etiology. *International Journal of Dentistry*. 2014;**234508**:2014. DOI: 10.1155/2014/234508
- [73] Fragelli CM, Souza JF, Jeremias F, R de C C, Santos-Pinto L. Molar incisor hypomineralization (MIH): Conservative treatment management to restore affected teeth. *Brazilian Oral Research*. 2015;**29**:1-7. DOI: 10.1590/1807-3107BOR-2015.vol29.0076
- [74] Shrestha A, Marla V, Shrestha S, Maharjan IK. Developmental anomalies affecting the morphology of teeth—A review. *RSBO Rev Sul-Brasil de Odont*. 2015;**12**:68-78
- [75] Caufield PW, Li Y, Bromage TG. Hypoplasia-associated severe early childhood caries—A proposed definition. *Journal of Dental Research*. 2012;**91**:544-550. DOI: 10.1177/0022034512444929
- [76] Jahanimoghdam F. Dental anomalies: An update. *Advances in Human Biology*. 2016;**1**:112-118. DOI: 10.4103/2321-8568.195316

- [77] Goldberg M. Deciduous tooth and dental caries. *Annals of Pediatrics and Child Health*. 2017;**5**:1120
- [78] Moretto SG, Anfe TEA, Nagase DY, Kuguimiya RN, Lago ADN, Freitas PM, Oda M, Vieira GF. Theoretical knowledge versus practical performance in dental sculpting—preliminary study *Clinical and Laboratorial Research in Dentistry*. 2014;**20**:82-87. DOI: <http://dx.doi.org/10.11606/issn.2357-8041.v20i2p82-87>
- [79] Manjunatha BS. *Textbook of Dental Anatomy and Oral Physiology*. 1st ed. Delhi: Jaypee; 2013. DOI: 10.5005/jp/books/11841
- [80] Siéssere S, Vitti M, de Sousa LG, Semprini M, Regalo SC. Educational material of dental anatomy applied to study the morphology of permanent teeth. *Brazilian Dental Journal*. 2004;**15**:238-242. DOI: S0103-64402004000300014