

# We are IntechOpen, the world's leading publisher of Open Access books Built by scientists, for scientists

6,900

Open access books available

186,000

International authors and editors

200M

Downloads

Our authors are among the

154

Countries delivered to

TOP 1%

most cited scientists

12.2%

Contributors from top 500 universities



WEB OF SCIENCE™

Selection of our books indexed in the Book Citation Index  
in Web of Science™ Core Collection (BKCI)

Interested in publishing with us?  
Contact [book.department@intechopen.com](mailto:book.department@intechopen.com)

Numbers displayed above are based on latest data collected.  
For more information visit [www.intechopen.com](http://www.intechopen.com)



---

# Advanced Technologies in Dermatology

---

Diana Kitala, Agnieszka Klama-Baryła,  
Wojciech Łabuś, Marcelina Misiuga,  
Mariusz Nowak and Marek Kawecki

Additional information is available at the end of the chapter

<http://dx.doi.org/10.5772/intechopen.70288>

---

## Abstract

Cellular therapies are an attractive area of regenerative medicine. For large partial thickness wound, keratinocytes transplant is suggested. The transplantation of cell graft is achieved by obtaining large amounts of cultured cells from a skin biopsy in 3 weeks. Stem cells can be applied before that, but are also efficient in chronic wound closure. Alternative treatment methods are transplants of allogeneic, biostatic skin and amnion. Amnion can be applied as a skin substitute on shallow facial burn wounds, hand burn wounds, on donor areas and granulating wounds. For medium depth or even deep burns, allogeneic skin is recommended. Thanks to the removing of cells from human allogeneic dermis, collagen scaffolding is obtained. It can be populated *de novo* by autologous skin cells. Artificial skin substitutes are especially good for hand burns and shallow burns. Even though scarring is a part of normal wound healing, it often leads to a pathological process. When scar treatment methods prove insufficient, surgical intervention becomes necessary. Surgical scar intervention involves removal of the pathological skin tissue fragment and replacing it with healthy skin or application of expanders. Improvement of the visual features can be also achieved by laser therapy.

**Keywords:** skin graft, skin cell graft, amniotic membrane, acellular dermal matrix, laser therapy, skin substitutes, scars

---

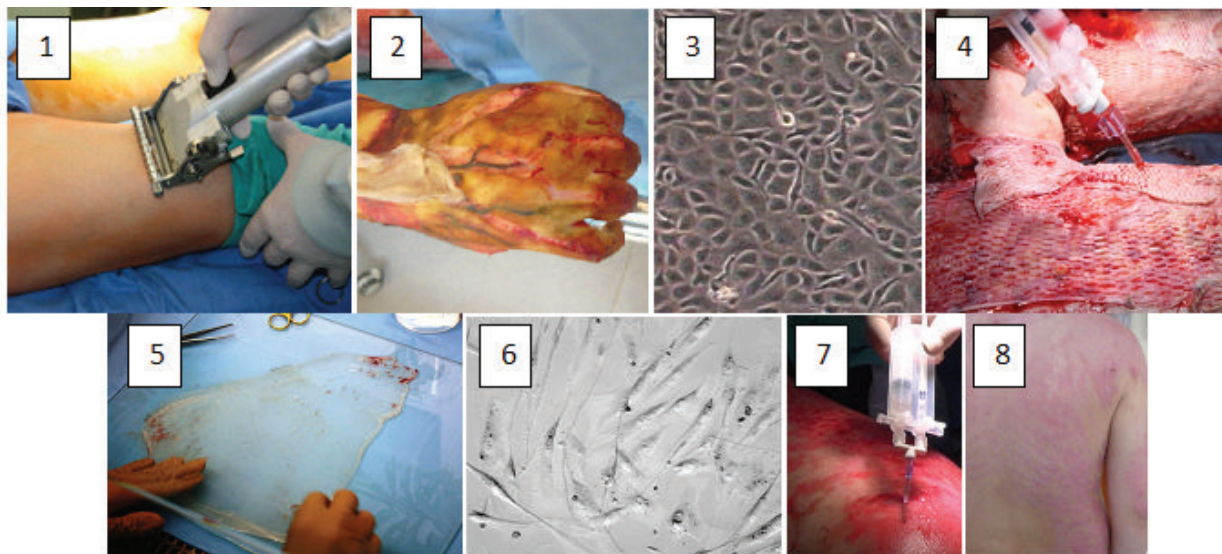
## 1. Introduction

The current trend in medicine is focused on two aspects of healing: on preventive medicine, preventing disease when possible and regenerative medicine, regenerating fractured cells [1]. The methods of treating burn wounds and chronic wounds have changed over the last decades [2]. Early removal of the dead necrosis and closing the wound with an autologous skin transplant of medium thickness (STSG) is still the basis of wound treatment [3], yet new methods that could provide a better esthetic effect continue to be sought after. This change

follows a growing consciousness of the patients and the resulting growing demand for new methods of wound treatment and scar healing.

## 2. Cellular therapies

Cellular therapies used to return the patient to the stage of skin completeness are an attractive area of translational medicine [4]. One should remember, however, that cell transplants (autologous keratinocytes or stem cells) were qualified as a healing product for advanced therapy by the Commission for Advanced Therapies of the European Medicines' Agency (EMA). Their manufacturing is thus, with all consequences, regulated by the rules of Good Practice [5–8]. Cultivated skin cells and products obtained by bioengineering means are used in treating patients with both genetic and acquired skin diseases [4]. They are especially useful in the treatment of traumas of chronic surface or depth, such as burns [9]. One of the methods is the delivery of cultured cells to the bed of the wound [10] by, among others, applying autologous cultured cells or skin substitutes obtained by cellular bioengineering [11]. The transplantation of keratinocytes is achieved thanks for obtaining large amounts of cultured cells from a skin biopsy in 3–4 weeks [12]. One of the benefits of using stem cells is their ability to migrate and differentiate the endothelium [13], which promotes revascularization [14]. The increased optimization of microvascular activity is the result of the injection of stem cells into a protracted wound [13]. What is more, the application of cells affects local cellular response, which plays an important role in the rebuilding of skin integrity in the infected wound [15]. It has been proven that stem cells from adipose tissue rebuild skin layering [7]. In our clinic, a positive result was obtained in all the cases of injecting stem cells from adipose tissue into the wound bed [16] (20 patients). There is a thesis that the transplant of allogeneic cells of the amnion can be more effective in the treatment of chronic wounds than autologous stem cells from adipose tissue or bone marrow [17]. Skin epidermis transplants with amniocytes act in an almost physiological way, which suggests that in the stimulation of the stratification of keratinocytes, fibroblasts can be replaced [18]. Fibroblasts seeded over the amnion show good adherence and longevity [19]. This type of wound dressing is suggested for chronic wounds and burn wounds [19, 20]. Alternatively, seeding the keratinocytes over the allogeneic, acellular amnion stimulates their proliferation. The life span of seeded cells is up to 4 weeks [20]. Experience shows that stem cells of the amnion shorten the time of wound healing by two-fold. The culturing of keratinocytes was implemented in the Center in 2008. Since then, about 200 cellular transplants have been effectuated in patients with burn wounds, mostly thermal wounds. About 75% of the patients were qualified for the culturing (**Figure 1**). The size of the wound was 40–79% total body surface area (TBSA) in more than half of the patients who were subject to a cellular transplant. According to Sood et al., the average life of patients subject to the cultured epidermal autografts (CEA) transplant is 91%, while we obtained 88%. It is worth remembering that when it comes to cells of the epidermis, key is the right matching of the patients as leading complications are dermal blisters, itchiness and the loss of the cellular transplant. A common and chronic after-effect is the occurrence of swollen scars [21]. One



**Figure 1.** The right choice of the research field for the sourcing of autologous skin for culturing (1) is often problematic due to the limited amount of available research fields (2). The culturing of the epidermis for the transplant (3) and wound before the transplant (4). The source material for the isolation of stem cells (5), stem cell culture (6), the transplant (7) and the final result (8).

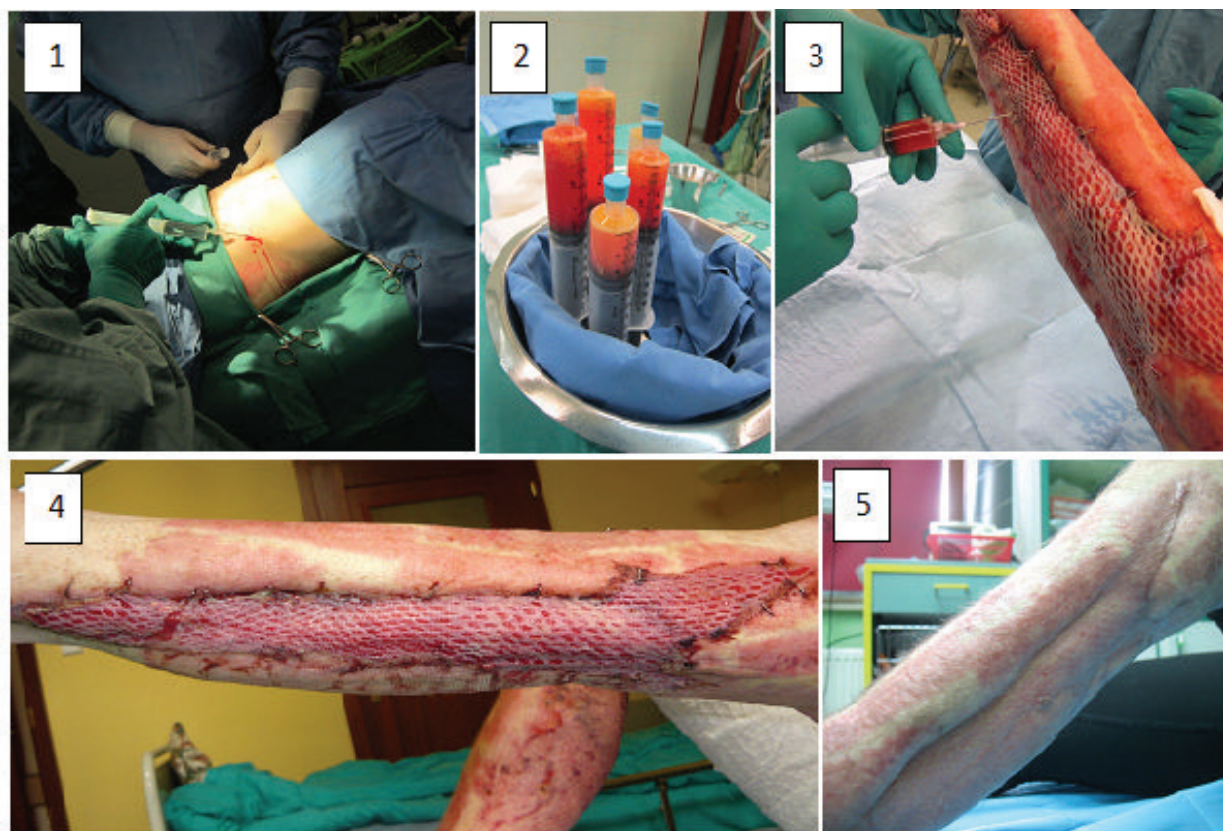
solution seems to be the use of stem cells [22] which help reduce the scarring [23]. The cells of the epidermis help the healing of wounds to the maximum depth of IIb. Mansilla et al. and Rasulov et al. suggest the use of stem cells for wounds of great depth [24, 25].

RenovaCare is now performing clinical trials of the SkinGun™, which is to distribute stem cells as a suspension (fog) into the wound bed. The isolation, processing and application of the autologous cells takes only 90 min. The inventors of the gun have obtained an award for the patent and assure users that the vitality of the obtained stem cells is up to 97.3% [26]. HARVEST TERUMOBCT used the The Harvest® AdiPrep® system, allowing to obtain a suspension of cells (containing mesenchymal stem cells) in 4 minutes. The singular platform produced by this company allows to transform the platelet rich leukocyte concentrate of bone marrow and fatty tissue into stem cells with the concentration of 160,000/ml and vitality from 78 to 95% [27]. Cytori Therapeutics, Inc. also proposes a device for autologous cell therapy using fractions of cells sourced from fatty tissue (ADRCs). Adipose tissue is a good source of stem cells, but the sine qua non condition for the use of The Celution® System is the minimal amount of fatty tissue of 200 g. In our experience, the whole sourcing and transformation process takes about 2.5 h even though Fraser and associates cites 1.5 h [28], the equivalent of the transformation of the framework in our device. Our Center uses this system as liposuction is a noninvasive procedure while the amount of sourced stem cells and regenerative cells does not require a long cell culturing process. The vitality of cells obtained using the The Celution® System is 93% and is higher than that coming from the PNC's Multi Station (a manual device), the CHA Biotech Cha-Station and the Medi-Khan's Lipokit from MaxStem [29]. In our Center, this system is used for the treatment of chronic wounds as it allows for the operation to be performed on the day of admission which shortens the



patient's hospitalization time and allows for the assurance of enough hospital beds to meet the needs of the other burn patients. Subjects included for this procedure contained patients who did not properly responded to CEA therapy and those with non-healing wounds. The procedure of applying ADRC cells sourced from The Celution® System was performed since 2011 in 20 patients (aged 18–80 years old). Good clinic results (final wounds closure) were obtained, which is a huge success preceded by the many months of non-responsive to healing wounds before the procedure (**Figure 2**).

The biggest limitation of the commercially available systems of sourcing stem cells for transplants is the amount of obtained cells, which is why burn patients qualify for stem cells cultured in a Stem Cell Bank. This is most effective from the point of view of a therapeutic success, yet much more complicated from the legal and financial point of view. It requires the production of stem cells in accordance with pharmaceutical law in Clean Rooms. Our Center has carried out a transplant of amniotic stem cells in a hospital exclusion which requires an extra permission from the bioethical commission and the signing of a conscious consent from the recipient. A 30-year-old patient with a thermal wound of 36% IIb/III got the cells in the fourth day after the burn. In 12 days, the wounds healed to a very good esthetic effect. It was



**Figure 2.** The isolation and application of regenerative cells from fatty tissue: liposuction (1), the sourced lipoaspirate (2), wound bed injection combined with a grated autologous skin cell transplant (3), the healing of the wound 7 days after the procedure (4), the final effect: a functioning, intact limb (5).

said that the legal regulations prevent the procedure from being routinely used. To sum, the good effects of cellular engineering in the last 30 years have been achieved in field of treatment of chronic wounds, such the diabetic foot and venous ulcers as well as deep wounds [30, 31]. It seems they will become a canonical medical practice. The only question is the right choice of therapy methods for the given patient.

### 3. The allogeneic amnion

The preparation which is an optimal alternative for traditional treatment methods is a transplant of allogeneic, biostatic amniotic tissue [19]. Amniotic tissue is a thin, half-permeable tissue which constitutes the most inner layer of the amnion and is obtained from seronegative donors during pre-planned Cesarean sections. Histologically, the amnion is a five-layer membrane from 0.02 to 0.5 mm thick. Amniotic membrane transplants are undertaken in sterile environments and undergo a final radiative sterilization [20]. The clinical reason for amniotic membrane transplants stems from its natural properties, such as

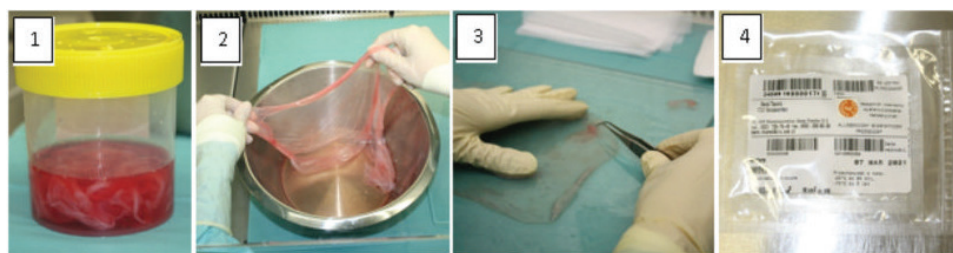
- it being non-immunogenic, mainly an effect of the expression of HLA-G genes in the placenta and amniotic liquid, which are responsible for the immune response during the pregnancy [34],
- reducing the risk of infection; it has been proven that the aqueous solution of the amniotic membrane promotes the apoptosis of monocells, such as lymphocytes and macrophages. [35]. This effect is proven by the latest research of Alikarami et al., which have proven the limiting effect of mesenchymal amniotic liquid cells on the proliferation of mitogenically active T lymphocytes in the *in vitro* coculturing of T lymphocytes [36],
- its anti-inflammatory properties; the antibacterial effect observed during the application of the amniotic membrane in the process of wound healing is a common and documented phenomenon. The antibacterial effect is thought to be due to the presence of lysozyme and progesterone in the amniotic liquid as well as the very exact link between the dressing and the wound. Lysozyme is a protein with the properties of a hydrolytic enzyme which breaks down the peptidoglycan present in the cell wall of the bacteria. Progesterone is bacteriostatic against many Gram (+) bacteria [32, 33, 37, 38],
- as well as modulating the stroma of the wound; the stromal matrix amnion is rich in extracellular matrix content, such as hyaluronic acid from the embryo, glycosaminoglycans, various types of collagen and growth factors which promote and modulate the regenerative processes occurring in the wound [39],
- stimulating proliferation processes; due to the rich ECM content. The amniotic membrane of the amnion included laminin, fibronectin, collagen IV, V and VII, as well as growth factors such as TGF, which greatly facilitates the adhesion and anchoring of the endothelial cells in the stroma and their proliferation [39, 40],

- minimizing pain; the painkiller effect is due to the very close link between the amniotic membrane and the wound, thanks to which the exposed, irritated nerve endings are protected [19, 33].

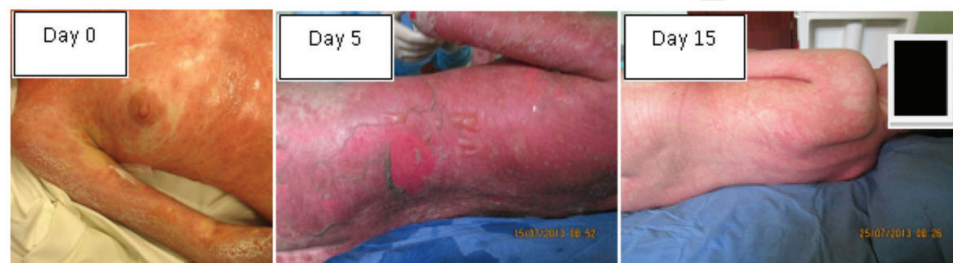The clinical scope of the use of the amniotic membrane may include its application as a skin substitute on facial burn wounds, hand burn wounds, on donor areas and granulating wounds. An alternative is the STSG wound dressing of high gradation. Amniotic membrane transplants are useful also in the treatment of autoimmune diseases, for example, the Lyell's disease [18, 19]. The amniotic membrane can be used together with biological wound dressings, such as allogeneic skin [12, 20]. Properly aseptically prepared biovital transplants such as allogeneic transplants of the amniotic membrane are of high interest today. Good results of intravital transplants of the amniotic membrane in the treatment of wounds can result from the physiological functions of secretion of the amnion cells [41].

The Dr Stanisław Sakiel Centre for Burn Treatment in Siemianowice Śląskie, we began the undertaking of biostatic transplants of the amniotic membrane in 2011. The transplants are produced in the Clean Rooms of the Cell Bank in accordance with the Good Manufacturing Practice (GMP) (**Figure 3**). From August 2011 to March 2017, 245,229 cm<sup>2</sup> transplant cells have been produced. 513 patients have been served by a total of 235,317 cm<sup>2</sup>, including 9 patients with the Lyell's Syndrome (**Figure 4**).

The obtained evidence and clinical observation suggest a conclusion that the amniotic membrane is an optimal skin substitute in the treatment of shallow burn wounds, specifically facial burn wounds.



**Figure 3.** Select stages of production of allogeneic, biostatic transplants of human amnion: (1) the amniotic membrane in a transportation container; (2) rinsing; (3) cutting uneven fragments, measuring the surface; (4) a packaged transplant before sterilization by radiation.



**Figure 4.** The clinical effect of the therapy of Lyell's effect in days: 0, 5 and 15.



## 4. The allogeneic skin

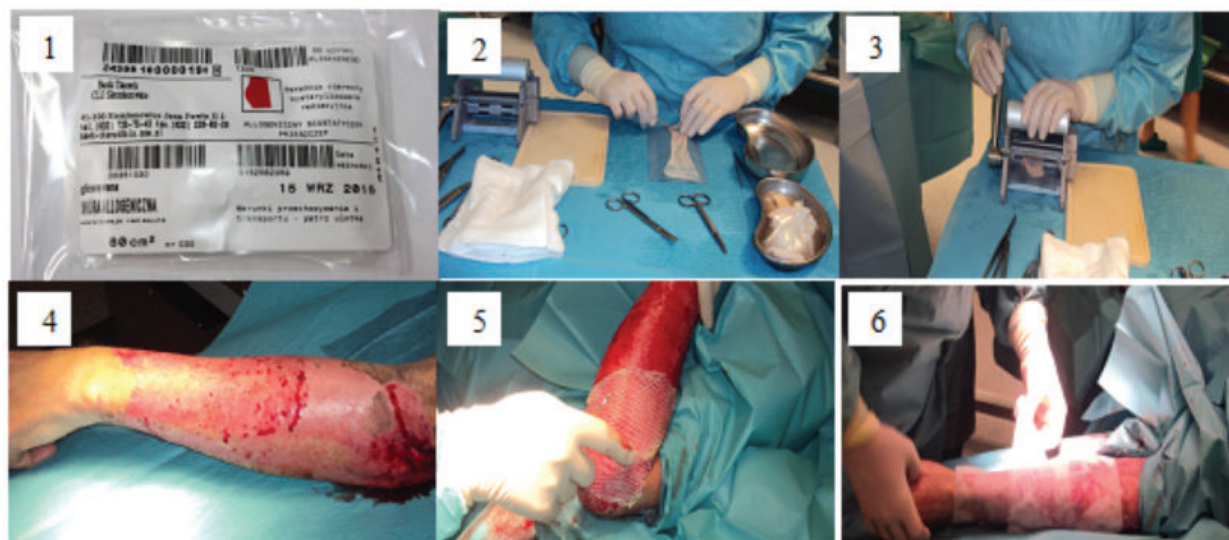
Allogeneic skin, obtained mainly from dead, and rarely from living donors, has the properties of an ideal wound dressing: it protects the wound, stimulates healing and reduces pain. This is why is so successful in treating skin diseases such as Stevens-Johnson's disease and Lyell's disease [22]. Allogeneic skin is also used for the treatment of topical burn wounds and deep wounds alike, especially when there is not enough of the patient's skin available to dress their wound [43, 44]. One of its biggest advantages is the ease of gathering it, the possibility of gathering enough for a huge grafting surface, its low toxicity, the ease of keeping it and the relative ease of application [45]. In the case of both widespread and deep wounds, allogeneic skin used to dress a surgically cleaned wound prevents the skin from losing water, electrolytes and proteins, while at the same time preventing the dehydration of other cells. Moreover, by being a barrier against environmental stimuli, it reduces the proliferation of microorganisms [46]. Thanks to a lowered heat loss experienced by the wound, the hypermetabolic response of the skin to the burn wound diminishes. In wounds suffered by all the layers of skin and thus lacking regenerative potential, an allogeneic skin transplant stimulates the granulation process and wound epithelization, thus creating a stroma for further surgical intervention [47]. The allogeneic skin is also a good biological dressing, which is effective in the treatment of burn wounds of medium depth, covering the epidermis and the dermis. The allogeneic skin initiates the growth of blood vessels in the wound bed and stimulates revascularization. While closely adhering to the stroma, it minimizes the level of pain and reduces the amount of necessary dressing changes, allowing for the process of the recreating of the epidermis to continue while the allogeneic skin disassociates itself from it without violating the emerging epidermis [48]. In certain cases, allogeneic skin serves as a dressing of wounds previously covered by mesh transplants of autologous skin, allowing to minimize metabolic stress and prevent infections within the wound and creating scaffolding for *in vitro* cultured keratinocytes [42]. In the Center of Wound Treatment in Siemianowice Śląskie, allogeneic skin is the standard operating procedure for patients with severe wounds, allowing for the temporary dressing and protection of wounds [49]. Moreover, it is also used when the exact depth of the wound cannot be determined while a risk of the wound deepening and the loss of the entire autologous transplant exists [50]. In our clinic, allogeneic skin is used also for the treatment of wounds of medium depth as a dressing meant for the stimulation of granulation tissue and the final closing of the wound thanks to its initiation of the epithelization process [51]. Allogeneic skin was first included in preparations in 2009 while the first transplant was executed in early 2010. At first, it was sourced from multiple organs. Due to clinical demand, from 2014 skin from Departments of Forensic Medicine is being used. Skin sourced in the latter way carries the risk of infected material increased by 58%, with the most common pathogen being *Klebsiella pneumoniae* [52]. In 2016, allogeneic skin was transplanted 235 times. The skin was sourced from about 50 donors. Until the end of 2016, the total amount of donors grew to 163. Allogeneic skin transplants sourced from dead people fulfilling the criteria of donors in accordance with the Bill of Law from July 1, 2005 on the sourcing, storage and transplantation of cells, tissue and organs is being prepared in the Cell Bank and *in vitro* Cell Culture Center in the Center for Burn Treatment. The transplants are then sterilized by radiation to eliminate dangerous



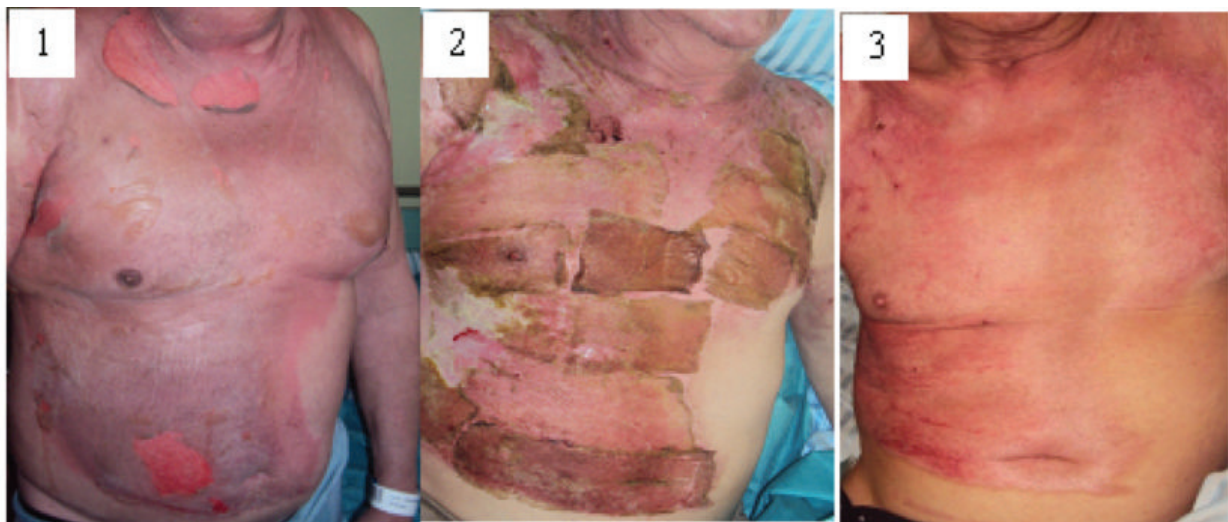
pathogens, microbiologically tested and checked for viruses to conclude the sterilization process. If the results of the tests are negative, skin substitutes are stored in  $-80^{\circ}\text{C}$  until application. The next stage, performed under anesthetics at the Surgical Ward, the burn wounds are surgically cleaned from dead tissue. Then the allogeneic skin is grated and applied to the wound. After the application of the transplant, the wound is dressed in an external wound dressing. The next stages of the dressing of burn wounds by allogeneic skin transplants are pictured in **Figure 5**.

Patients of our Center with IIB wounds and some patients with IIB/III wounds had the allogeneic skin transplant lead to a definitive closing of the wound, despite a previous nephrectomy, resulted in the stimulation of the growth of cells in the wound bed and the revascularization of the wound, as well the initiating of the epithelization process (**Figure 6**). This eliminated the need for an own skin transplant to be performed on the patient [49, 51]. Similar results have been observed by Oliver and associates, who have proven that allogeneic skin modulates the proliferation process, as well as differentiation of granulation tissue [53].

Other patients with deep skin burn wounds had allogeneic skin used as a dressing preventing the loss of water, microelements and proteins, as well protecting them from bacteria and viruses. The dressing was a source of cytokines and growth factors stimulating chemotaxation and the proliferation of cells, stimulated the grantulation of tissue and prepared the stroma for a surgical intervention and provided grounds for the definitive closing of the wound thanks to an autologous skin transplant. Moreover, allogeneic skin is used in the Center when it is impossible to assess the depth of the wound and when there is a clear risk that it can deepen and the transplant can be rejected, as well as when the patient has a limited amount of source beds for own skin transplants [50]. Allogeneic skin is also applied on wounds coming from as escharotomy. To conclude, allogeneic skin is a good alternative to autologous skin transplants. An allogeneic skin transplant results in the complete healing of the wound,



**Figure 5.** The allogeneic, biostatic transplant (1 and 2), the grating of allogeneic skin (3), a IIB burn wound cleaned from dead tissue (4), the application of an allogeneic skin transplant (5) and the application of an external wound dressing (6).



**Figure 6.** The patient on the day of admission to the Center (1), on the third day after the allogeneic skin transplant (2), on the 16th day from the hospital admission (the day of leaving the Center) (3).

eliminating the necessity for own skin sourcing for the transplant, which could result in further complications, pain and scarring. It is worth noting, however, that allogeneic skin can only be a temporary wound dressing, allowing for and facilitating the autologous skin transplant, which remains one of the best methods of closing a burn wound [54].

## 5. Acellular collagen human skin matrix (Acellular dermal matrix, ADM)

In order to improve the properties and the longevity of the transplants, tissue engineering methods such as cell removal are used. The reason for the removal of cells from tissues/organs is the obtaining of a non-immunogenic transplant, which could be populated *in vivo* by the patients' own cells after the transplantation is completed [21]. A transplant devoid of cells is thus composed of the elements of an extracellular matrix, the ECM. The influence of the ECM on the mitogenesis and chemotaxis of cells and their targeted differentiation has been proven. It has also been proven that the ECM induces the creation and promotes the constructive remodeling of the host's tissue. Correctly used materials can modulate certain stages of healing by helping and inducing the transition from the inflammatory period to the constructive restructuring of the fractured cells. Effects observed during the interaction between the used biomaterial and the body of the recipient are complex and include immune system reactions, the proliferation of stem cells and their differentiation [55]. Moreover, ECM has many elements that are produced and populated by its colonizing cells. Between the extracellular matrix and the cells, a dynamic mutual relationship occurs. It affects their microenvironment and the proliferation and differentiation of cells. The described phenomena occur in natural body homeostasis, but are key for the healing of the wound [56]. The ECM cells regulated the biosynthesis of collagen and the process of production of other elements of the extracellular synthesis. The role of these cells is the regulation of all the processes of biosynthesis, transformation and degradation of connective tissue [57]. Cellular residue, however, coming from the aftermath

of the process of restructuring of allogeneic cells can provoke an unwanted immune response, which can in turn destroy the transplant [58, 59]. As the autoimmunological response is mostly targeted against proteins and fatty cells of the cellular tissue, the removal of cells from the tissue is a promising method that may lead to the sustaining of the induction of the immune response in the patient's body after the transplant [58, 60, 61]. The removal of cellular components should minimize the immune induced inflammation, which may weaken the biodegradation of the transplanted bioprosthesis. It is worth noting that the process of removing cells from tissue does not completely eliminate the immune response [62]. The process of eliminating cells from tissue/organs is chemical, enzymatic and mechanical in the genesis of how the cellular material is eliminated. In order to the removal of cells from human allogeneic skin, a collagen scaffolding is obtained, which can be *de novo* peopled by autologous skin cells and transplanted into the area that lacks [33]. The process of removing cells from tissues/organs is comprised of chemical, enzymatic and mechanical techniques of elimination of cellular matter. Thanks to the removing of cells from human allogeneic dermis, collagen scaffolding is obtained. It can be *de novo* populated by autologous skin cells and transplanted into the skin damage area. The method of treating burn wounds based on the use of human allogeneic, acellular extracellular matrix of the dermis (acellular dermal matrix, ADM) as a matrix for *in vitro* cultivated autologous fibroblasts and keratinocytes can be an effective method in the treatment of burn wounds [22]. The clinical need of using this method arises in patients with deep burn wounds of at least 50% TBSA and when the sites from which the skin was obtained for autologous skin grafting heal badly [12, 15]. In the Dr Stanisław Sakiela Burn Centre in Siemianowice Śląskie, the application of acellular human skin matrix (ADM) began in 2015. Until March 2017, an ADM transplant was executed on six patients. Those qualified for the procedure had deep burn wounds which healed badly. Based on the obtained results and clinical observation, we concluded that the use of ADM with *in vitro* cultured skin cells can be an optimal treatment method for burn wounds. To obtain a definitive scientific result, however, the number of the analyzed cases has to be increased [63–66].

## 6. Skin substitutes

The use of skin substitutes is an alternative to auto- and allogeneic transplants in the treatment of wounds of various provenance, including burn wounds and chronic wounds. Skin substitutes have to meet certain criteria to fulfill their function as actual "substitutes". They should not be immunogenic for the patient. They should modulate the proteolytic activity of the wound. The main role of synthetic skin substitutes is the provision of a bioresorptive scaffolding which facilitates cellular migration and deposition of the extracellular matrix [23]. This scaffolding should also stimulate angiogenesis and promote the migration of skin cells (fibroblasts), stimulate the synthesis of granulation and absorb and neutralize free radicals. The ideal skin substitutes should be commonly available and able to recreate various functions and layers of the skin in a short time. Skin substitutes have to undergo vascularization quickly and integrate fast into the wound bed of the patient. The majority of the currently available materials are based on scaffoldings of cattle collagen (e.g. Integra) or beef collagen as



well as allogeneic keratinocytes and fibroblasts (Apligraf) [24]. Other substitutes are human-based skin equivalents, such as Apligraf®, Dermagraft® or TheraSkin® [25]. Other substitutes are acellular, natural biopolymer scaffoldings, such as Kolagen, Oasis®, GraftJacket®, DermACELL®, EpiFix®, Integra™, Promogran™, alginians and chitozans.

In the case of burn wounds, the first stage of treatment is the removal of dead tissue and a temporary wound closing, which at best may be definitive [30, 67]. A necrotomy procedure, removing the source of the infection, which is dead cells, affects the humoral reaction of the system and the amount of endotoxins in the patient's blood [30, 68]. There are many substitutes that can be used for wound dressing. In our Center, we use human biostatic transplants skin, allogeneic amnion, cellular transplants (of keratinocytes and fibroblasts) as well as commercially available synthetic substitutes. Based on years of clinical research, we developed recommendations for the use of particular skin substitutes. We have experience in the use of three commercially available skin substitutes: Suprathel, Oasis and Biobrane. Shallow wounds, usually of the IIA type, benefit from Suprathel as an epidermis substitute. The decision on using a certain skin substitute is made every time by the lead doctor for every given patient. The final decision on the use of a synthetic substitute instead of an own skin transplant of an allogeneic transplant is often made in the operations room after the cleansing of the wound.

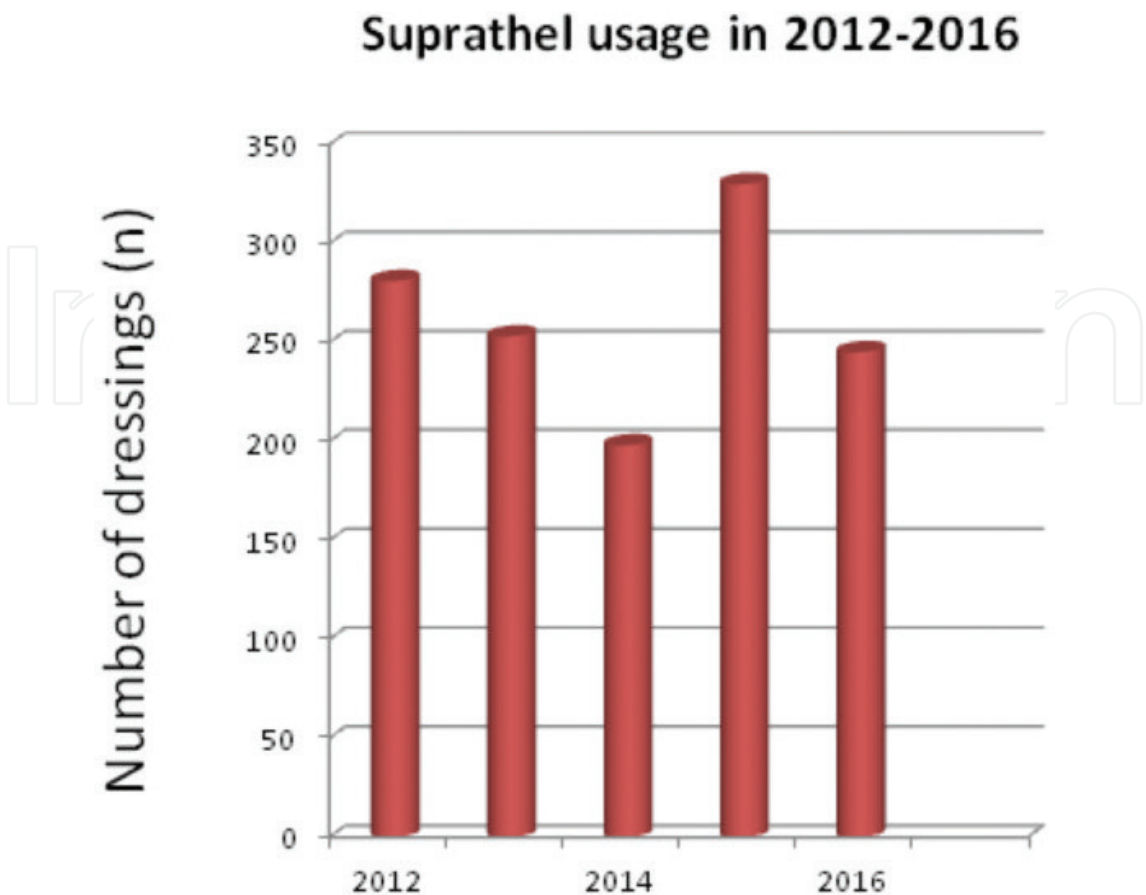
Suprathel is a resorbed epidermis substitute characterized by a high permeability of oxygen and steam and matching the physiological qualities of human skin. The pH of the dressing is initially 5.5 and a later 4.0 (in *in vitro* conditions). The risk of infection when using this dressing is minimal. Suprathel is made of lakto-kapromer, its main ingredient being *polylactic acid*. It is fully synthetic and does not include collagen, so the biological risk is fully eliminated here. The time of hydraulic degradation of the dressing is 4 weeks.

We use Suprathel in our Center since 2011. That year, we used this substitute on burn wounds of 5 × 5 cm area in five patients and on the 9 × 10 cm in five patients. Starting in 2012 and upon the observation of the first clinically positive effects of the dressing, Suprathel became more and more popular in our Center. Below is a diagram detailing the use of Suprathel in 18 × 23 cm increments in 2012–2016 (**Figure 7**).

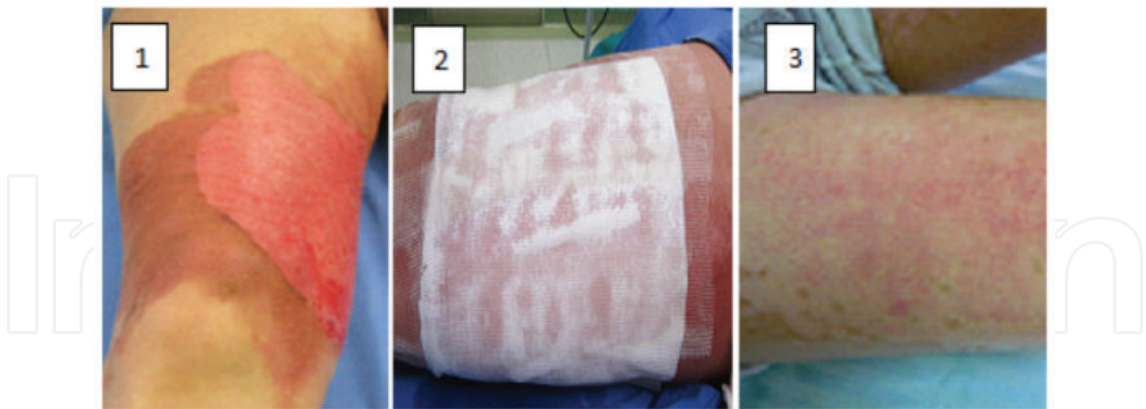
During these years, Suprathel was mainly used in the Surgical Ward in artificial skin transplants. However, it was used twice in the Anesthesiology and Intensive Therapy Ward (**Figure 8**).

Deeper, IIB wounds are treated by Biobrane and Oasis in our Center. Biobrane is a dressing made of ultrathin, half-permeable membrane kept together by an elastic nylon band. It is made of a nontoxin mix of highly purified peptides made from collagen isolated from porcine skin and kept together by a nylon/silicone membrane. This structure ensures high elasticity and a fitting of the dressing to the wound. This substitute is highly adjoined and very hydrophilic and biocompatible. It is a 3D structure, containing a natural extracellular matrix facilitating the migration of cells, the filling of the wound and the stimulation of healing [45, 69]. In our Center, Biobrane was used as the first commercially available skin substitute. In 2008–2012, it was used in the burn wound ward: once in the 13 × 13 cm size and nine times





**Figure 7.** The amount of Suprathel used in 2012–2016.



**Figure 8.** The wound (1) before the application of Suprathel (2) after the application of a substitute (3) upon healing with Suprathel.

in the 13 × 38 cm size. In the first stage, Biobrane was used in the cosmetic treatment of burn and chronic wounds and used with anesthetics. Later on, Biobrane was also used during surgery. Biobrane is a mutlipurpose biosynthetic dressing [70]. It is a relatively inexpensive, easy to store and reliable dressing when used according to recommendations [71]. Despite its several pros, Lal et al. suggest that it should only be used on wound not deeper than 25%

TBSA to exclude the risk of infection [72]. Hubik et al. confirm that Biobrane carries a 37.8% risk infection [73]. Our experience confirms this data: in rare cases, an infection of the substitute occurred after it was transplanted on the cleansed burn wounds. Oasis is another skin substitute good for deeper wounds and chronic, seeding wound of the IIB type. This substitute is a natural matrix (Healthpoint) made of submucosal porcine lower intestine containing ECM (>90% collagen). It is thin (ca. 0.15 mm), half transparent and contains mainly type I collagen. The porcine component has a porous structure with pores of 20–30  $\mu\text{m}$  that allow for the diffusion of oxygen and facilitates the survival of cells [74]. It maintains the biological activity of other skin elements that allow for binding of the cell growth factor and enzymes degrading the matrix, which allows an increased permeability of the cells and their accessing the fractured tissue. The matrix is the place of settling of glycosaminoglycans, proteoglycans, fibronectin and other growth factors, which gives it is responsible for the substantial biological activity of this substitute [75–77]. This way, it gives not only the structural matrix, but provides growth factors as well, stimulating the angiogenesis and cellular migration, regulating the proteolytic activity and halting the extracellular matrix metalloproteinase: MMP-1, MMP-2 and MMP-9, affecting the migration of keratinocytes [78]. In our Center, we demarcated the matrix and applied the Oasis dressing during one procedure in the case of six patients between 2009 and 2015. In the case of each of these substitutes, the proper preparation of the wound bed is key. The wound has to be chemically or surgically cleansed. A very good method is VersaJet—a water knife removing dead cells. A wound cleansed of dead tissue has to be dressed with the substitute as recommended by the producer in terms of direction. The protection of the substitute is achieved by covering it with gauze soaked in vaseline (e.g. Jelonet), which is further covered by gauze dressings ready to be injected with water and covered with bandage. The change of the dressing should happen no earlier than in the second day after the surgical procedure. Due to Suprathel being biodegradable, there is no need to remove it after the changing of the dressing unless an infection occurs. In this case, the infected substitute has to be removed immediately, cleanse the wound again and introduce antibacterial or antifungal procedures. To conclude, the use of commercially available skin substitutes in the treatment of burn and chronic wounds is a common practice in most Centers dealing with these kinds of wounds. Due to the high differentiation of the available products, each Center should develop its own procedure governing their good use. The procedures we described are ready recommendations for the use of commercially available skin substitutes which can be implemented in the treatment of patients with burn and chronic wounds. Due to their structure, epidermis substitutes are good for shallow wounds no deeper than IIA. Synthetic epidermis substitutes and natural skin substitutes may be equivalent to free skin transplants of medium depth and can be used on cleansed wounds no deeper than IIB [79, 80].

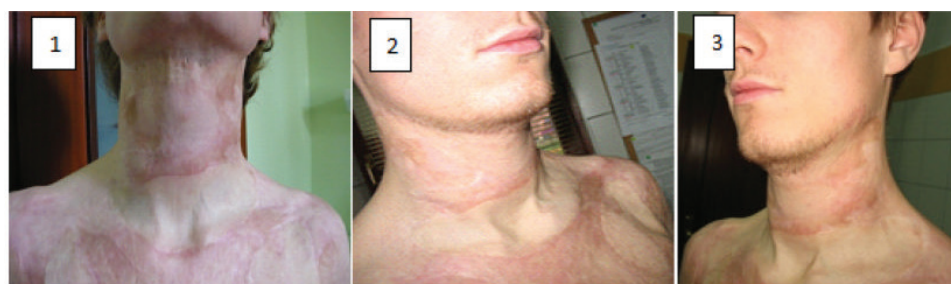## 7. Scars treatment

Another group of skin substitutes is made of acellular synthetic polymer matrix. While they are available on the market of skin substitutes, they have various limitations, such as limiting vascularization, heightening scarring, low mechanical resistance and the danger of being rejected

by the patients' immunological system. Synthetic skin substitutes often do not vascularize, which leads to the necrosis of cells and the final separation of the transplant from the wound [26]. An important limitation for the use of commercially available skin substitutes is the creation of scars, which lead to functional, mechanical and esthetic problems [27]. Even though scarring is a part of normal wound healing, it often leads to a pathological process. When the connective tissue fills the fractured skin part, it does not lead to the creation of a regular skin tone as the fibrous tissue lacks natural skin pigment. The connective tissue lacks hair follicles as well, which is why scars in hairy places can pose serious esthetic challenges. The uncovering and mechanisms of scarring would allow to determine the exact prophylaxis and therapeutic measures to undertake. A series of methods for the treatment of scars exist, yet neither one of them is fully effective. Since the use of one single method provokes a rapid relapse of the illness, a combined therapeutic approach is usually administered, allowing for a good cosmetic effect [28]. The combined therapeutic approach employing cryotherapy alone or combined with the use of steroids is one of the leading ways of scar treatment. Another method of improvement of the visual features of wounds is laser therapy. Its effectiveness is judged in various ways because of the type of wounds that can undertake this therapy. Its effects are usually augmented by corticosteroids. Another method, pressotherapy is based on treating scars by administering controlled pressure. Different compression models, compression clothes and clips' are used to this effect [29]. When scar treatment methods prove insufficient, surgical intervention becomes necessary. It involves the removal of the pathological skin tissue fragment and replacing it with new and healthy skin, usually sourced from other parts of the patients' body. Another surgical method for burn removal is the application of tissue stretchers (expanders). The use methods of burn treatment should result in the improvement of esthetic qualities of the patient, which further affect their self-confidence and quality of life [81]. More importantly, however, the aim of the therapy is to minimize clinical symptoms by minimizing or eliminating pain and burning and obtaining the full functionality of the joints affected by scarring. Wound treatment is a process of many stages, including various therapeutic methods depending on the level of maturity of the wound. The surgical procedure itself must be planned in a way that has in mind the caring for the scars. The removal of the necrosis should lead to retention of a reticular layer of the dermis, which allows for the faster healing of a wound thanks to less closely adhering scar. The use of VersaJet in the early resection of the necrosis positively impacts the look of the cleansed wounds. Depending on the type of transplant, the look of the wound at various stages of healing can be very different. The best esthetic effects are obtained by closing the wound with an autologous transplant of medium depth. A good cosmetic effect is also obtained by an *in vitro* transplant of autologous keratinocytes and fibroblasts in the grafted transplant of medium density. We have observed a good cosmetic effect of commercially available skin substitutes (Oasis, Biobrane). Besides prophylaxis, the treatment of wounds should lead to the creation of a soft, regular, non-discolored surface. During the treatment, the creation of pathological wounds has to be avoided thanks to the provision of quick wound healing, the prevention of infections or and scar contractures (thanks to railing and rehab). At the first stage, a mild finger massage of the wound and the use of silicone gels and ointments are recommended. The silicone prevents the loss of water, the drying and chapping of the wound and alleviates the burning sensation. A layer of ointment or gel protects the wound from external dangers and mechanical damage, as well as creating slight pressure, which is why a finger massage is recommended before its application. The use of silicone band

aids is recommended at the night-time, as they delicately pressurize the wound, preventing its drying. The most common silicone gels are Dermatix, Veraderm, Medigel and Cicacare and band aids are used [82]. Constant wound pressuring is obtained by pressotherapy using flexible fabrics. The effectiveness of the therapy depends on the choice of the correct pressure: too little may not be effective, too much may lead to side effects such as chafes, abrasions, maceration of the skin, sores or blisters. In the treatment of severe burn wounds, pressure clothing is used, employing slight pressure, classified by the European Standardization Commission as class I (18–21 mmHg). These clothes should be used for 6–24 months from the end of the wound healing until cosmetic effects such as the flattening, whitening and reduction of the size of the scar are achieved. The effectiveness of pressure clothing depends on their size, which is why they have to be fitted exactly and exchanged in the case of a change in body size (specifically in children) [82]. Scars can be treated by various methods. In our Center, we most commonly employ surgical treatment and laser therapy. Wound correction may comprise of their cutting out and sewing together, thus changing their direction and alleviating skin pressure. The cutting of skin must be undertaken with respect to the Langer lines. Surgical methods of wound healing used in our Center are topical, such as the “Z” method, based on making a cut of the “Z” shape. The middle part of this cut is perpendicular to the long axis of the closed wound and situated at least 3 cm from the wounds’ brim. The angles between this section and the rest should be 30–90°. During the coming together of the wound brims, the resulting triangular areas change places and the “Z” shape changes from perpendicular to parallel to the long axis of the wound. This method was used six times a year. Another method of surgical wound treatment is using neighboring skin. It is thicker and stronger than the transplanted skin, which is why it can be used on areas devoid of veins. These methods are used in the treatment of contracted wound of the limbs, corpus and eyelids [83–85]. Laser therapy may, depending on the type of the laser, be used in the treatment of wounds at various stages of their maturity. At the level of wound healing, biostimulating lasers can be used. Biostimulation used low energy lasers (stimulants). These lasers emit rays up to 5 mW [83], and the wavelengths emitted by the lasers used in the biostimulation fall in the middle of the electromagnetic spectrum [84]. Biostimulation uses mainly lasers such as the He-Ne laser helium-neon and the arsen-gala semiconductor diode. The biostimulation process itself is effective in providing a predetermined amount of energy, expressed in Joules (J) to an appropriate depth. The degree of absorption and the penetration of the radiation are dependent on both the structure of the irradiated tissue, its blood flow, pH, water content, pigment, melanin and hemoglobin, as well as the wavelength, the color of light, its strength and the duration of treatment [84]. Upon the formation of the scar, our Center uses CO<sub>2</sub> laser ablation. The CO<sub>2</sub> laser emits radiation at a wavelength of 10,600 nm, which is continuous at the power of 30–100 W [83]. The radiation emitted by a CO<sub>2</sub> laser is invisible to the eye and absorbed by the intra- and extracellular fluid [85]. The absorption of the laser light is not selective and results in tissue damage to a depth of 0.6 mm. This causes thrombotic necrosis reaching 0.4–0.5 mm deep. A reticular layer of the skin is then formed due to thermal damage to the surrounding area of evaporation, which can sadly cause significant scarring at the site around the lesion [85]. The beneficial effect of the CO<sub>2</sub> laser radiation on tissue involves the evaporation of the affected tissue. This impact can, however, be complicated by adverse changes in the skin [85, 86]. This laser is used in the treatment of scars due to the very good absorption of water and shallow penetration of the tissue. Since water is the major component of tissues, it allows the beam of the laser to cut both soft tissue and even





**Figure 9.** The wound before (1) laser therapy, after the first session (2) after the second session (3).

bone. This is why the laser is used in other medical fields such as gynecology, dermatology, ENT, where surgical intervention is necessary [83, 87]. CO<sub>2</sub> laser ablation procedures must be repeated three to five times to make their effects lasting and sufficient. Long intervals between treatments must be kept, allowing from 4 to 5 weeks to regenerate the patient's tissue. It is important to maintain sufficient extent of treatment, as during each session of laser therapy, it is only performed in about 15–25% of the scars (**Figure 9**). These treatments are performed in our Center's department of cosmetic surgery on an average of 96 times a year, with 93 times being laser therapy aiding in condition of scarring and fibrosis of the skin [88].

To conclude, the process of healing scars comes in stages and begins with the resection of the necrosis, which has to be carried out in such a way as to leave a layer of reticularis dermis and to perform the cuts Langer lines. This is the first stage of prophylaxis to prevent the formation of ugly scars. The type of transplant has a decisive influence on the appearance of scars, with the most cosmetically sound scars created by a medium depth solid transplant or an autologous keratinocytes and fibroblasts transplant in the scaffolding of a reticulated transplant. The very process of scar treatment should begin as soon as possible. Already the wound healing process can be aided by biostimulating lasers. The prophylaxis of scars includes the prevention of wound infection and contracted scars. Upon healing of the wound, the first step of scar treatment is a finger massage and the use of silicone gels and ointments, then pressure therapy using pressure clothing. Upon the forming of pathological scars, surgical methods such as the "Z" cut method and neighboring skin method, as well as laser therapy using the ablative CO<sub>2</sub> laser.

## Author details

Diana Kitala<sup>1\*</sup>, Agnieszka Klama-Baryła<sup>1,2</sup>, Wojciech Łabuś<sup>1</sup>, Marcelina Misiuga<sup>1</sup>, Mariusz Nowak<sup>1</sup> and Marek Kawecki<sup>1,3</sup>

\*Address all correspondence to: dp.kitala@gmail.com

1 Dr Stanisław Sakiel's Burn Treatment Centre, Siemianowice Śląskie, Poland

2 Silesian Higher Medical School in Katowice, Katowice, Poland

3 Department of Health Sciences, Technical-Humanistic Academy, Bielsko-Biała, Poland

## References

- [1] Ogliari KS, Marinowic D, Brum DE, Loth F. Stem cells in dermatology. *Anais Brasileiros de Dermatologia*. 2014;**89**(2):286-292. DOI: 10.1590/abd1806-4841.20142530
- [2] Sorg H, Betzler C, Rennekampff HO, Vogt PM. Burns. *Unfallchirurg*. 2012;**115**(7):635-648. DOI: 10.1007/s00113-012-2239-3
- [3] Shen YM, Hu XH, Mi HR, Yu DN, Qin FJ, Chen H, Wang H, Zhang GA. Early treatment of high-voltage electric burn wound in the limbs. *Zhonghua Shao Shang Za Zhi*. 2011;**27**(3):173-177
- [4] Petrof G, Abdul-Wahab A, McGrath JA. Cell therapy in dermatology. *Cold Spring Harb Perspect Med*. 2014;**4**(6):pii: a015156. DOI: 10.1101/cshperspect.a015156
- [5] Official Journal of the European Union. Commission Directive 2009/120/EC of 14 September 2009 amending Directive 2001/83/EC of the European Parliament and of the Council on the Community code relating to medicinal products for human use as regards advanced therapy med [Internet]. 2009. Available from: [http://ec.europa.eu/health/sites/health/files/files/eudralex/vol-1/dir\\_2009\\_120/dir\\_2009\\_120\\_en.pdf](http://ec.europa.eu/health/sites/health/files/files/eudralex/vol-1/dir_2009_120/dir_2009_120_en.pdf) [Accessed: 14-02-2017]
- [6] Official Journal of the European Union 10.12.2007. European Parliament and Council (2007). Regulation (EC) No 1394/2007 of the European Parliament and of the Council of 13 November 2007 on advanced therapy medicinal products and amending Directive 2001/83/EC and Regulation (EC) No 726/2004 [Internet]. 2007. Available from: [http://www.biosafety.be/PDF/1394\\_2007\\_EN.pdf](http://www.biosafety.be/PDF/1394_2007_EN.pdf)
- [7] European Medicines Agency. Scientific advice and protocol assistance [Internet]. [Updated: 2012]. Available from: [http://www.ema.europa.eu/ema/index.jsp?curl=pages/regulation/general/general\\_content\\_000300.jsp&mid=WC0b01ac058007f4bd](http://www.ema.europa.eu/ema/index.jsp?curl=pages/regulation/general/general_content_000300.jsp&mid=WC0b01ac058007f4bd) [Accessed: 14-02-2017]
- [8] Celis P. CAT—the new committee for advanced therapies at the European Medicines Agency. *Bundesgesundheitsblatt, Gesundheitsforschung, Gesundheitsschutz*. 2010;**53**(1): 9-13. DOI: 10.1007/s00103-009-0998-y
- [9] Blais M, Parenteau-Bareil R, Cadau S, Berthod F. Concise review: Tissue-engineered skin and nerve regeneration in burn treatment. *Stem Cells Translational Medicine*. 2013;**2**(7): 545-551. DOI: 10.5966/sctm.2012-0181
- [10] Klama-Baryła A, Kraut M, Łabuś W, Maj M, Kawecki M, Nowak M, Glik J, Cichowski A, Szydło A, Lesiak M, Anioł J, Sieroń AL. Application of platelet leukocyte gel in in vitro cultured autologous keratinocyte grafts. *Journal of Orthopaedics Trauma Surgery and Related Research*. 2011;**2**(22):77-86
- [11] Sumide T, Nishida K, Yamato M, Ide T, Hayashida Y, Watanabe K, Yang J, Kohno C, Kikuchi A, Maeda N, Watanabe H, Okano T, Tano Y. Functional human corneal endothelial cell sheets harvested from temperature-responsive culture surfaces. *The FASEB Journal*. 2006;**20**(2):392-394. DOI: 10.1096/fj.04-3035fje

- [12] Bargues L, Prat M, Leclerc T, Bey E, Lataillade JJ. Present and future of cell therapy in burns. *Pathologie-Biologie*. 2011;**59**(3):e49-e56. DOI: 10.1016/j.patbio.2009.12.006
- [13] Jeong JH. Adipose stem cells and skin repair. *Current Stem Cell Research & Therapy*. 2010;**5**(2):137-140
- [14] Danner S, Kremer M, Petschnik AE, Nagel S, Zhang Z, Hopfner U, Reckhenrich AK, Weber C, Schenck TL, Becker T, Kruse C, Machens HG, Egaña JT. The use of human sweat gland-derived stem cells for enhancing vascularization during dermal regeneration. *The Journal of Investigative Dermatology*. 2012;**132**(6):1707-1716. DOI: 10.1038/jid.2012.31
- [15] Kawecki M, Hoff-Lenczewska D, Klama-Baryła A, Glik J. Oparzenia. In: Dziki, editor. *Przegląd Piśmiennictwa Chirurgicznego*. Fundacja Polski Przegląd Chirurgiczny: Warsaw; 2013
- [16] Hoff-Lenczewska D, Klama-Baryła A, Kawecki M, Łabuś W, Glik J, Maj M, Gola J, Mazurek U, Sieroń AL. The use of modern Technologies of cell and tissue engineering in burn treatment. *Acta Biochimica Polonica*. 2012;(supplement 1):17-22
- [17] Kim SW, Zhang HZ, Guo L, Kim JM, Kim MH. Amniotic Mesenchymal stem cells enhance wound healing in diabetic NOD/SCID mice through high angiogenic and engraftment capabilities. *PLoS One*. 2012;**7**(7):e41105. DOI: 10.1371/journal.pone.0041105
- [18] Hartmann-Fritsch F, Hosper N, Luginbühl J, Biedermann T, Reichmann E, Meuli M. Human amniotic fluid derived cells can competently substitute dermal fibroblasts in a tissue-engineered dermo-epidermal skin analog. *Pediatric Surgery International*. 2013;**29**(1):61-69. DOI: 10.1371/journal.pone.0041105
- [19] Mahmoudi-Rad M, Abolhasani E, Moravvej H, Mahmoudi-Rad N, Mirdamadi Y. Acellular amniotic membrane: An appropriate scaffold for fibroblast proliferation. *Clinical and Experimental Dermatology*. 2013;**38**(6):646-651. DOI: 10.1111/ced.12087
- [20] Wilshaw SP, Kearney J, Fisher J, Ingham E. Biocompatibility and potential of acellular human amniotic membrane to support the attachment and proliferation of allogeneic cells. *Tissue Engineering. Part A*. 2008;**14**(4):463-472. DOI: 10.1089/tea.2007.0145
- [21] Sood R, Roggy D, Zieger M, Balledux J, Chaudhari S, Koumanis DJ, Mir HS, Cohen A, Knipe C, Gabehart K, Coleman JJ. Cultured epithelial autografts for coverage of large burn wounds in eighty-eight patients: The Indiana University experience. *Journal of Burn Care & Research*. 2010;**31**(4):559-568. DOI: 10.1097/BCR.0b013e3181e4ca29
- [22] Pellegrini G, Ranno R, Stracuzzi G, Bondanza S, Guerra L, Zambruno G. The control of epidermal stem cells (holoclones) in the treatment of massive full-thickness burns with autologous keratinocytes cultured on fibrin. *Transplantation*. 1999;**68**:868-879
- [23] MS H, Rennert RC, McArdle A, Chung MT, Walmsley GG, Longaker MT, Lorenz HP. The role of stem cells during Scarless skin wound healing. *Advances in Wound Care*. 2014;**3**(4):304-314. DOI: 10.1089/wound.2013.0471

- [24] Mansilla E, Marín GH, Berges M, Scafatti S, Rivas J, Núñez A, Menvielle M, Lamonega R, Gardiner C, Drago H, Sturla F, Portas M, Bossi S, Castuma MV, Luengas SP, Roque G, Martire K, Tau JM, Orlandi G, Tarditti A. Cadaveric bone marrow mesenchymal stem cells: First experience treating a patient with large severe burns. *Burns & Trauma*. 2015;**3**(1):1-9. DOI: 10.1186/s41038-015-0018-4
- [25] Rasulov MF, Vasilchenkov AV, Onishchenko NA, Krashenninnikov ME, Kravchenko VI, Gorshenin TL, Pidtsan RE, Potapov IV. First experience of the use bone marrow mesenchymal stem cells for the treatment of a patient with deep skin burns. *Bulletin of Experimental Biology and Medicine*. 2005;**139**(1):141-144
- [26] Cell Renewal, Naturally™. SkinGun™ and CellMist™ Technology Overview [Internet]. Available from: <http://renovacareinc.com/> [Accessed: 20-02-2017]
- [27] TERUMO BCT, INC. AdiPrep® Adipose Concentration System [Internet]. Available from: <https://www.harvesttech.com> [Accessed: 02-02-2017]
- [28] Fraser JK, Hicok KC, Shanahan R, Zhu M, Miller S, Arm DM. The Celution® system: Automated processing of adipose-derived regenerative cells in a functionally closed system. *Advances in Wound Care*. 2014;**3**(1):38-45
- [29] Aronowitz JA, Ellenhorn JD. Adipose stromal vascular fraction isolation: A head-to-head comparison of four commercial cell separation systems. *Plastic and Reconstructive Surgery*. 2013;**132**(6):932e-939e. DOI: 10.1097/PRS.0b013e3182a80652
- [30] Kawecki M, Glik J, Kitala D, Misiuga M. Oparzenia [Burns]. In: Dziki A, editor. *Przegląd Piśmiennictwa Chirurgicznego*. 1st ed. Łódź: Stowarzyszenie Popierania Rozwoju Proktologii; 2017. p. 192-196
- [31] Halim AS, Khoo TL, Mohd SJ. Biologic and synthetic skin substitutes: An overview. *Indian Journal of Plastic Surgery*. 2010;**43**(Suppl):S23-S28. DOI: 10.4103/0970-0358.70712
- [32] Gierek M, Kawecki M, Mikuś K, Glik J, Klama-Baryła A, Hoff-Lenczewska D, Nowak M. The treatment of burns wounds with human amniotic membrane dressings in the Centre for Burns in Siemianowice Śląskie—Own experience. *Journal of Orthopaedics Trauma Surgery and Related Research*. 2012;**3**(29):75-83
- [33] Gierek M, Kawecki M, Mikuś K, Glik J, Klama-Baryła A, Hoff-Lenczewska D, Nowak M. Use of amniotic membrane in treatment of burns. *Journal of Orthopaedics Trauma Surgery and Related Research*. 2012;**3**(29):70-75
- [34] Strom SC, Gramignoli R. Human amnion epithelial cells expressing HLA-G as novel cell-based treatment for liver disease. *Human Immunology*. 2016;**77**(9):734-739. DOI: 10.1016/j.humimm.2016.07.002
- [35] He H, Li W, Chen SY, Zhang S, Chen YT, Hayashida Y, Zhu YT, Tseng SC. Suppression of activation and induction of apoptosis in RAW264.7 cells by amniotic membrane extract. *Investigative Ophthalmology & Visual Science*. 2008;**49**(10):4468-4475. DOI: 10.1167/iovs.08-1781



- [36] Alikarami F, Yari F, Amirizadeh N, Nikougoftar M, Jalili MA. The immunosuppressive activity of amniotic membrane mesenchymal stem cells on T lymphocytes. *Avicenna Journal of Medical Biotechnology*. 2015;**7**(3):90-96. DOI: PMC4508338
- [37] Barling PM, John MJ, Walsh JR, Niall HD. The isolation and characterization of lysozyme from human foetal membranes: A comparison with the enzyme from other sources. *Comparative Biochemistry and Physiology Part B*. 1985;**81**(2):509-513 PMID: 4017555
- [38] Flores-Espinosa P, Pineda-Torres M, Vega-Sánchez R, Estrada-Gutiérrez G, Espejel-Núñez A, Flores-Pliego A, Maida-Claros R, Paredes-Vivas Y, Morales-Méndez I, Sosa-González I, Chávez-Mendoza A, Zaga-Clavellina V. Progesterone elicits an inhibitory effect upon LPS-induced innate immune response in pre-labor human amniotic epithelium. *American Journal of Reproductive Immunology*. 2014;**71**(1):61-72. DOI: 10.1111/aji.12163
- [39] Taghiabadi E, Nasri S, Shafieyan S, Jalili Firoozinezhad S, Aghdami N. Fabrication and characterization of spongy denuded amniotic membrane based scaffold for tissue engineering. *Cell Journal*. 2015;**16**(4):476-487. DOI: 10.22074/cellj.2015.493
- [40] Zhang T, Yam GH, Riau AK, Poh R, Allen JC, Peh GS, Beuerman RW, Tan DT, Mehta JS. The effect of amniotic membrane de-epithelialization method on its biological properties and ability to promote limbal epithelial cell culture. *Investigative Ophthalmology & Visual Science*. 2013;**54**(4):3072-3081. DOI: 10.1167/iovs.12-10805
- [41] DiDomenico LA, Orgill DP, Galiano RD, Serena TE, Carter MJ, Kaufman JP, Young NJ, Zelen CM. Aseptically processed placental membrane improves healing of diabetic foot ulcerations: Prospective, randomized clinical trial. *Plastic and Reconstructive Surgery-Global Open*. 2016;**4**(10):e1095. DOI: 10.1097/GOX.0000000000001095
- [42] Rogers AD. Indications for cadaver skin in burns and complex wound care. *Wound Healing Southern Africa*. 2013;**6**(2):54-55
- [43] Fletcher JL, Caterson EJ, Hale RG, Cancio LC, Renz EM, Chan RK. Characterization of skin allograft use in thermal injury. *Journal of Burn Care & Research*. 2013;**34**(1):168-175. DOI: 10.1097/BCR.0b013e318270000f
- [44] Kagan RJ, Peck MD, Ahrenholz DH, Hickerson WL, Holmes J 4th, Korentager R, Kraatz J, Pollock K, Kotoski G. Surgical management of the burn wound and use of skin substitutes: An expert panel white paper. *Journal of Burn Care & Research*. 2013;**34**(2):e60-e79. DOI: 10.1097/BCR.0b013e31827039a6
- [45] Selig HF, Lumenta DB, Giretzlehner M, Jeschke MG, Upton D, Kamolz LP. The properties of an “ideal” burn wound dressing—What do we need in daily clinical practice? Results of a worldwide online survey among burn care specialists. *Burns*. 2012;**38**(7):960-966. DOI: 10.1016/j.burns.2012.04.007
- [46] Cleland H, Wasiak J, Dobson H, Paul M, Pratt G, Paul E, Herson M, Akbarzadeh S. Clinical application and viability of cryopreserved cadaveric skin allografts in severe burn: A retrospective analysis. *Burns*. 2014;**40**(1):61-66. DOI: 10.1016/j.burns.2013.05.006

- [47] Zidan SM, Eleowa SA. Banking and use of glycerol preserved full-thickness skin allograft harvested from body contouring procedures. *Burns*. 2014;**40**(4):641-647. DOI: 10.1016/j.burns.2013.08.039
- [48] Horner CWM, Atkins J, Simpson L, Philp B, Shelley O, Dziewulski P. Estimating the usage of allograft in the treatment of major burns. *Burns*. 2011;**37**(4):590-593. DOI: 10.1016/j.burns.2010.12.006
- [49] Kitala D, Kawecki M, Klama-Baryła A, Łabuś W, Kraut M, Glik J, Ryszkiewicz I, Kawecki MP, Nowak M. Allogeneic vs. autologous skin grafts in the therapy of patients with burn injuries: A retrospective, open-label clinical study with pair matching. *Advances in Clinical and Experimental Medicine*. 2016;**25**(5):923-929. DOI: 10.17219/acem/61961
- [50] Singh V, Devgan L, Bhat S, Miler SM. The pathogenesis of burn wound conversion. *Annals of Plastic Surgery*. 2007;**59**(1):109-115. DOI: 10.1097/01.sap.0000252065.90759.e6
- [51] Misiuga M, Glik J, Kawecki M, et al. The effect of hyperbaric oxygen therapy on burn wounds covered with skin allografts. *Journal of Orthopaedics Trauma Surgery and Related Research*. 2016;**1**(38):17-27
- [52] Kitala D, Klama-Baryła A, Kawecki M, Kraut M, Łabuś W, Glik J, Ples M, Tomanek E, Nowak M. Infections in the tissue material and their impact on the loss of transplants in the laboratory of in vitro cell and tissue culture with tissue Bank in the years 2011-2015. *Cell and Tissue Banking*. 2016;**17**(66):1-8. DOI: 10.1007/s10561-016-9597-y
- [53] Oliver AM, Kaawach W, Mithoff EW, Watt A, Abramovich DR, Rayner CR. The differentiation and proliferation of newly formed epidermis on wounds treated with cultured epithelial allografts. *British Journal of Dermatology*. 1991;**125**(2):147-154
- [54] Debels H, Hamdi M, Abberton K, Morrison W. Dermal matrices and bioengineered skin substitutes: A critical review of current options. *Plastic and Reconstructive Surgery Global Open*. 2015;**3**(1):e284. DOI: 10.1097/GOX.0000000000000219
- [55] Londono R, Badylak SF. Biologic scaffolds for regenerative medicine: Mechanisms of in vivo remodeling. *Annals of Biomedical Engineering*. 2015;**43**(3):577-592. DOI: 10.1007/s10439-014-1103-8
- [56] Kawecki M, Łabuś W, Klama-Baryła A, Kitala D, Kraut M, Glik J, Misiuga M, Nowak M, Bielecki T, Kasperczyk A. A review of decellurization methods caused by an urgent need for quality control of cell-free extracellular matrix' scaffolds and their role in regenerative medicine. *Journal of Biomedical Materials Research—Part B: Applied Biomaterials*, Forthcoming. DOI: 10.1002/jbm.b.33865
- [57] Schmidt C, Baier JM. Acellular vascular tissues: Natural biomaterials for tissue engineering. *Biomaterials*. 2000;**21**(22):2215-2231
- [58] Atiyeh BS, Costagliola M. Cultured epithelial autograft (CEA) in burn treatment: Three decades later. *Burns*. 2007;**33**(4):405-413. DOI: 10.1016/j.burns.2006.11.002

- [59] Grauss RW, Hazekamp MG, van Vliet S, Gittenberger-de Groot AC, DeRuiter MC. Decellularization of rat aortic valve allografts reduces leaflet destruction and extracellular matrix remodeling. *The Journal of Thoracic and Cardiovascular Surgery*. 2003;**126**(6):2003-2010. DOI: 10.1016/S0022
- [60] Sullivan DC, Mirmalek-Sani SH, Deegan DB, Baptista PM, Aboushwareb T, Atala A, Yoo JJ. Decellularization methods of porcine kidneys for whole organ engineering using a high-throughput system. *Biomaterials*. 2012;**33**(31):7756-7764. DOI: 10.1016/j.biomaterials.2012.07.023
- [61] Ott HC, Matthiesen TS, Goh SK, Black LD, Kren SM, Netoff TI, Taylor DA. Perfusion-decellularized matrix: Using nature's platform to engineer a bioartificial heart. *Nature Medicine*. 2008;**14**(2):213-221. DOI: 10.1038/nm1684
- [62] Atiyeh B, Masellis A, Conte C. Optimizing burn treatment in developing low- and middle-income countries with limited health care resources (part 1). *Annals of Burns and Fire Disasters*. 2009;**22**(3):121-125
- [63] Troy J, Karlinski R, Downes K, Brown KS, Cruse CW, Smith DJ, Payne WG. The use of EZ Derm<sup>®</sup> in Partial-Thickness Burns: An Institutional Review of 157 Patients. *Eplasty*. 2013;**13**:e14
- [64] Gould LJ. Topical collagen-based biomaterials for chronic wounds: Rationale and clinical application. *Advances in Wound Care*. 2016;**1**(5):19-31. DOI: 10.1089/wound.2014.0595
- [65] Zaulyanov L, Kirsner RS. A review of a bi-layered living cell treatment (Apligraf (R<sup>®</sup>)) in the treatment of venous leg ulcers and diabetic foot ulcers. *Clinical Interventions in Aging*. 2007;**2**(1):93-98
- [66] Di Domenico L, Landsman AR, Emch KJ, Landsman A. A prospective comparison of diabetic foot ulcers treated with either cryopreserved skin allograft or bioengineered skin substitute. *Wounds*. 2011;**23**(7):184-189
- [67] Zhao JH, Diao JS, Xia WS, Pan Y, Han Y. Clinical application of full-face, whole, full-thickness skin grafting: A case report. *Journal of Plastic, Reconstructive & Aesthetic Surgery*. 2012;**65**(11):1576-1579. DOI: 10.1016/j.bjps.2012.04.002
- [68] Lloyd EC, Michener M, Williams MS. Outpatient burns: Prevention and care. *American Family Physician*. 2013;**85**(9):25-32
- [69] Philandrianos C, Andrac-Meyer L, Mordon S, Feuerstein JM, Sabatier F, Veran J, Magalon G, Casanova D. Comparison of five dermal substitutes in full-thickness skin wound healing in a porcine model. *Burns*. 2012;**38**(9):820-829
- [70] Whitaker IS, Prowse S, Potokar TS. A critical evaluation of the use of Biobrane as a biologic skin substitute: A versatile tool for the plastic and reconstructive surgeon. *Annals of Plastic Surgery*. 2008;**60**(3):333-337

- [71] Greenwood JE, Clausen J, Kavanagh S. Experience with biobrane: uses and caveats for success. *Eplasty*. 2009 Jun 26;**9**:e25
- [72] Lal S, Barrow RE, Wolf SE, Chinkes DL, Hart DW, Hegggers JP, Herndon DN. Biobrane improves wound healing in burned children without increased risk of infection. *Shock*. 2000;**14**(3):314-318
- [73] Hubik DJ, Wasiak J, Paul E, Cleland H. Biobrane: A retrospective analysis of outcomes at a specialist adult burns centre. *Burns*. 2011;**37**(4):594-600
- [74] Nihsen ES, Johnson CE, Hiles MC. Bioactivity of small intestinal submucosa and oxidized regeneratem cellulose/collagen. *Advances in Skin & Wound Care*. 2008;**21**(10):479-486
- [75] Hodde JP, Badylak SF, Brightman AO, Voytik-Harbin SL. Glycosaminoglycan content of small intestinal submucosa: A bioscaffold for tissue replacement. *Tissue Engineering*. 1996;**2**(3):209-217
- [76] Hodde JP, Record RD, Liang HA, Badylak SF. Vascular endothelial growth factor in porcine-derived extracellular matrix. *Endothelium*. 2001;**8**(1):11-24
- [77] Shi L, Ronfard V. Biochemical and biomechanical characterization of porcine small intestinal submucosa (SIS): A mini review. *International Journal of Burns and Trauma*. 2013;**3**(4):173-179
- [78] Shi L, Ramsay S, Ermis R, Carson D. In vitro and in vivo studies on matrix metalloproteinases interacting with small intestine submucosa wound matrix. *International Wound Journal*. 2012;**9**(1):44-53
- [79] Moore M, Samsell B, Wallis G, Triplett S, Chen S, Linthurst Jones A, et al. Decellularization of human dermis using non-denaturing anionic detergent and endonuclease: A review. *Cell and Tissue Banking*. 2015;**16**:249-259
- [80] Dumville JC, Keogh SJ, Liu Z, Stubbs N, Walker RM, Fortnam M. Alginate dressings for treating pressure ulcers. *Cochrane Database of Systematic Reviews*. 2015;**3**:CD011277
- [81] O'Meara S, Martyn-St James M, Adderley UJ. Alginate dressings for venous leg ulcers. *Cochrane Database of Systematic Reviews*. 2015;**19**:CD010182
- [82] Kawecki K, Pawlik-Kanpik D, Glik J, Misuga M. Oparzenia. Blizny jako problem w chirurgii oparzeń. In: Dziki A, editor. *Przegląd Piśmiennictwa Chirurgicznego* 2015. Warszawa: Fundacja Polski Przegląd Chirurgiczny ed.; 2016
- [83] Wójcicka P, Gadomska-Krasny J, Zawodny JP. Zastosowanie Laserów w Medycynie Estetycznej. Fotoodmładzanie w terapii przebarwień oraz rozszerzonych naczyń krwionośnych – cz. 1. *OPM*. 2010;**12**:46-49
- [84] Kurkus B, Kuliński W. Laseroterapia w medycynie fizykalnej. *Borgis – Balneologia Polska*. 2005;**3**(4):76-83



- [85] Borzęcki A, Cielica W. Zastosowanie lasera CO<sub>2</sub> w praktyce dermatologicznej. *Borgis-Nowa Medycyna*. 2000;**11**:1-14
- [86] Miturska R, Borzęcki A. Papilloma condylomatoides okolic narządów płciowych i odbytu leczona laserem CO<sub>2</sub>. *Dermatologia Estetyczna*. 2009;**11/6**(65):481-485
- [87] Stocka A, Huryń A, Królicki A, Orzechowska B, Maleszka R. Laseroterapia ablacyjna w leczeniu skórnej manifestacji stwardnienia guzowatego – opis przypadku. *Dermatologia Estetyczna*. 2010;**12/6**(71):367-372
- [88] Macedo JL, Santos JB. Predictive factors of mortality in burn patients. *Revista do Instituto de Medicina Tropical de São Paulo*. 2007;**49**(6):365-370