

# We are IntechOpen, the world's leading publisher of Open Access books Built by scientists, for scientists

6,900

Open access books available

185,000

International authors and editors

200M

Downloads

Our authors are among the

154

Countries delivered to

TOP 1%

most cited scientists

12.2%

Contributors from top 500 universities



WEB OF SCIENCE™

Selection of our books indexed in the Book Citation Index  
in Web of Science™ Core Collection (BKCI)

Interested in publishing with us?  
Contact [book.department@intechopen.com](mailto:book.department@intechopen.com)

Numbers displayed above are based on latest data collected.  
For more information visit [www.intechopen.com](http://www.intechopen.com)



---

## Focused Sonography in Cardiac Arrest

---

Marc Delaney, Bjorn Flora and Sahar Ahmad

Additional information is available at the end of the chapter

<http://dx.doi.org/10.5772/intechopen.70585>

---

### Abstract

Cardiac arrest (CA) is a high mortality event where the ability for clinicians to diagnose etiology and assess for intervention has a direct impact on patient outcomes. Bedside ultrasound (US) has emerged in current literature as a clinical tool to aid clinicians in CA resuscitation, though it remains underutilized. Reversible etiologies that can be efficiently diagnosed with US include tension pneumothorax, hypovolemia, pulmonary embolus with acute cor pulmonale, and cardiac tamponade. Other US findings may provide evidence in regard to prognosis. In this review, we present major applications of US in CA, compare existing protocols, and propose future research needs.

**Keywords:** cardiac arrest, resuscitation, ultrasonography, echocardiography

---

## 1. Introduction

Successful resuscitation in cardiac arrest (CA) requires discrete decision-making regarding circulation, airway, and breathing. It is crucial to identify and treat reversible causes of cardiac arrest during resuscitation in order to make decisions that reverse them and more efficiently achieve return of spontaneous circulation (ROSC) [1]. Bedside ultrasound (US) has emerged as an invaluable tool in the diagnosis and management of critically ill patients, including CA [2, 3]. US may aid to diagnose reversible causes of CA, such as pericardial tamponade, tension pneumothorax, or hypovolemia; guide procedures and other management strategies for quality resuscitation; and reveal signs that can serve in clinical context as prognosticators for the ability to achieve ROSC and longer term recovery. In critical care medicine, bedside US has been found to be faster and have greater sensitivity and specificity than conventional imaging, which is unavailable during resuscitation efforts [4].

Bedside US remains underutilized in resuscitation medicine as there is controversy as to how efficiently and reliably it can be implemented by clinicians, especially in a high-stakes and

time-sensitive setting such as CA. This review will present literature that evaluates implementation of US in CA resuscitation and demonstrates the potential of US to improve patient outcomes.

## **2. Intra-arrest: US to identify reversible causes of cardiac arrest**

The standard of care for advanced cardiac life support (ACLS) during pulseless electrical activity (PEA) or asystolic CA dictates that providers actively work to diagnose and treat the reversible causes of CA. The following is a summary of the role of US in detecting such reversible causes:

### **2.1. Tension pneumothorax**

Tension pneumothorax (PTX) is a well-known etiology of CA, especially in chest trauma, and can be rapidly reversed with emergent evacuation of air by needle or tube thoracotomy. Approximately 1% of non-traumatic in-hospital CA events are caused by PTX [5]. A meta-analysis showed US to be more sensitive and specific than chest roentgenography (CXR) for detecting PTX, with a sensitivity and specificity of 91 and 98% as compared to 50 and 99% for CXR [6]. Another meta-analysis showed that consultant performed and clinician performed US examinations had similar sensitivity and specificity for PTX [7].

US can also investigate how an identified PTX is altering patient physiology, as clinicians can obtain sub-xiphoid cardiac windows to see inferior vena cava (IVC) engorgement with impaired right heart filling as obstructive physiology. Further research is looking into how the location of a specific lung US finding, called lung point, can be used to quantify PTX size, with initial data showing that lung points found in the mid axillary line of supine patients predicting a greater than 15% lung collapse size as measured by CT with a sensitivity of 83% and specificity of 82% [8]. The convenience and repeatability of bedside US for PTX makes it clinically useful in CA [7, 9].

### **2.2. Pericardial effusion with cardiac tamponade**

Cardiac tamponade is a significant contributor to in-hospital CA, with reported incidence as high as 6% of in-hospital CA [5]. Performing cardiac ultrasound, or echocardiography, during chest compression holds, allows for rapid detection of pericardial effusion. Several studies have validated the diagnostic power of US in this setting, including in the hands of non-cardiologist physicians, with reported sensitivities ranging from 96 to 100% and specificities ranging from 87 to 98% [10, 11]. In the medical literature, outside of the case of CA, use of bedside US to detect tamponade physiology is widely supported. Internal medicine (IM) physicians with handheld US devices identified moderate to large pericardial effusions with moderate agreement (kappa of 0.51) compared to cardiologist-read formal echocardiography [12]. Detecting increased central venous congestion in this setting using the presence of IVC plethora on US has shown a sensitivity of 97% for predicting tamponade, with

an understandably small specificity of 40% given the many causes of IVC plethora [13, 14]. Other US predictors of tamponade physiology relate to the enhanced ventricular interdependence seen in tamponade include right atrial collapse (sensitivity of 50–100%, specificity of 33–100%) [15, 16], left atrial collapse (sensitivity of 13%, specificity of 98%), and right ventricular collapse (sensitivity of 48–100%, specificity of 72–100%) [13, 17].

### 2.3. Pulmonary embolus with acute cor pulmonale

US diagnosis of acute cor pulmonale due to pulmonary embolism (PE) relies on identification of right ventricle (RV) enlargement as an important finding during targeted echocardiography. Outside of the case of CA, other findings of acute cor pulmonale include septal flattening or leftward bowing and RV systolic dysfunction [18, 19]. The RV:LV end diastolic diameter ratio, D-sign, and McConnell's sign are validated echocardiography patterns of acute cor pulmonale in PE [20]. Of course, these signs are a product of a large flow-obstructing PE altering hemodynamic physiology in the presence of spontaneous circulation, a factor that is not present at CA. However, several case reports and observational studies have reported that, even during CA, PE can still be identified using the same signs of disproportionate RV size and direct embolism visualization in the pulmonary artery, right atrium, or IVC as a homogeneously echogenic structure independent of underlying anatomy (suggestive of thrombus presence [21–25]). Such findings may lead to change in management including use of thrombolysis, an intervention that could largely benefit mortality in these patients [26, 27]. Administration of thrombolytic agents during cardiopulmonary resuscitation (CPR) is a controversial and high-risk procedure that can produce serious complications, including fatal hemorrhage, leading to controversy in recommendations and guidelines [27]. Interestingly, studies have added contrast to early case reports of hemorrhage including a recent single-center retrospective analysis of 42 patients that found thrombolysis during CA yielded no significant difference in major and minor bleeding events [28]. In regards to resuscitation, one study on 42 CA patients with PE found higher rates of ROSC in patients who received emergent thrombolysis than those who did not (81% vs. 43%,  $p = 0.03$ ) [29]. While prospective data in this setting is sparse, the largest randomized trial was performed by Böttiger et al. in 2008 with 1050 out-of-hospital CA patients. The trial was terminated early due to futility when no significant differences were detected between tenecteplase and placebo groups in 30-day survival, hospital admission rates, ROSC, 24-hour survival, survival to discharge, or neurologic outcomes [30].

Ultrasound can be used to view the lower extremity vessels for a rapid deep venous thrombosis (DVT) study without interfering with compressions or other resuscitation measures. Studies have shown that bedside US DVT exams performed by clinician-sonographers have similar speed and diagnostic accuracy as compared to a formal US study with a radiologist [31, 32]. One meta-analysis of 15 studies and nearly 7000 patients by Rodrigues et al. in 2016 showed that an abbreviated proximal-focused DVT study, had a pooled sensitivity of 41%, and specificity of 96% for DVT detection compared to 79 and 84% of a relatively time-intensive whole-extremity exam [33]. In this study, the positive likelihood ratio of the limited DVT studies was pooled at 11.9, suggesting a utility of this abbreviated study in settings such as cardiac arrest.

While there is a clear need for further research in this area, many sources are advocating for more widespread use of thrombolysis during CPR in CA patients, especially in those where intra-arrest US helps to diagnose PE early and identify those at the highest risk of mortality [34].

## 2.4. Hypovolemia

Perhaps one of the most commonly used applications of bedside US is the evaluation of intravascular volume status and prediction of fluid tolerance or responsiveness [11, 35]. During management of CA, imaging of the IVC can help a code-leader rapidly diagnose hypovolemic shock, a tool whose sensitivity and specificity can be enhanced by adding US images of the lung fields and basic cardiac windows in conjunction with US of the IVC [36].

Early studies involved viewing the IVC in dialysis patients and blood donors, showing differences in IVC diameters pre and post infusions with associated changes in vessel caliber with respiratory cycle thoracic pressure changes [37, 38]. The largest meta-analysis in support of IVC US showed a pooled sensitivity of 76% and specificity of 86% for the detection of fluid responsiveness, defined as improved cardiac output (CO) on cardiac catheterization [39]. In both spontaneously breathing and mechanically ventilated patients, IVC US has high sensitivity and specificity for assessing fluid volume and responsiveness, suggesting applicability in the setting of CA, where hypovolemia may be a reversible etiology of arrest [39, 40]. However, US interrogation of fluid responsiveness during CA requires the clinician to be aware of the altered hemodynamic physiology of CA, where there is significant venous congestion and an elevated central venous pressure associated with decreased cardiac output (CO) [41]. In addition, sonographers need to be aware of the comorbidities that decrease IVC imaging sensitivity for hypovolemia, such as an obstructive physiology such as cor pulmonale, cardiac tamponade, or a myocardial infarction with markedly decreased CO [41].

With this hemodynamic physiology of CA in mind, US evaluation of hypovolemia as a cause of CA can still be useful as IVC imaging can be coupled with rapid and sensitive interrogation of the thoracic, abdominal, and pelvic cavities. In these spaces, such a large volume of fluid can accumulate to where this could cause significant hypovolemia if blood loss into these spaces has decreased effective circulating volume [41, 42]. US evaluation for significant intra-abdominal and pelvic fluid accumulation is a widely accepted modality, with sensitivities ranging from 60 to 100% [43–46]. In the setting of CA, this technique can take place without interruption of compressions and has the potential to alter CA management [47].

## 3. Peri-arrest and post-arrest care: US to guide ACLS

Outside of its use in diagnosing reversible etiologies of CA, US has also been supported by the literature for guidance of interventions in the intra and peri-arrest period.



### 3.1. US to interrogate cardiac rhythm

During CA resuscitation, one can directly visualize the heart both during compressions and at pulse checks. This has allowed clinicians more insight into the physiology of each patient in addition to data provided by pulse palpation and electrical monitors. US has bolstered the clinical utility of categorizing electromechanical dissociation (EMD) into “true-EMD” vs. “pseudo-EMD.” Pseudo-EMD is defined as the sonographic evidence of intrinsic and coordinated myocardial and valvular movement in the absence of a palpable pulse [11, 48, 49]. Several authors have noted that this observation of pseudo-EMD is associated with a better prognosis for ROSC as compared to true-EMD, which shows no contractile movement of the heart. One such prospective observational study involving 49 intensive care unit (ICU) CA events showed pseudo-EMD to occur on US in 55% of PEA patients [48]. This study showed the rates of ROSC were 70% for those in pseudo-EMD compared to 20% for those in true EMD [48, 50]. This US distinction could aid clinicians in their prognostication and decisions to continue or halt resuscitative efforts, with implications to resource utilization. Alternatively, the finding of pseudo-EMD may support a clinical strategy of using vasopressors/inotropes to support this coordinated cardiac activity and better optimize cerebral and coronary perfusion pressures for achieving ROSC. While there is currently no data to support this practice in CA resuscitation, this approach has been utilized with success in shock patients [51, 52].

Similarly, authors have described resuscitative events where “pseudo-asystole” is identified as asystole on electrical cardiac monitor with asynchronous fibrillatory activity of the ventricles on echo, suggesting ventricular fibrillation (VF). In the existing case reports describing this finding, this immediately changed ACLS algorithm as unsynchronized defibrillation was indicated [53–55].

### 3.2. US to guide chest compressions

US has been suggested as a means to optimize the effectiveness of chest compressions and to increase accuracy and efficiency of pulse check intervals [56]. While there remains a paucity of data to support these uses, the potential demonstrated by early case reports warrants discussion. Effective chest compressions allow for adequate coronary and cerebral perfusion pressure during CA [57]. While ACLS guidelines state the optimal site of compressions is on the lower half of the sternum along the nipple line, some studies suggest significant anatomical variation among structures at this site [58]. One study of 30 out-of-hospital CA patients tested this site compared to three caudal alternatives and found that maximal end-tidal carbon dioxide was achieved at the AHA recommended site in only 1/3rd of their sample [59]. Another study using transesophageal echocardiography (TEE) observed 34 non-traumatic CA patients and identified the anatomic area of maximal compression (AMC) to be over the aorta or left ventricular outflow tract in all cases with a statistically significant linear association between LV stroke volume and AMC distance from the aortic valve [60]. In a swine model of cardiac arrest, animals randomized to have compressions centered over their LV, as identified by transesophageal echocardiography (TEE), had a greater proportion of ROSC and survival to 60 minutes compared to those that had compressions centered over their aortic root [61].

While more research in this area is needed, it is reasonable to predict a role for bedside ultrasound and echocardiography to be identifying appropriate positioning for chest compression efforts, either by trans-thoracic echocardiography (TTE) and/or TEE by viewing the anatomic landmarks directly.

### **3.3. US to guide pulse checks**

Current ACLS guidelines state that pulse-checks during CA resuscitation should last no longer than 10 seconds. Some authors have called the accuracy of pulse palpation into question [62]. One study involving pulse palpation during cardiac bypass surgery (spontaneous vs. non-pulsatile blood flow) showed that, while health care providers with advanced levels of training had decreased decision delay, only 16.5% of the participants (34 of 206) were able to reach a confident decision about their patients' pulse status within 10 seconds [63]. A similar earlier study in basic life support-trained personnel found that although sensitivity of all participants for central pulselessness approached 90%, specificity was only 55% [64]. While these studies have their limitations, they call attention to a potential role for ancillary devices to augment the accuracy of pulse palpation. Case reports have shown handheld Doppler US devices can allow for faster pulse checks in patients during in-hospital CA [62]. Other authors have already reported the utility of US performed concomitantly with pulse palpation to be effective in identifying perfusing heart rhythms [21]. While US in this exact context is not yet well studied, it seems of little risk but some benefit to use US to eliminate some of this intrinsic inaccuracy in pulse palpation during CA resuscitation.

### **3.4. US for endotracheal tube (ETT) placement confirmation**

Verification of endotracheal intubation during ACLS can be accomplished with US of the neck. The usual methods of ETT placement verification have limitations when applied during cardiac arrest. Direct visualization is often not reliable especially if the intubation takes place during chest compressions due to the movements of the patient. Colorimetry methods can be misleading in the setting of a previously insufflated stomach, which is the case with the bag valve mask technique ongoing prior to intubation attempts or prior esophageal intubation with insufflation. Continuous waveform capnography remains as a reliable confirmatory method if this equipment is readily available. It can require time to set up and to evaluate the waveform over several breaths, which can be considered a limitation. US can distinguish an intubated trachea from and an intubated esophagus as each has distinct sonographic findings that can be rapidly attained.

Cadaver studies have shown that neck US findings of "double lumen sign" and "tube sliding" artifact can predict endotracheal or esophageal intubation with 100% sensitivity and 100% specificity [65]. The largest meta-analysis of studies with both adult patient and cadaveric models determined that bedside physicians and house staff had a pooled sensitivity and specificity of 93 and 97% [66]. US for ETT placement is especially useful when waveform capnography is not readily available [67] or if a conventional method is misleading, such as colorimetry-verified placement with continued hypoxia. Several authors have shown that US is quicker than conventional methodologies of ETT placement confirmation, demonstrating

an average time to confirmation of 5.8 seconds, significantly faster than capnography at 11.8 seconds [68]. We advocate for enhancing testing characteristics by combining visualization of neck airway structures with lung field pleural sliding and respiratory diaphragmatic motion, which can be performed during pulse check.

### **3.5. US to guide post-ROSC hemodynamic management**

Post-ROSC management includes the immediate initiation of hemodynamic support measures such as fluids, vasopressors, and inotropes. The ability to quickly utilize bedside US to evaluate fluid responsiveness and overall cardiac function can be clinically useful to guide this hemodynamic support.

Goal-directed echocardiography (GDE) is a concept that uses high-fidelity qualitative analysis, without Doppler technology or valvular measurements, to assess targeted cardiac windows in real-time with high sensitivity of identifying marked abnormalities and gross pathophysiology. GDE emphasizes grading LV function as normal, decreased, or very decreased, allowing bedside clinicians to make real-time evaluations upon which to guide management of CA [69]. Current literature supports agreement of GDE interpretations between formal consultant cardiologists and clinician-sonographers at the bedside. One such study demonstrated that, after a brief training course, novice sonographers with hand-held US at the bedside demonstrated 75% agreement with cardiologist in their formal-US study interpretations of LV dysfunction, compared to 83% intra-cardiologist agreement [12]. Thereby, in a CA resuscitation event, when a cardiologist is not always available, a relatively novice-level sonographer is sufficient for diagnostic capability.

Using this concept of GDE, clinician-sonographers can use US to better inform their post-ROSC hemodynamic management including the use of inotropes, pressors, and/or fluid support with the treating clinician acquiring selected TTE views to characterize pre-load and cardiac contractility in the immediately post-arrest period.

## **4. US for prognostication in CA**

An important emerging area of current study in CA US involves using US data in prognostication for survival and neurological outcomes in CA. Despite best efforts during resuscitation, there is continued poor survivorship. The ability to prognosticate the patient's likelihood of achieving ROSC can improve the practitioner's ability to allocate resources and manage expectations of the treating team and patient's caretakers.

The strongest literature supporting prognostic value of US in CA relates to the presence or absence of coordinated cardiac activity as noted by US [11, 48, 70]. Pooled data from over 500 patients showed that the presence of any cardiac kinetics by intra-arrest US had a positive likelihood ratio of 4.26 and negative likelihood ratio of 0.18 to predict ROSC [71]. Another observational study observed the survivorship of nearly 800 non-traumatic CA patients who received US examination as part of their resuscitative efforts upon presentation



to the emergency room and showed presence of any cardiac activity on US was associated with ROSC, survival to admission, and survival to discharge [72].

Further areas of research into US in CA prognostication are looking outside the heart, including measuring optic nerve sheath diameter (ONSD) to predict a positive neurological outcome. ONSD was measured in CA patients 12–72 hours after ROSC and at 28 days after ROSC or discharge from the hospital before 28 days [73]. ONSD of less than or equal to 5.4 mm predicted a favorable neuro-functional prognosis as measures by Glasgow Outcomes Scale with a sensitivity of 83%, specificity of 73%, positive likelihood ratio of 3.1 and negative likelihood ratio of 0.23 [73].

## **5. Bedside CA US is feasible to be implemented today**

The viability of using US during a cardiac arrest depends on the premise that non-radiologist and non- cardiologist physicians can obtain and rapidly interpret imaging data about patient anatomy and physiology with high diagnostic accuracy. Among the significant barriers to its implementation and widespread use are lack of confidence in usage of new technologies and inertia against supplementing traditional methods with new tools for guiding CA management.

In response to the issue of implementation, there is much known about the learning curve for non-radiologist and non-cardiologist practitioners to operate, interpret, and apply this bedside imaging technology. Authors from many different fields including emergency medicine, IM, and anesthesiology have conducted research to address this question of feasibility [74]. Multiple studies have shown that, after short-term (hours-days) educational sessions, novice and expert sonographers can perform without significant differences in sensitivity or specificity in challenging US applications such as ventricular function, volume status or cardiac tamponade [75].

Even at the trainee level, it has been shown that US is a technology which physicians can consistently learn. The Accreditation Council of Graduate Medical Education (ACGME) now requires that critical care ultrasonography be a mandatory component of critical care medicine fellowship training, surgical critical care fellowship training, and emergency medicine residencies [75, 76]. It is well established that this can be done successfully with a mixture of didactics, simulation, and hands on training [75]. In a 3 day critical care US course, 300 novice physicians were shown to proficiently acquire and interpret content from thoracic, vascular, and abdominal ultrasonography [77].

Integrating US techniques into CA management is simply a matter of targeted educational sessions focused on image acquisition, interpretation, and immediate application. After a 1-day training course in CA echocardiography given to novice clinicians of all training levels, the rate of US usage in CA management increased from 4.3 to 19.8% and that echocardiography during the CA event altered management in 70% of cases [78]. Another study found that novice sonographers as a part of an ACLS response team were able to integrate US into their management of cardiac arrest with images obtained and interpreted within an average

of 8 min from CA alert activation and demonstrated strong image interpretation agreement with expert sonographers upon retrospective repeat interpretation [42]. In an analysis of CA events in the ICU where US was used in the setting of PEA or asystole, images of adequate quality were obtained during compressions in 100% of there were changes in management and diagnosis due to US findings in 51% of cases [48]. These data together suggest that US has significant potential to aid in CA resuscitation management and potentially improve patient mortality, morbidity, and outcomes [42, 72, 79, 80].

## 6. Overview of selected current CA US protocols

Implementation of US for CA will be most organized if a standardized approach can be systematically integrated into CA management. There are several example US for CA protocols noted to date, including our institutional protocol (**Table 1**). These protocols focus on rapidly identifying causes of PEA/asystole such as cardiac tamponade, PE, PTX, and hypovolemia. Each protocol is designed to minimally interfere with ACLS. Our institutional protocol

Title or author	Views obtained	# views	During CPR, pulse-checks, or both?	Estimated time of protocol	Notes/uniqueness
Ahmad	Lung, cardiac, Abd/IVC, deep venous, tracheal/ETT	5	Both	Cardiac: 10s Noncardiac: Variable Total: Variable, includes US at pulse checks, compressions, and post-ROSC	Only protocol to include verification of ETT placement.
Niendorff [42]	Cardiac	1	Pulse checks	Cardiac: 10s Noncardiac: N/A Total: 10s	Sonographer ends each exam by voicing "this is a limited screening examination"
C.A.U.S.E. Protocol [41]	Cardiac, lungs	2	Both	Cardiac: <30s Noncardiac: 1 min Total: 1.5 min	Relies on good 4-chamber cardiac views.
P.E.A. Protocol [47]	Lung, cardiac, Abd/IVC, deep veins, bowel, aorta	6	Both	Cardiac: 10s Noncardiac: Variable Total: Variable, US during pulse checks, compressions, and post-ROSC.	The most extensive variety of imaging recommended.
SESAME Protocol [79]	Lung, deep veins, Abd/IVC, cardiac	4	Both	Cardiac: 10–12 s Noncardiac: 40s Total: 50s	Describes addressing most common reversible causes first, includes optimizing depth parameters before imaging.

Abd, abdomen; IVC, inferior vena cava; ETT, endotracheal tube; CPR, cardiopulmonary resuscitation.

**Table 1.** Comparison of currently proposed organized protocols for cardiac arrest ultrasound.

includes the use of neck tracheal US for confirming placement of the ETT. Most protocols were estimated to take less than 1 min to complete and none endorse interruption of chest compressions beyond the standard time limit of a pulse check. One protocol advocates for saving a video loop of a subcostal view of the heart during a 10 s pulse check, allowing for repeat image analysis [42]. Most protocols emphasize knowledge of diagnostic limitations and careful image interpretation. The complexity of the protocols ranges from 1 view (echocardiography only) to 6 views (Table 1).

6.1. Reflections on institutional experience

Our institution is a tertiary care center in New York State, where all inpatient medicine CA resuscitative events are led by senior IM residents, variably with attending. Since early 2014, our institution has incorporated US training into CA management training for these team leaders. In addition, the pulmonary and critical care medicine (PCCM) fellowship program incorporates extensive educational experience in using bedside US in many aspects of critical care, including that for CA. Since the advent of use of this US protocol (Table 1 and Figure 1) for CA, our institution has conducted over 280 CA events and we have implemented use of handheld US devices when a trained clinician can participate. So far, we have received positive feedback from residents regarding the incorporation of ultrasound in CA. Finding a reversible cause has so far been rare. The largest impact has been that the use of US at CA allows code leaders to feel more comfortable stopping resuscitation by ruling out reversible etiologies of CA or findings that represent poor prognosis.

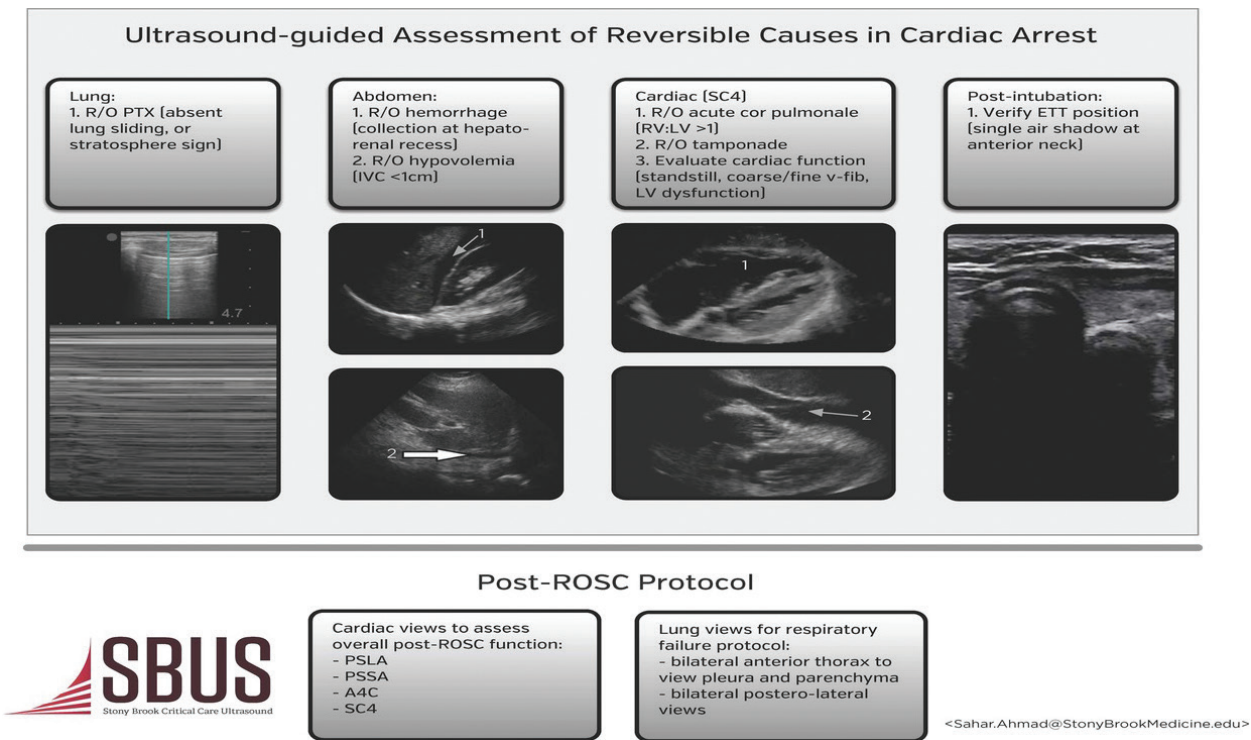


Figure 1. CA US protocol at Stony Brook University medical center critical care ultrasound (SBUS) program.

## 7. Summary and conclusions

Bedside US has significant implications in the setting of guiding cardiac arrest management. In CA resuscitation, clinicians must make rapid, yet informed decisions about patient care in a fast-paced and high pressure environment. In the case of CA characterized by PEA/asystole, US can quickly assess for reversible causes. US can help physicians better interrogate cardiac rhythm or intrinsic cardiac activity, perform more effective chest compressions, reduce error in pulse checks, more rapidly rule out esophageal intubation, provide more tailored post-ROSC hemodynamic support, and provide assistance in prognostication. CA US allows clinicians to offer a higher level of care quality in concordance with, yet beyond, basic ACLS.

Incorporation of US at all CA may improve cost effectiveness and efficiency of hospital resource distribution. Rapid TTE improved the use of health care resources in patients with CA secondary to trauma, where patients who did not received US had a significantly higher mean cost of care, with an average of approximately \$1100 less spent on the US examined group [81]. The prognostic value of US in CA carries an additional resource utilization benefit when considering effects such as ending futile resuscitative efforts earlier and redirecting valuable physician time, hospital personnel resources, as well as medication and equipment costs.

US has become a required part training and accreditation for several medical specialties and it has been consistently shown that physicians can learn US through targeted cumulative educational exposures, even starting at the residency and fellowship levels. It follows that emerging clinicians can be expected to gradually learn to apply these skills to the challenging clinical setting of CA. Most authors advocate for the adoption of a protocolized approach to US in CA as such an approach allows physicians to implement high-yield bedside US in conjunction with ACLS and with minimal interference. Protocolized approaches should include views of the heart to assess cardiac function and for pericardial fluid, IVC for volume status, lung fields to rule out PTX and fluid dependent spaces in the abdomen and pelvis for hemorrhage. Additionally, DVT study and airway confirmation by US may be employed.

Several authors agree that there is a paucity of research to evaluate differences in patient outcomes from US use in CA, therefore true benefits are difficult to assess [82]. Recent survey data identified that there is an existing perception that training in hemodynamic relevant US imaging takes too long, and that only specialized individuals can perform these examinations [83]. However, the literature reviewed here advocate against this criticism. Several authors have shown that time constraints do not prohibit a limited US study and that bedside clinicians can demonstrate success in learning US applications after simple educational interventions. Another barrier is the perception that US devices and sonographers will not be able to join an already crowded space. At our institution, we have found that an US provider, with either a portable or handheld US unit, can easily navigate a resuscitation event without interrupting ACLS. A dedicated sonographer is easily able to adopt to the needs of the resuscitation, change positions and deliver diagnostics to code leaders without interfering with team communications, medication administration, or procedural interventions.

We strongly support the role of US in guiding CA resuscitation management. In light of our and others' experiences reporting US changes management in a majority of CA cases and we suggest that there needs to be support of ongoing research to investigate correlations of US to patient outcomes. US should be part of the standard of care in cardiac resuscitation events as it is currently one of the only means of real time diagnosis of several reversible causes of CA [84].

## Author details

Marc Delaney, Bjorn Flora and Sahar Ahmad\*

\*Address all correspondence to: sahar.ahmad@stonybrookmedicine.edu

Division of Pulmonary and Critical Care Medicine, Stony Brook University Medical Center, Stony Brook, New York, USA

## References

- [1] AHA MFH, Nolan JP. 2010 international consensus on cardiopulmonary resuscitation and emergency cardiovascular care science with treatment recommendations. *Circulation*. 2010;**122**:S249
- [2] Kendall JL, Hoffenberg SR, Smith RS. History of emergency and critical care ultrasound: The evolution of a new imaging paradigm. *Critical Care Medicine*. 2007;**35**:S126-S130
- [3] Price S, Uddin S, Quinn T. Echocardiography in cardiac arrest. *Current Opinion in Critical Care*. 2010;**16**:211-215
- [4] Lumb P. *Critical Care Ultrasound: Expert Consult*. Elsevier Health Sciences. Philadelphia, PA. 2014
- [5] Wallmuller C, Meron G, Kurkciyan I, Schober A, Stratil P, Sterz F. Causes of in-hospital cardiac arrest and influence on outcome. *Resuscitation*. 2012;**83**:1206-1211
- [6] Alrajhi K, Woo MY, Vaillancourt C. Test characteristics of ultrasonography for the detection of pneumothorax: A systematic review and meta-analysis. *CHEST*. 2012;**141**:703-708
- [7] Alrajab S, Youssef AM, Akkus NI, Caldito G. Pleural ultrasonography versus chest radiography for the diagnosis of pneumothorax: Review of the literature and meta-analysis. *Critical Care*. 2013;**17**:1
- [8] Volpicelli G, Boero E, Sverzellati N, Cardinale L, Busso M, Boccuzzi F, Tullio M, Lamorte A, Stefanone V, Ferrari G. Semi-quantification of pneumothorax volume by lung ultrasound. *Intensive Care Medicine*. 2014;**40**:1460-1467



- [9] Azad A, Al Juma S, Bhatti JA, Dankoff J. Validity of ultrasonography to diagnosing pneumothorax: A critical appraisal of two meta-analyses. *CJEM*. 2015;**17**:199-201
- [10] Lucas BP, Candotti C, Margeta B, Mba B, Kumapley R, Asmar A, Franco-Sadud R, Baru J, Acob C, Borkowsky S. Hand-carried echocardiography by hospitalists: A randomized trial. *The American Journal of Medicine*. 2011;**124**:766-774
- [11] Whitson MR, Mayo PH. Ultrasonography in the emergency department. *Critical Care*. 2016;**20**:227
- [12] Alexander JH, Peterson ED, Chen AY, Harding TM, Adams DB, Kisslo JA. Feasibility of point-of-care echocardiography by internal medicine house staff. *American Heart Journal*. 2004;**147**:476-481
- [13] Guntheroth W. Sensitivity and specificity of echocardiographic evidence of tamponade: Implications for ventricular interdependence and pulsus paradoxus. *Pediatric Cardiology*. 2007;**28**:358-362
- [14] Himelman RB, Kircher B, Rockey DC, Schiller NB. Inferior vena cava plethora with blunted respiratory response: A sensitive echocardiography sign of cardiac tamponade. *Journal of the American College of Cardiology*. 1988;**12**:1470-1477
- [15] Rifkin R, Pandian N, Funai J, Wang SS, Sharma S, Lojeski E, Levine H. Sensitivity of right atrial collapse and right ventricular diastolic collapse in the diagnosis of graded cardiac tamponade. *American Journal of Noninvasive Cardiology*. 1987;**1**:73-80
- [16] Kronzon I, Cohen ML, Winer HE. Diastolic atrial compression: A sensitive echocardiographic sign of cardiac tamponade. *Journal of the American College of Cardiology*. 1983;**2**:770-775
- [17] Ceriani E, Cogliati C. Update on bedside ultrasound diagnosis of pericardial effusion. *Internal and Emergency Medicine*. 2016;**11**:477-480
- [18] Weekes AJ, Oh L, Thacker G, Johnson AK, Runyon M, Rose G, Johnson T, Templin M, Norton HJ. Interobserver and intraobserver agreement on qualitative assessments of right ventricular dysfunction with echocardiography in patients with pulmonary embolism. *Journal of Ultrasound in Medicine*. 2016;**35**:2113-2120
- [19] Poth JM, Beck DR, Bartels K. Ultrasonography for haemodynamic monitoring. *Best Practice & Research. Clinical Anaesthesiology*. 2014;**28**:337-351
- [20] Squizzato A, Rancan E, Dentali F, Bonzini M, Guasti L, Steidl L, Mathis G, Ageno W. Diagnostic accuracy of lung ultrasound for pulmonary embolism: A systematic review and meta-analysis. *Journal of Thrombosis and Haemostasis*. 2013;**11**:1269-1278
- [21] Zengin S, Yavuz E, Al B, Cindoruk Ş, Altunbaş G, Gümüşboğa H, Yıldırım C. Benefits of cardiac sonography performed by a non-expert sonographer in patients with non-traumatic cardiopulmonary arrest. *Resuscitation*. 2016;**102**:105-109

- [22] MacCarthy P, Worrall A, McCarthy G, Davies J. The use of transthoracic echocardiography to guide thrombolytic therapy during cardiac arrest due to massive pulmonary embolism. *Emergency Medicine Journal*. 2002;**19**:178-179
- [23] Volpicelli G, Mussa A, Frascisco MF. Sonographic diagnosis of pulmonary embolism with cardiac arrest without major dilation of the right ventricle or direct sign of lower limb venous thrombosis. *Journal of Clinical Ultrasound*. 2012;**40**:529-533
- [24] Lin T, Chen Y, Lu C, Wang M. Use of transoesophageal echocardiography during cardiac arrest in patients undergoing elective non-cardiac surgery. *British Journal of Anaesthesia*. 2006;**96**:167-170
- [25] Comess KA, DeRook FA, Russell ML, Tognazzi-Evans TA, Beach KW. The incidence of pulmonary embolism in unexplained sudden cardiac arrest with pulseless electrical activity\*. *The American Journal of Medicine*. 2000;**109**:351-356
- [26] Bailén MR, Cuadra JÁR, de Hoyos EA. Thrombolysis during cardiopulmonary resuscitation in fulminant pulmonary embolism: A review. *Critical Care Medicine*. 2001;**29**:2211-2219
- [27] Padosch S, Motsch J, Böttiger B. Thrombolysis during cardiopulmonary resuscitation. *Der Anaesthesist*. 2002;**51**:516-532
- [28] Yousuf T, Brinton T, Ahmed K, Iskander J, Woznicka D, Kramer J, Kopiec A, Chadaga AR, Ortiz K. Tissue plasminogen activator use in cardiac arrest secondary to fulminant pulmonary embolism. *Journal of Clinical Medicine Research*. 2016;**8**:190
- [29] Kürkciyan I, Meron G, Sterz F, Janata K, Domanovits H, Holzer M, Berzlanovich A, Bankl HC, Laggner AN. Pulmonary embolism as cause of cardiac arrest: Presentation and outcome. *Archives of Internal Medicine*. 2000;**160**:1529-1535
- [30] Bottiger BW, Arntz H-R, Chamberlain DA, Bluhmki E, Belmans A, Danays T, Carli PA, Adgey JA, Bode C, Wenzel V. Thrombolysis during resuscitation for out-of-hospital cardiac arrest. *The New England Journal of Medicine*. 2008;**359**:2651
- [31] Pomero F, Dentali F, Borretta V, Bonzini M, Melchio R, Douketis JD, Fenoglio LM. Accuracy of emergency physician-performed ultrasonography in the diagnosis of deep-vein thrombosis. *Thrombosis and Haemostasis*. 2013;**109**:137-145
- [32] Kory PD, Pellecchia CM, Shiloh AL, Mayo PH, DiBello C, Koenig S. Accuracy of ultrasonography performed by critical care physicians for the diagnosis of DVT. *CHEST*. 2011;**139**:538-542
- [33] Da Costa Rodrigues J, Alzuphar S, Combescure C, Le Gal G, Perrier A. Diagnostic characteristics of lower limb venous compression ultrasonography in suspected pulmonary embolism: A meta-analysis. *Journal of Thrombosis and Haemostasis*. 2016;**14**:1765-1772
- [34] Harris T, Meek S. When should we thrombolyse patients with pulmonary embolism? A systematic review of the literature. *Emergency Medicine Journal*. 2005;**22**:766-771
- [35] T Arntfield R, J Millington S. Point of care cardiac ultrasound applications in the emergency department and intensive care unit—A review. *Current Cardiology Reviews*. 2012;**8**:98-108

- [36] Boyd JH, Sirounis D, Maizel J, Slama M. Echocardiography as a guide for fluid management. *Critical Care*. 2016;**20**:274
- [37] Kircher BJ, Himelman RB, Schiller NB. Noninvasive estimation of right atrial pressure from the inspiratory collapse of the inferior vena cava. *The American Journal of Cardiology*. 1990;**66**:493-496
- [38] Cheriex E, Leunissen K, Janssen J, Mooy J, Van Hooff J. Echography of the inferior vena cava is a simple and reliable tool for estimation of 'dry weight' in haemodialysis patients. *Nephrology, Dialysis, Transplantation*. 1989;**4**:563-568
- [39] Zhang Z, Xu X, Ye S, Xu L. Ultrasonographic measurement of the respiratory variation in the inferior vena cava diameter is predictive of fluid responsiveness in critically ill patients: Systematic review and meta-analysis. *Ultrasound in Medicine & Biology*. 2014;**40**:845-853
- [40] Barbier C, Loubieres Y, Schmit C, Hayon J, Ricome J-L, Jardin F, Vieillard-Baron A. Respiratory changes in inferior vena cava diameter are helpful in predicting fluid responsiveness in ventilated septic patients. *Intensive Care Medicine*. 2004;**30**(9):1740-1746
- [41] Hernandez C, Shuler K, Hannan H, Sonyika C, Likourezos A, Marshall J. C.A.U.S.E.: Cardiac arrest ultra-sound exam—A better approach to managing patients in primary non-arrhythmogenic cardiac arrest. *Resuscitation*. 2008;**76**:198-206
- [42] Niendorff DF, Rassias AJ, Palac R, Beach ML, Costa S, Greenberg M. Rapid cardiac ultrasound of inpatients suffering pea arrest performed by nonexpert sonographers. *Resuscitation*. 2005;**67**:81-87
- [43] Dammers D, El Moumni M, Hoogland I, Veeger N, ter Avest E. Should we perform a fast exam in haemodynamically stable patients presenting after blunt abdominal injury: A retrospective cohort study. *Scandinavian Journal of Trauma, Resuscitation and Emergency Medicine*. 2017;**25**:1
- [44] Dolich MO, McKenney MG, Varela JE, Compton RP, McKenney KL, Cohn SM. 2,576 ultrasounds for blunt abdominal trauma. *Journal of Trauma and Acute Care Surgery*. 2001;**50**:108-112
- [45] Tso P, Rodriguez A, Cooper C, Militello P, Mirvis S, Badellino MM, Boulanger BR, Foss FA Jr, Hinson DM, Mighty HE. Sonography in blunt abdominal trauma: A preliminary progress report. *Journal of Trauma and Acute Care Surgery*. 1992;**33**:39-44
- [46] Kumar S, Bansal VK, Muduly DK, Sharma P, Misra MC, Chumber S, Singh S, Bhardwaj D. Accuracy of focused assessment with sonography for trauma (fast) in blunt trauma abdomen—A prospective study. *The Indian Journal of Surgery*. 2015;**77**:393-397
- [47] Testa A, Cibinel G, Portale G, Forte P, Giannuzzi R, Pignataro G, Silveri NG. The proposal of an integrated ultrasonographic approach into the als algorithm for cardiac arrest: The pea protocol. *European Review for Medical and Pharmacological Sciences*. 2010;**14**:77-88
- [48] Flato UAP, Paiva EF, Carballo MT, Buehler AM, Marco R, Timerman A. Echocardiography for prognostication during the resuscitation of intensive care unit patients with non-shockable rhythm cardiac arrest. *Resuscitation*. 2015;**92**:1-6

- [49] Paradis NA, Martin GB, Goetting MG, Rivers EP, Feingold M, Nowak RM. Aortic pressure during human cardiac arrest. Identification of pseudo-electromechanical dissociation. *CHEST*. 1992;**101**:123-128
- [50] Salen P, Melniker L, Chooljian C, Rose JS, Alteveer J, Reed J, Heller M. Does the presence or absence of sonographically identified cardiac activity predict resuscitation outcomes of cardiac arrest patients? *The American Journal of Emergency Medicine*. 2005;**23**:459-462
- [51] Bouferrache K, Amiel J-B, Chimot L, Caille V, Charron C, Vignon P, Vieillard-Baron A. Initial resuscitation guided by the surviving sepsis campaign recommendations and early echocardiographic assessment of hemodynamics in intensive care unit septic patients: A pilot study. *Critical Care Medicine*. 2012;**40**:2821-2827
- [52] Vieillard-Baron A, Prin S, Chergui K, Dubourg O, Jardin F. Hemodynamic instability in sepsis: Bedside assessment by doppler echocardiography. *American Journal of Respiratory and Critical Care Medicine*. 2003;**168**:1270-1276
- [53] Limb C, Siddiqui MA. Apparent asystole: Are we missing a lifesaving opportunity? *BMJ Case Reports*. 2015;**2015**:bcr2014208364
- [54] Amaya SC, Langsam A. Ultrasound detection of ventricular fibrillation disguised as asystole. *Annals of Emergency Medicine*. 1999;**33**:344-346
- [55] Querellou E, Meyran D, Petitjean F, Le Dreff P, Maurin O. Ventricular fibrillation diagnosed with trans-thoracic echocardiography. *Resuscitation*. 2009;**80**:1211-1213
- [56] Ramarapu S. Complete neurological recovery after transesophageal echocardiography-guided diagnosis and management of prolonged cardiopulmonary resuscitation. *A&A Case Reports*. 2015;**5**:192-194
- [57] Georgiou M, Papathanassoglou E, Xanthos T. Systematic review of the mechanisms driving effective blood flow during adult cpr. *Resuscitation*. 2014;**85**:1586-1593
- [58] Shin J, Rhee JE, Kim K. Is the inter-nipple line the correct hand position for effective chest compression in adult cardiopulmonary resuscitation? *Resuscitation*. 2007;**75**:305-310
- [59] Qvigstad E, Kramer-Johansen J, Tømte Ø, Skålhegg T, Sørensen Ø, Sunde K, Olasveengen TM. Clinical pilot study of different hand positions during manual chest compressions monitored with capnography. *Resuscitation*. 2013;**84**:1203-1207
- [60] Hwang SO, Zhao PG, Choi HJ, Park KH, Cha KC, Park SM, Kim SC, Kim H, Lee KH. Compression of the left ventricular outflow tract during cardiopulmonary resuscitation. *Academic Emergency Medicine*. 2009;**16**:928-933
- [61] Anderson KL, Castaneda MG, Boudreau SM, Sharon DJ, Bebart VS. Left ventricular compressions improve hemodynamics in a swine model of out-of-hospital cardiac arrest. *Prehospital Emergency Care*. 2016;**2**:272-280
- [62] Schonberger RB, Lampert RJ, Mandel EI, Feinleib J, Gong Z, Honiden S. Handheld doppler to improve pulse checks during resuscitation of putative pulseless electrical activity arrest. *The Journal of the American Society of Anesthesiologists*. 2014;**120**:1042-1045



- [63] Dick WF, Eberle B, Wisser G, Schneider T. The carotid pulse check revisited: What if there is no pulse? *Critical Care Medicine*. 2000;**28**:N183-N185
- [64] Eberle B, Dick W, Schneider T, Wisser G, Doetsch S, Tzanova I. Checking the carotid pulse check: Diagnostic accuracy of first responders in patients with and without a pulse. *Resuscitation*. 1996;**33**:107-116
- [65] Gottlieb M, Bailitz JM, Christian E, Russell FM, Ehrman RR, Khishfe B, Kogan A, Ross C. Accuracy of a novel ultrasound technique for confirmation of endotracheal intubation by expert and novice emergency physicians. *The Western Journal of Emergency Medicine*. 2014;**15**:834
- [66] Chou EH, Dickman E, Tsou P-Y, Tessaro M, Tsai Y-M, Ma MH-M, Lee C-C, Marshall J. Ultrasonography for confirmation of endotracheal tube placement: A systematic review and meta-analysis. *Resuscitation*. 2015;**90**:97-103
- [67] Das SK, Choupoo NS, Haldar R, Lahkar A. Transtracheal ultrasound for verification of endotracheal tube placement: A systematic review and meta-analysis. *Canadian Journal of Anesthesia/Journal canadien d'anesthésie*. 2015;**62**:413-423
- [68] Karacabey S, Sanrı E, Gencer EG, Guneyssel O. Tracheal ultrasonography and ultrasonographic lung sliding for confirming endotracheal tube placement: Speed and reliability. *The American Journal of Emergency Medicine*. 2016;**34**:953-956
- [69] Walley PE, Walley KR, Goodgame B, Punjabi V, Sirounis D. A practical approach to goal-directed echocardiography in the critical care setting. *Critical Care*. 2014;**18**:1
- [70] Blaivas M, Fox JC. Outcome in cardiac arrest patients found to have cardiac standstill on the bedside emergency department echocardiogram. *Academic Emergency Medicine*. 2001;**8**:616-621
- [71] Blyth L, Atkinson P, Gadd K, Lang E. Bedside focused echocardiography as predictor of survival in cardiac arrest patients: A systematic review. *Academic Emergency Medicine*. 2012;**19**:1119-1126
- [72] Gaspari R, Weekes A, Adhikari S, Noble VE, Nomura JT, Theodoro D, Woo M, Atkinson P, Blehar D, Brown SM. Emergency department point-of-care ultrasound in out-of-hospital and in-ed cardiac arrest. *Resuscitation*. 2016;**109**:33-39
- [73] Ueda T, Ishida E, Kojima Y, Yoshikawa S, Yonemoto H. Sonographic optic nerve sheath diameter: A simple and rapid tool to assess the neurologic prognosis after cardiac arrest. *Journal of Neuroimaging*. 2015;**25**:927-930
- [74] Alsaddique A, Royse AG, Royse CF, Mobeirek A, El Shaer F, AlBackr H, Fouda M, Canty DJ. Repeated monitoring with transthoracic echocardiography and lung ultrasound after cardiac surgery: Feasibility and impact on diagnosis. *Journal of Cardiothoracic and Vascular Anesthesia*. 2016;**30**:406-412
- [75] Vignon P, Dugard A, Abraham J, Belcour D, Gondran G, Pepino F, Marin B, François B, Gastinne H. Focused training for goal-oriented hand-held echocardiography performed by noncardiologist residents in the intensive care unit. *Intensive Care Medicine*. 2007;**33**:1795-1799



- [76] Greenstein YY, Martin TJ, Rolnitzky L, Felner K, Kaufman B. Goal-directed transthoracic echocardiography during advanced cardiac life support: A pilot study using simulation to assess ability. *Simulation in Healthcare*. 2015;**10**:193-201
- [77] Greenstein YY, Littauer R, Narasimhan M, Mayo PH, Koenig SJ. Effectiveness of a critical care ultrasonography course. *CHEST*. 2017;**151**(1): 34-40
- [78] Preston HM, Collins AS, Reed MJ, Connolly J. A description of echocardiography in life support use during cardiac arrest in an emergency department before and after a training programme. *European Journal of Emergency Medicine*. 2015;**22**:426-429
- [79] Lichtenstein DA. How can the use of lung ultrasound in cardiac arrest make ultrasound a holistic discipline. The example of the sesame-protocol. *Medical Ultrasonography*. 2014;**16**:252
- [80] Salen P, O Connor R, Sierzenski P, Passarello B, Pancu D, Melanson S, Arcona S, Reed J, Heller M. Can cardiac sonography and capnography be used independently and in combination to predict resuscitation outcomes? *Academic Emergency Medicine*. 2001;**8**:610-615
- [81] Ferrada P, Wolfe L, Anand RJ, Whelan J, Vanguri P, Malhotra A, Goldberg S, Duane T, Aboutanos M. Use of limited transthoracic echocardiography in patients with traumatic cardiac arrest decreases the rate of nontherapeutic thoracotomy and hospital costs. *Journal of Ultrasound in Medicine*. 2014;**33**:1829-1832
- [82] Royse CF, Canty DJ, Faris J, Haji DL, Veltman M, Royse A. Core Review: Physician-performed ultrasound: The time has come for routine use in acute care medicine. *Anesthesia and Analgesia*. 2012;**115**:1007-1028
- [83] Eisen LA, Leung S, Gallagher AE, Kvetan V. Barriers to ultrasound training in critical care medicine fellowships: A survey of program directors. *Critical Care Medicine*. 2010;**38**:1978-1983
- [84] Breitzkreutz R, Price S, Steiger HV, Seeger FH, Ilper H, Ackermann H, Rudolph M, Uddin S, Weigand MA, Müller E. Focused echocardiographic evaluation in life support and peri-resuscitation of emergency patients: A prospective trial. *Resuscitation*. 2010;**81**:1527-1533