

We are IntechOpen, the world's leading publisher of Open Access books Built by scientists, for scientists

6,900

Open access books available

186,000

International authors and editors

200M

Downloads

Our authors are among the

154

Countries delivered to

TOP 1%

most cited scientists

12.2%

Contributors from top 500 universities



WEB OF SCIENCE™

Selection of our books indexed in the Book Citation Index
in Web of Science™ Core Collection (BKCI)

Interested in publishing with us?
Contact book.department@intechopen.com

Numbers displayed above are based on latest data collected.
For more information visit www.intechopen.com



Evaluation of the Anatomy of the Lower First Premolar

Ticiana Sidorenko de Oliveira Capote,
Suellen Tayenne Pedroso Pinto,
Marcelo Brito Conte,
Juliana Álvares Duarte Bonini Campos and
Marcela de Almeida Gonçalves

Additional information is available at the end of the chapter

<http://dx.doi.org/10.5772/intechopen.71038>

Abstract

This chapter provides information about the lower first premolars. This tooth is considered to be one of the most complex teeth and the dentistry graduation students usually have difficulties in identifying it. The aim of this chapter is to present a detailed morphological study of extracted lower first premolars. One hundred lower first premolars, belonging to the collection of the Laboratory of Anatomy of the Department of Morphology of the São Paulo State University (UNESP), School of Dentistry, Araraquara, SP, Brazil, were evaluated. Nine measurements were performed through direct observation without any instruments. Other 20 measurements were made by photographs and they were analyzed by the Image Tool 3.0 program. According to the results, it was concluded that most of the teeth presented the following features such as one lingual cusp; the distal occlusal pits were wider than the mesial occlusal pits; an enamel bridge linking the buccal and lingual cusps; the grooves in the lingual surface that emerged from the mesial and distal occlusal pits were absent, and where the grooves were present, they emerged from the mesial occlusal pit; one rectilinear root with no root grooves and where the root groove was present, it was observed in the mesial surface.

Keywords: dental anatomy, lower first premolar, morphometric, tooth morphology, teeth

1. Introduction

The lower first premolar is considered to be one of the most complex teeth. During the practical classes of Dental Anatomy, we can see some students with difficulties in the identification of the first premolars. Probably this is due to the wide anatomic variations present in those teeth.

There are few studies in which researchers performed standardized measures and provided more detailed information about the lower first premolars.

The lower first premolar is the smallest of all premolars. It has a very characteristic crown that differs from the other teeth, mainly due to its buccal cusp, which is disproportionately larger than the lingual cusp. The buccal surface of the crown is strongly inclined toward the lingual side and the buccal cusp is about two times larger than the lingual cusp [1].

Being smaller than the buccal cusp, the lingual cusp may be so small to become a single tubercle. Between the two cusps, buccal and lingual, there is a principal groove, whose concavity is directed toward the buccal surface [1, 2].

An enamel bridge may also be present linking the buccal and lingual cusps [3], which separates the principal groove in two pits, the mesial occlusal pit (MOP) and the distal occlusal pit (DOP) [4]. According to Madeira and Rizzolo [5], the distal occlusal pit is the largest, and between both occlusal pits (mesial and distal), the distal one is the closest to the lingual surface.

Usually, the tooth has only one root [1, 4]. The mesial and distal longitudinal grooves of the root are shallow and the root apex is rarely divided [4].

The aim of this chapter is to present a detailed morphological study of extracted lower first premolars.

2. Methodology

This project was approved by the Ethics Committee of the School of Dentistry of Araraquara, São Paulo State University (UNESP) (CAAE 17513313.6.0000.5416).

One hundred lower first premolars with no information about gender and age were evaluated, and they belong to the collection of the Laboratory of Anatomy of the Department of Morphology of the São Paulo State University (UNESP), School of Dentistry, Araraquara. The teeth were cleaned with dental instruments and solutions of hydrogen peroxide and ammonium hydroxide. The teeth were stored dry, without any solutions, in glass containers. Those teeth are routinely used in the dental anatomy classes.

For identifying the proximal surfaces, a previous study was done to determine the criteria of their identification.

Nine measurements were performed through direct observation without any instruments:

- Mesial occlusal pit (MOP): 1 = discreet, 2 = small, 3 = medium, 4 = large (**Figure 1**).
- Distal occlusal pit (DOP): 1 = discreet, 2 = small, 3 = medium, 4 = large (**Figure 1**).
- Presence/absence of groove in the lingual surface that emerged from the mesial occlusal pit (G-MOP).
- Presence/absence of groove in the lingual surface that emerged from the distal occlusal pit (G-DOP).

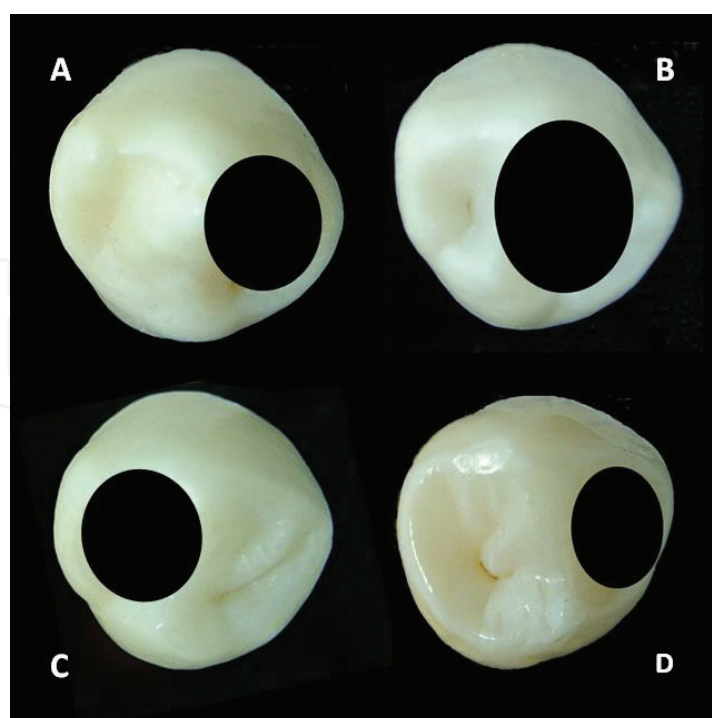


Figure 1. Classification of occlusal pits. (A) Discreet occlusal pit; (B) small occlusal pit; (C) medium occlusal pit and (D) large occlusal pit.

- Number of lingual cusps (LC).
- Number of dental roots (DR).
- Region of root bifurcation or trifurcation: 0 = absent, 1 = cervical third, 2 = middle third, 3 = apical third.
- Presence/absence of root grooves in the mesial surface (MG-R).
- Presence/absence of root grooves in the distal surface (DG-R).

Other measures were made by photographs and they were analyzed by the Image Tool 3.0 program, which allowed the measurements of dimension, angle and area.

Prior to the photographs, some points were registered in the teeth to facilitate some measurements through the use of the Image Tool program such as signaling of the distal surface, apex of the cusps, limits of the mesial and distal longitudinal edges of all cusps, point of largest dimension of the mesial and distal marginal ridges, contour of the mesial and distal longitudinal edge of the buccal cusp and contour of the cervical line (**Figures 3, 6 and 7**).

The teeth were photographed on the occlusal, buccal, lingual, mesial and distal surfaces. For standardization of the photographs, a digital camera (FujiFilm FinePix S7000) was positioned on a stand. In each photograph, a ruler was photographed for calibration of the images and the measurements were made using the Image Tool 3.0 program. The calibration was made in millimeters. For the occlusal photographs, the teeth were fixed in a device elaborated by

Prof. Dr. Hélio Ferraz Porciúncula, a retired adjunct professor of Anatomy of the School of Dentistry of Araraquara, São Paulo State University (UNESP) (**Figure 2**).

Photograph of occlusal surface (Figure 3):

- Measurement of the mesial longitudinal edge of the buccal cusp (MLE-BC).
- Measurement of the distal longitudinal edge of the buccal cusp (DLE-BC).



Figure 2. Metallic device where the teeth were fixed for occlusal photographs.

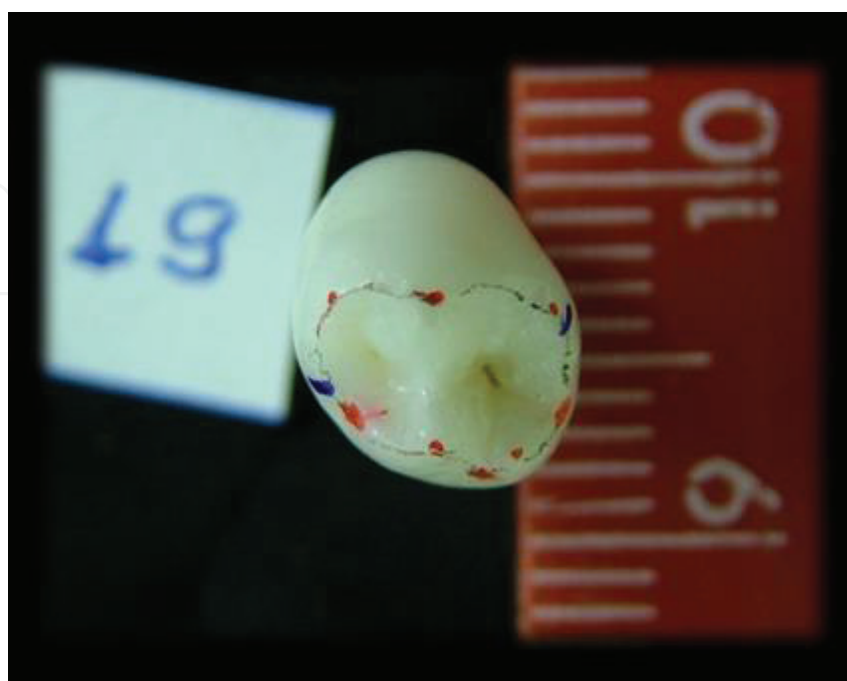


Figure 3. Occlusal surface photograph.

- Measurement of the mesial longitudinal edge of the lingual cusp (MLE-LC): presence of only a lingual cusp located in the middle third (MLE-LC0), presence of a lingual cusp located in the mesial third (MLE-LC1) and presence of a lingual cusp located in the distal third (MLE-LC2).
- Measurement of the distal longitudinal edge of the lingual cusp (DLE-LC): presence of only a lingual cusp located in the middle third (DLE-LC0), presence of a lingual cusp located in the mesial third (DLE-LC1) and presence of a lingual cusp located in the distal third (DLE-LC2).
- Measurement of the buccolingual dimension of the occlusal surface (BL-O): measurement between the buccal and lingual surfaces made from the buccal cusp apex to the lingual cusp apex.
- Measurement of the mesiodistal dimension of the occlusal surface (MD-O): measurement between the mesial and distal marginal ridges on the occlusal surface in the region of greatest dimension.
- Measurement of the buccolingual dimension of the mesial marginal ridge (BL-MMR).
- Measurement of the buccolingual dimension of the distal marginal ridge (BL-DMR).
- Measurement of the mesiodistal dimension of the enamel bridge (M-PE): when it was present, a mesiodistal measurement was performed between the two surfaces that limit the enamel bridge and coincide with the margin of the occlusal pits.
- Position of the enamel bridge: absent, mesial, middle and distal position (P-PE).
- Presence/absence of the mesiodistal groove crossing the enamel bridge (G-PE).
- Measurement of the distance from the mesial occlusal pit to the buccal surface (MOP-MLE): a measurement made from the center of the mesial occlusal pit to the mesial longitudinal edge.
- Measurement of the distance from the distal occlusal pit to the buccal surface (DOP-DLE): a measurement made from the center of the distal occlusal pit to the distal longitudinal edge.

Photograph of buccal surface (Figure 4):

- Measurement of the cervical-occlusal dimension of the crown (CO-BS): measurement of the buccal cusp apex to the most cervical region of the cervical line, made on the buccal surface.
- Measurement of the root length (RL): measurement of the most cervical region of the cervical line up to the root apex, made on the buccal surface.
- Measurement of the mesiodistal dimension of the root (MD-R): measurement made between the mesial and distal root surfaces in the dental cervix, made on the buccal surface.
- Measurement of the deviation of the root apex from the long axis of the crown (DRA): measurement of the angle formed between the long axis of the tooth and the root apex.

Photograph of lingual surface (Figure 5):

- Measurement of the cervical-occlusal dimension of the lingual surface (CO-LS): measurement from the apex of the highest lingual cusp to the most cervical region of the cervical line, made on the lingual surface.

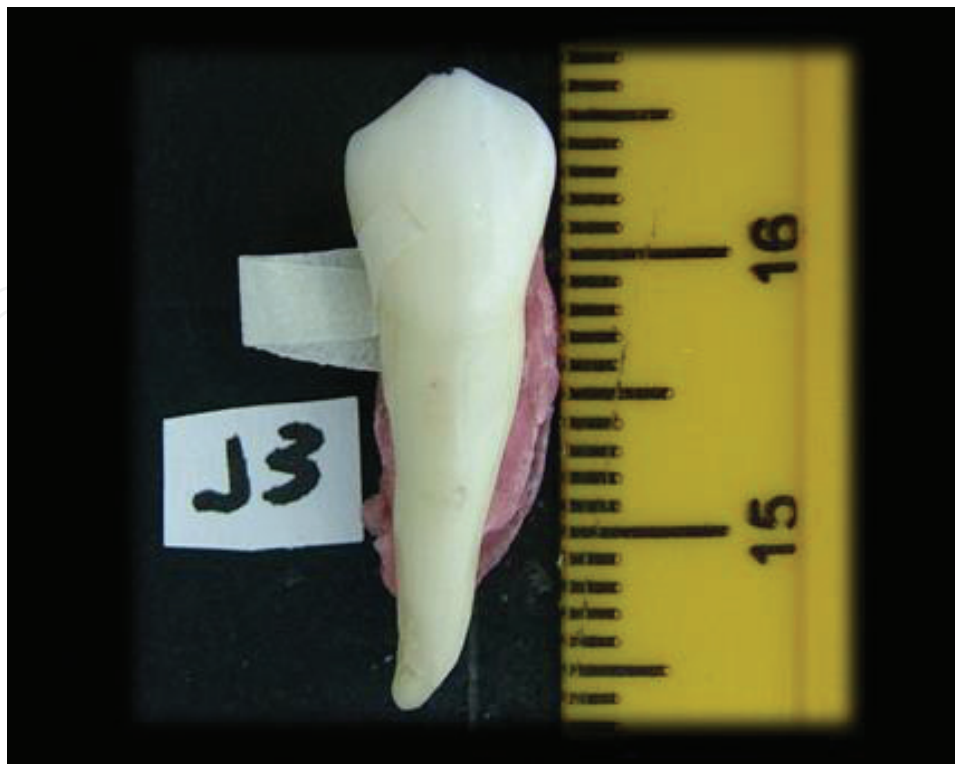

Figure 4. Buccal surface photograph.

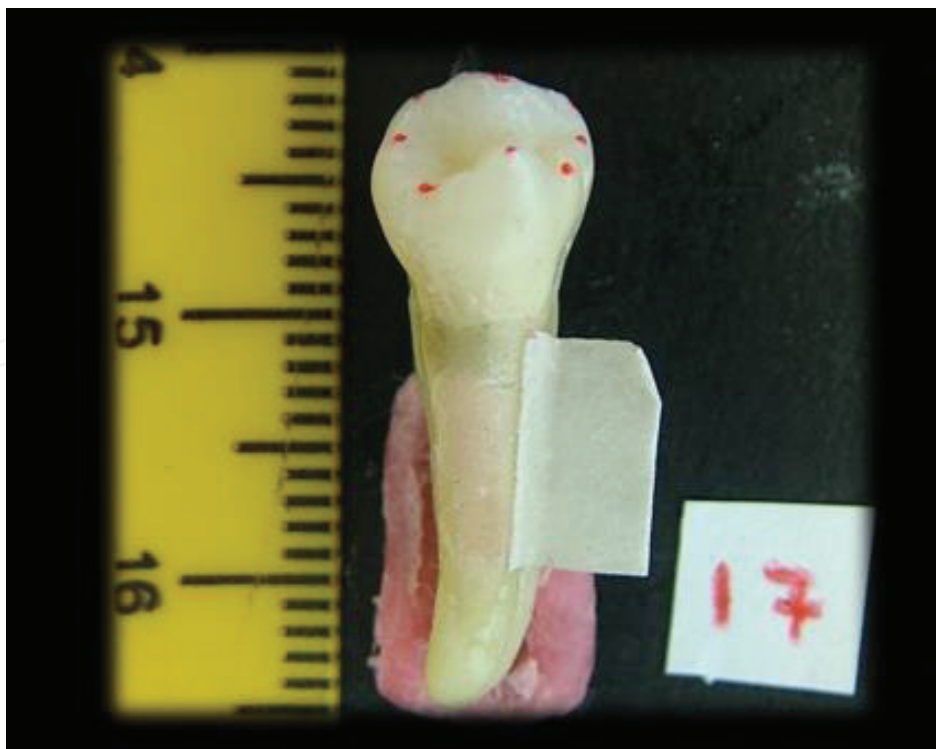

Figure 5. Lingual surface photograph.

Photograph of mesial surface (Figure 6):

- Measurement of the cervical-occlusal dimension of the mesial surface (CO-MS): measurement from the cervical line of the crown in the middle third to the mesial marginal ridge.
- Measurement of the buccolingual dimension of the root (BL-R): measurement between the buccal and lingual surfaces of the root in the dental cervix, made on the mesial surface.

Photograph of distal surface (Figure 7):

- Measurement of the cervical-occlusal dimension of the distal surface (CO-DS): measurement from the cervical line of the crown in the middle third to the distal marginal ridge.

The measurement of total tooth length (TL) will be obtained by adding the cervical-occlusal dimension of the crown (CO-C) to the root length measurement (RL).

2.1. Statistical analysis

The analyses were made by a qualified examiner. For reproducibility analysis, the teeth were analyzed in duplicate, with an interval of at least 7 days between the analyses. From the 100 teeth, which constituted the sample, 30 teeth were randomly selected. The reproducibility was estimated using intraclass correlation coefficient (ICC).

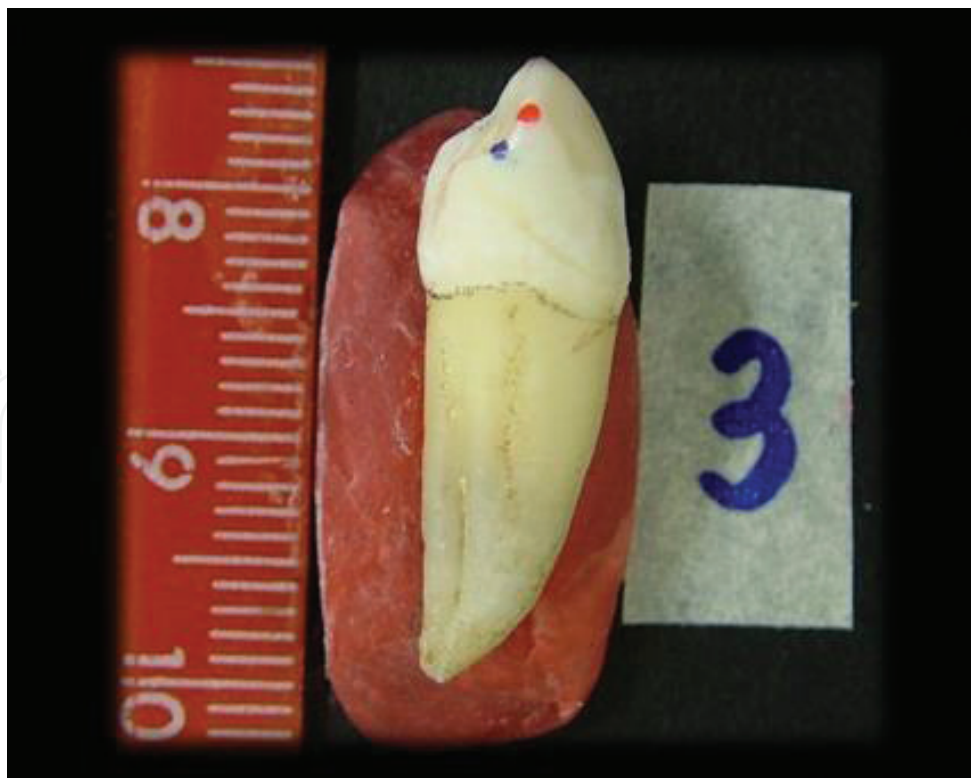

Figure 6. Mesial surface photograph.

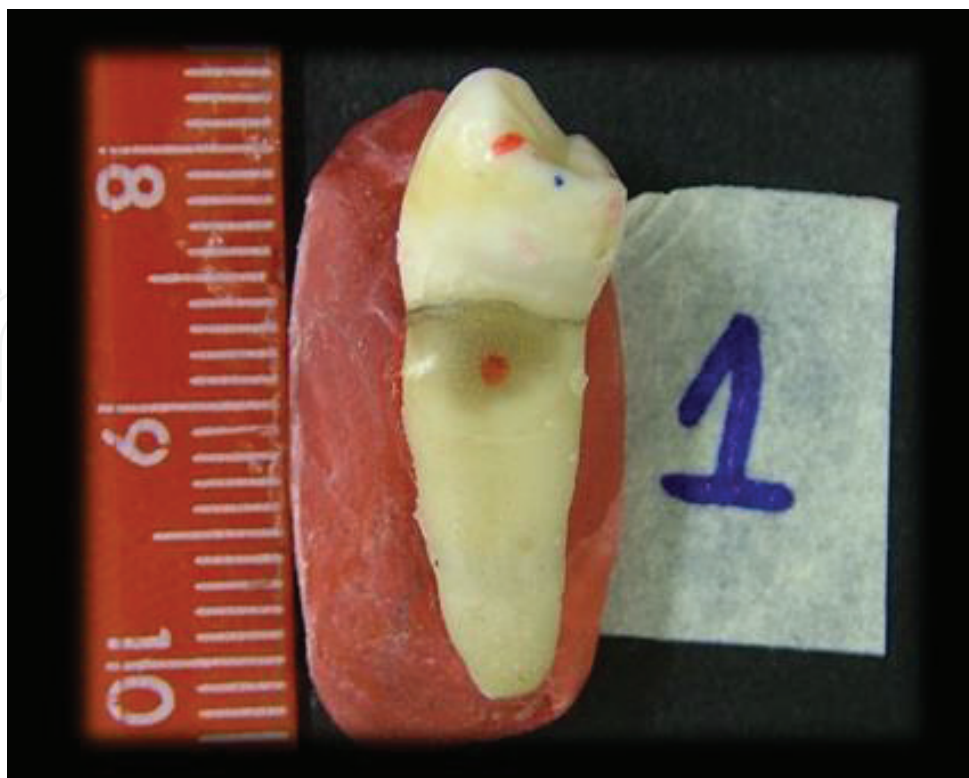

Figure 7. Distal surface photograph.

From the two evaluations (initial and after the interval) performed to obtain the reproducibility, the measurements obtained from the initial evaluation were considered to compose the sample, since the other teeth were evaluated only once.

Descriptive statistics was performed.

The comparisons of interest were estimated using Kruskal-Wallis and Dunn's tests. An association study between mesial occlusal pits (MOP) and distal occlusal pits (DOP) was performed using Fisher's exact test. The level of significance was 5%.

3. Results

Table 1 shows intraexaminer reproducibility performed in two different times. From the seven evaluated parameters, six presented "excellent" agreement and one presented "satisfactory" agreement (intraclass correlation coefficient, ICC).

Tables 2–7 present the frequencies of the anatomical features evaluated through direct observation of the teeth.

From the first 100 evaluated lower first premolars, 97% were uniradicular and only three teeth (3%) presented a apical third bifurcation.

Anatomical features	ICC	P
MOP-MLE	0.647	<0.001
BL-DMR	0.953	<0.001
MLE-BC	0.799	<0.001
BL-O	0.886	<0.001
MD-O	0.876	<0.001
CO-C	0.958	<0.001
MD-R	0.821	<0.001

Table 1. Reproducibility of measurements performed by one examiner in two different times.

	Frequency	%
MOP		
Discreet	20	20
Small	63	63
Medium	15	15
Large	2	2
DOP		
Discreet	6	6
Small	24	24
Medium	43	43
Large	27	27
Total	100	100

Table 2. Distribution of mesial and distal occlusal pits (MOP and DOP).

	Frequency	%
G-MOP		
Absent	58	58
Present	42	42
G-DOP		
Absent	70	70
Present	30	30
Total	100	100

Table 3. Frequency of the grooves in the lingual surface that emerged from mesial and distal occlusal pits (G-MOP and G-DOP).

Number of lingual cusps	Frequency	%
1	78	78
2	19	19
3	3	3
Total	100	100

Table 4. Frequency of the number of lingual cusps.

	Frequency	%
MG-R		
Absent	61	61
Present	39	39
DG-R		
Absent	92	92
Present	8	8
Total	100	100

Table 5. Frequency of grooves in the mesial and distal root surfaces (MG-R and DG-R).

Enamel bridge position	Frequency	%
Absent	6	6
Mesial	47	47
Middle	45	45
Distal	2	2
Total	100	100

Table 6. Frequency of the enamel bridge position.

Mesiodistal groove crossing the enamel bridge	Frequency	%
Absent	50	50
Present	50	50
Total	100	100

Table 7. Frequency of the mesiodistal groove crossing the enamel bridge.

Table 8 shows the frequency of the measurements made through the photographs and the use of the Image Tool 3.0 program.

Regarding the number of lingual cusps, 78 teeth presented only one cusp. From those, 25 teeth showed the lingual cusp positioned in the mesial third, 37 teeth showed that it is positioned

in the middle third and 16 teeth showed that it is positioned in the distal third. Nineteen teeth presented two cusps and only three teeth presented three lingual cusps.

From the 100 lower first premolars, 70 presented a rectilinear root, without any angulation of the root apex. Thirty teeth (30%) presented deviation of the root apex or the apical third, varying from 16.67 to 172.47°, with a mean of 153.16°, being 26 with a distal deviation and 4 presenting a mesial deviation of the apical third (**Figure 8**).

Only two teeth presented MOP with score 4 (large), which were not considered for the statistical analysis.

Anatomical feature	n	Mean	Standard deviation
MLE-BC	100	3.75	0.557
DLE-BC	100	3.81	0.563
MLE-LC0	40	0.90	1.185
DLE-LC0	40	1.00	1.326
MLE-LC1	47	1.04	1.230
DLE-LC1	47	1.10	1.337
MLE-LC2	37	0.71	1.081
DLE-LC2	37	0.63	0.899
BL-O	100	4.81	0.940
MD-O	100	7.08	0.761
BL-MMR	100	3.29	0.957
BL-DMR	100	3.76	0.854
M-PE	100	3.09	1.026
MOP-MLE	100	1.89	0.424
DOP-DLE	100	2.12	0.433
CO-BS	100	8.34	0.901
CO-LS	100	5.59	0.842
CO-MS	100	5.33	0.682
CO-DS	100	5.21	0.608
RL	100	14.43	1.971
BL-R	100	7.21	0.701
MD-R	100	5.36	0.578
TL	100	22.85	1.888
DRA	30	153.16	29.692

Table 8. Frequency of the measurements obtained by the use of photographs and the Image Tool program.

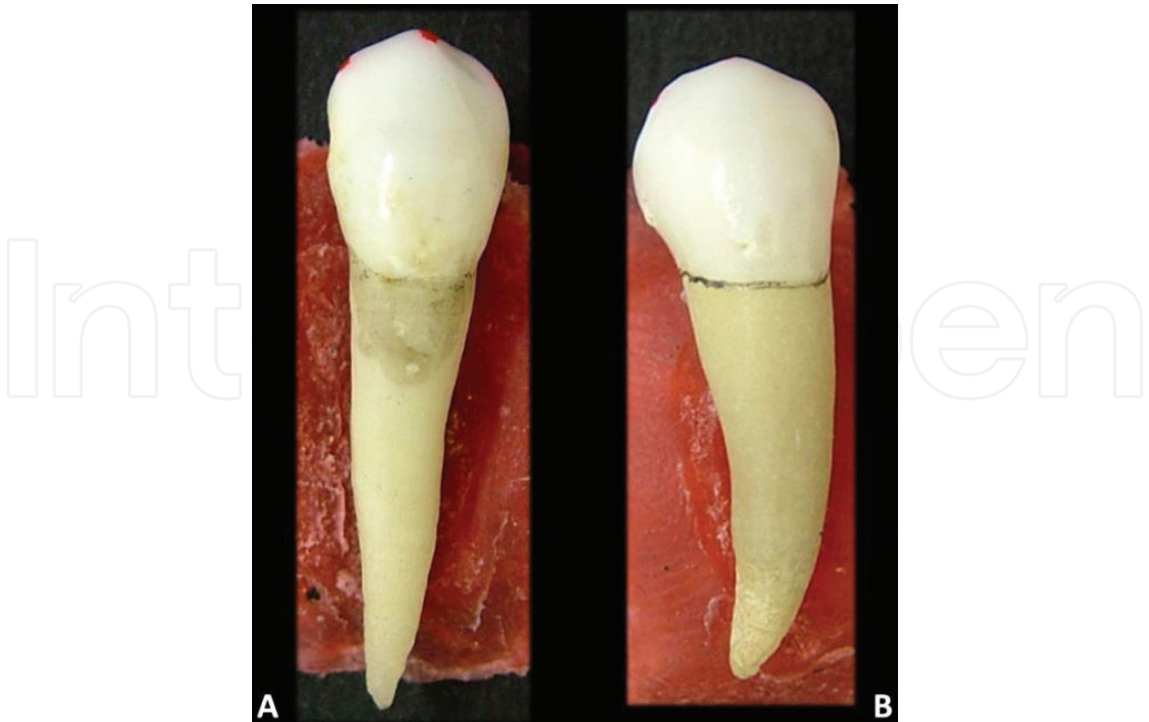


Figure 8. Lower first premolars with a rectilinear root (A) and with a distal deviation (B).

The relation between MOP and MOP-MLE was analyzed. It was verified that the dimension of MOP-MLE was statistically related to the size of MOP ($p = 0.037$; Kruskal-Wallis followed by Dunn’s test), that is, the higher the MOP, the higher the MOP-MLE was.

Statistical analysis showed that there was no statistically significant relation between DOP and DOP-DLE ($p = 0.486$; Kruskal-Wallis), as well as there was no significant relation between BL-MMR and MOP ($p = 0.769$); BL-DMR and DOP ($p = 0.07$); MOP-MLE and DOP-DLE ($p = 0.075$); BL-MMR and BL-DMR ($p = 0.947$).

According to **Table 9**, there was a significant association between MOP and DOP ($p = 0.007$; Fisher’s exact). It may be noted that the distal occlusal pits were usually higher when compared to the mesial occlusal pits.

DOP						
MOP	1	2	3	4	Total	p
1	5	3	8	5	20	0.007
2	1	20	27	15	63	
3	0	1	7	7	15	
Total	6	24	42	26	98	

Table 9. Distribution of the size of the mesial occlusal pits according to the size of the distal occlusal pits.

4. Discussion

In this study, we evaluated the anatomical features of the lower first premolar because it is considered one of the most complex teeth and the dentistry graduation students usually have difficulties in identifying it. According to Kraus and Furr [6], the lower first premolar shows an extremely wide range of morphologic variability.

There was no information about gender and age related to the teeth analyzed in this study. This is a limitation of this study because it was not possible to make associations between the measurements and those criteria.

The methodology was elaborated to cover the most of the anatomical structures of the lower first premolar for a detailed characterization of it. In order to do that, the classification of the pits, the way photographs were taken and the measurements made through the program Image Tool 3.0 were standardized.

Besides the anatomy books, there are practically no studies that describe the lower first premolars fully in detail. As those teeth have a wide anatomical variation and the dentistry students have difficulties in identifying them, this study sought to improve the information already known about those teeth, by facilitating the teaching-learning process in the dental anatomy.

The results presented in this chapter showed that the widest occlusal pit was the distal one. According to Figún and Garino [7], even though the occlusal pits are irregularly arranged, the distal pit is the widest one. Some authors [1, 2, 4] reported that the distal occlusal pit is the widest one [5, 8] but they did not mention whether there were differences between the occlusal pits.

The groove from the mesial occlusal fossa frequently continues to the lingual surface of the tooth [4, 5]. In our study, the grooves in the lingual surface that emerged from mesial and distal occlusal pits were usually absent. When the groove was present, it emerged, more frequently, from the mesial occlusal pit. According to Pagano et al. [8], there are some different situations related to the occlusal grooves such as grooves from the distal occlusal pit, short grooves from the mesial and distal occlusal pits or mesiolingual groove crossing the mesial marginal ridge.

Regarding the number of lingual cusps, most of the evaluated teeth had only one lingual cusp. This characteristic is in agreement with other studies [1–5].

Regarding the dimension of the total length of the lower first premolars, Della Serra and Ferreira [1] cited a variation from 17.0 to 27 mm and Sicher and Dubrul [4] reported a similar variation (18.5–27 mm). According to Picosse [2], the mean length of the lower first premolars in men was 21.97 mm and in women, it was 22.47 mm. In the present study, the total length of the evaluated teeth ranged from 19 to 28 mm, with a mean length of 22.85 mm.

In this study, we evaluated the cervical-occlusal measurement of the crown on the buccal surface (CO-BS) and the lingual surface (CO-LS). The mean values were 8.34 mm (ranging from 7 to 10 mm) and 5.59 mm (ranging from 2 to 8 mm), respectively. Sicher and Dubrul [4] also

made the same evaluation and reported values from 7.5 to 11 mm for the length of the dental crown in the buccal surface and 5 to 5.8 mm in the lingual surface. Picosse [2] reported a mean value of 8.69 mm for men and 7.40 mm for women, for the length of dental crown, whereas Della Serra and Ferreira [1] cited a variation from 6.2 to 11 mm.

Regarding the mesiodistal dimension of the dental crown, we found in the literature a variation from 6.0 to 8.0 mm [4], 5.5 to 8.5 mm [1] and a maximum value of 6.87 mm [2]. In the present study, the same measurement ranged from 6 to 9 mm with a mean value of 7.08 mm.

Observing the size of the mesial and distal longitudinal edges of the buccal cusp, there was similarity between them. Although, Picosse [2] reported that the distal edge is slightly larger and more inclined.

In this study, it was verified that the distal marginal ridge was frequently larger than the mesial marginal ridge. This feature may contribute for the largest buccolingual dimension of the distal surface, besides the wider distal occlusal pit observed in the lower first premolars. Figun and Garino [7] also verified that the distal segment is the largest portion of the occlusal surface, and the mesial segment presents a large slope and a small dimension. Pagano et al. [8] reported that the occlusal surface presents a large/moderate reduction of the mesiolingual segment; the convex lingual surface is continuous with the contact surface and a large buccolingual dimension of the distal surface.

According to Madeira and Rizzolo [5], the buccal and lingual cusps are almost always linked by an enamel bridge. Some authors also mentioned the constant presence of the enamel bridge [1, 4]. A similar situation was verified in this study. The enamel bridge was absent only in 6% of the teeth; it was present 47% in the mesial third and 45% in the middle third.

The mesiodistal groove crossing the enamel bridge was present in 50% of the teeth. The literature did not report the percentage of the presence of this groove. It is reported that some lower first premolars may have the enamel bridge being crossed by a mesiodistal groove [1, 4, 5].

A large variation in the root canal morphology is reported in the literature, especially in lower premolars [9]. The lower first premolars are prone to variations in their internal anatomy, which may have different number of roots and root canals [10]. In the present study, 97% of the teeth were uniradicular and only three teeth (3%) presented a apical third bifurcation. Bernardino et al. [11] observed four lower first premolars (3.2%) presenting three roots and 123 (96.8%) being uniradicular from a sample of 127 teeth. According to the authors, lower first premolars with three roots can be considered a rare anatomical variation. The incidence of a three-rooted lower first premolar is approximately 0.2% [12]. It was verified that the root was rectilinear, without any angulation in 70% of the teeth. Della Serra and Ferreira [1] reported that the root was rectilinear in 47.5% of the cases. Therefore, according to Madeira and Rizzolo [5], the root curves a little to distal direction in a buccal view. Our results showed that, when there is a deviation of the root apex, it is usually to distal direction.

The root grooves were absent in most of the evaluated teeth and, when present, they were usually observed in the mesial surface, in agreement with the observations of Madeira and

Rizzolo [5], who reported the presence of shallow longitudinal grooves and sometimes almost imperceptible ones in the mesial surface of the root. Differently from them, Picosse [2] reported that the mesial and distal radicular grooves were always present.

It was observed that the buccolingual dimension of the root was larger than the mesiodistal dimension. This feature is in agreement with Sicher and Dubrul [4], who reported that the mesiodistal dimension is slightly smaller than the buccolingual dimension.

5. Conclusion

According to the results, it was concluded that the lower first premolars usually presented the following features:

- Only one lingual cusp.
- An enamel bridge linking the buccal and lingual cusps.
- Distal occlusal pits wider than the mesial occlusal pits.
- The grooves in the lingual surface that emerged from the mesial and distal occlusal pits were absent, and when the grooves were present, they emerged from the mesial occlusal pit.
- One rectilinear root with no root grooves.
- When the root groove was present, it was observed in the mesial surface.

Author details

Ticiana Sidorenko de Oliveira Capote^{1*}, Suellen Tayenne Pedroso Pinto¹, Marcelo Brito Conte¹, Juliana Álvares Duarte Bonini Campos² and Marcela de Almeida Gonçalves¹

*Address all correspondence to: ticiana@foar.unesp.br

1 Department of Morphology, School of Dentistry, São Paulo State University (UNESP), Araraquara, São Paulo, Brazil

2 Department of Food and Nutrition, Faculty of Pharmaceutical Sciences, São Paulo State University (UNESP), Araraquara, São Paulo, Brazil

References

- [1] Della Serra O, Ferreira FV. Anatomia dental. 3rd ed. São Paulo: Artes Médicas; 1981. 334p
- [2] Picosse M. Anatomia dentária. 4th ed. São Paulo: Sarvier; 1977. 294p

- [3] Girón G, Gómez P, Morales L, León M, Moreno F. Rasgos morfológicos y métricos dentales coronales de premolares superiores e inferiores en escolares de tres instituciones educativas de Cali, Colombia. *International Journal of Morphology*. 2009;**27**(3):913-925
- [4] Sicher H, Dubrul E. *Anatomia Oral*. 8th ed. Porto Alegre: Artes Médicas; 1991. 390p
- [5] Madeira MC, Rizzolo RJC. *Anatomia do dente*. 8th ed. São Paulo: Sarvier; 2016. 169p
- [6] Kraus BS, Furr ML. Lower first premolars part I. a definition and classification of discrete morphologic traits. *Journal of Dental Research*. 1953;**32**(4):554-564
- [7] Figún ME, Garino RR. *Anatomia odontológica funcional e aplicada*. 2nd ed. Porto Alegre: Artmed; 2003. 532p
- [8] Pagano JL, Carbó RAR, Ramón A. *Anatomía dentaria*. Buenos Aires: Mundi; 1965. 664p
- [9] Dotto SR, Pagliarin CML, Carvalho MGP, Travassos RMC, Rosa RA. Endodontic treatment of mandibular premolar with three radicular conducts—Case report. *Revista de Endodontia Pesquisa e Ensino Online*. 2007;**3**(6):1 Available from: [http://w3.ufsm.br/endodontiaonline/artigos/\[REPEO\]%20Numero%206%20Artigo%201.pdf](http://w3.ufsm.br/endodontiaonline/artigos/[REPEO]%20Numero%206%20Artigo%201.pdf)
- [10] Endo MS, Tomazoli ATP, Queiroz AF, de Moraes CAH, Pavan NNO. Tratamento endodôntico de primeiopré-molar inferior com três canais: relato de caso. *Archives of Health Investigation*. 2017;**6**(2):85-88
- [11] Bernardino Junior R, Lucas BL, Borges DP, Souza AC. Three-rooted first lower premolar: A case report. *Bioscience Journal*. 2007;**23**(4):104-107
- [12] Cleghorn BM, Christie WH, Dong CC. Anomalous mandibular premolars: A mandibular first premolar with three roots and a mandibular second premolar with a C-shaped canal system. *International Endodontic Journal*. 2008;**41**(11):1005-1014