

# We are IntechOpen, the world's leading publisher of Open Access books Built by scientists, for scientists

6,900

Open access books available

185,000

International authors and editors

200M

Downloads

Our authors are among the

154

Countries delivered to

TOP 1%

most cited scientists

12.2%

Contributors from top 500 universities



WEB OF SCIENCE™

Selection of our books indexed in the Book Citation Index  
in Web of Science™ Core Collection (BKCI)

Interested in publishing with us?  
Contact [book.department@intechopen.com](mailto:book.department@intechopen.com)

Numbers displayed above are based on latest data collected.  
For more information visit [www.intechopen.com](http://www.intechopen.com)



---

# Photodynamic Therapy and Skin Cancer

---

Eleni Papakonstantinou, Florian Löhr and  
Ulrike Raap

Additional information is available at the end of the chapter

<http://dx.doi.org/10.5772/intechopen.70309>

---

## Abstract

Non-melanoma skin cancer (NMSC) is the most common type of cancer among white skin individuals worldwide with an increasing incidence over the last years. NMSC is mostly treated with surgical or non-invasive methods such as cryotherapy or topical chemotherapeutics. Over the last years, there has been a rapidly growing interest in the use of photodynamic therapy (PDT) which is a well-tolerated, safe and effective alternative treatment option. PDT involves a photosensitizer, a light source and tissue oxygen and is based on a photo-oxidation reaction in the target tissue which results to a selective destruction of the cancer cells. PDT has been approved for treatment of actinic keratosis, Bowen's disease and basal cell carcinoma in Europe. Off-label uses include treatment of invasive squamous cell carcinoma, cutaneous T-cell lymphoma, Kaposi's sarcoma, Paget's disease and prevention of recurrence of squamous cell carcinoma in organ-transplant recipients. Also combination of PDT with other treatment options such as cryotherapy, surgery and topical therapies has been reported with improved efficacy, tolerability and long-term results. Development of novel photosensitizers and light sources together with targeted delivery systems will increase specificity, efficiency and treatment field of PDT in the future. This chapter aims to give the reader an overview of the important applications of PDT, including indications, approved treatments, advantages and disadvantages of this method such as future trends.

**Keywords:** photodynamic therapy, photosensitizer, non-melanoma skin cancer, basal cell carcinoma, squamous cell carcinoma, actinic keratosis

---

## 1. Introduction

Non-melanoma skin cancer (NMSC) is the most common type of cancer among white-skin individuals worldwide with an increasing incidence over the last years. Clinical examination, evaluation through dermoscopy and histopathology are the gold standard methods for the

diagnosis of skin cancer. These diagnostic procedures together with the location and extent of the tumor will determine the choice of treatment. NMSC is mostly treated with surgical excision or non-invasive methods such as cryotherapy, application of topical chemotherapeutics or radiotherapy. However, limitations and side-effects of the conventional therapies motivate the development of other techniques.

Over the last years, there has been a rapidly growing interest in the use of photodynamic therapy (PDT) for treatment and prevention of skin cancer. PDT is a well-tolerated, safe and effective alternative in the treatment and prevention of non-melanoma skin cancer. Nowadays, it is mostly used for the treatment for actinic keratosis but also for in situ squamous cell carcinoma (Bowen's disease), superficial- and also nodular basal cell carcinoma with acceptable response rates [1].

As a non-invasive targeted therapy with a low spectrum of adverse effects, PDT has advantages concerning the patient comfort and achieves excellent cosmetic results while the response rates are comparable to that of other surgical and nonsurgical procedures [2].

The aim of this chapter is to provide an assessment of the current state of use of PDT in the treatment of skin cancer and focus on new developments and future aspects of this procedure in the treatment of non-melanoma skin cancer.

## **2. General principles of photodynamic therapy**

The main principle of photodynamic therapy is based on photooxidation occurring in a target tissue. Key components of this technique are a photosensitizer, oxygen and light within the absorption spectrum of the photosensitizer.

The mechanism of action of photosensitizers is divided in two different types. Type I reaction involves direct oxidation by hydrogen peroxide, superoxide anion radical and hydroxyl radical of biological targets (DNA, membranes and proteins), while type II reaction includes oxidation mediated by singlet oxygen through energy transfer from triplet states to molecular oxygen [3]. The production of reactive oxygen species (ROS) depends on the uptake of a photosensitizing drug by the tumor, the subsequent irradiation of the tumor with visible light of an appropriate wavelength and the presence of an adequate concentration of molecular oxygen [3]. A photosensitizer can induce tissue damage either directly through induction of necrosis or apoptosis or indirectly by affecting its vascularization. It is important to know that in absence of any one of these components, the effectiveness of photodynamic response is disturbed. Therefore, careful selection of photosensitizer, type of tissue photosensitization and light dosimetry is essential [4, 5].

### **2.1. Photosensitizers**

Photosensitizers (PSs) are substances capable of making an organism, a cell or a tissue photosensitive by inducing the photo-oxidation of several types of molecules through energy transfer processes. The development of an ideal photosensitizer remains a major challenge since several characteristics have to be taken into consideration. It is important for the photosensitizer to be

chemically pure, to have chemical and physical stability, high selectivity and to be activated only in the presence of light, with no dark toxicity. The wavelength of the light used in PDT has to be longer than those in the UV spectrum in order to minimize the risk of UV-induced skin cancer. Its absorption peak should be a wavelength  $> 630$  nm, where it presents an optimal tissue penetration. Furthermore, it should have a high absorption capacity being able to be rapidly and predominantly retained in the tumor tissue and eliminated from the organism in order to prevent the risk of prolonged systemic photosensitivity. The photosensitizer should also have a clearance from the tumor tissue which is slower than that of normal cells and be capable to generate reactive oxygen species [6].

For dermatological appliance, only haematoporphyrin derivatives like porfimer sodium (Photofrin H) or protoporphyrin IX (PPIX)-inducing precursors like 5-aminolevulinic acid (ALA) or methyl aminolevulinate (MAL) are of practical concern. Therefore topical photosensitizers are preferred for use in dermatology. After topical application, both ALA and MAL are mainly taken up by cells of epithelial origin and are converted into photosensitizing porphyrins [7]. After an incubation period, followed by illumination with visible light to activate the photosensitizer a type II photo-oxidation reaction takes place and produces reactive oxygen species (ROS), which destroy cell membranes and structures, ultimately leading to cell death. The appropriate wavelength of light, concentration of sensitizer and molecular oxygen level in the tissue are all critical for the efficacy of PDT [8].

## 2.2. Topical photosensitizing drugs

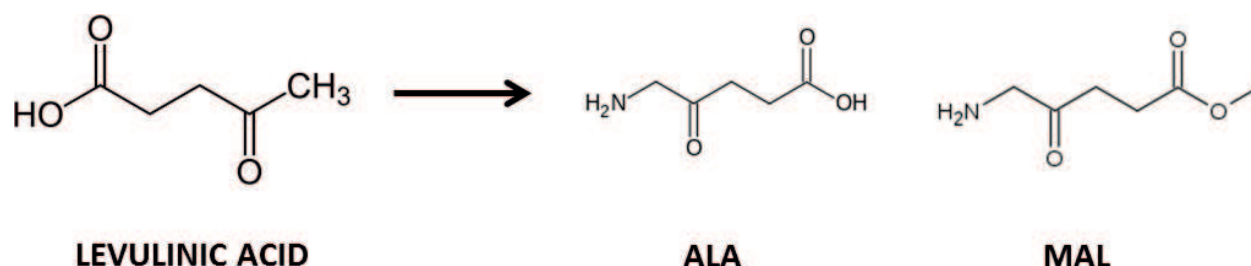
Current clinical practice utilizes the use of topical photosensitizers in PDT such as 5-aminolevulinic acid (5-ALA) or methyl-aminolevulinate (MAL), which are both precursors in the biosynthesis of protoporphyrin IX (PpIX) (**Figure 1**). PpIX is a native photosensitizing compound that accumulates in the cells and has an absorption peak at 505, 540, 580 and 630 nm.

The 5-ALA-based photosensitizers are not photoactive themselves, but show a preferential intracellular accumulation in the tissue target and particularly in the tumor cells where they are metabolized by the haem biosynthesis into photosensitizing porphyrins [7, 9].

Although these two molecules share a similar mechanism of action as prodrugs that lead to production of photoactive PpIX, they have notable differences.

ALA is a hydrophilic molecule and is used to treat more superficial lesions due to its modest tissue penetration [10]. Although the uptake of ALA is non-selective, accumulation of PpIX in tumor cells may occur selectively through alterations in enzymatic activity in the heme synthesis pathway. It is supposed, that activity of porphobilinogen deaminase (PBGD) increases in tumor tissue. PBGD synthesizes a precursor of PpIX and thus increases production of PpIX. The accumulation of PpIX in tumor tissue is further enhanced by decreased activity of ferrochelatase, which converts PpIX to heme [11]. Another postulated mechanism of selectivity for topical ALA relates to the altered stratum corneum of tumoral skin.

MAL is a more hydrophobic molecule which can better penetrate through the cell membranes and more easily reaches the deepest epidermal layers. Therefore, shows MAL a higher selectivity for tumor cells compared with ALA. However, the biosynthesis of protoporphyrin IX

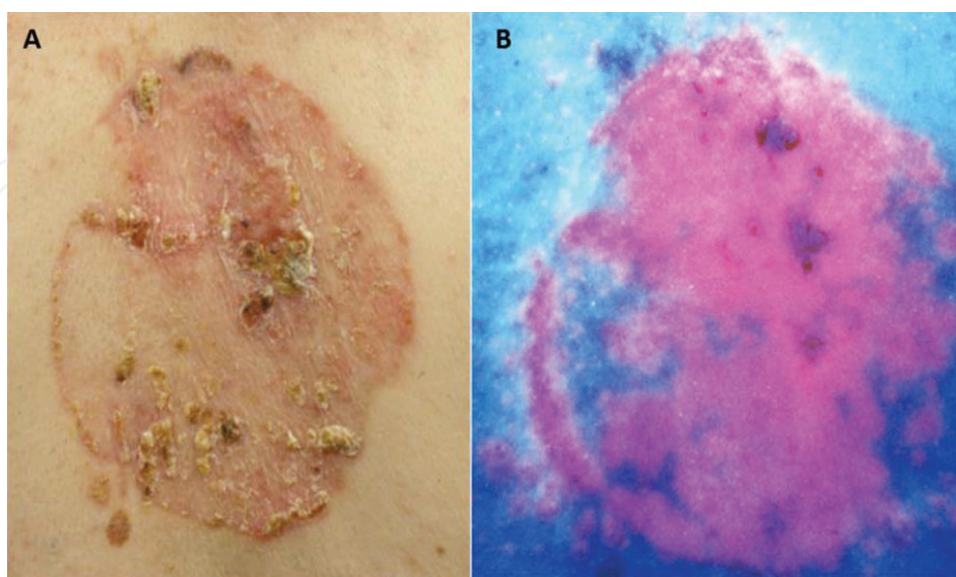


**Figure 1.** Molecular structures of 5-aminolevulinic acid (5-ALA) and methyl-aminolevulinate (MAL).

production from MAL is slightly slower because of the need of hydrolysis of this compound. Adjacent unaffected structures such as epidermis and mesenchymal cells show a much less pronounced production of porphyrin, thus leading to a high ratio between tumor and surrounding tissue [12]. This technique enables a selective detection (fluorescence detection) and selective destruction of the target tissue with minimal harm to the surrounding one (**Figure 2**).

Interestingly, there seems to be no significant differences in the efficacy between ALA- and MAL-PDT in the treatment of NMSC, as recently shown [13].

Standardized protocols for the application of both photosensitizing drugs have been developed. For MAL-PDT, there is a standardized protocol of two treatments 1 week apart for basal cell carcinoma (BCC) and Bowen's disease (BD), but with only one initial treatment for actinic keratosis (AK), repeated at 3 months, only if required [1]. MAL is typically applied for 3 h, but Levulan ALA although licensed for an 18–24 h application, is widely used with shorter application intervals around 1 h [14]. A shorter incubation for MAL-PDT for 1 h in AK can also be performed since no significant difference in clearance rates have been reported [15].



**Figure 2.** Selective detection of fluorescence due to prior application of ALA on a superficial BCC lesion.



Several novel topical photosensitizers such near-infrared (NIR) bacteriochlorin analogues [16], silicon phthalocyanine, alone [17] or in combination with C6-pyridinium ceramide (LCL29) [18] have promising characteristics for use in PDT but they are still in experimental level.

### 2.3. Light sources and action mechanism

Distinct light sources can be used for PDT. For therapy, the tissue must be irradiated with light at appropriate wavelengths (within the absorption spectrum of porphyrins) and the light source should have special characteristics for use in PDT in NMSC. Light should be perfectly absorbed by the photosensitizer, achieve a desirable penetration depth and thus reaching the target tissue, have an adequate power and duration in order to trigger the PDT reaction and cause minimal discomfort or side-effects such as erythema, crusting or dyspigmentation [19].

Porphyrins exhibit a very typical absorption spectrum with the highest peak at approximately 405 nm, called the Soret-band. Several so-called Q-bands also exist, the last having an absorption peak at 635 nm. Although the peak is much smaller than that at 405 nm, this wavelength is preferentially used for illumination since light at red spectrum results in a higher tissue penetration [20, 21].

The light sources available for PDT belong to three major groups: broad spectrum lamps, diode lamps and lasers. For a successful PDT-treatment using ALA- or MAL-PDT both laser and incoherent light sources can be used and there is no difference regarding the profile of light. Even pulsed laser light sources matching one of the Q-bands at 585 nm have comparable results to an incoherent light source in the treatment of AK [22]. Also the use of a long-pulsed dye laser at 595 nm seems to be effective for the same indication [19]. The incoherent light sources include the halogen lamps, the light-emitting diode (LED) lamps and intense pulsed light (IPL) lamps. Due to the possibility of distinct emission geometries and lower costs are an attractive option [23, 24].

Light with wavelengths of 635 nm is capable of penetrating the skin to a depth of approximately 6 mm compared to 1–2 mm with a wavelength of 400–500 nm. The effective therapeutic depth, however, appears to be close to 1–3 mm when 635 nm is used. This is due to the capacity to produce a photodynamic reaction, which depends on the dose of light and also on the quantity of photosensitizer used in the target tissue [25].

Advantages of lasers are that they provide a specific wavelength that corresponds to the peak absorption of the photosensitizer. Since lasers can emit high flux monochromatic light and have a focal precision, enable the treatment of small lesions with minimal damage to the surrounding tissue and within a short time interval. Nevertheless, for the treatment of dermatological conditions using PDT, lasers show no advantage compared to over cheaper and more practical options with non-coherent light sources. These sources emit a large radiation field, enabling larger areas of the skin surface to be treated [26]. However, the costs for purchasing and maintenance of these laser systems are extremely high. The gold standards in topical PDT are light sources with wide illumination fields which accomplish the simultaneous illumination of larger areas.

Here incoherent light sources are preferred, either lamps or light-emitting diodes (LEDs) which match the absorption maxima of the ALA- or MAL-induced porphyrins [25, 27, 28]. Using broad-spectrum red light (580–700 nm), a light dose of 100–150 J/cm<sup>2</sup> (100–200 mW/cm<sup>2</sup>) is essential for tissue damage. The light intensity should not exceed 200 mW/cm<sup>2</sup> in order to avoid hyperthermic side effects [27]. After a photosensitizer has been activated with light of appropriate wavelength, it comes to the generation of reactive oxygen species (ROS), in particular singlet oxygen. Depending on the extend and localization of the target tissue, these ROS modify either cellular functions or induce cell death by necrosis or apoptosis [29].

MAL-PDT using daylight has been shown to be as effective as conventional red light MAL-PDT in the treatment of AK, but with minimal to no therapy-related pain [30].

There is also an option for ambulatory PDT, where portable LED light source with low irradiance can be applied for over 100 min. Satisfactory results with clearing 11 of 17 lesions and minimal pain have been reported for treatment of BD and superficial BCC [31].

#### **2.4. Cutaneous fluorescence diagnosis**

Topical photosensitizing drugs can also be applied for diagnostic purposes. Cutaneous fluorescence diagnosis (FD) is a promising dermatological procedure based on the combination of a local application of a photosensitizer such ALA or MAL and the use of a light source adapted to the absorption spectrum of these molecules. After topical application of ALA or MAL on the skin lesional and non-lesional areas, they are irradiated with blue light (408 nm). As PpIX shows red fluorescence when excited by blue light, PpIX accumulating cells can be visualized [32]. The detection of skin surface fluorescence can be made either by using simple handheld Wood's lamp (long wave UVA) or by using CCD camera systems coupled to digital imaging and helps the clinician to differentiate lesions and perform either a guided biopsy or a controlled and complete resection of tumor, or even to identify persistent or recurrent disease. By using a commercial digital CCD camera system, together with digital imaging, the contrast of the acquired fluorescence images can be significantly enhanced and allows the determination of a threshold, which can be utilized either for a directed biopsy or for preoperative planning when Moh's surgery is scheduled [33].

Furthermore, FD is probably a helpful tool to prove the efficacy of PDT. Limitations of this technique are the difficult interpretation and the low reproducibility of the obtained data. Most studies have mainly focused on BCC [34], AK and SCC [35] so far. Truchuelo et al. [36] showed that FS is a valid diagnostic tool in the diagnosis and follow up of BD with a comparable evaluation to clinical and histopathological results, a specificity of 85.7% and a 100% sensitivity (higher than clinical evaluation alone).

Although, FS cannot be used to differentiate the different stages of AK, it was shown that through differences in fluorescence ratio between AK and SCC, these entities can be differentiated [35, 37].

## 2.5. Practical application, tolerability and side effects

PDT with ALA or MAL conventionally begins with the topical application of the photosensitizers on the target area. In case of hyperkeratotic lesions, a keratolysis using an ointment, wet cloth or by slight non-bleeding curettage has to be performed prior to the application of photosensitizer as this may be the cause of a poor therapeutic response [38, 39].

ALA has been applied in various formulations such as creams or gels, sometimes with penetration enhancers. ALA preparations are usually applied to the target lesions with little overlap to the surrounding tissue for 4–6 h prior to illumination under occlusion and with a light protective dressing or clothing [40].

MAL is mainly applied in ointments which have a shorter incubation time of 3 h due to the preferential uptake and their higher selectivity [41, 42]. The entire area is then covered with an occlusive foil to allow a better penetration during the incubation which is then followed by illumination with blue light.

Pain is a major and serious adverse event during PDT and can lead to discomfort of the patient to incomplete treatments and need for repeat treatments [43]. The pain or a kind of burning sensation is mostly experienced during the time of illumination and a couple of hours later [9].

In a previous study it could be shown that MAL-PDT induces less pain in comparison to ALA-PDT which can be partially explained due to the differences in selectivity between the two substances [44].

Various pain-relieving approaches have been used in order to reduce pain during PDT. During extensive treatment fields administration of oral analgesia can be useful [45]. The application of local anaesthetics like lidocaine/prilocaine substances prior to illumination is generally not recommended. As previously shown also application of morphine 0.3% gel 15 min prior to illumination did not result in a significant reduction of pain as compared to a placebo gel [46]. Furthermore, due to their high pH local anaesthetics carry the risk of interaction during the incubation period of ALA/MAL and thus inactivate the photosensitizing drug. Wiegell et al. showed that application of cold water and regular pauses in illumination led to a considerable reduction of pain during PDT [47]. An alternative option with satisfactory results is a concurrent cold air analgesia which has been shown to improve the tolerability of ALA- and MAL-PDT [48]. Also analgesia by means of a nitrous oxide/oxygen mixture during PDT led to an overall reduction in pain of 55.2% and willingness of patients to continue the therapy [43].

Previous studies have also demonstrated that the type of light applied plays also a role in the development of pain. Therefore, PDT with the use of PDL coherent light, when compared to LED incoherent light led to less pain and increased willingness of patients to further perform the therapy [49].

Besides pain also burning and prickling sensations are common side effects of PDT. These sensations are usually mild to moderate in intensity and reversible [50]. In a previous study with ALA-PDT used to treat AK, it was found that about 96% of patients experienced



stinging/burning sensations at 6 and 11 min during illumination. However, only 10% of them characterized pain intensity as severe [51].

Localized erythema and oedema in the treated area can also occur. Rarely a dry necrosis sharply restricted to the tumor areas can manifest over the next few days which is followed by complete re-epithelialization. Also pigmentary disorders presented as hypo- or hyperpigmentation are also potential adverse effects of PDT treatment but are rare and of temporary duration. More often, pigmentary disorders have been noted prior to PDT-treatment and resolved at the last follow-up evaluation [51]. Allergic contact dermatitis, although extremely rare, can also occur by presence of sensitization against active ingredients of the applied sensitizers [52].

Due to the high selectivity and photosensitization preferentially to cells of epithelial origin and no fibroblasts or dermal fibers, usually no scarring or ulceration is observed clinically [9, 40]. Also irreversible alopecia could not be observed after PDT treatment series on the scalp despite the concomitant sensitization of pilosebaceous units [40, 53]. With the exception of a porphyria or previous allergic reactions to the active ingredients of the applied sensitizers in the medical history, there are no severe limitations to performance of ALA- or MAL-PDT. PDT treatment can be repeated and applied even in areas with prior exposure to ionizing irradiation [54]. During PDT treatment, both patient and clinic staff should be wearing protective goggles to avoid the risk of eye damage [38].

### 3. Photodynamic therapy in non-melanoma skin cancer

PDT is nowadays widely applied in the therapy of NMSC. The range of possible indications is expanding continuously, including non-malignant conditions and even premature skin aging due to chronic sun exposure. MAL is approved for use in Europe and United States in combination with red light for treating AK, superficial or nodular BCC and in-situ SCC or BD. A combination of an alcohol-containing ALA solution in a special applicator (Levulan Kerastick) and blue light is also approved in United States for the treatment of AK. For therapy of multiple lesions or by immunodeficient patients, PDT may be the treatment of first choice [23]. PDT is also indicated for patients with important comorbidities when surgery and radiotherapy are contraindicated. It may also be used for palliative care in combination with chemo- or radiotherapy for advanced tumors with skin metastases.

In the dermatological daily practice, PDT has some advantages compared to conventional treatments such as radiotherapy, chemotherapy and surgery. Some of them are the limited duration of the treatment, the efficiency and the good cosmetic outcome due to its high selectivity.

#### 3.1. Actinic keratosis

Actinic keratoses (AKs) are premalignant disorders of keratinocytes occurring on chronically sun-damaged skin. Although a spontaneous regression may occur in up to 20% of cases [55] there is a risk of transformation to SCC within one year between 0.025 and 16% [56]. Since AK manifests in chronically sun-damaged skin and there are often multiple lesions the exact risk

of malignant transformation for individual lesions cannot be estimated [57]. Various treatment options such as cryotherapy, topical immunomodulation, laser and PDT are highly effective and recommended not only for individual lesions but also for field treatment [1, 58]. Several studies have been performed analyzing the efficacy of both ALA-PDT and MAL-PDT and comparing them with other procedures in treatment of AKs. Thin AK lesions or lesions of moderate thickness on the face and scalp respond well to topical PDT with clearance rates 89–92% 3 months after therapy [59]. A phase III clinical trial of ALA-PDT for the treatment of multiple AKs of the face and scalp found that 89% of patients had a remission of 75% or more of their AKs after 3 months of treatment [60]. Tschen et al. [51] reported remission rates of 78% 12 months after a single ALA-PDT treatment, with few adverse effects.

European guidelines recommend that for AK, MAL-PDT should be performed as a single treatment and repeated if required after 3 months, reflecting equivalent efficacy in a comparable study with a double therapy 1 week apart [59].

Also compared with other treatment options such as cryotherapy PDT achieves favorable outcomes [61, 62]. A novel self-adhesive patch ALA-PDT was superior to cryotherapy and placebo after 12 weeks in a multicenter phase III trial [61]. Also MAL-PDT achieved better therapeutic results compared to single cycle cryotherapy and placebo after 3 months in another large prospective randomized study [62]. When compared to double cycle cryotherapy for AKs on the extremities in a large randomized multicenter study MAL-PDT showed superior efficacy [63].

When compared with the topical application of 5-fluorouracil (5-FU) twice daily ALA-PDT showed similar outcomes in mean lesion reduction [64]. Recently Tanghetti et al. reported that patients with AK who had been treated with 5-FU prior to ALA-PDT showed a significant decrease of clinical lesions after 1 and 3 months compared to these substances alone, which indicates that 5-FU has a synergistic role to ALA-PDT [65].

No significant difference was found in treatment responses of facial AKs to topical 5% imiquimod compared to ALA-PDT in a randomized, single-blind, split-face study [66]. Tanaka et al. [67] also compared the use of topical 5% imiquimod, with ALA-PDT but also with combination therapy in a randomized study. Although the combination group showed outstanding effectiveness, it was more frequently associated with adverse events, when compared to the PDT and imiquimod alone groups. There were no differences in either efficacy or adverse events between PDT and imiquimod monotherapy, however development of pigmentation was higher in the imiquimod therapy group.

Interestingly, imiquimod 5%, showed superiority in histological and clinical outcomes over MAL-PDT for face and scalp AKs, in a further randomized study [68]. The same study found that sequential MAL-PDT and imiquimod 5% are significantly more effective than each therapy alone, indicating that combination treatment may be beneficial [68].

Compared to CO<sub>2</sub> laser ablation for the treatment of multiple scalp AKs in a randomized, half-side comparative study ALA-PDT showed superior efficacy [69]. By hyperkeratotic AKs, physical or chemical keratolytic pretreatment significantly improves the uptake of photosensitizer and light penetrance [70]. Topical application of 10% salicylic acid and 40% urea have similar efficacy to curettage, although chemical pre-treatment was associated with increased

pain [70]. The recent introduction of ALA patch PDT reduces the need of keratolytic treatment prior to PDT [71].

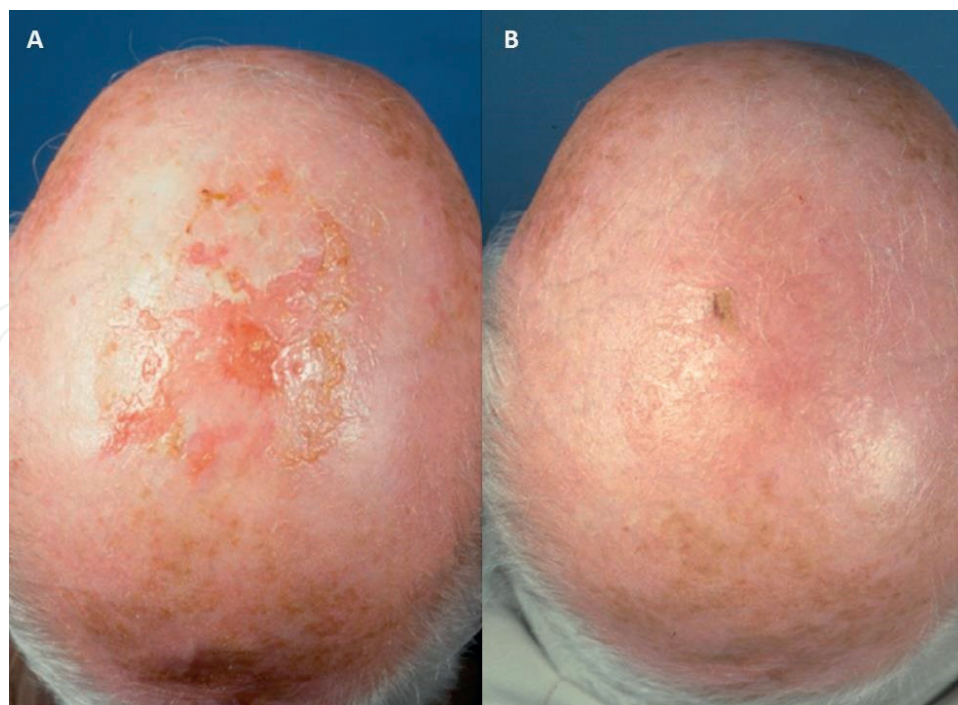
Efficacy of PDT for AK on acral sites is reduced by approximately 10%, probably due to a higher proportion of thicker lesions. Compared to cryotherapy, MAL-PDT proved to be less effective for acral AK (lesion clearance 78% versus 88% after 6 months) [51].

Several novel methods of delivering PDT have been used for the treatment of AK, including the adhesive patch, daylight, ambulatory light sources and fractionated light protocols. PDT using the BF-200 ALA, has been recently licensed and proven to be superior to MAL with clearance of 90% versus 83% of thin or moderate thickness face/scalp AK (complete clearance rates of 78% versus 64%) 12 weeks after one or two PDT treatments [72].

PDT is identified as an effective therapeutic option both for lesion and field treatment for AK and by presence of multiple and/or confluent AK, at sites of poor healing, or where there has been a poor response to other topical therapies [73]. Also patient tolerance to MAL-PDT or topical imiquimod for multiple face/scalp AK and level of satisfaction were significantly higher by patients who underwent PDT treatment in a randomized comparison trial [74]. **Figures 3 and 4** present clinical outcomes of ALA-PDT in AK lesions at the head and ear of two patients.

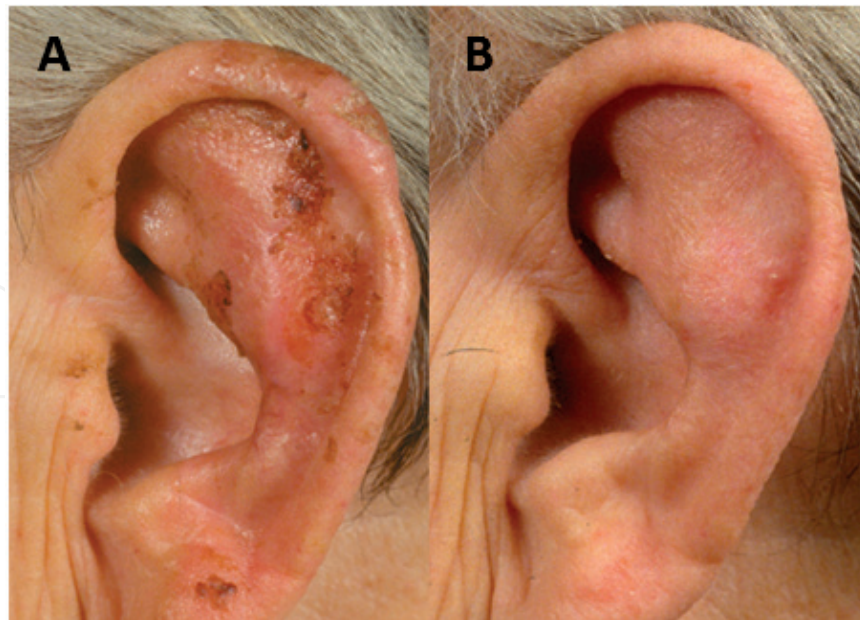
### 3.2. Basal cell carcinoma

PDT is an established treatment for superficial and nodular types of BCC, but is not indicated for the more aggressive or infiltrating types [75]. Response rates of PDT in the existing



**Figure 3.** (A) Clinical manifestation of AKs on the head, (B) clinical outcome 4 weeks after one therapy-cycle consisting of double PDT-treatment in 1 week apart.





**Figure 4.** (A) Clinical manifestation of AKs on the helix of the left ear, (B) clinical outcome 3 years after therapy (there has been performed two therapy-cycles each consisting of double PDT-treatment in 1 week apart).

literature vary between 70 and 90%, which may depend on the kind of tumors and the exact performance of PDT [76, 77]. MAL-PDT is approved in the EU for treatment of BCC, but remains off-label in the United States. Several studies have so far assessed the efficacy, cosmetic results and recurrence rates of BCC treated with PDT [78–80].

PDT has proven to generally be more effective for superficial BCC as compared to nodular BCC and also for lesions smaller than 2 cm [65, 66, 68]. Regarding the use of PDT for the treatment of larger and nodular BCC, MAL-PDT has proven to be a more effective treatment option with lower recurrence rates as compared to ALA-PDT [66, 68].

PDT appears to have good efficacy and cosmetic outcome but results in higher BCC recurrence rates in comparison to surgical excision [77, 79, 81–83]. Szeimies et al. [77] reported a similar efficacy at 3 months for MAL-PDT and surgical excision in the management of superficial BCC in a large randomized multicenter open study (92.2% clinical lesion response versus 99.2% in the surgical group). In a recent meta-analysis Zou et al. [83] found also that PDT is comparably effective to surgical excision for treatment of BCC, but with an increased risk of recurrence. Rhodes et al. [82] showed that the recurrence rate for primary nodular BCC after treatment with PDT was 14% versus 4% with surgical excision at the 5-year follow-up point. Data from other studies support that PDT leads to better cosmetic results compared to surgical excision [81, 82]. Also PDT serves as an effective alternative treatment option in difficult cases where an extensive surgical excision should have been performed carrying the risk of a worse cosmetic outcome [84].

When compared with cryotherapy for the treatment of superficial BCC, MAL-PDT led to comparable recurrence rates after 5 years, but better cosmetic results [85]. In a recent three-year follow up randomized controlled trial Roozeboom et al. [86] compared the efficacy of

MAL-PDT, topical imiquimod and 5-FU on the treatment of superficial BCC. Topical imiquimod has shown superiority to MAL-PDT (tumor-free survival 58.0% for MAL-PDT versus 79.7% for imiquimod) but comparable results with 5-FU (68.2%).

For nodular BCC, variable response rates have been reported in several studies. Rhodes et al. [82] observed comparable response rates for primary nodular BCC treated with MAL-PDT or surgical excision at 3 months (91 and 98%, respectively), again with greater recurrence rates but better cosmetic outcomes in the PDT group. The same group showed in a later randomized study persistent complete lesion response rates at 5 years which were 76% for MAL-PDT and 96% for surgical excision of nodular BCC. PDT led consistently to better cosmetic outcomes [87]. On the contrary, Mosterd et al. [88] showed in a further randomized controlled study of 173 primary nodular BCCs that surgical excision was significantly more effective compared to a single treatment of fractionated ALA-PDT, with a failure rate of 2.3% compared to 30.3% for PDT at 3 year follow up. Performance of two ALA-PDT treatments for both nodular and superficial BCC has given comparable clinical response rates to surgery (95.83% complete response versus 95.65%). Recurrence rates were also similar (4.16% versus 4.34%) [81]. In the longest follow-up study to date lasting 10 years, Christensen et al. [89] found that the overall complete response rate for all subtypes of BCC treated with ALA-PDT was 75%, with a 60% complete response after one treatment and 87% response after two treatments.

More aggressive types of BCC, which often occur on the face, show a greater frequency of recurrence, possibly due to genetic mutations resulting to resistance to apoptosis [75]. Although long-term recurrence may limit the use of PDT for nodular BCC, PDT seems to be suitable for cases where surgical excision is not appropriate. On the other side, randomized studies with only short-term follow-up had previously reported high efficacy for facial nodular BCCs treated with MAL-PDT [90].

Since thickness of the tumor can affect the penetration capacity of the photosensitizer, various methods have been already used prior to PDT as pre-treatment in order to enhance its efficacy. Therefore, dimethylsulphoxide (DMSO), which alters the intercellular lipid structure of the stratum corneum, has been used as a pretreatment penetration enhancer [91]. Curettage and DMSO pretreatment prior to one or two sessions ALA-PDT brought favorable 10-year response rates of 75% for primary small BCC [89]. Also intralesional ALA and light source application showed promising results in a small prospective study of 20 patients with nodular BCC, with no clinical recurrence observed after 19.5 months [92].

Combination of PDT with Mohs micrographic surgery has also been performed with beneficial outcomes by reducing the tumor size and thus improving the cosmetic outcomes [93, 94].

PDT can be a useful option for patients with naevoid BCC syndrome (Gorlin syndrome) depending on the localization and thickness of the lesions [95]. In these patients can MAL-PDT significantly improve patient satisfaction and reduce the need for many surgical procedures [96].

Although topical PDT does not serve as first-line therapy for BCC, it is recommended for primary superficial and thin low-risk nodular BCC but is a relatively poor choice for high-risk lesions including nodular BCC [97]. PDT is best considered for nodular lesions where surgical excision is relatively contraindicated, or where patient preference, reflecting past therapy history, comorbidities or cosmetic considerations, although the higher risk of recurrence has



to be taken into consideration. It is advised that patients receiving topical PDT for nodular BCC are reviewed for evidence of recurrence for at least 1 year. Further long-term studies are needed to better assess the effectiveness of PDT on BCC. **Figure 5** demonstrates the treatment and clinical outcome after ALA-PDT on a superficial BCC.

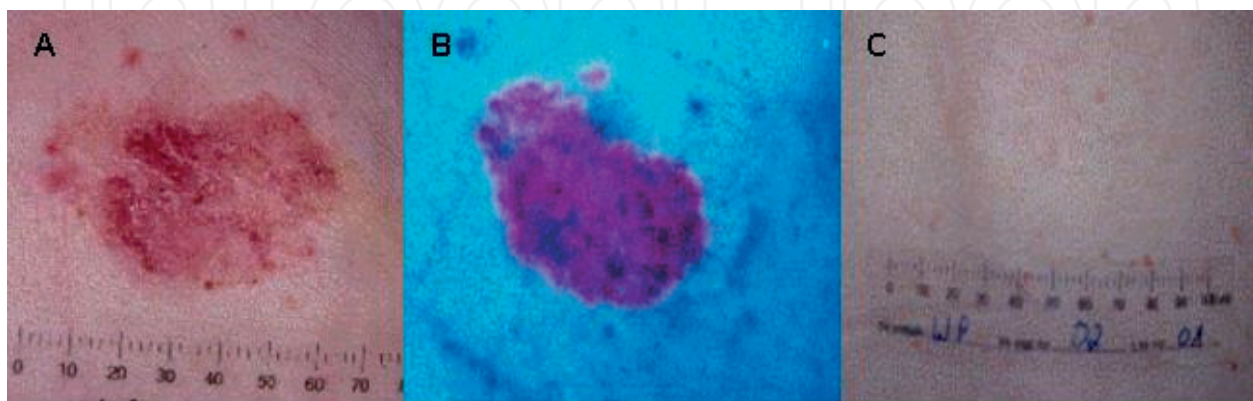
### 3.3. Squamous cell carcinoma

PDT has been also used for treatment of Bowen's disease, or squamous cell carcinoma in situ and is recommended for both extensive involvement and poor healing sites [98]. The approved MAL-PDT dosing regimen for Europe consists of two treatments 7 days apart, repeated at 3 months, if needed [99].

The clearance rates reported for BD lesions are high between 86 and 93% 3 months after one or two treatments of MAL-PDT using red light, with sustained clearance at 24 months of 68–71%, which is comparable with the conventional therapy, but with better cosmetic outcomes [100]. MAL-PDT was effective in treating lesions over 3 cm, with clearance rates of 96% in 3 months after one cycle of two treatments, with only three recurrences in a follow-up of 1 year [101]. Comparable outcomes have been reported from an observational study of 51 BD lesions which had been treated with two MAL-PDT treatments one week apart leading to clearance rates of 76.09% at 16.61 months with excellent cosmetic outcome and only mild cutaneous adverse effects [102].

Compared to cryotherapy and topical 5-FU, MAL-PDT showed similar response rates for BD at the 12 month follow-up point but superior cosmetic results [103]. Also ALA-PDT has been found to be significantly more effective for BD than topical 5-FU at 12 months (82% versus 48% complete clearance) at 12 months [104]. ALA-PDT compared to MAL-PDT, respectively, showed an 89% versus 78% response rate, at approximately 6 months after treatment [101].

Therapy guidelines recommend PDT as the treatment of choice for both large and small plaques of BD on poor-healing sites, representing the majority of lesions and a good choice



**Figure 5.** (A) Clinical manifestation of a superficial BCC, (B) selective detection of fluorescence after application of ALA on the lesion during PDT, (C) clinical outcome 3 years after therapy (there has been performed one therapy-cycle consisting of double PDT-treatment in 1 week apart).

for large lesions in good-healing sites [105]. However, larger studies with longer follow-up are needed to better assess response rates.

For invasive SCC there is a reduced efficacy of PDT where 24-month clearance rates of 57 and 26% have been reported. The degree of cellular atypia is a negative prognostic factor, suggesting that poorly differentiated keratinocytes are less sensitive to PDT because of reduced sensitivity to phototoxicity or decreased production of PpIX.

In some cases of invasive SCC, PDT-therapy was followed by resistance resulting in more aggressive disease. Gilaberte et al. [106] postulated that chromosomal instability is the reasonable factor through the induction of overexpression of CCND1 and aberration of the MAPK/ERK signal pathway, as previously shown in immunodeficient mice.

In view of its metastatic potential and reduced efficacy rates, PDT currently cannot be recommended for invasive SCC [100].

PDT can also be a useful treatment option by organ transplant recipients who are at an increased risk of NMSC and especially SCC due to long-term immunosuppressive therapy. Treatment with cyclic ALA-PDT at 4–8 week intervals over a 2-year period on 12 organ transplant recipients led to a significant reduction of SCC (98% mean reduction) [107]. Wennberg et al. [108] also found that repeat MAL-PDT treatments reduced the occurrence of new AKs in this special population.

#### 4. Conclusions and future expectations

Since the incidence of NMSC is increasing over the years, available therapies should aim to deliver good cosmetic outcomes and optimize patient comfort while still achieving acceptable response rates. PDT offers an attractive alternate to surgical treatment of NMSC, as well as an alternate to non-surgical treatments such as cryotherapy, imiquimod and 5-fluorouracil. Conventional PDT is in comparison to daylight PDT a well-tolerated treatment method, with pain during and shortly after treatment being the main adverse effect.

MAL appears to be associated with lower pain levels than ALA, which may be due to its greater selectivity for neoplastic lesions. New strategies, such as cooling and inhalation of a nitrous oxygen/oxygen mixture, are promising treatments to minimize pain. MAL also requires shorter incubation times compared to ALA, according to the FDA-approved treatment regimen. PDT utilizing ALA and MAL is a proven and even first line treatment for AK and superficial BCC. PDT has also demonstrated efficacy in treatment of nodular BCC and SCC in situ, although recurrence rates higher than those of standard surgical treatments preclude first-line use of PDT for these indications. Studies with MAL-PDT for superficial BCC offer acceptable response rates to consider it a reasonable therapeutic option for patients who are not eligible for surgery or do not desire surgery. PDT should be utilized with caution for nodular BCC and Bowen's disease given the risk of recurrence.

New strategies for improving the efficacy and tolerability of PDT are under continuous development. Although several classes of novel photosensitizers have been proposed, they seem to be of no advantage regarding the overall efficacy of PDT [109]. Novel delivery systems such as nanoparticles, micelles or liposomes which are promising technologies leading to a better uptake and targeting of photosensitizers may be available in the future.

New indications for PDT including cutaneous infections, inflammatory dermatoses, cutaneous T-cell lymphoma or treatment of skin photo aging are also under investigation.

## Author details

Eleni Papakonstantinou<sup>1\*</sup>, Florian Löhr<sup>2</sup> and Ulrike Raap<sup>2</sup>

\*Address all correspondence to: [papakonstantinou.eleni@mh-hannover.de](mailto:papakonstantinou.eleni@mh-hannover.de)

1 Department of Dermatology and Allergy, Hannover Medical School, Germany

2 Department of Dermatology and Allergy, Klinikum Oldenburg AöR, University of Oldenburg, Germany

## References

- [1] Braathen LR, Szeimies RM, Basset-Seguin N, Bissonnette R, Foley P, Pariser D, et al. Guidelines on the use of photodynamic therapy for nonmelanoma skin cancer: An international consensus. *Journal of the American Academy of Dermatology*. 2007 Jan;**56**(1):125-143
- [2] Lehmann P. Methyl aminolaevulinate-photodynamic therapy: A review of clinical trials in the treatment of actinic keratoses and nonmelanoma skin cancer. *The British Journal of Dermatology*. 2007 May;**156**(5):793-801
- [3] Lam M, Oleinick NL, Nieminen AL. Photodynamic therapy-induced apoptosis in epidermoid carcinoma cells—Reactive oxygen species and mitochondrial inner membrane permeabilization. *The Journal of Biological Chemistry*. 2001 Dec 14;**276**(50):47379-47386
- [4] Henderson BW, Dougherty TJ. How does photodynamic therapy work. *Photochemistry and Photobiology*. 1992 Jan;**55**(1):145-157
- [5] Oleinick N, Morris RL, Belichenko T. The role of apoptosis in response to photodynamic therapy: What, where, why, and how. *Photochemical & Photobiological Sciences*. 2002 Jan;**1**(1):1-21
- [6] Dougherty TJ, Gomer GJ, Henderson BW, Jori G, Kessel D, Korbek M, et al. Photodynamic therapy. *Journal of the National Cancer Institute*. 1998 Jun 17;**90**(12):889-905
- [7] Fritsch C, Homey B, Stahl W, Lehmann P, Ruzicka T, Sies H. Preferential relative porphyrin enrichment in solar keratoses upon topical application of d-aminolevulinic acid methylester. *Photochemistry and Photobiology*. 1998 Aug;**68**(2):218-221

- [8] Ericson MB, Wennberg AM, Larkö O. Review of photodynamic therapy in actinic keratosis and basal cell carcinoma. *Therapeutics and Clinical Risk Management*. 2008 Feb;**4**(1):1-9
- [9] Morton CA, Brown SB, Collins S, Ibbotson S, Jenkinson H, Kurwa H, et al. Guidelines for topical photodynamic therapy: Report of a workshop of the British Photodermatology Group. *The British Journal of Dermatology*. 2002 Apr;**146**(4):552-567
- [10] Wennberg AM, Larkö O, Lönnroth P, Larson G, Krogstad AL. Delta-aminolevulinic acid in superficial basal cell carcinomas and normal skin—A microdialysis and perfusion study. *Clinical and Experimental Dermatology*. 2000 Jun;**25**(4):317-322
- [11] Kelty CJ, Brown NJ, Reed MW, Ackrovd R. The use of 5-aminolaevulinic acid as a photosensitiser in photodynamic therapy and photodiagnosis. *Photochemical & Photobiological Sciences*. 2002 Mar;**1**(3):158-168
- [12] Ackermann G, Abels C, Bäumler W, Langer S, Landthaler M, Lang E, et al. Simulations on the selectivity of 5-aminolevulinic acid-induced fluorescence in vivo. *Journal of Photochemistry and Photobiology. B*. 1998 Dec;**47**(2-3):121-128
- [13] Tarstedt M, Gillstedt M, Wennberg Larkö AM, Paoli J. Aminolevulinic acid and methyl aminolevulinate equally effective in topical photodynamic therapy for non-melanoma skin cancers. *Journal of the European Academy of Dermatology and Venereology*. 2016 Mar;**30**(3):420-423
- [14] Nester MS, Gold MH, Kauvar AN, Taub AF, Geronemus AR, Ritvo EC, et al. The use of photodynamic therapy in Dermatology: Results of a consensus conference. *Journal of Drugs in Dermatology*. 2006 Feb;**5**(2):140-154
- [15] Braathen LR, Paredes BE, Saksela O, Fritsch C, Gardlo K, Morken T et al. Short incubation with methyl aminolevulinate for photodynamic therapy of actinic keratoses. *Journal of the European Academy of Dermatology and Venereology* 2009 May;**23**(5):550-5
- [16] Patel N, Pera P, Joshi P, Dukh M, Tabaczynski WA, Siters KE, et al. Highly effective dual-function near-infrared (NIR) photosensitizer for fluorescence imaging and photodynamic therapy (PDT) of cancer. *Journal of Medicinal Chemistry*. 2016 Nov 10;**59**(21):9774-9787 Epub 2016 Oct 31
- [17] Baron ED, Malbasa CL, Santo-Domingo D, Fu P, Miller JD, Hanneman KK, et al. Silicon phthalocyanine (Pc 4) photodynamic therapy is a safe modality for cutaneous neoplasms: Results of a phase 1 clinical trial. *Lasers in Surgery and Medicine*. 2010 Dec;**42**(10):728-735
- [18] Boppana NB, Stochai U, Kodiha M, Bielawska A, Bielawski J, Pierce JS, et al. C6-pyridinium ceramide sensitizes SCC17B human head and neck squamous cell carcinoma cells to photodynamic therapy. *Journal of Photochemistry and Photobiology. B*. 2015 Feb;**143**:163-168
- [19] Alexiades-Armenakas MR, Geronemus RG. Laser-mediated photodynamic therapy of actinic keratoses. *Archives of Dermatology*. 2003 Oct;**139**(10):1313-1320
- [20] Szeimies RM, Abels C, Fritsch C, Karrer S, Steinbach P, Bäumler W, et al. Wavelength dependency of photodynamic effects after sensitization with 5-aminolevulinic acid in vitro and in vivo. *The Journal of Investigative Dermatology*. 1995 Nov;**105**(5):672-677



- [21] Brown SB. The role of light in the treatment of nonmelanoma skin cancer using methyl aminolevulinate. *The Journal of Dermatological Treatment*. 2003;**14**(Suppl 3):11-14
- [22] Karrer S, Bäuml W, Abels C, Hohlenleutner U, Landthaler M, Szeimies RM. Long-pulse dye laser for photodynamic therapy: Investigations in vitro and in vivo. *Lasers in Surgery and Medicine*. 1999;**25**(1):51-59
- [23] Babilas P, Schreml S, Landthaler M, Szeimies RM. Photodynamic therapy in dermatology: State-of-the-art. *Photodermatology, Photoimmunology & Photomedicine*. 2010 Jun;**26**(3):118-132
- [24] Issa MC, Manela-Azulay M. Photodynamic therapy: A review of the literature and image documentation. *Anais Brasileiros de Dermatologia*. 2010 Jul-Aug;**85**(4):501-511
- [25] Morton CA. Photodynamic therapy for nonmelanoma skin cancer — And more? *Archives of Dermatology*. 2004 Jan;**140**(1):116-120
- [26] Calzayara-Pinton PG, Venturini M, Sala R. Photodynamic therapy: Update 2006. Part 1: Photochemistry and photobiology. *Journal of the European Academy of Dermatology and Venereology*. 2007 Mar;**21**(3):293-302
- [27] Clark C, Bryden A, Dawe R, Moseley H, Ferguson J, Ibbotson SH. Topical 5-aminolaevulinic acid photodynamic therapy for cutaneous lesions: Outcome and comparison of light sources. *Photodermatology, Photoimmunology & Photomedicine*. 2003 Jun;**19**(3):134-141
- [28] Yang CH, Lee JC, Chen CH, Hui CY, Hong HS, Kuo HW. Photodynamic therapy for bowenoid papulosis using a novel incoherent light-emitting diode device. *The British Journal of Dermatology*. 2003 Dec;**149**(6):1297-1299
- [29] Zeitouni NC, Oseroff AR, Shieh S. Photodynamic therapy for nonmelanoma skin cancers. *Molecular Immunology*. 2003 Jul;**39**(17-18):1133-1136
- [30] Wiegell SR, Haedersal M, Philipsen PA, Eriksen P, Ed E, Wulf CH. Continuous activation of PpIX by daylight is as effective as and less painful than conventional photodynamic therapy for actinic keratoses; a randomized, controlled, single-blinded study. *The British Journal of Dermatology*. 2008 Apr;**158**(4):740-746
- [31] Attili SK, Lesar A, McNeill A, Camacho-Lopez M, Moseley H, Ibbotson S, et al. An open pilot study of ambulatory photodynamic therapy using a wearable low-irradiance organic light-emitting diode light source in the treatment of nonmelanoma skin cancer. *The British Journal of Dermatology*. 2009 Jul;**161**(1):170-173
- [32] Fritsch C, Neumann NJ, Ruzicka T, Lehmann P. Photodiagnostic tests. 3: Fluorescence diagnosis with delta-aminolevulinic acid-induced porphyrins (FDAP) in dermatology. *Hautarzt*. 2000 Jul;**51**(7):528-543 quizz 543-5
- [33] Bäuml W, Abels C, Szeimies RM. Fluorescence diagnosis and photodynamic therapy in dermatology. *Medical Laser Application*. 2003 Jan;**18**(1):170-173
- [34] Vereecken P, Da Costa SM, Steels E, Lathouwer O, Heenen M, De Mey A. Fluorescence diagnosis of face-located basal cell carcinomas: A new dermatological procedure which may help the surgeon. *Acta Chirurgica Belgica*. 2007 Mar-Apr;**107**(2):205-207



- [35] Kleinpenning MM, Wolberink EW, Smits T, Blokx WA, van De Kerkhof PC, van Erp PE et al. Fluorescence diagnosis in actinic keratosis and squamous cell carcinoma. *Photodermatology, Photoimmunology & Photomedicine* 2010 Dec;**26**(6):297-302
- [36] Truchuelo MT, Pérez B, Fernández-Guarino M, Moreno C, Jaén-Olaso P. Fluorescence diagnosis and photodynamic therapy for Bowen's disease treatment. *Journal of the European Academy of Dermatology and Venereology*. 2014 Jan;**28**(1):86-93
- [37] Smits T, Kleinpenning MM, Blokx WA, van de Kerkhof PC, van Erp PE, Gerritsen MA. Fluorescence diagnosis in keratinocytic intraepidermal neoplasias. *Journal of the American Academy of Dermatology* 2007 Nov;**57**(5):824-831
- [38] Morton CA. Methyl aminolevulinate (MetvixH) photodynamic therapy—Practical pearls. *The Journal of Dermatological Treatment*. 2003;**14**(Suppl 3):23-26
- [39] Thissen MR, Schroeter CA, Neumann HA. Photodynamic therapy with delta-aminolaevulinic acid for nodular basal cell carcinomas using a prior debulking technique. *The British Journal of Dermatology*. 2000 Feb;**142**(2):338-339
- [40] Nayak CS. Photodynamic therapy in dermatology. *Indian Journal of Dermatology, Venereology and Leprology*. 2005 May-Jun;**71**(3):155-160
- [41] Szeimies RM, Karrer S, Radakovic-Fijan S, Tanew A, Calzavara-Pinton PG, Zane C, et al. Photodynamic therapy using topical methyl 5-aminolevulinate compared with cryotherapy for actinic keratosis: A prospective randomized study. *Journal of the American Academy of Dermatology*. 2002 Aug;**47**(2):258-262
- [42] Foley P. Clinical efficacy of methyl aminolevulinate (MetvixH) photodynamic therapy. *The Journal of Dermatological Treatment*. 2003;**14**(Suppl 3):15-22
- [43] Fink C, Uhlmann L, Enk A, Gholam P. Pain management in photodynamic therapy using a nitrous oxide/oxygen mixture: A prospective, within-patient, controlled clinical trial. *Journal of the European Academy of Dermatology and Venereology*. 2017 Jan;**31**(1):70-74
- [44] Wiegell SR, Stender IM, Na R, Wulf HC. Pain associated with photodynamic therapy using 5-aminolevulinic acid or photodynamic therapy for non-melanoma skin cancer 5-aminolevulinic acid methylester on tape-stripped normal skin. *Archives of Dermatology*. 2003 Sep;**139**(9):1173-1177
- [45] Touma D, Yaar M, Whitehead S, Konnikov N, Gilchrest BA. A trial of short incubation, broad-area photodynamic therapy for facial actinic keratoses and diffuse photodamage. *Archives of Dermatology*. 2004 Jan;**140**(1):33-40
- [46] Skiveren J, Haedersdal M, Philipsen PA, Wiegell SR, Wulf HC. Morphine gel 0.3% does not relieve pain during topical photodynamic therapy: A randomized, double-blind, placebo-controlled study. *Acta Dermato-Venereologica*. 2006;**86**(5):409-411
- [47] Wiegell SR, Haedersdal M, Wulf HC. Cold water and pauses in illumination reduces pain during photodynamic therapy: A randomized clinical study. *Acta Dermato-Venereologica*. 2009;**89**(2):145-149

- [48] Pagliaro J, Elliott T, Bulsara M, King C, Vinciullo C. Cold air analgesia in photodynamic therapy of basal cell carcinomas and Bowen's disease: An effective addition to treatment: A pilot study. *Dermatologic Surgery*. 2004 Jan;**30**(1):63-66
- [49] Kessels JP, Nelemans PJ, Mosterd K, Kelleners-Smeets NW, Krekels GA, Ostertag JU. Laser-mediated photodynamic therapy: An alternative treatment for actinic keratosis. *Acta Dermato-Venereologica*. 2016 Mar;**96**(3):351-354
- [50] Lee PK, Kloser A. Current methods for photodynamic therapy in the US: Comparison of MAL/PDT and ALA/PDT. *Journal of Drugs in Dermatology*. 2013 Aug;**12**(8):925-930
- [51] Tschen EH, Wong DH, Pariser DH, Dunlap FE, Houlihan A, Ferdon MB. Photodynamic therapy using aminolaevulinic acid for patients with nonhyperkeratotic actinic keratoses of the face and scalp: Phase IV multicentre clinical trial with 12-month follow up. *The British Journal of Dermatology*. 2006 Dec;**155**(6):1262-1269
- [52] Wulf HC, Philipsen P. Allergic contact dermatitis to 5-aminolaevulinic acid methylester but not 5-aminolaevulinic acid after photodynamic therapy. *The British Journal of Dermatology*. 2004 Jan;**150**(1):143-145
- [53] Morton CA, Burden AD. Treatment of multiple scalp basal cell carcinomas by photodynamic therapy. *Clinical and Experimental Dermatology*. 2001 Jan;**26**(1):33-36
- [54] Guillen C, Sanmartin O, Escudero A, Bottela-Estrada R, Svila A, Castejon P. Photodynamic therapy for in situ squamous cell carcinoma on chronic radiation dermatitis after photosensitization with 5-aminolevulinic acid. *Journal of the European Academy of Dermatology and Venereology*. 2000 Jul;**14**(4):298-300
- [55] Ko DY, Jeon SY, Kim KH, Song KH. Fractional erbium: YAG laser-assisted photodynamic therapy for facial actinic keratoses: A randomized, comparative, prospective study. *Journal of the European Academy of Dermatology and Venereology*. 2014 Nov;**28**(11):1529-1539
- [56] Glogau RG. The risk of progression to invasive disease. *Journal of the American Academy of Dermatology*. 2000 Jan;**42**(1 Pt 2):23-24
- [57] Morton C, Campbell S, Gupta G, Keohane S, Lear J, Zaki I, et al. Intraindividual, right-left comparison of topical methyl aminolaevulinate-photodynamic therapy and cryotherapy in subjects with actinic keratoses: A multicentre, randomized controlled study. *The British Journal of Dermatology*. 2006 Nov;**155**(5):1029-1036
- [58] Lucena RS, Salazar N, Gracia-Cazaña T, Zamarrón A, González S, Juarranz A, et al. Combined treatments with photodynamic therapy for non-melanoma skin cancer. *International Journal of Molecular Sciences*. 2015 Oct 28;**16**(10):25912-25933
- [59] Tarstedt M, Rosdahl I, Berne B, Svanberg K, Wennberg KM. A randomized multicenter study to compare two treatment regimens of topical methyl aminolevulinate (Metvix)-PDT in actinic keratosis of the face and scalp. *Acta Dermato-Venereologica*. 2005;**85**(5):424-428

- [60] Piacquadio DJ, Chen DM, Farber HF, Fowel JB, Glazer SD, Goodman JJ, et al. Photodynamic therapy with aminolevulinic acid topical solution and visible blue light in the treatment of multiple actinic keratoses of the face and scalp. *Archives of Dermatology*. 2004 Jan;**140**(1):41-46
- [61] Hauschild A, Stockfleth E, Popp G, Borrosch F, Brünig H, Dominicus R, et al. Optimization of photodynamic therapy with a novel self-adhesive 5-aminolaevulinic acid patch: Results of two randomized controlled phase III studies. *The British Journal of Dermatology*. 2009 May;**160**(5):1066-1074
- [62] Freeman M, Vinciullo C, Francis D, Spelman L, Nguyen R, Fergin P, et al. A comparison of photodynamic therapy using topical methyl aminolevulinate (Metvix) with single cycle cryotherapy in patients with actinic keratosis: A prospective, randomized study. *The Journal of Dermatological Treatment*. 2003 Jun;**14**(2):99-106
- [63] Kaufmann R, Spelman L, Weightman W, Reifenberger J, Szeimies RM, Verhaeghe E, et al. Multicentre intraindividual randomized trial of topical methyl aminolaevulinate-photodynamic therapy vs. cryotherapy for multiple actinic keratoses on the extremities. *The British Journal of Dermatology*. 2008 May;**158**(5):994-999
- [64] Smith S, Piacquadio D, Morhenn V, Atkin D, Fitzpatrick R. Short incubation PDT versus 5-FU in treating actinic keratoses. *Journal of Drugs in Dermatology*. 2003 Dec;**2**(6):629-635
- [65] Tanghetti EA, Hamann C, Tanghetti MA. Controlled comparison study of topical fluorouracil 5% cream pre-treatment of aminolevulinic acid/photodynamic therapy for actinic keratosis. *Journal of Drugs in Dermatology*. 2015 Nov;**14**(11):1241-1244
- [66] Hadley J, Tristani-Firouzi P, Hull C, Florell S, Cotter M, Hadley M. Results of an investigator-initiated single-blind split-face comparison of photodynamic therapy and 5% imiquimod cream for the treatment of actinic keratoses. *Dermatologic Surgery*. 2012 May;**38**(5):722-727
- [67] Tanaka N, Ohata C, Ishii N, Imamura K, Ueda A, Furumura M, et al. Comparative study for the effect of photodynamic therapy, imiquimod immunotherapy and combination of both therapies on 40 lesions of actinic keratosis in Japanese patients. *The Journal of Dermatology*. 2013 Dec;**40**(12):962-967
- [68] Serra-Guillen C, Nagore E, Hueso L, Traves V, Messequer F, Sanmartin O, et al. A randomized pilot comparative study of topical methyl aminolevulinate photodynamic therapy versus imiquimod 5% versus sequential application of both therapies in immunocompetent patients with actinic keratosis: Clinical and histologic outcomes. *Journal of the American Academy of Dermatology*. 2012 Apr;**66**(4):e131-e137
- [69] Scola N, Terras S, Georgas D, Othlinghaus N, Matip R, Pantelaki I, et al. A randomized, half-side comparative study of aminolaevulinate photodynamic therapy vs. CO<sub>2</sub> laser ablation in immunocompetent patients with multiple actinic keratoses. *The British Journal of Dermatology*. 2012 Dec;**167**(6):1366-1373
- [70] Gholam P, Fink C, Bosselmann I, Enk AH. Retrospective analysis evaluating the effect of a keratolytic and physical pretreatment with salicylic acid, urea and curettage on the

efficacy and safety of photodynamic therapy of actinic keratoses with methylaminolaevulinate. *Journal of the European Academy of Dermatology and Venereology*. 2016 Apr; **30**(4):619-623

- [71] Szeimies RM, Hauschild A, Ortland C, Moor AC, Stocker M, Surber C. Photodynamic therapy simplified: Nonprepared, moderate-grade actinic keratosis lesions respond equally well to 5-aminolaevulinic acid patch photodynamic therapy as do mild lesions. *The British Journal of Dermatology*. 2015 Nov; **173**(5):1277-1279
- [72] Dirschka T, Radny P, Dominicus R, Mensing H, Brünig H, Jenne L, et al. Photodynamic therapy with BF-200 ALA for the treatment of actinic keratoses: Results of a multicentre, randomized, observer-blind phase III study in comparison with registered methyl-5-aminolaevulinate cream and placebo. *The British Journal of Dermatology*. 2012 Jan; **166**(1):137-146
- [73] De Becker D, Mc Gregor J, Hughes B. Guidelines for the management of actinic keratosis. *The British Journal of Dermatology*. 2007 Feb; **156**(2):222-230
- [74] Serra-Guillen C, Nagore E, Hueso L, Llombart B, Reguena C, Sanmartín O, et al. A randomized comparative study of tolerance and satisfaction in the treatment of actinic keratosis of the face and scalp between 5% imiquimod cream and photodynamic therapy with methyl aminolaevulinate. *The British Journal of Dermatology*. 2011 Feb; **164**(2):429-433
- [75] Fiechter S, Skaria A, Nievergelt H, Anex R, Borradori L, Parmentier L. Facial basal cell carcinomas recurring after photodynamic therapy: A retrospective analysis of histological subtypes. *Dermatology*. 2012; **224**(4):346-351
- [76] Roozeboom MH, Arits AH, Nelemans PJ, Kelleners-Smeets NW. Overall treatment success after treatment of primary superficial basal cell carcinoma: A systematic review and meta-analysis of randomized and nonrandomized trials. *The British Journal of Dermatology*. 2012 Oct; **167**(4):733-756
- [77] Szeimies RM, Ibbotson S, Murrell DF, Rubel D, Frambach Y, De Becker D, et al. A clinical study comparing methyl aminolevulinate photodynamic therapy and surgery in small superficial basal cell carcinoma (8-20 mm), with a 12-month follow-up. *Journal of the European Academy of Dermatology and Venereology*. 2008 Nov; **22**(11):1302-1311
- [78] Lindberg-Larsen R, Sølvsten H, Kragballe K. Evaluation of recurrence after photodynamic therapy with topical methylaminolaevulinate for 157 basal cell carcinomas in 90 patients. *Acta Dermato-Venereologica*. 2012 Mar; **92**(2):144-147
- [79] Roozeboom MH, Aardoom MA, Nelemans PJ, Thissen MR, Kelleners-Smeets NW, Kuijpers DI, et al. Fractionated 5-aminolevulinic acid photodynamic therapy after partial debulking versus surgical excision for nodular basal cell carcinoma: A randomized controlled trial with at least 5-year follow-up. *Journal of the American Academy of Dermatology*. 2013 Aug; **69**(2):280-287
- [80] Kessels J, Hendriks J, Nelemans P, Mosterd K, Kelleners-Smeets N. Two-fold illumination in topical 5-aminolevulinic acid (ALA)-mediated photodynamic therapy (PDT) for



- superficial basal cell carcinoma (sBCC): A retrospective case series and cohort study. *Journal of the American Academy of Dermatology*. 2016 May;**74**(5):899-906
- [81] Cosgarea R, Susan M, Crisan M, Senila S. Photodynamic therapy using topical 5-aminolaevulinic acid vs. surgery for basal cell carcinoma. *Journal of the European Academy of Dermatology and Venereology*. 2013 Aug;**27**(8):980-984
- [82] Rhodes LE, de Rie M, Enstrom Y, Groves R, Morken T, Goulden V et al. Photodynamic therapy using topical methyl aminolevulinate vs. surgery for nodular basal cell carcinoma: Results of a multicenter randomized prospective trial. *Archives of Dermatology* 2004 Jan;**140**(1):17-23
- [83] Zou Y, Zhao Y, Yu J, Luo X, Han J, Ye Z, et al. Photodynamic therapy versus surgical excision to basal cell carcinoma: Meta-analysis. *Journal of Cosmetic Dermatology*. 2016 Dec;**15**(4):374-382
- [84] Vinciullo C, Elliott T, Francis D, Gebauer K, Spelman L, Nguyen R, et al. Photodynamic therapy with topical methyl aminolaevulinate for "difficult-to-treat" basal cell carcinoma. *The British Journal of Dermatology*. 2005 Apr;**152**(4):765-772
- [85] Basset-Seguin N, Ibbotson SH, Emtestam L, Tarstedt M, Morton C, Maroti M, et al. Topical methyl aminolaevulinate photodynamic therapy versus cryotherapy for superficial basal cell carcinoma: A 5 year randomized trial. *European Journal of Dermatology*. 2008 Sep-Oct;**18**(5):547-553
- [86] Roozeboom MH, Arits AH, Mosterd K, Sommer A, Essers BA, de Rooij MJ. Three-year follow-up results of photodynamic therapy vs. imiquimod vs. fluorouracil for treatment of superficial basal cell carcinoma: A single-blind, noninferiority, randomized controlled trial. *The Journal of Investigative Dermatology* 2016 Aug;**136**(8):1568-1574
- [87] Rhodes LE, De Rie MA, Leifsdottir R, RC Y, Bachmann I, Goulden V, et al. Five-year follow-up of a randomized, prospective trial of topical methyl aminolevulinate photodynamic therapy vs surgery for nodular basal cell carcinoma. *Archives of Dermatology*. 2007 Sep;**143**(9):1131-1136
- [88] Mosterd K, Thissen M, Nelemans P, Kelleners-Smeets NW, Janssen R, Broekhof K, et al. Fractionated 5-aminolaevulinic acid-photodynamic therapy vs. surgical excision in the treatment of nodular basal cell carcinoma: Results of a randomized controlled trial. *The British Journal of Dermatology*. 2008 Sep;**159**(4):864-870
- [89] Christensen E, Mørk C, Skogvoll E. High and sustained efficacy after two sessions of topical 5-aminolaevulinic acid photodynamic therapy for basal cell carcinoma: A prospective, clinical and histological 10-year follow-up study. *The British Journal of Dermatology*. 2012 Jun;**166**(6):1342-1348
- [90] Foley P, Freeman M, Menter A, Siller G, El-Azhary RA, Gebauer K, et al. Photodynamic therapy with methyl aminolevulinate for primary nodular basal cell carcinoma: Results of two randomized studies. *International Journal of Dermatology*. 2009 Nov;**48**(11):1236-1245



- [91] Gerritsen MJ, Smits T, Kleinpenning MM, van de Kerkhof PC, van Erp PE. Pretreatment to enhance protoporphyrin IX accumulation in photodynamic therapy. *Dermatology* 2009;**218**(3):193-202
- [92] Angel Rodríguez-Prieto MA, González-Sixto B, Pérez-Bustillo A, Alonso-Alonso T, Ortega-Valín L, Martínez-Valderrabano V, et al. Photodynamic therapy with intralesional photosensitizer and laser beam application: An alternative treatment for nodular basal cell carcinoma. *Journal of the American Academy of Dermatology*. 2012 Oct;**67**(4):e134-e136
- [93] Kuijpers DI, Smeets NW, Krekels GA, Thissen MR. Photodynamic therapy as adjuvant treatment of extensive basal cell carcinoma treated with Mohs micrographic surgery. *Dermatologic Surgery*. 2004 May;**30**(5):794-798
- [94] Al-Niajmi F, Sheth N, Kurwa HA, Mallipeddi R. Photodynamic therapy followed by mohs micrographic surgery compared to mohs micrographic surgery alone for the treatment of basal cell carcinoma: Results of a pilot single-blinded randomised controlled trial. *Journal of Cutaneous and Aesthetic Surgery*. 2015 Apr-Jun;**8**(2):88-91
- [95] Loncaster J, Swindell R, Slevin F, Sheridan L, Allan D, Allan E. Efficacy of photodynamic therapy as a treatment for Gorlin syndrome-related basal cell carcinomas. *Clinical Oncology (Royal College of Radiologists)*. 2009 Aug;**21**(6):502-508
- [96] Pauwels C, Mazereeuw-Hautier J, Basset-Sequin N, Livideanu C, Viraben R, Paul C, et al. Topical methyl aminolevulinate photodynamic therapy for management of basal cell carcinomas in patients with basal cell nevus syndrome improves patient's satisfaction and reduces the need for surgical procedures. *Journal of the European Academy of Dermatology and Venereology*. 2011 Jul;**25**(7):861-864
- [97] Telfer N, Colver G, Morton C. Guidelines for the management of basal cell carcinoma. *The British Journal of Dermatology*. 2008 Jul;**159**(1):35-48
- [98] Morton CA, Szeimies RM, Sidoroff A, Braathen LR. European guidelines for topical photodynamic therapy part 1: Treatment delivery and current indications actinic keratoses, Bowen's disease, basal cell carcinoma. *Journal of the European Academy of Dermatology and Venereology*. 2013 May;**27**(5):536-544
- [99] Morton CA. Methyl aminolevulinate: Actinic keratoses and Bowen's disease. *Dermatologic Clinics*. 2007 Jan;**25**(1):81-87
- [100] Calzavara-Pinton P, Venturini M, Sala R, Capezzea R, Parrinello G, Specchia C. Methylaminolevulinatebased photodynamic therapy of Bowen's disease and squamous cell carcinoma. *The British Journal of Dermatology*. 2008 Jul;**159**(1):137-144
- [101] López N, Meyer-Gonzalez T, Herrera-Acosta E, Bosch R, Castillo R, Herrera E. Photodynamic therapy in the treatment of extensive Bowen's disease. *The Journal of Dermatological Treatment*. 2012 Dec;**23**(6):428-430
- [102] Truchuelo M, Fernandez-Guarino M, Fleta B, Alcantara J, Jaen P. Effectiveness of photodynamic therapy in Bowen's disease: An observational and descriptive study in 51 lesions. *Journal of the European Academy of Dermatology and Venereology*. 2012 Jul;**26**(7):868-874

- [103] Morton C, Horn M, Leman J, Tack B, Bedane C, Tjioe M, et al. Comparison of topical methyl aminolevulinate photodynamic therapy with cryotherapy or fluorouracil for treatment of squamous cell carcinoma in situ—Results of a multicenter randomized trial. *Archives of Dermatology*. 2006 Jun;**142**(6):729-735
- [104] Salim A, Leman JA, McColl JH, Chapman R, Morton CA. Randomized comparison of photodynamic therapy with topical 5-fluorouracil in Bowen's disease. *The British Journal of Dermatology*. 2003 Mar;**148**(3):539-543
- [105] Cox N, Eedy D, Morton C. Guidelines for management of Bowen's disease: 2006 update. *The British Journal of Dermatology*. 2007 Jan;**156**(1):11-21
- [106] Gilaberte Y, Milla L, Salazar N, Vera-Alvarez J, Kourani O, Damian A, et al. Cellular Intrinsic factors involved in the resistance of squamous cell carcinoma to photodynamic therapy. *The Journal of Investigative Dermatology*. 2014 Sep;**134**(9):2428-2437
- [107] Willey A, Mehta S, Lee PK. Reduction in the incidence of squamous cell carcinoma in solid organ transplant recipients treated with cyclic photodynamic therapy. *Dermatologic Surgery*. 2010 May;**36**(5):652-658
- [108] Wennberg AM, Stengquist B, Stockfleth E, Keohane S, Lear JT, Jemec G, et al. Photodynamic therapy with methyl aminolevulinate for prevention of new skin lesions in transplant recipients: A randomized study. *Transplantation*. 2008 Aug 15;**86**(3):423-429
- [109] Neittaanmaki-Perttu N, Gronroos M, Karppinen TT, Tani TT, Snellmann E. Hexyl-5-aminolaevulinate 0.2% vs. methyl-5-aminolaevulinate 16% daylight photodynamic therapy for treatment of actinic keratoses: Results of a randomized double-blinded pilot trial. *The British Journal of Dermatology*. 2016 Feb;**174**(2):427-429