

We are IntechOpen, the world's leading publisher of Open Access books Built by scientists, for scientists

6,900

Open access books available

185,000

International authors and editors

200M

Downloads

Our authors are among the

154

Countries delivered to

TOP 1%

most cited scientists

12.2%

Contributors from top 500 universities



WEB OF SCIENCE™

Selection of our books indexed in the Book Citation Index
in Web of Science™ Core Collection (BKCI)

Interested in publishing with us?
Contact book.department@intechopen.com

Numbers displayed above are based on latest data collected.
For more information visit www.intechopen.com



Surgical Approaches in Shoulder Arthroplasty

Brian W. Sager and Michael Khazzam

Additional information is available at the end of the chapter

<http://dx.doi.org/10.5772/intechopen.70363>

Abstract

Shoulder arthroplasty is a complex procedure that is becoming increasingly more utilized throughout the world. Due to the numerous static and dynamic stabilizers of the glenohumeral joint, along with the relative proximity to vital neurovascular structures, great care must be taken to access the joint in a safe and effective manner. To date, there are two well-described approaches utilized in shoulder arthroplasty: the deltopectoral approach and the anterosuperior approach. Both of these approaches are effective in accessing the glenohumeral joint; however, due to their anatomic location, they both have distinct advantages and disadvantages. The aim of this book chapter is to describe the methodology for approaching the glenohumeral joint through each of these approaches, as well as to discuss the advantages and disadvantages of utilizing each. In addition, we aim to discuss the various methodologies for closing these wounds and, briefly, to discuss the other approaches described in the orthopedic literature.

Keywords: shoulder, arthroplasty, approaches, deltopectoral, anterosuperior

1. Introduction

Shoulder arthroplasty is becoming an increasingly popular procedure performed for a variety of problems. It has been utilized with great success for advanced degenerative and traumatic conditions of the shoulder [1–5]. Because the shoulder joint is surrounded by vital structures including muscles, nerves, and blood vessels, great care must be taken to ensure safe but adequate exposure to the glenohumeral joint when performing shoulder arthroplasty. To date, the deltopectoral approach [6] and the anterosuperior lateral approach [7] are the two main approaches that have been well described in the literature for access to the glenohumeral joint for shoulder arthroplasty. Each approach offers distinct advantages and disadvantages with

regard to glenoid exposure as well as technical challenges for component implantation. The aim of this chapter is to describe these two different approaches to the glenohumeral joint, the indications for use, and the advantages of each.

2. Positioning and draping

The semirecumbent, or beach-chair position, is the optimum position for open approaches to glenohumeral joint. It allows improved orientation for the surgeon, optimal rotational control of the arm, and allows for gravity traction on both the glenohumeral joint and the subacromial space [8]. It is critical that patient positioning allows for stabilization of the scapula to assure proper glenoid orientation. Additionally, equally important is that the patient is placed in a position on the operating table that allows for extension of the shoulder. Failure to recognize this is one of the most commonly made mistakes that can result in difficulty in exposure for both delivery of the proximal humerus out of the surgical wound and adequate exposure of the glenoid (**Figure 1**).

To begin, the patient should be transferred to the operating table and placed into the supine position for intubation. After successful induction of general anesthesia, the patient should be appropriately positioned on the table while supine in order to allow for the safest and easiest transition to the beach-chair position. While the patient is being elevated into position, the anesthesiologist should maintain cervical support while monitoring the airway. The head support should then be elevated to fit the patient's occiput and secured in place. Care must be taken to ensure that the patient's cervical spine remains in a neutral position as anesthesia literature has shown evidence of cerebrovascular and airway incidents that are felt to be caused by inappropriate cervical positioning and subsequent kinking of the carotid artery or trachea [9, 10]. The head should then be secured to the head support in a secure fashion and the endotracheal

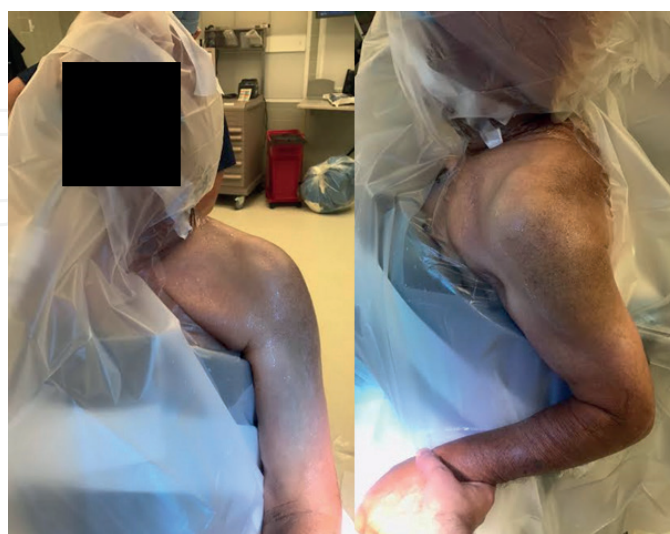

Figure 1. Appropriate positioning and preparation of the shoulder. Please note that the operative shoulder is placed off the edge of the table to allow for extension of the shoulder during the procedure.

tube should be positioned toward the nonoperative side. A pre-scrub with chlorhexidine, alcohol, and/or hydrogen peroxide may then be performed. Finally, a sterile skin preparation with chlorhexidine may be applied prior to final draping. The final draping should consist of down sheets to cover the head and lower extremities with split drapes or a specialized shoulder drape may be used to isolate the operative shoulder. The distal extremity can be placed in a stockinette and covered with a coban wrap, if preferred. An iodine-impregnated plastic drape or any other sterile adhesive dressing may be used to ensure that the edges of the drape adhere to the skin, ensuring a sterile field through the duration of the case. Prior to skin incision, it is important to administer appropriate antibiotics. Typically, this involves a second-generation cephalosporin such as cefazolin or, if the patient has an allergy to penicillin, clindamycin may be substituted. If preoperative testing indicates that the patient is colonized with methicillin-resistant *Staphylococcus aureus* (MRSA), studies show an increased risk of surgical-site infection [11]. In these situations, it is recommended either to decolonize the patient before the surgery or to give a one-time dose of vancomycin [12]. In addition to antibiotics, pre-incision intravenous administration of tranexamic acid has been shown in multiple studies to decrease intraoperative blood loss [13, 14]. At this point, skin incision is ready to be made.

3. Deltopectoral approach

The deltopectoral approach is an anterior approach to the shoulder that utilizes the plane between the deltoid and the pectoralis major muscles. It utilizes an internervous plane between the axillary nerve and the medial and lateral pectoral nerves. It is a robust approach to the shoulder as it has been used for fixation of proximal humerus fractures, reconstruction for shoulder instability, access to the glenohumeral joint in the setting of a septic shoulder, and others [15, 16]. When accessing the glenohumeral joint from the deltopectoral approach, the subscapularis tendon lies directly anterior to the joint capsule. It must be released to access the joint and there are a variety of methods for doing so which will be described in this chapter [17–19].

3.1. Superficial dissection

The surgeon should begin by palpating the bony landmarks around the shoulder, including the acromion, the clavicle, and the coracoid process. An 8–10-cm incision should be marked out, extending from the lateral margin of the coracoid process and extending down the deltopectoral groove toward the deltoid tuberosity. A scalpel should be used to carry the incision through the skin and the dermal layer. Electrocautery can then be used to address any bleeding in the subcutaneous layer. Dissection can continue through the subcutaneous tissue until the fascia overlying the deltoid and the pectoralis muscles is reached. At this point, careful dissection should be used to identify the interval between these muscles. The cephalic vein may be visualized running in the deltopectoral groove. If it is not evident, often times, a stripe of fat overlying the cephalic vein may be identified and used as a helpful marker for identifying the interval (**Figure 2**). The vein should be freed from the surrounding structures and retracted either medially or laterally, depending on surgeon preference. An anatomic study was performed on 40 cadaveric specimens with latex injection of the cephalic vein.

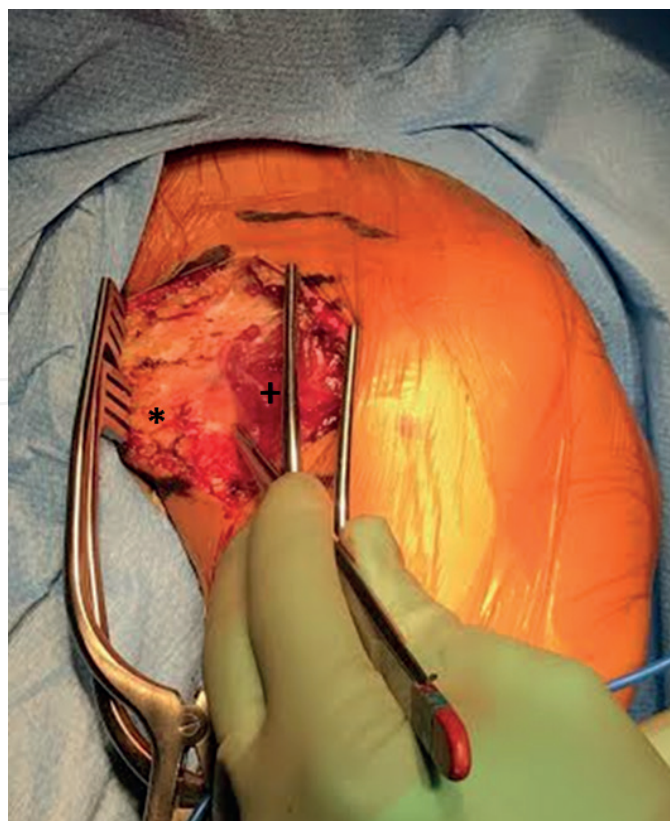


Figure 2. Deltopectoral interval as demarcated by the stripe of fat overlying the cephalic vein. The pectoralis major is identified by the *, while the deltoid is marked by the +.

The authors found more branches from the cephalic vein on the deltoid side, allowing them to conclude that lateral retraction may be more efficacious in preventing bleeding [20]. Once the vein has been retracted, blunt dissection can be used to identify the undersurface of both muscle bellies. A kobel retractor can then be used with one blade under each muscle belly, allowing exposure of the clavipectoral fascia and conjoined tendons of the short head of the biceps and the coracobrachialis (**Figure 3**). Once the fascia is divided in line with the incision, it is pivotal to identify the axillary nerve as it courses near the inferior border of the subscapularis tendon. The surgeon should gently palpate medially over the musculotendinous junction and feel for the axillary nerve. Once found, the nerve should be protected with retractors through the duration of the case. The nerve will then travel posteriorly as it passes inferior to the glenoid where it exits the quadrangular space along with the posterior circumflex humeral vessels. A kobel retractor should be utilized to retract the conjoined tendon medially, exposing the subscapularis tendon over the anterior aspect of the glenohumeral joint. Care must be taken to avoid excessive retraction of the conjoined tendon to avoid a neuropraxia of the musculocutaneous nerve [21].

3.2. Handling of the subscapularis

In order to access the glenohumeral joint capsule, the subscapularis tendon must be mobilized and retracted from the operative field. In the literature, three methods for releasing the

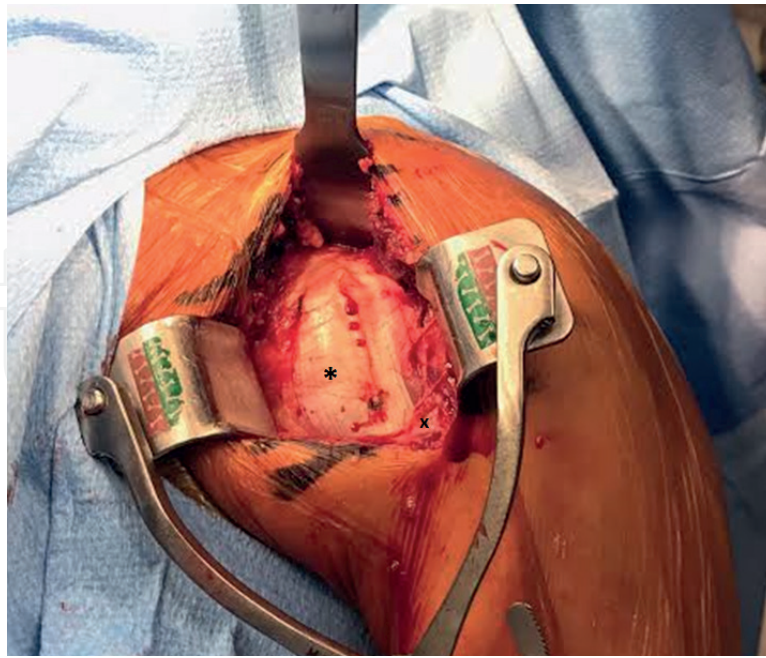


Figure 3. After splitting the deltpectoral interval, the conjoint tendon of the coracobrachialis and the short head of the biceps can be visualized, marked by the *. The pectoralis major tendon is marked with an X.

subscapularis have been described: a tenotomy [19], peeling the tendon off the lesser tuberosity [18], or an osteotomy of the lesser tuberosity [22]. Each of the methods will be described and compared in this chapter. The methods for repair for each of these procedures will be described in the closure section.

3.2.1. *Subscapularis tenotomy*

When preparing to tenotomize the subscapularis tendon, it is important to identify the superior and inferior borders of the tendon. The arm should be held in adduction and external rotation as it tensions the subscapularis tendon and moves the tenotomy site further away from the axillary nerve. The tenotomy should be made approximately 1 cm medial to the subscapularis insertion on the lesser tuberosity of the humerus. This is typically the location of the anatomic neck of the humerus. It is important to leave a small cuff of subscapularis tendon on the lesser tuberosity to which to repair the tendon during closure. In addition, when releasing the inferior portion of the subscapularis, it is necessary to identify and cauterize the anterior humeral circumflex artery and the two accompanying veins in order to prevent retraction and subsequent bleeding. When performing the tenotomy, it can be helpful to place two large-caliber, braided sutures in the medial aspect of the tendon in order to hold tension during the tenotomy and to help during repair of the tenotomy. When performing a tenotomy for shoulder arthroplasty, the tenotomy and subsequent capsulotomy may be performed simultaneously by releasing the deeper tissues and continuing the dissection along the neck of the humerus. If this method is chosen, it is very important to place a blunt retractor between your dissection and the axillary nerve, coursing inferior to the glenoid, in order to prevent iatrogenic injury (**Figure 4**). Alternatively, the subscapularis may be released

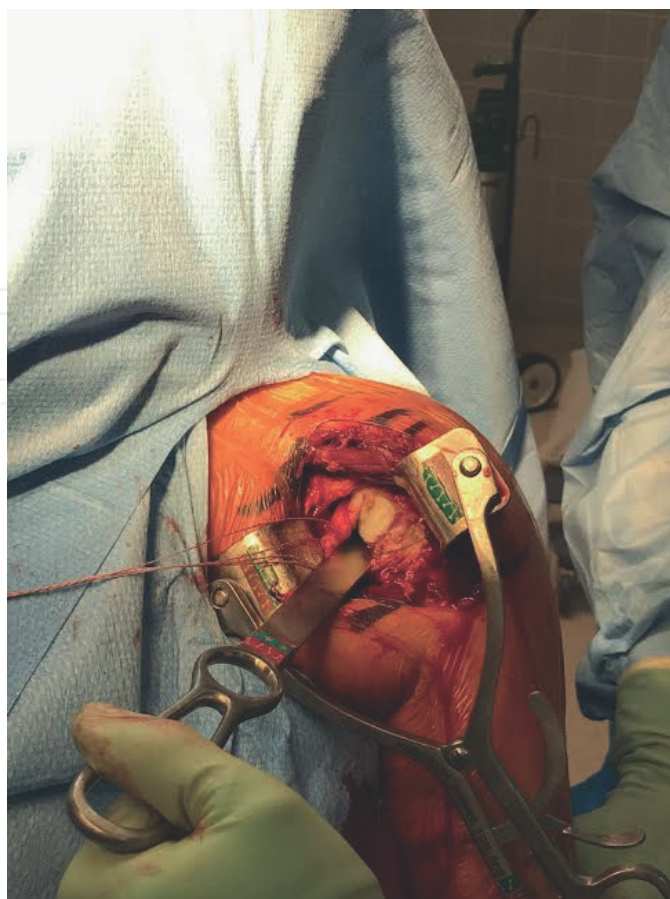


Figure 4. Subscapularis tendon after tenotomy. Note the stay sutures placed in the medial limb of the subscapularis tendon. Also, please note the placement of the Darrach retractor at the inferomedial border of the subscapularis protecting the axillary nerve.

from the anterior capsule prior to arthrotomy, but this method provides less robust tissue for later repair and may lead to subscapularis failure. This approach is the easiest and quickest to perform and repair of all the listed methods. It has been associated with good long-term outcomes [23]. While tendon-to-tendon healing is a reliable means of healing, data in the literature are mixed in regard to maintenance of subscapularis repair with some studies showing excellent healing rates [24] and others showing attenuation or ruptures being common [25]. One disadvantage to this method is the inability to medialize the insertion of the subscapularis tendon or the potential for shortening the tendon during repair causing limits in postoperative external rotation.

3.2.2. *Subscapularis peel*

Another method of releasing the subscapularis tendon is the subscapularis peel. Rather than releasing the tendon through a division within the substance of the tendon, the subscapularis is elevated in its entirety off of its insertion on the lesser tuberosity. After the subscapularis has been released from the lesser tuberosity, dissection should proceed as described earlier. The major advantage of the subscapularis peel is that it allows for medialization of

the insertion of the subscapularis tendon [26]. In addition, peeling the subscapularis off the humerus will allow for maximal surface area for bony healing to occur. The biggest drawback of this procedure is the need for tendon-to-bone healing to occur in order to maintain subscapularis function, which is, generally, felt to be less reliable than tendon-to-tendon or bone-to-bone. However, the literature does vary as there are studies showing excellent healing rates in patients undergoing a subscapularis peel [27]. In addition, the repair requires violating the cortex, thus weakening the proximal humerus.

3.2.3. *Lesser tuberosity osteotomy*

Lastly, the insertion of the subscapularis tendon, the lesser tuberosity, may be osteotomized and retracted without disrupting the tendon itself. Initially, the long head of the biceps tendon can be released and subsequently tenodesed to the upper margin of the pectoralis major tendon. Once the biceps tendon is out of the way, the lesser tuberosity may be visualized in its entirety. The arm should be held in adduction and internal rotation and an osteotome or oscillating saw should be used to perform the osteotomy from the medial aspect of the bicipital groove to the bone-cartilage interface at the anatomic neck. After the lesser tuberosity has been osteomized, freeing the remainder of the subscapularis should proceed as described in the tenotomy section. The lesser tuberosity osteotomy was originally introduced to provide a method of repairing the subscapularis which relied on bone-to-bone healing and did not violate the tendon itself. Healing rates have been shown to be excellent for this method [17, 22]. In addition, medialization of the tendon remains possible with this procedure. The disadvantages of this procedure include difficulty and timeliness of procedure, as well as the potential for iatrogenic fracture or nonunion due to violation of the cortical bone.

3.2.4. *Comparisons*

There have been several studies in the literature comparing the outcomes, biomechanics, and healing potential of the subscapularis tendon after the above procedures [25, 27–30]. Two cadaver biomechanical studies evaluated the failure rates of the above three methods of repair. One showed improved failure rates for both the subscapularis tenotomy and lesser tuberosity osteotomy [29]. Another showed no significant difference between the three methods [30]. Similarly, a biomechanical study comparing lesser tuberosity osteotomy to tenotomy showed no significant difference in load to failure; however, it did show that the tenotomy group had less displacement during repetitive loading [28]. Clinical comparisons between the groups also have mixed outcomes. A randomized controlled trial comparing subscapularis strength and functional outcomes between lesser tuberosity osteotomy versus subscapularis peel showed no significant difference at 2 years [27]. On the contrary, a retrospective study comparing lesser tuberosity osteotomy versus subscapularis tenotomy at an average of 33 months showed improved clinical outcomes and lower rates of subscapularis tears in the osteotomy group [25]. Because of the large amount of conflicting literature, it is likely that the most important factor regarding handling of the subscapularis is surgeon preference and experience. Great care should be taken to ensure an adequate repair while maintaining appropriate tendon length.

3.3. Humeral exposure

As stated earlier, when exposing the humerus after a subscapularis tenotomy, the subscapularis tendon and anterior shoulder capsule may be released as a single unit. However, when performing a subscapularis peel or a lesser tuberosity osteotomy, the subscapularis must be separated from the anterior capsule. This may be done by placing a blunt elevator between the two structures and then using a 15 blade to complete the dissection. Once the capsule has been isolated from the subscapularis, a retractor should be placed at the inferior margin of the glenoid to protect the axillary nerve. A capsulotomy may then be performed with sharp dissection or electrocautery extending along the anatomic neck of the humerus, continuing inferior down the humerus. It is important to dissect along the humerus to avoid damaging the nearby neurovascular structures. It is critical to release the capsule off of the neck of the humerus until the latissimus dorsi tendon is visualized as it wraps around the humerus. This provides not only assurance that complete visualization of the anatomic neck of the humerus and accompanying osteophytes is attained but also aids in glenoid visualization. The exposed osteophytes around the humerus should then be removed using a rongeur. Once the humerus has been exposed, a deltoid retractor can be placed posterior to the head to facilitate exposure of the head. The arm should be adducted, extended, and externally rotated in order to dislocate the head and deliver it into the surgical site (**Figure 5**). A Hohmann retractor may be placed on the calcar and a Darrach should be placed medially to protect the soft tissues, specifically the rotator cuff, during the humeral head cut. Depending on the implant system being utilized, an intramedullary or extramedullary cutting guide may be used to help guide your humeral head cut. If performing the cut freehand, the cut should be made along the anatomic neck of the humerus with care taken to avoid violating the supraspinatus insertion on the greater tuberosity. The angle of the cut should match the neck-shaft angle of the implant if the implant is a fixed angle device. Most implants will have a head-neck angle of around 130–140° [31]. After resection, the head should not be removed from the field as it may be useful in deciding implant size and can be used as a source of bone graft if needed. The timing of humeral head resection is typically dictated by surgeon preference and implant system constraints.

3.4. Glenoid exposure

After the humeral head has been cut, a Fukuda, or a Bankart, retractor should be placed on the posterior glenoid neck and used to retract the humeral shaft posteriorly and inferiorly, out of the operative field. A double-pronged retractor can be placed on the anterior glenoid neck, and most importantly a Hohmann or a Darrach retractor can be placed along the inferior glenoid neck to protect the axillary nerve at all times during the glenoid preparation. Anatomic studies have shown that the axillary nerve can range from 3 to 7 mm inferior to the musculotendinous junction of the subscapularis muscle [32, 33]. After appropriate retractors have been placed, electrocautery or a sharp 15 blade may be used to circumferentially remove the subscapularis, capsule, and labrum to expose the entire periphery of the glenoid. A 360 release of the subscapularis must be performed in order to adequately expose the glenoid. The inferior capsule must be released, carefully protecting the axillary nerve. The dissection should continue down the humeral shaft to the level of the latissimus dorsi. Afterwards, a pair of curved Mayo scissors may be used to release the rotator interval superiorly. This should extend to the level of

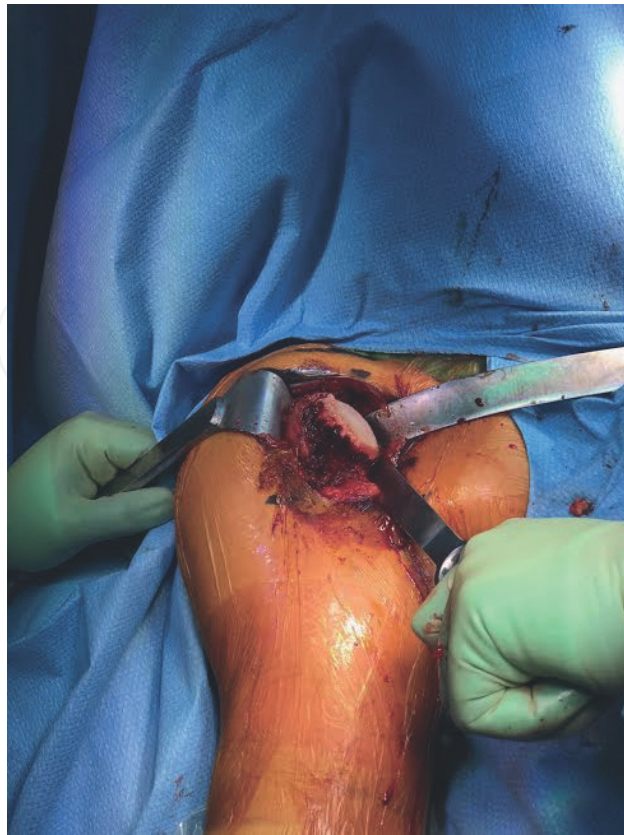

Figure 5. Proximal humeral exposure. The marginal osteophytes have been removed from the subchondral surface using a rongeur. The neck cut should be made along the anatomic neck.

the coracoid base. The anterior capsule should then be dissected from the anterior glenoid with great care taken not to violate the subscapularis tendon (**Figure 6**). Care should be taken to avoid releasing the glenoid capsule beyond the 6 o'clock position due to concerns of posterior instability. If the posterior capsule must be released, it should occur on the humeral side.

3.5. Preparation for implantation

At this point, the humerus and glenoid are exposed and ready to be prepared according to the specific methodology for the desired implant being utilized. As a rule, a guide pin is placed at approximately 11–12 mm above the inferior glenoid rim. This allows for ideal placement of the glenoid component and allows for minimization of scapular notching [34]. Hand reamers are then placed over this guide pin to concentrically ream the glenoid. A drill is then utilized to create a slot in the glenoid for which to place the central peg of the glenoid baseplate. If necessary, screws may be placed around the baseplate. Attention is then turned toward the humerus where the intramedullary canal is found. Sequential reamers are introduced into the humeral canal until adequate fit and fill is achieved. The reamer is removed and serial broaches are introduced until the appropriate size is reached. Trial components may be placed at this time to ensure appropriate range of motion with adequate stability. After implantation of the desired components, the shoulder should again be taken through a range of motion to ensure that the implant is not overstuffed, but also sufficiently stable.

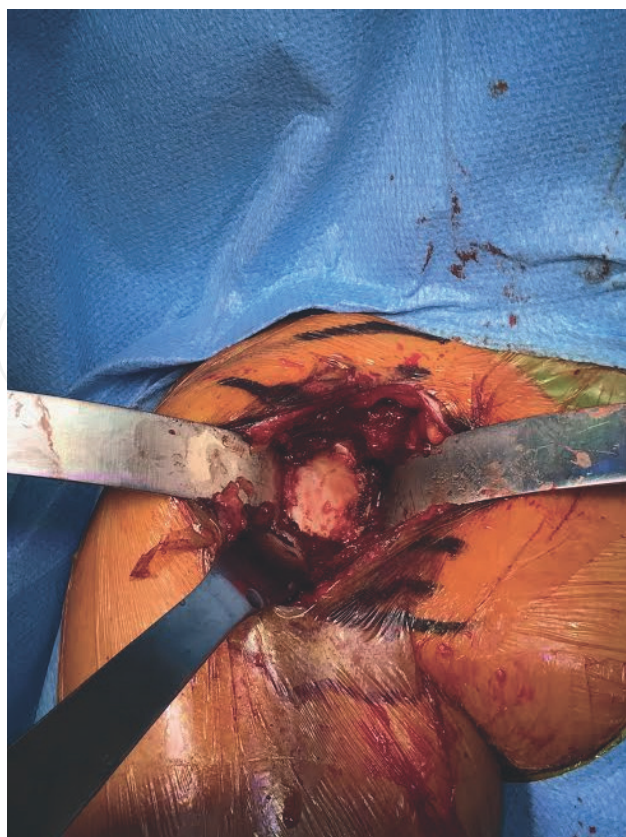

Figure 6. Glenoid exposure. Capsular attachments removed circumferentially around the glenoid.

3.6. Closure

After the components have been appropriately placed and trialed, the wound is ready to be closed. The wound should be irrigated with normal saline. If a significant amount of bleeding was encountered during the surgery, a drain may be placed at this time, if desired. If repairable, the first structure to be repaired is the subscapularis tendon. Depending on how the tendon was released when approaching the shoulder will dictate the method of repair for the tendon. If the subscapularis tenotomy was used, at least three figure-of-eight, large-caliber, braided sutures should be utilized to anatomically repair the tendon. In this particular repair, care should be taken to avoid shortening the tendon as this will result in decreased external rotation function when healed. If the subscapularis was peeled off the lesser tuberosity, the tendon must be repaired using bone tunnels extending from the anatomic neck of the humerus to the lesser tuberosity. Again, heavy, braided, non-absorbable suture should be passed through these drill holes and the subscapularis tendon and tied down in a secure fashion. If the glenohumeral offset was substantially medialized during the procedure, the repair of the insertion of the tendon may be moved more medially to facilitate this. Lastly, if the lesser tuberosity was osteotomized, the surgeon should drill holes in the medial aspect of the bicipital groove. Heavy non-absorbable suture should then be passed around the lesser tuberosity and into the subscapularis tendon. After the lesser tuberosity has been anatomically positioned, it may be secured in place with transosseous sutures. A plate may be placed to augment the repair depending on the preference of the surgeon [26].

After the subscapularis has been securely repaired, the deltopectoral interval may be loosely closed with a running interlocking non-absorbable suture to help identify the interval in future exposure. The subcutaneous layer may be closed in a simple interrupted fashion with either a braided or an unbraided suture depending on surgeon preference. Similarly, the skin may be closed with nylon suture, a running monofilament, staples, or any other acceptable method of skin closure. At this point, a dry dressing or an incisional vacuum should be placed over the wound and the patient should be placed into a sling with an abduction pillow to help keep the arm protected.

3.7. Advantages

The deltopectoral approach is the most commonly used approach to the shoulder-for-shoulder arthroplasty. This is in large part due to the many advantages provided by this approach. This approach is an internervous and intermuscular plane, that is, it utilizes the plane between the deltoid and the pectoralis major muscles. This is important as it preserves the origin of the deltoid and the pectoralis and allows for access beyond the muscles while minimizing the risk of denervation. Furthermore, because the approach is between muscles and not splitting the muscles, less bleeding is observed with this approach. Furthermore, should a fracture arise distal to the stem of the humeral component, it is quite easy to extend the deltopectoral approach into the anterolateral approach to the humerus, utilizing the interval between the brachialis and the brachioradialis. Lastly, approaching the glenohumeral joint from the front allows for easier access to the inferior structures, including the inferior humeral osteophytes and the inferior capsule [35]. Positioning of the glenoid component is also easier with this approach as the inferior portion of the glenoid is more readily available.

3.8. Disadvantages

Though the literature is inconsistent on the matter, many studies have shown that subscapularis-deficient shoulder arthroplasties have higher rates of instability [36, 37]. The deltopectoral approach to the shoulder requires the release of the subscapularis tendon with subsequent repair; however, it is not uncommon for these repairs to fail, leading to a risk of instability in these patients [24, 38]. Furthermore, approaching the glenohumeral joint from the anterior aspect causes difficulty reaching the more posterior structures including the glenoid, capsule, and greater tuberosity. This could be particularly noticeable when performing shoulder arthroplasty for proximal humerus fractures that include a large greater tuberosity fragment. Lynch et al. found that utilizing the deltopectoral approach was an independent risk factor for neurologic complications in total shoulder arthroplasty [39].

4. Anterosuperior approach

The anterosuperior approach to the shoulder was first described by Mackenzie in 1993 [40]. It does not utilize an internervous plane as it requires detachment of the anterior deltoid off the acromion as well as release of the coracoacromial ligament to reach the glenohumeral joint. Though it was initially designed to provide increased exposure of the glenoid for shoulder

arthroplasty, it is also frequently used in the open repair of difficult-to-manage rotator-cuff tears [41], proximal humerus fractures, and even long head of the biceps repair. The previously described protocol for anesthesia induction, positioning, and prepping should be utilized for the anterosuperior approach just as it was for the deltopectoral approach.

4.1. Superficial dissection

After the operative arm has been draped, the surgery should begin with the surgeon palpating the bony landmarks of the shoulder including the anterior and posterior aspects of the acromion, as well as the anterior border of the clavicle and the acromioclavicular joint. An approximately 5–7-cm incision should be drawn on the shoulder in line with the longitudinal axis of the clavicle (**Figure 7**). The incision should start just posterior to the anterolateral corner of the acromion and should be carried down through the skin and the subcutaneous tissue until the fascia overlying the deltoid muscle is reached. Careful hemostasis should be achieved with electrocautery. The surgeon should then identify the raphe between the anterior and middle portions of the deltoid (**Figure 8**). Once identified, the raphe should be split in line with the deltoid fibers for approximately 5 cm from the lateral border of the acromion. Care should be taken not to extend the incision beyond 5 cm from the lateral margin of the acromion in order to minimize the risk of damage to the axillary nerve [42]. A stay suture may be placed in the distal aspect of the deltoid to mark the level of the axillary nerve and to help prevent inadvertent damage during dissection. At several instances throughout the course of the surgery, the stay suture should be checked to ensure the integrity of the suture. If it is ever found to be compromised, it should be removed and replaced.

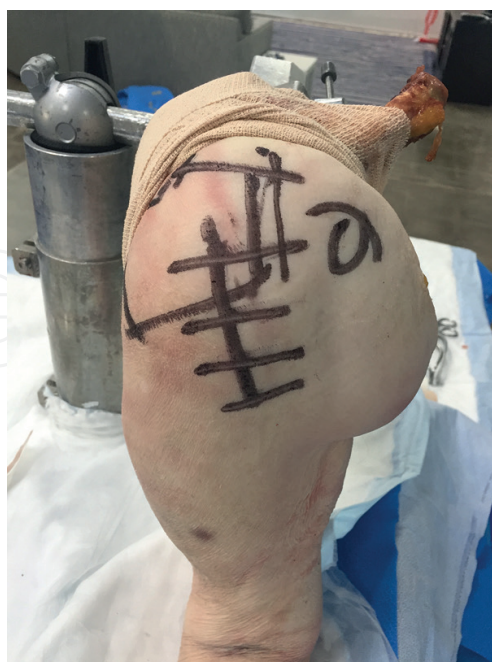

Figure 7. Surface landmarks with incision marked out for the anterosuperior approach. Care should be taken to ensure that the incision is not carried out more than 5 cm below the edge of the acromion to avoid iatrogenic axillary nerve injury. This is a Right shoulder cadaveric specimen.

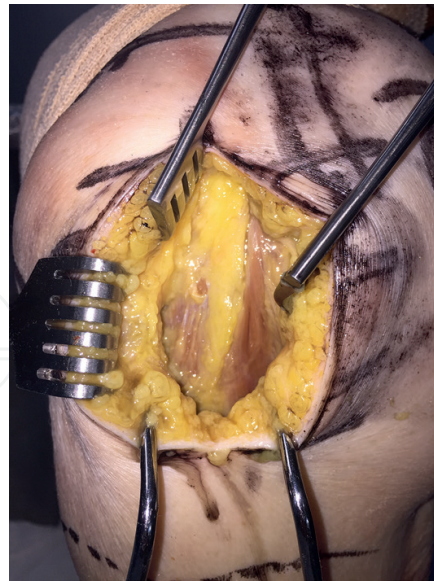


Figure 8. Fat stripe identifying the raphe between the anterior and middle portions of the deltoid.

4.2. Deltoid and coracoacromial ligament handling

At this point, the deltoid separates the surgeon from accessing the glenohumeral joint. The anterosuperior approach to the shoulder mandates the removal of a portion of the deltoid off of the acromion. There are two methods for releasing the anterior deltoid that have been described in the literature. These two methods, acromial osteotomy versus deltoid peel, will be described in this section.

4.2.1. Deltoid peel

The original article by Mackenzie advocated for the removal of approximately 1–2 cm of the deltoid from its origin on the anterior acromion [40]. The deltoid should be reflected in a subperiosteal fashion and care should be taken not to remove more than 2 cm of the deltoid off of the acromion as repairing the deltoid back to the acromion can be difficult. After the deltoid has been retracted out of the way, an acromioplasty of the anterior acromion may be performed to facilitate exposure to the proximal humerus [43]. The coracoacromial ligament may be removed from the undersurface of the acromion using sharp dissection or electrocautery. The acromial branch of the thoracoacromial artery may be encountered deep to the deltoid and should be ligated to prevent retraction and excess bleeding. The subdeltoid bursa can be divided at this time and the long head of the biceps may be identified and then tenotomized at its origin. Peeling the tendon from the acromion requires soft tissue-to-bone healing; however, one recent study showed no changes in axillary nerve or deltoid function 3 months after suture repair of the deltoid back to the acromion [44].

4.2.2. Acromial osteotomy

Rather than peeling the deltoid off the acromion and relying on muscle-to-bone healing, Mole describes an acromial osteotomy to facilitate healing with more robust bone-to-bone healing [7].

Once the dissection has been carried down to the lateral border of the acromion and the deltoid, an osteotome is used to remove a fleck of acromial bone along with the attached deltoid and coracoacromial ligament. This should be retracted, facilitating access now to the glenohumeral joint. Again, if the acromial branch of the thoracoacromial artery is encountered, it should be ligated. If needed, an acromioplasty should be performed in order to better visualize the humerus in preparation for the humeral osteotomy. The subdeltoid bursa should be incised and long head of the biceps tendon should be identified and released at its origin.

4.3. Humeral exposure

After releasing the deltoid and coracoacromial ligament, the humerus is ready to be osteotomized and prepared for implantation. If any question regarding the competency of the subscapularis, supraspinatus, or infraspinatus exists, they may be assessed at this point. In order to visualize the posterior rotator cuff, the arm should be extended and internally rotated to bring the greater tuberosity into the operative field (**Figure 9**). Originally, Mackenzie described a subscapularis tenotomy to allow for anterior dislocation and osteotomy; however, traditionally, the subscapularis has been preserved in this approach. The humeral head should be delivered by subluxating the head anterosuperiorly and the capsular attachments should be removed along the humeral neck. Care should be taken when removing the capsular attachments to cut toward the bone to minimize the risk of damage to surrounding structures. Once the neck is able to be visualized, the humeral head may be cut along the anatomic neck of the humerus with the assistance of implant-specific cutting guides as needed. Again, the excised head should not be removed from the operative field as it may be useful when determining implant size. Once the neck cut has been made, any osteophytes that are observed may be removed using a rongeur or an osteotome. Posterior and inferior osteophytes may be difficult to reach utilizing this approach.

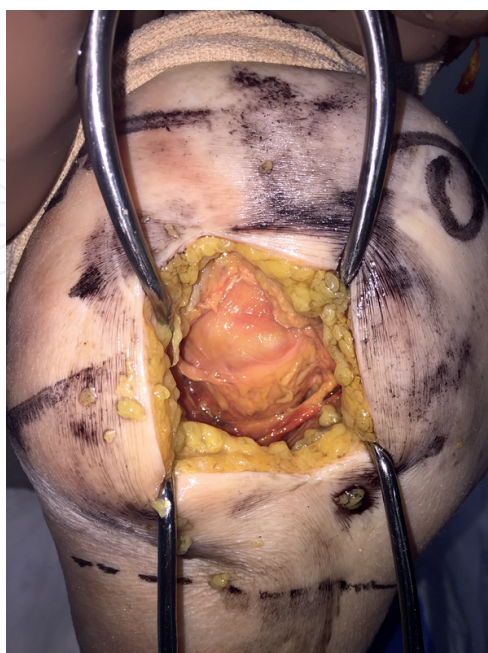


Figure 9. After the deltoid has been peeled off the acromion, the humeral head and rotator-cuff insertion are now visible.

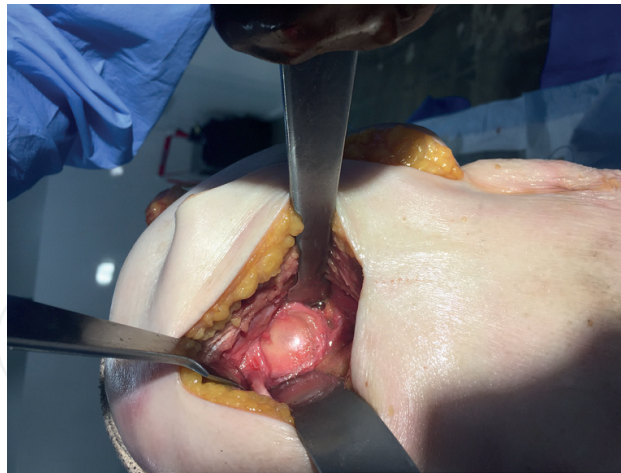

Figure 10. After retraction of the humerus, the anterosuperior approach allows for exceptional glenoid exposure.

4.4. Glenoid exposure

After the humeral neck has been cut, a curved retractor may be placed on the inferior aspect of the glenoid in order to retract the remainder of the humerus posteroinferiorly out of the operative field (**Figure 10**). Another retractor should be placed between the anteroinferior glenoid and the subscapularis tendon in order to protect the axillary nerve as it courses near the undersurface of the glenoid neck. The capsulo-labral attachments should be circumferentially removed from the glenoid periphery using either sharp dissection with a 15 blade or electrocautery.

4.5. Preparation for implantation

Once the humerus and glenoid have been sufficiently exposed, they are ready for preparation. Traditionally, a guide pin is placed in the center aspect of the glenoid in order to establish the axis for the central peg of the glenoid component. Great care should be taken with this particular approach to ensure that adequate inferior tilt of the glenoid component is achieved as the presence of the humerus can significantly interfere with the coronal position of the implant. After the appropriate plane has been achieved, the glenoid is reamed and prepared according to the implant-specific methods. The glenoid component should then be placed, and once it has been, the intramedullary canal of the humerus is identified and subsequently reamed and/or broached according to the protocols for the implant. Trial components are placed and stability and motion should be verified prior to placement of the final components.

4.6. Closure

Once the components have been placed, the shoulder should be reduced and taken through a full range of motion to ensure adequate stability and range of motion. The wound should be irrigated copiously with normal saline and any topical antibiotics should be placed in the wound. If a drain is desired, it should be placed prior to wound closure. The most important aspect of wound closure is the repair of the deltoid muscle back to the acromion. The method for repair of the deltoid back to the acromion will vary slightly based on the method that the deltoid was detached from the acromion.

If the deltoid was peeled subperiosteally off the acromion, it must be repaired using a large-diameter, non-absorbable suture in a transosseous fashion. Many large-diameter suture needles are strong enough to pass through the acromion without using a power drill; however, if the bone is hard, a drill may be used [44]. The suture should be passed through the deltoid with sufficient purchase to ensure that the suture does not pull through the muscle. If the acromial osteotomy was utilized, suture should be passed around the fleck of the acromion with sufficient purchase in the deltoid to again prevent pulling through the suture within the substance of the deltoid.

Once the deltoid has been adequately repaired to the acromion, the deltoid raphe should be sutured with a 0 vicryl or polydioxanone (PDS) suture in a running whipstitch or figure-of-eight interrupted fashion. Care should again be taken to avoid suturing below the previously placed stay suture to avoid damaging the axillary nerve. With the raphe closed, the subcutaneous layer may be closed with an absorbable 2-0 suture and the skin with a nylon, running monocryl or other method of skin closure. A dry dressing or an incisional vacuum should be placed over the wound and the arm placed into a sling with abduction pillow prior to awakening the patient.

4.7. Advantages

The anterosuperior approach provides several advantages to the deltopectoral approach. Perhaps, the greatest of these is the subscapularis sparing nature of the approach. Though originally Mackenzie described the approach with a subscapularis tenotomy, modern-day surgeons have typically modified this approach to spare the subscapularis. Utilizing a subscapularis tenotomy with adequate repair, Miller et al. showed, both clinically and functionally, that the subscapularis was deficient following shoulder arthroplasty in a majority of cases [45]. Jackson et al. showed high re-rupture rates following repair of a tenotomy using ultrasound and then showed that it was associated with decreased function [46]. Furthermore, early literature has shown that subscapularis-deficient shoulders have higher rates of instability [36], though other studies have shown no significant difference [47].

The anterosuperior lateral approach is also superior in terms of exposure to the posterior structures of the shoulder, including the posterior glenoid and the rotator cuff. This exposure may be particularly useful for three- or four-part proximal humerus fractures where the greater tuberosity fragment attached to the rotator cuff is pulled posterior and superior [44]. The exposure of the glenoid via the anterosuperior approach is, historically, felt to be superior to that of the deltopectoral approach. It allows for visualization of the entire glenoid and for better sagittal positioning of the glenoid component. Furthermore, it allows for easier preparation of the glenoid, particularly in obese patients and in cases where the glenoid may be retroverted.

4.8. Disadvantages

Despite having superior exposure of the glenoid as a whole, exposure of the inferior aspect of the glenoid is more difficult via the anterosuperior approach. As such, it is more difficult to provide sufficient inferior tilt of the glenoid component which may lead to scapular notching and subsequent failure of the glenoid component [35, 48, 49]. Furthermore, the presence of inferior osteophytes is a relative contraindication to this approach due to the extreme difficulty in accessing and removing these osteophytes. In addition, there is a theoretical disadvantage

of weakening of the deltoid through this exposure. There is no literature regarding the status of the deltoid repair or deltoid function after using this approach. However, because the repair of the deltoid to the acromion relies on muscle-to-bone healing, the deltoid may have difficulty healing and subsequent dysfunction. This could be particularly problematic when placing a reverse shoulder prosthesis that relies on intact deltoid function to be successful. If a fleck of acromion is taken, there is a theoretical risk of iatrogenic fracture to the acromion when harvesting the fleck. However, one study, comparing the two approaches, found a significantly higher rate of acromion fracture with the deltopectoral approach compared to the anterosuperior approach [7]. A final disadvantage of the anterosuperior approach is the inability to extend the incision distal if a periprosthetic humeral fracture is encountered. Because it does not utilize an intermuscular plane, it is not able to be extended to the midshaft of the humerus. Furthermore, at the distal aspect of the incision lies the axillary nerve. Webb, in his surgical technique for proximal humerus fractures, states that should distal exposure be needed, the axillary nerve can be identified, protected, and a plate may be placed underneath the axillary nerve [44].

5. Alternate approaches

The deltopectoral and anterosuperior approaches are by and large the most commonly used approaches for shoulder arthroplasty; however, there are other approaches to the glenohumeral joint which have been described in the literature. Lafosse et al. described an approach for anatomic total shoulder arthroplasty that spares all of the rotator-cuff tendons and is performed through the rotator interval [50]. The approach mimics that of the anterosuperior approach in that the deltoid is split in line with its fibers in the raphe between the anterior and middle portions of the deltoids. Again, similar to the anterosuperior approach, the authors had difficulty removing the inferior osteophytes as well as performing an anatomic humeral neck cut and sizing of the humeral head. Two-year follow-up data from this approach do show promising results, though no comparison was made to the deltopectoral approach.

Bellamy et al. performed a cadaveric study analyzing more minimally invasive approaches to the subscapularis including a partial tenotomy and a subscapularis split [51]. In this study, they measured the average area of the glenoid and the humerus that they could visualize through each of these approaches. They found that all of these approaches had adequate exposure of the glenoid; however, the split provided poor exposure of the humerus for humeral-based procedures, while the partial tenotomy provided sufficient exposure.

Gagey et al. presented the results of 53 patients who underwent anatomic total shoulder arthroplasty over a 6-year span via a posterolateral approach [52]. This approach begins with the patient in the lateral decubitus position and a posterior incision is made and carried down between the raphe of the posterior and middle portions of the deltoid. The bursa is then released to identify the tendons of the external rotators. The tendons are then removed via an osteotomy of the greater tuberosity. This allows for exposure to the glenohumeral joint. The osteotomy is then repaired in a manner similar to the lesser tuberosity osteotomy described in the deltopectoral section. Adequate exposure was achieved for placement of shoulder arthroplasty components; however, the authors did note two cases of posterior deltoid atrophy that was

unexplained. Brodsky described a modified approach that utilizes the internervous interval between the infraspinatus and the teres minor which allows for preservation of the external rotators [53]. However, no literature exists, which shows that this interval would be feasible for use with shoulder arthroplasty.

A cadaveric study in England compared these three alternative approaches and they found that the posterior approach to the glenohumeral joint provided significantly improved exposure compared to a subscapularis-splitting approach or an approach through the rotator interval [54]. They also measured the average force of retraction on the rotator cuff utilizing these approaches and found that significantly more force was placed on the rotator cuff by retractors in the subscapularis-splitting approach. Before any of these approaches will supplant the deltopectoral or anterosuperior approaches, more research needs to be performed to ensure that good outcomes with minimal morbidity can be achieved through these approaches.

6. Conclusion

While the deltopectoral approach is more widely used than the anterosuperior approach, particularly in shoulder arthroplasty, copious literature exists regarding the outcomes and complications for both of these approaches. Both approaches have been shown to be successful in their utilization for shoulder arthroplasty [1, 7, 55, 56]. The deltopectoral approach has been associated with an increased risk of instability, particularly when the subscapularis is deficient. The anterosuperior approach has been shown to have higher rates of scapular notching. Each approach has its own distinct advantages and disadvantages; however, each can be used successfully in the setting of shoulder arthroplasty. Surgeon preference and comfort with the approach should be the most important deciding factor when choosing an approach.

Author details

Brian W. Sager and Michael Khazzam*

*Address all correspondence to: drkhazzam@yahoo.com

University of Texas Southwestern Medical Center, Department of Orthopaedic Surgery,
Dallas, Texas, USA

References

- [1] Bufquin T, Hersan A, Hubert L, Massin P. Reverse shoulder arthroplasty for the treatment of three- and four-part fractures of the proximal humerus in the elderly: A prospective review of 43 cases with a short-term follow-up. *The Journal of Bone and Joint Surgery British*. 2007;89(4):516-520

- [2] Cuff D, Pupello D, Virani N, Levy J, Frankle M. Reverse shoulder arthroplasty for the treatment of rotator cuff deficiency. *The Journal of Bone and Joint Surgery America*. 2008;**90**(6):1244-1251
- [3] Green A, Norris TR. Shoulder arthroplasty for advanced glenohumeral arthritis after anterior instability repair. *Journal of Shoulder and Elbow Surgery*. 2001;**10**(6):539-545
- [4] Mulieri P, Dunning P, Klein S, Pupello D, Frankle M. Reverse shoulder arthroplasty for the treatment of irreparable rotator cuff tear without glenohumeral arthritis. *The Journal of Bone and Joint Surgery America*. 2010;**92**(15):2544-2556
- [5] Neer CS, 2nd. Replacement arthroplasty for glenohumeral osteoarthritis. *The Journal of Bone and Joint Surgery America*. 1974;**56**(1):1-13
- [6] Carayon A, Cornet L, Huet R. Deltopectoral approach: Value and indications in vasculo-nervous lesions of the axilla. *Medecine Tropicale (Mars)*. 1958;**18**(4):708-719
- [7] Mole D, Wein F, Dezaly C, Valenti P, Sirveaux F. Surgical technique: The anterosuperior approach for reverse shoulder arthroplasty. *Clinical Orthopaedics and Related Research*. 2011;**469**(9):2461-2468
- [8] Li X, Eichinger JK, Hartshorn T, Zhou H, Matzkin EG, Warner JP. A comparison of the lateral decubitus and beach-chair positions for shoulder surgery: Advantages and complications. *Journal of the American Academy of Orthopaedic Surgeons*. 2015;**23**(1):18-28
- [9] Hynson JM, Tung A, Guevara JE, Katz JA, Glick JM, Shapiro WA. Complete airway obstruction during arthroscopic shoulder surgery. *Anesthesia & Analgesia*. 1993;**76**(4):875-878
- [10] Pohl A, Cullen DJ. Cerebral ischemia during shoulder surgery in the upright position: A case series. *Journal of Clinical Anesthesiology*. 2005;**17**(6):463-469
- [11] Yano K, Minoda Y, Sakawa A, Kuwano Y, Kondo K, Fukushima W, Tada K. Positive nasal culture of methicillin-resistant *Staphylococcus aureus* (MRSA) is a risk factor for surgical site infection in orthopedics. *Acta Orthopaedica*. 2009;**80**(4):486-490
- [12] Bosco JA, Bookman J, Slover J, Edusei E, Levine B. Principles of antibiotic prophylaxis in total joint arthroplasty: Current concepts. *Journal of the American Academy of Orthopaedic Surgeons*. 2015;**23**(8):e27-35
- [13] Friedman RJ, Gordon E, Butler RB, Mock L, Dumas B. Tranexamic acid decreases blood loss after total shoulder arthroplasty. *Journal of Shoulder and Elbow Surgery*. 2016;**25**(4):614-618
- [14] Gillespie R, Shishani Y, Joseph S, Streit JJ, Gobeze R. Neer Award 2015: A randomized, prospective evaluation on the effectiveness of tranexamic acid in reducing blood loss after total shoulder arthroplasty. *Journal of Shoulder and Elbow Surgery*. 2015;**24**(11):1679-1684
- [15] Sanchez-Sotelo J, Sperling JW, Rowland CM, Cofield RH. Instability after shoulder arthroplasty: Results of surgical treatment. *The Journal of Bone and Joint Surgery America*. 2003;**85-A**(4):622-631

- [16] Buecking B, Mohr J, Bockmann B, Zettl R, Ruchholtz S. Deltoid-split or deltopectoral approaches for the treatment of displaced proximal humeral fractures? *Clinical Orthopaedics and Related Research*. 2014;**472**(5):1576-1585
- [17] Gerber C, Pennington SD, Yian EH, Pfirrmann CA, Werner CM, Zumstein MA. Lesser tuberosity osteotomy for total shoulder arthroplasty. Surgical technique. *The Journal of Bone and Joint Surgery America*. 2006;**88**(Suppl 1 Pt 2):170-177
- [18] Habermeyer P, Magosch P, Lichtenberg S. Recentering the humeral head for glenoid deficiency in total shoulder arthroplasty. *Clinical Orthopaedics and Related Research*. 2007;**457**:124-132
- [19] Harryman DT, 2nd. Common surgical approaches to the shoulder. *Instructional Course Lectures*. 1992;**41**:3-11
- [20] Radkowski CA, Richards RS, Pietrobon R, Moorman CT, 3rd. An anatomic study of the cephalic vein in the deltopectoral shoulder approach. *Clinical Orthopaedics and Related Research*. 2006;**442**:139-142
- [21] Boardman ND, 3rd, Cofield RH. Neurologic complications of shoulder surgery. *Clinical Orthopaedics and Related Research*. 1999;**368**:44-53
- [22] Gerber C, Yian EH, Pfirrmann CA, Zumstein MA, Werner CM. Subscapularis muscle function and structure after total shoulder replacement with lesser tuberosity osteotomy and repair. *The Journal of Bone and Joint Surgery America*. 2005;**87**(8):1739-1745
- [23] Torchia ME, Cofield RH, Settergren CR. Total shoulder arthroplasty with the Neer prosthesis: Long-term results. *Journal of Shoulder and Elbow Surgery*. 1997;**6**(6):495-505
- [24] Armstrong A, Lashgari C, Teefey S, Menendez J, Yamaguchi K, Galatz LM. Ultrasound evaluation and clinical correlation of subscapularis repair after total shoulder arthroplasty. *Journal of Shoulder and Elbow Surgery*. 2006;**15**(5):541-548
- [25] Scalise JJ, Ciccone J, Iannotti JP. Clinical, radiographic, and ultrasonographic comparison of subscapularis tenotomy and lesser tuberosity osteotomy for total shoulder arthroplasty. *The Journal of Bone and Joint Surgery America*. 2010;**92**(7):1627-1634
- [26] Defranco MJ, Higgins LD, Warner JJ. Subscapularis management in open shoulder surgery. *Journal of the American Academy of Orthopaedic Surgeons*. 2010;**18**(12):707-717
- [27] Lapner PL, Sabri E, Rakhra K, Bell K, Athwal GS. Healing rates and subscapularis fatty infiltration after lesser tuberosity osteotomy versus subscapularis peel for exposure during shoulder arthroplasty. *Journal of Shoulder and Elbow Surgery*. 2013;**22**(3):396-402
- [28] Giuseffi SA, Wongtriratanachai P, Omae H, Cil A, Zobitz ME, An KN, Sperling JW, Steinmann SP. Biomechanical comparison of lesser tuberosity osteotomy versus subscapularis tenotomy in total shoulder arthroplasty. *Journal of Shoulder and Elbow Surgery*. 2012;**21**(8):1087-1095
- [29] Van den Berghe GR, Nguyen B, Patil S, D'Lima DD, Mahar A, Pedowitz R, Hoenecke HR. A biomechanical evaluation of three surgical techniques for subscapularis repair. *Journal of Shoulder and Elbow Surgery*. 2008;**17**(1):156-161

- [30] Van Thiel GS, Wang VM, Wang FC, Nho SJ, Piasecki DP, Bach BR, Jr., Romeo AA. Biomechanical similarities among subscapularis repairs after shoulder arthroplasty. *Journal of Shoulder and Elbow Surgery*. 2010;**19**(5):657-663
- [31] Iannotti JP, Gabriel JP, Schneck SL, Evans BG, Misra S. The normal glenohumeral relationships. An anatomical study of one hundred and forty shoulders. *The Journal of Bone and Joint Surgery America*. 1992;**74**(4):491-500
- [32] Duparc F, Bocquet G, Simonet J, Freger P. Anatomical basis of the variable aspects of injuries of the axillary nerve (excluding the terminal branches in the deltoid muscle). *Surgical and Radiologic Anatomy*. 1997;**19**(3):127-132
- [33] Loomer R, Graham B. Anatomy of the axillary nerve and its relation to inferior capsular shift. *Clinical Orthopaedics and Related Research*. 1989;**243**:100-105
- [34] Kelly JD, 2nd, Humphrey CS, Norris TR. Optimizing glenosphere position and fixation in reverse shoulder arthroplasty, Part One: The twelve-mm rule. *Journal of Shoulder and Elbow Surgery*. 2008;**17**(4):589-594
- [35] Gillespie RJ, Garrigues GE, Chang ES, Namdari S, Williams GR, Jr. Surgical exposure for reverse total shoulder arthroplasty: Differences in approaches and outcomes. *Orthopedic Clinics of North America*. 2015;**46**(1):49-56
- [36] Edwards TB, Williams MD, Labriola JE, Elkousy HA, Gartsman GM, O'Connor DP. Subscapularis insufficiency and the risk of shoulder dislocation after reverse shoulder arthroplasty. *Journal of Shoulder and Elbow Surgery*. 2009;**18**(6):892-896
- [37] Trappey GJT, O'Connor DP, Edwards TB. What are the instability and infection rates after reverse shoulder arthroplasty? *Clinical Orthopaedics and Related Research*. 2011;**469**(9):2505-2511
- [38] Miller BS, Joseph TA, Noonan TJ, Horan MP, Hawkins RJ. Rupture of the subscapularis tendon after shoulder arthroplasty: Diagnosis, treatment, and outcome. *Journal of Shoulder and Elbow Surgery*. 2005;**14**(5):492-496
- [39] Lynch NM, Cofield RH, Silbert PL, Hermann RC. Neurologic complications after total shoulder arthroplasty. *Journal of Shoulder and Elbow Surgery*. 1996;**5**(1):53-61
- [40] Mackenzie D. The antero-superior exposure for total shoulder replacement. *Orthopaedics and Traumatology*. 1993;**2**(2):71-77
- [41] Warner JP, Krushell RJ, Masquelet A, Gerber C. Anatomy and relationships of the suprascapular nerve: Anatomical constraints to mobilization of the supraspinatus and infraspinatus muscles in the management of massive rotator-cuff tears. *The Journal of Bone and Joint Surgery America*. 1992;**74**(1):36-45
- [42] Burkhead WZ, Jr, Scheinberg RR, Box G. Surgical anatomy of the axillary nerve. *Journal of Shoulder and Elbow Surgery*. 1992;**1**(1):31-36
- [43] Neer CS, 2nd. Anterior acromioplasty for the chronic impingement syndrome in the shoulder: A preliminary report. *The Journal of Bone and Joint Surgery America*. 1972;**54**(1):41-50

- [44] Webb MF, Funk L. An anterosuperior approach for proximal humerus fractures. *Techniques in Shoulder & Elbow Surgery*. 2006;**7**(2):77-81
- [45] Miller SL, Hazrati Y, Klepps S, Chiang A, Flatow EL. Loss of subscapularis function after total shoulder replacement: A seldom recognized problem. *Journal of Shoulder and Elbow Surgery*. 2003;**12**(1):29-34
- [46] Jackson JD, Cil A, Smith J, Steinmann SP. Integrity and function of the subscapularis after total shoulder arthroplasty. *Journal of Shoulder and Elbow Surgery*. 2010;**19**(7):1085-1090
- [47] Clark JC, Ritchie J, Song FS, Kissenberth MJ, Tolan SJ, Hart ND, Hawkins RJ. Complication rates, dislocation, pain, and postoperative range of motion after reverse shoulder arthroplasty in patients with and without repair of the subscapularis. *Journal of Shoulder and Elbow Surgery*. 2012;**21**(1):36-41
- [48] Levigne C, Boileau P, Favard L, Garaud P, Mole D, Sirveaux F, Walch G. Scapular notching in reverse shoulder arthroplasty. *Journal of Shoulder and Elbow Surgery*. 2008;**17**(6):925-935
- [49] Melis B, DeFranco M, Ladermann A, Mole D, Favard L, Nerot C, Maynou C, Walch G. An evaluation of the radiological changes around the Grammont reverse geometry shoulder arthroplasty after eight to 12 years. *The Journal of Bone and Joint Surgery British*. 2011;**93**(9):1240-1246
- [50] Lafosse L, Schnaser E, Haag M, Gobezie R. Primary total shoulder arthroplasty performed entirely thru the rotator interval: Technique and minimum two-year outcomes. *Journal of Shoulder and Elbow Surgery*. 2009;**18**(6):864-873
- [51] Bellamy JL, Johnson AE, Beltran MJ, Hsu JR, Skeletal Trauma Research Consortium (STReC). Quantification of the exposure of the glenohumeral joint from the minimally invasive to more invasive subscapularis approach to the anterior shoulder: A cadaveric study. *Journal of Shoulder and Elbow Surgery*. 2014;**23**(6):895-901
- [52] Gagey O, Spraul JM, Vinh TS. Posterolateral approach of the shoulder: Assessment of 50 cases. *Journal of Shoulder and Elbow Surgery*. 2001;**10**(1):47-51
- [53] Brodsky JW, Tullos HS, Gartsman GM. Simplified posterior approach to the shoulder joint. A technical note. *The Journal of Bone and Joint Surgery America*. 1987;**69**(5):773-774
- [54] Amirthanayagam TD, Amis AA, Reilly P, Emery RJ. Rotator cuff-sparing approaches for glenohumeral joint access: An anatomic feasibility study. *Journal of Shoulder and Elbow Surgery*. 2017;**26**(3):512-520
- [55] Levy O, Copeland SA. Cementless surface replacement arthroplasty of the shoulder. 5- to 10-year results with the Copeland mark-2 prosthesis. *The Journal of Bone and Joint Surgery British*. 2001;**83**(2):213-221
- [56] Matsen FA, 3rd, Boileau P, Walch G, Gerber C, Bicknell RT. The reverse total shoulder arthroplasty. *The Journal of Bone and Joint Surgery America*. 2007;**89**(3):660-667