

We are IntechOpen, the world's leading publisher of Open Access books Built by scientists, for scientists

6,900

Open access books available

186,000

International authors and editors

200M

Downloads

Our authors are among the

154

Countries delivered to

TOP 1%

most cited scientists

12.2%

Contributors from top 500 universities



WEB OF SCIENCE™

Selection of our books indexed in the Book Citation Index
in Web of Science™ Core Collection (BKCI)

Interested in publishing with us?
Contact book.department@intechopen.com

Numbers displayed above are based on latest data collected.
For more information visit www.intechopen.com



Ovarian Cancer and Pregnancy

Chrisostomos Sofoudis

Additional information is available at the end of the chapter

<http://dx.doi.org/10.5772/intechopen.70155>

Abstract

The annual incidence rate of cancer is estimated to be more than 11,000 patients in the U.K. in the age group of 15–40 years, which corresponds to 4% of all cancer patients. The diagnosis of cancer is followed by devastating consequences for the patients and their families in this age group. Although the treatment of cancer is of crucial significance, it should also examine the impact of the disease on fertility at the time of the diagnosis and the damages caused from the surgical treatment, chemotherapy, or radiotherapy. The gynecological cancer, especially the diagnosis of ovarian cancer, the prevention, and treatment, as well as the fertility preservation in young women, represent the gold standard for all gynecologists. The crucial disadvantage remains the difficulty in primary diagnosis of ovarian cancer and the coexistence with pregnancy, focusing on the fertility preservation and maintaining pregnancy. In the absence of large perspective randomized trials and cohort studies, the therapeutic mapping and optimal management of these patients are difficult. In order to establish detailed guidelines, it is necessary to ensure surgical mapping depending on the cancer staging and the quality of life of the patients.

Keywords: ovarian cancer, fertility preservation, pregnancy

1. Introduction

The presence of adnexal masses during pregnancy consists of a less rare condition. With the help and increase of the transvaginal ultrasound, the diagnosis of adnexal masses or cysts becomes more frequent. The incidence of these masses during pregnancy is estimated to be 0.2–2% depending on the week of gestation. The malignancy rate consisted of 1–6%, leaving the vast majority in benign level [1].

Distinguishing between malignant and nonmalignant adnexal masses or cysts especially during pregnancy depends on the level experience of the gynecologist and the disease staging.

The most common nonmalignant cyst represents the functional cysts. These cysts or presence of corpus luteum are harmonically influenced and depict different ultrasound morphology. Imaging findings consist of thin wall without disturbance of architecture and lack of vascularization (**Figure 1**) [2].

These functional cysts can be shortly or after a couple of months absorbed. The appearance of adnexal mass or cyst during early pregnancy must lead to differential diagnosis of an ectopic pregnancy. Other examples such as cystadenomas or dermoid cysts during pregnancy can be removed laparoscopically during the first trimester.

The evaluation of an adnexal mass and the differential diagnosis toward a possible adnexal malignancy can be managed with ultrasound examination, abdominal MRI, and tumor markers.

Ultrasound examination can easily be undergone and consists of routine procedure with increased sensitivity and specificity, respectively. Imaging findings can facilitate the differential diagnosis between a malignant and a benign adnexal disease.

Ovarian cancer associated with pregnancy represents a rare entity. Ultrasound examination can depict tumor morphology, tumor size, papillary protrusions, and color Doppler flow (**Figure 2**) [3].

The mentioned ultrasound imaging clearly depicts the presence of color Doppler as indirect sign of malignant vascularization, presence of papillary protrusions inside the adnexal wall, and disturbance of adnexal architecture. All these ultrasound characteristics indicate the presence of ovarian cancer [4].

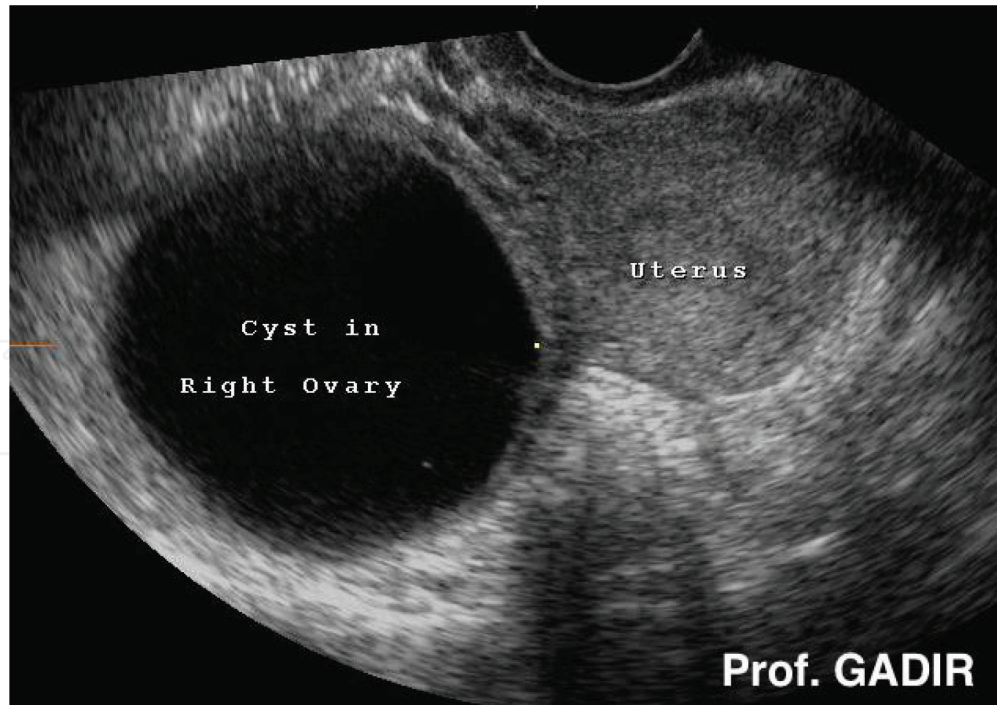


Figure 1. A simple ovarian cyst on the right side of the uterus fulfilling all the characteristics mentioned before (Professor Ahmed Abdel Gadir, Illustrated Gynecology and Infertility Ultrasound).

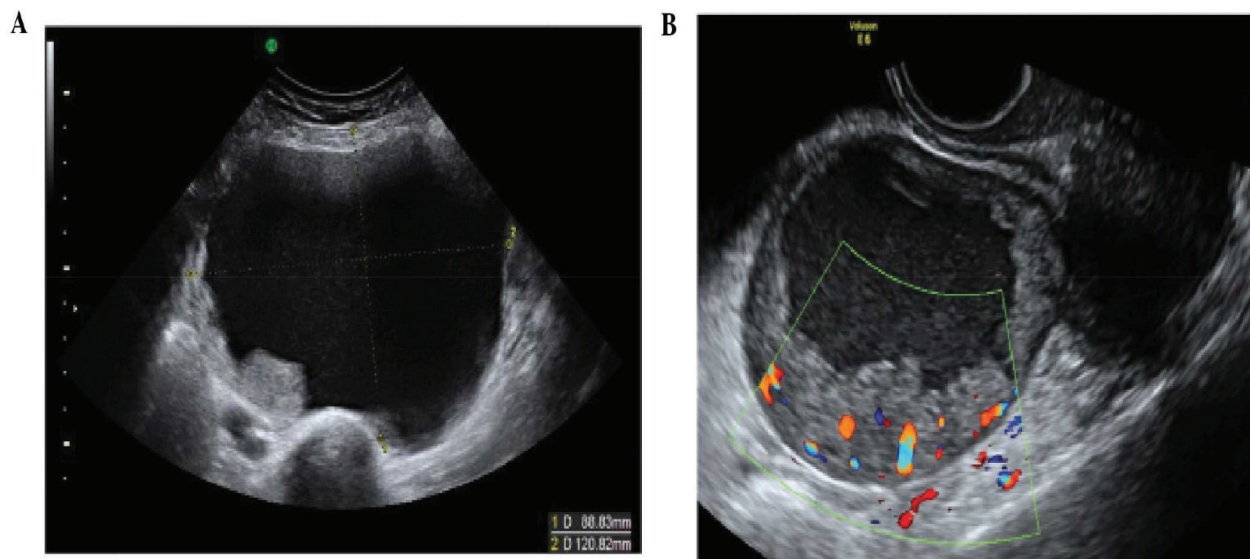


Figure 2. Primary invasive ovarian epithelial cancers. (A) Stage 1, clear cell carcinoma of the ovary. (B) Unilocular solid early invasive cancer with increased vascularity on color Doppler.

The use of MRI safely during second or third trimester of gestation increases, accompanied with the ultrasound imaging findings, the sensitivity and specificity of diagnosing ovarian cancer during pregnancy. Diagnostic keys during abdominal MRI can be tumor invasion or spread, lymphatic spread, disease staging, and possible metastatic lesions [5].

Classic imaging findings of adnexal malignancy consist of necrotic or solid elements inside the ovarian wall, septal thickening, or mural nodules and papillary excrescences (**Figure 3**) [6].

The use of tumor markers in cases of adnexal masses or cysts often accompanied with pregnancy remains a controversial entity. Due to daily physiologic and hormonal changes during pregnancy, all tumor markers are increased. Ca-125, a tumor marker capable of distinguishing a benign from a malignant adnexal mass, is often increased during pregnancy [7].

Other tumor markers, such as alpha fetoprotein (AFP) and b-HCG often increased in germ cell tumors or Inhibine B and anti-mullerean protein (AMH) often increased in granulosa-associated tumors, are equally increased during all trimesters of gestation [8].

Additionally, elevated Ca-125 levels were found in cases of acute pelvic inflammatory disease (PID). Many current studies have been conducted assuming the presence of the mentioned tumor marker in the fallopian tubes [9].

Generally, tumor markers are not used as a screening test. From their point of view, they contribute indirectly toward the final diagnosis. The therapeutic mapping consists of the assiduous physical examination, the imaging findings, and the ranges of the laboratory examination. Ultimate goal remains the quality of life regarding the mother and the fetus.

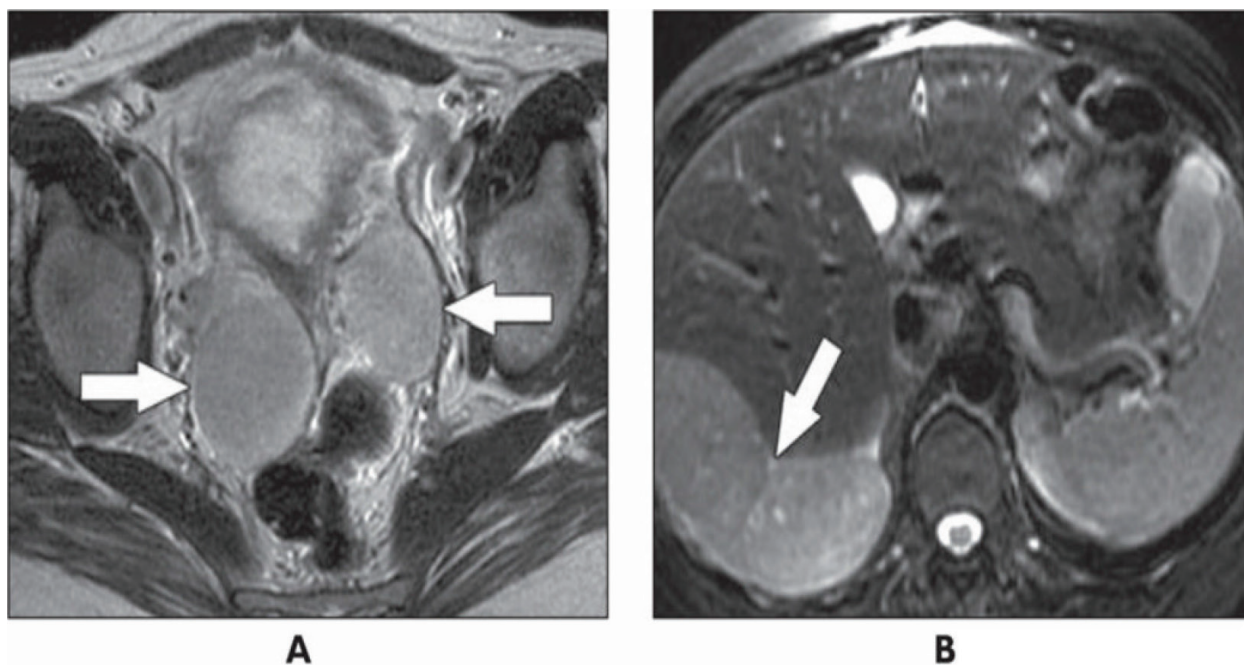


Figure 3. A 34-year-old pregnant woman. (A) Axial RARE T2-weighted MR image obtained at 23 weeks' gestation shows bilateral solid adnexal masses (arrows). (B) Axial RARE T2-weighted MR image through upper abdomen shows large tumor deposit (arrow) abutting liver. Appearances are considered indicative of malignancy. Cesarean hysterectomy and bilateral salpingo oophorectomy were performed at 28 weeks' gestation because of progression of subphrenic tumor with diaphragmatic irritation. Pathology results showed benign metastasizing leiomyoma. Masses spontaneously regressed after surgery and patient remains free of disease 3 years after surgery.

2. Discussion

According to current literature and long conductive series, the frequency of adnexal masses during pregnancy is estimated to be 1 in 81 to 1 in 2500 live births [10].

On the other side, the incidence of ovarian carcinoma in correlation to pregnancy is estimated to be 1 in 21,500 (**Figure 4**) [11].

The therapeutic mapping regarding the presence of ovarian carcinoma depends on the pre-disposition factors, such as the tumor size, tumor staging, lymphatic infiltration, tumor invasion, and presence of metastatic lesions such as liver, brain, and bone metastasis.

The ultimate goal remains the cytoreduction or better debulking. In other words, peritoneal washing, total hysterectomy, bilateral salpingo-oophorectomy, pelvic and paraortic lymph node dissection, inspection of all peritoneal surfaces and multiple biopsies, and finally, omentum dissection.

There are nonspecific clinical signs to primarily diagnose the existence of ovarian cancer (**Figure 5**).

For advanced stages of ovarian cancer, the optimal treatment consists of combination of chemotherapy and radiotherapy (**Figure 6**) [12].

NCCN Guidelines Version 1.2016

Epithelial Ovarian Cancer/Primary Peritoneal Cancer

American Joint Committee on Cancer (AJCC)

TNM and FIGO Staging System for Ovarian and Primary Peritoneal Cancer (7th ed., 2010)

ST-1

Primary Tumor (T)

TNM FIGO

TX Primary tumor cannot be assessed

T0 No evidence of primary tumor

T1 I Tumor limited to ovaries (one or both)

T1a IA Tumor limited to one ovary; capsule intact, no tumor on ovarian surface. No malignant cells in ascites or peritoneal washings

T1b IB Tumor limited to both ovaries; capsules intact, no tumor on ovarian surface. No malignant cells in ascites or peritoneal washings

T1c IC Tumor limited to one or both ovaries with any of the following: capsule ruptured, tumor on ovarian surface, malignant cells in ascites or peritoneal washings

T2 II Tumor involves one or both ovaries with pelvic extension

T2a IIA Extension and/or implants on uterus and/or tube(s). No malignant cells in ascites or peritoneal washings

T2b IIB Extension to and/or implants on other pelvic tissues. No malignant cells in ascites or peritoneal washings

T2c IIC Pelvic extension and/or implants (T2a or T2b) with malignant cells in ascites or peritoneal washings Note: Liver capsule metastasis is T3/stage III; liver parenchymal metastasis, M1/stage IV. Pleural effusion must have positive cytology for M1/stage IV.

TNM FIGO

T3 III Tumor involves one or both ovaries with microscopically confirmed peritoneal metastasis outside the pelvis

T3a IIIA Microscopic peritoneal metastasis beyond pelvis (no macroscopic tumor)

T3b IIIB Macroscopic peritoneal metastasis beyond pelvis 2 cm or less in greatest dimension

T3c IIIC Peritoneal metastasis beyond pelvis more than 2 cm in greatest dimension and/or regional lymph node metastasis

Regional Lymph Nodes (N)

NX Regional lymph nodes cannot be assessed

N0 No regional lymph node metastasis

N1 IIIC Regional lymph node metastasis

Distant Metastasis (M)

M0 No distant metastasis

M1 IV Distant metastasis (excludes peritoneal metastasis)

Figure 4. Ovarian cancer classification. Source: NCCN Guidelines 2016.

Signs and symptoms of Ovarian Cancer

Symptoms of ovarian cancer are not specific to the disease, and they often mimic those of many other more-common conditions, including digestive and bladder problems. When ovarian cancer symptoms are present, they tend to be persistent and worsen with time.

Signs and symptoms of ovarian cancer may include:

- Abdominal pressure, fullness, swelling or bloating
- Pelvic discomfort or pain
- Persistent indigestion, gas or nausea
- Changes in bowel habits, such as constipation
- Changes in bladder habits, including a frequent need to urinate
- Loss of appetite or quickly feeling full
- Increased abdominal girth or clothes fitting tighter around your waist
- A persistent lack of energy

Get Free Opinion from Best Doctors in India

<http://www.medworldindia.com/Medicalprocedures.htm>

Figure 5. Symptoms and clinical signs of ovarian cancer.

The most significant issue remains the therapeutic mapping regarding the combination of ovarian cancer and pregnancy.

As we mentioned above, primary goal represents the increase of free survival rate and quality of life of the mother and fetus, respectively (Figure 7).

The incidence of ovarian cancer is increased in older pregnant women [13]. In other words, age represents a predispositional factor which influences the pregnancy outcome.

Many studies from the current literature suggested that many histologic types of ovarian cancer in pregnant women are similar to those in nonpregnant women [14]. Surgical dissection of an adnexal mass diagnosed during pregnancy remains a controversial issue. Adnexal mass with diameter larger than 6 cm, with peripheral vascularization, ascites, or persistent presence of more than 4 months, requires surgical dissection and histologic confirmation and exclusion of potential malignancy [15].

Generally, the ultimate treatment of ovarian cancer during pregnancy consists of surgical intervention with adequate staging. For advanced stages, stages with metastatic lesions, the current literature, and the standard guidelines recommend treatment similar to nonpregnant women—surgical debulking combined with series of chemotherapy or radiotherapy (Figure 8).

As we mentioned above, the standard treatment of epithelial ovarian cancer (EOC), the histologic type with the worst prognosis, consists of total hysterectomy, bilateral salpingo-oophorectomy, peritoneal washing, dissection of the omentum, dissection of all peritoneal implants, and most of all lymph node dissection (pelvic and paraaortic).

If all imaging findings and the laboratory report advocate of an early-stage lesion, the therapeutic mapping is focusing on unilateral oophorectomy or adnexectomy with appropriate staging. It is very important to keep in mind all conservative surgical methods focusing on the pregnancy maintenance.

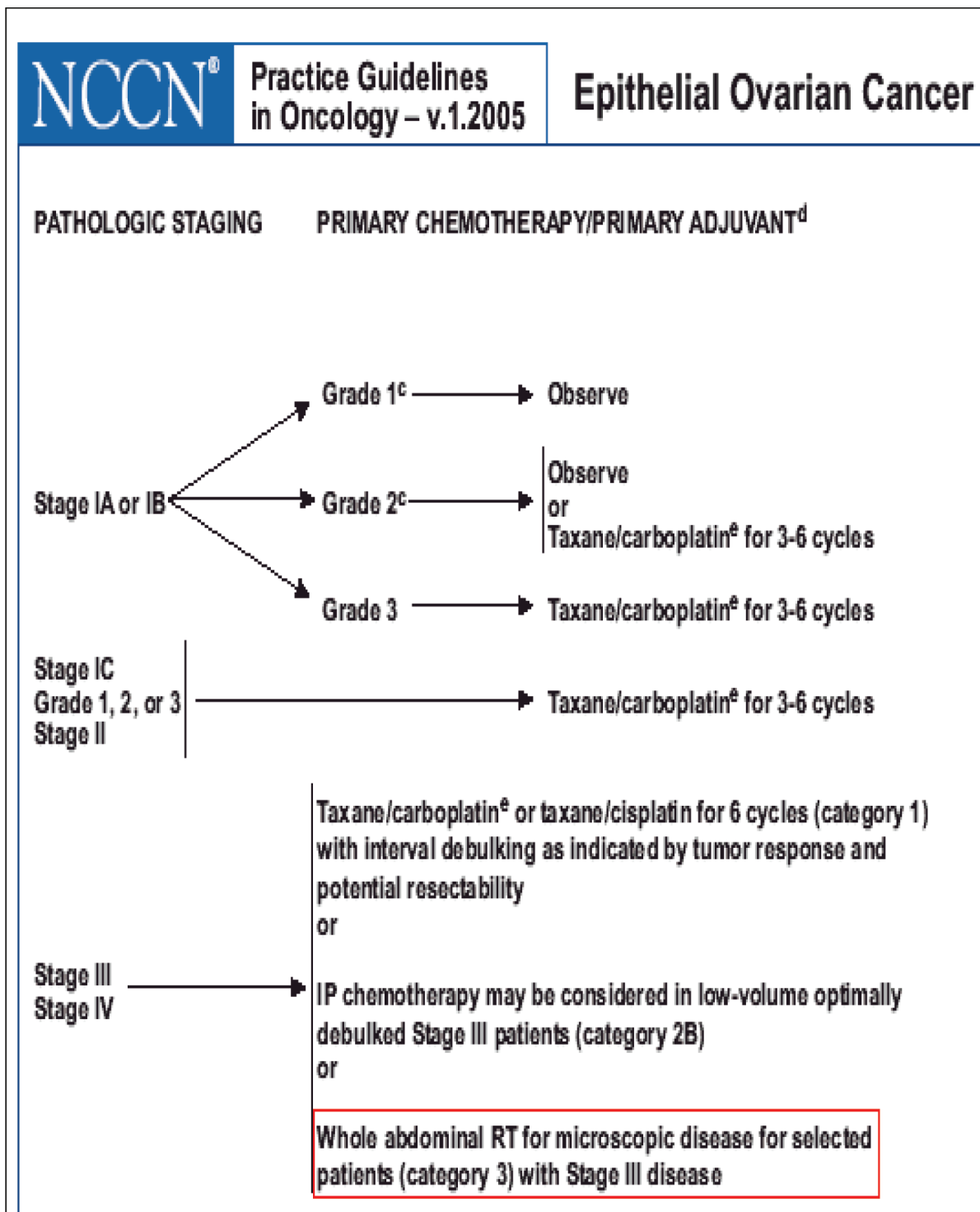


Figure 6. Chemotherapy in ovarian cancer.

In cases of advanced stages, termination of pregnancy and use of neoadjuvant chemotherapy or radiotherapy is recommended.

When series of chemotherapy are mandatory regarding advanced stages of ovarian cancer, the suitable period is during the second or third trimester, avoiding the organogenesis of

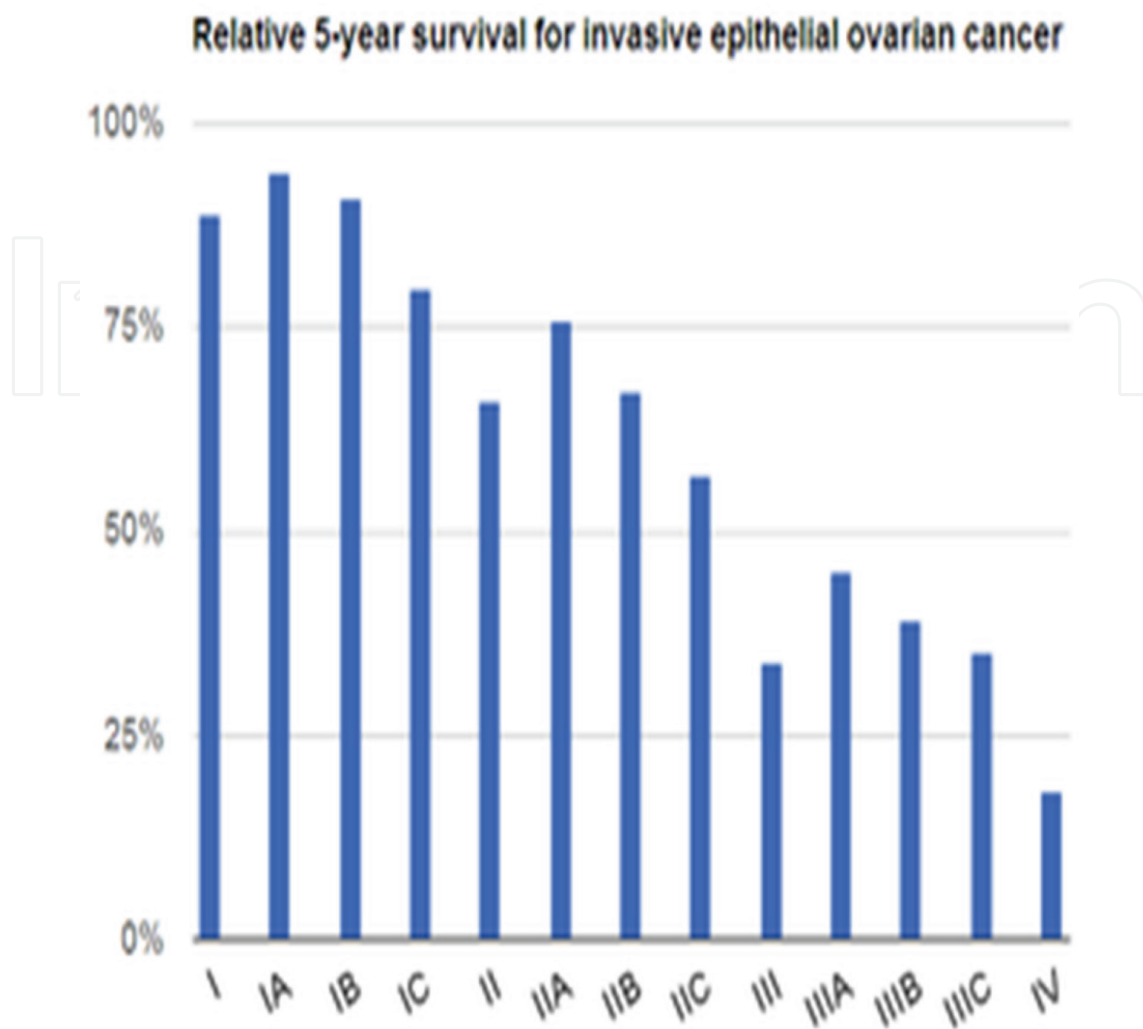


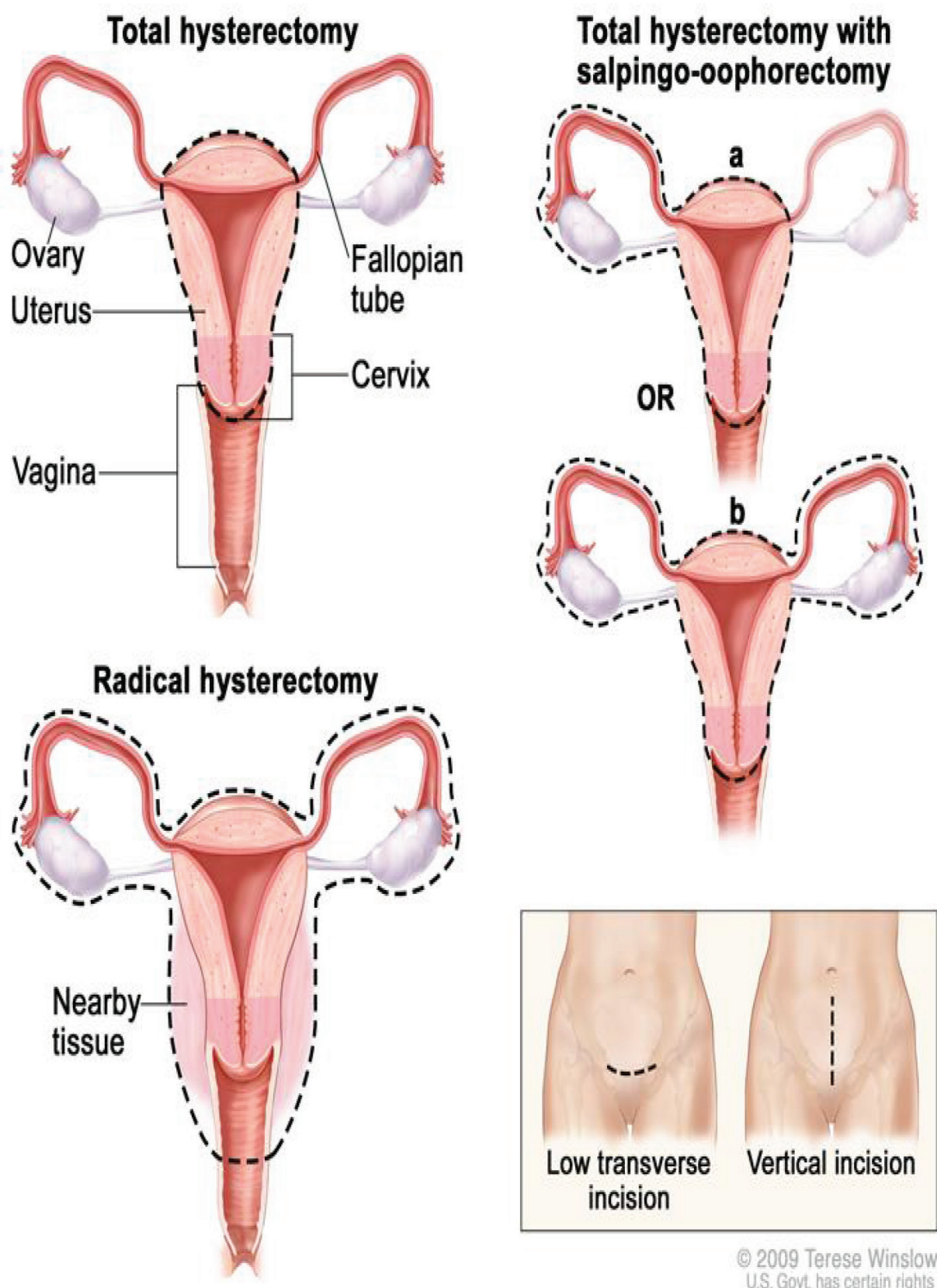
Figure 7. Relative 5-year survival for invasive epithelial ovarian cancer. Source: Wikipedia.

first trimester, period with increased incidence of genital malformations. During these trimesters, the risk of genital malformations does not exceed the risk of general population [16].

Additionally, for patients with diagnosed ovarian cancer during pregnancy and focusing on the current guidelines platinum-based chemotherapy, combination of carboplatin with weekly paclitaxel is strongly recommended after the first trimester, representing a safe chemotherapeutic procedure [17].

Radiotherapy is recommended in advanced stages alone or in combination with series of chemotherapy. The current literature and the global guidelines strongly advise doses of radiotherapy as in nonpregnant women.

Radiotherapy is restricted in cases of dysgerminoma as an example of the most common germ cell tumor due to its radiosensitivity. The field of exposure extends from T11 to L5, with shielding of the contralateral ovary and the femur head [18].



© 2009 Terese Winslow
U.S. Govt. has certain rights

Figure 8. Types of hysterectomy. Source: Cancer.org.

3. Conclusion

Therapeutic mapping of ovarian cancer during pregnancy remains a controversial issue. Many studies have been conducted in order to establish safe guidelines of treatment with the ultimate goal of increasing free survival and quality of life of the mother and the fetus. Primary diagnosis, multidisciplinary cooperation, assiduous imaging findings, and laboratory examinations assure proper treatment.

Disclosure of interest

The author declares no financial interest with respect to this manuscript.

Author details

Chrisostomos Sofoudis

Address all correspondence to: chrisostomos.sofoudis@gmail.com

Department of Obstetrics and Gynecology, Konstandopoulou General Hospital, Athens, Greece

References

- [1] Hoover K, Jenkins TR. Evaluation and management of adnexal mass in pregnancy. *American Journal of Obstetrics & Gynecology*. 2011;**205**:97-102
- [2] Parsons AK. Imaging the human corpus luteum. *Journal of Ultrasound in Medicine*. 2001;**20**:811-819
- [3] Glanc P, Salem S, Farine D. Adnexal masses in the pregnant patient: A diagnostic and management challenge. *Ultrasound Quarterly*. 2008;**24**:225-240
- [4] Sayasneh A, Ekechi C, Ferrara L, Kaijser J, Stalder C, Sur S, Timmerman D, Bourne T. *International Journal of Oncology*. 2015;**46**:445-458
- [5] Sugano K, Nakamura S, Ando J, et al. Cross sectional analysis of germline BRCA1 and BRCA2 mutations in Japanese patients suspected to have hereditary breast/ovarian cancer. *Cancer Science*. 2008;**99**(10):1967-1976
- [6] Telischak N, Yeh B, Joe B, Westphalen A, Poder N, Coackley F. MRI of adnexal masses in pregnancy. *American Journal of Roentgenology*. 2008;**191**(2):364-370
- [7] Han SN, Lotgerink A, Gziri MM, et al. Physiologic variations of serum tumor markers in gynaecologic malignancies during pregnancy: A systematic review. *BMC Medicine*. 2012;**10**:86

- [8] Cromabach G, Zippel HH, Wurz H. Erfahrungen mit Ca-125, einem Tumormarker für maligne epitheliale Ovariantumore. *Geburtsh Frauenklinik*. 1985;**45**:205-212
- [9] Kabawat SE, Bast Jr RC, Welch WR, Knapp RC, Colvin RB. Immunpathologic characterization of a monoclonal antibody that recognizes common surface antigens of human ovarian tumors of serous endometrioid and clear cell types. *American Journal of Clinical Pathology*. 1983;**79**:98-104
- [10] Hess CW, Peaceman A, O'Brien WT, Winkel CA. Adnexal masses occurring with intra-uterine pregnancy: Report of fifty-four patients requiring laparotomy for definite management. *American Journal of Obstetrics and Gynecology*. 1988;**158**:1029-1034
- [11] Hovman M, Cavabgh D, Iotama E, Ruggolo E. Adnocarcinoma of the endometrium with pregnancy. *Gynecologic Oncology*. 1984;**32**:82
- [12] Vergote I, Tropé CG, Amant F, Kristensen GB, Ehlen T, Johnson N, et al. Neoadjuvant chemotherapy or primary surgery in stage IIIC or IV ovarian cancer. *The New England Journal of Medicine*. 2010;**363**:943-953
- [13] American Cancer Society. General Information About Ovarian Cancer [Internet]. Available from: [http://www.cancer.org/cancer/ovarian cancer/index](http://www.cancer.org/cancer/ovarian%20cancer/index) [Accessed October 31, 2013]
- [14] Zanotti KS, Belinson JL, Kennedy AW. Treatment of gynecologic cancers in pregnancy. *Seminars in Oncology*. 2000;**27**:686-698
- [15] Dudkiewicz J, Kowalski T, Grzonka D, Czarnecki M. Ovarian tumors in pregnancy. *Ginekologia Polska*. 2002;**73**:342-345
- [16] Zemlickis D, Lishner M, Degendorfer P, Panzarella T, Sutcliffe SB, Koren G. Fetal outcome after in utero exposure to cancer chemotherapy. *Archives of Internal Medicine*. 1992;**152**:573-576
- [17] Han SN, Lotgerink A, Gziri MM, et al. Physiologic variations of serum tumor markers in gynecologic malignancies during pregnancy: A systematic review. *BMC Medicine*. 2012;**10**:86
- [18] De Palo G, Lattuada A, Kenda R, Musumeci R, Zanini M. Germ cell tumors of the ovary: The experience of the National Cancer Institute of Milan. I. Dysgerminoma. *International Journal of Radiation Oncology, Biology, Physics*. 1987;**13**(6):853-860

