

We are IntechOpen, the world's leading publisher of Open Access books Built by scientists, for scientists

6,900

Open access books available

186,000

International authors and editors

200M

Downloads

Our authors are among the

154

Countries delivered to

TOP 1%

most cited scientists

12.2%

Contributors from top 500 universities



WEB OF SCIENCE™

Selection of our books indexed in the Book Citation Index
in Web of Science™ Core Collection (BKCI)

Interested in publishing with us?
Contact book.department@intechopen.com

Numbers displayed above are based on latest data collected.
For more information visit www.intechopen.com



Reconstruction for Mandibular Implant Failure

Shih-Heng Chen, Hao-Chih Tai, Tai-Ju Cheng,
Hung-Chi Chen, An-Ta Ko, Tyng-Luan Roan,
Yo-Shen Chen and Yueh-Bih Tang

Additional information is available at the end of the chapter

<http://dx.doi.org/10.5772/intechopen.70166>

Abstract

Mandibular defects may result from tumor ablations, trauma, or radiation necrosis. Significant segmental mandibular loss or hemimandibular loss may sometimes be replaced with mandibular implants by ENT surgeons/oral surgeons/head and neck surgeons. However, this may bring about mandibular implant failure in long-term follow-up. Mandibular implant failures usually manifest as: soft tissue atrophy, mandibular implant extrusion, infection, facial nerve involvement, facial asymmetry, derangement of occlusion and mastication, orocutaneous fistula, etc. Over 30 years, the authors have treated 102 patients with mandibular implant failure. Reconstruction may involve removal of the mandibular implant and immediate replacement of the mandibular defect with a piece of vascularized bone flap, not only to compensate for bone loss but also to replace neighboring soft tissue and possible skin defects. Frequently used flaps have been vascularized iliac bone (89/102) or vascularized fibula grafts (13/102). During follow-up, iliac bone flap reconstruction has yielded more favorable results due to its ample bone bulk and adequate soft tissue coverage. Fibula flaps with osteotomies have been associated with an increasing incidence of malunion/nonunion and subsequent easy deformation.

Keywords: mandibular reconstruction, implant failures, vascularized iliac bone flap, vascularized fibula bone flap, finesse

1. Introduction

Mandibular defects may result from tumor ablations, trauma, or radiation necrosis. Significant segmental mandibular loss or hemimandibular loss may be replaced with mandibular implants by head and neck surgeons or oral surgeons in order to terminate surgery quickly [1]. However, mandibular implant failure may ensue on long-term follow-up.

The cause of mandibular implant failure may be related to high functional demands on mastication, speech, yawning, and singing. The force and pressures imposed on the mandible by chewing, yawning, and mouth opening make mandibular implants liable to extrusion sooner or later.

Complications of mandibular implant include infection, loosening, deformation, soft tissue wasting, extrusion, capsular contracture, and sometimes the development of a skin defect owing to infection with subsequent scar contracture (**Table 1**).

Infection
Extrusion
Malocclusion
Soft tissue wasting
Loosening of implant
Facial nerve involvement
Deformation of lower face

Table 1. Mandibular implant failures.

2. Manifestations

- 1. Facial deformities
 - a. Soft tissue wasting (**Figure 1**)
 - b. Deformation (**Figures 2 and 3**)
 - c. Deviation of mandible and chin (**Figure 4**)
- 2. Extrusion of mandibular implant (**Figure 5**)
- 3. Infection (**Figure 6**)
- 4. Orocutaneous fistula (**Figure 7(a)**: extrusion of mandibular implant intraorally, (7b): mandibular implant at symphysis, **Figure 7(c)**: orocutaneous fistula)

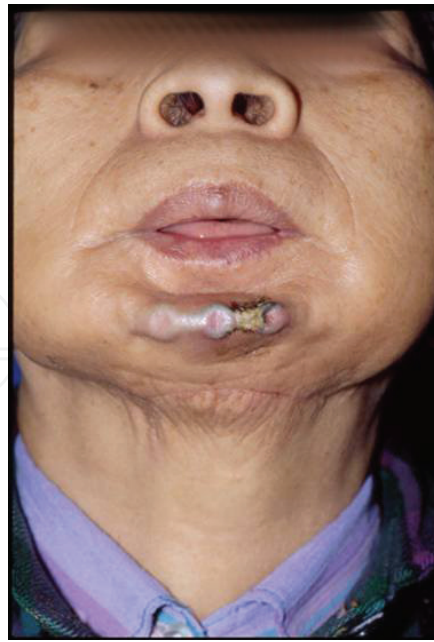

Figure 1. Soft tissue wasting.

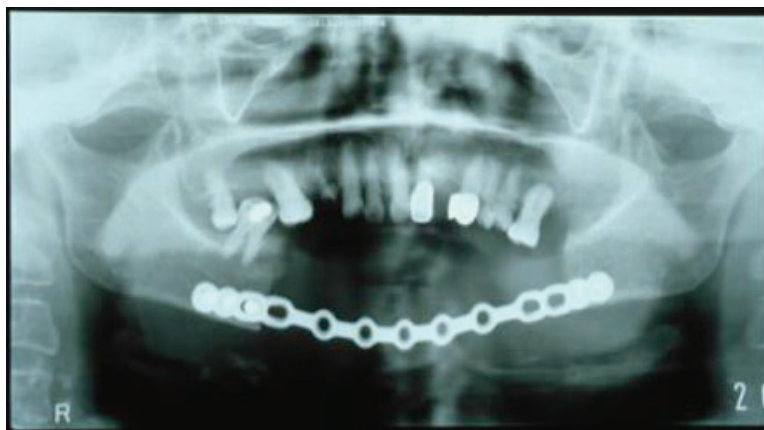

Figure 2. Immediate after operation.

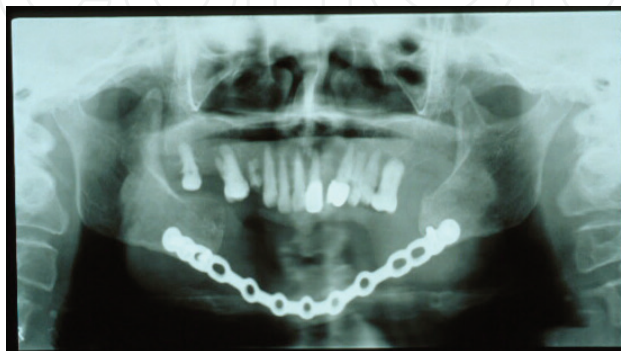

Figure 3. Angulation deformity 1 year after operation.

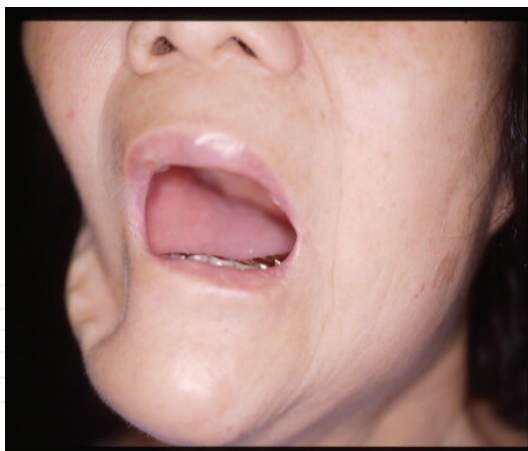

Figure 4. Deviation of mandible and chin.

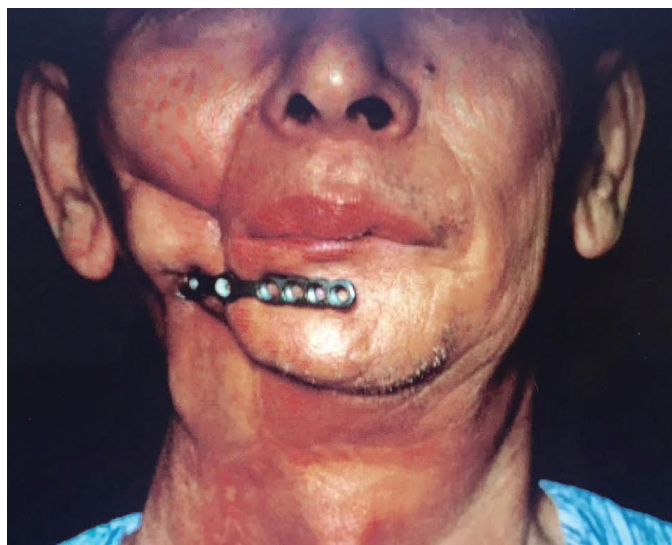


Figure 5. Extrusion of mandibular implant.

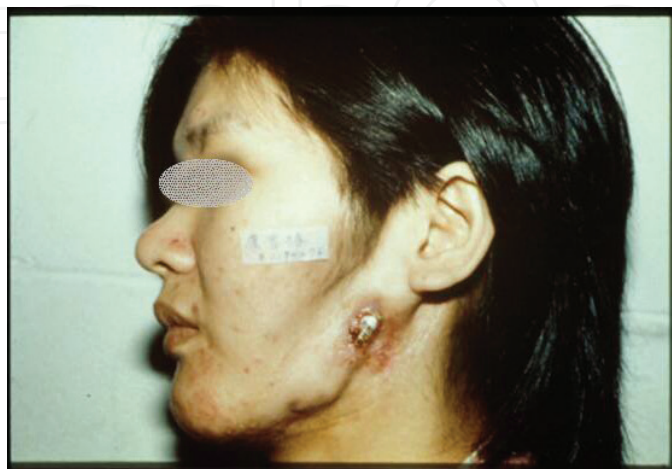

Figure 6. Mandibular implant extrusion with infection.

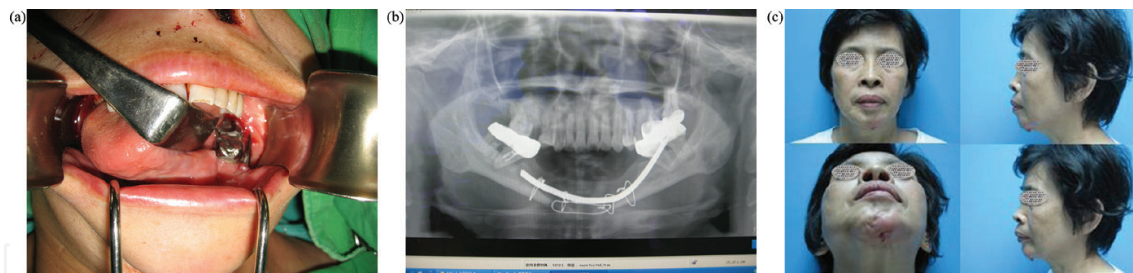

Figure 7. (a) Extrusion of mandibular implant intraorally. (b) Mandibular implant at symphysis. (c) Orocutaneous fistula.

3. Patients and methods

During the past 35 years, 102 patients with mandibular implant failures had been referred for further treatments (Table 2) [2].

The manifestations were

1. Facial deformities

Significant facial deformities usually brought the patients to seek plastic surgeons.

- a. Soft tissue wasting (Figure 8)
- b. Deviation of mandible and chin (Figure 9)

2. Extrusion of mandibular implant

Extrusion occurred intraorally (Figure 10(a)) or extraorally (Figure 10(b))

3. Infection

Infection ensued with or without extrusion of mandibular implant (Figure 11(a) and (b))

4. Orocutaneous fistula (Figure 12)

Orocutaneous fistula occurred when intraoral extrusion of the implant brought saliva passing by the implant, causing infection. This was soon supervened with an orocutaneous fistula, which never healed.

Removal of implant	36
Total	32
Partial	4
Retention of implant	66
Reconstruction with	
Vascularized iliac bone	83
Vascularized fibula	19

Table 2. Method.

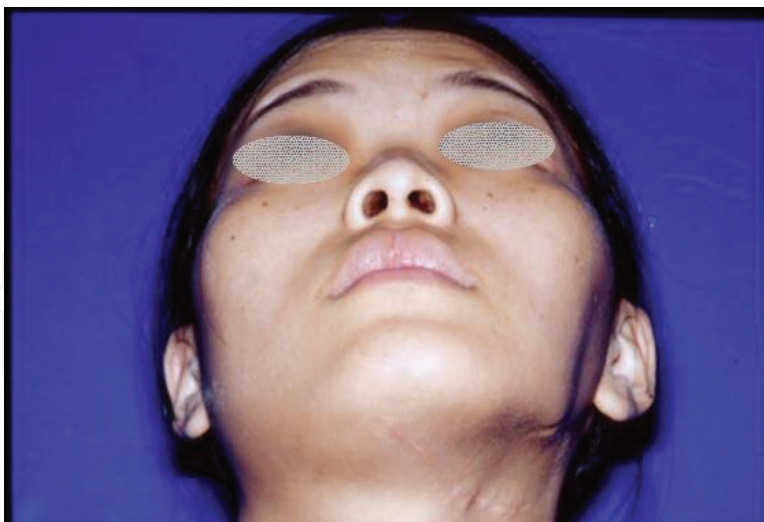

Figure 8. Soft tissue wasting at left side lower face.

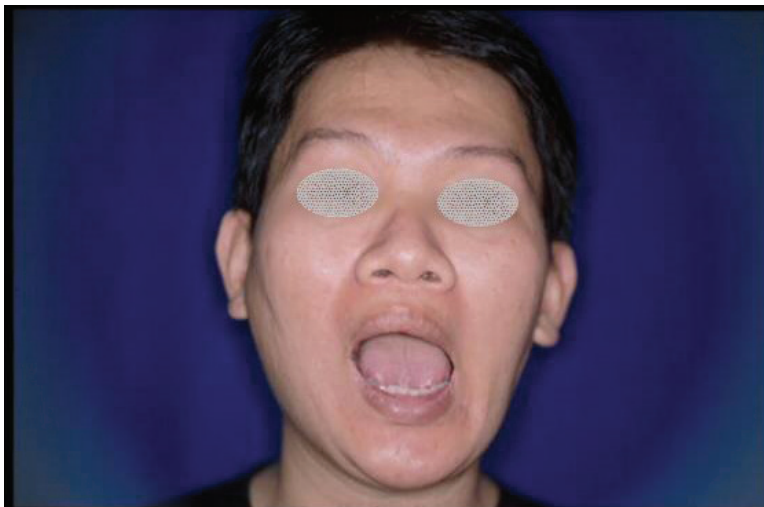


Figure 9. Deviation of mandible and chin.

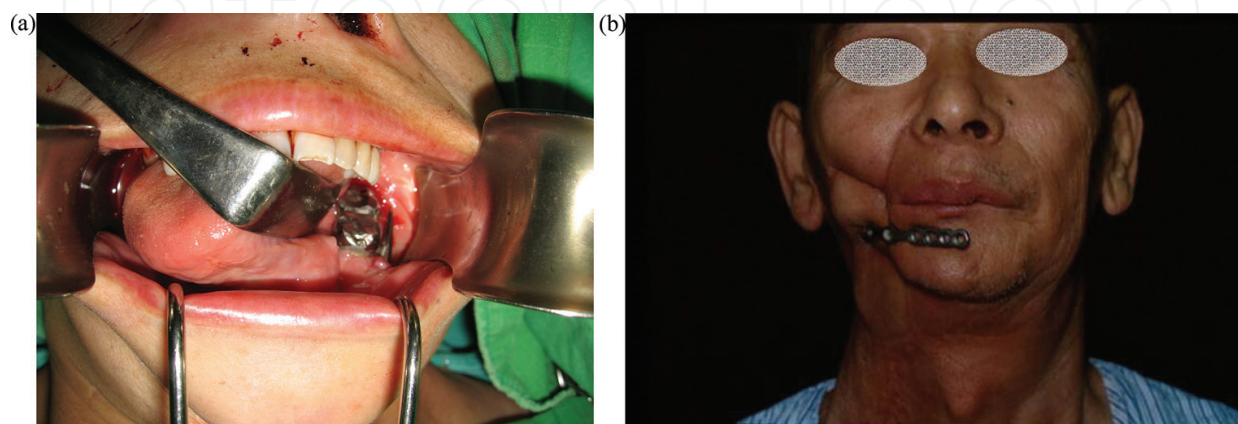


Figure 10. (a) Extrusion of mandibular implant intraorally. (b) Extrusion of mandibular implant extraorally.

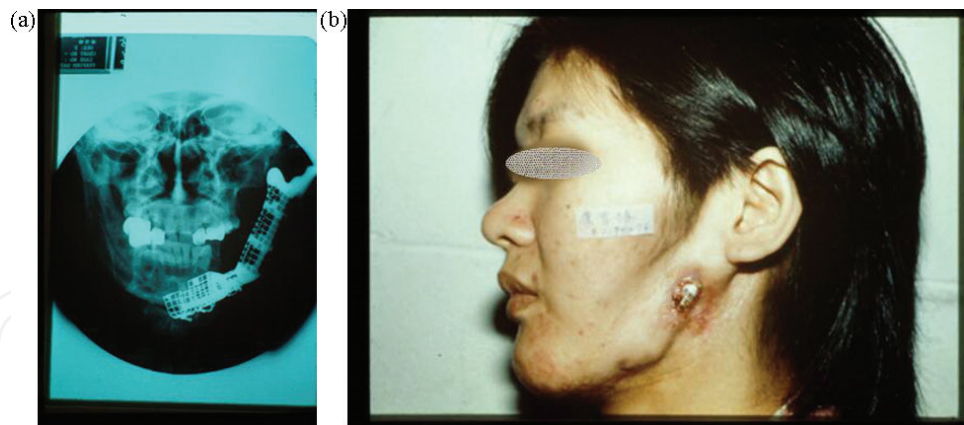


Figure 11. (a) Left mandibular implant. (b) Extrusion of mandibular implant with infection.

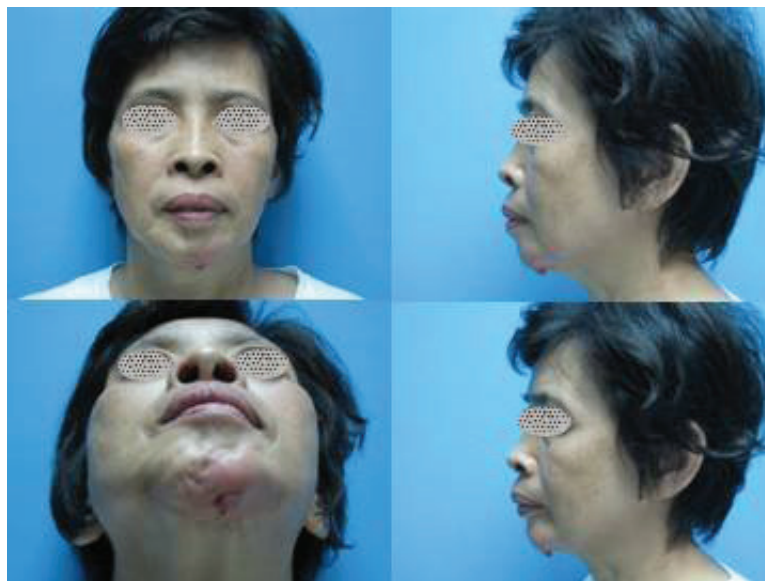

Figure 12. Orocutaneous fistula.

4. Strategy of treatment

- I. Removal of mandibular implant when the implant became extruded or got infected [3].
- II. Immediate reconstruction of missing mandibular segment or hemimandible with vascularized bone, incorporating soft tissue and skin flap for intraoral mucosal lining/external skin defect reconstruction/replacement of soft tissue defect. The vascularized bone can be an iliac bone flap or fibula flap [4, 5]. Selection of vascularized bone (**Table 3**)
 - A. Hemimandibular defect: vascularized iliac bone [2, 6–8].

With implant retained *in situ* in patients without implant extrusion.

With implant removed in patients with implant extrusion.

- B. Segmental defect**
Iliac bone flap was more preferable than fibular flap due to more bony height with ample soft tissue and skin paddle [7–10].
- C. Anterior mandibular defect: vascularized iliac bone**
- D. Lateral segment defect: fibula flap [5]**
- III. Repositioning of skin flap**
Banked external skin flap could be moved intraorally after the subsidence of tissue swelling.
- IV. Reshaping of bony contour**
After bony union, some imperfect bony contour may be reshaped [4].
- V. Removal of the mandibular plate**
- VI. For nearly hemimandibular reconstructions, overzealous removal of the reconstruction plate for further reconstruction might jeopardize the overlying facial nerve which had already been surrounded by fibrosis and might have assumed a nonanatomical path. Thereafter, surgical manipulation in this area to create space might stretch the facial nerve overlying the implant and might lead to its inadvertent injury. For this reason, the plate was either partially removed or not removed at all as long as it had not been already become extruded or infected; instead, it was overlaid with a piece of vascularized bone flap.**

I. Removal of Mandibular implant when the implant become or got in fected.

II. Immediate reconstruction of missing mandibular segment.

(A) Hemimandibular defect:

Vascularized iliac bone

With implant retained *in situ*

With implant removed (total or partial)

(B) Segmental defect:

Iliac bone flap is more preferable than fibular flap due to more bony height

(C) Anterior mandibular defect:

Vascularized iliac bone

(D) Lateral segment defect:

Fibula flap

III. Reposition of skin flap

Banked external skin flap can be moved inwardly with subsidence of tissue swelling

IV. Reshaping of bony contour

After bony union, some imperfect bony contour may be reshaped

Table 3. Summary of operation technique.

5. Problems of reconstruction with implant failure and removal of the implant

1. Scarring and capsule formation around the implant.
2. Difficulty in dissecting and approaching the glenoid fossa.
3. Lack of a clear plane to expand the pocket to accommodate a vascularized bone mimicking the ascending ramus.
4. Possibility of facial nerve injury or traction during dissection or expansion.
5. Placement of incision should be carefully designed since there had been soft tissue atrophy and thinning of skin (**Figure 13(a)** and **(b)**).

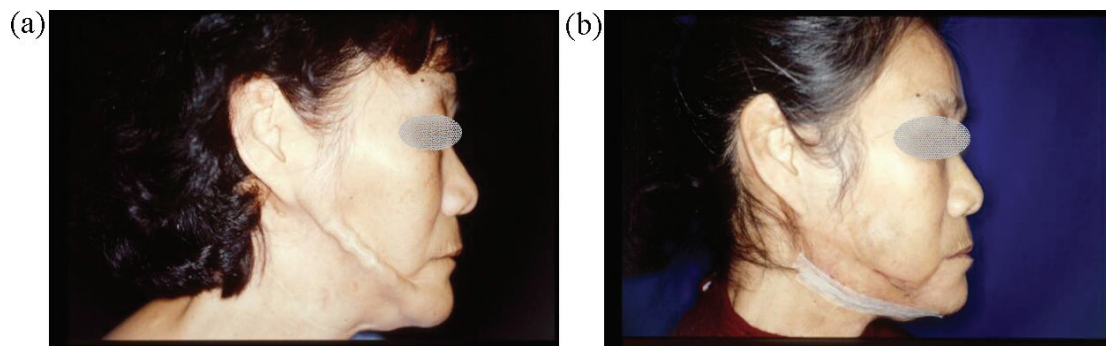


Figure 13. (a) Thinning of skin overlying mandibular implant. (b) Reconstruction with iliac bone flap with upper neck transverse incision.

6. Case presentations

- A. Hemimandibular reconstruction with mandibular tray implant (**Figure 14(a–d)**).
 1. Removal of mandibular implant.
 2. Immediate hemimandibular reconstruction with vascularized iliac bone flap.
 3. Fascia lata sling operation to hold the mandibular body to temporal muscle and fascia.
 4. Facial recontouring, soft tissue, and bone.
- B. Facial asymmetry after resection of mandibular ameloblastoma and mere reconstruction with mandibular reconstruction plate (**Figure 15(a)** and **(b)**).
- C. Young man, aged 25 years, suffered from soft tissue wasting 1 year after sole mandibular implant insertion and his status after subcondylar mandibular reconstruction (**Figure 16(a–d)**).
- D. Young man, aged 28 years, suffered from soft tissue wasting and chin deviation 6 months after resection of a left side mandibular ameloblastoma and subsequent reconstruction with

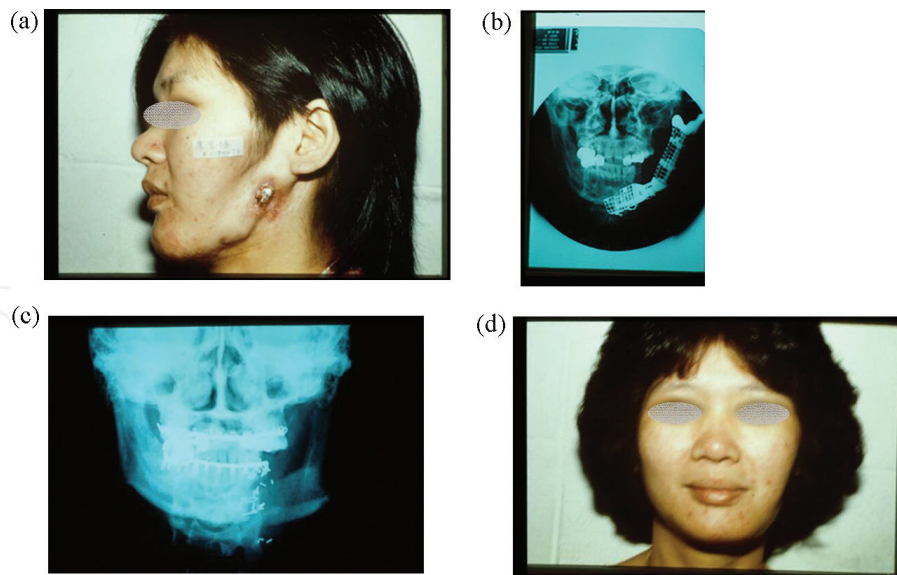


Figure 14. (a) Extrusion of mandibular implant with infection, soft tissue wasting and facial deformity. (b) Preoperative roentgenography. (c) Postoperative roentgenography after reconstruction with vascularized iliac bone flap. (d) Postoperative photo showing satisfactory facial contour.

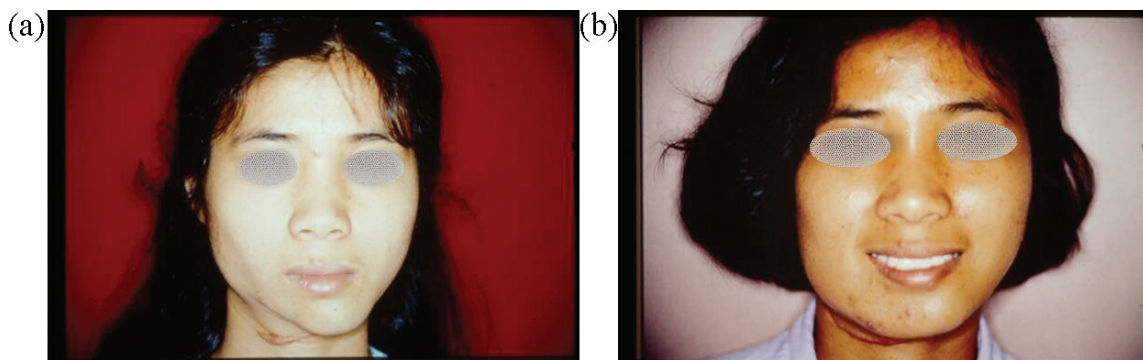


Figure 15. (a) Deformation of right side mandibular implant with deviation of chin. (b) Reconstruction with iliac bone flap, regained more symmetric facial contour.

mandibular reconstruction plate only (**Figure 17(a)**). He received mandibular reconstruction with retention of implant by onlaying a vascularized iliac bone flap on the reconstruction plate with osteosynthesis at the medial end of the mandibular section margin (**Figure 17(b)** and **(c)**). Picture 15 years after left hemimandibular reconstruction by an onlaying vascularized iliac bone flap on the reconstruction plate. No soft tissue atrophy or wasting was noticed. Occlusion was satisfactory with symmetric facial expression (**Figure 17(d)**).

- E. This 24-year-old lady suffered from left side facial wasting after sub-hemimandibular reconstruction with reconstruction plate only (**Figure 18(a)**). She received mandibular reconstruction with an onlaying vascularized iliac bone flap with retaining the titanium reconstruction plate (**Figure 18(b–d)**).
- F. A 66-year-old lady suffered from soft tissue wasting, deformation with impending extrusion of the implant 1 year after reconstructing a segmental symphyseal defect with a

titanium mandibular reconstruction plate (**Figure 18(a–c)**). Removal of anterior segment mandibular implant and reconstruction with an iliac bone flap resulted in satisfactory bone union and facial contour (**Figure 18(d)**).

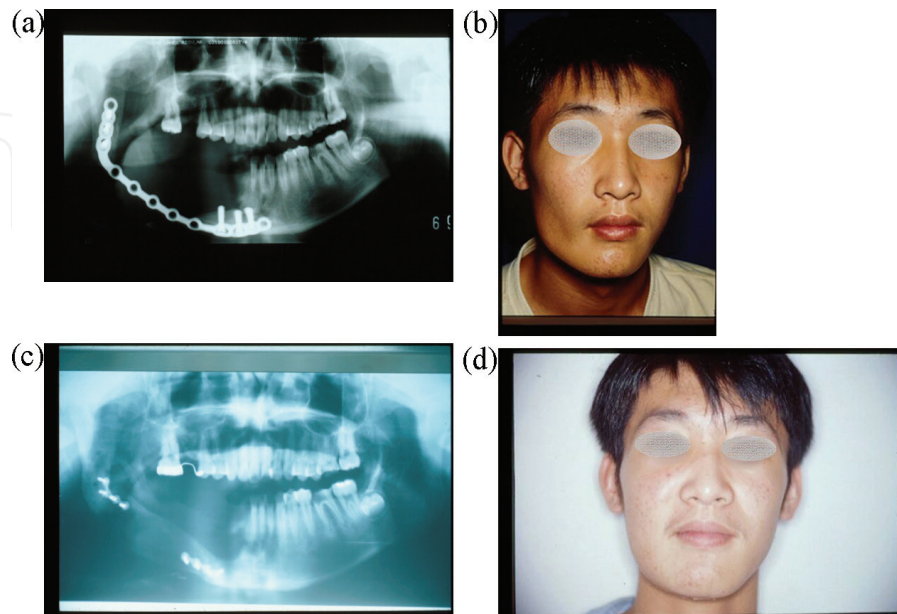


Figure 16. (a) Mandibular implant only, subcondylar hemimandibular reconstruction. (b) Soft tissue wasting 1 year after mandibular implant only subcondylar mandibular reconstruction. (c) Removal of reconstruction plate and replacement with vascularized iliac bone flap. (d) Postoperative photograph, s/p removal of reconstruction plate and replacement with vascularized iliac bone flap.

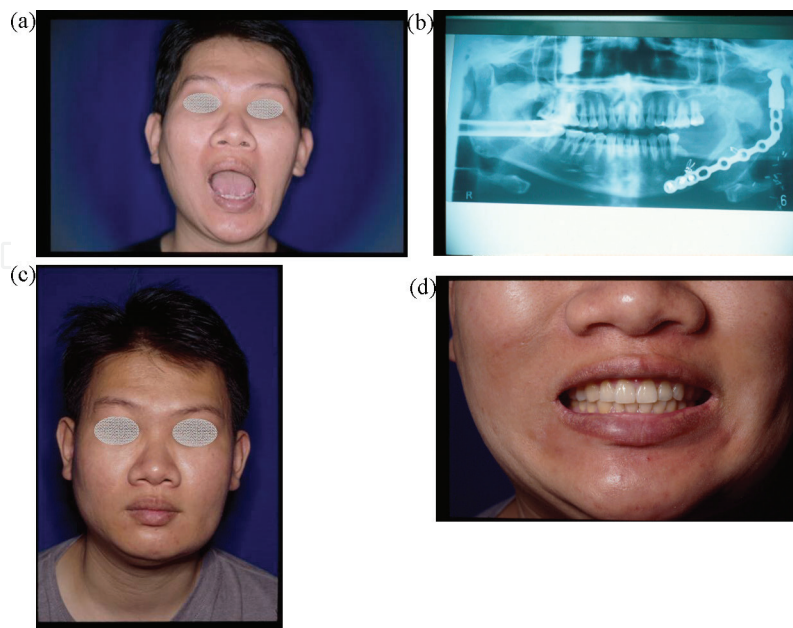


Figure 17. (a) Soft tissue wasting with deviation of chin. (b) Reconstruction was performed with retention of implant by onlaying a vascularized iliac bone flap on the reconstruction plate with osteosynthesis at the medial extreme. (c) Postoperative photography. (d) 15 years after left hemimandibular reconstruction by onlaying vascularized iliac bone flap on reconstruction plate, no soft tissue atrophy, wasting noticed. Occlusion was satisfactory with symmetric facial expression.

- G.** This 27-year-old young man received a hemimandibular implant reconstruction after resection of an ameloblastoma. However, it was complicated with infection and extrusion and ended up with implant removal, leaving a significant facial deformity (**Figure 19(a)**). The lateral segment mandibular defect was reconstructed with a fibula flap incorporating with a titanium mandibular condyle (**Figure 19(b)** and **(c)**) [5].

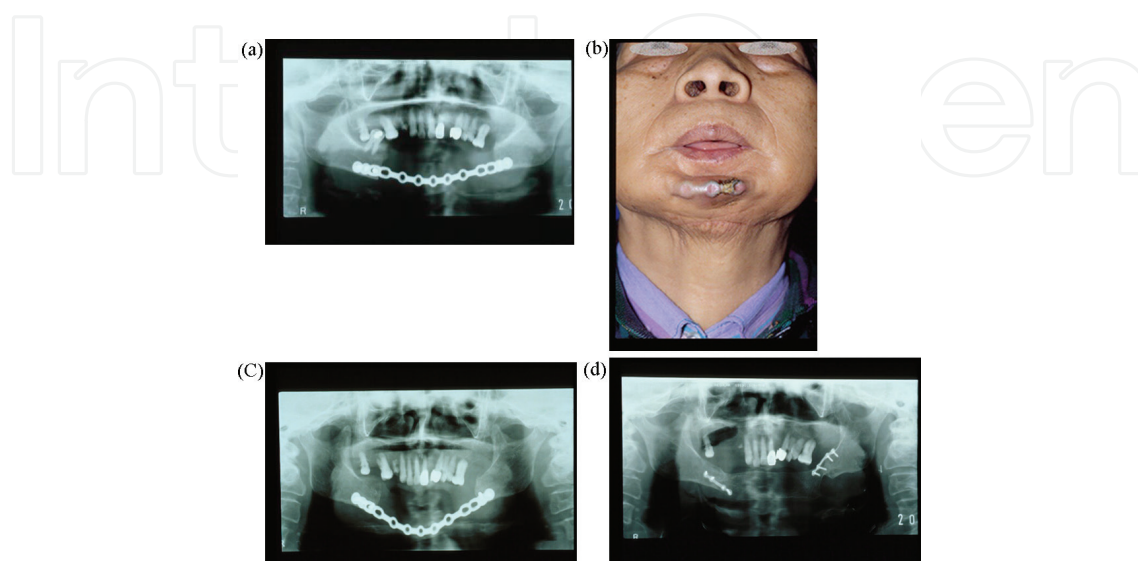


Figure 18. (a) Reconstruction plate only for reconstruction of symphyseal defect after resection of mandibular ameloblastoma. (b) Impending extrusion of symphyseal reconstruction plate. (c) Panex at 1 year post operation showing deformation of mandibular reconstruction plate. (d) Removal of anterior segment mandibular implant and reconstruction with iliac bone flap resulted in satisfactory bone union and facial contour.

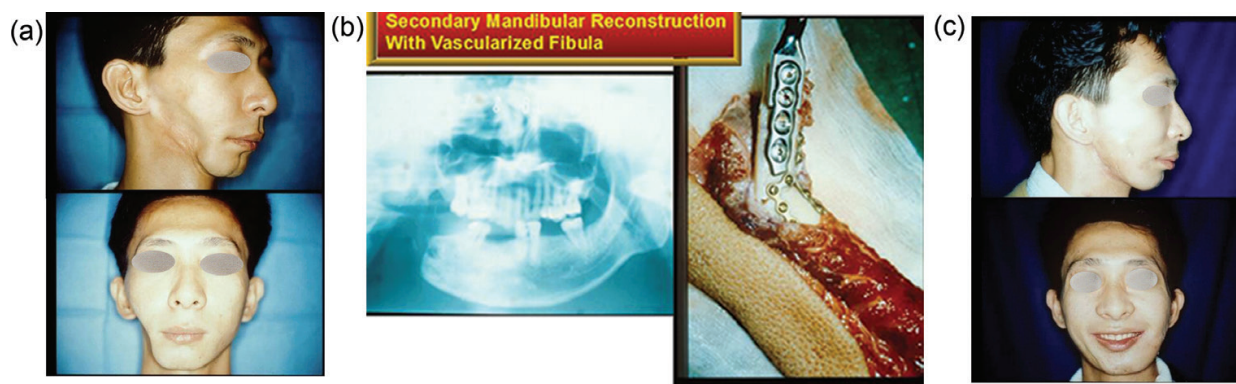


Figure 19. (a) This 27-year-old young man received hemimandibular reconstruction with implant after resection of ameloblastoma, however, complicated with infection and extrusion, ended up with removal of implant, leaving significant facial deformity. (b) The lateral segment mandibular defect was then reconstructed with fibula flap 1 year later. (c) Postoperative photos showing regain of facial contour and symmetry after reconstruction with fibula flap.

Ancillary procedures:

Ancillary procedures are always required to achieve satisfactory functional and aesthetic results are shown in (**Table 4**) and (**Table 5**).

- A. Hemimandibular reconstruction with implant (**Figure 20(a–d)**).
- B. Soft tissue wasting above the left mandibular implant area (**Figure 21(a–c)**).
- C. Secondary resurfacing of the lower sulcus with a banked iliac bone skin flap with revolving door technique to facilitate denture fitting and restoration of chin profile (**Figure 23(a–f)**).

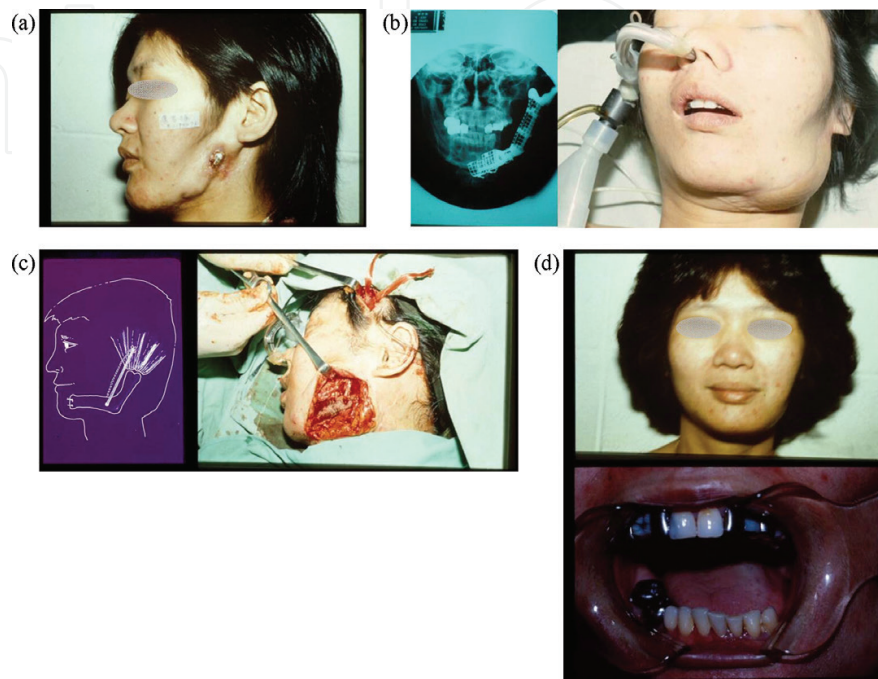

Figure 20. (a) Mandibular implant extrusion with infection. (b) Removal of mandibular implant and reconstruction with vascularized iliac bone flap. Sagging down of the reconstructed mandible was noticed due to lack of holding power of the temporal muscle to coronoid process. (c) Fascial at a sling operation was performed to hold the reconstructed mandible to the temporalis muscle. (d) Post-op front view with adequate mouth opening shown.

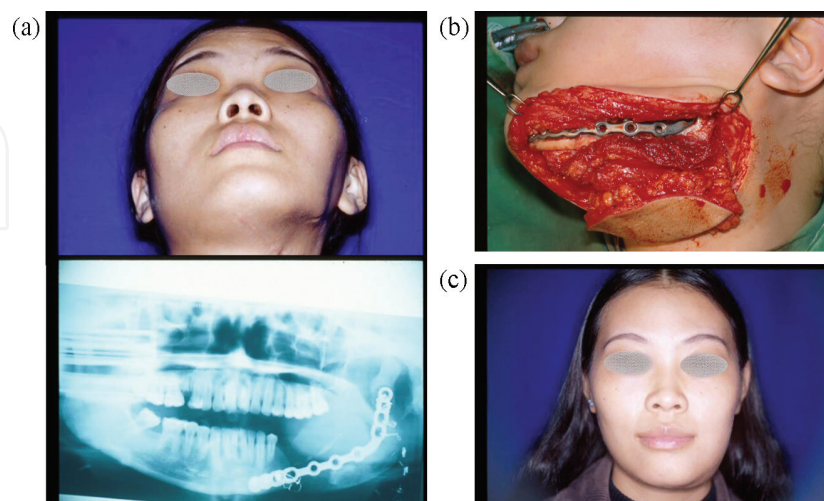


Figure 21. (a) Retention of mandibular implant and onlaying with a vascularized iliac bone flap. (b) Vascularized iliac bone osteocutaneous flap, placed overlying the mandibular implant with osteosynthesis. (c) Postoperative result: soft tissue wasting and atrophy ceased with long term follow up.

Mouth opening
Oral competence
temporo-mandibular joint function
Deepening of buccogingival sulcus
Feasibility in fixation of denture
Osseointegration

Table 4. Functional considerations.

Recontouring of mandibular margin
Soft tissue repositioning
Sliding genioplasty
Fascial sling operation for hemimandibular reconstruction
Myectomy of contralateral lower lip depressors
Z-plasty, W-plasty on scars
Reduction of bulk
Commissuroplasty
Fat graft, fascial graft

Table 5. Aesthetic considerations.

7. Results

In 102 patients presenting with mandibular implant extrusions, the primary etiologies were mostly ameloblastoma (100/102), fibroma (1/102), and malignant mixed tumor (1/102). Before extrusion of the implant occurs, the implant may be retained and overlaid with a vascularized bone.

Keeping the mandibular implant and overlaying it with a vascularized iliac bone flap can achieve not only a good functional result (**Table 4**) If extrusion of the implant has occurred, infection will supervene, and inevitably the implant should be removed totally. Reconstruction may involve removal of the mandibular implant and immediate replacement of the mandibular defect with a piece of vascularized bone flap, not only to compensate for bone loss, but also to replace neighboring soft tissue and possible skin defect. With the night strategy, good functional outcome and satisfactory aesthetic result can always be achieved, but also a satisfactory aesthetic outcome (**Table 5**). Soft tissue wasting and atrophy ceased with long-term follow-up (**Figure 22(a)** and **(b)**).

For reconstruction of anterior segment mandibular defect, vascularized iliac bone grafting associated with external banking of the skin and soft tissue, followed by turning the skin flap and soft tissue intraorally with revolving door technique, can resurface the anterior vestibule and augment the chin profile, a procedure that also facilitate fitting lower denture fitting (**Figure 23(a–f)**).

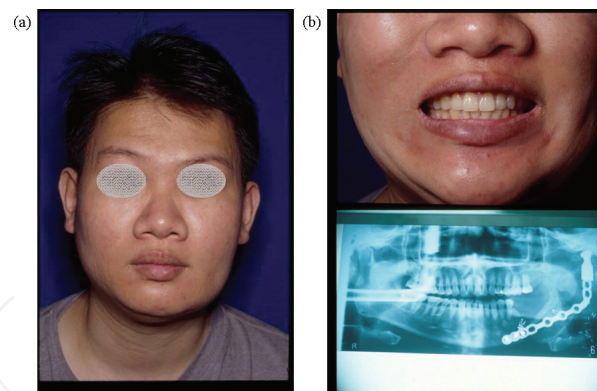


Figure 22. (a) Retention of mandibular implant and overlying with vascularized iliac bone flap can achieve not only good functional result, but also satisfactory aesthetic outcome. (b) Post-op result: soft tissue wasting and atrophy ceased with long-term follow-up.

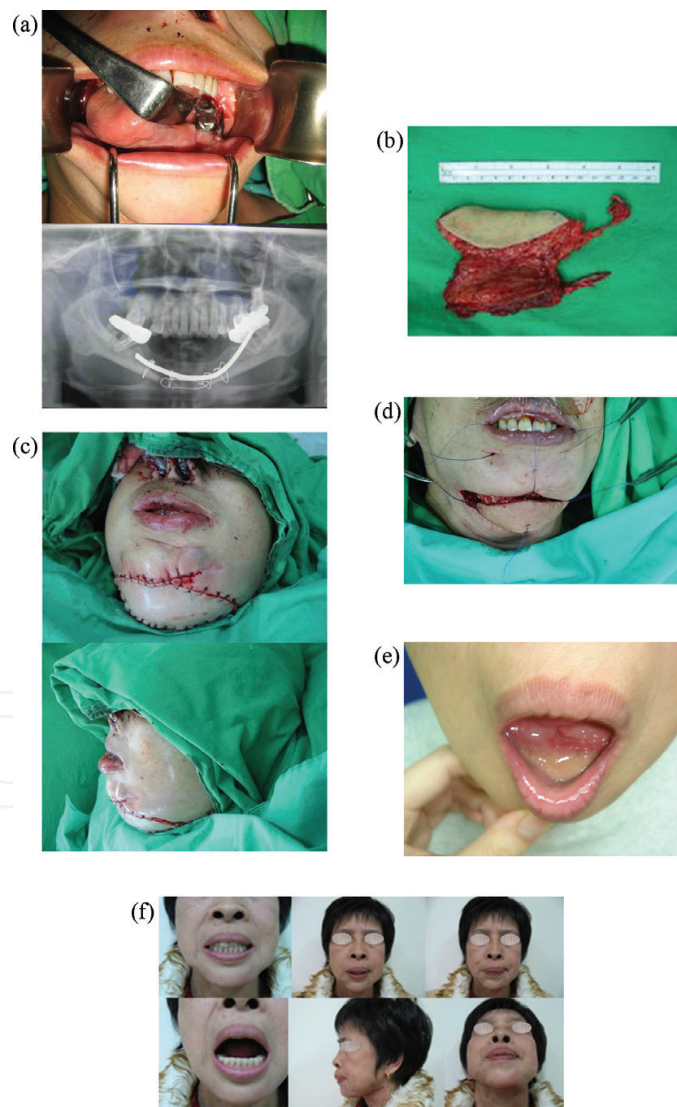


Figure 23. (a) Pre-op. (b) Harvesting of iliac bone osteomyocutaneous flap. (c) Insetting of flap. (d) Flap transposition with revolving door technique. (e) Anterior sulcus reconstruction was completed by employing revolving door technique. (f) Reconstruction of lower sulcus by mobilizing the banked skin flap inward with revolving door technique can accommodate further denture fitting, resulting in good functional and aesthetic result.

8. Discussions

Mandibular defects may result in significant facial disfigurement. When the defect is associated with inner mucosal defect and/or external skin defect, the situation become even more complicated [11]. Conventional bone grafting can only succeed in less than 5 cm segmental defect or partial thickness defect.

Mandibular implants made of different materials (titanium, vitellium, etc.) and having different brands have been used by many head and neck surgeons to reconstruct segmental mandibular defects or hemimandibular defects. However, they are fraught with miscellaneous miserable complications [12].

In this article, we have presented many kinds of failures resulting from mandibular reconstructions with implants.

Reconstructions problems associated with implant failure include:

- scarring and capsule formation around the implant,
- difficulty in dissecting and approaching the glenoid fossa,
- lack of a clear plane to expand the pocket in order to accommodate a vascularized bone graft camouflaging the ascending ramus, resulting in
- possibility of facial nerve injury or traction during dissection or expansion.
- Careful planning of the incision should be elaborated because of soft tissue atrophy and thinning of skin on top of the mandibular implant.

The choice of bone flap for reconstructions is iliac bone flap for anterior mandibular, segmental and hemimandibular reconstructions while, for lateral mandibular defect, fibular flap is preferred.

9. Conclusions

The fate of various reconstructive modes for major mandibular defects has been presented. Selecting the ideal modes of reconstruction for significant mandibular defects is of paramount importance if an uncomplicated outcome and excellent functional result without facial disfigurement are to be achieved.

Secondary mandibular reconstruction after implant failure may cause facial nerve injury due to scarring which result in difficulty in approaching the glenoid fossa.

When mandibular reconstruction with implant fails, extrusion and infection may ensue and necessitate removal of the implant. In this situation, soft tissue wasting, fibrosis, and contracture will supervene. The overlying facial nerve will be endangered during further reconstruction consequent upon creating additional space to accommodate a vascularized bone flap.

A fascia lata sling operation is always required in hemimandibular reconstruction in patients with the implant failures, in order to hold the reconstructed mandible to an anatomical and functional place.

The use of mandibular implants as the sole reconstruction tool for significant mandibular defects should be limited. Since patients suffering from mandibular ameloblastomas are mostly young, it is advised that vascularized bone be the ideal choice in major mandibular reconstructions.

Acknowledgements

The authors are indebted to Ms. Hsiao-Fang Wei and Ms. Fang-I Chu for their assistance in preparing and finishing this manuscript. Without their endeavor, this chapter would not come out so soon.

Author details

Shih-Heng Chen^{1,2}, Hao-Chih Tai², Tai-Ju Cheng², Hung-Chi Chen³, An-Ta Ko⁴, Tyng-Luan Roan⁴, Yo-Shen Chen⁴ and Yueh-Bih Tang^{2,4*}

*Address all correspondence to: phoebetang0103@gmail.com

1 Chang-Gung Memorial Hospital, Taoyuan, Taiwan

2 National Taiwan University Hospital, Taipei, Taiwan

3 China Medical University Hospital, Taichung City, Taiwan

4 Far-Eastern Memorial Hospital, New Taipei City, Taiwan

References

- [1] Hidalgo DA. Deep circumflex iliac artery free flaps. In: Shaw WW, Hidalgo DA, editors. *Microsurgery in Trauma*. Mount Kisco, New York: Futura Publishing Company, Inc; 1988
- [2] Chen YB, Chen HC, Hahn LH. Major mandibular reconstruction with vascularized bone grafts: Indications and selection of donor tissue. *Microsurgery*. 1994;**15**(4):227-237
- [3] Boyd JB. Use of reconstruction plates in conjunction with soft-tissue free flaps for oro-mandibular reconstruction. *Clinics in Plastic Surgery*. 1994;**21**(1):69-77
- [4] Hidalgo DA. Aesthetic improvements in free-flap mandible reconstruction. *Plastic and Reconstructive Surgery*. 1991;**88**(4):574-585; discussion 586-587

- [5] Roan TL, et al. New modified free chimeric fibular flap design for head and neck reconstruction. *Head & Neck*. 2013;**35**(8):E231-E233
- [6] Boyd JB. The place of the iliac crest in vascularized oromandibular reconstruction. *Microsurgery*. 1994;**15**(4):250-256
- [7] Chen SH, et al. Reconstruction for osteoradionecrosis of the mandible: Superiority of free iliac bone flap to fibula flap in postoperative infection and healing. *Annals of Plastic Surgery*. 2014;**73**(Suppl 1):S18-S26
- [8] Taylor GI. Reconstruction of the mandible with free composite iliac bone grafts. *Annals of Plastic Surgery*. 1982;**9**(5):361-376
- [9] Taylor GI, Townsend P, Corlett R. Superiority of the deep circumflex iliac vessels as the supply for free groin flaps. *Plastic and Reconstructive Surgery*. 1979;**64**(5):595-604
- [10] Chen YB, Chen SH, Chen HC. *Finesse in Aesthetic Facial Recontouring*. Oral Cancer, InTech Open Science, Croatia, 2012
- [11] Chen SH, et al. Features of oral cancers in Taiwanese females with free tissue transfers: Based on NTUH data. *Plastic and Reconstructive Surgery R.O.C.* 2009;**18**(4):311-320
- [12] Chen YB, Hahn LJ, Yao YT. Long-term survival of patients with mandibular osteosarcoma. *Journal of the Formosan Medical Association*. 1999;**98**(11):773-777