

We are IntechOpen, the world's leading publisher of Open Access books Built by scientists, for scientists

6,900

Open access books available

186,000

International authors and editors

200M

Downloads

Our authors are among the

154

Countries delivered to

TOP 1%

most cited scientists

12.2%

Contributors from top 500 universities



WEB OF SCIENCE™

Selection of our books indexed in the Book Citation Index
in Web of Science™ Core Collection (BKCI)

Interested in publishing with us?
Contact book.department@intechopen.com

Numbers displayed above are based on latest data collected.
For more information visit www.intechopen.com



Permanent Maxillary and Mandibular Incisors

Mohammed E. Grawish, Lamyaa M. Grawish and
Hala M. Grawish

Additional information is available at the end of the chapter

<http://dx.doi.org/10.5772/intechopen.69542>

Abstract

The permanent incisors are the front teeth that erupt between 6 and 8 years of age. They are eight in number, four upper and four lower, two centrals and two laterals. They have sharp biting surfaces designed for shearing and cutting of food materials into small chewable pieces. They are the teeth most visible to the others during eating, smiling and talking, and thus, they have high aesthetic value for the individuals. The unique characteristics, arch position, function, development and chronological age of each tooth will be highlighted. In addition, the different aspects with their geometric outlines, outlines and surface anatomy of these teeth will be described. A brief explanation about the pulp cavity, tooth socket and normal occlusion for each tooth will be included.

Keywords: anatomical feature, mandibular central, mandibular lateral, maxillary central, maxillary lateral, occlusion, pulp cavity, tooth socket

1. Introduction

Identifying tooth number, size and shape has an important clinical significance in many dental disciplines, particularly pediatric dentistry, orthodontics, restorative dentistry and oral surgery [1]. Mammalian dentition is characterized by heterodonty, in which both the upper and lower teeth are differentiated morphologically into four types: flat, chisel-shaped incisors, conical canines, bicuspid premolars and multicuspid molars in the mesiodistal direction [2]. The dental formula for the permanent dentition in human beings consists of two incisors, a canine, two premolars and three molars in each half of the jaw [3]. There are four incisors per arch, two per quadrant. The first or the central incisor is next to the midline. The second or the lateral incisor is distal to central [4]. The importance of the recognition of morphological and anatomical-functional characteristics of teeth, seeking adaptation to individual conditions, has been acknowledged [5].

2. General character

1. The word incisor is derived from the Latin word incidere, "to cut."
2. They are the front teeth existing in most heterodont mammals.
3. They are located in the premaxilla above and the mandible below.
4. Maxillary incisors exist in the premaxilla; mandibular incisors are the teeth that occlude with them.
5. They are eight in number; four maxillary and four mandibular, two on each side of the middle line, one central and one lateral.
6. The maxillary and mandibular central incisors are the first teeth centralized in both sides of the midline, with the mesial of each one is on contact with the mesial surface of the other.
7. In some individuals, the two maxillary central incisors are separated by a space called diastema.
8. The maxillary and mandibular lateral incisors are the teeth located distally from either maxillary or mandibular central incisors and mesially from either maxillary or mandibular canines.
9. The maxillary central is larger in all dimensions than the maxillary lateral, but the reverse is the true for the mandibular central and lateral.
10. The mesiodistal dimension is greater than the labiopalatal dimension in the maxillary incisors, while the labiolingual dimension is greater than the mesiodistal dimension in mandibular incisors.
11. They developed from four lobes, three labially and one lingually (palatally), the lingual (palatal) lobe being represented by the cingulum. Each labial lobe of the incisor terminates incisally in rounded eminence known as mamelon.
12. Unworn, newly erupted incisors have three small mamelons forming the incisal ridge. These mamelons are worn down with use to flat edge.
13. All incisors except the mandibular central incisor have rounded distoincisor angle compared to the mesioincisor angle as the mandibular central incisor has almost symmetrical anatomy.
14. The geometric outlines of the labial and lingual (palatal) surfaces are trapezoid while those for the proximal surfaces are triangular in shapes.
15. In some instances, they have vertical mesial and distal developmental depressions on the root surfaces to prevent tooth rotation and provide tooth anchorage.
16. The incisal tip from the proximal aspects is on one line with the root apices (root axis) in maxillary incisors, while there is a lingual tilting in mandibular incisors as the incisal tip is lingually positioned in relation to the root apices.

17. Maxillary incisors overlap the mandibular incisors, vertically and horizontally producing what is called overjet and overbite.
18. The mesial surfaces of the maxillary and mandibular central incisors are on one line at the median plane. With the exception of mandibular central incisor, each incisor occludes with two antagonists from the opposite arch.
19. They have lingual (palatal) convergence as the mesiodistal dimension of the lingual (palatal) surface less than the labial one.
20. The eruption date of the incisors ranges from 6 to 9 years. The specific sequence within this range is centrals preceding laterals, and mandibular incisors precede maxillary incisors.
21. They have only one root. The root canal systems of these single-rooted teeth often have three pulp horns and a single root canal. Over 40% of the mandibular incisors have two canals, but only just over 1% has two separate foramina.
22. The socket border of the maxillary central incisor is regular and rounded; its interior is evenly cone-shaped, accommodating the shape of the conical root. The upper lateral incisor socket is smaller in cross section but deeper than the socket of the upper central incisor. Meanwhile, the socket of mandibular central is flattened on its mesial surface and is somewhat concave distally to accommodate the developmental depression on the root. The socket of mandibular lateral is similar to that of central incisor with two variations; the socket is larger and deeper.
23. Anterior superior dental branch that arises from the infraorbital artery supplies maxillary incisors. Incisive branch of the inferior dental artery supplies the mandibular incisors. The infraorbital artery and inferior dental artery are the branches of the maxillary artery which is a terminal branch from the external carotid artery.
24. Anterior superior dental nerve originates from the infraorbital nerve. A branch from the maxillary nerve supplies the maxillary incisors, while the incisive nerve originates from the inferior dental nerve and a branch of the mandibular nerve supplies the mandibular incisors. The maxillary and mandibular nerves are the second and third divisions of the trigeminal nerve.
25. The venous drainage for maxillary incisors is to the anterior superior dental vein, while that for mandibular incisors is to the inferior dental vein. The anterior superior and the inferior dental veins drain to the maxillary vein, to the retromandibular vein and finally to the external jugular vein.
26. The maxillary and mandibular incisors drain the lymph into submental and upper deep cervical lymph nodes.
27. The major function of the incisors is biting, shearing or cutting food material during mastication by their incisal ridges or edges. They play important roles in speech and aesthetic.

The mandibular incisors differ from the maxillary ones in the followings:

28. Mandibular incisors are smaller than maxillary incisors in all dimensions.
29. They have smaller mesiodistal dimension than any other teeth.
30. Their crowns labially are fan-shaped.
31. The mesiolabial and distolabial developmental grooves are less prominent in mandibular incisors.
32. Mandibular incisors have less developed lingual anatomy.
33. Lingual pit and fissure are less common in mandibular incisors compared to maxillary ones.
34. Their contact areas are near the incisal ridges mesially and distally.
35. Attrition occurs on the incisal ridge, labially and not lingually as the maxillary incisors.
36. Their roots are flattened mesiodistally and are longer in proportion to the crown. The roots are frequently grooved on the mesial and distal surfaces with distal groove being more marked.

3. Permanent maxillary central incisor

3.1. Unique characteristics

This is the most noticeable tooth in the mouth. The general crown size exceeds that of any other incisor in either arch. The mesiodistal crown dimension is the greatest of any anterior tooth. The mesial curvature of cervical line toward the incisal is the greatest of any tooth. The incisal ridge is centralized labiopalatally (see **Figure 1**).

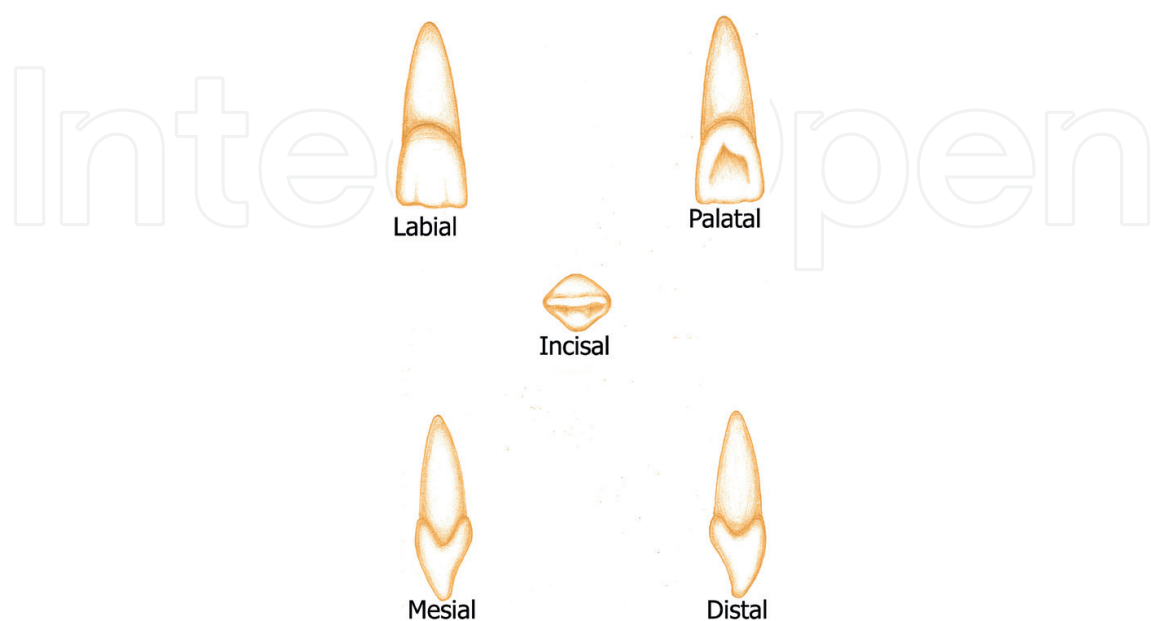


Figure 1. Diagram showing the labial, palatal, mesial, distal and incisal aspects of the maxillary permanent central incisor.

3.2. Arch position

The maxillary central incisors are the two teeth which are adjacent to the midline in the maxillary arch. They share a mesial contact with each other and have a distal contact with the lateral incisors.

3.3. Function

The main function is biting, cutting, incising and shearing the food materials. They also play an important role in the aesthetic and phonetic functions of the human teeth.

3.4. Development

It developed from four lobes, three labially and one palatally, the palatal lobe being represented by the cingulum. Each labial lobe of the incisor terminates incisally in rounded eminence known as mamelon [6] (Table 1). The mesiodistal and labiopalatal measurements for maxillary permanent central incisor (mm) are shown in Table 2.

Appearance of dental organ	5 months intrauterine life (I.U.L.)
Beginning of calcification	3–4 months
Crown completed	4–5 years
Eruption	7–8 years
Root completed	10 years

Table 1. Chronology table of maxillary permanent central incisor.

Crown length	Root length	MD at contact area	MD at cervical line	LP at crest of curvature	LP at cervical line	Curvature of CL	
						M	D
10.5	13.0	8.5	7.0	7.0	6.0	3.5	2.5

Table 2. Measurements in millimeter of maxillary permanent central incisor.

3.5. Labial aspect

3.5.1. Geometric outline

It is trapezoidal in shape with the shortest uneven side toward the cervix and the longest one toward the incisal ridge.

3.5.2. Outlines

Cervical line: it is line that demarcates the anatomical crown and the anatomical root. This line is a semicircle and convex root wise. It is found at the center of the tooth aspect and closer to the apex of the root.

Mesial outline: is straight or slightly convex from the cervical line to the mesial contact area (the point furthest away from the central axis of the tooth).

Distal outline: more convex than the mesial outline.

Incisal outline: after the mamelons are worn away, the incisal edge of the maxillary central incisor is straight mesiodistally.

Contact areas: the mesial contact is in the incisal third near the mesioincisal angle, while the distal contact is more cervically positioned at the junction between the incisal and middle thirds.

Angles: the distoincisal angle is not as sharp as the mesioincisal angle.

Root: from this aspect, the root has a cone shape with blunt apex. Although there is a numerous variation between populations, the length of the root is usually longer than the length of the crown by about 3 mm.

3.5.3. Surface anatomy

The labial surface is generally convex in mesiodistal and incisocervical dimensions. The convexity is normally greatest in the cervical third (cervical ridge) and tends to be more closely to approach flatness toward the incisal third. The mesiolabial and distolabial developmental grooves that denote the union of the three labial lobes are straight, shallow depressions, which extend from the incisal edge toward the cervical, and fade out, in the middle third. Faint imbrication curved lines (preikymata), which roughly parallel the cemento-enamel junction in the cervical third, are always present in the newly erupted incisors (see **Figure 2**).




Figure 2. Labial aspect of maxillary permanent central incisor.

3.6. Palatal aspect

3.6.1. Geometric outline

It is trapezoidal in shape with the smallest uneven side toward the cervix.

3.6.2. Outlines

Cervical line: the cervical outline has a slightly greater depth of curvature apically than on the labial surface and is asymmetrical, with its area of maximum curvature offset to the distal.

Mesial outline: is similar to its labial counterpart.

Distal outline: is similar to its labial counterpart.

Incisal outline: the incisal margin is also similar to that of the labial aspect.

Contact areas: are similar in position to their labial counterparts.

Angles: are similar to their labial counterparts.

Root: the root tapers more than the crown toward the palatal side.

3.6.3. Surface anatomy

The palatal side of the maxillary central incisor has a smooth rounded convexity, called cingulum near the cervical line, and has a large concavity, called the palatal fossa. Along the mesial and distal sides of the palatal fossa are little elevated linear prominences called marginal ridges. The height of the palatoincisor ridge is raised as well to the height of the marginal ridges. The borders of the palatal fossa are the palatoincisor ridge, incisally; the mesial marginal ridge, mesially; the distal marginal ridge, distally; and the cingulum, cervically. Occasionally, developmental linear grooves are found over the cingulum that extended into the palatal fossa. The mesiodistal dimension of the palatal side is less than of the labial one, and thus, the tooth tapers toward the palatal, accommodating the shape of the dental arch. As a result, the mesial and distal sides of the tooth can be easily seen from the palatal side than the labial one (palatal convergence). Moreover, the tooth cross section at the cervix has a triangular appearance. The sides of the triangle are the labial outline, the mesial outline and the slightly shorter distal outline. On occasion, there may also be a palatal pit located between the cingulum and fossa. This palatal pit may be found near the center of the palatocervical groove, if that structure is present. The palatocervical groove and palatal pit are much more commonly found on maxillary laterals than on maxillary centrals. However, neither structure is a usual finding on the crown of any permanent incisors (see **Figure 3**).



Figure 3. Palatal aspect of maxillary permanent central incisor.

3.7. Mesial aspect

3.7.1. Geometric outline

It is triangular in shape with the wide base at the cervix and narrow apex at the incisal tip.

3.7.2. Outlines

Cervical line: curves evenly toward the incisal. It exhibits the greatest depth of curvature of any tooth surface in the mouth. The marked curvature of the cervical line also is greater in this aspect compared to the distal one.

Labial outline: convex at the cervical one-third representing the cervical ridge then becomes slightly convex to the incisal tip. The incisal tip is on one line with the root apex.

Palatal outline: convex at the cervical one-third representing cingulum then becomes concave in the middle one-third, representing the palatal fossa, and then becomes convex again to follow the palatoincisor tip. The entire outline may be described as a shallow "S."

Incisal outline: it is usually pointed or slightly rounded in newly erupted incisors. In teeth with incisal wear, the outline is straight and slopes down from labial to palatal.

Crest of curvatures: the labial crest (the point furthest away from the central axis of the tooth) is at the cervical third near the cervical line, while the palatal one is found at the middle of the cervical one-third at the prominence of the cingulum.

Note: the incisal ridge is the projection of enamel on newly erupted teeth, which is the incisal termination of the tooth. In a proximal view, it is normally pointed or slightly rounded. After the tooth enters into occlusion, this ridge becomes blunted and flattened, resulting in a sloping, straight outline from the proximal aspect. This flattened area is termed the incisal edge (Table 4).

Root: cone-shaped with a rounded blunted end, square at the cervical one-third then gradually tapered to the root apex. The labial outline is convex, while the palatal one is more convex.

3.7.3. Surface anatomy

The crown surface is somewhat flattened with the mesial contact located in the incisal third, near the incisal margin, and is centralized labiopalatally. It is roughly ovoid, long incisocervically and narrow labiopalatally. It is the only proximal area in the maxillary arch where mesial surface contacts mesial surface (see Figure 4).



Figure 4. Mesial aspect of maxillary permanent central incisor.

3.8. Distal aspect

3.8.1. Geometric outline

It is triangular in shape.

3.8.2. Outlines

Cervical line: the curvature of the cervical line is less distally than mesially.

Labial outline: similar to the labial outline of the mesial surface.

Palatal outline: similar to the palatal outline of the mesial surface.

Incisal outline: the crown appears somewhat thicker at the incisal third.

Crest of curvatures: are similar in position to their mesial counterparts.

Root: the surface of the root is convex, and does not have a depression.

3.8.3. Surface anatomy

The distal view describes the surface of the tooth distant from the middle line of the face. This side closely resembles the mesial one. A greater part of the tooth surface is seen from this aspect compared to the mesial one as the labial surface of the crown steeped palatally, accommodating the horseshoe shape of the dental arch. Because it contacts the lateral incisor, which is a smaller tooth, the distal contact area is accordingly smaller in size. Its shape is still ovoid, but it is more nearly round than on the mesial. It is also located farther cervically, still in the incisal third, but very near the junction of the incisal and middle thirds (see **Figure 5**).

3.9. Incisal aspect

The incisal view of this tooth considers the portion of the tooth visible from the side where the incisal ridge is located. From this angle, only the crown of the tooth is visible, and overall, the



Figure 5. Distal aspect of maxillary permanent central incisor.

tooth looks bilateral. The outlines are roughly triangular with the labial surface appears broad and flat, and the palatal surface tapers toward the cingulum. The distance between the mesio-incisal angles to the cingulum is slightly longer than the distance between the distoincisor angles to the cingulum. The incisal edge is centrally situated in a labiopallatal direction. The palatal fossa is seen as broad concavity between the two marginal ridges and incisal to the cingulum [7, 8] (see **Figure 6**).




Figure 6. Incisal aspect of maxillary permanent central incisor.

3.10. Pulp cavity

3.10.1. Mesiodistal section

The mesiodistal measurement of the pulp chamber is wider compared to the labiopallatal one. The outlines of the pulp cavity follow the general shape of the tooth. If the mamelons are well developed, three definite pulp horns are found at the incisal portion of the tooth. The pulp cavity tapers gradually and evenly along its whole length until the apical constriction of the root is reached. The apical foramen may be located slightly off center to the root tip.

3.10.2. Labiopallatal section

The pulp cavity follows the general outline of the crown and root. The pulp chamber is very narrow in the incisal region. Cervically, the pulp chamber widens to its largest labiopallatal width. Then, the root canal tapers gradually and evenly ending in a constriction at the root tip. The apical foramen may be located a little bit to the palatal or labial aspect of the root, near the very tip of the root.

3.10.3. Cervical cross section

At the cervical level, the pulp cavity mimics the external shape of the tooth. It is the widest in dimension compared to the other cross sections and centralized within the root dentin.

In newly erupted teeth, the outline of the pulp chamber is roughly triangular in shape with the base of this triangle at the labial surface. As the amount of physiologic secondary dentin increases, the pulp cavity becomes more rounded in shape. The root and pulp canal tend to be rounder at midroot level than at the cervical level. The anatomy at the midroot level is essentially the same as that found at the cervical level, just smaller in all dimensions [9] (see **Figure 7**).

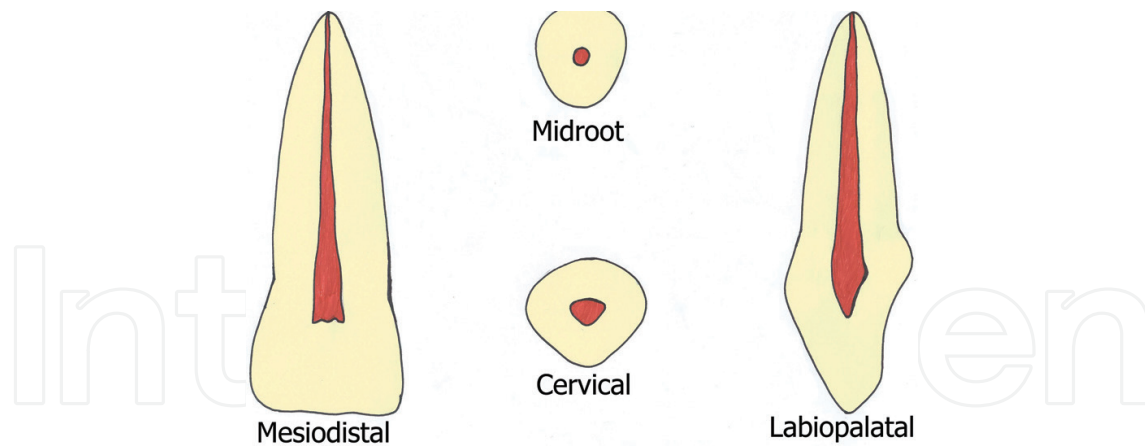


Figure 7. Pulp cavity for the mesiodistal, labiopalatal, midroot and cervical sections of maxillary permanent central incisor.

3.11. Tooth socket

The first socket right or left of the median line is that of the maxillary central incisor. The periphery of the socket often dips down palatally, labially, mesially and distally to accommodate the shape of the root. The central incisor socket is flattened on its mesial surface and is usually somewhat concave distally [10].

3.12. Occlusion

Like all upper front teeth and when the mouth is closed, the central incisors are ordinarily positioned labially to the mandibular ones. In some instances, the upper front teeth are positioned palatally to the lower ones and in such case the condition is referred as anterior cross-bite. When the teeth are biting down, the upper central incisors occlude with the lower central and lateral incisors. The contact point of the lower teeth is in the palatal fossa of the upper central incisor about 2 mm cervically from the incisal edge. The anterior open bite occurs when the upper and lower incisors do not contact even when the mouth is fully closed. This incorrect arrangement of teeth may result from some habits, such as thumb sucking. On the other hand, the deep bite occurs when the contact of the lower incisors to the upper incisors is near or completely on the gingiva. When upper anterior teeth are located too far in front of the lower teeth, this is termed as large overjet [11].

3.13. Variation

1. Considered to be a common variation in Asian populations, shovel-shaped incisors derive their name from the prominent marginal ridges and the deeper palatal fossa of the teeth. When seen from palatal view, the tooth is said to resemble a shovel.
2. When space exists between maxillary central incisors, the condition is referred to as a diastema. One frequent cause of the space is the presence of a large labial frenum from the upper lip extending near the teeth.

3. The maxillary incisors are the most likely teeth to have a talon cusp, which is an extra cusp on the lingual surface.
4. Also, the permanent maxillary incisors are the most likely teeth to have a dilacerations, which is a sharp curve on a tooth.
5. When the root is exceptionally short, in conjunction with an abnormal contour of the crown, this anomalous condition is referred to as dwarfed root, and the lack of root support may endanger the tooth's longevity in the mouth.
6. In the cases affected by congenital syphilis, a notch forms on the incisal edges of all incisors. When such notch is found, the teeth are described as screwdriver-shaped and they are called Hutchinson's incisors.
7. The alveolar bone between the roots of the two central incisors is occasionally the site of supernumerary teeth or extra teeth, known as mesiodens [1].

4. Permanent maxillary lateral incisor

4.1. Unique characteristics

The general shape is similar to maxillary central incisor except that they are shorter and narrower. The mesiodistal crown dimension is the smallest of any maxillary teeth. The mesio-incisal and disto-incisal angles are more rounded than the corresponding angles of maxillary central incisor. On the palatal aspect, the marginal ridges and cingulum are more prominent. It has the most cervically located contact area of any incisor. Next to third molars, maxillary lateral incisors are the teeth that show most variation in crown size, shape and form (see **Figure 8**).

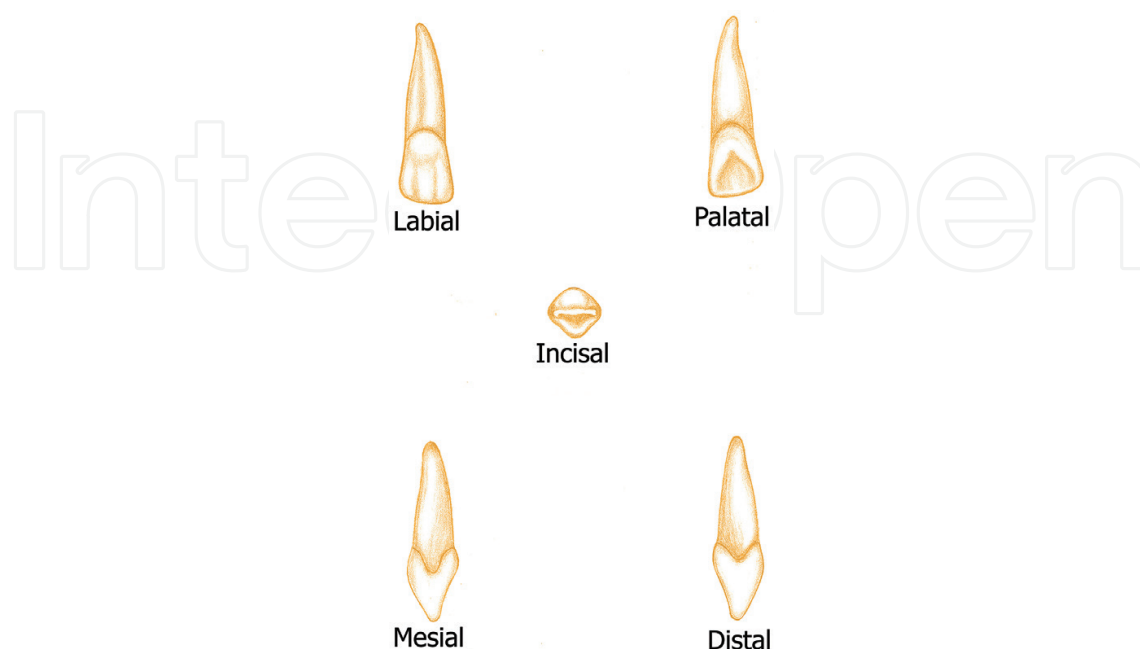


Figure 8. Diagram showing the labial, palatal, mesial, distal and incisal aspects of the maxillary permanent lateral incisor.

4.2. Arch position

The maxillary lateral incisor is the tooth located distally from both maxillary central incisors and mesially from both maxillary canines.

4.3. Function

Like all the incisors, their function is for shearing or cutting food material during mastication.

4.4. Development

It is developed from four lobes, three labially and one palatally, the palatal lobe being represented by the cingulum. Each labial lobe of the incisor terminates incisally in rounded eminence known as mamelon. Mamelons are better seen on the central incisors as compared to the lateral incisors [6] (**Table 3**). The mesiodistal and labiopalatal measurements for maxillary permanent lateral incisor (mm) are shown in **Table 4**.

4.5. Labial aspect

4.5.1. Geometric outline

It is trapezoidal in shape with the shortest uneven side toward the cervix.

4.5.2. Outlines

Cervical line: curves in a regular arc apically, with only slightly less depth than in the central incisor.

Appearance of dental organ	5 months I.U.L.
Beginning of calcification	10–12 months
Crown completed	4–5 years
Eruption	8–9 years
Root completed	11 years

Table 3. Chronology table of maxillary permanent lateral incisor.

Crown length	Root length	MD at contact area	MD at cervical line	LP at crest of curvature	LP at cervical line	Curvature of CL	
						M	D
9.0	13.0	6.5	5.0	6.0	5.0	3.0	2.0

Table 4. Measurements in millimeter of maxillary permanent lateral incisor.

Mesial outline: this margin resembles that of the central incisor, but usually is more convex and has a more rounded mesioincisal angle. The contact area is located farther cervically in the incisal third, quite near its junction with the middle third.

Distal outline: the distal margin is always more rounded than the distal outline of the central incisor, with a more cervically located contact area. The distoincisal angle is noticeably more rounded than its central incisor counterpart, and also more rounded than its own mesioincisal angle.

Incisal outline: the incisal outline resembles the central incisor, but it is not so straight, partially because of the greater rounding of the two incisal angles. It exhibits the greatest rounding of any incisor. The number and prominence of mamelons is variable, but two are the most common finding.

Contact areas: the mesial contact at the junction between middle and incisal on-third ewhile the distal contact at the center of the middle third.

Angles: the distoincisal angle being more rounded than the mesioincisal angle.

Root: the root tapers toward the pointed apex. The root apex is inclined distal to midline. It is narrow mesiodistally than that of maxillary central and usually as long as or somewhat longer than that of the central.

4.5.3. Surface anatomy

The labial surface itself is more convex both mesiodistally and incisocervically than the maxillary central. Labial developmental grooves, and imbrication lines are often present, similar to those of the central incisor but are less prominent. The labial height of contour is located at the cervical third (see **Figure 9**).




Figure 9. Labial aspect of maxillary permanent lateral incisor.

4.6. Palatal aspect

4.6.1. Geometric outline

It is trapezoidal in shape with the smallest uneven side toward the cervix.

4.6.2. Outlines

Cervical line: it curves toward the apical, but is offset to the distal.

Mesial outline: is similar to its labial counterpart.

Distal outline: is similar to its labial counterpart, and the distoincisor angle is much more rounded than the mesioincisor angle.

Incisal outline: is similar to the labial aspect.

Contact areas: are similar in position to their labial counterparts.

Angles: are similar in position to their labial counterparts.

Root: the root tapers more than the crown toward the palatal side.

4.6.3. Surface anatomy

The mesial and distal marginal ridges, as well as the cingulum, are relatively more prominent, and the palatal fossa is deeper, when compared to the same structures of the central incisor. A palatocervical groove is a more common finding in maxillary lateral incisors than in central incisors. A palatal pit, near the center of this groove, is also more common, and when present, is a potential site for caries. The palatocervical groove usually originates in the palatal pit and extends cervically, and slightly distally, onto the cingulum. It might be helpful to think of the palatocervical fissure as running in a more or less vertical direction, while the palatocervical groove extends in a roughly horizontal direction (see **Figure 10**).

4.7. Mesial aspect

4.7.1. Geometric outline

It is triangular in shape with the wide base at the cervix and narrow apex at the incisal tip.




Figure 10. Palatal aspect of maxillary permanent lateral incisor.

4.7.2. Outlines

Cervical line: exhibits less depth of curvature than it does on the mesial surface of the central incisor.

Labial outline: convex at the cervical one-third representing the cervical ridge then becomes slightly convex to the incisal tip. The incisal tip is on one line with the root apex.

Palatal outline: convex at the cervical one-third representing cingulum then becomes concave in the middle one-third, representing the palatal fossa, and then becomes convex again to follow the palatoincisal tip. The entire outline may be described as a shallow "S."

Crest of curvatures: the labial crest is at the cervical third near the cervical line, while the palatal one is found at the middle of the cervical one-third at the prominence of the cingulum.

Incisal outline: the incisal portion is on one line with root apex.

Root: the root appears longer but narrower than that of the central.

4.7.3. Surface anatomy

The crown is shorter, and the labiopallatal measurement of the crown is smaller. The contact area is also similar in shape to the contact of the central incisor. It is found in the incisal third very near the junction of the incisal and middle thirds, centered labiopallatally (see **Figure 11**).

4.8. Distal aspect

4.8.1. Geometric outline

It is triangular in shape with the wide base at the cervix and narrow apex at the incisal tip.



Figure 11. Mesial aspect of maxillary permanent lateral incisor.

4.8.2. Outlines

Cervical line: shows less curvature incisally than on the mesial surface.

Labial outline: similar to the labial outline of the mesial surface.

Palatal outline: similar to the palatal outline of the mesial surface.

Crest of curvatures: are similar in position to their mesial counterparts.

Incisal outline: rounded in newly erupted teeth and flat in worn out teeth.

Root: the distal surface of the root is slightly more convex than mesial.

4.8.3. Surface anatomy

The distal surface is smaller and more convex in all dimensions than the mesial surface. The contact area is shorter and not as incisally placed, when compared to the mesial contact. It is normally located at middle of the middle one-third and centered labiopalatally (see **Figure 12**).

4.9. Incisal aspect

In incisal view, this tooth resembles the central incisor to varying degrees. The tooth is narrower mesiodistally than the maxillary central incisor; however, it is nearly as thick labiopalatally. The incisal outline is more rounded labially and palatally than the central incisor. When palatal pit is present; it is located in the depth of the palatal fossa [7, 8] (see **Figure 13**).

4.10. Pulp cavity

4.10.1. Mesiodistal section

The pulp cavity nearly follows the external shape of the tooth. When viewed from the labial aspect of the tooth, the pulp horns appear to be blunted. The pulp chamber and root canal taper evenly and gradually toward the root apex. In the apical portion, the root often shows a significant curvature.

4.10.2. Labiopalatal section

The anatomical feature is almost identical to that of the central incisor. Generally, the pulp cavity of the lateral incisor closely resembles the outline form of the crown and the root. The

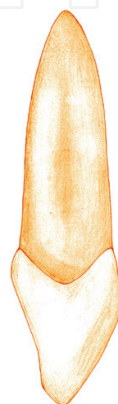


Figure 12. Distal aspect of maxillary permanent lateral incisor.




Figure 13. Incisal aspect of maxillary permanent lateral incisor.

pulp projections are usually well developed and prominent. In the incisal region, the pulp chamber is narrow, and at the cervical level of the tooth it may become very wide. When the cervical enlargement of the pulp chamber is lacking, the root canal tapers slightly to the apical constriction at the root tip. Many of the apical foramina exit on the labial or palatal aspect of the root.

4.10.3. Cervical cross section

The cervical cross section shows the pulp chamber to be centered within the root. The root form of this tooth shows a large variation in shape. The outline form of this tooth may be triangular, oval or round. The pulp chamber generally follows the outline form of the root, but secondary dentin may narrow the canal significantly [9] (see **Figure 14**).

4.11. Tooth sockets

The second socket from the midline is that of the lateral incisor. It is generally conical and egg-shaped, or ovoid, with the widest portion to the labial. It is smaller on cross section, although it is often deeper than the central alveolus. Sometimes, it is curved at the upper extremity [10].

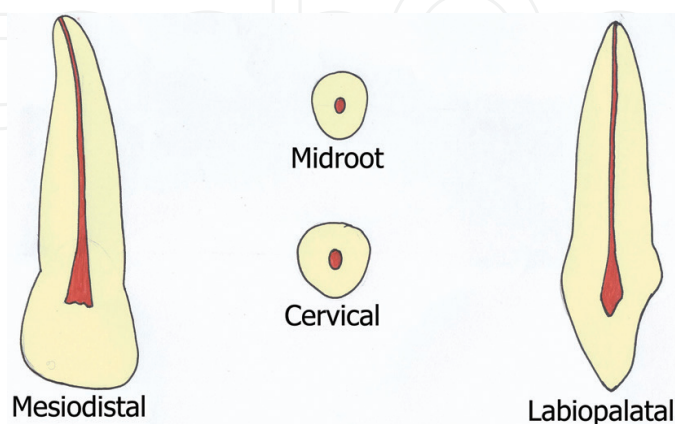


Figure 14. Pulp cavity for the mesiodistal, labiopalatal, midroot and cervical sections of maxillary permanent lateral incisor.

4.12. Occlusion

The upper lateral incisors are usually located labially to the mandibular teeth when the mouth is closed. The upper lateral incisor occludes with the distolabial half of the mandibular lateral and with the mesiolabial inclined plane of the mandibular canine [11].

4.13. Variation

1. The incisal portion of the cingulum may exhibit a tubercle.
2. Palatocervical fissure may extend all the way onto the root surface from the adjacent cingulum.
3. Distorted crowns and unusual root curvatures are more commonly seen than with any other incisor.
4. A diminutive peg-shaped crown form, which is relatively common, and is due to a lack of development of the mesial and distal portions of the crown.
5. Maxillary laterals sometimes are congenitally missing, that is, tooth buds do not form.
6. The palatal pit of the maxillary lateral may be the entrance site where enamel and dentin have become invaginated in the tooth's pulp cavity, due to a developmental aberrancy called dens in dente [1].

5. Permanent mandibular central incisor

5.1. Unique characteristics

The crown dimensions are the smallest of any tooth, it has bilaterally symmetrical crown, and the line angles are the sharpest of any tooth. The proximal contact areas are at the same level. The incisal edge is lingual to labiolingual bisector. It shows the shallowest labial developmental grooves, smoothest lingual surface contour and the least developed cingulum. As the smallest tooth in the dentition, the mandibular central incisor has only one antagonist. This tooth and the maxillary third molar are the only teeth that have one antagonist (see **Figure 15**).

5.2. Arch position

It occupies the position adjacent to the midline in each mandibular quadrant. They share a mesial contact area with each other, while the distal contact is with the permanent lateral incisor.

5.3. Function

These teeth function in biting, cutting, incising and shearing, just as do their maxillary counterparts.

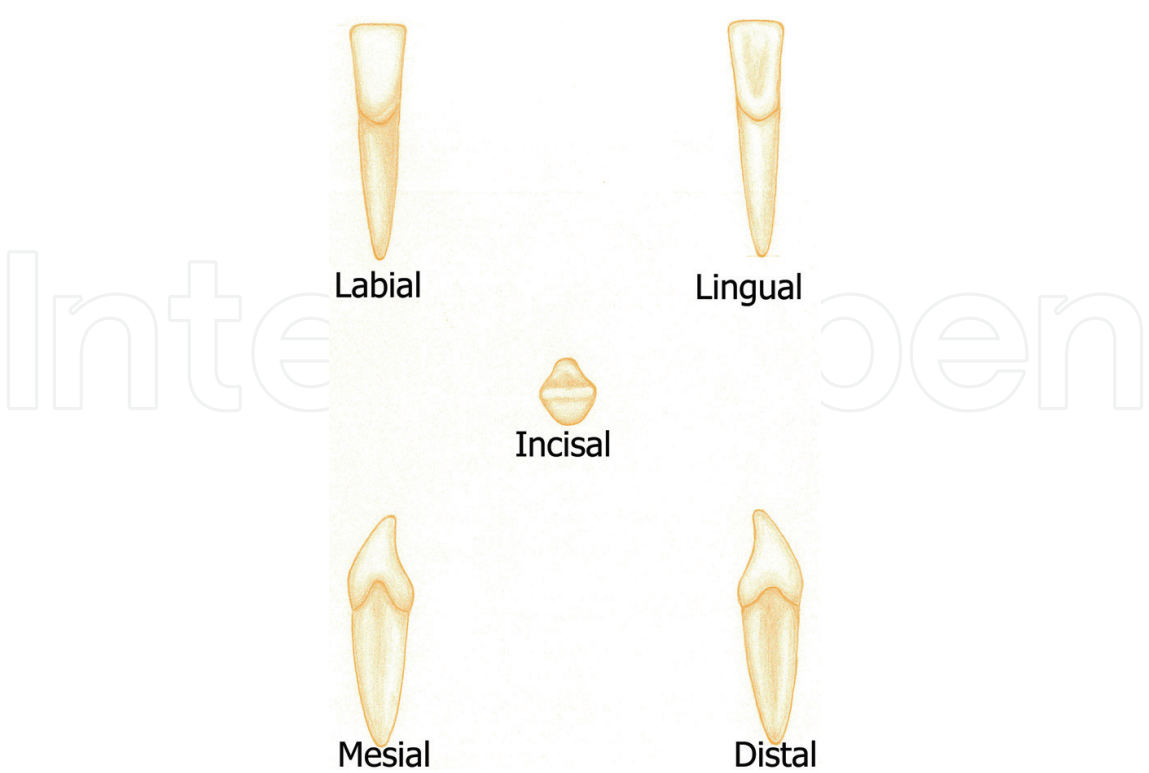


Figure 15. Diagram showing the labial, lingual, mesial, distal and incisal aspects of the mandibular permanent central incisor.

5.4. Development

It developed from four lobes (three mamelons and one cingulum). Shortly after eruption, mamelons are usually worn away by attrition and the incisal edges of all incisors are straight [6] (**Table 5**). The mesiodistal and labiolingual measurements for mandibular permanent central incisor (mm) are shown in **Table 6**.

Appearance of dental organ	5 months I.U.L.
Beginning of calcification	3–4 months
Crown completed	4–5 years
Eruption	6–7 years
Root completed	9 years

Table 5. Chronology table of mandibular permanent central incisor.

Crown length	Root length	MD at contact area	MD at cervical line	LL at crest of curvature	LL at cervical line	Curvature of CL	
						M	D
9.0	12.5	5.0	3.5	6.0	5.3	3.0	2.0

Table 6. Measurements in millimeter of mandibular permanent central incisor.

5.5. Labial aspect

5.5.1. Geometric outline

It is trapezoidal in shape with the shortest uneven side toward the cervix.

5.5.2. Outlines

Cervical line: the cervical line is symmetrically curved toward the root.

Mesial outline: the mesial margin normally tapers evenly toward the cervical part in a nearly straight line.

Distal outline: the outline is straight and almost exactly like the mesial outline.

Incisal outline: In newly erupted teeth, three mamelons most always be seen. After incisal wear has obliterated the mamelons, the incisal outline is straight, and at right angles to the long axis of the tooth.

Contact areas: mesially, the height of contour is associated with the contact area in the incisal third, very close to the incisal margin. The height of contour is also in the incisal third and in the same level, distally.

Angles: the mesioincisal angle is quite sharp with a similarly sharp distoincisal angle, normally more so than any of the incisal angles of maxillary incisors.

Root: a straight single root, tapering at the apical third. The labial surface is narrow and convex. The mesial and distal outlines are straight down to the apical portion. Its apical third ends in a pointed apex, which tends to curve distally. The root appears longer compared to the crown length.

5.5.3. Surface anatomy

The labial surface is generally convex both mesiodistally and incisocervically, but not to the extent of the maxillary incisors, especially the maxillary lateral. However, like the maxillary

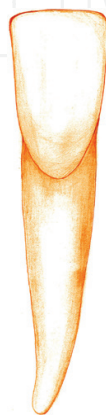


Figure 16. Labial aspect of mandibular permanent central incisor.

incisors, the convexities are much greater in the cervical third. In fact, in some specimens the labial surface may be quite flat incisal to the height of contour. Developmental grooves and imbrication lines are not normally present. Occasionally, there are very faint grooves which only occur near the incisal margin of the labial surface (see **Figure 16**).

5.6. Lingual aspect

5.6.1. Geometric outline

It is trapezoidal in shape with the smallest uneven side toward the cervix.

5.6.2. Outlines

Cervical line: curves evenly toward the root, but is located farther from the incisal ridge than the labial surface counterpart.

Mesial outline: closely resembles the mesial outline of the labial aspect.

Distal outline: closely resembles the distal outline of the labial aspect.

Incisal outline: closely resembles the incisal outline of the labial aspect.

Contact areas: are similar in position to their labial counterparts.

Angles: are similar to their labial counterparts.

Root: is slightly narrower on the lingual side than on the labial side.

5.6.3. Surface anatomy

The crown is narrower on the lingual surface (lingual convergence). The lingual surface is relatively smooth, and its structures are generally less prominent than those of the maxillary incisors. There is usually a slight concavity, or lingual fossa, bordered by indistinct marginal ridges on the mesial and distal. There are normally no grooves, fissures or pits on the lingual surface. A cingulum is normally present, although it is not as prominent as in the maxillary incisors. The height of contour is located in the cervical third of the surface, associated with the greatest convexity of the cingulum (see **Figure 17**).

5.7. Mesial aspect

5.7.1. Geometric outline

It is triangular in shape with the wide base at the cervix and narrow apex at the incisal tip.

5.7.2. Outlines

Cervical line: there is a marked, even curvature incisally of the cervical margin.

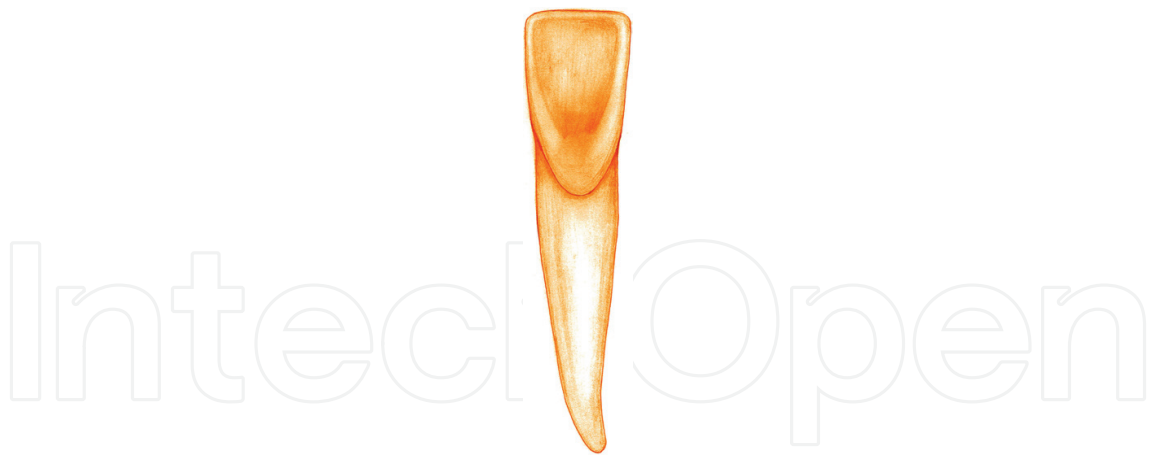


Figure 17. Lingual aspect of mandibular permanent central incisor.

Labial outline: slopes in a straight to slightly convex line from the incisal ridge to the crest of curvature and is then convex in the remainder of the cervical third.

Lingual outline: concave in the incisal two-thirds and convex in the cingulum area, or cervical third.

Incisal outline: normally rounded, but can be straight and is located lingual to the center of the root. The profile of the incisal edge has downward inclination toward the labial, which is opposite to the lingual slope of the maxillary incisors. This is due to the wear pattern between the upper and lower incisors.

Crest of curvatures: the labial crest is at the cervical third near the cervical line while the lingual one is found at the middle of the cervical third at the prominence of the cingulum.

Root: the root outlines are nearly straight from the cervical line to the middle third and then taper to the rounded apex. The mesial surface of the root is flat with a deep longitudinal developmental depression

5.7.3. Surface anatomy

The mesial surface is roughly triangular, or wedge-shaped, like all other anterior teeth. Unlike the maxillary incisors, the crown appears to be slightly offset toward the lingual. The contact area is located about half way from labial to lingual, and in the incisal third, very close to the incisal edge. It has an ovoid shape, which is long incisocervically and narrow labiolingually (see **Figure 18**).

5.8. Distal aspect

5.8.1. Geometric outline

It is triangular in shape.

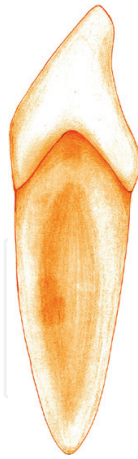

Figure 18. Mesial aspect of mandibular permanent central incisor.

5.8.2. Outlines

Cervical line: curves slightly less toward the incisal.

Labial outline: similar to the labial outline of the mesial surface.

Lingual outline: similar to the lingual outline of the mesial surface.

Incisal outline: similar to the incisal outline of the mesial surface. It is located lingual to the center of the root.

Crest of curvature: are similar in position to their mesial counterparts.

Root: similar to the mesial but with a deeper longitudinal developmental depression and groove at its center.

5.8.3. Surface anatomy

Even the contact area has a similar location, a fact which is unique among incisors (see **Figure 19**).

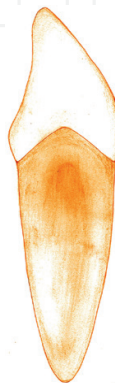


Figure 19. Distal aspect of mandibular permanent central incisor.

5.9. Incisal aspect

The most notable features from the incisal aspect are the symmetry of the mesial and distal portions, and the straight incisal edge. Unlike the maxillary central, this tooth is roughly four sided, or diamond-shaped, from this aspect, and the tooth is normally wider labiolingually than mesiodistally. Because the crown is offset toward the lingual, more of the labial surface than the lingual surface is visible from this aspect. Even though the central incisor is described as symmetrical from the incisal aspect, careful scrutiny will reveal that the cingulum is very slightly offset toward the distal, an important feature when attempting to distinguish right from left mandibular central incisors [7, 8] (see **Figure 20**).

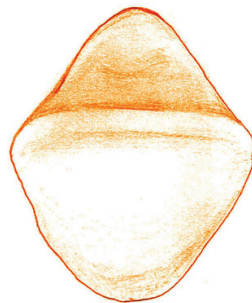


Figure 20. Incisal aspect of mandibular permanent central incisor.

5.10. Pulp cavity

5.10.1. Mesiodistal section

The mesiodistal section of the mandibular central incisor demonstrates the narrowness of the pulp cavity. The pulp horns are usually less prominent. The canal also appears narrow, having a gentle taper from the pulp chamber to the apical constriction. The canal may exit at the apex, or mesially or distally to the apex of the root.

5.10.2. Labiolingual section

The mandibular central incisor is the smallest tooth in the mouth, but its labiolingual dimension is very large. This tooth usually has one canal, but two canals may be found quite frequently. The pulp chamber may be very small in size, intermediate in size or very large. In the apical 3 or 4 mm of the root, the pulp canal may taper gently to the apex or narrow abruptly. The apical foramen may exit at the root apex or on the labial aspect of the root.

5.10.3. Cervical cross section

The cervical cross section demonstrates the proportions of the root dimensions. The mesiodistal dimension is small, whereas the labiolingual dimension is very large, the external shape is variable; some are round, oval or elliptical. Two separate canals may be present, or a dentinal island may make it appear as though two canals are present [9] (see **Figure 21**).

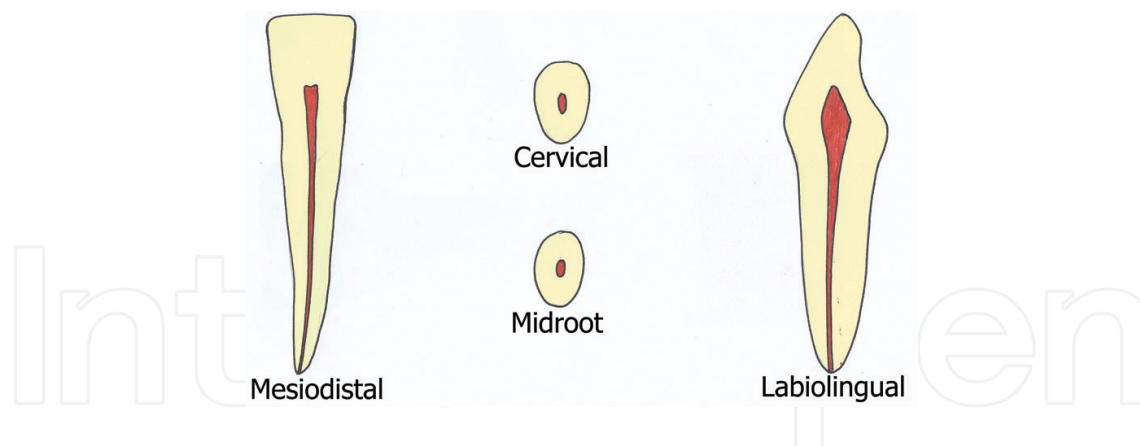


Figure 21. Pulp cavity for the mesiodistal, labiolingual, midroot and cervical sections of mandibular permanent central incisor.

5.11. Tooth sockets

The central incisor socket is flattened on its mesial surface and is usually somewhat concave distally to accommodate the developmental groove on the root [10].

5.12. Occlusion

The labioincisal ridge of the lower central incisor strikes the palatal surface of the upper central incisor at the junction between the incisal and middle thirds. Its mesial outline is in line with the midline and the mesial outline of upper central incisor, while its distal outline is below the junction of the mesial two-thirds and distal thirds of the upper central [11].

5.13. Variation

1. There is great variability in the lingual inclination of the labial surface of mandibular central incisor specimens.
2. Anomalies are very rare. Occasionally, a bifurcated root is found which, in mandibular incisors, has labial and lingual locations [1].

6. Permanent mandibular lateral incisor

6.1. Unique characteristics

The crown of this tooth is similar to that of the mandibular central incisors, but not bilaterally symmetrical. The labial surface has more fan-shaped appearance compared to lower central incisor. The incisal ridge is straight and slopes downward toward the distal. The crown of the mandibular lateral incisor twisted distolingually slightly on its root in order to allow the incisive ridge to follow the curve of the dental arch. The cingulum is shifted to the distal (see **Figure 22**).

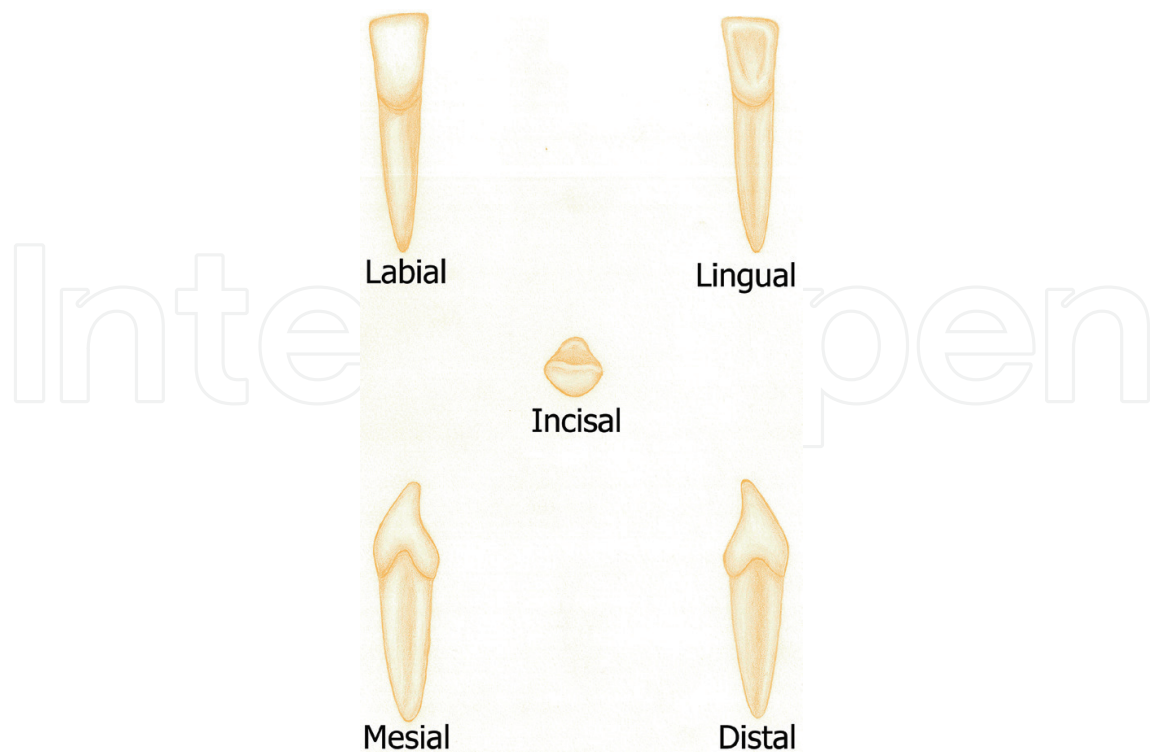


Figure 22. Diagram showing the labial, lingual, mesial, distal and incisal aspects of the mandibular permanent lateral incisor.

6.2. Arch position

The lateral incisors contact mesially with the distal surface of the central incisors and distally with the mesial surface of the canines.

6.3. Function

This tooth has the function of incising food as well as aesthetic.

6.4. Development

It developed from four lobes (three mamelons and cingulum) [6] (**Table 7**). The mesiodistal and labiolingual measurements for mandibular permanent lateral incisor (mm) are shown in **Table 8**.

6.5. Labial aspect

6.5.1. Geometric outline

Crown outline is trapezoidal. It has a more fan-shaped appearance from the labial aspect as the cervical portion is narrower, while the incisal portion is wider compared to the mandibular central incisor.

Appearance of dental organ	5 months I.U.L.
Beginning of calcification	3–4 months
Crown completed	4–5 years
Eruption	6–7 years
Root completed	9 years

Table 7. Chronology table of mandibular permanent lateral incisor.

Crown length	Root length	MD at contact area	MD at cervical line	LL at crest of curvature	LL at cervical line	Curvature of CL	
						M	D
9.5	14.0	5.5	4	6.5	5.3	3.0	2.0

Table 8. Measurements in millimeter of mandibular permanent lateral incisor.

6.5.2. Outlines

Cervical line: the cervical line is symmetrically curved toward the root.

Mesial outline: the mesial outline of the crown is often longer than the distal outline.

Distal outline: shorter than the mesial outline.

Incisal outline: the incisal ridge is slightly wider mesiodistally. The incisal ridge slopes downward in a distal direction.

Contact areas: the distal contact area is more cervically positioned than the mesial contact area. The mesial contact is found at the incisal third, near the incisal ridge. The distal contact is found also at the incisal third, but more cervical to the level of the mesial contact area.

Angles: the distoincisor angle of the lower lateral incisor is relatively more rounded and obtuse than the sharp mesioincisor angle of the mandibular central incisor.

Root: it is similar to that of the central incisor, but is slightly longer.

6.5.3. Surface anatomy

The labial face of the mandibular lateral incisor crown is smooth, with a flattened at the incisal third; the middle third is more convex, narrowing down to the convexity of the root at the cervical portion (see **Figure 23**).

6.6. Labial aspect

6.6.1. Geometric outline

Crown outline is trapezoid in shape.

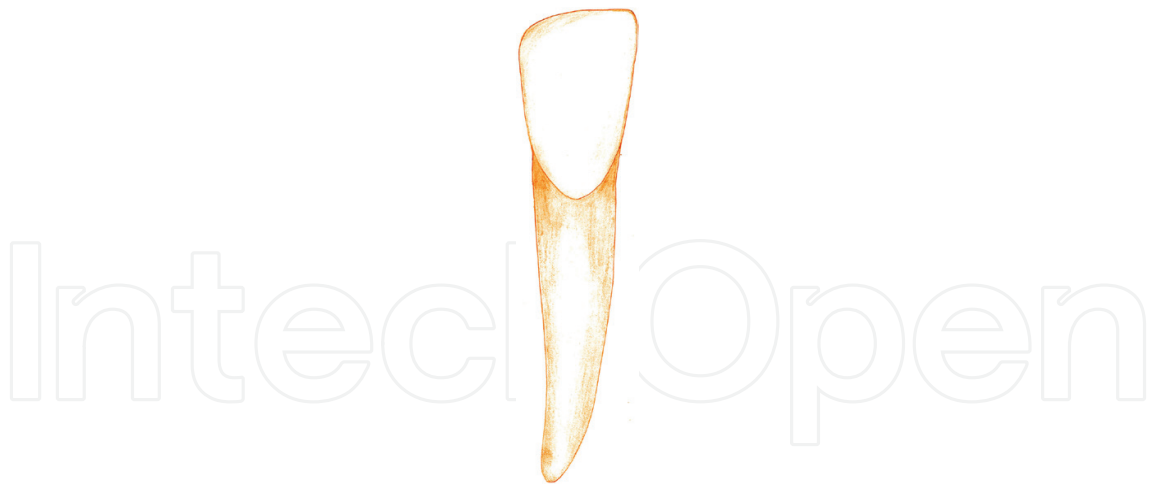


Figure 23. Labial aspect of mandibular permanent lateral incisor.

6.6.2. Outlines

Cervical line: semicircular more curved root wise compared to its labial counterpart. The curvature of cervical line is also offset distally.

Mesial outline: closely resembles the mesial outline of the labial aspect.

Distal outline: closely resembles the distal outline of the labial aspect.

Incisal outline: closely resembles the incisal outline of the labial aspect.

Contact areas: are similar in position to their labial counterparts.

Angles: are similar in position to their labial counterparts.

Root: is slightly narrower on the lingual side than on the labial side.

6.6.3. Surface anatomy

It has faint mesial and distal marginal ridges as well as cingulum, which are less developed. The mesial marginal ridge is longer than the distal marginal ridge. The cingulum is deviated distal to the center of the lingual surface (see **Figure 24**).

6.7. Mesial aspect

6.7.1. Geometric outline

It is triangular in shape with the wide base at the cervix and narrow apex at the incisal tip.

6.7.2. Outlines

Cervical line: there is a marked, even curvature incisally of the cervical margin.

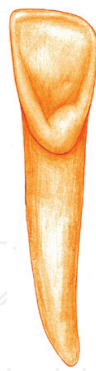


Figure 24. Lingual aspect of mandibular permanent lateral incisor.

Labial outline: slopes in a straight to slightly convex line from the incisal ridge to the crest of curvature and is then convex in the remainder of the cervical third.

Lingual outline: concave in the incisal two-thirds and convex in the cingulum area, or cervical third.

Incisal outline: normally rounded, but can be straight and is located lingual to the center of the root.

Crest of curvatures: the labial crest is at the cervical third near the cervical line, while the lingual one is found at the middle of the cervical third at the prominence of the cingulum.

Root: the root form is similar to that of the mandibular central incisor, including the presence of developmental depression, mesially.

6.7.3. Surface anatomy

The mesial side of the crown is often longer than the distal side; this causes the incisal ridge, which is straight, to slope downward in a distal direction. The mesial contact area centered labiolingually and at the incisal third near the mesioincisal angle, incisocervically (see **Figure 25**).

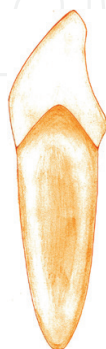

Figure 25. Mesial aspect of mandibular permanent lateral incisor.

6.8. Distal aspect

6.8.1. Geometric outline

It is triangular in shape.

6.8.2. Outlines

Cervical line: curves slightly less toward the incisal.

Labial outline: similar to the labial outline of the mesial surface.

Lingual outline: similar to the lingual outline of the mesial surface.

Incisal outline: normally rounded but can be straight and is located lingual to the center of the root.

Crest of curvature: is similar in position to their mesial counterparts.

Root: the root form is similar to that of the mandibular central incisor, including the presence of developmental depression, distally.

6.8.3. Surface anatomy

The distal surface is shorter incisocervically. The distal contact area is more cervical than the mesial one. The concavity immediately above the cervical line on the distal surface of the mandibular lateral incisor is deeper than that of the lower central incisor (see **Figure 26**).

6.9. Incisal aspect

The incisal ridge is tilted distally and lingually. The crown of the lower lateral incisor twisted distolingually slightly on its root in order to allow the incisive ridge to follow the curve of the dental arch. The cingulum is shifted to the distal. It is interesting to note that the labiolingual root axes of mandibular central and lateral incisors remain almost parallel in the alveolar process, even though the incisal ridges are not directly in line [7, 8] (see **Figure 27**).

6.10. Pulp cavity

6.10.1. Mesiodistal section

Similar to that of the mandibular central incisor.

6.10.2. Labiolingual section

Similar to that of the mandibular central incisor.

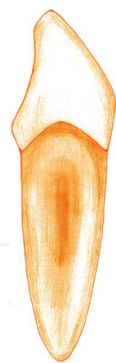


Figure 26. Distal aspect of mandibular permanent lateral incisor.

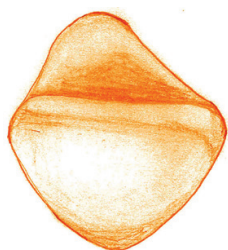


Figure 27. Incisal aspect of mandibular permanent lateral incisor.

6.10.3. *Cervical cross section*

Similar to that of the mandibular central incisor [9] (see **Figure 28**).

6.11. Tooth sockets

The socket of the mandibular lateral incisor is similar to that of the central incisor. It usually has the following variations; the socket is larger and deeper to accommodate a larger and longer root [10].

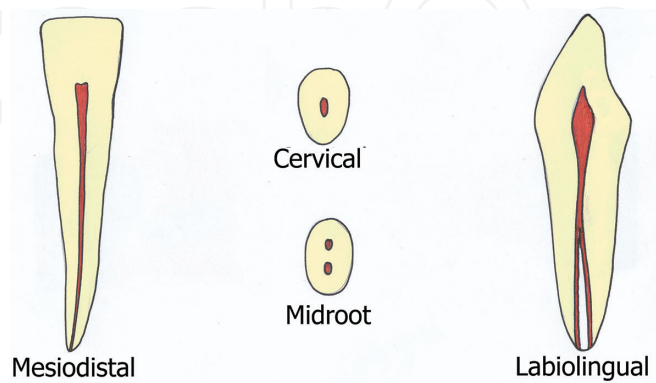


Figure 28. Pulp cavity for the mesiodistal, labiolingual, midroot and cervical sections of mandibular permanent lateral incisor.

6.12. Occlusion

Labioincisal ridge contacts both maxillary central and lateral incisors at the junction of their incisal and middle thirds. The cingulum is free of contact. The mesial outline is identical with the junction of the distal and middle thirds of maxillary central. The distal outline is centered below maxillary lateral incisor [11].

6.13. Variation

Anomalies are rare, but occasionally a bifurcated root is found [1].

Acknowledgements

Great thanks to Dr Rami Rabie, a postgraduate student in Oral Biology Department, Faculty of Dentistry, Mansoura University, Egypt, and thanks for Rana Ahmed Ezzat Edris, a level 3 student at Faculty of Oral and Dental Medicine, Delta University for Science and Technology, for their valuable contributions providing the original diagrams for the different teeth aspects and different dental pulp sections.

Author details

Mohammed E. Grawish^{1,2*}, Lamyaa M. Grawish³ and Hala M. Grawish³

*Address all correspondence to: grawish2005@yahoo.com

1 Department of Oral Biology, Faculty of Dentistry, Mansoura University, Egypt

2 Department of Oral Biology, Faculty of Oral and Dental Medicine, Delta University for Science and Technology, Gamasa, Mansoura, Egypt

3 Faculty of Oral and Dental Medicine, Delta University for Science and Technology, Gamasa, Mansoura, Egypt

References

- [1] Brook AH, Jernvall J, Smith RN, Hughes TE, Townsend GC. The dentition: The outcomes of morphogenesis leading to variations of tooth number, size and shape. *Australian Dental Journal*. 2014;**59**(Suppl 1):131-142
- [2] Yamanaka A, Iwai H, Uemura M, Goto T. Patterning of mammalian heterodont dentition within the upper and lower jaws. *Evolution and Development*. 2015;**17**:127-138

- [3] Jussila M, Thesleff I. Signaling networks regulating tooth organogenesis and regeneration, and the specification of dental mesenchymal and epithelial cell lineages. *Cold Spring Harbor Perspectives in Biology*. 2012;**4**:a008425
- [4] Al-Johany SS. Tooth numbering system in Saudi Arabia: Survey. *The Saudi Dental Journal*. 2016;**28**:183-188
- [5] Eugênio OS. Anatomia e Escultura Dental: Teoria e Prática de Ensino. São Paulo: Editora Santos; 1995
- [6] Nelson S. Wheeler's Dental Anatomy, Physiology and Occlusion. 10th edition. Philadelphia: 15 Saunders; 2014. p 392
- [7] Fuller J, Denely G, Schulein T. Concise Dental Anatomy and Morphology. 4th edition. Chicago: Book Medical Publishers Inc; 2001. p 218
- [8] Scheid R, Weiss G. Woelfel's Dental Anatomy. 8th edition. Philadelphia: Wolters Kluwer Health; 2012. p. 504
- [9] Vertucci FJ. Root canal anatomy of the human permanent teeth. *Oral Surgery, Oral Medicine, Oral Pathology*. 1984;**58**:589-599
- [10] Saffar JL, Lasfargues JJ, Cherruau M. Alveolar bone and the alveolar process: The socket that is never stable. *Periodontology 2000*. 1997;**13**:76-90
- [11] Hagag G, Yoshida K, Miura H. Occlusion, prosthodontic treatment, and temporomandibular disorders: A review. *Journal of medical and dental sciences*. 2000;**47**:61-66