

We are IntechOpen, the world's leading publisher of Open Access books Built by scientists, for scientists

6,900

Open access books available

186,000

International authors and editors

200M

Downloads

Our authors are among the

154

Countries delivered to

TOP 1%

most cited scientists

12.2%

Contributors from top 500 universities



WEB OF SCIENCE™

Selection of our books indexed in the Book Citation Index
in Web of Science™ Core Collection (BKCI)

Interested in publishing with us?
Contact book.department@intechopen.com

Numbers displayed above are based on latest data collected.
For more information visit www.intechopen.com



Periodontal Considerations in Adult Orthodontic Patients

Zamira Kalemaj, Antonios D. Anastasiou,
Animesh Jha and Felice R. Grassi

Additional information is available at the end of the chapter

<http://dx.doi.org/10.5772/intechopen.69960>

Abstract

The relationship between periodontology and orthodontics consists of a highly complex, bidirectional and close interaction that is nowadays characterized by controversial scientific opinions and clinical approaches. The relevant increasing number of adult orthodontic patients which in most cases present already-compromised periodontal tissues has markedly highlighted the potential of orthodontic treatment in enhancing or deteriorating periodontal health and also the outmost relevance of peculiar periodontal planning prior and during orthodontic treatment. Since the progress in adult orthodontics trend is rapid, there is also an increasing need for evidence-based protocols that might guide clinicians through a comprehensive, interdisciplinary and successful treatment. This chapter has been compiled with the aim of providing orthodontists, periodontists and general practitioners with sound evidence-based protocols and valid clinical approaches that have proven to be successful for numerous patients over long follow-ups. It is structured following the steps for a correct therapy management, starting from comprehensive examination and diagnosis to before and during orthodontic treatment considerations, and finally analysing the present state of new adult orthodontic technologies.

Keywords: adult orthodontics, periodontal health, orthodontic therapy, interdisciplinary treatment, accelerated orthodontics, future orthodontics

1. Introduction

Over the past three decades, the number of adult orthodontic patients has increased markedly. Recent surveys have reported that orthodontic treatment contributes to significant improvements in both professional and personal life, especially in adult patients who generally have undergone substantial loss of sustaining tissues, resulting in compromised function

and aesthetics. Based on the new-found self-confidence, the majority of these patients suggest orthodontic treatment to friends and relatives. Therefore, orthodontic treatment seems to be a promising emerging therapy to be integrated into a multidisciplinary dental treatment approach.

Apart from establishing a functional occlusion and improving dental and facial aesthetics, one of the major objectives of orthodontic therapy is enhancement and maintenance of periodontal health. In adult patients, the altered periodontal health might result in teeth loss, altered function and compromised aesthetics. Most of these patients present a variety of problems, which include teeth overeruption, migration, traumatic occlusion, irregular interdental spacing, consumed occlusal surfaces, irregular occlusal planes and loss of vertical dimension. In such complex and challenging clinical situations, an interdisciplinary treatment is mandatory. Unfortunately, in everyday orthodontic practice, insufficient emphasis is placed on comprehensive diagnosis prior to orthodontic therapy with particular attention to periodontal health and to its control and maintenance throughout the therapy. All attempts of limited treatment, with poor consideration of the whole picture will result in failure, relapse and very often aggravation of the pathology. The careful control of periodontal pathologies before, during and after orthodontic treatment, along with functional rehabilitation and patient's compliance can provide the most satisfactory results and long-term stability.

We present herein our step-by-step approach on pre-orthodontic and orthodontic treatment of periodontally compromised patients, through several detailed clinical cases and clear scientific protocols. Moreover, we consider several important issues concerning the bidirectional interaction of orthodontics and periodontology and discuss ways to optimize it. Potentials and limitations of such interaction are reflected. Furthermore, we summarize scientific evidence and clinical expertise on different techniques aiming enhancement and acceleration of adult orthodontic therapy, leading to conclusions of high relevance in terms of an effective and efficient therapy.

Guided by sound scientific principles and constructive clinical experience, it is vitally important to keep in mind that adult patients with orthodontic needs require individualized and tailored treatment plans to meet both clinical success and patient's expectations. The information presented in this chapter is gathered by considering these aspects and with the hope of providing investigators and clinicians with solid bases for the state of art and potential future directions of interdisciplinary treatments.

2. Periodontal considerations prior to orthodontic treatment

2.1. Comprehensive diagnosis

As all medical treatments, dental therapies might have two approaches, which are referred to as 'causal' and 'symptomatic'. It is of utmost importance that when possible, these approaches are considered complementary, not as an alternative to each other. Therefore, in all cases when causal factors can be identified, the treatment should focus on addressing them first. If these approaches are followed, the symptomatic spectrum might be easier to treat or even disappear.

In oral-related pathologies, many etiological factors are recognized and widely accepted, whereas sometimes their precise effects and multifactorial influences are difficult to quantify. Nevertheless, the identification of potential causal factors is the fundamental part of any diagnostic process and should be performed through an accurate clinical visit.

In case of particular malocclusions, such as severe deep bite or crowding, the direct causative relationships and influences on periodontal health are evident. Such influences are determined primarily by the pathological traumatic occlusion and unfavourable position of the tooth inside the bone envelope, and secondarily, by favouring the plaque accumulation which results in progression of plaque-induced periodontal breakdown.

This is not always the case for periodontal pathologies that trigger or predispose orthodontic problems. In the absence of a thorough clinical check and comprehensive causal diagnosis, numerous orthodontic symptoms might be wrongly treated without accounting for the underlying periodontal, often causative or predisposing factor. Such a situation is typically encountered in adult patient referring diastemas opening over time and teeth flaring (**Figure 1a**). If no detailed clinical and radiographic checks were performed, neglecting the periodontal health, the orthodontic treatment alone would have aggravated the periodontal state, resulting in an iatrogenic damage and the post-treatment stability would have been questionable.

The clinical check-up itself should always be preceded by a detailed anamnesis for identification of potential risk factors. Thereafter, it should include compilation of a periodontal chart including all relevant periodontal indexes, general radiographic estimation and, when deemed necessary, a detailed radiographic assessment through series of periapical radiographs (**Figure 1b**).

It is of utmost importance to consider the presence of highly compromised periodontal health in young patients as an indicator that might suggests need for further laboratory and genetic analysis in order to identify potential risk factors to periodontal pathology or important systemic pathologies (**Figure 1c**).

In terms of ethology, it is well established that periodontitis is a multifactorial condition and apart from microbial and environmental factors, its progression is determined also by genetic susceptibility [1]. Epidemiologic data suggest that approximately 10–15% of populations are susceptible to a quick progression from gingivitis to periodontitis which can hardly be explained by solely microbiological or external factors [2, 3]. Numerous genetic polymorphisms have been characterized and recognized to play a role here [4]. While the influence of genomic testing on non-surgical periodontal treatment outcomes has been recently questioned [5], it should be kept in mind that its consideration remains highly important for prevention measures, early diagnosis and better individualized treatment protocol. Moreover, when integrated into a multifactorial diagnostic scheme, it allows for a comprehensive estimation of risk factors. To-date epidemiological evidence is limited and further investigation is required in order to thoroughly understand the nature of this association and its clinical implications [3]. Nevertheless, since full genome sequencing is feasible, phenotypic and genotypic data can be used to improve ‘personalized’ treatment and public oral health [6]. Apart from genetic influences, other risk factors such as diabetes, smoking

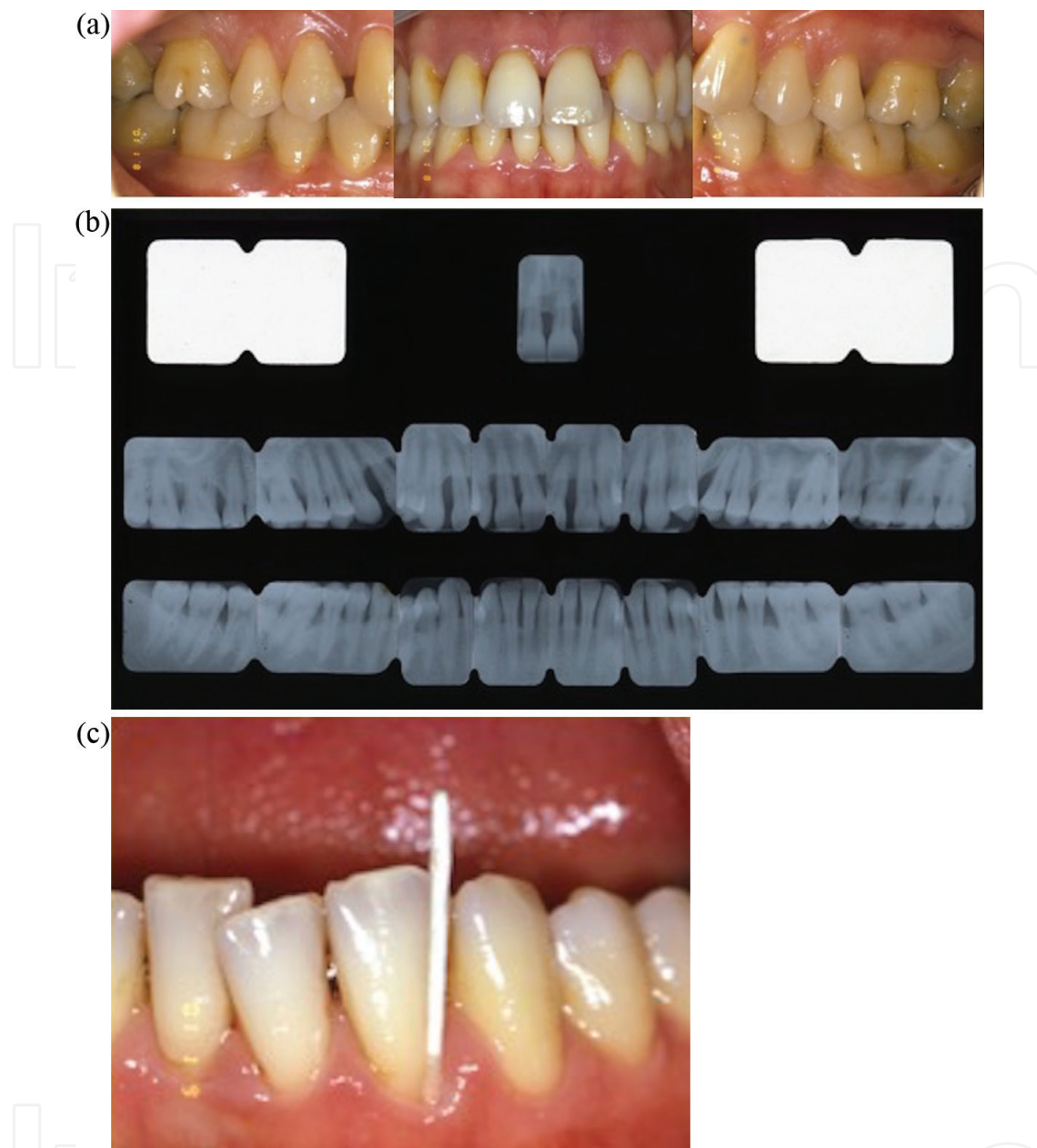


Figure 1. Twenty-eight-year-old female patient (FG), whose major requirement is diastema closure and teeth alignment. (a) Intraoral aspect; (b) during periodontal probing, it is noticed the presence of infrabony defects in multiple sites on both maxilla and mandible. A complete series of periapical radiographs is performed, showing a diffuse bone loss. (c) Bacteriological analysis on collected gingival cervical fluid indicated high levels of *actinobacillus actinomycetemcomitans*, *porphyromonas gingivalis* and *prevotella intermedia*.

and stress should also be considered, controlled and integrated into the overall treatment plan. The destructive effects of smoking on periodontal tissues have long been recognized, and recent biochemical and genetic studies have clarified direct and indirect pathways of this association [7, 8]. Levels of matrix metalloproteinase-8 (MMP-8), which is involved in periodontal destructions, are significantly increased in smoking patients. Additionally,

immune response is modified and the pathogenesis of the disease is negatively affected [8]. A similar pattern is present in patients affected by type 2 diabetes mellitus suggesting that diabetic-smoker patients have increased periodontal breakdown and are prone to a more severe periodontitis [9].

2.2. Multidisciplinary treatment plan

Oral functional and aesthetic rehabilitation in adult patients is a complex process that requires exhaustive scientific knowledge, extensive clinical experience and, in most cases, a multidisciplinary treatment planning. Independently of what the role of orthodontic therapy might be in the multidisciplinary frame, each tooth movement should initiate and be fulfilled in the presence of a healthy periodontium. It has already been demonstrated that if orthodontic treatment is conducted in the presence of periodontitis, it causes major bone destruction and clinical attachment loss (**Figure 2a, b**).

General treatment guidelines for orthodontic patients with chronic periodontitis suggest initial non-surgical therapy for adequate plaque control and then reevaluation [10]. It is purported that critical pocket depth for maintaining periodontal health with no need for surgical intervention is 4–5 mm, but this should be carefully estimated considering patient compliance on adequate oral hygiene and specific needs for regenerative therapy [11].

The non-surgical periodontal treatment consisting of scaling a root planning results in gingival recession due to inflammation reduction (**Figure 3a**). It is advisable to inform the patient in advance regarding this effect as it might compromise aesthetics. Following the classical approach, in case of persistence of infrabony defects of 4–5 mm deep after the initial periodontal therapy, the open flap debridement and regenerative treatment are carried out (**Figure 3b–e**). Another more recent alternative approach at this stage is the performance of

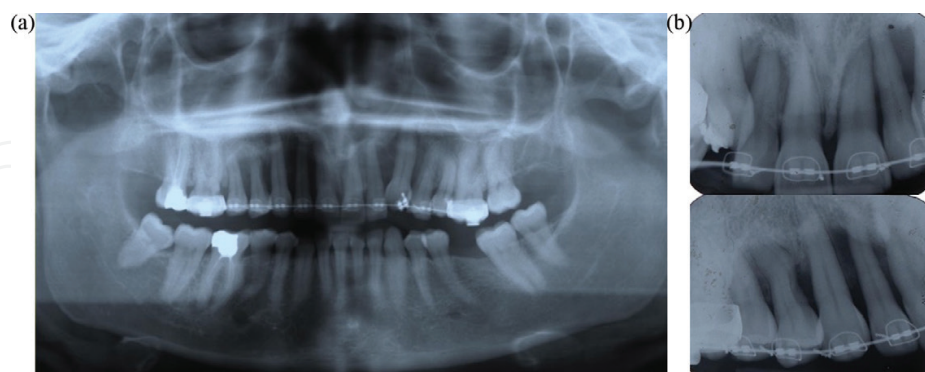

Figure 2. Twenty-two-year-old female patient having a fixed orthodontic appliance for 2 years. She was referred to us by an orthodontist who after one year of orthodontic therapy realised the gravity of the periodontal situation after performing a panoramic radiograph. The orthodontist refused to remove the orthodontic appliance, afraid that the patient would lose the teeth, being retained in their position only through the ligation to the archwire. (a) Panoramic radiograph showing the extensive bone loss in almost all maxillary teeth. (b) Periapical radiographs indicating the almost complete loss of periodontal support for multiple maxillary teeth.

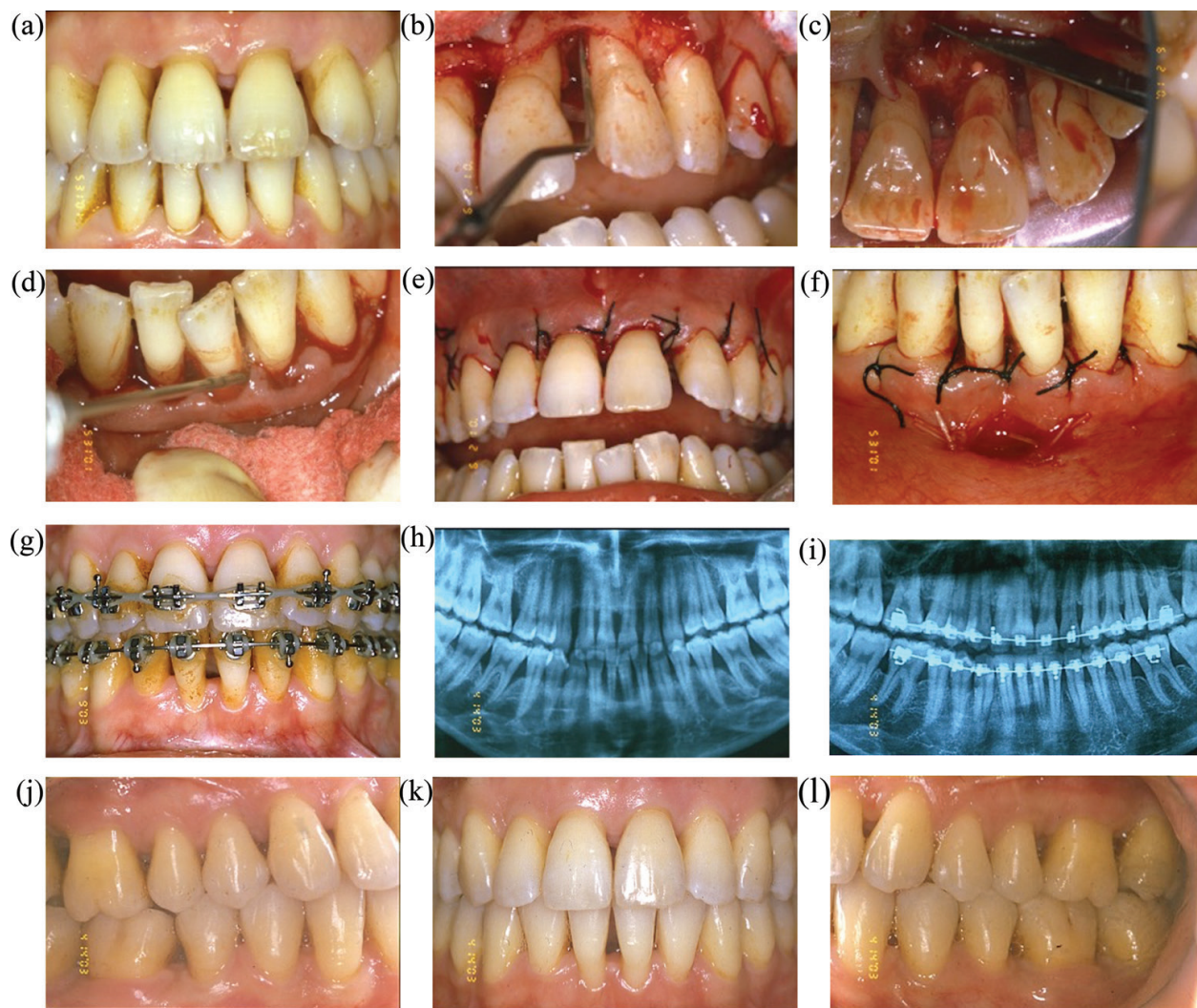

Figure 3. Patient F.G. (a) Intraoral aspect 2 weeks after completion of periodontal causal therapy (scaling and root planing). Notice the gingival recession that follows the reduction of inflammation; (b, c) open flap debridement on vestibular and palatal side; (d) injection of enamel matrix derivatives; (e, f) flap adaptation and suturing on the maxillary and mandibular arch. Because of the post-periodontal therapy recession, the flap adaptation results more challenging; (g) orthodontic therapy during space closure phase; (h) panoramic radiograph before periodontal therapy; (i) panoramic radiograph during orthodontic therapy. Please notice the overall enhancement of bone level and reduction of infrabony defects. (j, k, l) intraoral aspects at the day of orthodontic appliance removal. The patient showed great compliance during the entire treatment.

deep debridement and regeneration in a unique phase intra-surgically proceeded only by superficial debridement in order to avoid gingival recession and to have the possibility to reposition the soft tissues more coronally. This would allow for unaltered aesthetics and better root coverage, especially considering the fact that flap adaption is a crucial aspect of the healing quality (**Figures 4a–g** and **5a–g**). Despite the preferred approach, the surgical stage should be followed by a healing time before orthodontic therapy commencement. This period would allow for connective tissue stabilization and remodelling, restoration of health and evaluation of patient's compliance [12]. If the regenerative therapy is integrated into an ongoing orthodontic treatment, the compromised teeth should be immobilized through rigid splinting in order to stabilize the clot and the regenerative material throughout the healing phase.

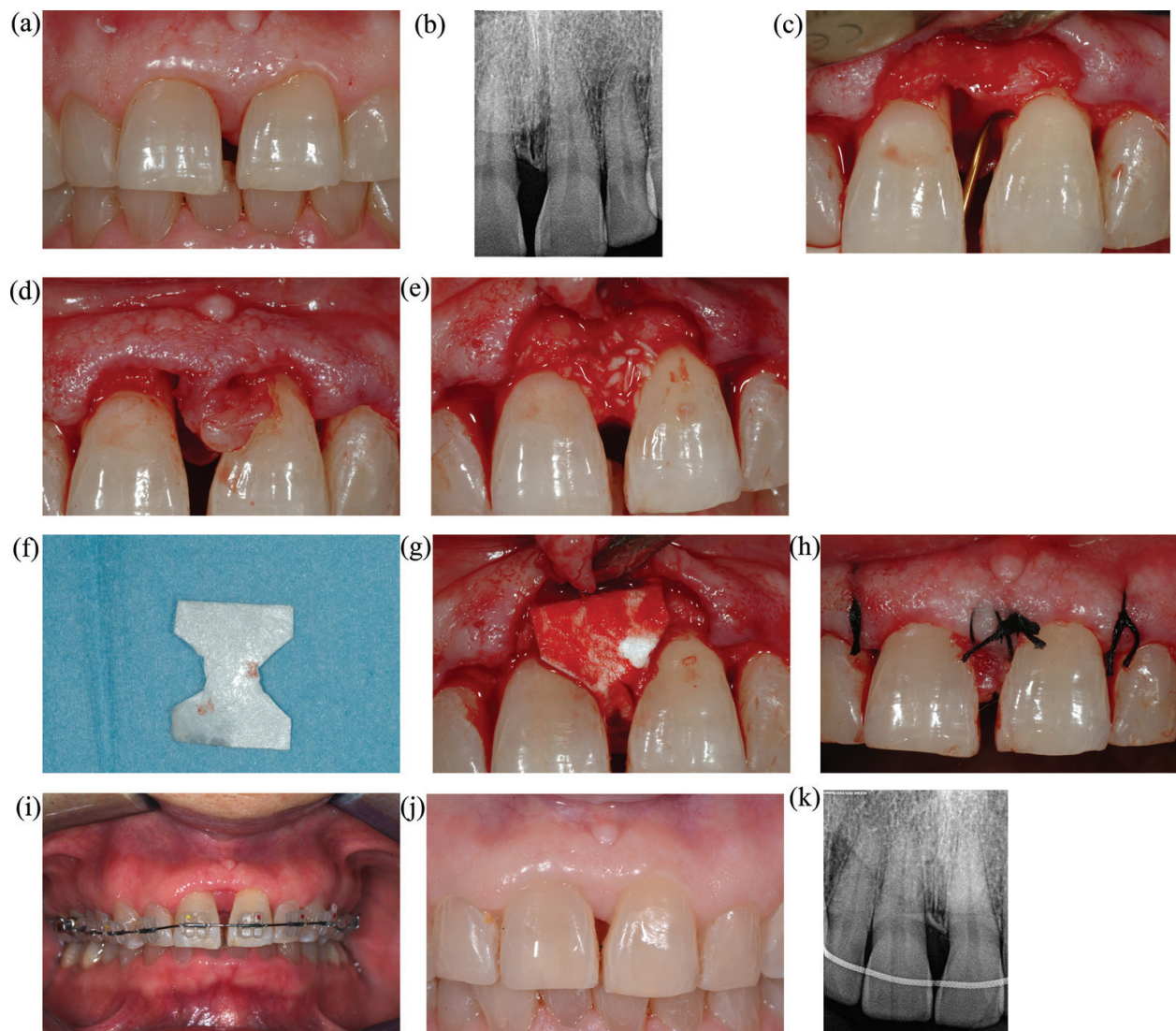


Figure 4. Thirty-eight-year-old female patient (T.A.), whose midline diastema was opened during the past 3 years. Major request was diastema closure. (a) Initial intraoral aspect; (b) initial radiograph; (c) deep manual debridement during surgical intervention. A supragingival debridement was previously performed; (d) sufficient gingival tissue for appropriate coverage of regenerative materials; (e) synthetic bone grafting; (f) membrane shaped extraorally following the area to be covered; (g) adaptation of the membrane in order to cover all grafting material; (h) suturing with coronal flap adaptation; (i) orthodontic treatment started 3 months after surgery; (j) clinical aspect at the end of orthodontic treatment; (k) radiograph at the end of orthodontic treatment with lingual fixed retainer.

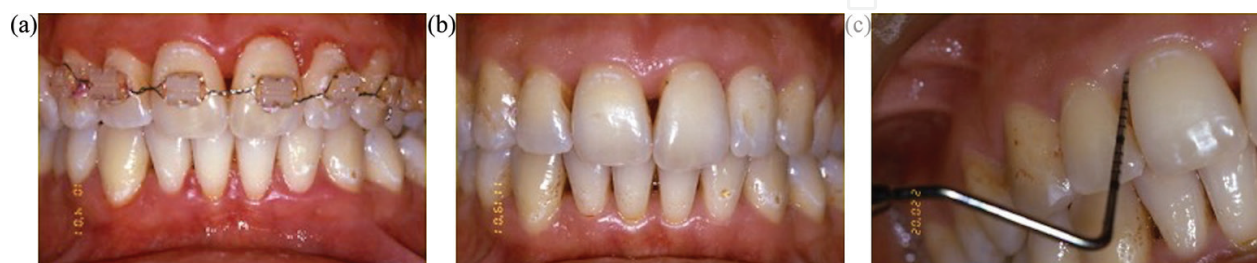

Figure 5. (a) Gingivitis present during orthodontic therapy. (b) when the inflammation is limited only at the gingival level and the deep periodontal tissue is not compromised, after orthodontic appliance removal the gingival inflammation disappears. (c) Periodontal probing after orthodontic appliance removal indicates healthy periodontal state.

The regenerative therapy might follow several approaches, including open flap debridement, guided tissue regeneration (GTR) associated or not with different types of bone grafting, growth factors and more recently also stem cell-based therapy [13–15]. Utilization of mesenchymal stem cells in periodontal regenerative therapy has already resulted in promising outcomes that need to be further elucidated especially in terms of cell survival and efficient expression of programmed proliferative capacity to consent fully translation of mesenchymal stem cell-based therapy into clinical practice [15–22]. Irrespective of the chosen regenerative approach, the orthodontic treatment that follows should aim for elimination of occlusal traumatic contacts and establishment of a functional occlusion, which is one of the major factors for maintenance of periodontal health. Dental implant therapy for tooth replacement is incorporated after a thorough treatment planning followed by the positioning of teeth and roots into correct positions. If implants are planned and inserted before the end of orthodontic therapy, they might also be used as an anchorage unit for facilitating the orthodontic treatment. Maintenance of periodontal health is of utmost importance also for implants success and survival. Patients susceptible to periodontal pathologies are more prone to peri-implant inflammation and implant failure. Potential prosthetic restorations are usually performed at the end of orthodontic therapy, aiming reconstruction of lost tooth tissues or replacement of missing crowns.

Most of adult patients suffer also from enamel and dentine excessive consumption especially at the cervical area, which results in highly compromised aesthetics, hypersensitivity and important discomfort [23, 24]. Treatment of these cervical, non-carious defects is mainly focused on hypersensitivity reduction [25], whereas hard tissue reconstruction remains a controversial and challenging issue, especially considering the aetiology and progress of such pathology. Recent emerging technologies have proposed restoration of dental enamel using high repetition rate femtosecond lasers and novel iron-doped calcium phosphate biomaterials. During this procedure, the irradiated mineral transforms into a densified layer of acid-resistant ion-doped β -pyrophosphate, which bonds with enamel and dentine surface of non-carious lesions [26, 27]. This promising technology is yet to be fully developed for optimal clinical usage.

Attempts in reducing duration of orthodontic treatment especially in adult patients have recently resulted in therapies combining surgical and non-surgical approaches to orthodontics. Even if surgical adjunctive therapies have been studied for many decades, their overall benefit is still questionable, whereas non-surgical approaches do not provide solid scientific bases for incorporation into everyday clinical practice [28, 29]. Careful consideration of patient-centred aspects, treatment time and overall cost-benefits must be performed for a thorough estimation of these approaches.

Each adult patient is a challenging situation that in the majority of cases requires the periodontal and orthodontic therapy for denture preparation and later prosthetic therapy for full rehabilitation. In almost all cases of mature patients, orthodontic treatment alone would not result in the best possible approach for oral functional and aesthetic rehabilitation and sometimes it would also deteriorate the overall state of oral health.

It should be bared in mind that all orthodontic movements are guided by a periodontal dimension that should be of primary consideration during treatment planning and application of orthodontic biomechanics. On the other hand, correct functional occlusion and ideal tooth position are one of the major prerequisites for maintenance of periodontal health.

3. Interrelationship between periodontics and orthodontics in adult patients

3.1. Periodontal considerations during adult orthodontic treatment

The presence of healthy periodontal tissues is of vital importance for undertaking any kind of orthodontic or prosthetic therapy. In adult patients, even if periodontal tissues might be reduced and have compromised sustaining capacity, they should be free of inflammation. All attempts in applying an orthodontic treatment on inflamed periodontal tissues will aggravate the periodontal state and result in an iatrogenic damage [30].

Components of orthodontic appliances predispose aggregation of bacterial plaque which, if not properly controlled through accurate hygiene regimen, might trigger gingivitis or its conversion into periodontitis [31, 32]. On the other hand, when a thorough oral hygiene regimen is applied, gingivitis is easily controlled, and when no other periodontal tissues get involved, it seems to disappear in long term after appliance removal (**Figure 5**) [12, 33]. Periodontal short-term effects after orthodontic therapy remain controversial [34], which suggest that in all cases orthodontic patients are at a higher risk for periodontal disease development. The increasing demand for orthodontic treatment and the occurrence of biofilm-related complications has positioned orthodontic treatment as a potential public health threat [35].

Independent of whether the periodontal health is compromised or not, in all adult patients, particular attention should be paid to avoid when possible bulk elements such as bands or other orthodontic components placed close to gingival margin that apart from plaque retention might cause marginal gingival injury and attachment loss. In this respect, orthodontic treatments based on removable appliances or aligners permit unimpeded oral hygiene and result in better periodontal health [36]. Nonetheless, while these aligners behave superiorly in terms of oral hygiene maintenance and periodontal health, other important considerations, such as occlusal interferences, gnathologic effects and postural ones, must be made before applying them.

According to the 'bone envelope' theory, orthodontic tooth movement should be performed within an anatomically and functionally periodontal limited space which is in any case to be respected in order to obtain the desired movement. If the periodontal space is violated, its connective tissue might react through a series of mechanisms such as bone dehiscence and fenestration, gingival inflammation and gingival recession. Apical migration of the gingiva (gingival recession) has an unpleasant effect in both aesthetics and cervical dentinal hypersensitivity. It might be caused by periodontitis, gingival trauma and specific anatomical conditions such as tooth crowding or muscular inserts. It has been demonstrated that in cases of tooth movement beyond the 'alveolar envelope' such as uncontrolled orthodontic movement, the recession might arise immediately but also years after, resulting in unpleasant post-treatment effects [37, 38]. It has been reported that factors related to the development or progression of recessions in adult patients are the presence of pre-treatment recessions, thin gingival biotype, reduced width of keratinized gingiva and visual gingival inflammation [39]. Other features, such as gingival margin thickness smaller than 0.5 mm and vestibular incisor inclination (over 95°), have also been associated with higher incidence and severity of recession [40]. In cases of pre-existing recessions, it is recommended that mucogingival interceptive surgery

be accomplished before orthodontic therapy to maintain the width of keratinized gingiva in the long term [41].

Every orthodontic movement induces remodelling and reorganization of periodontal tissues. It is demonstrated that light and continuous forces illicit non-destructive periodontal turnover, whereas heavy forces might result in necrotic periodontal tissue and further irreversible periodontal damage. Another consequence of these uncontrolled and heavy forces might be the root resorption, which is of extreme importance in teeth with reduced periodontium as further loss of periodontal support results in increased crown-root ratio and in compromised stability and aesthetics. Peculiar control of force levels has been outlined especially for orthodontic intrusion where the surface of force application is reduced. Intrusion also requires absolute control of inflammation and bacterial biofilms in order to avoid any aggravation or creation of infrabony defect and loss of attachment [42–45].

In most adult patients, the already-compromised periodontal tissue would need particular care in order to avoid further destruction and when possible aim for periodontal health enhancement.

Professional cleaning and examination of periodontal tissues should be performed routinely during the entire orthodontic treatment, following a personalized schedule that is determined by the individual risk factors and the specific treatment plan.

In all cases, orthodontic treatment should be suspended if patient fails to comply in maintaining the appropriate level of oral hygiene.

3.2. Orthodontics as a tool for periodontal health enhancement

Orthodontic therapy on adult patients has become particularly popular in the last few decades, following the general trend of the modern life where overall aesthetic enhancement has become one of the major priorities. However, orthodontic treatment as a corrective tool that eliminates pathologic migration of teeth on periodontally compromised patients had been suggested long time ago in the literature, by authors such as Neustadt [46] Dummett [47] and Scoop [48]. Later studies conducted principally on animal models confirmed the beneficial effect of orthodontic therapy on periodontal health. The results of these animal studies demonstrated that movements of teeth with infrabony defects in an inflammation-free environment result in elimination of the bone defect through creation of a long epithelial junction [49, 50].

Extrapolation of animal studies' findings to human conditions has been questioned, mostly because of the specific pattern of attachment loss that occurs on humans [51]. However, it is well established that in the absence of periodontal inflammation, the biological process of bone resorption and apposition during orthodontic tooth movement might positively influence the healing of periodontal defects. Similarly, the positioning of teeth into correct occlusal relations, which allow for axial and physiological distribution of masticatory forces, results in reduced stress to periodontal tissues. Moreover, such an occlusal stability contributes in diminishing mesial migration of posterior teeth and related consequences such as incorrect

interdental contact points, flaring of incisor teeth and diastema opening. All these clinical symptoms are typical in adult patients, in which the malocclusion is aggravated by chronic periodontitis, resulting in the establishment of a vicious cycle where the two pathologies contribute to the exacerbation of each other (**Figure 6**). If the therapeutic approach does not account for both pathologies and does not follow a correct protocol starting with periodontal therapy and stabilization, the final result and its maintenance are highly questionable.

The orthodontic therapy can contribute to the improvement of periodontal health through reduction of intraosseous defects or furcation lesions [52–56]. It can also help in reducing gingival recession, levelling uneven gingival margins or rebuilding missing interdental papilla [12, 57, 58].

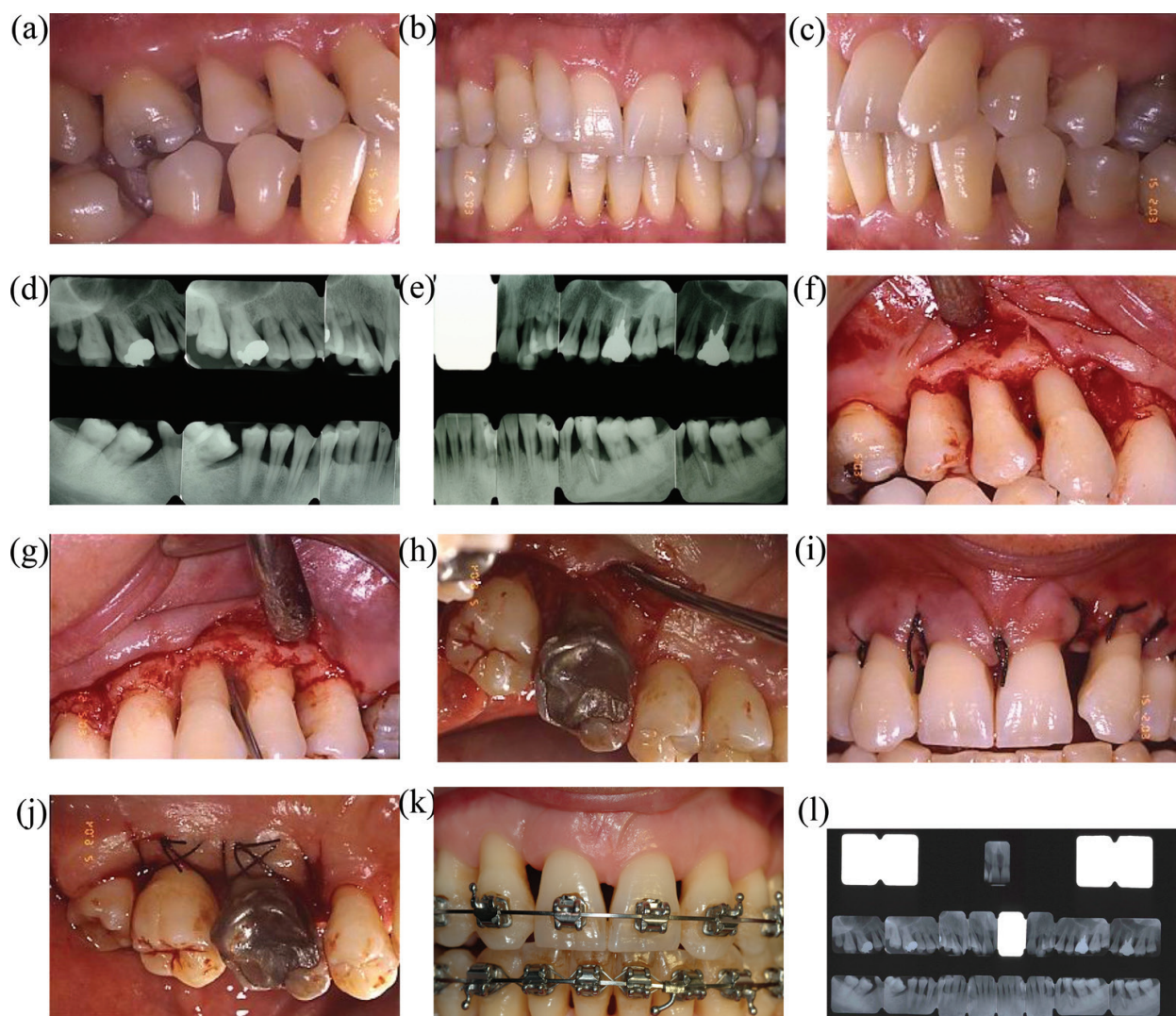


Figure 6. (a–e) The periodontal pathology has contributed in aggravating the malocclusion, characterized mainly by mesial tipping of posterior teeth, incisors flaring and diastema opening; (f–h) open flap debridement and regeneration; (i, j) soft tissue adaptation and suturing; (k) orthodontic therapy performed on a reduced periodontal tissue but with no active inflammation; (l) set of periapical radiographs after orthodontic alignment.

However, as reported by several recent systematic reviews, despite the major interest in trying to understand the beneficial effect of orthodontic therapy on periodontal health, the orthodontic scientific evidence still lacks solid protocols in this field and human studies are poor both qualitatively and quantitatively [44, 45, 54].

3.3. Post-orthodontic stability

Preservation of final orthodontic result is often considered as the third phase of overall orthodontic therapy and its major long-term goal. Post-orthodontic relapse has been mainly attributed to elasticity of gingival tissues that are compressed towards the direction of tooth movement. Considering this, the suggested retention period should exceed the time for remodelling of periodontal fibres, which usually ranges from 4 to 6 months [59, 60]. In order to enhance post-treatment stability attributed to soft periodontal fibres, many authors have suggested adjunctive interventions such as overcorrection, interproximal reduction or circumferential fibrotomy of supracrestal gingival fibres [61]. The variety of retainers is represented by the two big categories of fixed and removable ones. Scientific data report controversial opinions regarding the retentive method of choice for patients with reduced periodontal support. While the fixed retainer assures firm position and satisfying long-term stability, it does not allow for teeth to retain their physiological mobility, and in most cases, it impedes maintenance of good oral hygiene which is of fundamental importance for these patients [62]. In all cases, bulk fixed retentions that block easy access through interdental spaces should be avoided and patients should be given exhaustive instructions for appropriate oral hygiene maintenance (**Figure 7**).

Finally, despite the importance of considering all periodontal and mechanical features of retentive devices, the authors of the present manuscript consider of primary importance for long term retention a final orthodontic result that assures occlusal stability, meaning correct teeth positioning, physiological movement with no interferences or dislocating pre-contacts [63]. It is extremely relevant to recognize the importance of a good balance between static and dynamic occlusion and all related craniofacial structures represented by temporomandibular joint (TMJ) and the neuromuscular system for both oral rehabilitation and long-term stability. A final orthodontic result that respects these parameters is the best tool for physiological retention, with no need for external mechanical elements (**Figure 8**).

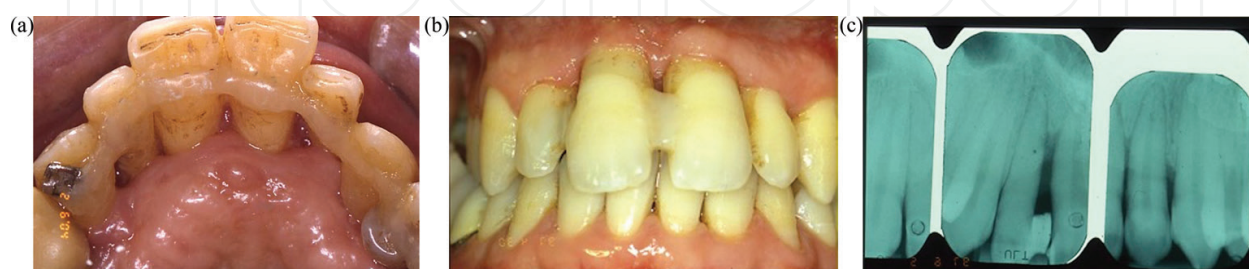

Figure 7. (a, b) Bulk lingual and vestibular splinting of teeth, which do not allow for appropriate oral hygiene maintenance. (c) Radiographic image showing the complete loss of periodontal support.

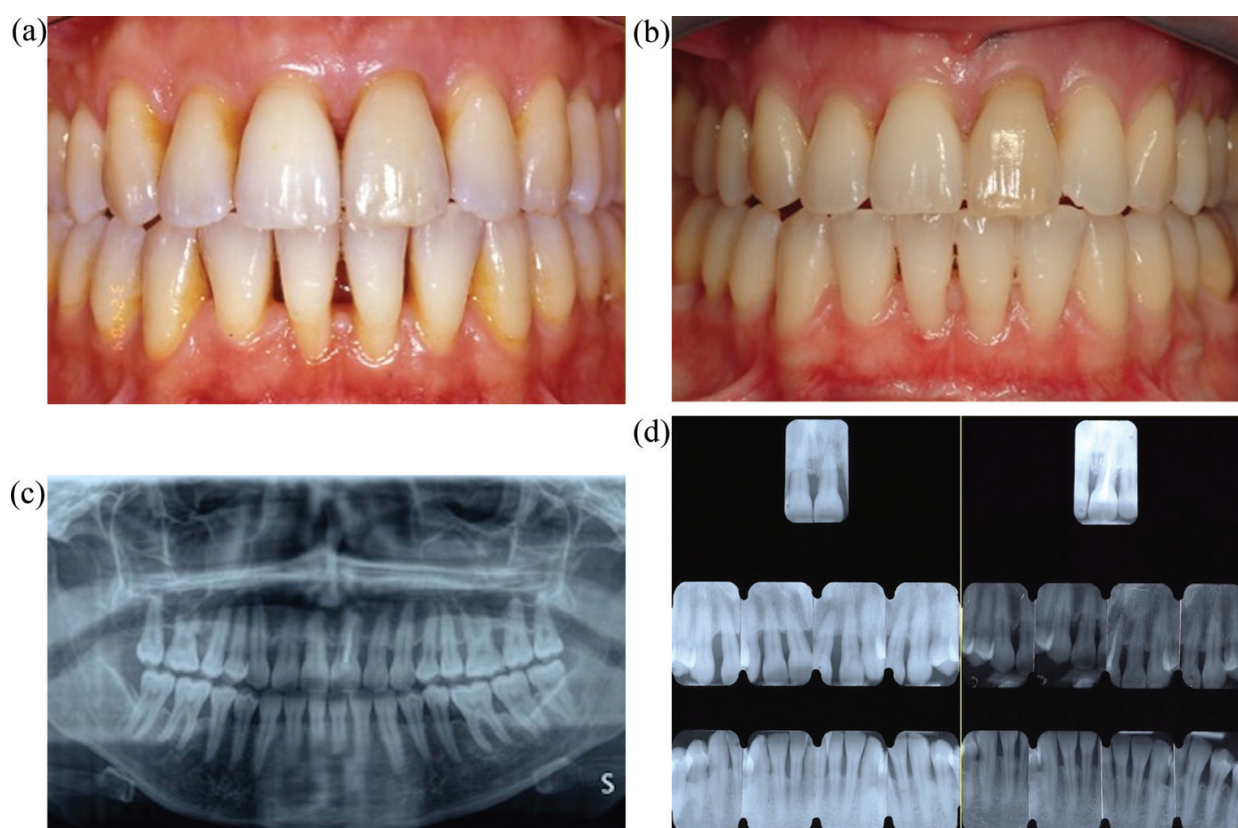


Figure 8. (a) Clinical check at 7 years of follow-up. (b) Clinical check at 13 years of follow-up. (c) Panoramic radiograph at 13 years of follow-up. (d) Periodontal radiographic status before the therapy and 13 years after the therapy with no fixed orthodontic retainer.

Acknowledgements

The authors acknowledge the financial support of EU-Marie-Curie-IAPP LUSTRE (324538) project.

Author details

Zamira Kalemaj^{1*}, Antonios D. Anastasiou¹, Animesh Jha¹ and Felice R. Grassi²

*Address all correspondence to: kalemajzamira@gmail.com

¹ Faculty of Engineering, School of Chemical and Process Engineering, University of Leeds, United Kingdom

² Department of Basic and Medical Sciences, Neurosciences and Sense Organs, University of Bari, Italy

References

- [1] Sofaer JA. Genetic approaches in the study of periodontal diseases. *Journal of Clinical Periodontology* [Internet]. 1990;**17**(7):401-408. Available from: <http://doi.wiley.com/10.1111/j.1600-051X.1990.tb02337.x> [Accessed: 19 March 2017]
- [2] Johnson NW, Griffiths GS, Wilton JM, Maiden MF, Curtis MA, Gillett IR, et al. Detection of high-risk groups and individuals for periodontal diseases. Evidence for the existence of high-risk groups and individuals and approaches to their detection. *Journal of Clinical Periodontology* [Internet]. 1988;**15**(5):276-282. Available from: <http://www.ncbi.nlm.nih.gov/pubmed/3292592> [Accessed: 19 March 2017]
- [3] Lopez R, Hujoel P, Belibasakis GN. On putative periodontal pathogens: An epidemiological perspective. *Virulence*. 2015;**6**(3):249-257. [Internet]. Available from: <http://www.ncbi.nlm.nih.gov/pubmed/25874553> [Accessed: 19 March 2017]
- [4] Brunetti G, Oranger A, Mori G, Sardone F, Pignataro P, Coricciati M, et al. TRAIL effect on osteoclast formation in physiological and pathological conditions. *Frontiers in Bioscience (Elite Ed)*. 2011;**3**:1154-1161. [Internet]. Available from: <http://www.ncbi.nlm.nih.gov/pubmed/21622121> [Accessed: 17 September 2016]
- [5] Chatzopoulos G-S, Doufexi A-E, Kalogirou F. Association of susceptible genotypes to periodontal disease with the clinical outcome and tooth survival after non-surgical periodontal therapy: A systematic review and meta-analysis. *Medicina Oral, Patologia Oral Y Cirugia Bucal*. 2016;**21**(1):e14–e29. [Internet]. Available from: <http://www.ncbi.nlm.nih.gov/pubmed/26595831> [Accessed: 19 March 2017]
- [6] Braun TM, Doucette-Stamm L, Duff GW, Kornman KS, Giannobile WV. Counterpoint: Risk factors, including genetic information, add value in stratifying patients for optimal preventive dental care. *Journal of the American Dental Association*. 2015;**146**(3):174-178. [Internet]. Available from: <http://linkinghub.elsevier.com/retrieve/pii/S0002817715002378> [Accessed: 17 May 2017]
- [7] Haber J, Wattles J, Crowley M, Mandell R, Joshipura K, Kent RL. Evidence for cigarette smoking as a major risk factor for periodontitis. *Journal of Periodontology*. 1993;**64**(1):16-23. [Internet]. Available from: <http://www.ncbi.nlm.nih.gov/pubmed/8426285> [Accessed: 18 May 2017]
- [8] Gupta N, Gupta ND, Goyal L, Moin S, Khan S, Gupta A, et al. The influence of smoking on the levels of matrix metalloproteinase-8 and periodontal parameters in smoker and nonsmoker patients with chronic periodontitis: A clinicobiochemical study. *Journal of Oral Biology and Craniofacial Research*. 2016;**6**(Suppl 1):S39–S43. [Internet]. Available from: <http://www.ncbi.nlm.nih.gov/pubmed/27900249> [Accessed: 18 May 2017]
- [9] Gupta N, Gupta ND, Garg S, Goyal L, Gupta A, Khan S, et al. The effect of type 2 diabetes mellitus and smoking on periodontal parameters and salivary matrix metalloproteinase-8 levels. *Journal of Oral Science*. 2016;**58**(1):1-6. [Internet]. Available from: <http://www.ncbi.nlm.nih.gov/pubmed/27021533> [Accessed: 18 May 2017]

- [10] Drisko CL. Periodontal debridement: Still the treatment of choice. *Journal of Evidence-Based Dental Practice*. 2014;**14**:33-41.e1. [Internet]. Available from: <http://www.ncbi.nlm.nih.gov/pubmed/24929587> [Accessed: 17 May 2017]
- [11] Socransky SS, Haffajee AD. The nature of periodontal diseases. *Annals of Periodontology*. 1997;**2**(1):3-10. [Internet]. Available from: <http://www.ncbi.nlm.nih.gov/pubmed/9151538> [Accessed: 18 May 2017]
- [12] Gkantidis N, Christou P, Topouzelis N. The orthodontic-periodontic interrelationship in integrated treatment challenges: A systematic review. *Journal of Oral Rehabilitation*. 2010;**37**(5):377-390. [Internet]. Available from: <http://www.ncbi.nlm.nih.gov/pubmed/20202098> [Accessed: 19 March 2017]
- [13] Needleman I, Worthington H V, Giedrys-Leeper E, Tucker R. Guided tissue regeneration for periodontal infra-bony defects. In: Needleman I, editor. *Cochrane Database of Systematic Reviews*. Chichester, UK: John Wiley & Sons, Ltd; 2006. p. CD001724 [Internet]. Available from: <http://www.ncbi.nlm.nih.gov/pubmed/16625546> [Accessed: 18 May 2017]
- [14] Ogihara S, Marks MH. Enhancing the regenerative potential of guided tissue regeneration to treat an intrabony defect and adjacent ridge deformity by orthodontic extrusive force. *Journal of Periodontology*. 2006;**77**(12):2093-2100 [Internet]. Available from: <http://www.ncbi.nlm.nih.gov/pubmed/17209797> [Accessed: 18 May 2017]
- [15] Scarano A, Crincoli V, Di Benedetto A, Cozzolino V, Lorusso F, Podaliri Vulpiani M, et al. Bone regeneration induced by bone porcine block with bone marrow stromal stem cells in a minipig model of mandibular “Critical Size” defect. *Stem Cells International*. 2017;**2017**:1-9 [Internet]. Available from: <https://www.hindawi.com/journals/sci/2017/9082869/> [Accessed: 18 May 2017]
- [16] Brunetti G, Oranger A, Mori G, Tamma R, Di Benedetto A, Pignataro P, et al. TRAIL is involved in human osteoclast apoptosis. *Annals of the New York Academy of Sciences*. 2007;**1116**(1):316-322 [Internet] Available from: <http://doi.wiley.com/10.1196/annals.1402.011> [Accessed: 17 September 2016]
- [17] Mori G, Brunetti G, Oranger A, Carbone C, Ballini A, Lo Muzio L, et al. Dental pulp stem cells: osteogenic differentiation and gene expression. *Annals of the New York Academy of Sciences*. 2011;**1237**:47-52 [Internet]. Available from: <http://www.ncbi.nlm.nih.gov/pubmed/22082364> [Accessed: 18 September 2016]
- [18] Mori G, Centonze M, Brunetti G, Ballini A, Oranger A, Mori C, et al. Osteogenic properties of human dental pulp stem cells. *Journal of Biological Regulators and Homeostatic Agents*. **24**(2):167-175 [Internet] Available from: <http://www.ncbi.nlm.nih.gov/pubmed/20487630> [Accessed: 8 September 2016]
- [19] Brunetti G, Colucci S, Pignataro P, Coricciati M, Mori G, Cirulli N, et al. T cells support osteoclastogenesis in an in vitro model derived from human periodontitis patients. *Journal of Periodontology*. 2005;**76**(10):1675-1680 [Internet]. Available from: <http://www.ncbi.nlm.nih.gov/pubmed/16253089> [Accessed: 17 September 2016]

- [20] Scarano A, Crincoli V, Di Benedetto A, Cozzolino V, Lorusso F, Podaliri Vulpiani M, et al. *Stem Cells Int.* 2017;**2017**:9082869
- [21] Colucci S, Mori G, Brunetti G, Coricciati M, Pignataro P, Oranger A, et al. Interleukin-7 production by B lymphocytes affects the T cell-dependent osteoclast formation in an in vitro model derived from human periodontitis patients. *International Journal of Immunopathology and Pharmacology.* **18**(3 Suppl):13-19. Available from: <http://www.ncbi.nlm.nih.gov/pubmed/16848983> [Accessed: 17 September 2016]
- [22] Di Benedetto A, Brunetti G, Posa F, Ballini A, Grassi FR, Colaianni G, et al. Osteogenic differentiation of mesenchymal stem cells from dental bud: Role of integrins and cadherins. *Stem Cell Research.* 2015;**15**(3):618-628 [Internet]. Available from: <http://www.ncbi.nlm.nih.gov/pubmed/26513557> [Accessed: 20 May 2017]
- [23] Martens LC. A decision tree for the management of exposed cervical dentin (ECD) and dentin hypersensitivity (DHS). *Clinical Oral Investigations.* 2013;**17**(S1):77-83 [Internet]. Available from: <http://www.ncbi.nlm.nih.gov/pubmed/23262746> [Accessed: 19 May 2017]
- [24] van Loveren C. Exposed cervical dentin and dentin hypersensitivity summary of the discussion and recommendations. *Clinical Oral Investigations.* 2013;**17**(S1):73-76 [Internet]. Available from: <http://www.ncbi.nlm.nih.gov/pubmed/23224117> [Accessed: 2017 May 19]
- [25] Zhu M, Li J, Chen B, Mei L, Yao L, Tian J, et al. The effect of calcium sodium phosphosilicate on dentin hypersensitivity: A systematic review and meta-analysis. Milgrom PM, editor. *PLoS One* [Internet]. 2015;**10**(11):e0140176. Available from: <http://www.ncbi.nlm.nih.gov/pubmed/26544035> [Accessed: 19 May 2017]
- [26] Anastasiou AD, Thomson CL, Hussain SA, Edwards TJ, Strafford S, Malinowski M, et al. Sintering of calcium phosphates with a femtosecond pulsed laser for hard tissue engineering. *Materials & Design.* 2016;**101**:346-354 [Internet]. Available from: <http://www.sciencedirect.com/science/article/pii/S026412751630452X> [Accessed: 18 May 2017]
- [27] Anastasiou AD, Strafford S, Posada-Estefan O, Thomson CL, Hussain SA, Edwards TJ, et al. β -pyrophosphate: A potential biomaterial for dental applications. *Materials Science and Engineering: C.* 2017;**75**:885-894 [Internet]. Available from: <http://www.sciencedirect.com/science/article/pii/S0928493116319129> [Accessed: 18 May 2017]
- [28] Kalemaj Z, Debernardi CL, Buti J. Efficacy of surgical and non-surgical interventions on accelerating orthodontic tooth movement: A systematic review. *European Journal of Oral Implantology.* 2015;**8**(1):9-24 [Internet]. Available from: <http://www.ncbi.nlm.nih.gov/pubmed/25738176> [Accessed: 29 November 2015]
- [29] Kalemaj Z, Buti J, Deregibus A, Canuto RM, Maggiora M, Debernardi CL. Aligning effectiveness, secretion of interleukin 1 β and pain control during fixed orthodontic treatment with Self-Ligating appliances and supplemental vibrational appliances. A randomized

- controlled clinical trial. *Journal of Biomedical*. 2017;**2**(1):25-33 [Internet]. Available from: <http://www.jbiomed.com/v02p0025.htm> [Accessed: 20 May 2017]
- [30] Melsen B. Tissue reaction to orthodontic tooth movement—A new paradigm. *European Journal of Orthodontics*. 2001;**23**(6):671-681 [Internet]. Available from: <http://www.ncbi.nlm.nih.gov/pubmed/11890063> [Accessed: 18 May 2017]
- [31] Paolantonio M, Festa F, di Placido G, D’Attilio M, Catamo G, Piccolomini R. Site-specific subgingival colonization by *Actinobacillus actinomycetemcomitans* in orthodontic patients. *American Journal of Orthodontics and Dentofacial Orthopedics*. 1999;**115**(4):423-428 [Internet]. Available from: <http://www.ncbi.nlm.nih.gov/pubmed/10194288> [Accessed: 19 March 2017]
- [32] Topaloglu-Ak A, Ertugrul F, Eden E, Ates M, Bulut H. Effect of orthodontic appliances on oral microbiota—6 month follow-up. *Journal of Pediatric Dentistry*. 2011;**35**(4):433-436 [Internet]. Available from: <http://www.ncbi.nlm.nih.gov/pubmed/22046705> [Accessed: 19 March 2017]
- [33] Diamanti-Kipioti A, Gusberti FA, Lang NP. Clinical and microbiological effects of fixed orthodontic appliances. *Journal of Clinical Periodontology*. 1987;**14**(6):326-333 [Internet]. Available from: <http://www.ncbi.nlm.nih.gov/pubmed/3509967> [Accessed: 19 March 2017]
- [34] Pan S, Liu Y, Zhang L, Li S, Zhang Y, Liu J, et al. Profiling of subgingival plaque biofilm microbiota in adolescents after completion of orthodontic therapy. Ojcius DM, editor. *PLoS One* [Internet]. 2017;**12**(2):e0171550. Available from: <http://www.ncbi.nlm.nih.gov/pubmed/28158292> [Accessed: 19 March 2017]
- [35] Ren Y, Jongsma MA, Mei L, van der Mei HC, Busscher HJ. Orthodontic treatment with fixed appliances and biofilm formation—A potential public health threat? *Clinical Oral Investigations*. 2014;**18**(7):1711-1718 [Internet]. Available from: <http://www.ncbi.nlm.nih.gov/pubmed/24728529> [Accessed: 19 March 2017]
- [36] Azaripour A, Weusmann J, Mahmoodi B, Peppas D, Gerhold-Ay A, Van Noorden CJF, et al. Braces versus Invisalign®: Gingival parameters and patients’ satisfaction during treatment: A cross-sectional study. *BMC Oral Health*. 2015;**15**(1):69 [Internet]. Available from: <http://www.ncbi.nlm.nih.gov/pubmed/26104387> [Accessed: 19 March 2017]
- [37] Tatakis DN, Chambrone L, Allen EP, Langer B, McGuire MK, Richardson CR, et al. Periodontal soft tissue root coverage procedures: A consensus report from the AAP regeneration workshop. *Journal of Periodontology*. 2015;**86**(2-s):S52–S55 [Internet]. Available from: <http://www.ncbi.nlm.nih.gov/pubmed/25315018> [Accessed: 16 March 2017]
- [38] Bueno Rossy LA, Chambrone L. Management of multiple recession-type defects after orthodontic therapy: A clinical report based on scientific evidence. *American Academy of Periodontology*. 2016;**6**(2):70-75 [Internet]. Available from: <http://www.joponline.org/doi/10.1902/cap.2015.150034> [Accessed: 16 March 2017]

- [39] Melsen B, Allais D. Factors of importance for the development of dehiscences during labial movement of mandibular incisors: A retrospective study of adult orthodontic patients. *American Journal of Orthodontics and Dentofacial Orthopedics*. 2005;**127**(5):552-561; quiz 625 [Internet]. Available from: <http://linkinghub.elsevier.com/retrieve/pii/S0889540604011126> [Accessed: 19 May 2017]
- [40] Yared KFG, Zenobio EG, Pacheco W. Periodontal status of mandibular central incisors after orthodontic proclination in adults. *American Journal of Orthodontics and Dentofacial Orthopedics*. 2006;**130**(1):6.e1-8 [Internet]. Available from: <http://linkinghub.elsevier.com/retrieve/pii/S0889540606002940> [Accessed: 19 May 2017]
- [41] Pini Prato G, Baccetti T, Magnani C, Agudio G, Cortellini P. Mucogingival interceptive surgery of buccally-erupted premolars in patients scheduled for orthodontic treatment I. A 7-year longitudinal study. *Journal of Periodontology*. 2000;**71**(2):172-181 [Internet]. Available from: <http://www.ncbi.nlm.nih.gov/pubmed/10711607> [Accessed: 19 May 2017]
- [42] Redlich M, Shoshan S, Palmon A. Gingival response to orthodontic force. *American Journal of Orthodontics and Dentofacial Orthopedics*. 1999;**116**(2):152-158 [Internet]. Available from: <http://www.ncbi.nlm.nih.gov/pubmed/10434088> [Accessed: 19 May 2017]
- [43] Murakami T, Yokota S, Takahama Y. Periodontal changes after experimentally induced intrusion of the upper incisors in *Macaca fuscata* monkeys. *American Journal of Orthodontics and Dentofacial Orthopedics*. 1989;**95**(2):115-126 [Internet]. Available from: <http://www.ncbi.nlm.nih.gov/pubmed/2916468> [Accessed: 19 May 2017]
- [44] Corrente G, Abundo R, Re S, Cardaropoli D, Cardaropoli G. Orthodontic movement into infrabony defects in patients with advanced periodontal disease: A clinical and radiological study. *Journal of Periodontology*. 2003;**74**(8):1104-1109 [Internet]. Available from: <http://www.ncbi.nlm.nih.gov/pubmed/14514223> [Accessed: 19 March 2017]
- [45] Cardaropoli D, Re S, Corrente G, Abundo R. Intrusion of migrated incisors with infrabony defects in adult periodontal patients. *American Journal of Orthodontics and Dentofacial Orthopedics*. 2001;**120**(6):671-675 [Internet]. Available from: <http://www.ncbi.nlm.nih.gov/pubmed/11742313> [Accessed: 19 March 2017]
- [46] Neustadt E. The orthodontist's responsibility in the prevention of periodontal disease. *Journal of the American Dental Association*. 1930;**17**:1329
- [47] Dummet CO. Orthodontics and periodontal disease. *Journal of Periodontology*. 1951;**22**:34-41
- [48] Scopp IW, Bien SM. The principles of correction of simple malocclusion in the treatment of periodontal disease. *Journal of Periodontology*. 1952;**23**:135-143
- [49] Polson A, Caton J, Polson AP, Nyman S, Novak J, Reed B. Periodontal response after tooth movement into intrabony defects. *Journal of Periodontology*. 1984;**55**(4):197-202 [Internet]. Available from: <http://www.ncbi.nlm.nih.gov/pubmed/6585537> [Accessed: 19 March 2017]

- [50] Wennström JL, Stokland BL, Nyman S, Thilander B. Periodontal tissue response to orthodontic movement of teeth with infrabony pockets. *American Journal of Orthodontics and Dentofacial Orthopedics*. 1993;**103**(4):313-319 [Internet]. Available from: <http://www.ncbi.nlm.nih.gov/pubmed/8480696> [Accessed: 19 March 2017]
- [51] Harrel SK, Nunn ME, Hallmon WW. Is there an association between occlusion and periodontal destruction?: Yes—Occlusal forces can contribute to periodontal destruction. *Journal of the American Dental Association*. 2006;**137**(10):1380, 1382, 1384 passim [Internet]. Available from: <http://www.ncbi.nlm.nih.gov/pubmed/17012716> [Accessed: 18 May 2017]
- [52] Ingber JS. Forced eruption: Part I. A method of treating isolated one and two wall infrabony osseous defects—Rationale and case report. *Journal of Periodontology*. 1974;**45**(4):199-206 [Internet]. Available from: <http://www.ncbi.nlm.nih.gov/pubmed/4522455> [Accessed: 18 May 2017]
- [53] Joo J-Y, Kwon E-Y, Lee J-Y. Intentional passive eruption combined with scaling and root planing of teeth with moderate chronic periodontitis and traumatic occlusion. *Journal of Periodontal & Implant Science*. 2014;**44**(1):20 [Internet]. Available from: <http://www.ncbi.nlm.nih.gov/pubmed/24616830> [Accessed: 18 May 2017]
- [54] Rotundo R, Bassarelli T, Pace E, Iachetti G, Mervelt J, Pini Prato G. Orthodontic treatment of periodontal defects. Part II: A systematic review on human and animal studies. *Progress in Orthodontics*. 2011;**12**(1):45-52 [Internet]. Available from: <http://linkinghub.elsevier.com/retrieve/pii/S1723778511000137> [Accessed: 19 March 2017]
- [55] Mayer T, Basdra EK. A combined surgical and orthodontic treatment of Class III furcations. Report of a case. *Journal of Clinical Periodontology*. 1997;**24**(4):233-236 [Internet]. Available from: <http://www.ncbi.nlm.nih.gov/pubmed/9144045> [Accessed: 18 May 2017]
- [56] Re S, Cardaropoli D, Abundo R, Corrente G. Reduction of gingival recession following orthodontic intrusion in periodontally compromised patients. *Orthodontics & Craniofacial Research*. 2004;**7**(1):35-39 [Internet]. Available from: <http://www.ncbi.nlm.nih.gov/pubmed/14989753> [Accessed: 18 May 2017]
- [57] Martegani P, Silvestri M, Mascarello F, Scipioni T, Ghezzi C, Rota C, et al. Morphometric study of the interproximal unit in the Esthetic Region to correlate anatomic variables affecting the aspect of soft tissue embrasure space. *Journal of Periodontology*. 2007;**78**(12):2260-2265 [Internet]. Available from: <http://www.ncbi.nlm.nih.gov/pubmed/18052697> [Accessed: 18 May 2017]
- [58] Kurth JR, Kokich VG. Open gingival embrasures after orthodontic treatment in adults: Prevalence and etiology. *American Journal of Orthodontics and Dentofacial Orthopedics*. 2001;**120**(2):116-123 [Internet]. Available from: <http://www.ncbi.nlm.nih.gov/pubmed/11500652> [Accessed: 18 May 2017]
- [59] Reitan K. Principles of retention and avoidance of posttreatment relapse. *American Journal of Orthodontics*. 1969;**55**(6):776-790 [Internet]. Available from: <http://www.ncbi.nlm.nih.gov/pubmed/4890739> [Accessed: 19 May 2017]

- [60] Manni A, Pasini M, Mazzotta L, Mutinelli S, Nuzzo C, Grassi FR, et al. Comparison between an Acrylic Splint Herbst and an Acrylic Splint Miniscrew-Herbst for Mandibular Incisors Proclination Control. *International Journal of Dentistry*. 2014;**2014**:1-7 [Internet]. Available from: <http://www.ncbi.nlm.nih.gov/pubmed/24963293> [Accessed: 20 May 2017]
- [61] Will LA. Stability and retention. *Frontiers of Oral Biology* [Internet]. 2016:56-63. Available from: <http://www.ncbi.nlm.nih.gov/pubmed/26599118> [Accessed: 19 May 2017]
- [62] Al-Moghrabi D, Pandis N, Fleming PS. The effects of fixed and removable orthodontic retainers: a systematic review. *Progress in Orthodontics*. 2016;**17**(1):24 [Internet]. Available from: <http://www.ncbi.nlm.nih.gov/pubmed/27459974> [Accessed: 19 May 2017]
- [63] Bourzgui F, Aghoutan H, Diouny S. Craniomandibular disorders and mandibular reference position in orthodontic treatment. *International Journal of Dentistry*. 2013;**2013**:1-6 [Internet]. Available from: <http://www.ncbi.nlm.nih.gov/pubmed/24101929> [Accessed: 19 May 2017]