

# We are IntechOpen, the world's leading publisher of Open Access books Built by scientists, for scientists

6,900

Open access books available

185,000

International authors and editors

200M

Downloads

Our authors are among the

154

Countries delivered to

TOP 1%

most cited scientists

12.2%

Contributors from top 500 universities



WEB OF SCIENCE™

Selection of our books indexed in the Book Citation Index  
in Web of Science™ Core Collection (BKCI)

Interested in publishing with us?  
Contact [book.department@intechopen.com](mailto:book.department@intechopen.com)

Numbers displayed above are based on latest data collected.  
For more information visit [www.intechopen.com](http://www.intechopen.com)



---

# Omental Flap in Breast Reconstruction

---

Ashraf Khater, Adel Fathi and Hosam Ghazy

Additional information is available at the end of the chapter

<http://dx.doi.org/10.5772/intechopen.70115>

---

## Abstract

**Objectives:** The use of omental flap for breast reconstruction was reported by the Romanian surgeon Kiricuta in 1963, since that time some surgeons tried to use the omentum either pedicled or free for breast reconstruction. It can be used after partial or total mastectomy.

**Aims:** The aim of this chapter is to address indications, limitations, contraindications, and technique of omental flap for breast reconstruction.

**Technique:** This flap could be retrieved by either a small midline laparotomy or preferably by laparoscopic harvesting. Details of retrieval, tips and tricks are highlighted in this chapter.

**Conclusions:** Omental flap is a strong working horse in breast reconstruction after partial or skin sparing mastectomy (SSM). It can be free or pedicled. It could be retrieved by minilaparotomy or preferably by laparoscopic harvesting omental flap (LHOF). It is a simple, safe, and reliable flap that mimics the natural contour of the breast. In about 30% with volume insufficiency it can be used with an implant as a cover with low complication rate and good esthetic outcome.

**Keywords:** breast, reconstruction, omental flap, mastectomy

---

## 1. Historical background

The omentum is not just an abdominal structure, it is an unique organ with a peculiar location, shape, attachments, supply, and function. The omentum has a mechanical function as a barrier or sealant. It has an immune function and an endocrinal function through secreting many cytokines, growth factors, and hormones [1, 2]. Surgeons aimed to use this organ in many reconstructive procedures. The first use of a pedicled omental flap was reported by Senn in

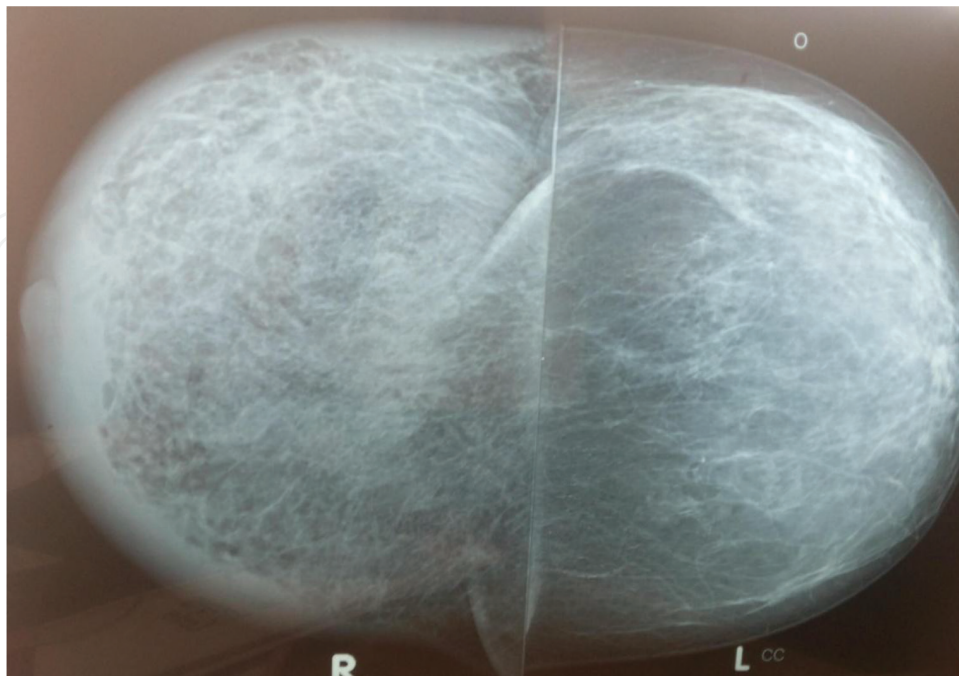
1888 when he used it for protection of intestinal anastomosis [3]. More recently, the omentum was revisited by Knazozovicky in 1929 when he used the pedicled omentum after arthroplasty [4]. Due to its immune function, it was used for coverage of deep sternal and infected wounds as well as to protect anastomoses [5, 6]. The Romanian surgeon, Kiricuta described the use of the pedicled omental flap for repair of vesicovaginal fistula and for breast reconstruction after mastectomy [7, 8]. He reported on 10 cases of breast reconstruction after subcutaneous mastectomy with 40% pure omental reconstruction without any need for implants. This opened the gate for use of pedicled omental flap in breast reconstruction. The main two problems with this flap were the unpredictable volume [9, 10] and the requirement of laparotomy for retrieval. The latter was associated with potential morbidity especially in regards to the occurrence of incisional hernia [11]. Some researchers tried to extract this flap through a minilaparotomy; yet incisional hernia still remained a complication [12]. For this reason Saltz described omental flap retrieval through a laparoscopic approach [13]. Later on, there was a shift toward the laparoscopic retrieval with great success. The largest series was reported by Hisamitsu Zaha who performed around 200 cases of laparoscopically harvested omental flap (LHOF) with minimal complications and satisfactory aesthetic results [14]. Subsequently, to avoid any traction over the pedicle with added length of the pedicle to the total flap volume, a trend emerged toward usage of free omental flaps extracted through a small abdominal incision to avoid any traction over the pedicle with added length of the pedicle to the total flap volume [15, 16]. The first free omental flap was performed in an emergent basis to cover a large defect in the scalp after avulsion [15]. After that, its indications were widened and it was applied to several locations [17]. In this work, we shall try to answer the following question: is there a role for omental flap in breast reconstruction in the era of oncoplastic surgery?

## 2. Advantages of the omental flap

We can list several advantages of the omental flap [11, 12, 18]:

1. Easy harvest which is not technically demanding, and that is characterized by a short learning curve.
2. Minimal donor site morbidity especially with the use of laparoscopic harvesting.
3. Minimal blood loss.
4. Can be retrieved simultaneously with mastectomy by two teams with neither need for extra time nor for changing patient's position for staged operations.
5. Fast recovery with early discharge especially with laparoscopic harvesting.
6. This flap is fatty in nature, so it mimics the normal breast and you can hardly differentiate in between even with the use of mammography (**Figure 1**).
7. Reliability of its axial blood supply with less common ischemic complications transverse rectus abdominis myocutaneous flap (TRAM) is a perforator flap with common ischemic complications and fat necrosis.

8. Great adaptability to any cavities.
9. Great malleability with ease in reshaping to mimic the breast mound.
10. It is a good reconstructive tool in obese women (its volume increases with weight gain) and can be retrieved with the laparoscope without major complications. On the other hand, obesity is a relative contraindication for TRAM flap and its ischemic complications increases in obese women.
11. Long pedicle which can be transferred easily to the mastectomy bed through an epigastric incision.
12. The flap is bipedicled and can be divided to work for both breasts simultaneously.
13. It has a characteristic absorptive power, so seroma is less evident and drain output is usually of lesser amount.
14. It is the only flap that shows a unique phenomenon of size gain, which is completed by the end of the sixth month. Other flaps (or lipofilling) usually undergo size decrease with progress of time due to either muscle atrophy or adipose tissue loss [19].
15. It has an immune function and good tissue adherence, so it can cover ischemic areas.
16. It is suitable for all ages, stages, body weights, and controllable comorbidities.
17. It has a very good tolerance for postoperative radiotherapy.
18. Surprisingly, if it is used as a cover for the silicone implants, capsular contracture, and rupture are rare [12].



**Figure 1.** Mammographic view of the right breast reconstructed with an omental flap.

### 3. Limitations

1. The main drawback of this flap is the unpredictable volume, however if volume is insufficient [9, 11], it can be used safely as a cover for an implant.
2. It is not suitable for cases in which the whole breast with its skin is removed.
3. It may be deficient in thin women (implant can be used as an adjunct).
4. It is considered an abdominal operation with all hazards of laparoscopic use as bleeding, visceral injuries, and complications of laparoscopy.
5. Presence of adhesions may be a limiting factor.
6. Presence of peritoneal metastases or omental deposits may preclude flap retrieval.

#### 3.1. Contraindications

1. The main contraindication is the presence of omental malignant nodules, omental cake, or malignant ascites [11].
2. If omentectomy was done for any reason.
3. Presence of marked abdominal adhesions that make retrieval difficult.
4. Contraindications of laparoscopy.

### 4. Anatomic considerations

The greater omentum is attached inferiorly to the transverse colon after making a loop over itself forming a four layer loop. Superiorly, it is attached to the greater curve of the stomach (**Figure 2**) [20–22].

It has the advantage of having a dual blood supply from both gastroepiploic arteries (right epiploic from gastroduodenal and left from the splenic). Both form anterior and posterior epiploic arcades (**Figure 3**) and gives rise to anterior, posterior, and accessory epiploic arteries.

The flap pedicle can be based on either the right or the left gastroepiploic arteries (commonly the right) after dividing the contralateral artery (**Figure 4**). However, if a free flap is used, both vascular pedicles can be anastomosed to the branches of the axillary artery through a microvascular anastomosis.

Moreover, the flap can be lengthened by dividing the anterior epiploic arteries keeping the anterior and posterior omental arcades (**Figure 5**).



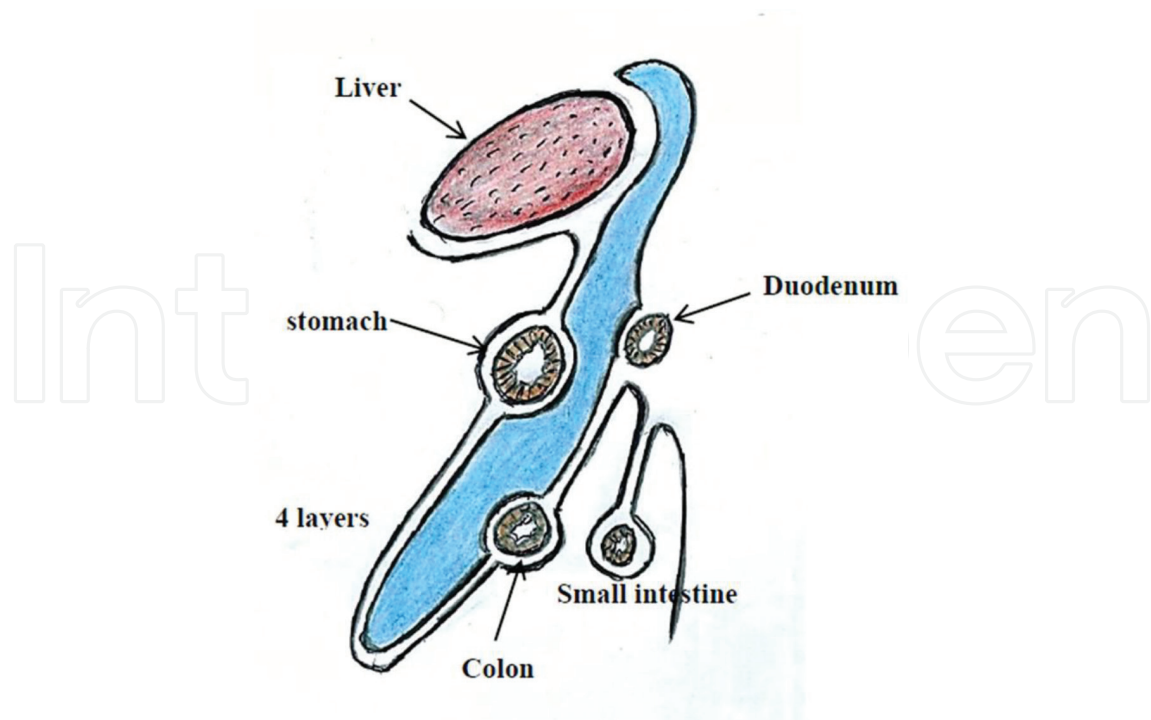


Figure 2. Layers and attachment of the greater omentum.

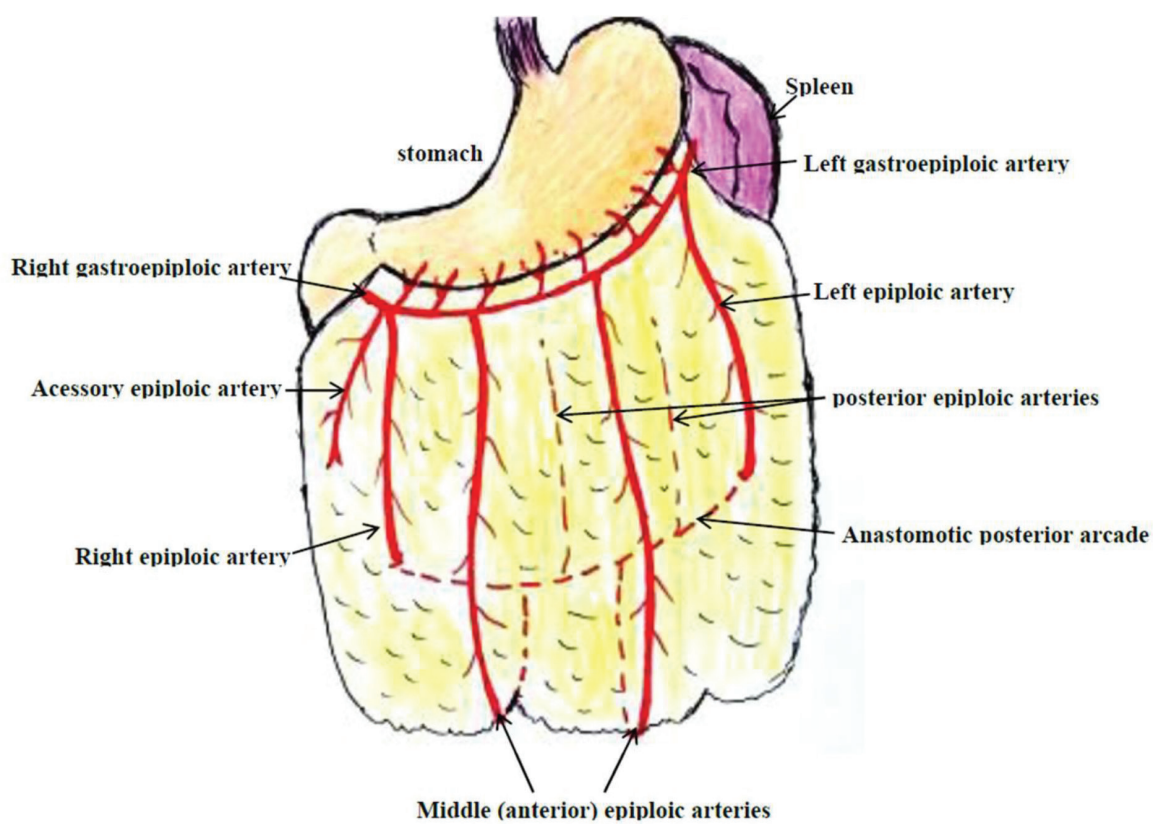
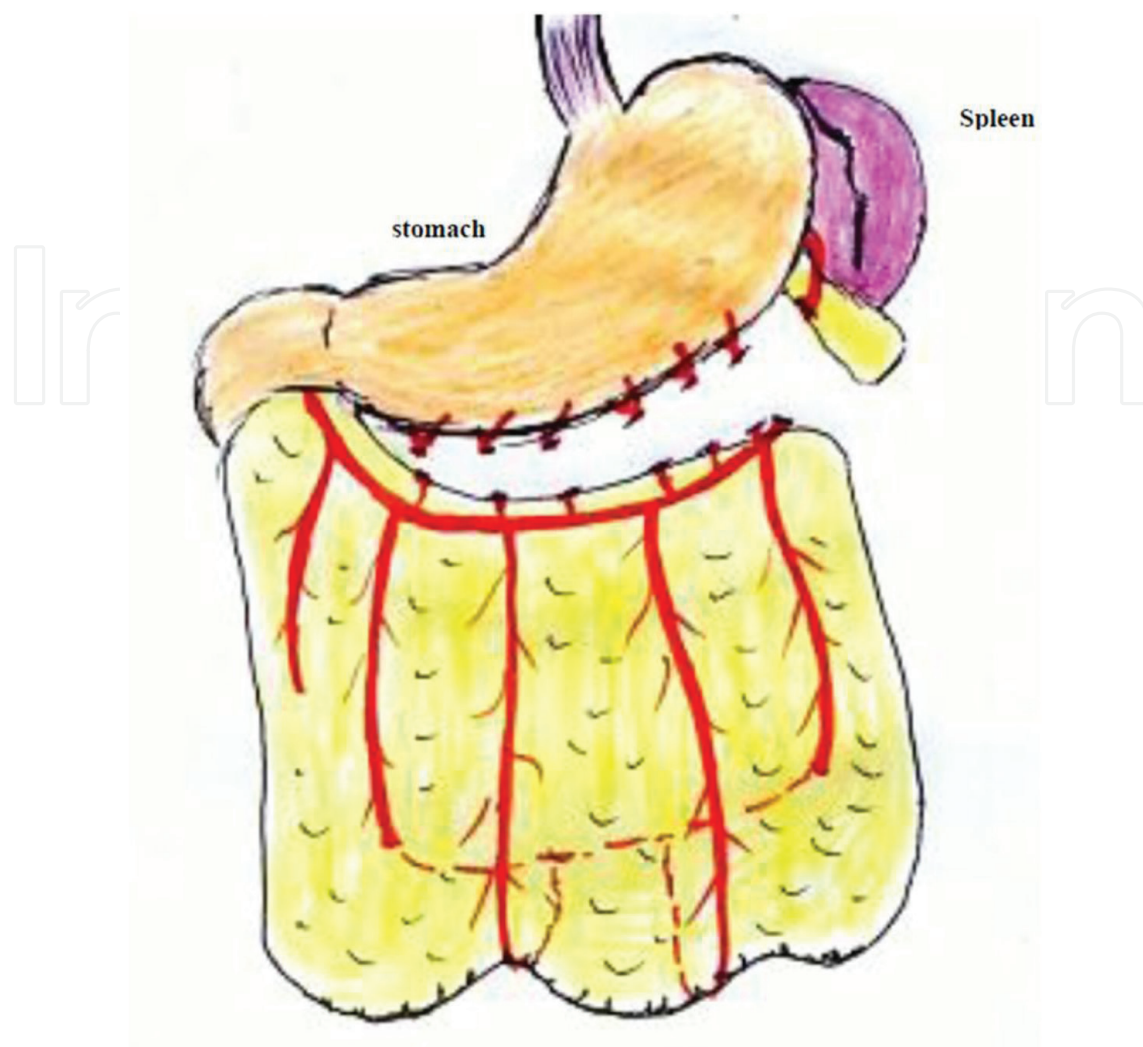
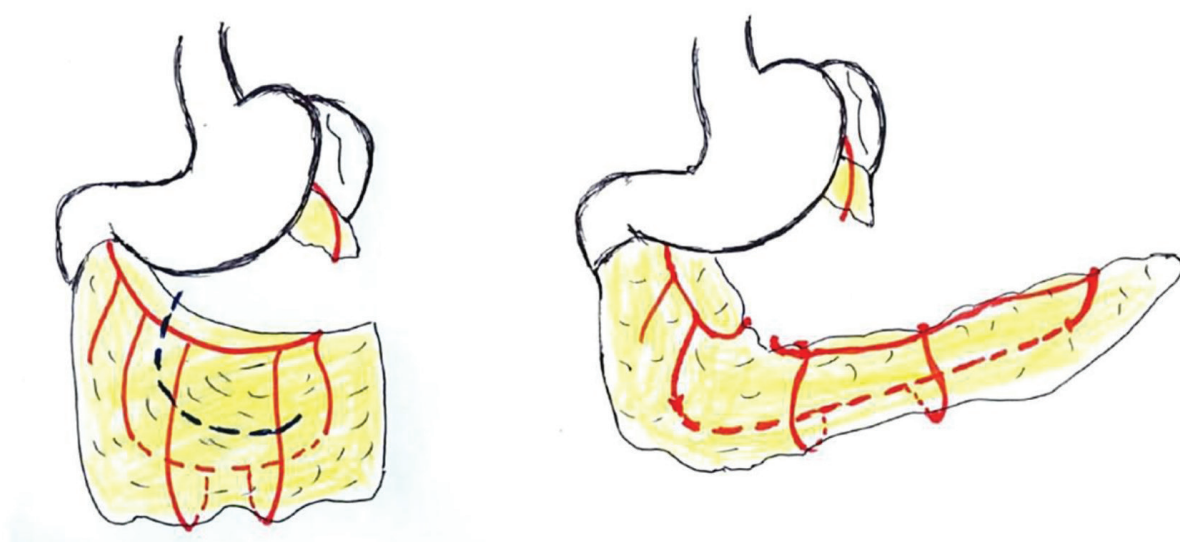


Figure 3. Arterial supply of the greater omentum.



**Figure 4.** Pedicled omental flap based on the right gastroepiploic artery.



**Figure 5.** Lengthened omental flap (dotted division line).

## 5. Technique

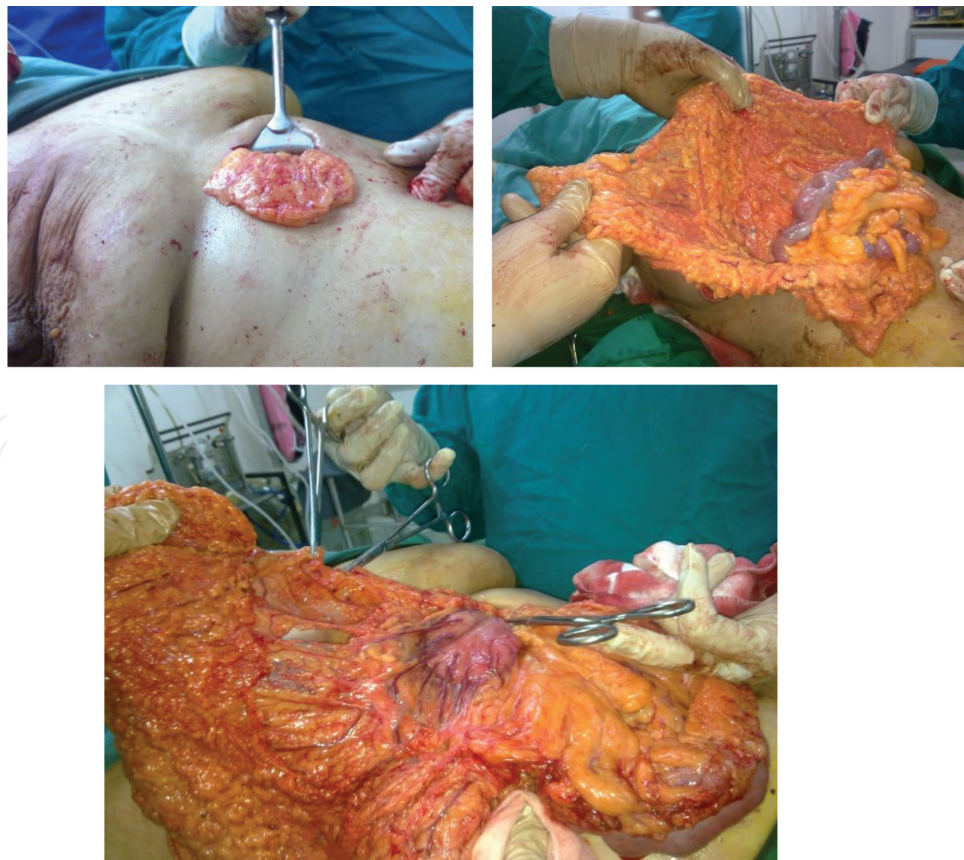The omentum may be retrieved through a small epigastric minilaparotomy (**Figure 6**) or through laparoscopy. Laparoscopic ports are usually infra-umbilical; a 12 mm port just below the umbilicus for the camera and two 5 mm lateral ports for handling and dissection. Optional one or two 5 mm ports may be used in the upper right or left hypochondrium for omental retraction if it has a large volume (**Figure 7**).

In laparoscopic harvest, it is preferable to start dissection with separation of the omentum from the colonic attachment to preserve the flap suspended from the greater curve (**Figure 8**).

Then working in a counterclockwise direction, dissection is extended toward the left gastropiploic artery which is sealed and divided either by harmonic scalpel or preferably by Ligasure as this device can control sizable vessels (**Figure 9**).

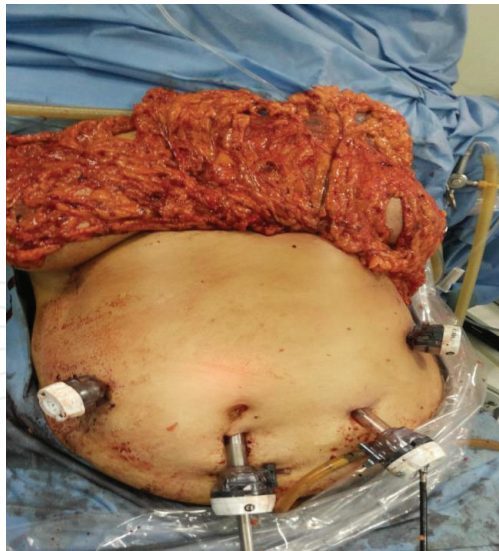Then, we start dividing the attachment to the greater curvature of the stomach up to the visualization of the right gastropiploic artery within a fold (**Figure 10**).

The last step is a creation of an epigastric incision through the lower mastectomy flap, then a 12 mm trocar is introduced to grasp the distal tip of the freed omentum which is widened to 2–3 fingers width to allow transmission of the flap to the mastectomy bed (**Figure 11**).

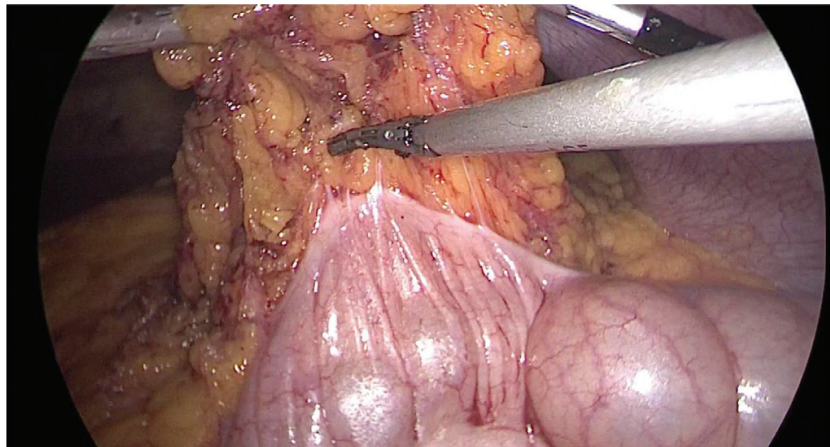


**Figure 6.** Omental flap retrieved through a small epigastric minilaparotomy.

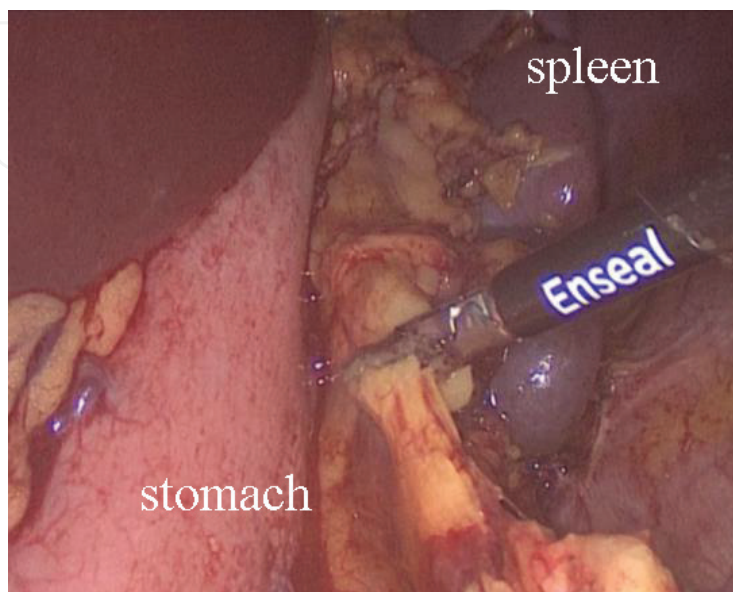




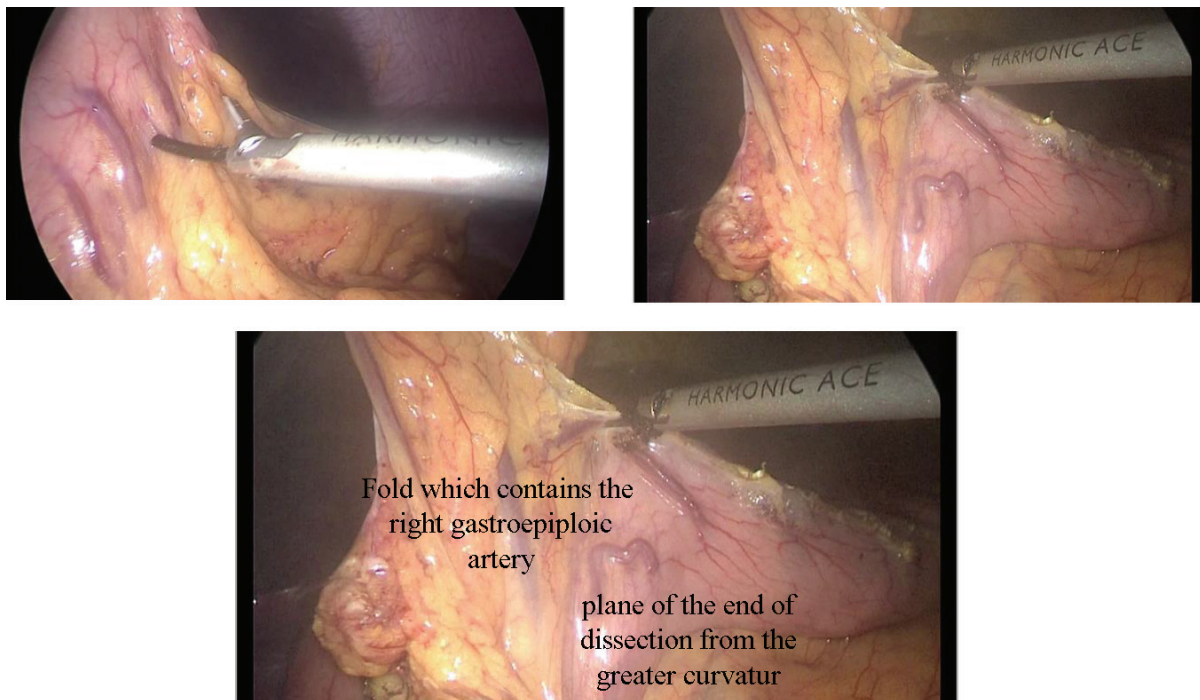
**Figure 7.** Laparoscopically retrieved omental flap with port sites demonstrated.



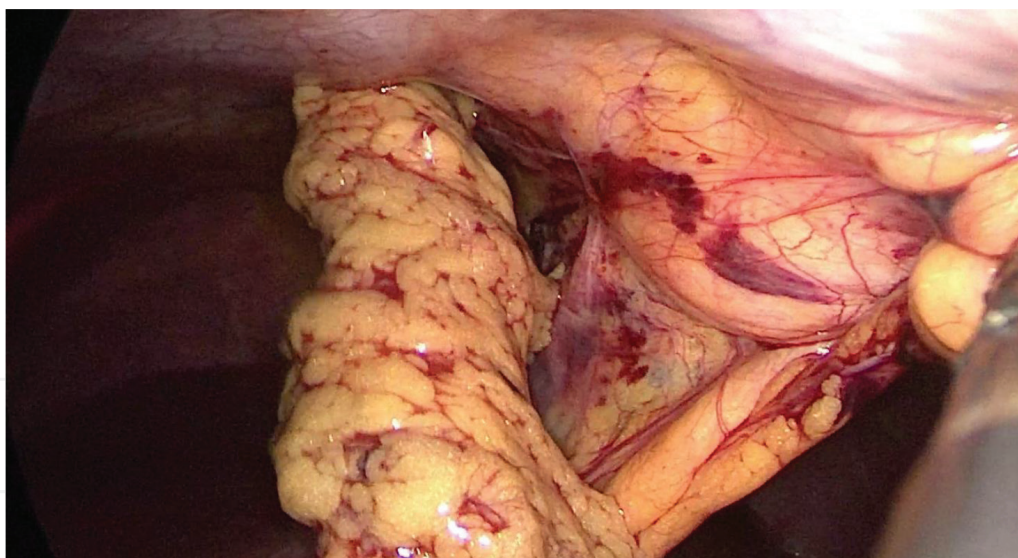
**Figure 8.** Separation of the greater omentum from the colonic attachment.



**Figure 9.** Division of the left gastroepiploic artery.



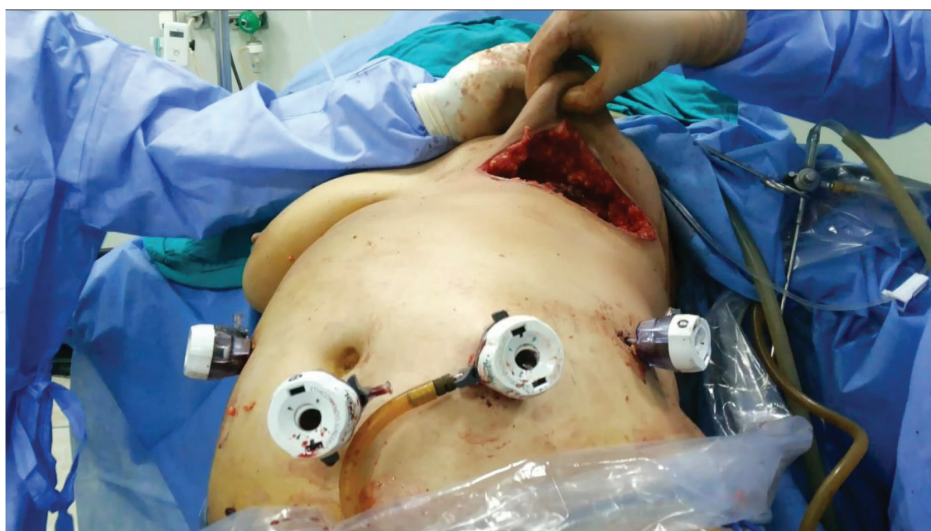**Figure 10.** Division of attachments to the greater curvature.



**Figure 11.** Grasping of the flap distal end to be transmitted into the mastectomy bed.

When the flap is transferred to the bed, it could be molded to fit to the breast envelope, then the flap should be fixed by few nonabsorbable sutures to the underlying muscles to avoid flap retraction into the abdomen. Care should be exercised to avoid injury of the vascular pedicle by these sutures. We prefer carrying mastectomy through a hidden inframammary incision close to the epigastrium. This allows delivery of the flap through the subcutaneous tunnel and enables us to obtain a very good cosmetic outcome “scarless procedure” (**Figure 12**). The problem with this incision is the relative higher ischemic complications, these can be avoided



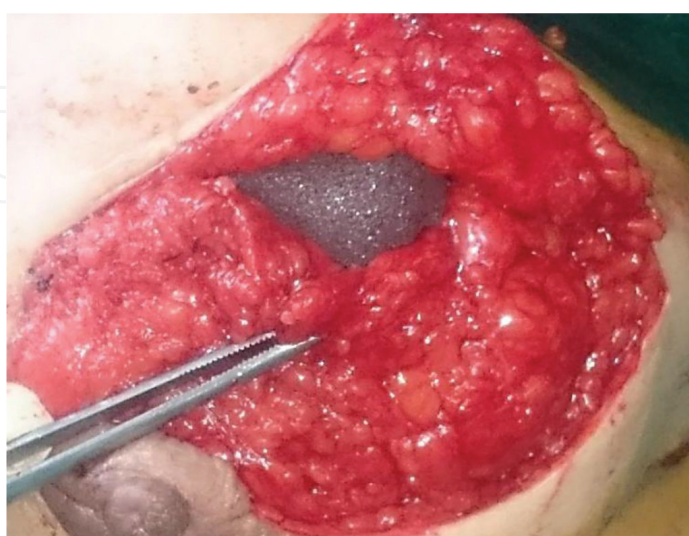

**Figure 12.** Inframammary incision to make a scarless procedure and to ease flap retrieval through the epigastric incision.

by testing its vascularity by either simple pricking, peripheral cutting or through dye techniques. However, any ischemia could be easily managed in the outpatient clinic with a very satisfactory cosmetic outcome.

## 6. Volume insufficiency

In the largest reported series by the Japanese surgeon Hisamitsu Zaha that included 200 cases, volume insufficiency was around 30%; in such case, a silicone implant could be used as an adjunct with a very good aesthetic outcome (**Figure 13**) [14].



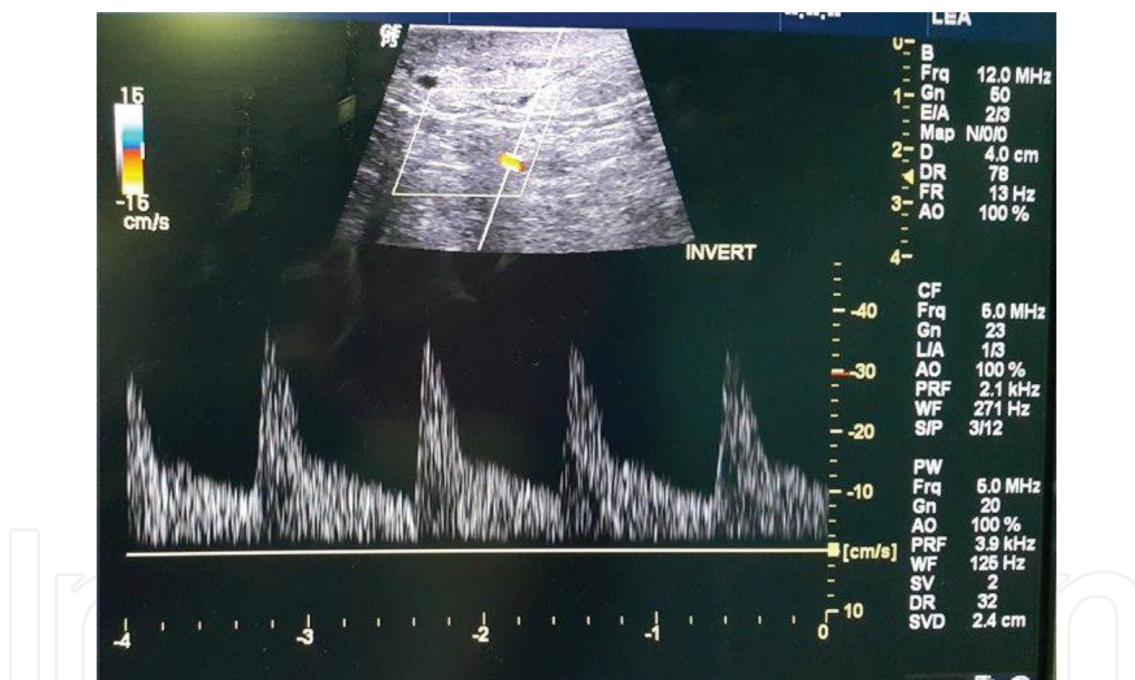
**Figure 13.** Silicone implant as an adjunct with omental flap.

## 7. Pedicled versus free flaps

A free omental flap is recommended if remote coverage is required such as scalp avulsion, however there are advantages for free omental flap transfer in breast reconstruction, such as making benefit of the length of pedicle when added to the flap [16], ridding the patient of epigastric discomfort or pain due to passage of the pedicle through the tunnel, and finally minimal incidence of epigastric hernia consequent upon avoidance of the epigastric wound. This is especially so, if the omental flap is retrieved through a small Pfannenstiel incision or even through an epigastric wound which is completely closed.

## 8. Evaluation of flap integrity

Some authors leave a small window for this purpose, however the best way is to perform an intraoperative Doppler study and postoperative Duplex assessment (**Figure 14**).

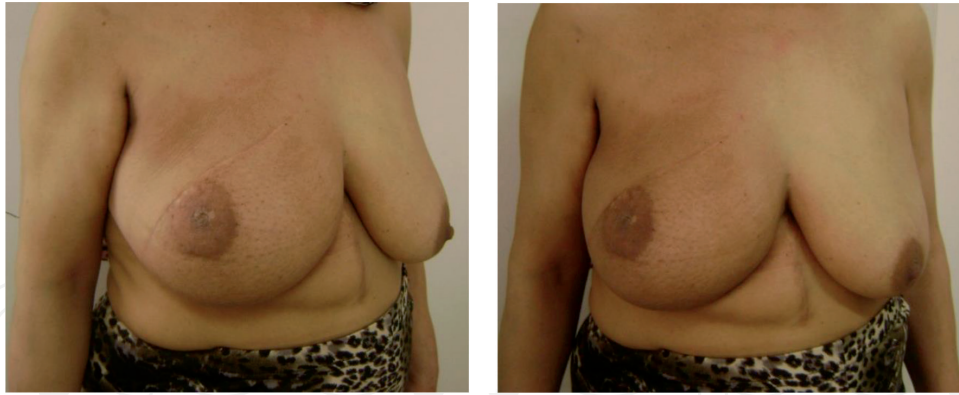


**Figure 14.** Duplex assessment showing an intact vascularity.

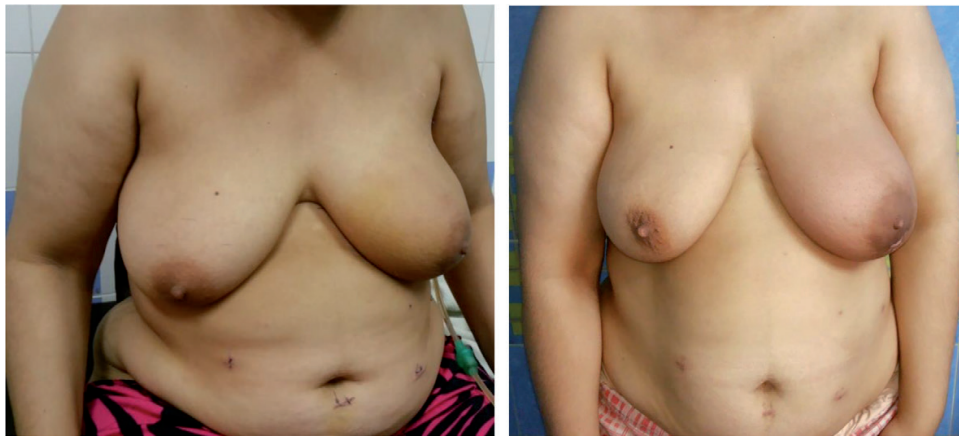## 9. The aesthetic outcome

As reported by many authors, more than 80% of patients express an excellent aesthetic outcome [14]. **Figures 15** and **16** show cases of skin sparing mastectomy (SSM) reconstructed with a pedicled omental flap. In **Figure 15**, retrieval was done through a minlaparotomy and in **Figure 16** it was through a laparoscopic harvesting (LHOF) with a nearly scarless procedure.





**Figure 15.** SSM which is reconstructed with pedicled omental flap through minilaparotomy.



**Figure 16.** SSM which is reconstructed with laparoscopically harvested omental flap (LHOF).

## 10. Complications

### 10.1. General

1. Those of laparoscopy, as complications of the access, visceral injury, gas embolism, etc.
2. Chest complications.
3. Deep venous thrombosis (DVT) and pulmonary embolism.

### 10.2. Specific

1. Flap loss which may be either total or partial (partial loss may be minor or major that mandates surgical resection).
2. Traumatic fat necrosis.

3. Local sepsis that may end up with necrotizing fasciitis especially in poorly controlled diabetics; this may be another cause of flap loss.
4. Hemorrhage, either in the mastectomy bed or intra-abdominal after flap retrieval. The most common abdominal sources are, the sealed left gastroepiploic vessels, short gastric vessels, or sealed vessels along the greater curve.
5. Epigastric discomfort or hernia due to passage of the pedicle through the epigastric tunnel.
6. Port site hernia after laparoscopic retrieval.
7. Seroma which is less common than with mastectomy alone due to the absorptive power of this flap.

## 11. Place of the omental flap in the era of oncoplastic surgery

This flap is ideal to solve the problem of volume replacement of medial quadrant volume replacement in cases of partial mastectomy for tumors in the medial quadrant. Moreover, it is a very good choice for total breast reconstruction after skin sparing mastectomy (SSM) especially in women with body mass index above the age of 30 years. This is particularly so, even if the volume is not adequate, because in such case it can be used to cover a silicone implant to avoid the capsular contracture and implant rupture.

## 12. Conclusion

Omental flap is a strong working horse in breast reconstruction after partial or skin sparing mastectomy. It can be free or pedicled. It could be retrieved by a minilaparotomy or preferably by laparoscopic harvesting (LHOF). It is a simple, safe, and reliable flap that mimics the natural contour of the breast. In about 30% of cases with volume insufficiency, it can be used with an implant as a cover with low complication rate and good aesthetic outcome.

## Author details

Ashraf Khater<sup>1\*</sup>, Adel Fathi<sup>1</sup> and Hosam Ghazy<sup>2</sup>

\*Address all correspondence to: [dr.ashrafkhater@yahoo.com](mailto:dr.ashrafkhater@yahoo.com)

1 Department of Surgical Oncology, Faculty of Medicine, Mansoura Oncology Center (OCMU), Mansoura University, Egypt

2 General Surgery Department, Mansoura University Hospital, Mansoura University, Egypt

## References

- [1] Smitka K, Marešová D. Adipose tissue as an endocrine organ: An update on pro-inflammatory and anti-inflammatory microenvironment. *Prague Medical Report*. 2015;**116**(2):87-111
- [2] Fonseca-Alaniz MH, Takada J, Alonso-Vale MI, Lima FB. The adipose tissue as a regulatory center of the metabolism. *Arquivos Brasileiros de Endocrinologia & Metabologia*. 2006;**50**:216-229
- [3] Senn N. An experimental contribution to intestinal surgery, with special reference to the treatment of intestinal obstruction (concluded). *Annals of Surgery*. 1888;**7**:421-430
- [4] Lieberman-Meffert D, White H. *The Greater Omentum: Anatomy, Physiology, Pathology, Surgery, with a Historical Survey*. New York: Springer; 1983
- [5] Irons GB, Witzke DJ, Arnold PG, Wood MB. Use of the omental free flap for soft-tissue reconstruction. *Annals of Plastic Surgery*. 1983;**11**(6):501-507
- [6] Parissis H, Al-Alao B, Soo A, Orr D, Young V. Risk analysis and outcome of mediastinal wound and deep mediastinal wound infections with specific emphasis to omental transposition. *Journal of Cardiothoracic Surgery*. Sep 2011;**6**:111
- [7] Kiricuta I. The use of the great omentum in the surgery of breast cancer. *La Presse Médicale*. 1963;**5**:15-17
- [8] Kiricuta I, Goldstein AM. The repair of extensive vesicovaginal fistulas with pedicled omentum: A review of 27 cases. *The Journal of Urology*. 1972;**108**:724-727
- [9] Cothier-Savey I, Tamtawi B, Franck D, et al. Immediate breast reconstruction using laparoscopically harvested omental flap. *Plastic and Reconstructive Surgery*. 2001;**107**:1156-1163
- [10] Zaha H, Inamine S, Naito T, Nomura H. Laparoscopically harvested omental flap for immediate breast reconstruction. *The American Journal of Surgery*. Oct 2006;**192**(4):556-558
- [11] Zaha H, Inamine S. Laparoscopically harvested omental flap: Results for 96 patients. *Surgical Endoscopy*. 2010;**24**:103-107
- [12] Khater A. Erratum to: Evaluation of pedicled omental flap delivered through a minilaparotomy for immediate breast reconstruction in obese patients. *Aesthetic Plastic Surgery*. 2014;**38**:482
- [13] Saltz R, Stowers R, Smith M, Gadacz TR. Laparoscopically harvested omental free flap to cover a large soft tissue defect. *Annals of Surgery*. 1993;**217**(5):542-546; discussion 6-7
- [14] Zaha H, Abe N, Sagawa N, Unesoko M. Oncoplastic surgery with omental flap reconstruction: A study of 200 cases. *Breast Cancer Research and Treatment*. Jan 24, 2017;**162**(2):267-274. DOI: 10.1007/s10549-017-4124-9. [Epub ahead of print]

- [15] McLean DH, Buncke HJ. Autotransplant of omentum to a large scalp defect, with microsurgical revascularization. *Plastic and Reconstructive Surgery*. 1972;**49**(3):268-274
- [16] Gomez JA, Pascal SG, Michel S, Mitchel H, Richard L. Free omental flap for skin-sparing breast reconstruction harvested laparoscopically. *Plastic & Reconstructive Surgery*. 2002;**110**(2):545-551
- [17] Losken A, Carlson GW, Culbertson JH, Scott Hultman C, Kumar AV, Jones GE, Bostwick 3rd J, Jurkiewicz MJ. Omental free flap reconstruction in complex head and neck deformities. *Head & Neck*. Apr 2002;**24**(4):326-331
- [18] Costa SS, Blotta RM, Mariano MB, Meurer L, Edelweiss MIA. Laparoscopic treatment of Poland's syndrome using the omentum flap technique. *Clinics Sao Paulo*. 2010;**65**(4):401-406
- [19] Costa SS, Blotta RM, Meurer L, Edelweiss MIA. Adipocyte morphometric evaluation and angiogenesis in the omentum transposed to the breast: A preliminary study. *Clinics Sao Paulo*. Feb 2011;**66**(2):307-312
- [20] Skandalakis JE, Colborn GL, Weidman TA, Foster Jr RS, Kingsnorth AN, et al. *Surgical Anatomy: The Embryologic and Anatomic Basis of Modern Surgery*. Chapter 10. Peritoneum, Omenta, and Internal Hernias. Athens, Greece: Paschalidis Medical Publications; 2004
- [21] Nakao K, Miyata M, Ito T, et al. Omental transposition and skin graft in patients for advanced or recurrent breast cancer. *The Japanese Journal of Surgery*. 1986;**16**:112
- [22] Samson R, Pasternak BM. Current status of surgery of the omentum. *Surgery, Gynecology & Obstetrics*. 1979;**149**:437



