

We are IntechOpen, the world's leading publisher of Open Access books Built by scientists, for scientists

6,900

Open access books available

186,000

International authors and editors

200M

Downloads

Our authors are among the

154

Countries delivered to

TOP 1%

most cited scientists

12.2%

Contributors from top 500 universities



WEB OF SCIENCE™

Selection of our books indexed in the Book Citation Index
in Web of Science™ Core Collection (BKCI)

Interested in publishing with us?
Contact book.department@intechopen.com

Numbers displayed above are based on latest data collected.
For more information visit www.intechopen.com



Patient Optimization is the Key in Surgical Repair of Ruptured Umbilical Hernia in Cirrhotic Patients and Tense Ascitis

Ashraf E. Abbas, Amro ElHadidi,
Tamer Fakhry AbdElaziz and
Mahmoud Awad Ibrahim

Additional information is available at the end of the chapter

<http://dx.doi.org/10.5772/intechopen.69446>

Abstract

Background: Ulceration, leakage, and rupture are considered as the most common complications of umbilical hernias in patients with refractory ascites due to advanced cirrhosis. We aim to determine optimal management and outcome after umbilical herniorrhaphy or hernioplasty in those patients.

Methods: A retrospective chart review was performed on 37 patients with advanced cirrhosis who underwent umbilical herniorrhaphy or hernioplasty at our hospital.

Results: A total of 37 patients (12 female, 32.4%) had refractory ascites, with mean age of 52.2 ± 7.7 years (ranging from 37 to 70 years), 30 presented with leaking fluid, 5 with ulceration, and only 2 with spontaneous umbilical rupture. A total of 33 (89.2%) required perioperative human albumin transfusion, and only 7 (18.9%) required perioperative paracentesis. Only five patients (13.5%) required preoperative platelets transfusion. Propylene mesh was used in seven (18.9%) cases. Eleven patients (29.7%) developed ascites-related wound complications. Leaking ascites was recorded in three cases (8.1%) and only one case (2.7%) developed wound dehiscence and required reoperation. Hematemesis and melena were recorded in three (8.1%) early post operative without renal deterioration or encephalopathy. No early postoperative mortality.

Conclusion: With meticulous preoperative patient optimization, management of ruptured umbilical hernias in patients with advanced hepatic cirrhosis and refractory ascites is feasible.

Keywords: ascites, hernia, leaking umbilical hernia, cirrhosis, ruptured hernia

1. Introduction

About 14% of all Egyptian population were tested positive for antibodies against hepatitis C virus (HCV), indicating that these individuals have been infected with the RNA hepatitis C virus at some point [1]. However, only 10% of the population is considered as carriers for the viral RNA and is chronically infected. It was estimated that about half a million people are newly infected every year [2]. Ascites is a common complication of cirrhosis [3]. Cirrhosis is common with alcohol abuse and hepatitis virus infection [4]. Raised intraabdominal pressure leads to umbilical hernia in 20% of those patients [5]. Surgery for patient with liver cirrhosis is considered a “difficult field” because of many factors, such as deficiency in protein synthesis and coagulation disorders, in addition to respiratory and lung disease or cardiac dysfunction associated with late stages [6]. Complications of umbilical hernias in those patients with cirrhosis and tense refractory ascites include ulceration, leakage, incarceration, and rupture [7].

Flood syndrome, or spontaneous umbilical hernia rupture, is an important complication of longstanding tense ascites and end-stage liver disease [8]. Rupture may follow a sudden increase in intraabdominal pressure such as vomiting, coughing, and straining of stool [9]. The spontaneous rupture and evisceration is usually preceded by other factors such as inflammation that weaken the hernia covering [10, 11].

Other factors which can contribute to the rupture of a hernia are friction by the patient's external corset or abdominal support, and lack of adhesions between the bowel and the hernial sac allowing the bowel to act as a hammerhead upon the skin [12]. Irrespective of the pathogenesis of the ventral hernia, a factor that increases the risk of rupture is delayed repair of the defect [10, 11]. Unfortunately, many surgeons are reluctant to perform elective repairs because of the risk of increasing operative mortality [10]. However, this attitude exposes those patients to more risk of rupture or impending rupture announced by skin ulceration or a sudden increase in the size of the hernia [13].

Because nonsurgical management of a ruptured umbilical hernia has a mortality rate of 60–80% after supportive care [14], operative management either by local tissue repair or mesh repair is recommended [9]. Hemodynamic instability and even death may be precipitated by the loss of a massive quantity of ascites [15]. To assume portal decompression, transjugular intrahepatic portosystemic shunt (TIPS) can be used for a better control of the ascites that may allow these patients to undergo surgery [7]. The management of these patients requires a multidisciplinary approach, and a delay leads to higher recurrence, morbidity, and mortality [5].

The aim of our study is to evaluate the outcome of these patients during emergency situation to determine the optimal management after umbilical herniorrhaphy or hernioplasty in patients with advanced cirrhosis and refractory ascites to minimize the morbidity and mortality in such cases.

2. Patient and method

Thirty-seven consecutive cases of patients with liver cirrhosis and tense ascites treated in the surgery department of Mansoura University Emergency Hospital with ruptured or impending

rupture of ventral hernia were reviewed. Exclusion criteria including complicated cases with strangulated bowel, and those operated electively with normal skin covering.

The average age of the study group was 52.28 years, with a male:female ratio of 2.08:1, 25 men and 12 women. Presentation of hernia that required surgery was: 30 presented with leaking fluid, 5 with ulceration, and only 2 with spontaneous umbilical rupture. Thirty-three (89.2%) patients required perioperative human albumin transfusion, and only seven (18.9%) required perioperative paracentesis. Only five patients (13.5%) required preoperative platelets transfusion.

Surgical procedures were practiced under local anesthesia (32 cases), or spinal anesthesia (5 cases). A total of thirty cases were managed by using a two-layer repair technique and 7 cases of interrupted sutures using polypropylene and additional layer of polypropylene mesh. Intraabdominal closed drain and another subcutaneous suction drain were applied routinely. Patients were followed for 30 days postoperatively in outpatient clinic and after that either in the outpatient or using phone calls and complications were recorded in these patients, see **Table 1**.

	Number	Percentage
<i>Sex</i>		
Male	25	67.6
Female	12	32.4
<i>Presentation</i>		
Ulceration	5	13.5
Leaking fluid	30	81.1
Complete rupture	2	5.4
<i>Preoperative preparation</i>		
Albumin infusion	33	89.2
Paracentesis	7	18.9
Platelets infusion	5	13.5
<i>Surgical technique</i>		
Herniorrhaphy	32	86.5
Hernioplasty	5	13.5

Table 1. Demographic data, presentation, and preoperative preparation of the examined group.

3. Results

All the patients of the study group were followed and quantified for early and late postoperative complications. There were no death in the early first 30 days postoperatively, see **Table 2**.

	Number	Percentage
<i>Local wound problem</i>	11	29.7
- Seroma	4	10.8
- Hematoma	4	10.8
- Wound infection	3	8.1
<i>Ascites fluid leakage</i>	3	8.1
<i>Complete dehiscence</i>	1	2.7

Table 2. Local wound complications in the examined group.

A seroma, hematoma, or wound infection have been noted in 11 (29.7%) cases, and required only a local treatment. Ascites fluid leakage appeared in three cases (8.1%) and was treated by diuretics, albumin transfusion, and ascites drainage. It did not need any surgical intervention. However, complete dehiscence and rupture of the repair occurred only in one case (2.7%) and required reoperation in the 10th postoperative day, see **Table 2**.

On contrary to our expectation, systemic complication in the form of hepatorenal failure or death did not occur in any case. However, three cases of postoperative hematemesis and melena were recorded. Only one patient needed endoscopic ligation of active variceal bleeding beside antisecretory and hemostatic treatment and blood transfusion; other two cases were diagnosed as mild erosive gastritis and responded well to antisecretory and hemostatic treatment and blood transfusion. One patient presented a dynamic ileus, treated by a nasogastric tube and correcting electrolyte imbalance. ICU admission for the treatment of electrolyte imbalance, early signs of encephalopathy, or bleeding varices was needed in six cases (16.2%) but without any mortality. Late complications as hernia recurrence was recorded in only one case (2.7%) after 8 months of surgery, see **Table 3**.

	Number	Percentage
<i>Systemic complications</i>	11	29.7
- Hematemesis	3	8.1
- Melena	3	8.1
- Renal failure	0	0
- Ileus	1	2.7
- ICU admission	6	16.2
- Death	0	0
<i>Recurrence</i>	1	2.7

Table 3. Systemic complications and recurrence in the examined group.

4. Discussion

Incidence of hernia in cirrhotics with ascites is 20% [5, 16]. Literature is scarce about spontaneous rupture of hernia [10]. Delay in seeking treatment or neglect for early operative intervention increases the risk of rupture [17]. Unfortunately, many surgeons are reluctant to perform elective repairs because of the risk of increasing operative mortality [10] (see **Figure 1**). The delay in repair carries the risk of more protrusion and attenuation of the covering by ischemia from pressure and stretching [10], resulting in erosion, ulceration, and rupture. Delayed surgical management of cirrhotic patients with umbilical hernia and ascites is associated with elevated rate of grave complications, and carries the risks of more mortality and morbidities as incarceration, evisceration, ascites drainage, and peritonitis [18] (see **Figure 2**). Other reports found increase in mortality with complicated hernias [11, 18]. However, elective umbilical herniorrhaphy is safe and effective in most cirrhotic patients in which ascites is adequately controlled [19] (see **Figures 1 and 2**).

Other studies have also suggested elective umbilical herniorrhaphy in cirrhotic patients and described superior results over conservative management to avoid complications associated with this kind of management [20, 21].

The treatment of cirrhotic patients with umbilical hernia is still controversial [22]. Indication, timing, and technical aspects of herniorrhaphy in these patients also remain controversial [20].

Hernia repair in these patients remains a procedure with a high morbidity and mortality rate if it is performed in emergency conditions due to the occurrence of complications [23].

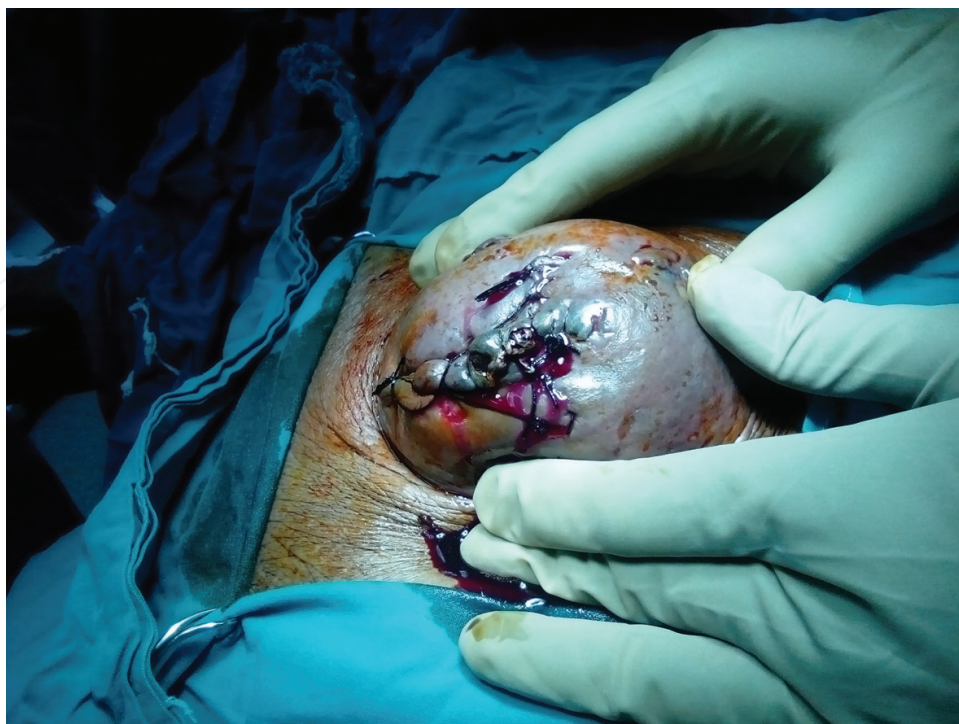

Figure 1. A badly skin stitched leaked hernia reflect the unaccepted surgeon attitude against those cases.

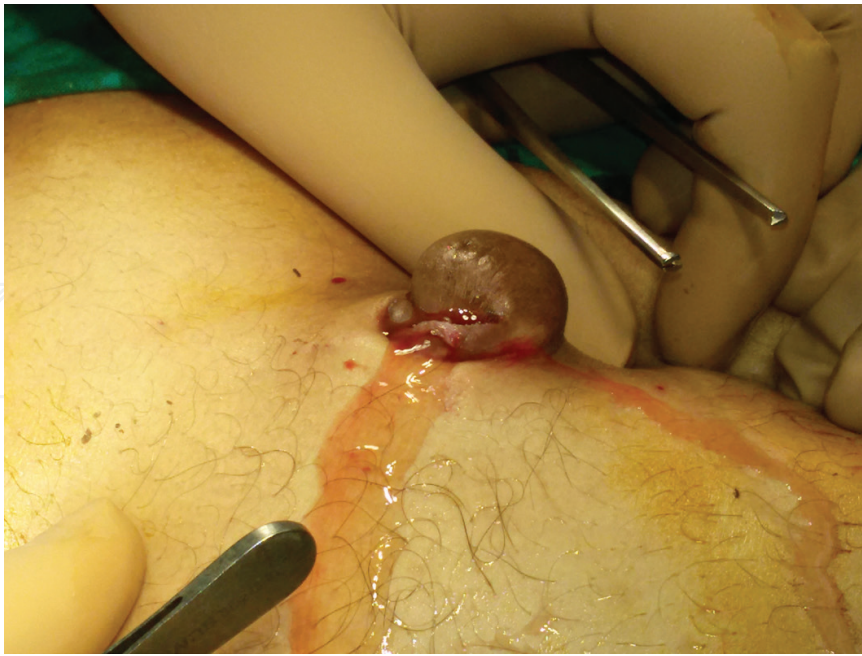


Figure 2. Leaking or ruptured umbilical hernia.

Medical treatment of ascites with diuretics, sodium restriction, and paracentesis should be the first step in the management. Effective ascites control reduces complications, such as wound infection, evisceration, ascites drainage from the wound, and peritonitis [24].

In our study group after exclusion of complicated cases with strangulation and bowel resection, it was noted that local wound problem persisted in 29.7%, and systemic problem in the form of attack of hematemesis and melena in three cases only (8.1%), with no cases of hepatorenal and no mortality. ICU admission for six patients (16.2%) is not a complication and helps our team for better ascites control and to avoid development of encephalopathy. These facts denote that hernia repair procedure alone is not a risky procedure even during emergency situation. Urgent aggressive control of ascites and herniorrhaphy or hernioplasty has near or the same results of elective repair in these patients.

5. Conclusion

With meticulous preoperative patient optimization and good ascites control, the management of ruptured umbilical hernias in patients with advanced hepatic cirrhosis and refractory ascites is feasible, and safe procedure even during emergency situation, mortality reported by other authors belongs mainly to complications of the hernia especially strangulation, and to less extent evisceration. Finally all data enforce the opinion that encourage surgical repair of the hernia once diagnosed on elective base or even during emergency, and avoid waiting complications, especially strangulation, and subsequent possible bowel resection which carries the main cause for mortality in these patients. More study is needed to determine the risk factors and may be a new score to predict mortality in these patients.

Author details

Ashraf E. Abbas^{1*}, Amro ElHadidi¹, Tamer Fakhry AbdElaziz³ and Mahmoud Awad Ibrahim²

*Address all correspondence to: ashrafabbaas@hotmail.com

1 General Surgery Department, Mansoura University Hospital, Mansoura, Egypt

2 Internal Medicine Department, Gastroenterology Unit, Mansoura University Hospital, Mansoura, Egypt

3 General Surgery Department, Faculty of Medicine, Menoufia University, Al Minufya, Egypt

References

- [1] El-Zanaty F, Way A. Egypt Demographic and Health Survey 2008. Egyptian Ministry of Health, El-Zanaty and Associates and Macro International; 2009 {United States Agency for International Development (USAID). Support for the survey was also provided by UNICEF}. <http://www.measuredhs.com>
- [2] Miller FD and Abu-Raddad LJ (2010) Evidence of Intense Ongoing Endemic Transmission of Hepatitis C Virus in Egypt. *Proceedings of the National Academy of Sciences of the United States of America*, 107, 14757-14762
- [3] Baron HC. Umbilical hernia secondary to cirrhosis of the liver—Complications of surgical correction. *The New England Journal of Medicine*. 1960;**263**:824-828
- [4] Schiff ER, Sorrell MF, Maddrey E. Schiff's Diseases of the Liver. 11th ed. Philadelphia: Lippincott, Williams & Wilkins; 2012. p. 367
- [5] Victor AJ and Ajitha MB: Umbilical hernia in ascites due to cirrhosis: A surgical challenge *International Journal of Biomedical and Advance Research*; 6(06): 457-461 (2015).
- [6] Bhangui P, Laurent A, Amathieu R, Azoulay D. Assessment of risk for nonhepatic surgery in cirrhotic patients. *Journal of Hepatology*. 2012;**57**:874-884
- [7] Triantos CK, Kehagias I, Nikolopoulou V, Burroughs AK. Surgical repair of umbilical hernias in cirrhosis with ascites. *The American Journal of the Medical Sciences*. 2011;**341**(3):222-226
- [8] Granese J, Valaulikar G, Khan M, Hardy 3rd H. Ruptured umbilical hernia in a case of alcoholic cirrhosis with massive ascites. *The American Surgeon*. 2002;**68**:733-734
- [9] Kirkpatrick S, Schubert T. Umbilical hernia rupture in cirrhotics with ascites. *Digestive Diseases and Sciences*. 1988;**33**:762-765
- [10] Gupta RK, Sah S, Agrawal SC. Spontaneous rupture of incisional hernia: A rare cause of a life-threatening complication. *BMJ Case Reports*. 2011;**3**:11

- [11] Good DW, Royds JE, Smith MJ, Neary PC, Eguare E. Umbilical hernia rupture with evisceration of omentum from massive ascites: A case report. *Journal of Medical Case Reports*. 2011;**5**:170
- [12] Hartley RC. Spontaneous rupture of incisional hernia. *British Journal of Surgery*. 1961;**49**:617-618
- [13] Lemmer JH, Strodel WE, Knol JA, Eckhauser FE. Management of spontaneous umbilical hernia disruption in the cirrhotic patient. *Annals of Surgery*. 1983;**198**:30-34
- [14] Chatzizacharias NA, Bradley JA, Harper S, Butler A, Jah A, Hugu E, Praseedom RK, Michael Allison M, Gibbs P. Successful surgical management of ruptured umbilical hernias in cirrhotic patients. *World Journal of Gastroenterology*. 2015;**21**(10):3109-3113
- [15] Long W and Hayden GE: Images in Emergency Medicine, A man rushing fluid from his Umblicus *Annals of Emergency Medicine*. 2013;**62**(4):439
- [16] Dokmak S, Aussilhou B, Belghiti J. Umbilical hernias and cirrhose. *Journal of Visceral Surgery*. 2012;**149**:e32-e39
- [17] Husain M, Mohsin M, Mir IS. Spontaneous rupture of incisional hernia: A case report. *International Journal of Surgery*. 2007;**11**:2
- [18] Coelho JC, Claus C, Campos AC, Costa MA, Blum C. Umbilical hernia in patients with liver cirrhosis: A surgical challenge. *World Journal of Gastrointestinal Surgery*. 2016;**8**(7):476-482
- [19] Eker HH, van Ramshorst GH, de Goede B, Tilanus HW, Metselaar HJ, de Man RA, Lange JF, Kazemier G. A prospective study on elective umbilical hernia repair in patients with liver cirrhosis and ascites. *Surgery*. 2011;**150**:542-546
- [20] Choi SB, Hong KD, Lee JS, Han HJ, Kim WB, Song TJ, Suh SO, Kim YC, Choi SY. Management of umbilical hernia complicated with liver cirrhosis: An advocate of early and elective herniorrhaphy. *Digestive and Liver Disease*. 2011;**43**:991-995
- [21] Carbonell AM, Wolfe LG, DeMaria EJ. Poor outcomes in cirrhosis-associated hernia repair: A nationwide cohort study of 32,033 patients. *Hernia*. 2005;**9**:353-357
- [22] Cho SW, Bhayani N, Newell P, Cassera MA, Hammill CW, Wolf RF, Hansen PD. Umbilical hernia repair in patients with signs of portal hypertension: Surgical outcome and predictors of mortality. *Archives of Surgery*. 2012;**147**:864-869
- [23] Banu P, Popa F, Constantin VD, Bălălaşu C, Nistor M. Prognosis elements in surgical treatment of complicated umbilical hernia in patients with liver cirrhosis. *Journal of Medicine and Life*. 2013;**6**(3):278-282
- [24] Belghiti J, Durand F. Abdominal wall hernias in the setting of cirrhosis. *Seminars in Liver Disease*. 1997;**17**:219-226