

We are IntechOpen, the world's leading publisher of Open Access books Built by scientists, for scientists

6,900

Open access books available

185,000

International authors and editors

200M

Downloads

Our authors are among the

154

Countries delivered to

TOP 1%

most cited scientists

12.2%

Contributors from top 500 universities



WEB OF SCIENCE™

Selection of our books indexed in the Book Citation Index
in Web of Science™ Core Collection (BKCI)

Interested in publishing with us?
Contact book.department@intechopen.com

Numbers displayed above are based on latest data collected.
For more information visit www.intechopen.com



Cone-Beam Computed Tomography for Oral and Maxillofacial Imaging

Ufuk Tatli and Burcu Evlice

Additional information is available at the end of the chapter

<http://dx.doi.org/10.5772/intechopen.69282>

Abstract

The invention of computed tomography (CT) technique revolutionized diagnostic imaging. Compared to conventional X-ray imaging procedures, CT involves higher radiation doses. Recently, cone-beam CT (CBCT) specifically designed for maxillofacial imaging was introduced. CBCT technique is based on a cone-shaped X-ray beam centered on a two-dimensional (2D) detector. The detector system performs one rotation around the patient, producing a series of 2D images which are then reconstructed in a 3D data set. The contemporary knowledge regarding CBCT and its proper application guides the practitioner for improvement in diagnostic purposes and treatment planning. The aim of this chapter is to focus on the details, advantages, drawbacks, and clinical applications of CBCT as a headmost CT imaging technique in the oral and maxillofacial (OMF) region. The main clinical applications of CBCT in the OMF region are dentistry including dentoalveolar and maxillofacial surgery, orthodontics, endodontics, and periodontics; and otolaryngology. The aforementioned clinical use of CBCT was described in detail with illustrated sample cases. In most of the cases in OMF region, CBCT takes the place of multi-slice CT. Thus, clinicians should know the clinical applications and capabilities of CBCT technique with its drawbacks.

Keywords: cone-beam computed tomography, dentistry, maxillofacial imaging, maxillofacial surgery, otolaryngology

1. Introduction

Accurate diagnostic imaging is a key factor for diagnosis and treatment planning. The invention of computed tomography (CT) technique revolutionized diagnostic imaging. Since the inception of CT in the 1970s, it has become one of the commonly used imaging methods [1]. Three-dimensional (3D) imaging provided by CT technology gives the opportunity to the clinician to examine the oral and maxillofacial (OMF) region without superimposition and distortion of the

image. Compared to conventional 2D imaging procedures, CT involves higher radiation doses. Recently, cone-beam computed tomography (CBCT) specifically designed for maxillofacial imaging was introduced to offset some of the limitations of conventional CT scanning devices [2].

The contemporary knowledge regarding CBCT and its proper application guides the practitioner for improvement in diagnostic purposes and treatment planning. The aim of this chapter is to focus on the technical features, advantages, drawbacks, limits, and clinical applications of CBCT as a headmost CT imaging technique in the OMF region.

2. Cone-beam technique

The CBCT scanners for maxillofacial region were introduced in the 1990s independently in Japan [3] and in Italy [4]. Although it has been given several names including dental volumetric tomography (DVT), cone-beam volumetric tomography (CBVT), dental computed tomography (DCT), and cone-beam imaging (CBI), the most preferred name is cone-beam computed tomography (CBCT) [5].

CBCT imaging is performed by using a rotating gantry to which an X-ray source and detector are fixed. Cone-beam machines radiate an X-ray beam shaped like a cone or pyramid, rather than a fan, as in conventional CT machines. The X-ray source and detector rotate around a rotation abutment fixed within the center of the region of interest. The beam exiting the patient is captured on a 2D planar detector, usually an amorphous silicon flat panel or sometimes an image intensifier/charge coupled device (CCD) detector. During the rotation, multiple consecutive planar projection images of the field of view (FOV) are acquired in a complete, or sometimes partial, arc. This procedure varies from a traditional medical CT, which uses a fan-shaped X-ray beam in a helical progression to obtain individual image slices of the FOV and then heaps the slices to get a 3D representation. Each slice requires a separate scan and separate 2D reconstruction. Because CBCT exposure combines the whole FOV, only one rotational turn of the gantry is necessary to acquire enough data for image reconstruction [6, 7]. A cone-beam reconstruction process creates a 3D matrix that can be viewed as a series of 2D cross-sectional images—axial, sagittal, and coronal views. From this data set, the operator can also extract thick or thin, planar or curved reconstructions in any orientation. Axial planes are a series of slices from top to bottom in the volume. Sagittal planes are a series of 2D slices from left to right, and coronal planes are a series of 2D slices from anterior to posterior. In a multi-planar reformation (MPR) window, these three orthogonal planar views are related through intersection lines or crosshairs, allowing for straightforward orientation and navigation (**Figure 1**).

The dose associated with each scan is affected by a number of scan parameters selected by the practitioner, either manually or through preset exposure protocols. For most CBCT systems, the kVp is fixed, and the tube current (mA) and exposure time (s) can be varied depending on the desired image quality and patient size. After reconstruction, CBCT images can be manipulated in different ways to optimize the visualization of anatomical structures and lesions and to isolate certain parts of the image. Basic filtering can also be applied, both during and after reconstruction, in order to smooth or sharpen the image [8]. CBCT has some advantages and disadvantages over conventional CT. These items are summarized below [9–14].

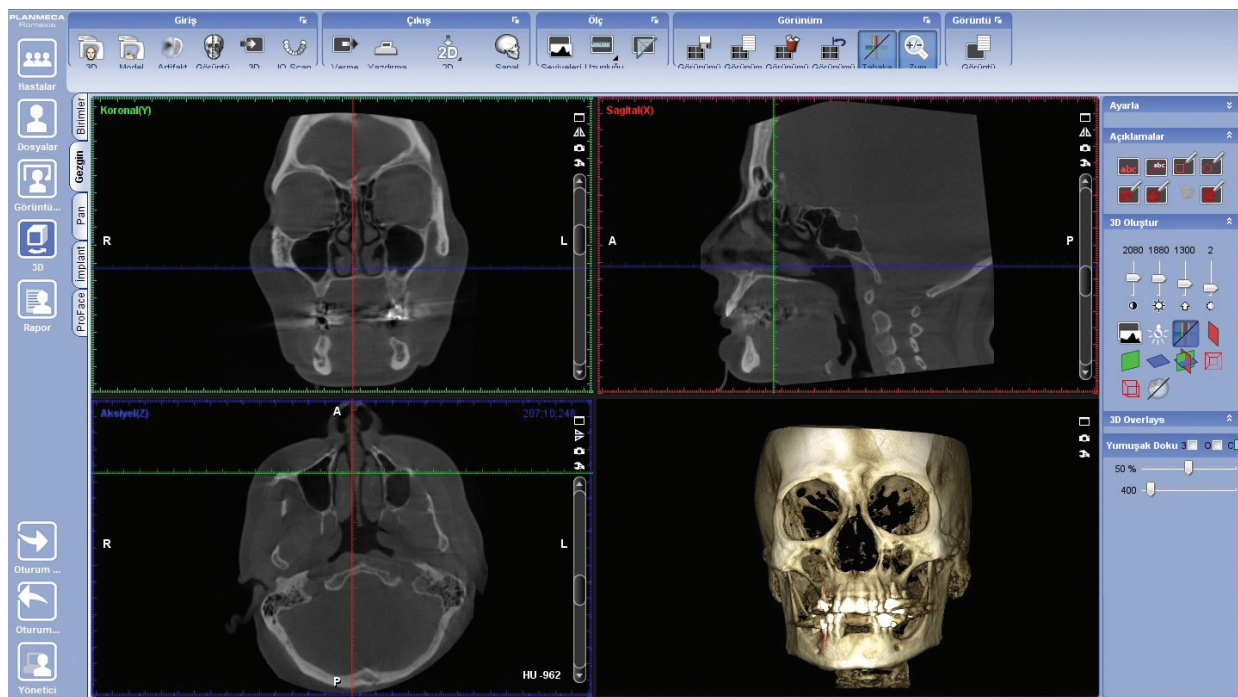


Figure 1. The example of multi-planar CBCT images including coronal, sagittal, axial, and 3D views.

2.1. Advantages of CBCT over conventional CT

- CBCT is less expensive and involves a smaller system, thus providing in-office imaging.
- The X-ray beam is limited, and lower radiation dose is used.
- CBCT provides multi-planar image reconstruction.
- CBCT has higher spatial resolution, providing better visualization of mineralized structures.
- Accurate images are obtained.
- The scan time is more rapid.
- The display modes are exclusive for oral and maxillofacial imaging.
- The imaging artifacts are fewer.
- CBCT has potential for vertical scanning in a natural seated position.

2.2. Disadvantages of CBCT over conventional CT

- Scattered radiation.
- Limited dynamic range of the X-ray detectors.
- Owing to the small detector size, the FOV, and scanned volume are limited.
- Limited contrast resolution.
- Limited soft tissue contrast.

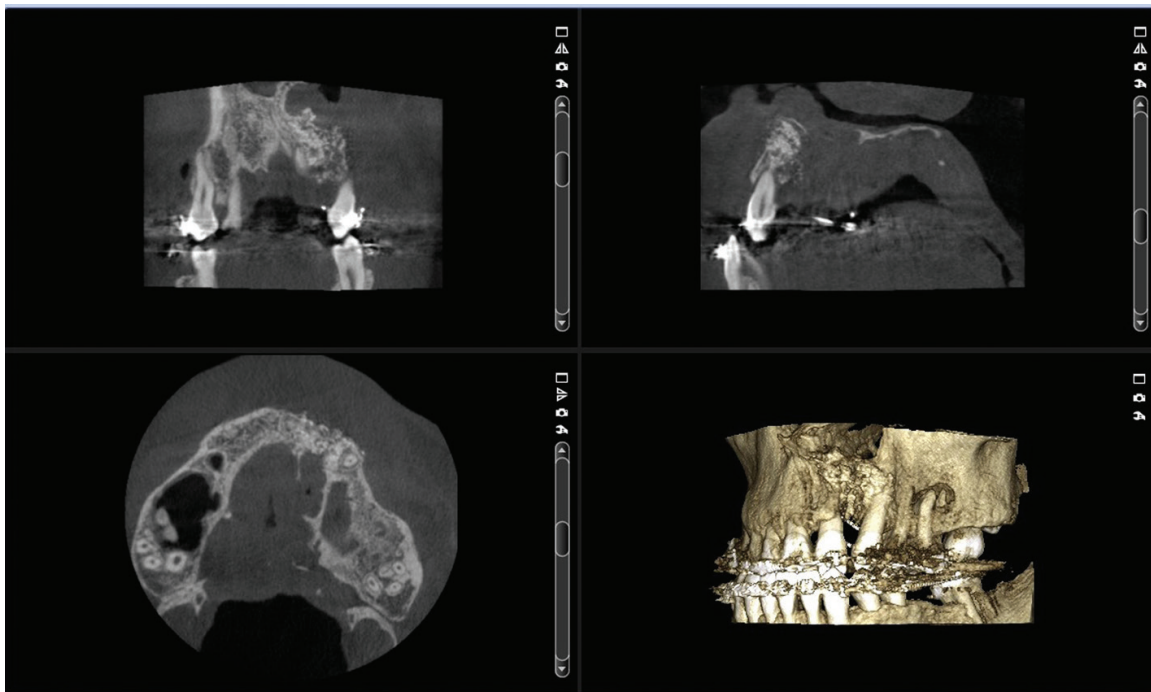


Figure 2. The example of CBCT imaging of an alveolar cleft case showing only the region of interest in order to reduce radiation exposure.

- Bone density values without a linear correlation between different devices.
- Reduced image quality in regions close to high-density neighboring structures such as dental restorations and implants.

According to literature, the subjective image quality was lower on older CBCT units compared to multi-slice CT [15]. However, recent CBCT units with higher resolution showed opposite results [16]. Although new CBCT scanners with flat panel detectors seem to be less prone to metal artifacts, an important problem including susceptibility to movement artifacts still remains [9]. The effective radiation doses for various CBCT devices range from 52 to 1025 micro-sieverts [5]. It was reported that 3D volumetric images obtained with CBCT technology involved up to four times less radiation than conventional CT [17]. Although CBCT requires lower radiation doses compared to CT imaging, the aforementioned radiation doses are still higher than 2D imaging. In order to protect patients and staff during acquisition of images, the selection criteria of CBCT examination should weigh potential benefits against the risks associated with radiation dose. For this purpose, appropriate clinical usage, protective shielding, and the smallest FOV for diagnostic purposes should be obtained (**Figure 2**).

3. Applications of CBCT in oral and maxillofacial region

CBCT is used in all medical and dental disciplines practicing in OMF region, whereas early CBCT devices were dedicated to implantology and dental imaging; nowadays, applications include the whole face and skull. Image analysis function obtains quantifiable accurate data from the image for diagnostic and scientific purposes. Linear, curved, and angular

measurements, area and volume calculation, and densitometric analysis can be performed [13, 18–20]. The main clinical applications of CBCT in the OMF region are: dentoalveolar and maxillofacial surgery, maxillofacial pathology, orthodontics, implantology, endodontics, periodontics, and otolaryngology. The CBCT technology can also be used in forensic medicine. The clinical use of CBCT will be reviewed below with illustrated sample cases:

3.1. Oral and maxillofacial surgery

The OMF surgery is the main discipline which uses the CBCT technology. In a literature review, it was reported that 41% of the scientific papers related to the clinical applications of CBCT dealt with the use for maxillofacial surgery [9]. The main topics may be summarized as dental implantology, impacted and supernumerary tooth, OMF pathology, maxillofacial trauma, temporomandibular joint (TMJ) disorders, dentofacial discrepancies, and cleft palate.

3.1.1. Dental implantology

During the preoperative planning of dental implant treatment, radiographic methods for assessment of bone quality and quantity are frequently used. For 2D assessment, orthopantomography (OPG) is frequently used. The American Association of Oral and Maxillofacial Radiology recommends cross-sectional views for evaluation of a potential implant site [14]. CBCT provides the 3D visualization of the alveolar bone height, width, and thickness, and spatial proximity of inferior alveolar and incisive canals, maxillary sinus, and nasal cavity (**Figure 3**). It is the contemporary method used for planning dental implant surgery and bone augmentation

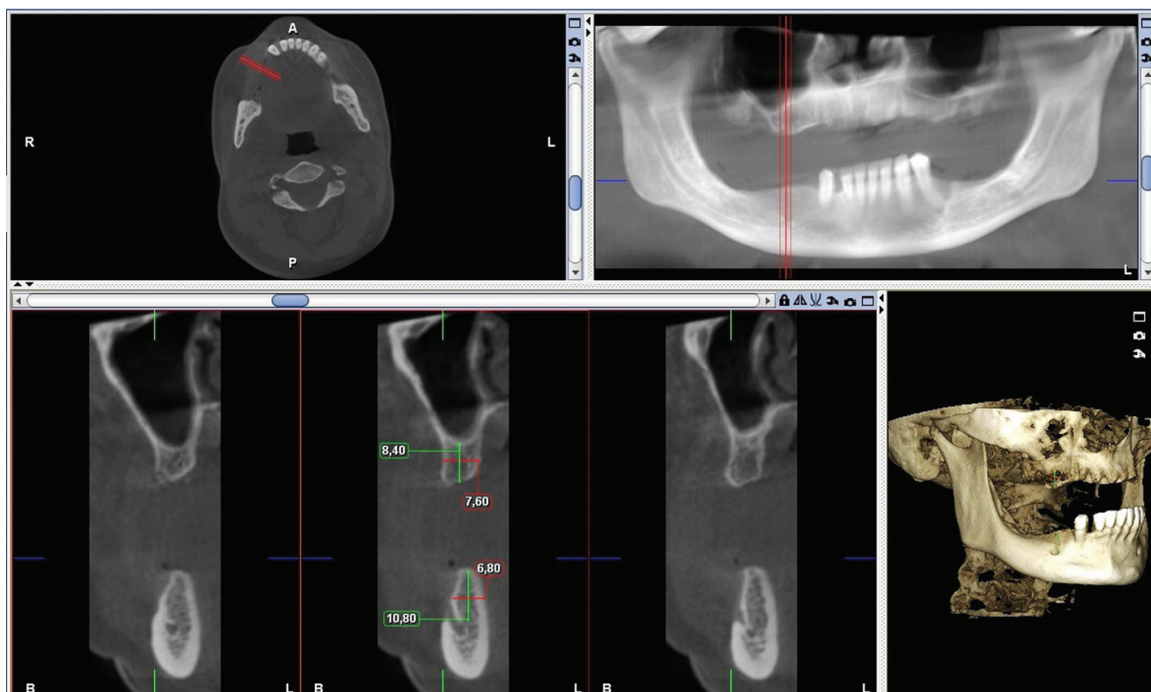


Figure 3. The example of CBCT imaging including cross-sectional view showing the alveolar bone height and width, and localization of maxillary sinus and mental nerve.

procedures (**Figure 4**). As shown in our previous clinical study, accurate measurements can be performed on CBCT images for diagnosis, treatment planning, and evaluation of treatment results of bone augmentation and dental implants [21]. The CBCT images are free from distortion; however, errors in patient positioning may lead to inaccurate measurements which may

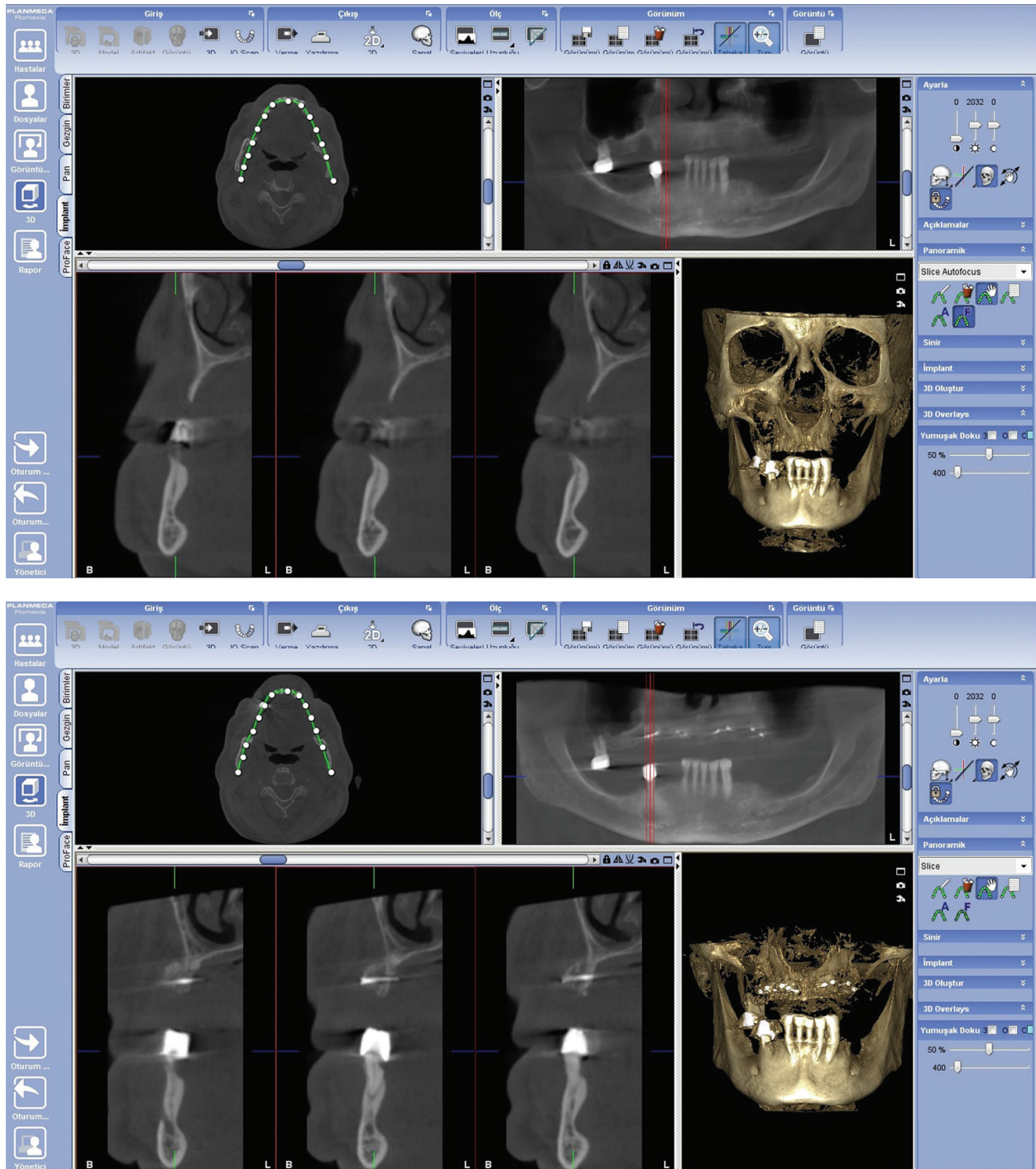


Figure 4. The CBCT imaging of a patient with atrophic maxilla who needs bone augmentation and dental implant treatment. **a.** Before bone augmentation. **b.** After bone augmentation (from iliac crest).

cause damage to anatomical structures. The success of dental implant treatment is influenced by both the quality and quantity of available bone for implant placement. During the past few years, the concept of using CT-derived Hounsfield unit (HU) values had increasing popularity for quantitative assessment of bone density [22, 23]. However, patients are exposed to high radiation during CT scanning. Besides quantitative assessment of bone, CBCT can also be used for evaluation of bone quality (**Figure 5**). In recent studies, significant correlations between the density values of CBCT and HU values of CT were reported [24, 25]. In contrast, controversial results concerning the assessment of bone density using CBCT were also reported in literature [13, 26]. In our previous clinical studies, we observed significant correlation between CBCT-derived bone density and dental implant stability parameters including insertion torque value and resonance frequency analysis [27, 28]. Thus, it seems to be possible to predict bone density, initial implant stability, and possibility of immediate or early loading using CBCT scan prior to implant surgery.

Moreover, it is also possible to perform navigation-guided implant surgery by using specific software and CBCT imaging. The 3D specific navigation system provides surgeons an additional planning tool during implant surgery, offering instant and continuous visualization of drill tip and angle and their relations with neighboring vital structures that have to be respected in the three spatial planes in CBCT images. With the guidance of the dynamic navigation system, surgeon can monitor the 360° view of the relationship among implant drill, inferior alveolar nerve, maxillary sinus, nasal cavity, and buccal and lingual alveolar bone plates during surgery (**Figure 6**).

3.1.2. Impacted and supernumerary tooth

The CBCT is also used for presurgical evaluation of impacted teeth, supernumerary teeth, and their relations with neighboring anatomic structures (adjacent teeth, inferior alveolar nerve,

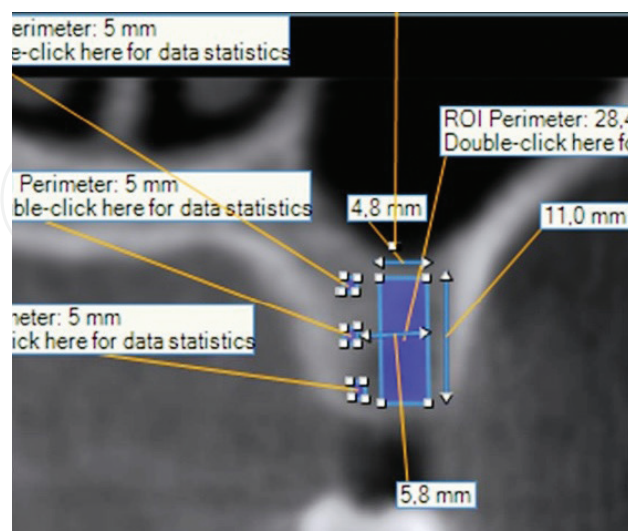
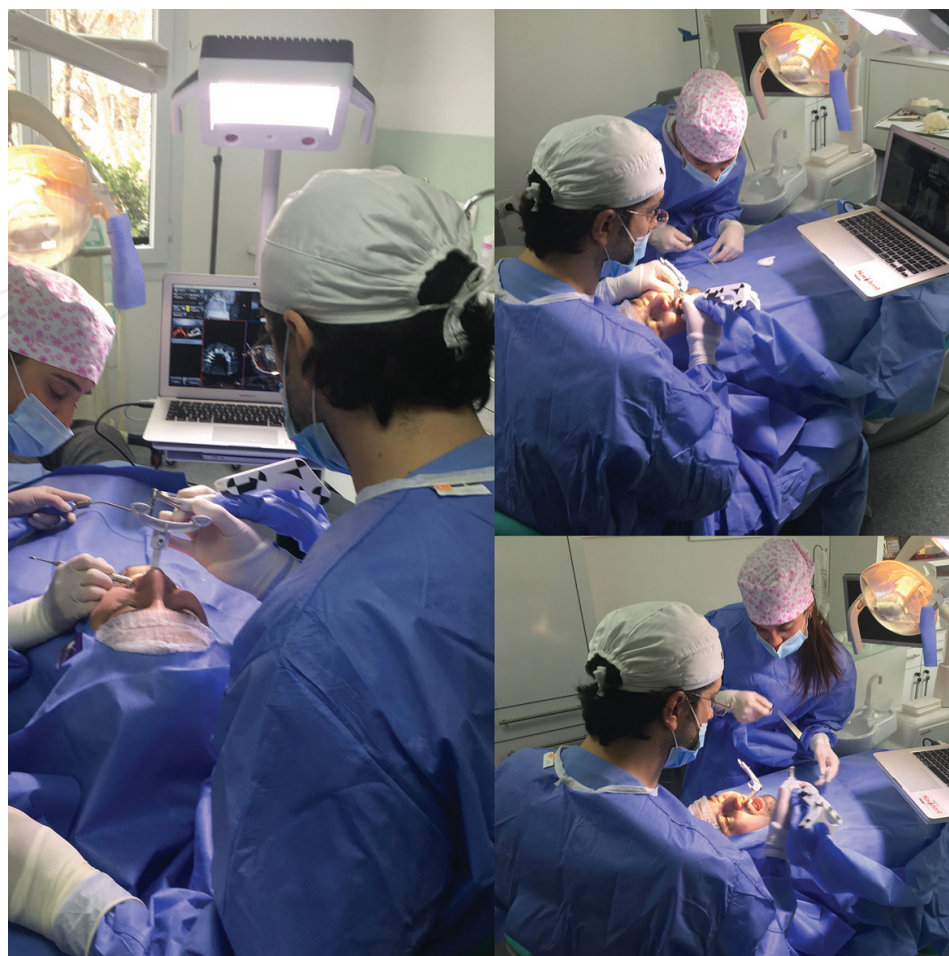
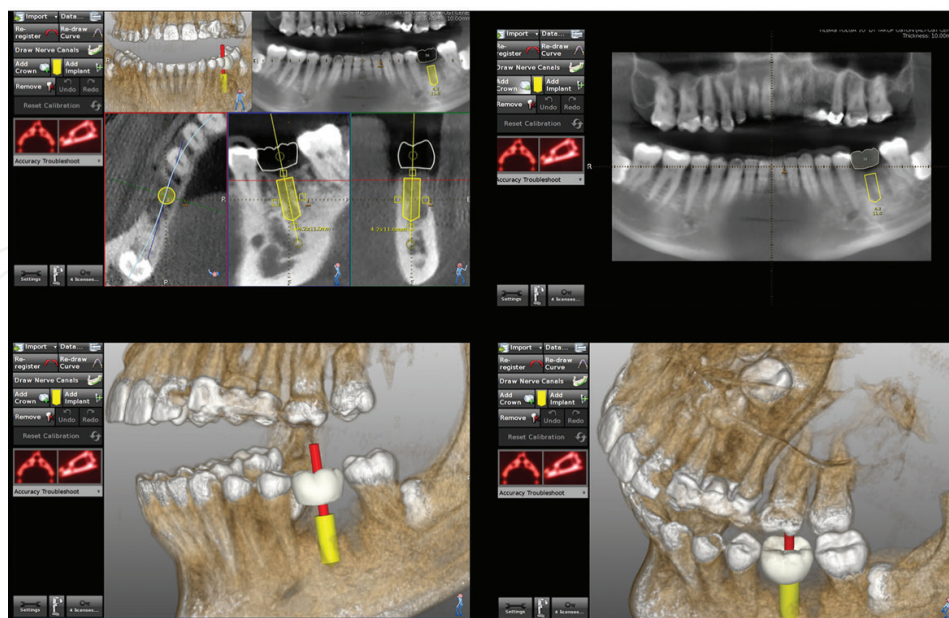


Figure 5. The example of cross-sectional CBCT imaging used to calculate bone density of the designated implant region.



a.



b.

Figure 6. CBCT-based navigation-guided dental implant surgery. **a.** Clinical view. **b.** Software view (by the courtesy of Dr Yakup Üstün).

mental nerve, and maxillary sinus). Thus, clinician is able to plan the surgery and inform the patients about possible risks (**Figure 7**). In a recent clinical study, Jawad et al. reported that CBCT provided improved detection rates (63% versus 45% for plain radiographs) of root resorption associated with impacted canines. The authors also introduced a new root resorption scale for CBCT imaging [29].

3.1.3. Oral and maxillofacial pathology

All kinds of pathologic lesions which affect bone tissue in the OMF region including infection, cysts, tumors, and osteonecrosis can be monitored by CBCT imaging. The CBCT assessment provides maxillofacial surgeon to visualize the accurate localization of pathologic entity and its relation with adjacent vital structures in multi-planar view (**Figure 8**). For medication-related osteonecrosis of the jaws (MRONJ) lesions, the innovative use of routine tumor-surveillance imaging in combination with CBCT imaging was described to provide a high-resolution 3D analysis [30]. The authors interpreted functional imaging information by fusing positron emission tomography/computed tomography (PET/CT) and single-photon emission computed tomography/computed tomography (SPECT/CT) data with CBCT data. Hence, the authors stated that this new composite image analysis, if validated, will facilitate surgical planning by demarcating MRONJ area. The 3D model preparation and adaptation of the reconstruction plates to the jawbone before surgery can also be possible with CBCT imaging for maxillofacial reconstruction patients (**Figure 9**).

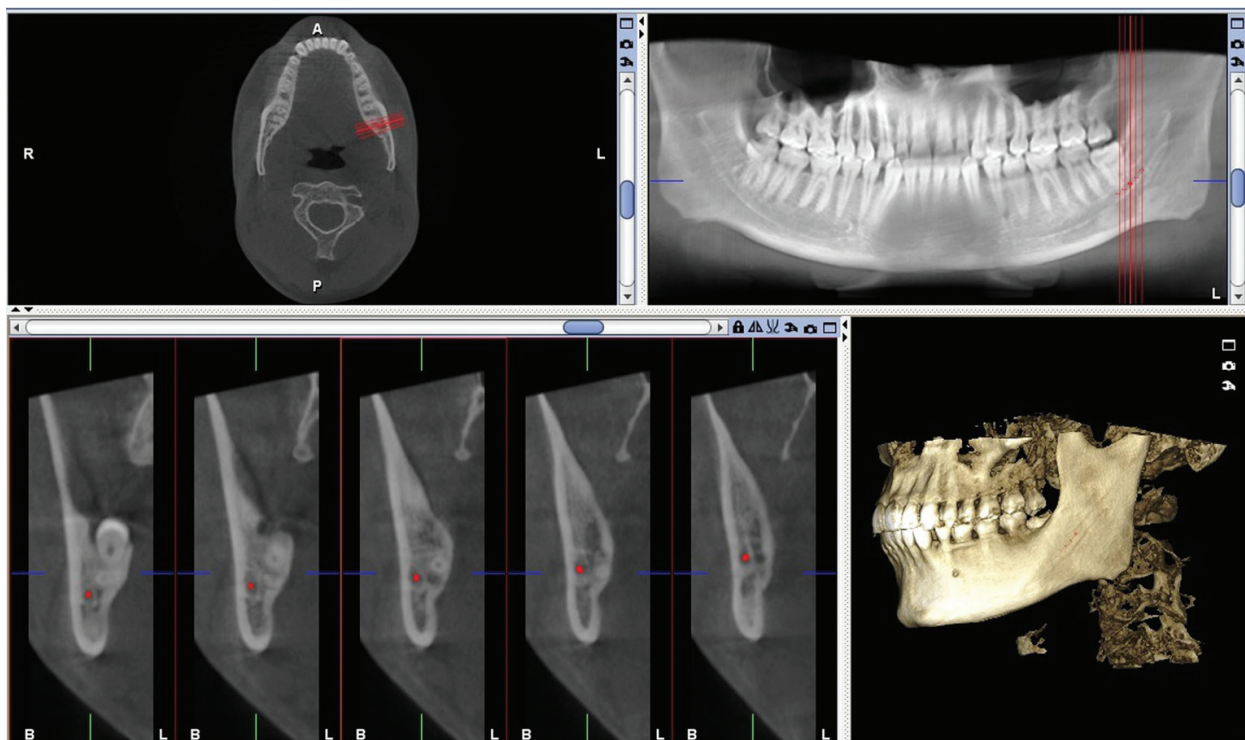


Figure 7. The example of CBC imaging showing the inferior alveolar nerve and its relation with mandibular impacted third molar tooth.

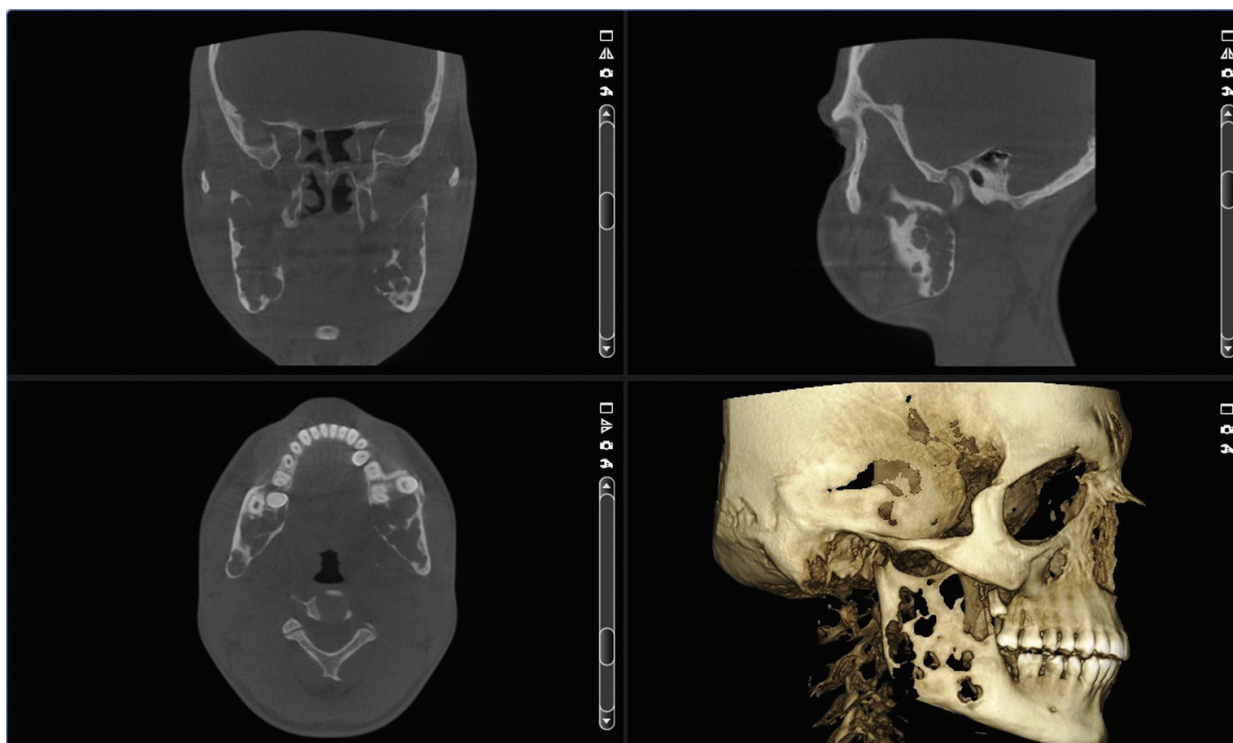


Figure 8. The example of CBCT imaging of a pathologic lesion located in the mandible (reparative giant cell granuloma).

3.1.4. Maxillofacial traumatology

Maxillofacial trauma patients can be assessed with CBCT to plan appropriate treatment method (**Figure 10**). The diagnostic performance of CBCT in detecting orbital floor fractures was reported to be better than ultrasonography. Moreover, it was also reported that CBCT could be used in detecting fractures as a reliable surrogate to CT [31]. The CBCT technology

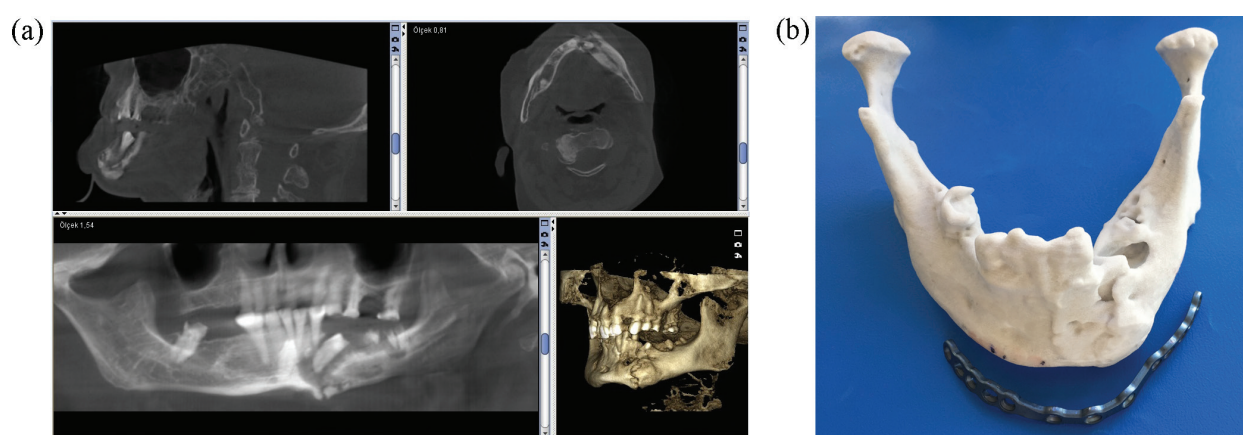


Figure 9. (a) The CBCT imaging of a patient with pathologic mandible fracture due to MRONJ. (b) The CBCT-based 3D model of the patient. Note that bending and adaptation of the titanium plate to the model before surgery can facilitate reconstructive procedures.

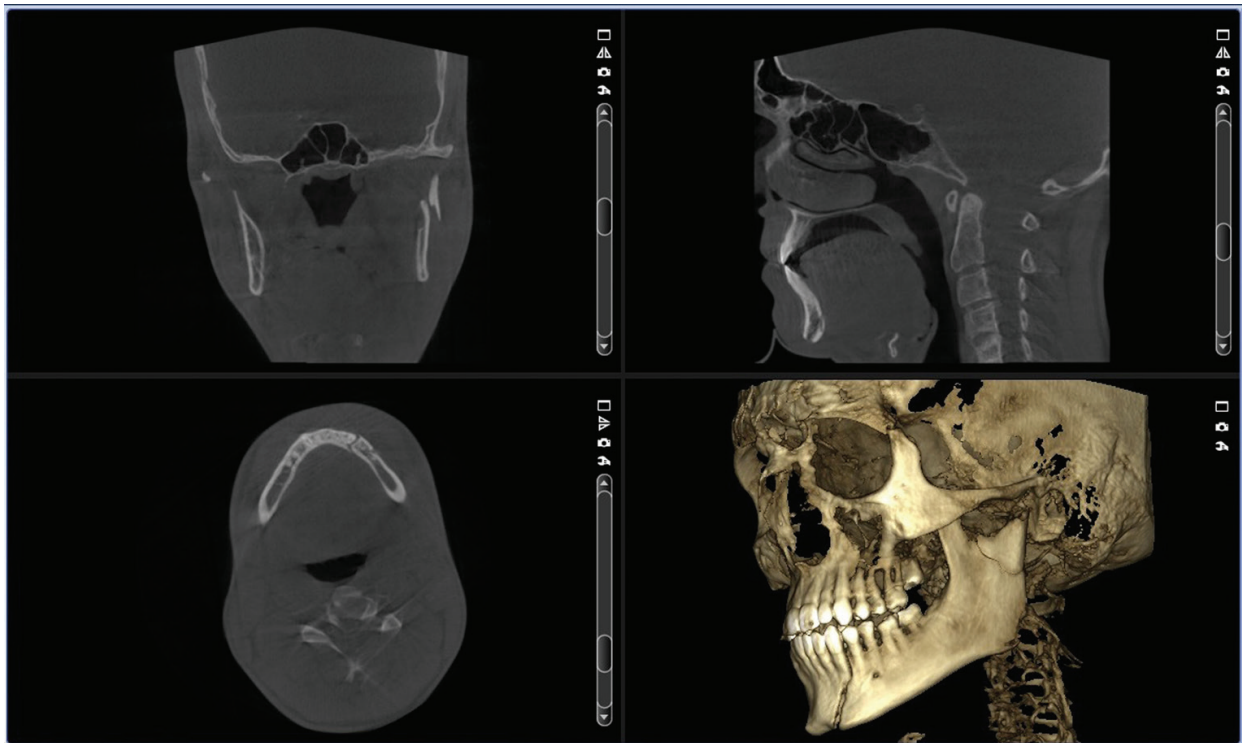


Figure 10. The example of CBCT imaging of a patient with mandibular left parasymphysis and condyle fracture.

can also be used in combination with specific computer software for preoperative virtual planning and fabrication of patient-specific reconstruction plate for mandibular fractures [32]. When CBCT and multi-detector CT were compared in diagnostic imaging of midface, it was concluded that CBCT provided better image quality at lower doses, comparable image quality at higher doses, and superior spatial resolution in standard- and reduced-dose settings [33]. However, in another recent study, it was concluded that CBCT was not optimal for post-operative facial imaging compared to multi-slice CT in terms of visualization of maxillofacial bony structures in the vicinity of osteosynthesis materials [34].

3.1.5. Temporomandibular joint disorders

Temporomandibular disorders associated with degenerative pathologies or abnormalities in the bony structures of condyle, glenoid fossa, and articular eminence such as cortical erosion, articular surface flattening, osteophytes, condylar hyper-, hypo-, or aplasia, ankylosis, and coronoid process hyperplasia can be visualized with CBCT [9–11]. A CBCT imaging for TMJ complex requires less time and lower radiation doses, it provides the multi-planar views for both TMJs from a single 360° rotation scan, and it simplifies positioning of patient [11]. The linear, angular, and volumetric measurements can also be performed with CBCT imaging software for research purposes. The image-guided puncture technique for TMJ using CBCT can also be used to determine the optimum angle and distance in order to prevent middle cranial fossa damage [35]. These measurements can be used to produce stereographic models

and custom-made TMJ prosthesis. The CBCT imaging can only be used to assess the bony structures of TMJ. In general, it is not the imaging of choice for TMJ disorders including myofascial pain dysfunction or internal derangements. The examples of CBCT images acquired for TMJ disorders are shown in **Figures 11–13**.

3.1.6. Dentomaxillofacial discrepancies and cleft palate

The growth abnormalities of maxillofacial bones can be assessed by CBCT imaging (**Figure 14**). The treatment planning and success of the surgical treatments of alveolar cleft patients can be assessed with CBCT imaging (**Figure 15**). As reported in our previous study, it is possible to compare the bone density values of the cleft and non-cleft sites to evaluate the success of alveolar cleft repair using CBCT technology [36]. Moreover, 3D measurement of cleft area including volume of bone defect and outcomes after alveolar grafting in cleft lip and palate patients can also be assessed by CBCT imaging. The dentofacial discrepancies can be visualized, and virtual planning of orthognathic surgeries can be performed with CBCT imaging and special software. Recently, a novel technique for splintless orthognathic surgery, using CBCT imaging with computer-aided design/computer-aided manufacturing (CAD/CAM) technology and virtual planning software, was introduced [37].

The growth abnormalities of head and neck bones can also be scanned using CBCT technology (**Figure 16**). As reported in our previous study, visualization of the styloid process elongation in detail including linear and angular measurements can also be performed with CBCT imaging [18].

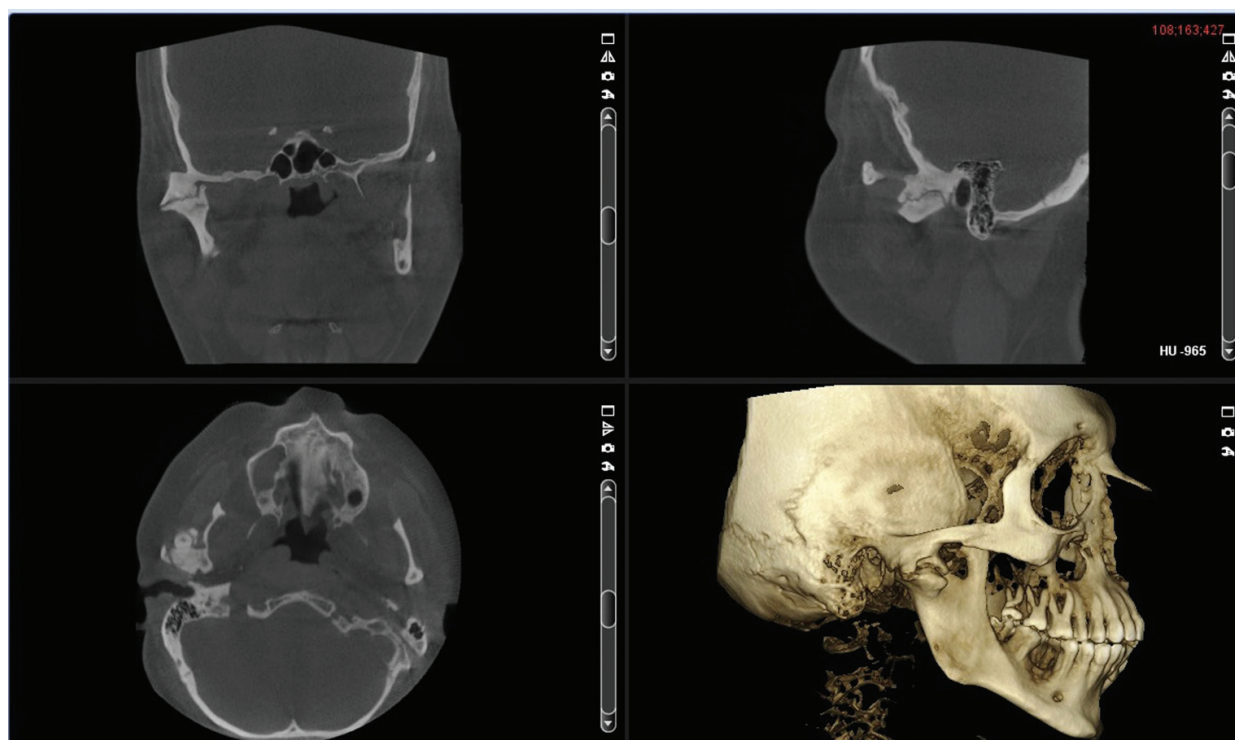


Figure 11. The multi-planar CBCT imaging of a patient with right TMJ ankylosis.

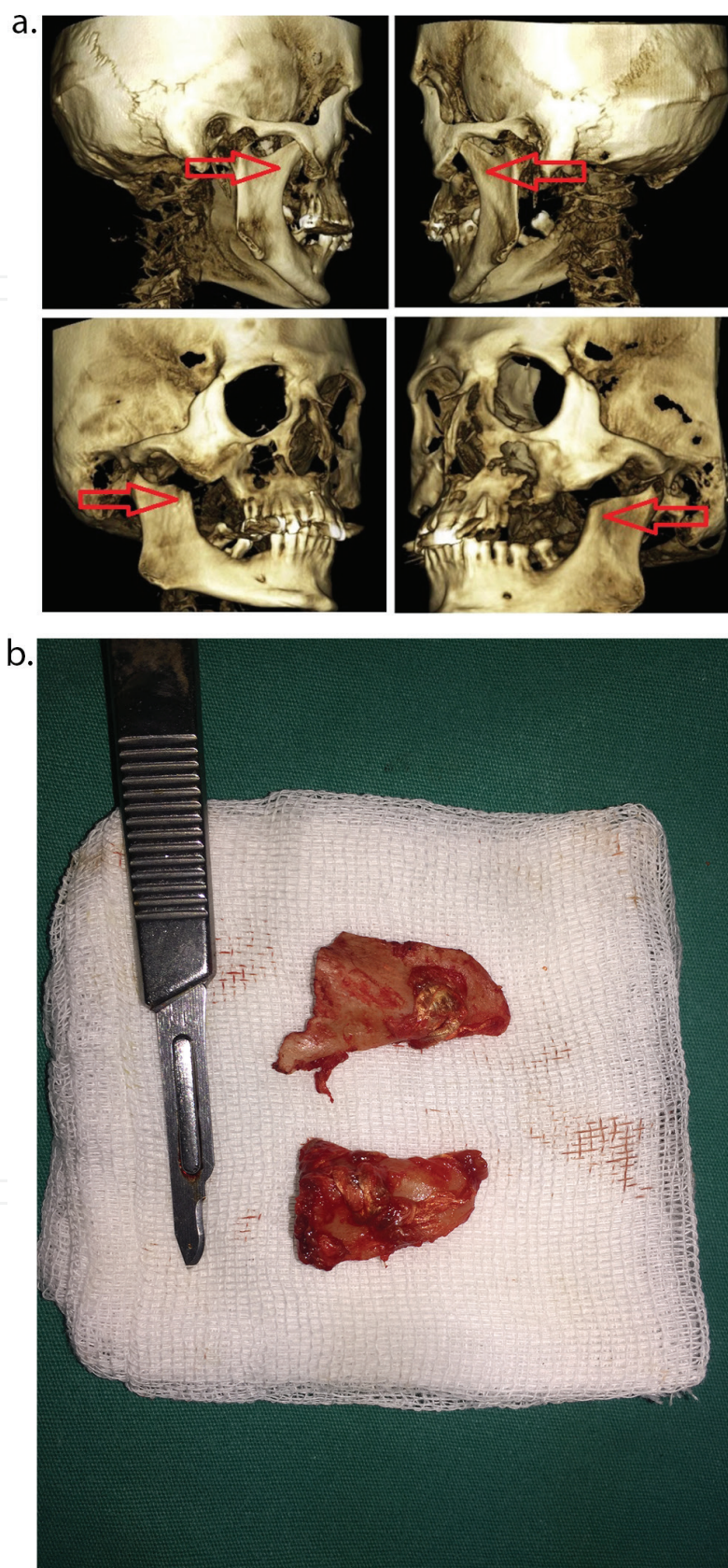


Figure 12. (a) The 3D CBCT views of a patient with bilateral coronoid process hyperplasia before and after coronoidectomy surgery (arrows). (b) The resected bone pieces of coronoid process.

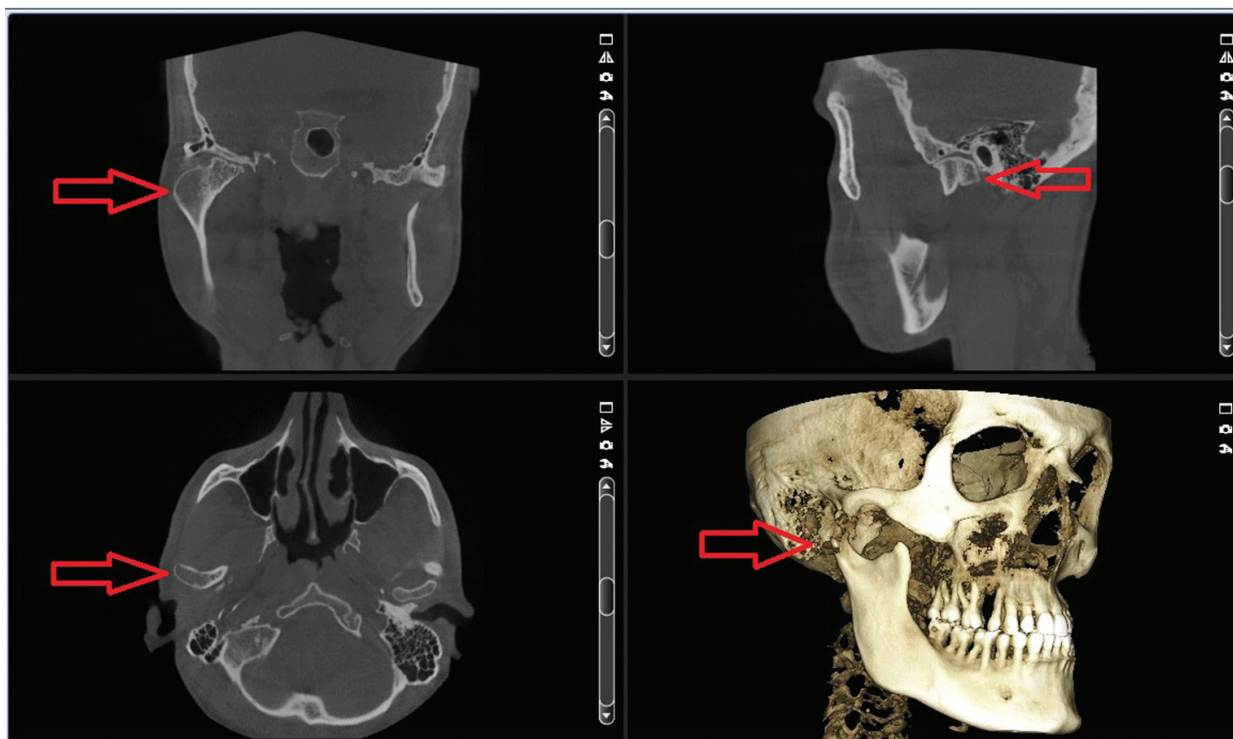
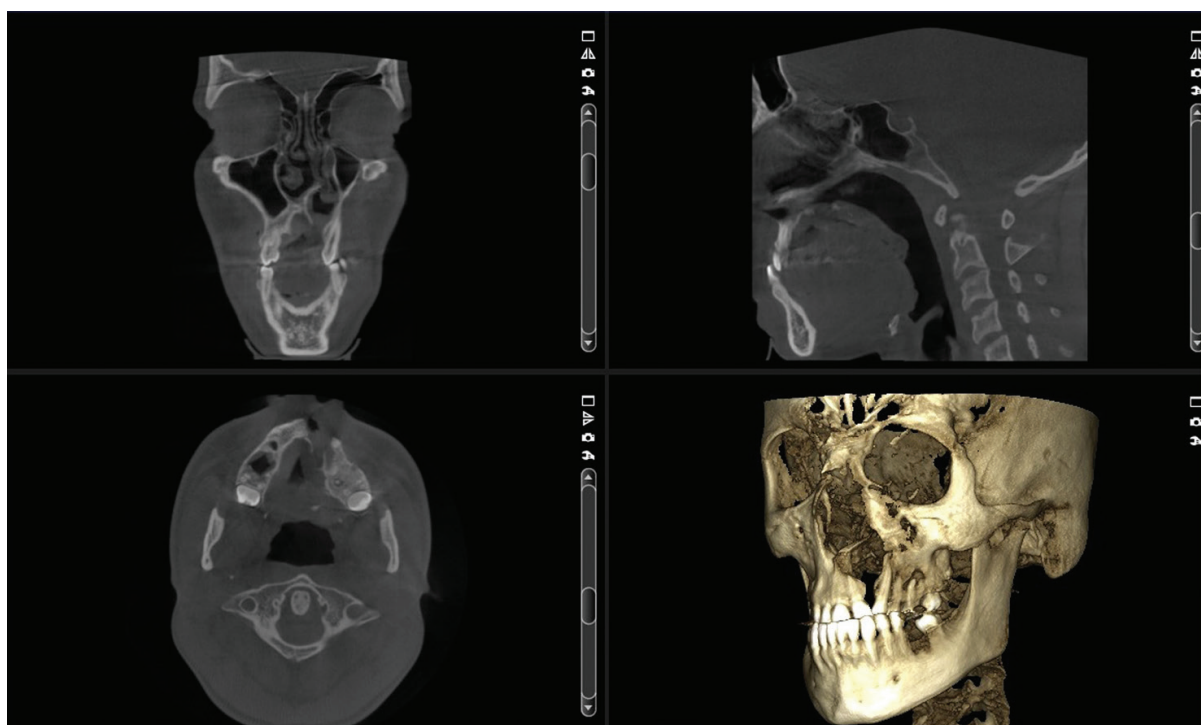


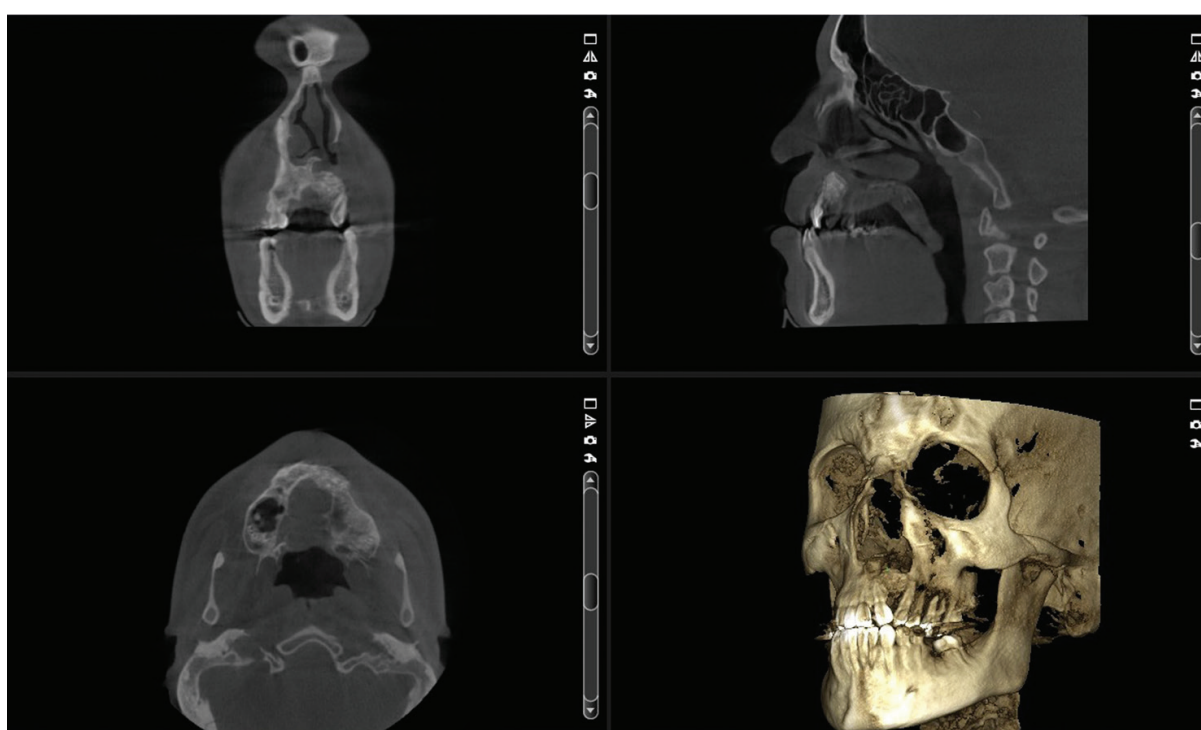
Figure 13. The CBCT imaging of a patient with right mandibular condylar hyperplasia (red arrows).

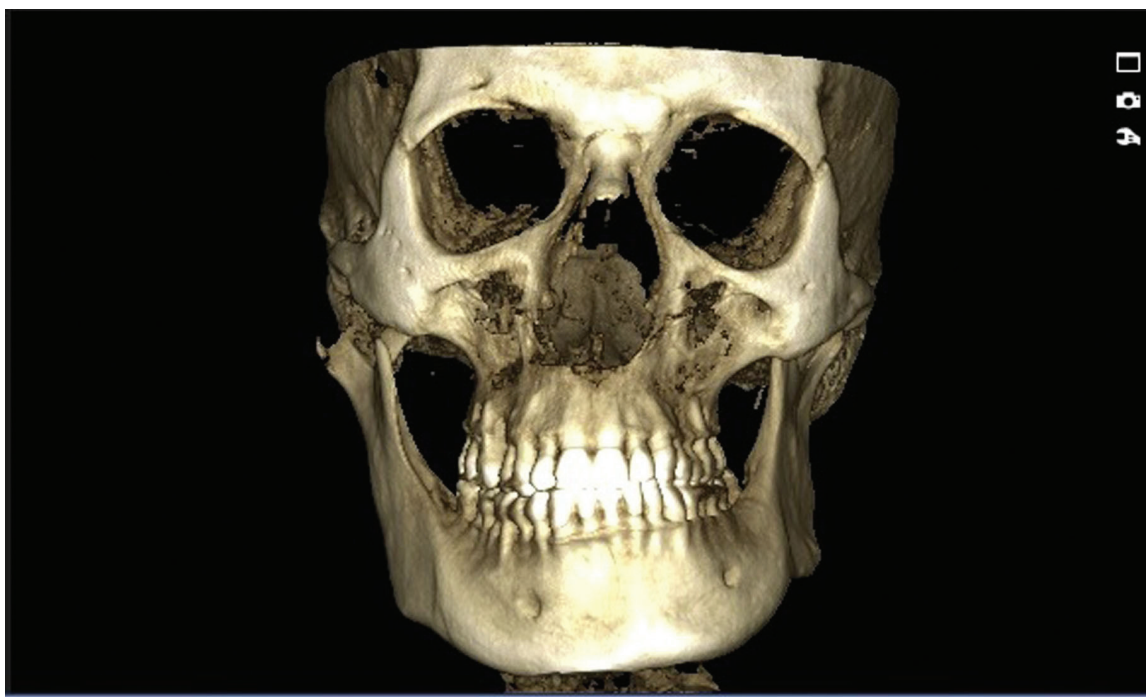

Figure 14. The 3D CBCT imaging of a patient with mandibular asymmetry who needs orthognathic surgery.



a.



b.

Figure 15. The multi-planar CBCT imaging of a patient with cleft palate on the left site. **a.** Before cleft repair surgery. **b.** After bone augmentation surgery.

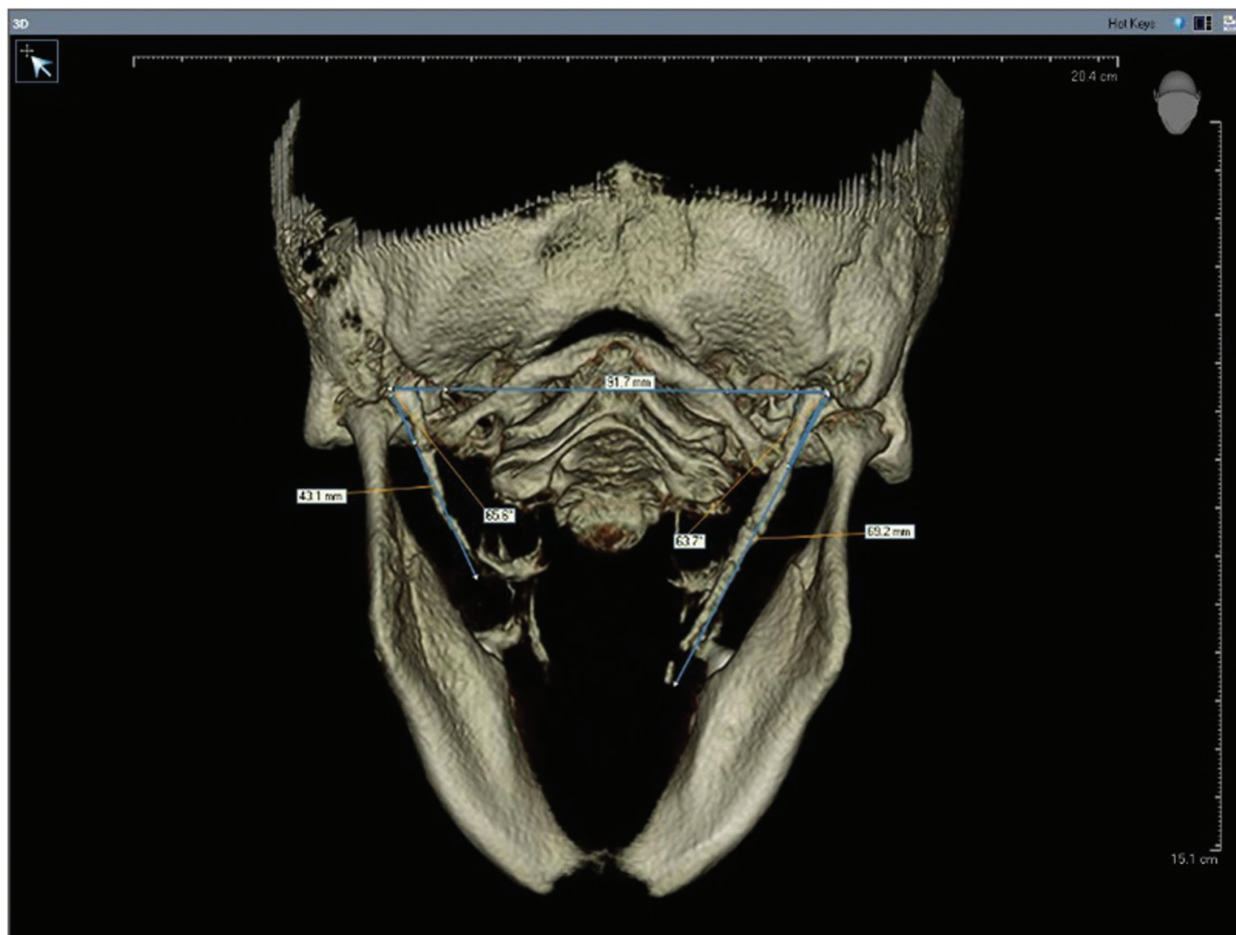


Figure 16. The 3D CBCT imaging of a patient with bilateral elongated styloid process (Eagle syndrome). Note that the length and medial angulations of the styloid process can be measured by using CBCT software.

3.2. Orthodontics

Radiographic analysis is an important aspect for diagnosis and treatment planning in orthodontics. CBCT imaging allows the radiographic assessments in detail with lower radiation doses and without any distortion and superimposition of the other structures. The airway analysis before and after orthognathic surgeries, growth assessment, accurate measurements of cleft area in cleft lip and palate patients, assessment of skeletal and dental structures, assessment of TMJ complex, treatment planning for orthognathic surgery, accurate estimation of space requirement for unerupted or impacted teeth, assessment of orthodontics-induced root resorption, determination of possible regions for mini screw placement, and linear and angular measurements for severe skeletal discrepancies can be performed with CBCT imaging.

The CBCT imaging can be used to assess the amount of interradicular bone, root proximity, the localization of maxillary sinus and inferior alveolar nerve, and density of the available bone, all of which are important in determining the stability and success of orthodontic mini screws. Due to the considerable variation of available bone thickness between individuals, a CBCT imaging is recommended in order to determine the maximum screw length [38]. A CBCT

imaging study indicated that vertical facial pattern of the patients should be taken into consideration when adjusting the insertion angle of mini screws at the maxillary buccal site [39].

CBCT can also be used in association with CAD/CAM technology for production of custom-made orthodontic appliances [40].

In terms of evaluation of impacted teeth, small volume of CBCT can be used as a supplement to panoramic imaging in the following cases: when canine inclination in the panoramic X-ray exceeds 30°, when root resorption is suspected at adjacent teeth, and when the canine apex is not clearly seen in the panoramic X-ray [41].

The CBCT scans can be used to evaluate the outcomes of orthodontic treatments and orthognathic surgery. The 3D overlays of superimposed models and 3D color-coded displacement maps provided assessments of treatment changes, displacements of soft and hard tissue during postsurgical follow-up, and amount of relapse [42, 43].

The landmark identification is greatly enhanced in CBCT images. It was reported that reproducibility of cephalometric measurements obtained from CBCT scans was better than that obtained from conventional cephalograms [44]. One of the application areas of CBCT for orthodontics is the growth assessment of patients. The cervical vertebra maturity assessment with CBCT provides reliable assessment of pubertal growth; thus, CBCT can be used to evaluate skeletal maturity for orthodontic treatment [45]. For airway analysis, lateral cephalograms have been routinely used. Axial cuts of 3D CBCT scans provide soft tissue points which are more clearly visible in CBCT sections compared with conventional radiography, thereby enhancing airway assessment [46]. The CBCT-assisted airway analysis also facilitates the diagnosis and treatment planning of obstructive sleep apnea (OSA) [47]. A recent CBCT imaging study concluded that 3D image reconstruction accurately confirmed morphological changes in the upper airway during oral appliance therapy of patients with OSA [48]. In terms of airway analysis with CBCT technology, there are controversial conclusions in literature. A recent systematic review shows that upper pharyngeal airway analysis using CBCT is a reliable method; however, there are some significant limitations including lack of manual orientation of images and selection of threshold sensitivity. Thus, further researches are necessary to adequately establish the reliability of airway analysis with CBCT imaging [49]. A CBCT image used for airway analysis is shown in **Figure 17**.

3.3. Periodontology

The role of CBCT in the diagnosis of periodontal diseases was studied in literature. CBCT displays 2D and 3D images that are necessary for the diagnosis and treatment planning of intrabony defects, furcation involvements, and buccal/lingual bone destructions [50]. In a recent experimental animal study, the diagnostic value of CBCT and digital intraoral radiography for detection of periodontal defects including furcation involvements, one-, two-, three-wall and trough-like intrabony defects, fenestration, and dehiscence were compared. It was concluded that CBCT was superior to digital radiography for detection of grade 1 furcation involvements, three-wall defects, fenestrations, and dehiscences [51]. It is also clinically reported that CBCT imaging provides detailed information about furcation involvement and reliable basis for decision of periodontal treatment [52]. In literature, most of the studies

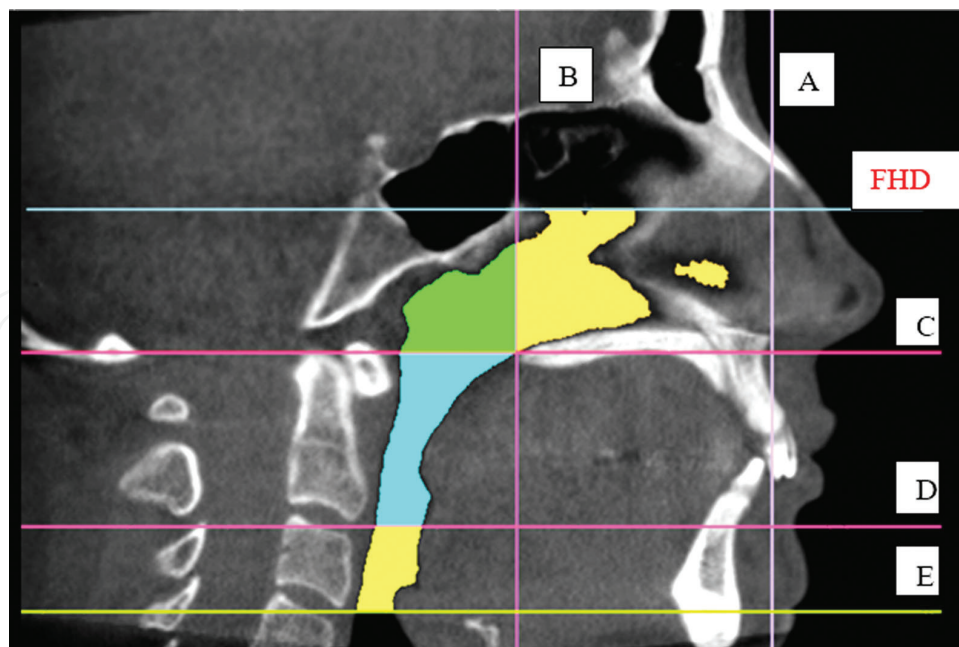


Figure 17. The right lateral view of pharyngeal airway on CBCT image (A: anterior nasal plane, B: posterior nasal plane, C: upper pharyngeal plane, D: middle pharyngeal plane, E: lower pharyngeal plane, FHD: Frankfurt horizontal plane).

concerning the accuracy of CBCT in periodontal diagnosis assessed the efficiency of CBCT in bone defects. However, in our recent study, we concluded that gingival soft tissue thickness and acellular dermal grafts can be consistently evaluated with CBCT technique [53]. The detailed diagnostic imaging of periodontal diseases as well as peri-implantitis may be performed with CBCT technology (**Figures 18 and 19**). Literature shows that optimal detection of peri-implant bone loss is achieved using the smallest FOV, the highest number of acquisition frames, and the smallest voxel [54]. When the CBCT-derived features of peri-implantitis defects compared to the corresponding histomorphometric findings, it is concluded that CBCT represents an accurate diagnostic tool to estimate the histological extent of peri-implantitis [55]. When the performances of different radiographic techniques (intraoral radiography, OPG, CBCT, and CT) in detecting peri-implant bone defects were compared, the highest sensitivity was found with intraoral radiography and CBCT, and the highest specificity was found with intraoral radiography, while CT demonstrated the lowest performance [56].

3.4. Endodontics

The CBCT imaging for endodontic purposes provides the clinicians' wide view in the visualization of periapical lesions, internal or external root resorption, vertical root fractures, and accessory root canals. It was found that CBCT assessment of changes in periapical lesion and mucosal thickening dimensions may reveal useful information regarding endodontic treatment success [57]. The CBCT imaging also guides the clinicians for planning endodontic surgery and in elucidation of causes of fail after endodontic treatment [10, 58]. However, there are two major disadvantages concerning the utilization of CBCT in endodontics: The increased radiation doses, compared to 2D imaging methods, limit its routine usage. Thus, benefits

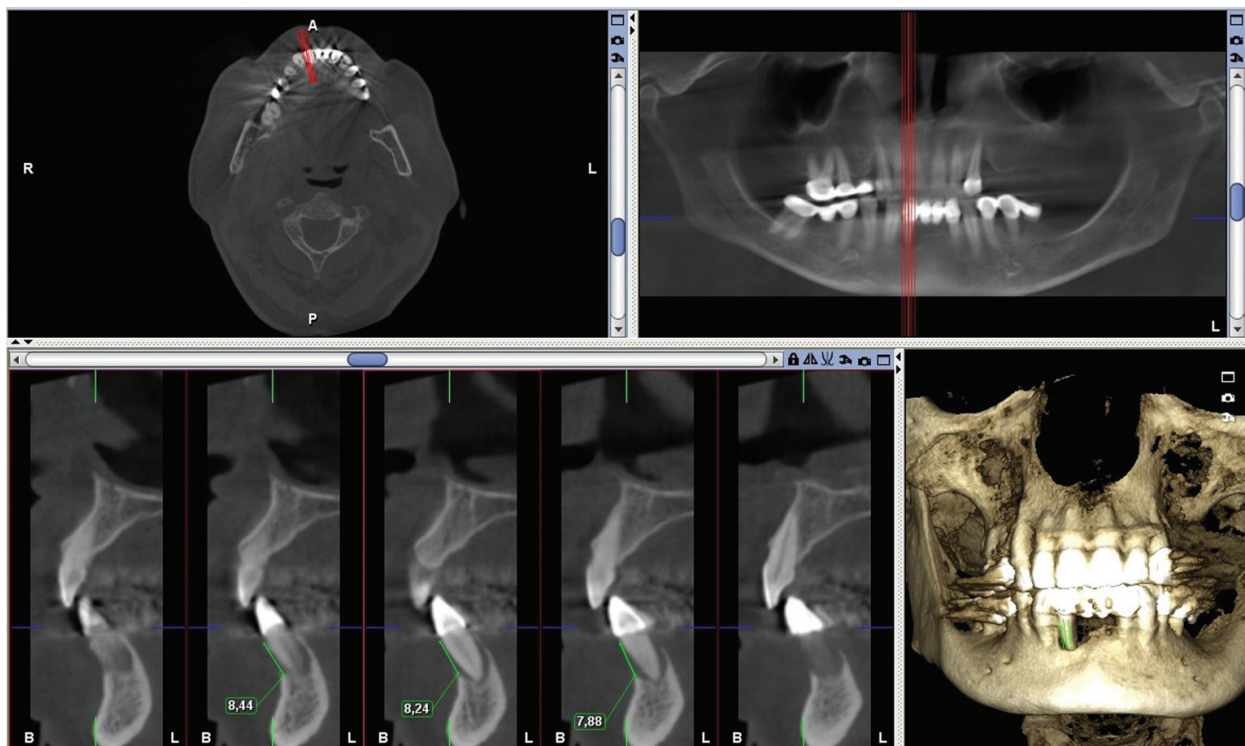


Figure 18. The CBCT imaging of a periodontitis case. Note that the amount of bone resorption around mandibular incisor tooth can be measured in detail using CBCT software.

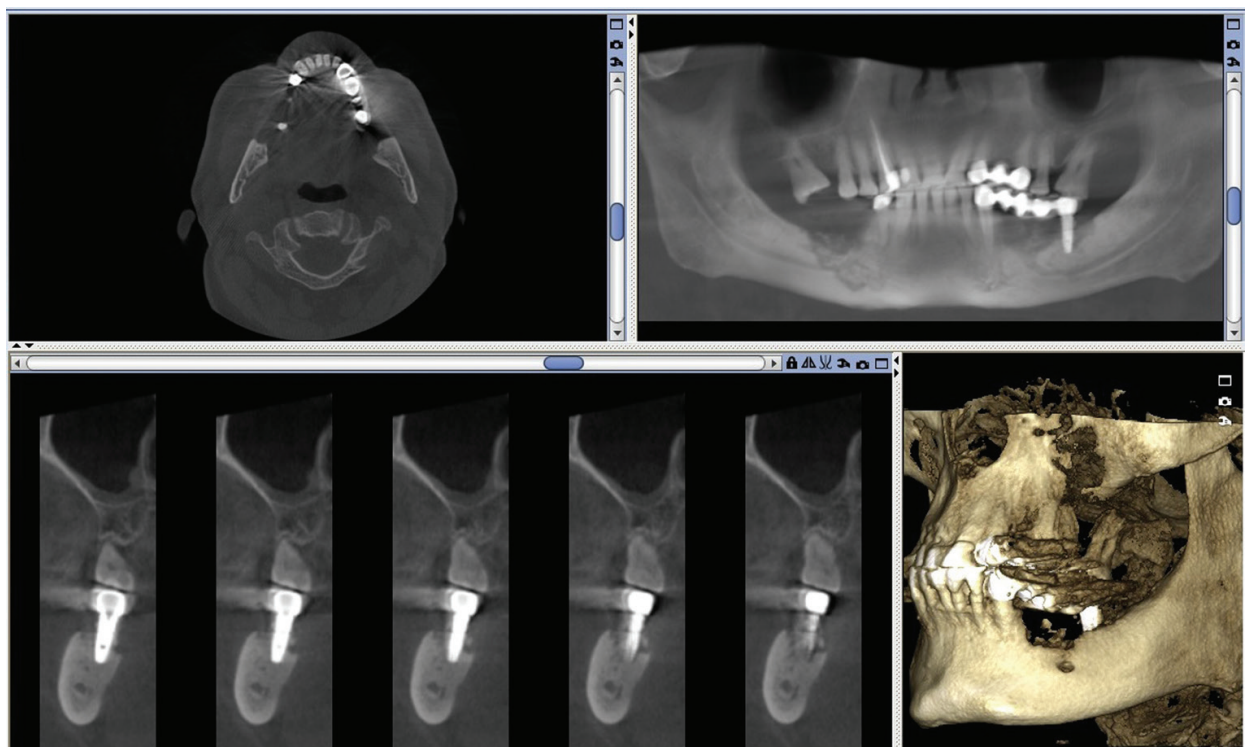


Figure 19. The CBCT imaging of a peri-implantitis case showing bone resorption around dental implant.

getting with CBCT imaging should be carefully evaluated on an individual basis to protect the patients. The other disadvantage is that the radiopaque filling materials and posts create artifacts which may compromise the diagnosis.

In a recent clinical study, it was reported that CBCT scans had 93% sensitivity, 78% specificity, and 88% accuracy for detection of vertical root fractures in endodontically treated teeth [59]. When CBCT and digital periapical radiography were compared in detecting mandibular molar root perforations, in the non-obtured root canals, the sensitivity and specificity of CBCT scans in perforation detection were better than those of three-angled periapical radiographs. However, in obtured root canals, periapical radiography was reported to be more trustworthy than CBCT for perforation detection [60]. In a recent study, periapical radiographs and CBCT were compared in detecting fractured instruments in root canals with and without filling. The results showed that in the absence of filling, accuracy values were similar in all imaging techniques. In the presence of filling, CBCT had low accuracy [61]. In our recent clinical study, we observed that preoperative CBCT examination demonstrated positive contributions to the endodontic surgery of maxillary first molar teeth [62]. Maxillary posterior teeth have close relationship with maxillary sinus. This may cause the peri-radicular infection to destroy cortical border of the maxillary sinus and spread into the sinus. Such cases may make the clinician to do false or missing diagnosis. In such cases, CBCT imaging allows the practitioner to do appropriate diagnosis of the peri-radicular lesion and its relationship with the adjacent anatomic structures [63]. A CBCT image acquired for planning of endodontic surgery is shown in **Figure 20**.

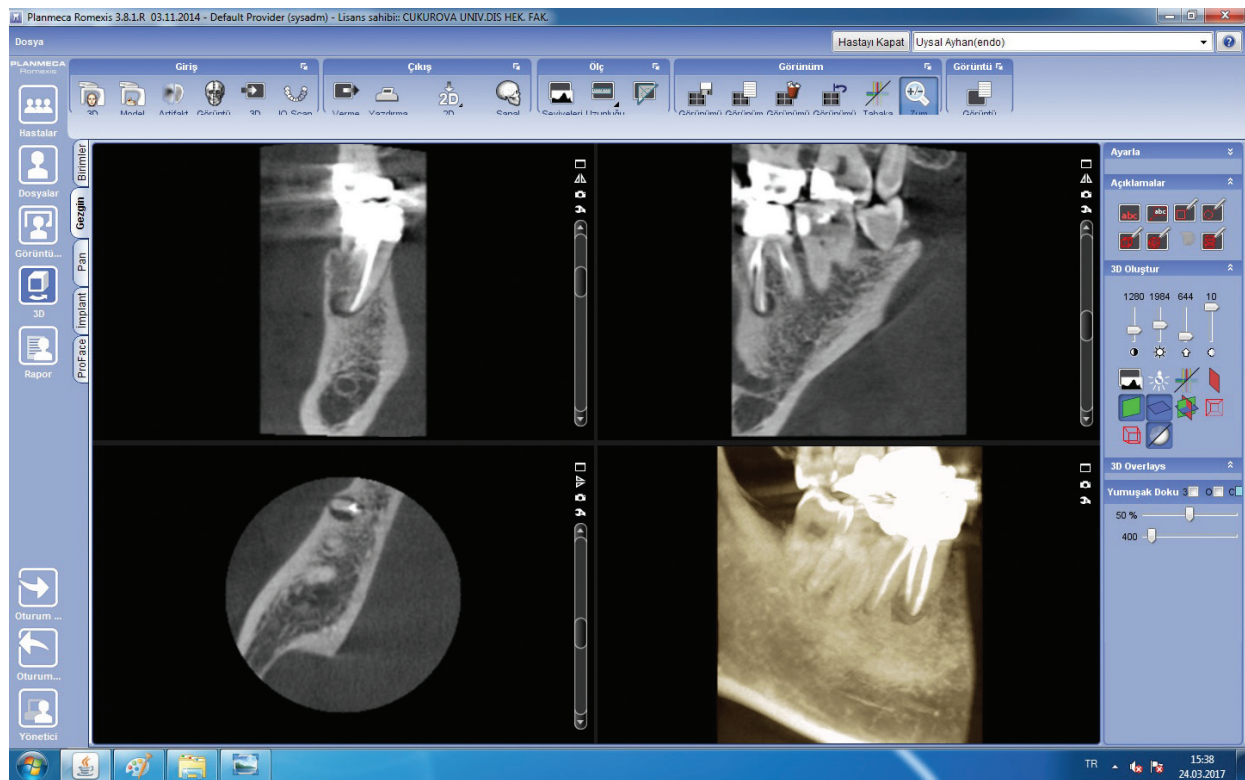

Figure 20. The example of CBCT imaging acquired for detailed assessment of mandibular first molar tooth after endodontic treatment.

In conclusion, according to the contemporary literature, the decision to perform a CBCT examination in endodontics should be kept in limited due to its low accuracy in diagnosis. However, utilization of CBCT may give more benefits in planning endodontic surgery.

3.5. Otolaryngology

Depending on the FOV used, CBCT images may show partial or the entire nasal cavity, paranasal sinuses, airway, cervical vertebrae, and temporal bone. In fact, specific ear, nose, and throat imaging programs have been increasingly included in CBCT systems, suggesting that CBCT may at some point entirely replace medical CT imaging in certain otolaryngology-related applications [64]. In terms of otolaryngology, CBCT imaging can be used to assess airway, paranasal sinus pathologies, nasal polyps, temporal and frontal bone anatomy, middle ear, and cochlear implantation [9, 65–68]. As an imaging guidance, CBCT can be used to treat lymphatic leakage after thyroidectomy [69]. The CBCT-based percutaneous image-guided technique may provide mini invasivity and identification of the anatomy and site of the leakage. An example of CBCT imaging used for detailed assessment of maxillary sinus volume is shown in **Figure 21**.

3.6. Forensic medicine

One of the contemporary application fields of CBCT for maxillofacial imaging is forensic medicine. Age estimation of individuals is an important aspect of forensic science. The CBCT can also be used as new method of age estimation by measuring the pulp-to-tooth area ratio

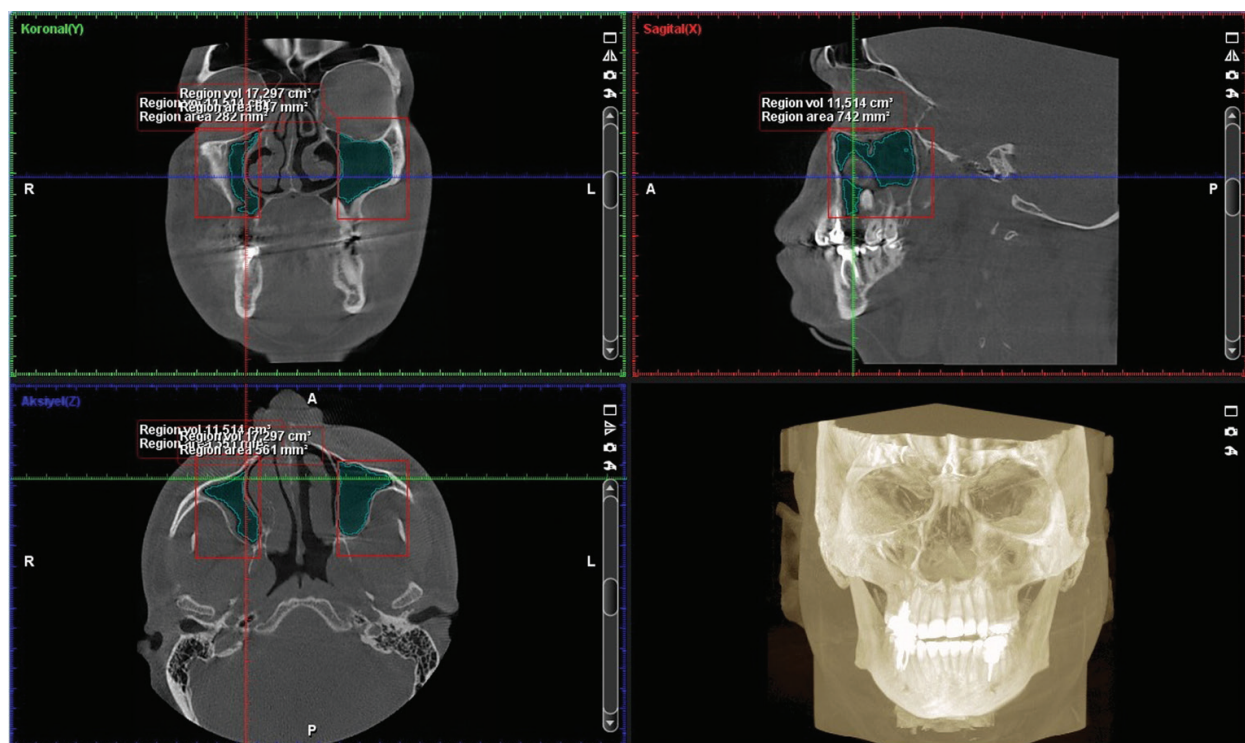


Figure 21. An example of CBCT imaging showing measurement of maxillary sinus volume.

in 3D images in living individuals [70, 71]. The forensic age estimation can also be performed using CBCT-derived analysis of spheno-occipital synchondrosis [72].

Moreover, the CBCT-derived anthropometric measurements on mandibular images can be used for sex estimation in forensic settings [73]. Besides age and sex estimation, CBCT can be used in forensic science for identification of unknown human bodies through frontal sinus 3D superimposition technique [74].

4. Conclusion

In the present chapter, a review of literature related to the clinical applications of CBCT technique for oral and maxillofacial imaging was undertaken with illustrated sample cases. Tremendous advancements have been acquired after the introduction of CBCT imaging technology especially for oral and maxillofacial practice. The contributions of CBCT for maxillofacial imaging have been demonstrated in several studies for diagnosis, treatment planning, evaluation of treatment outcome, and research purposes. The widespread use of CBCT in maxillofacial region represents the most important advance in diagnostic radiology without disadvantages of multi-slice CT especially including high radiation dose and increased cost. In most of the cases in OMF region, CBCT takes the place of multi-slice CT. Dentists and clinicians dealing with this field should have the knowledge of working principles, requirements, appropriate indications, clinical benefits, drawbacks, and hazardous effects of CBCT technology for proper utilization. In literature, there were inconsistencies and discrepancies about the CBCT device settings, properties, radiation doses, image acquisition protocol, and estimation of bone density which confuse the readers. The most common clinical applications of CBCT were in OMF surgery including implantology and impacted teeth. The subjective image quality was higher in multi-slice CT than in older CBCT units. However, the recent CBCT units showed opposite results. Moreover, new CBCT units with flat panel detectors seem to be less prone to metal artifacts. The CBCT provides less radiation than multi-slice CT but more than panoramic X-ray. Thus, it is crucial that the ALARA principle ("As Low As Reasonably Achievable" radiation dose) should be respected.

Author details

Ufuk Tatli^{1*} and Burcu Evlice²

*Address all correspondence to: dr.ufuktatli@gmail.com

1 Department of Oral and Maxillofacial Surgery, Faculty of Dentistry, Çukurova University, Adana, Turkey

2 Department of Oral and Maxillofacial Radiology, Faculty of Dentistry, Çukurova University, Adana, Turkey

References

- [1] Brenner DJ, Hall EJ. Computed tomography—An increasing source of radiation exposure. *The New England Journal of Medicine*. 2007;**357**:2277-2284. DOI: 10.1056/NEJMr072149
- [2] Hatcher DC, Dial C, Mayorga C. Cone beam CT for pre-surgical assessment of implant sites. *Journal of the California Dental Association*. 2003;**31**:825-833
- [3] Arai Y, Tammisalo E, Iwai K, Hashimoto K, Shinoda K. Development of a compact computed tomographic apparatus for dental use. *Dentomaxillofacial Radiology*. 1999;**28**:245-248. DOI: 10.1038/sj/dmfr/4600448
- [4] Mozzo P, Procacci C, Tacconi A, Martini PT, Andreis IA. A new volumetric CT machine for dental imaging based on the cone-beam technique: Preliminary results. *European Radiology*. 1998;**8**:1558-1564
- [5] Scarfe WC, Farman AG. Cone beam computed tomography. In: White SC, Pharoah MJ, editors. *Oral Radiology: Principles and Interpretation*. 6th ed. St. Louis: Mosby Elsevier; 2009. pp. 225-243
- [6] Scarfe WC, Farman AG. What is cone-beam CT and how does it work? *Dental Clinics of North America*. 2008;**52**:707-730. DOI: 10.1016/j.cden.2008.05.005
- [7] White SC, Pharoah MJ. The evolution and application of dental maxillofacial imaging modalities. *Dental Clinics of North America*. 2008;**52**:689-705. DOI: 10.1016/j.cden.2008.05.006
- [8] Pauwels R, Araki K, Siewerdsen JH, Thongvigitmanee SS. Technical aspects of dental CBCT: State of the art. *Dentomaxillofacial Radiology*. 2015;**44**:20140224. DOI: 10.1259/dmfr.20140224
- [9] De Vos W, Casselman J, Swennen GR. Cone-beam computerized tomography (CBCT) imaging of the oral and maxillofacial region: A systematic review of the literature. *International Journal of Oral and Maxillofacial Surgery*. 2009;**38**:609-625. DOI: 10.1016/j.ijom.2009.02.028
- [10] Akarslan ZZ, Peker I. Advances in radiographic techniques used in dentistry. In: Viridi MS, editor. *Emerging Trends in Oral Health Sciences and Dentistry*. Rijeka: InTech; 2015. pp. 763-799. DOI: 10.5772/59129
- [11] Machado GL. CBCT imaging—A boon to orthodontics. *The Saudi Dental Journal*. 2015;**27**:12-21. DOI: 10.1016/j.sdentj.2014.08.004
- [12] Isoda K, Ayukawa Y, Tsukiyama Y, Sogo M, Matsushita Y, Koyano K. Relationship between the bone density estimated by cone-beam computed tomography and the primary stability of dental implants. *Clinical Oral Implants Research*. 2012;**23**:832-836. DOI: 10.1111/j.1600-0501.2011.02203.x

- [13] Kamburoğlu K. Use of dentomaxillofacial cone beam computed tomography in dentistry. *World Journal of Radiology*. 2015;7:128-130. DOI: 10.4329/wjr.v7.i6.128
- [14] Tyndall DA, Price JB, Tetradis S, Ganz SD, Hildebolt C, Scarfe WC, American Academy of Oral and Maxillofacial Radiology. Position statement of the American Academy of Oral and Maxillofacial Radiology on selection criteria for the use of radiology in dental implantology with emphasis on cone beam computed tomography. *Oral Surgery, Oral Medicine, Oral Pathology and Oral Radiology*. 2012;113:817-826. DOI: 10.1016/j.oooo.2012.03.005
- [15] Holberg C, Steinhäuser S, Geis P, Rudzki-Janson I. Cone-beam computed tomography in orthodontics: Benefits and limitations. *Journal of Orofacial Orthopedics*. 2005;66:434-444. DOI: 10.1007/s00056-005-0519-z
- [16] Hashimoto K, Kawashima S, Kameoka S, Akiyama Y, Honjo T, Ejima K, Sawada K. Comparison of image validity between cone beam computed tomography for dental use and multidetector row helical computed tomography. *Dentomaxillofacial Radiology*. 2007;36:465-471. DOI: 10.1259/dmfr/22818643
- [17] Schulze D, Heiland M, Thurmann H, Adam G. Radiation exposure during midfacial imaging using 4- and 16-slice computed tomography, cone beam computed tomography systems and conventional radiography. *Dentomaxillofacial Radiology*. 2004;33:83-86. DOI: 10.1259/dmfr/28403350
- [18] Oztunç H, Evlice B, Tatlı U, Evlice A. Cone-beam computed tomographic evaluation of styloid process: A retrospective study of 208 patients with orofacial pain. *Head & Face Medicine*. 2014;10:5. DOI: 10.1186/1746-160X-10-5
- [19] Orhan K, Kusakci Seker B, Aksoy S, Bayindir H, Berberoğlu A, Seker E. Cone beam CT evaluation of maxillary sinus septa prevalence, height, location and morphology in children and an adult population. *Medical Principles and Practice*. 2013;22:47-53. DOI: 10.1159/000339849
- [20] Sinanoglu A, Orhan K, Kursun S, Inceoglu B, Oztas B. Evaluation of optic canal and surrounding structures using cone beam computed tomography: Considerations for maxillofacial surgery. *The Journal of Craniofacial Surgery*. 2016;27:1327-1330. DOI: 10.1097/SCS.0000000000002726
- [21] Erdogan Ö, Uçar Y, Tatlı U, Sert M, Benlidayı ME, Evlice B. A clinical prospective study on alveolar bone augmentation and dental implant success in patients with type 2 diabetes. *Clinical Oral Implants Research*. 2015;26:1267-1275. DOI: 10.1111/clr.12450
- [22] Turkyilmaz I, Sennerby L, McGlumphy EA, Tözüm TF. Biomechanical aspects of primary implant stability: A human cadaver study. *Clinical Implant Dentistry and Related Research*. 2009;11:113-119. DOI: 10.1111/j.1708-8208.2008.00097.x
- [23] Farré-Pagés N, Augé-Castro ML, Alaejos-Algarra F, Mareque-Bueno J, Ferrés-Padró E, Hernández-Alfaro F. Relation between bone density and primary implant stability. *Medicina Oral Patologia Oral y Cirugia Bucal*. 2011;16:e62-e67. DOI: 10.4317/medoral.16.e62

- [24] Naitoh M, Hirukawa A, Katsumata A, Ariji E. Evaluation of voxel values in mandibular cancellous bone: Relationship between cone-beam computed tomography and multislice helical computed tomography. *Clinical Oral Implants Research*. 2009;**20**:503-506. DOI: 10.1111/j.1600-0501.2008.01672.x
- [25] Nomura Y, Watanabe H, Honda E, Kurabayashi T. Reliability of voxel values from cone-beam computed tomography for dental use in evaluating bone mineral density. *Clinical Oral Implants Research*. 2010;**21**:558-562. DOI: 10.1111/j.1600-0501.2009.01896.x
- [26] Pauwels R, Nackaerts O, Bellaiche N, Stamatakis H, Tsiklakis K, Walker A, Bosmans H, Bogaerts R, Jacobs R, Horner K. Variability of dental cone beam CT grey values for density estimations. *The British Journal of Radiology*. 2013;**86**:20120135. DOI: 10.1259/bjr.20120135
- [27] Salimov F, Tatli U, Kürkcü M, Akoğlan M, Oztunç H, Kurtoğlu C. Evaluation of relationship between preoperative bone density values derived from cone beam computed tomography and implant stability parameters: A clinical study. *Clinical Oral Implants Research*. 2014;**25**:1016-1021. DOI: 10.1111/clr.12219
- [28] Tatli U, Salimov F, Kürkcü M, Akoğlan M, Kurtoğlu C. Does cone beam computed tomography-derived bone density give predictable data about stability changes of immediately loaded implants?: A 1-year resonance frequency follow-up study. *The Journal of Craniofacial Surgery*. 2014;**25**:e293–e299. DOI: 10.1097/SCS.0000000000000727
- [29] Jawad Z, Carmichael F, Houghton N, Bates C. A review of cone beam computed tomography for the diagnosis of root resorption associated with impacted canines, introducing an innovative root resorption scale. *Oral Surgery, Oral Medicine, Oral Pathology and Oral Radiology*. 2016;**122**:765-771. DOI: 10.1016/j.oooo.2016.08.015
- [30] Subramanian G, Kalyoussef E, Blitz-Goldstein M, Guerrero J, Ghesani N, Quek SY. Identifying MRONJ-affected bone with digital fusion of functional imaging (FI) and cone-beam computed tomography (CBCT): Case reports and hypothesis. *Oral Surgery, Oral Medicine, Oral Pathology and Oral Radiology*. 2017;**123**:e106–e116. DOI: 10.1016/j.oooo.2016.11.007
- [31] Johari M, Ghavimi MA, Mahmoudian H, Javadrashid R, Mirakhor Samani S, Fouladi DF. A comparable study of the diagnostic performance of orbital ultrasonography and CBCT in patients with suspected orbital floor fractures. *Dentomaxillofacial Radiology*. DOI: 10.1259/dmfr.20150311
- [32] Thor A. Preoperative planning of virtual osteotomies followed by fabrication of patient specific reconstruction plate for secondary correction and fixation of displaced bilateral mandibular body fracture. *Craniofacial Trauma and Reconstruction*. 2016;**9**:188-194. DOI: 10.1055/s-0036-1572492
- [33] Veldhoen S, Schöllchen M, Hanken H, Precht C, Henes FO, Schön G, Nagel HD, Schumacher U, Heiland M, Adam G, Regier M. Performance of cone-beam computed tomography and multidetector computed tomography in diagnostic imaging of the mid-face: A comparative study on phantom and cadaver head scans. *European Radiology*. 2017;**27**:790-800. DOI: 10.1007/s00330-016-4387-2

- [34] Peltola EM, Mäkelä T, Haapamäki V, Suomalainen A, Leikola J, Koskinen SK, Kortnesniemi M, Koivikko MP. CT of facial fracture fixation: An experimental study of artefact reducing methods. *Dentomaxillofacial Radiology*. 2017;**46**:20160261. DOI: 10.1259/dmfr.20160261
- [35] Honda K, Bjørnland T. Image-guided puncture technique for the superior temporomandibular joint space: Value of cone beam computed tomography (CBCT). *Oral Surgery, Oral Medicine, Oral Pathology, Oral Radiology and Endodontics*. 2006;**102**:281-286. DOI: 10.1016/j.tripleo.2005.10.042
- [36] Benlidayi ME, Tatli U, Kurkcu M, Uzel A, Oztunc H. Comparison of bovine-derived hydroxyapatite and autogenous bone for secondary alveolar bone grafting in patients with alveolar clefts. *Journal of Oral and Maxillofacial Surgery*. 2012;**70**:e95–e102. DOI: 10.1016/j.joms.2011.08.041
- [37] Gander T, Bredell M, Eliades T, Rücker M, Essig H. Splintless orthognathic surgery: A novel technique using patient-specific implants (PSI). *Journal of Craniomaxillofacial Surgery*. 2015;**43**:319-322. DOI: 10.1016/j.jcms.2014.12.003
- [38] Holm M, Jost-Brinkmann PG, Mah J, Bumann A. Bone thickness of the anterior palate for orthodontic miniscrews. *The Angle Orthodontist*. 2016;**86**:826-831. DOI: 10.2319/091515-622.1
- [39] Tozlu M, Germeç Cakan D, Ulkur F, Ozdemir F. Maxillary buccal cortical plate inclination at mini-screw insertion sites. *The Angle Orthodontist*. 2015;**85**:868-873. DOI: 10.2319/070914-480.1
- [40] Kwon SY, Kim Y, Ahn HW, Kim KB, Chung KR, Kim Sunny SH. Computer-aided designing and manufacturing of lingual fixed orthodontic appliance using 2D/3D registration software and rapid prototyping. *International Journal of Dentistry*. 2014;**2014**:164164. DOI: 10.1155/2014/164164
- [41] Wriedt S, Jaklin J, Al-Nawas B, Wehrbein H. Impacted upper canines: Examination and treatment proposal based on 3D versus 2D diagnosis. *Journal of Orofacial Orthopedics*. 2012;**73**:28-40. DOI: 10.1007/s00056-011-0058-8
- [42] Cevdanes LH, Heymann G, Cornelis MA, DeClerck HJ, Tulloch JF. Superimposition of 3-dimensional cone-beam computed tomography models of growing patients. *American Journal of Orthodontics and Dentofacial Orthopedics*. 2009;**136**:94-99. DOI: 10.1016/j.ajodo.2009.01.018
- [43] Almeida RC, Cevdanes LH, Carvalho FA, Motta AT, Almeida MA, Styner M, Turvey T, Proffit WR, Phillips C. Soft tissue response to mandibular advancement using 3D CBCT scanning. *International Journal of Oral and Maxillofacial Surgery*. 2011;**40**:353-359. DOI: 10.1016/j.ijom.2010.11.018
- [44] van Vlijmen OJ, Bergé SJ, Swennen GR, Bronkhorst EM, Katsaros C, Kuijpers-Jagtman AM. Comparison of cephalometric radiographs obtained from cone-beam computed tomography scans and conventional radiographs. *Journal of Oral and Maxillofacial Surgery*. 2009;**67**:92-97. DOI: 10.1016/j.joms.2008.04.025

- [45] Joshi V, Yamaguchi T, Matsuda Y, Kaneko N, Maki K, Okano T. Skeletal maturity assessment with the use of cone-beam computerized tomography. *Oral Surgery, Oral Medicine, Oral Pathology and Oral Radiology*. 2012;**113**:841-849. DOI: 10.1016/j.oooo.2011.11.018
- [46] Vizzotto MB, Liedke GS, Delamare EL, Silveira HD, Dutra V, Silveira HE. A comparative study of lateral cephalograms and cone-beam computed tomographic images in upper airway assessment. *European Journal of Orthodontics*. 2012;**34**:390-393. DOI: 10.1093/ejo/cjr012
- [47] Ogawa T, Enciso R, Shintaku WH, Clark GT. Evaluation of cross-section airway configuration of obstructive sleep apnea. *Oral Surgery, Oral Medicine, Oral Pathology, Oral Radiology and Endodontics*. 2007;**103**:102-108. DOI: 10.1016/j.tripleo.2006.06.008
- [48] Cossellu G, Biagi R, Sarcina M, Mortellaro C, Farronato G. Three-dimensional evaluation of upper airway in patients with obstructive sleep apnea syndrome during oral appliance therapy. *The Journal of Craniofacial Surgery*. 2015;**26**:745-748. DOI: 10.1097/SCS.0000000000001538
- [49] Zimmerman JN, Lee J, Pliska BT. Reliability of upper pharyngeal airway assessment using dental CBCT: A systematic review. *European Journal of Orthodontics*. DOI: 10.1093/ejo/cjw079
- [50] Acar B, Kamburoğlu K. Use of cone beam computed tomography in periodontology. *World Journal of Radiology*. 2014;**6**:139-147. DOI: 10.4329/wjr.v6.i5.139
- [51] Bayat S, Talaeipour AR, Sarlati F. Detection of simulated periodontal defects using cone-beam CT and digital intraoral radiography. *Dentomaxillofacial Radiology*. DOI: 10.1259/dmfr.20160030
- [52] Walter C, Kaner D, Berndt DC, Weiger R, Zitzmann NU. Three-dimensional imaging as a pre-operative tool in decision making for furcation surgery. *Journal of Clinical Periodontology*. 2009;**36**:250-257. DOI: 10.1111/j.1600-051X.2008.01367.x
- [53] Ozturan S, Oztunc H, Keles Evlice B. Assessment of the soft tissue volumetric changes following acellular dermal matrix grafts with cone beam computerized tomography. *Quintessence International*. 2015;**46**:171-178. DOI: 10.3290/j.qi.a32826
- [54] Pinheiro LR, Scarfe WC, Augusto de Oliveira Sales M, Gaia BF, Cortes AR, Cavalcanti MG. Effect of cone-beam computed tomography field of view and acquisition frame on the detection of chemically simulated peri-implant bone loss in vitro. *Journal of Periodontology*. 2015;**86**:1159-1165. DOI: 10.1902/jop.2015.150223
- [55] Golubovic V, Mihatovic I, Becker J, Schwarz F. Accuracy of cone-beam computed tomography to assess the configuration and extent of ligature-induced peri-implantitis defects. A pilot study. *Oral and Maxillofacial Surgery*. 2012;**16**:349-354. DOI: 10.1007/s10006-012-0320-2
- [56] Kühl S, Zürcher S, Zitzmann NU, Filippi A, Payer M, Dagassan-Berndt D. Detection of peri-implant bone defects with different radiographic techniques—A human cadaver study. *Clinical Oral Implants Research*. 2016;**27**:529-534. DOI: 10.1111/clr.12619

- [57] Kamburoğlu K, Yılmaz F, Gulsahi K, Gulen O, Gulsahi A. Change in periapical lesion and adjacent mucosal thickening dimensions one year after endodontic treatment: Volumetric cone-beam computed tomography assessment. *Journal of Endodontics*. 2017;**43**:218-224. DOI: 10.1016/j.joen.2016.10.023
- [58] Tyndall DA, Kohltfarber H. Application of cone beam volumetric tomography in endodontics. *Australian Dental Journal*. 2012;**57**:72-81. DOI: 10.1111/j.1834-7819.2011.01654.x
- [59] Saberi E, Mollashahi NF, Movasagh Z, Moghaddam AA, Mohammadi A. Value of CBCT in vertical root fracture detection in endodontically-treated teeth. *Minerva Stomatologica*. 2017;**66**:69-74. DOI: 10.23736/S0026-4970.17.03972-3
- [60] Haghaniifar S, Moudi E, Mesgarani A, Bijani A, Abbaszadeh N. A comparative study of cone-beam computed tomography and digital periapical radiography in detecting mandibular molars root perforations. *Imaging Science in Dentistry*. 2014;**44**:115-119. DOI: 10.5624/isd.2014.44.2.115
- [61] Ramos Brito AC, Verner FS, Junqueira RB, Yamasaki MC, Queiroz PM, Freitas DQ, Oliveira-Santos C. Detection of fractured endodontic instruments in root canals: Comparison between different digital radiography systems and cone-beam computed tomography. *Journal of Endodontics*. 2017;**43**:544-549. DOI: 10.1016/j.joen.2016.11.017
- [62] Kurt SN, Üstün Y, Erdogan Ö, Evlice B, Yoldas O, Öztunc H. Outcomes of periradicular surgery of maxillary first molars using a vestibular approach: A prospective, clinical study with one year of follow-up. *Journal of Oral and Maxillofacial Surgery*. 2014;**72**:1049-1061. DOI: 10.1016/j.joms.2014.02.004
- [63] Low KM, Dula K, Bürgin W, von Arx T. Comparison of periapical radiography and limited cone-beam tomography in posterior maxillary teeth referred for apical surgery. *Journal of Endodontics*. 2008;**34**:557-562. DOI: 10.1016/j.joen.2008.02.022
- [64] Miracle AC, Mukherji SK. Conebeam CT of the head and neck, part 2: Clinical applications. *American Journal of Neuroradiology*. 2009;**30**:1285-1292. DOI: 10.3174/ajnr.A1654
- [65] Güldner C, Diogo I, Leicht J, Mandapathil M, Wilhelm T, Teymoortash A, Jahns E. Reduction of radiation dosage in visualization of paranasal sinuses in daily routine. *International Journal of Otolaryngology*. 2017;**2017**:3104736. DOI: 10.1155/2017/3104736
- [66] Güldner C, Diogo I, Bernd E, Dräger S, Mandapathil M, Teymoortash A, Negm H, Wilhelm T. Visualization of anatomy in normal and pathologic middle ears by cone beam CT. *European Archives of Oto-Rhino-Laryngology*. 2017;**274**:737-742. DOI: 10.1007/s00405-016-4345-2
- [67] Razafindranaly V, Truy E, Pialat JB, Martinon A, Bourhis M, Boublay N, Faure F, Ltaïef-Boudrigua A. Cone beam CT versus multislice CT: Radiologic diagnostic agreement in the postoperative assessment of cochlear implantation. *Otology & Neurotology*. 2016;**37**:1246-1254. DOI: 10.1097/MAO.0000000000001165

- [68] Al Abduwani J, ZilinSkienne L, Colley S, Ahmed S. Cone beam CT paranasal sinuses versus standard multidetector and low dose multidetector CT studies. *American Journal of Otolaryngology*. 2016;**37**:59-64. DOI: 10.1016/j.amjoto.2015.08.002
- [69] Ierardi AM, Pappalardo V, Liu X, Wu CW, Anuwong A, Kim HY, Liu R, Lavazza M, Inversini D, Coppola A, Floridi C, Boni L, Carrafiello G, Dionigi G. Usefulness of CBCT and guidance software for percutaneous embolization of a lymphatic leakage after thyroidectomy for cancer. *Gland Surgery*. 2016;**5**:633-638. DOI: 10.21037/gs.2016.12.13
- [70] Rai A, Acharya AB, Naikmasur VG. Age estimation by pulp-to-tooth area ratio using cone-beam computed tomography: A preliminary analysis. *Journal of Forensic Dental Sciences*. 2016;**8**:150-154. DOI: 10.4103/0975-1475.195118
- [71] Pinchi V, Pradella F, Buti J, Baldinotti C, Focardi M, Norelli GA. A new age estimation procedure based on the 3D CBCT study of the pulp cavity and hard tissues of the teeth for forensic purposes: A pilot study. *Journal of Forensic and Legal Medicine*. 2015;**36**:150-157. DOI: 10.1016/j.jflm.2015.09.015
- [72] Sinanoglu A, Kocasarac HD, Noujeim M. Age estimation by an analysis of sphenoccipital synchondrosis using cone-beam computed tomography. *Legal Medicine (Tokyo, Japan)*. 2016;**18**:13-19. DOI: 10.1016/j.legalmed.2015.11.004
- [73] Gamba Tde O, Alves MC, Haiter-Neto F. Mandibular sexual dimorphism analysis in CBCT scans. *Journal of Forensic and Legal Medicine*. 2016;**38**:106-110. DOI: 10.1016/j.jflm.2015.11.024
- [74] Beaini TL, Duailibi-Neto EF, Chilvarquer I, Melani RF. Human identification through frontal sinus 3D superimposition: Pilot study with Cone Beam Computer Tomography. *Journal of Forensic and Legal Medicine*. 2015;**36**:63-69. DOI: 10.1016/j.jflm.2015.09.003

