Chapter 3

Anatomic Origin and Molecular Genetics in Neuroblastoma

Murat Tosun, Hamit Selim Karabekir, Mehmet Ozan Durmaz, Harun Muayad Said, Yasemin Soysal and Nuket Gocmen Mas

Additional information is available at the end of the chapter

http://dx.doi.org/10.5772/intechopen.69568

Abstract

Neuroblastoma is considered as the most common extracranial solid tumor occurring during childhood, but takes place rarely after the age of 10 years. The tumors are considered as embryonal tumors that result from the fetal or early postnatal life development and are formed from neural crest-derived cells, and their origination is from the early nerve cells which are called as neuroblasts of sympathetic nervous system. Being heterogeneous in their biological, genetic, and morphological characteristics, tumors which are distinct from other solid tumors due to their biological heterogeneity result in the clinical pattern changes from spontaneous regression to a highly aggressive metastatic disease. Neuroblastoma tumorigenesis is regulated by Myc oncogene, leading to aggressive tumor subset. Many epigenetic factors play crucial role in the disease induction and development, while regulatory effect and outcome result in epigenetic patterns distinguishing neuroectoderm, neural crest, and more mature neural states. Neuroblastoma patients' clinical management is based on prognostic categories subtracted from studies correlating outcome and clinico-biological variables. Neuroblastoma anatomic boundaries include primarily autonomic nervous system besides other rare locations. Neuroblastoma molecular pathogenesis classifies the tumor according to the different clinical behaviors that are important for the improvement of the patients outcome and overall survival according to the different therapy modalities applied.

Keywords: neuroblastoma, anatomy, clinic, genetics

1. Introduction

Neuroblastoma is the most common extracranial solid tumor in childhood; moreover, it is very rare after age of 10 years. They are regarded as embryonal tumors developed during fetal or

early postnatal life and arise from the immature or dedifferentiated neural crest-derived cells. It is important to understand that they originate from the early nerve cells which are called as neuroblasts of the sympathetic nervous system, so they can be found anywhere along this system.

The system includes sympathetic trunk and ganglia, adrenal medulla, and also an aggregation of cells called as paraganglion [1].

2. The autonomic nervous system

The autonomic nervous system (ANS) is a part of peripheral nervous system, and under the control of the central nervous system, it governs many involuntary processes of the body such as heart rate, vascular tone, glandular activity, digestive motility, and others. It has two main contents as the sympathetic (thoracolumbar—from T1 to L2) and parasympathetic (craniosacral—from S2 to S4 and parasympathetic cranial nerves) systems. These two main systems contain both preganglionic and postganglionic neurons which are governed by hypothalamus. Posterior part of the hypothalamus is related to the sympathetic system [1–4]. Sympathetic nervous system starts to develop from the neural crest cells, and anterior part of the neural tube of the thoracic region migrates on either side of the spinal cord, toward the region behind the dorsal aorta about week 5 of embryogenesis. Some of them leave neural tube in order to arrange along the motor root [5, 6]. Mammalian neural crest cells are multipotent cells and originate from ectoderm. It has been accepted as the fourth layer of embryo for some researcher, because of their contribution to the cellular diversity in vertebrates. During embryological development, neural crest cells migrate from neural tube and differentiate into different structures including adrenomedullary cells and sympathetic neurons in adrenergic system. The ganglia cells of the thoracic region migrate during 5th week of development. Neural crest cells forming sympathetic ganglia also migrate both cranially and caudally and extend these trunks into cervical and pelvic regions. The migration and localization of neural crest cells are controlled by bone morphogenetic proteins (BMP) secreted by dorsal aorta [7–9].

3. Gross anatomy of sympathetic trunk and ganglia

The sympathetic ganglia together with the suprarenal (adrenal) medulla and chromaffin cells of paraganglia are derived from the sympathoadrenal linage cells. From the suprarenal medulla, these cells differentiate into a number of types consisting of small and intermediate-sized neuroblasts and sympathoblasts and larger, initial rounded phechromocytoblasts. Large cells harboring pale nuclei might be the progenitors of chromaffin cells. These cells secrete either adrenaline (epinephrine) or noradrenaline (norepinephrine), while the intermediate-sized neuroblasts differentiate into the typical multipolar postganglionic symphatic

neurons, and secrete only noradrenaline while paraganglia, situated near, on the surface of, or embedded in, the capsules of the ganglia of the sympathetic chain, or in some of the large autonomic plexuses which are cell masses called paraganglion [10–12].

The sympathetic system consists of two ganglionated trunks together with their branches, plexuses, and subsidiary ganglia, while the sympathetic ganglia include sympathetic trunk cell aggregations in the autonomic plexuses and intermediate ganglia while the plexuses contain dispersed preganglionic cells (**Figure 1**).

Trunks ganglia correspond numerically to the dorsal spinal roots ganglia, while adjoining ganglia may fuse in man and there are rarely more than 22 or 23 and sometimes fewer. Subsidiary ganglia in the major autonomic plexuses (e.g., coeliac, superior mesenteric ganglia, etc.) are trunks ganglia derivates [13–20].

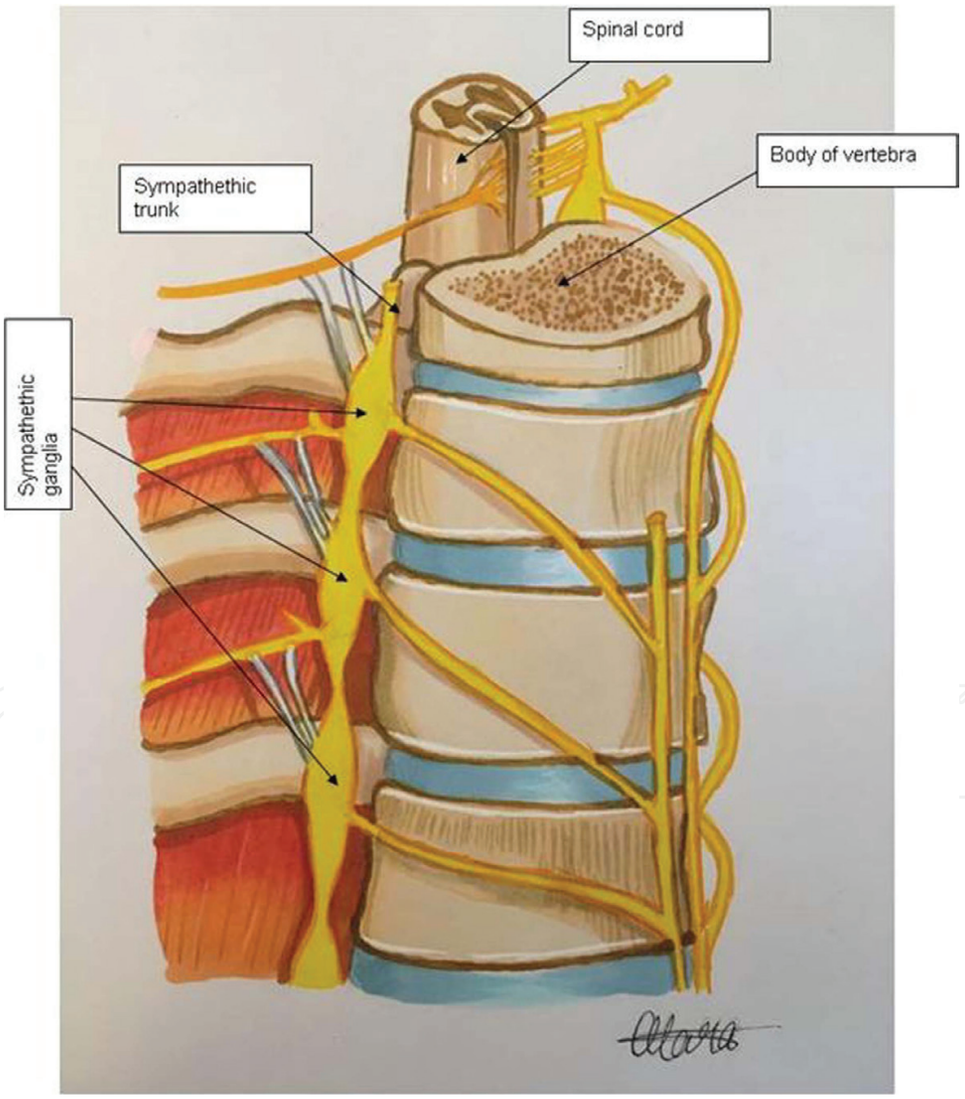

Figure 1. Components of the sympathetic trunk. Redrawn from Wolf-Heidegger's Atlas of Human Anatomy.

The sympathetic trunk is positioned just laterally to the vertebral bodies for the entire vertebral column length and interacts with the spinal nerves anterior rami via rami communicantes. The sympathetic trunk allows the sympathetic nervous system including the preganglionic fibers to ascend to spinal levels superior to T1 and descend to spinal levels inferior to L2/3. The sympathetic trunk ganglion returns to the spinal nerve of preganglionic origin via gray ramus comminicans, while the higher end was continuing via the carotid canal forming at the end a plexus located at the internal carotid artery and on the other hand the lower parts move before the coccyx and at this position it merges with the other ganglion impar basal structures. Paravertebral ganglia are sympathetic ganglia along the length of the sympathetic trunk which is a sympathetic nervous system and also a basal part of the autonomic nervous system. It enables nerve fibers to extend toward the spinal nerves located at a superior position as well as inferior position to those they were emanated from. We have here also to mention that various nerves like a high percentage of the splanchnic nerves emerge directly from this trunks [14–20].

3.1. Embryology of sympathetic trunk

Mammalian neural crest cells are multipotent cells originating from the ectoderm. They represent the fourth layer of embryo because of their contribution to the cellular diversity in vertebrates [21–23]. During embryological development, neural crest cells migrate from neural tube and differentiate into different structures including both the adrenomedullary cells and the sympathetic neurons in the adrenergic system (**Table 1**). Also, the thoracic region ganglia cells migrate at the end of 5th week of development [22]. Neural crest cells forming the sympathetic ganglia also migrate both cranially and caudally and extend these trunks into cervical and pelvic regions. Bone morphogenetic proteins (BMP) secreted by dorsal aorta norepinephrine produced by notochord control neural crest cell migration and localization, while at the same time and molecular level, Wnt/β-catenin-related Gbx2 homeobox gene deactivation is essential for the neural crest development [22, 23].

3.2. Histology of sympathetic ganglia

The nervous system anatomically divides into two parts which are both the central and the peripheral nervous systems, and at the same time, it was functionally divided into somatic and autonomic nervous systems including sympathetic and parasympathetic subdivisions. All the nervous system was built from two main structures, namely the neurons and glial cells in intercellular matrix. Neurons differ in their type being bipolar, pseudounipolar or motor, while three types of glial cells can be seen in the neural matrix including all of the astrocytes, oligodendroglia and microglia [24, 25]. All neurons have two main processes, axon and dendrites, and two of them form an extremely dense connecting network and where all the processes make synapses with each other [24, 25]. The signals from central neurons are transported from presynaptic membrane to postsynaptic membrane via neurotransmitters such as serotonin, dopamine, acetylcholine, epinephrine (E) [adrenalin (A)] and norepinephrine (NE) [noradrenaline (NA)] [24, 25]. One of the main differences between neuron functions

Neural Crest	
Cranial Neural Crest Cell	Trunk Neural Crest Cell
- Diencephalic Neural Crest Cell - Mesencephalic Neural Crest Cell - Rhomboencephalic Neural Crest Cell - Cardiac Neural Crest Cell	- Chromaffin cells in adrenal medula - Dorsal Root Ganglia - Epidermal pigment cells (Melanocytes) - Satellite Glial Cells - Tooth Papilae - Corneal endothelium and stroma - Sympathetic neurons - Vagal Neural Crest Cells - Calcitonin Secreting Cells - Carotid body type I Cells - Multipolar neurons in sympathetic ganglion

Table 1. Structures formed from the neural crest cell differentiation.

is which kind of neurotransmitters being secreted for signal transmission in synaptic space. In adrenergic neurons, E and NE are named as catecholamines, while dopamine is the main neurotransmitter synthesized from tyrosine NE and serves as a transmitter between axons and effectors in autonomic nervous system [24]. Neurons using NE as a neurotransmitter are adrenergic neurons. Epinephrine is secreted by some both the central nervous system cells and the endocrine chromaffin cells in the adrenal medulla [24, 25].

3.3. Genetics and clinical characteristics

It has been shown in Ref. [26] that both the dicer and miRNAs are required for the survival of neural crest-derived tissues by preventing apoptosis during differentiation because the dicer was essential for the differentiation process related to the neural crest cells survival, while neuronal crest needs specific hdac1 function during its development as shown in a series of zebrafish experiment [27]. In the trunk region, the ventrally migrating neural crest cells move through the somitic mesenchyme in a segmented pattern, presumably setting the basis for the sensory and sympathetic ganglia metameric organization along the anterior-posterior axis later in development [28].

When grafting experiments were performed, a specific migratory behavior of the cells was observed which was under the control of the cellular microenvironment endowed by both the surrounding mesenchymal cells and the extra cellular matrix (ECM). Also, the posterior sclerotome which represents a nonpermissive tissues generative barriers for the movement of

the neuronal crest cells is formed together with the perinotochordal region and, transiently, the tissue located below the dorsolateral ectoderm [29–31]. Neural crest cells reorganize as they migrate; formation of iterated, discrete sympathetic ganglia is not the direct result of patterned crest cell migration through the somites, and the chain formation is a common configuration adopted by migrating cells in the developing nervous system [32]. Also it has been shown in [33] that the parasympathetic neurons originate from nerve-associated peripheral glial progenitors besides that the development of noradrenergic neurons in the hindbrain medulla and in the sympathetic nervous system depends on retinoic acid signaling in addition to the fact that the mount Blanc mutation disrupts the development of noradrenergic centers in the CNS and of sympathetic ganglia [34, 35].

4. Adrenal medulla

The adrenal glands also develop from neural crest ectoderm and intermediate mesoderm. While the medulla originated from neural crest cells migrating from sympathetic ganglion, adrenal cortex develops from intermediate mesoderm. During the 5th week of development, proliferating mesothelium-derived cells infiltrate the retroperitoneal mesenchyme at the cranial end of the mesonephros and give rise to the primitive adrenal cortex. Further, a second layer of proliferated cells surrounds the primitive cortex and, as a consequence, forms the future adult adrenal cortex. At the 7th week of development, the mesothelial cells are invaded at its medial region by neural crest-derived chromaffinoblast cells. These cells differentiate into two kinds of chromaffin cells of the adrenal medulla which renders homologous to a diffuse sympathetic ganglion without postganglionic processes, leading to complete development of the adrenal gland at the 4th month of age. Further, the fetal cortex regresses and disappears within the 1st year of life with replacement by the definitive cortex [36–45].

The cells migrating from the neural tube compose two chains of sympathetic ganglia at both sides of the vertebral column. One of them is lateral vertebral sympathetic chain that occurs from the interconnecting ganglia by longitudinal nerve fibers and the other ones: superior cervical ganglion, the middle cervical ganglion and the inferior cervical ganglion; lumbosacral region of the sympathetic ganglia occurs from the neuroblast migration and extends from thoracic region. Some of the sympathetic neuroblasts migrate further anteriorly to form preaortic ganglia as celiac and mesenteric plexuses, the visceral ganglia of the Auerbach myenteric plexus and in the Meissner submucous plexus [41–45].

4.1. Gross anatomy of adrenal medulla

For the position of the adrenal glands, they are both positioned on the two sides of the body located at the retroperitoneum slightly elevated and at medial position from the kidneys. It is a characteristic of the human adrenal glands that their shape differs according to its position, possessing a pyramidal shape for the right adrenal gland versus a larger and semilunar shape for the left adrenal glands. Adrenal gland size also differs depending on the age of the subject but in average they are 5.3 cm in size and 7–10 g in weight. The glands are yellowish in

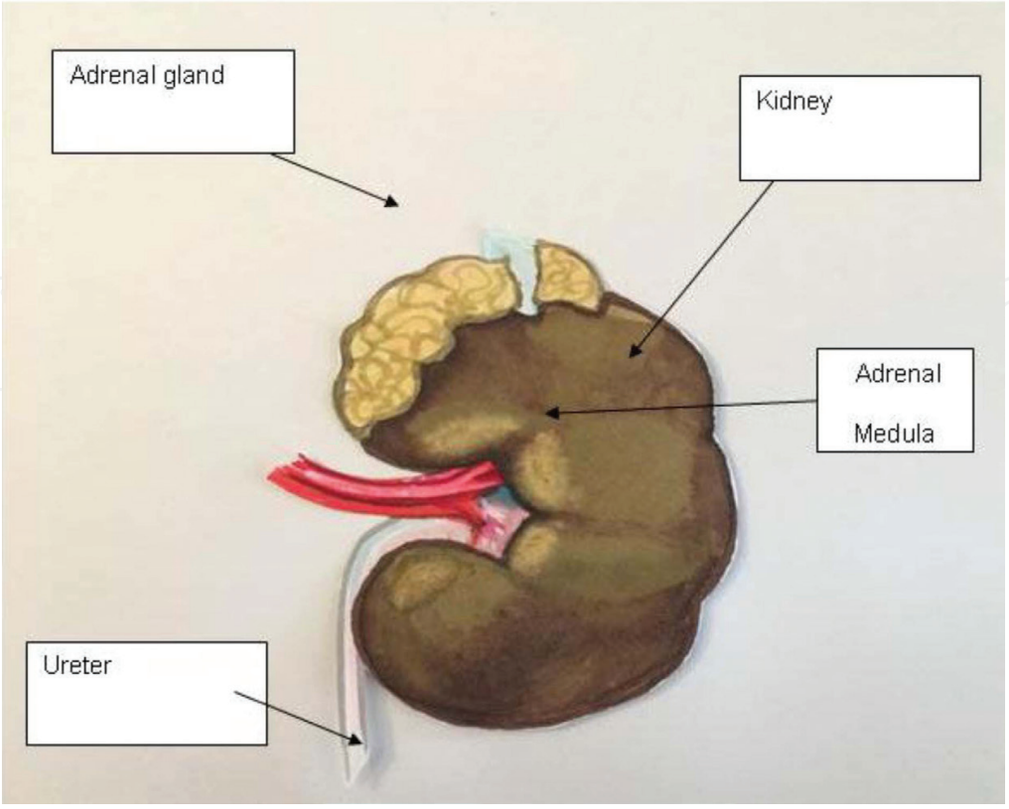

Figure 2. The components from the adrenal medulla. Redrawn from Wolf-Heidegger's Atlas of Human Anatomy.

color and surrounded by a fatty capsule and lie within the renal fascia which also surrounds the kidneys, while a weak wall of connective tissue separates the glands from the kidneys (**Figure 2**) [41–45].

The adrenal glands are positioned directly below the diaphragm and attached to the diaphragm crura by the renal fascia. The adrenal gland is consisted of two distinct parts, the outer adrenal cortex and the inner medulla, each with a unique function, but both produce hormones. The adrenal medulla is at the center of each adrenal gland and is surrounded by the adrenal cortex. The chromaffin cells of the medulla are the body's main source of the catecholamine's adrenaline and noradrenalin, released by the medulla (**Figure 3**) [41–45].

The adrenal medulla is driven by the sympathetic nervous system via preganglionic fibers originating in the thoracic spinal cord, from vertebrae T5–T11. Because it is innervated by preganglionic nerve fibers, the adrenal medulla can be considered as a specialized sympathetic ganglion. Unlike other sympathetic ganglia, however, the adrenal medulla lacks distinct synapses and releases its secretions directly into the blood [41–45]. The sympathetic nervous system through the preganglionic fibers that are originated from the thoracic spinal cord at the vertebrae T5–T11 controls the adrenal medulla, which can be considered as a specialized sympathetic ganglion due to its strengthening via the preganglionic nerve fibers. One of the characteristics of the adrenal medulla was that it differs from the sympathetic ganglion that is latching of independent synapses and its secretions are released into the blood by a direct manner [41–45]. These hormones are released by the adrenal medulla, which contains a dense

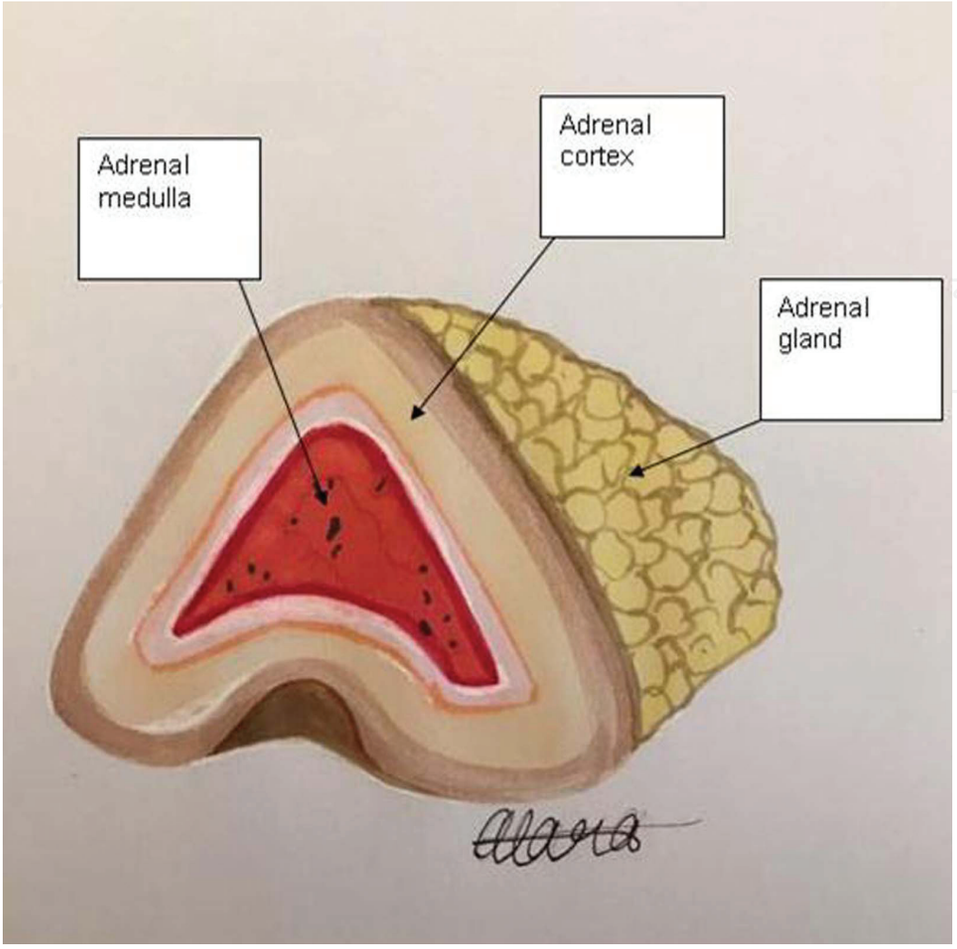

Figure 3. The components from the adrenal gland. Redrawn from Wolf-Heidegger's Atlas of Human Anatomy.

network of blood vessels. Adrenaline and noradrenaline act at adrenoreceptors throughout the body, leading to increase both the circulating blood pressure and heart beat speed also known as heart rate. There is also a phenomenon called "flight response" where both adrenalin and noradrenalin are responsible for it and this phenomenon of increasing the speed of breathing, heartbeat, and blood pressure is due to the increased blood vessel contraction in the different parts of the body [46, 47]. Catecholamines are produced in chromaffin cells in the medulla of the adrenal gland, from tyrosine, a nonessential amino acid either derived from food or produced from phenylalanine in the liver. Suprarenal medulla is composed of chromaffin cell column groups separated by wide venous sinusoids, while single and small groups of neurons occur in the medulla. Tyrosine hydroxylase converts tyrosine to L-DOPA during the initial step of catecholamine synthesis with further conversion of L-DOPA to dopamine prior to its conversion into noradrenaline. On the other hand, the enzyme phenylethanolamine N-methyltransferase (PNMT) converts noradrenaline into epinephrine and becomes stored in cytosolic granules.

Tyrosine hydroxylase and PNMT levels play an important regulative role in the catecholamines synthesis in a way that when their level increases they affect the adrenal cortex glucocorticoids that in turn stimulate the catecholamine synthesis, where the sympathetic nervous system via its activation stimulates the catecholamine release. Also, the adrenal gland

medulla is innervated by the sympathetic nervous system splanchnic nerves, where as a consequence the stimulation of the cell membrane calcium channels opening evokes the release of the catecholamines from the storage granules [41–45, 48–52]. Adrenal gland's medulla and para-aortic body tumors can cause excessive adrenaline and noradrenaline secretion, leading to palpitation attacks, excessive sweating, pallor, hypertension, headaches and retinitis and renal vascular changes as a consequence of a long persistence of the tumor [41–45].

4.2. Embryology of the adrenal gland

The adrenal glands develop from neural crest ectoderm and intermediate mesoderm. While the medulla originated from neural crest cells migrating from sympathetic ganglion, adrenal cortex was developed from the intermediate mesoderm [42]. During the 5th week of development, proliferating mesothelium-derived cells infiltrate the retroperitoneal mesenchyme at the cranial end of the mesonephros and give rise to the primitive adrenal cortex [23–25]. A second proliferation of these cells surrounds the primitive cortex and forms the future adult adrenal cortex. At the 7th week of development, neural crest-derived chromaffinoblast cells invade the mesothelial cells at its medial region [24]. These cells differentiate into chromaffin cells of the adrenal medulla. The adrenal medulla is homologous to a diffuse sympathetic ganglion without postganglionic processes [24]. At the 4th month of age, the adrenal gland is fully developed. The fetal cortex regresses and disappears within the 1st year of life and is replaced by the definitive cortex. During adrenal gland development, some transcription factors such as Wnt4 and Wnt1 have very important regularity functions [53].

4.3. Histology of adrenal gland

Histologically, the adrenal glands (**Figure 4**) have two main structures, one of which is the cortex including three substructures (**Figure 3**) and medulla (**Figure 5**). The cortex cover with capsule contains collagen and elastic fibers and has three layers, and each has different functions: the outermost, zona glomerulosa, the middle, zona fasciculata and the innermost layer, zona reticularis. Although zona glomerulosa cells produce aldosterone, zona fasciculate cells mainly produce cortisol, while zona reticularis cells synthesize androgen. Both zona fasciculata and reticularis are stimulated by adrenocorticotropic hormone (ACTH), but zona glomerulosa is primarily stimulated by angiotensin II that stimulates both zona glomerulosa and proliferation and aldosterone synthesis [24, 25]. The adrenal medulla is located in the adrenal gland center and contains the chromaffin cells, which are modified sympathetic postganglionic neurons derived from neural crest, and forms epithelioid cords surrounded by fenestrated capillaries [24]. Chromaffin cell cytoplasm contains membrane-bounded dense granules containing chromogranins, one class of catecholamine epinephrine and norepinephrine and a little dopamine. Two kinds of chromaffin cells exist in the adrenal medulla, 80% of which produce epinephrine and 20% of which produce norepinephrine that is stored in granules with a dense eccentric core, while epinephrine contains granules that are smaller and occupy less dense central core, whereas all circulating epinephrine produced by adrenal medulla, norepinephrine produces both adrenal medulla and postganglionic sympathetic neurons, but we have to mention here that adrenal cortex cells do not store their steroid hormones in granules [24, 25].

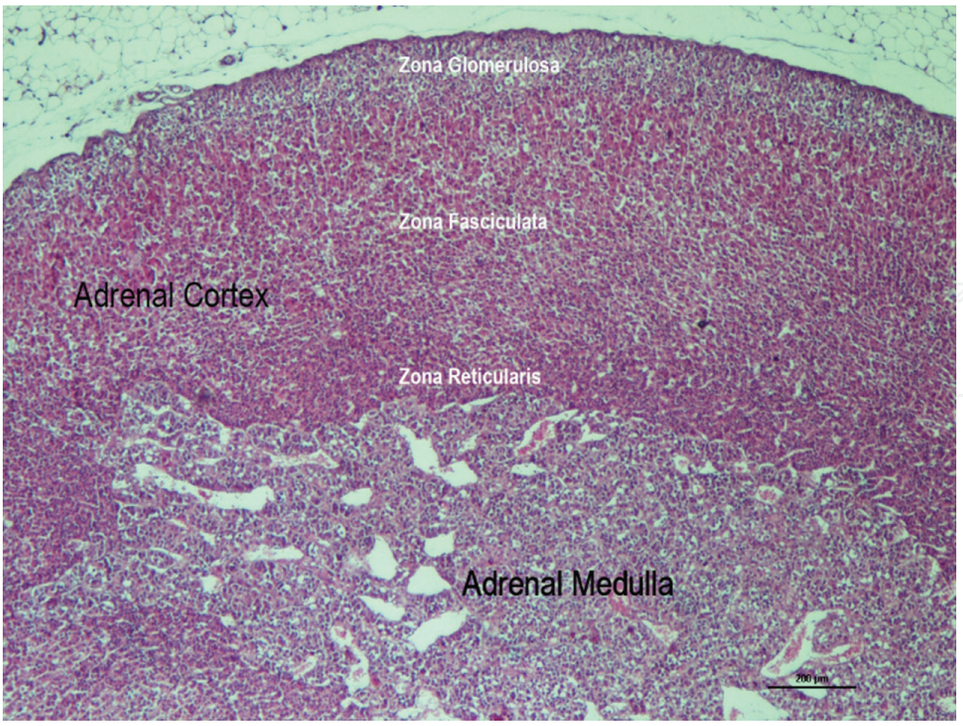

Figure 4. General microscopic view of the adrenal gland. Hematoxylin-eosin staining. 400× (image recorded and edited by Murat TOSUN MD PhD).

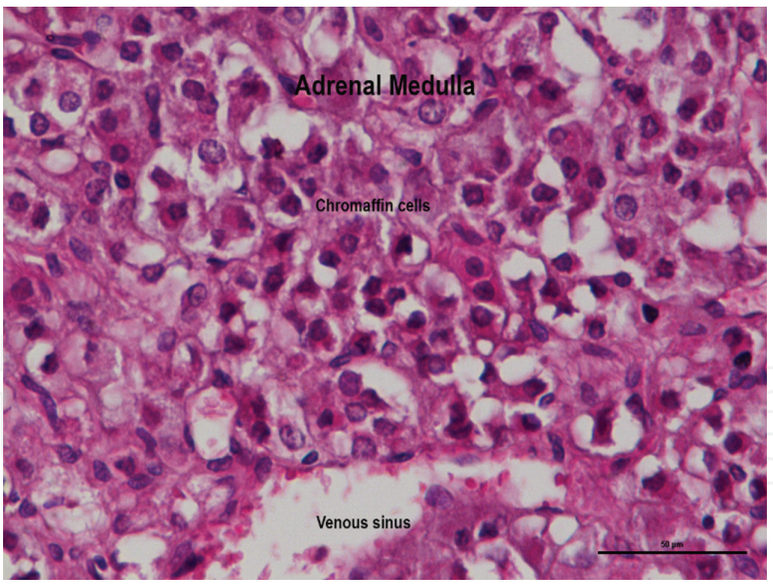

Figure 5. Microscopic view of the adrenal medulla. Hematoxylin-eosin. 400× (image recorded and edited by Murat TOSUN MD PhD).

The adrenal medulla is composed of groups and columns of chromaffin cells (phaeochromocytes) separated by wide venous sinusoids and supported by a network of reticular fibers. Chromaffin cells bear the name as a result of their response to the use of dichromate fixative during the fixation process. Structurally and functionally, they are comparable to the postganglionic sympathetic neurons being at the same time a member of the neuroendocrine system.

Since they are derived from the neuronal crest, they produce, store before release and release different hormones into the venous sinusoids which are catecholamines, noradrenalin (or as mentioned in other references norepinephrines) or adrenaline. The synthesis, storage and release of these hormones are under the control of the sympathetic nervous system precisely by the sympathetic neurons where the preganglion and their sympathetic neurons are shown as a single appearance or as a small group located at the medulla. When the noradrenaline-secreting cells are rarely present, they possess bigger sized granules having a dense eccentric kernel [5, 6, 54–56]. Normally, cells differ in their hormone secretion manner. While some cells secret only hormone, others are secreting two hormones. Catecholamines together with enkephalins represent opiate like proteins that are under certain conditions pached by the chromogranin proteins. The cells that are formed here are shown as large cells possessing a large nuclei with a cytoplasmic region that is faintly granular and basophilic ahead the venous sinusoids and in a single-lined alignment. The sympathetic axon terminals are forming synapses together with the chromaffin cells where these synapses are positioned locations opposite and distant to the sinusoids. These sinusoids in turn are arranged via a branched construct of cells called the fenestrated endothelium and elapse to both the central medullar vein and the Hilary suprarenal vein, while according to the knowledge available until now the suprarenal medulla presence and function do not represent a necessity for life activities [57, 58].

Further, we have here to address that the scientific community should concentrate their research efforts to study the different aspects of the adrenal medulla since the information available about it is restricted and the availability of it can help to unravel many unknown points about the development of this disease.

4.4. Genetic and clinical investigations of adrenal medulla

For the establishment of genetic parameters of neuroblastomas, continuous scientific efforts were necessary [59]. In molecular and genetic analysis, different pathology-related findings were possible. One research group was able to prove experimentally that activated ALK collaborates with MYCN during neuroblastoma pathogenesis where they used the Zebrafish model that was able to help them proving that neuroblastomas arise in MYCN expressing transgenic Zebrafish and showing the MYCN-induced loss of sympathoadrenal cells; the absence of expression of early sympathoadrenal markers was absent in MYCN transgenic embryos during early development; MYCN expression causes sympathoadrenal cell loss and the role of the activated ALK in the disease onset acceleration and increases the penetrance of MYCN-induced neuroblastoma [60]. Experimentally, the direct role of dopamine in the generation and/or expansion of mitochondrial DNA deletions in dopaminergic neurons was proven unraveling more knowledge about the Parkinson's disease pathogenesis, showing here the mitochondrial DNA deletions accumulation role and representing the missing link between aging and Parkinson's disease, while the catecholaminergic adrenal medulla is the preferential location of mitochondrial DNA deletions [61]. Also in another experimental setup, gene expression profiling helped to identify eleven DNA repair genes downregulated during mouse neural crest cell migration process [62]. Radiotherapy, chemotherapy and surgery are only suitable for neuroblastomas treatment but MIBG (metaiodobenzylguanidine) application, and nuclear medicine has a dual function aiding in diagnosis as well as its function as

a treatment modality, but immunological methods like the application of a monoclonal antibody and proved to be more effective and promising when applied at early stages [63–65].

5. Paraganglion

5.1. Gross anatomy, embryology and histology of the paraganglion

Paraganglia are extrasuprarenal chromaffin tissue aggregations that distribute (near to/within) the automatic nervous system. This type of paraganglia cells also occurs in the sympathetic ganglia of various viscera as well as in variety of retroperitoneal and mediastinal sites; all of these cells synthesize and store catecholamines and are derived from the neural crest, and their function is defined by their position. Being a remainder source of neuroendocrine secretion, intraneuronal cells are functioning as interneurons. In suprarenal medulla, chemical stimuli are responsible for catecholamine release, while the role of the neuronal stimuli is neglectable regarding to this functional detail. Within the fetus, the extrasuprarenal chromaffin tissue is representing the main repository of catecholamine where within this regard the suprarenal medulla plays no role due to the fact of being immature.

However, many paraganglia are well vascularized and their secretory cells are usually close to one or more fenestrated capillaries. Most like the suprarenal medullary chromaffin cells, they have a sympathetic innervation and thereby act as endocrine organs [1]. Para-aortic bodies and coccygeal body (glomus coccygeum) are paraganglia which include chromaffin cells and produce adrenaline and noradrenaline. Para-aortic bodies place on lateral side of abdominal aorta and usually united anterior to it by a horizontal mass immediately above the inferior mesenteric artery [13].

5.2. Coccygeal body

The coccygeal glomus (coccygeal gland or body also it is referred as the Luschka's coccygeal body by others) represents a vestigial structure situated either in front of or immediately below the coccyx tip that is situated near the ganglion impar in the pelvis in addition to another position near the median sacral artery termination [66]. Its diameter is 2.5 mm and has an irregular oval shape; several smaller nodules are found around or near the main mass and consist of irregular masses of round or polyhedral cells or epithelioid cells, forming a group around a dilated sinusoidal capillary vessel [66–68].

Each cell includes a large round or oval nucleus and the protoplasm surrounding the nucleus which is clear, and not stained when chromic salts are applied; therefore, it is not considered as a part of chromaffin system, the system which includes cells stained by chromic salts and consists of renal medulla, paraganglia and para-aortic bodies [66–68]. Clinically, the coccygeal body looks like a glomus tumor, thereby causing problems in the diagnosis that can lead to misinterpretations [69–71].

Paraganglia are extrasuprarenal aggregations of chromaffin tissue, distributed near to or within the autonomic nervous system. This type of cells also occurs in the sympathetic ganglia

of various viscera and in a variety of retroperitoneal and mediastinal sites. All of these cells are derived from the neural crest, and all of them synthesize and store catecholamines. Also, their function depends on the way and site they are positioned; several cells role is functioning as interneurons, while in other cases, there are cells existing that are functioning in another manner within this context by acting as a source for the neuroendocrine secretion. In the coccygeal bodies, chemical inducers are responsible of the paraganglionic release of catecholamines. The period of the paraganglion existence in human is different, while their regulating factors and mechanisms are still not completely understood, and a population of them keep present until adulthood mostly as a microscopic paraganglia with its later degeneration [36–40].

6. Para-aortic bodies

The para-aortic bodies are chromaffin tissue condensations found closely to the aortic autonomic plexuses and lumbar sympathetic chains. In the fetus, they are at the largest size but later become relatively smaller in childhood and disappear at the beginning of the adulthood. Mostly, their presence of existence is as a pair of bodies positioned within intermesenteric, inferior mesenteric and hypogastric plexus anterolaterally to the aorta. They can be elevated at the celiac plexus or bounded below at the hypogastric plexus of the pelvis, or can be nearby the sympathetic ganglia of the lumbar chain. Scattered cells, which persist into adulthood, may rarely be the chromaffin tissue tumor development sites (phaeochromocytoma); these scattered cells are much more commonly found arising from the suprarenal medulla cells. The wide variation in the persistent para-aortic body tissue site accounts for the range of locations of such tumors [54, 55, 72].

7. Experimental treatment of neuroblastoma cells: *in vitro*

During a series of experiments conducted that aimed to evaluate cytotoxic effects of melatonin (MLT) which is an endogen hormone and 13-*cis* retinoic acid (13-*cis*-RA) also named as isotretinoin a vitamin A analogue on neuroblastoma SH-SY5Y cell line by our research group [73]. We found that treatment of neuroblastoma cells with melatonin resulted into a cytotoxic effect in a way where in cell culture the cells were exposed to different doses of MLT and 13-*cis*-RA for either 24 or 48 h. While the viabilities were estimated with MTT cell viability assay test, apoptotic indexes were calculated after staining with TUNEL-based apoptosis determination. We observed the effective cytotoxic potential on neuroblastoma cell line which MLT l poses which was higher than the one 13-*cis*-RA. At the same time, when MLT and 13-*cis*-RA were combined, the obtained effect was potentiated. On the other hand, it was found that the effect of 13-*cis*-RA individually was very slight. Results gathered from the current study have indicated that MLT exhibited neurotoxic effect on SH-SY5Y neuroblastoma cell line and this effect was potentiated by 13-*cis*-RA.

As a consequence, we believe that administration of these agents in neuroblastoma patient treatment may contribute to obtain outcomes that bear potential for the design of innovative treatment modalities, leading to the successful treatment of this type of diseases, with taking

in account the necessity of *in vivo* studies based on these results that clearly determine the dose range necessary. It is expected that the results of them can improve the currently applied treatment modalities applied against neuroblastomas to be more successful.

8. Conclusions

Neuroblastoma is the most common extracranial solid tumor occurring during childhood till the age of 10 when it might occur rarely. Many epigenetic factors play a crucial role in the disease induction and development of neuroblastoma, while the regulatory effect and outcome resulting into epigenetic patterns is well known but needs further study. Different research efforts were made by various research groups to study this type of disease from the different levels, where some results like neuroblastoma treatment with melatonin was one positive example, while the study of the adrenal medulla needs to be more intensified by the scientific community since the understanding of its different regulatory aspects can be one target for the optimization of the treatment methods applied against this disease.

Acknowledgements

The authors would like to thank the Dokuz Eylul University and the Afyon Kocatepe University for their kind support. Also, we would like to thank Ms. Alara Karabekir for the graphic design. Finally, we also would like to thank Assoc. Prof. Dr Nilüfer Yonguc from the Dokuz Eylül University and Mr Ali Ege Mas from the Near Eastern University, Cyprus, for technical support during the different stages of the research.

Author details

Murat Tosun[1]*, Hamit Selim Karabekir[2], Mehmet Ozan Durmaz[3], Harun Muayad Said[4], Yasemin Soysal[4] and Nuket Gocmen Mas[5]

*Address all correspondence to: murat_tosun@yahoo.com

1 Department of Histology and Embryology, Faculty of Medicine, Afyon Kocatepe University, Afyonkarahisar, Turkey

2 Department of Neurosurgery, Faculty of Medicine, Dokuz Eylul University, Izmir, Turkey

3 Department of Neurosurgery, Bozyaka Education and Research Hospital, Health Science University, Izmir, Turkey

4 Department of Molecular Medicine, Graduate Institute of Health Science, Dokuz Eylul University, Izmir, Turkey

5 Department of Anatomy, Faculty of Medicine, Dokuz Eylul University, Izmir, Turkey

References

[1] Standring S. Gray's Anatomy. 39th ed. Elsevier, Churchill Livingstone, London 2005. pp. 419-430

[2] McCorry LK. Physiology of the autonomic nervous system. American Journal of Pharmaceutical Education. 2007;**71**(4):78

[3] Shields RW Jr. Functional anatomy of the autonomic nervous system. Journal of Clinical Neurophysiology. 1993;**10**(1):2-13

[4] Amann JF, Constantinescu GM. The anatomy of the visceral and autonomic nervous systems. Seminars in Veterinary Medicine and Surgery (Small Animal). 1990;**5**(1):4-11

[5] Selleck MA, Bronner-Fraser M. Origins of the avian neural crest: The role of neural plate-epidermal interactions. Development. 1995;**121**(2):525-538

[6] Thorogood P. Review of developmental and evolutionary aspects of the neural crest. Trends in Neurosciences. 1989;**12**:38-39

[7] Bhatt S, Diaz R, Trainor PA. Signals and switches in mammalian neural crest cell differentiation. Cold Spring Harbor Perspectives in Biology. 2013;**5**(2):a008326. DOI: 10.1101/cshperspect.a008326

[8] Motohashi T, Watanabe N, Nishioka M, et al. Gene array analysis of neural crest cells identifies transcription factors necessary for direct conversion of embryonic fibroblasts into neural crest cells. Biology Open. 2016;**5**(3):311-322. DOI: 10.1242/bio.015735

[9] Simões-Costa M, Bronner ME. Establishing neural crest identity: A gene regulatory recipe. Development. 2015;**142**(2):242-257. DOI: 10.1242/dev.105445

[10] Morrison SF, Cao WH. Different adrenal sympathetic preganglionic neurons regulate epinephrine and norepinephrine secretion. American Journal of Physiology. Regulatory, Integrative and Comparative Physiology. 2000;**279**(5):R1763-R1775

[11] Rubin RP, Miele E. A study of the differential secretion of epinephrine and norepinephrine from the perfused cat adrenal gland. Journal of Pharmacology and Experimental Therapeutics. 1968;**164**(1):115-121

[12] Standring S. Gray's Anatomy. 39th ed. Elsevir Churchill Livingstone, London; 2005. pp. 181-182, 254-255

[13] Standring S. Gray's Anatomy. 38th ed. Churchill Livingstone, London; 1995. pp. 1905-1906

[14] Mader SS. Human Biology. New York: McGraw-Hill; 2000. ISBN: 0-07-290584-0; ISBN: 0-07-117940-2

[15] Pritchard TE, Alloway D. Medical Neuroscience. FL, United States: Hayes Barton Press; 1999. ISBN: 978-1-59377-200 0. Available from: https://books.google.com/books/about/Medical_neuroscience.html?id=m7Y80PcFHtsC

[16] Butler AB, Hodos W. Comparative Vertebrate Neuroanatomy: Evolution and Adaptation. Hoboken, NJ, US: Wiley-Blackwell; 2005. ISBN: 978-0-471-21005-4

[17] Hall JE, Guyton AC. Textbook of Medical Physiology. 11th ed. St. Louis, MO: Elsevier Saunders; 2006. ISBN: 0-7216-0240-1

[18] Warrell DA, Cox TM, Firth JD. The Oxford Textbook of Medicine. 5th ed. Philadelphia, Pennsylvania, US: Oxford University Press; 2010

[19] Greenstein B, Greenstein A. Color Atlas of Neuroscience: Neuroanatomy and Neurophysiology. Stuttgart, New York: Thieme; 2002. ISBN: 9783131081711

[20] Moore KL, Agur AMR. Essential Clinical Anatomy. 2nd ed. Philadelphia, Pennsylvania, US: Lippincott Williams & Wilkins. 2002. p. 199. ISBN: 978-0-7817-5940-3

[21] Gilbert SF. The cranial neural crest. In: Developmental Biology. 6th ed. Sinauer Associates. Bookshelf ID: NBK10065, Oxford, UK: Oxford University Press, ISBN-10: 0-87893-243-7

[22] Moore KL, Persaud TVN, Torchia MG. Development of suprarenal glands. In: The Developing Human: Clinically Oriented Embryology. 9th ed. Elsevier Saunders, Philadelphia, 2012

[23] Carlson BM. Neural crest. In: Human Embryology and Developmental Biology. 5th ed. Carlson BM. Elsevier Saunders, Philadelphia, 2014

[24] Kiezenbaum AL, Tres LL. Adrenal gland. In: Histology and Cell: An Introduction to Pathology. 3rd ed. Elsevier Saunders, Philadelphia, 2012

[25] Abrahamsohn I, Dos Santos MF, Tenario Zorn TM. Endocrine glands. In: Basic Histology (Text & Atlas). 11th ed. McGraw Hill: NY, USA 2005

[26] Zehir A, Hua LL, Maska EL, Morikawa Y, Cserjesi P. Dicer is required for survival of differentiating neural crest cells. Developmental Biology. 2010;**340**(2):459-467. DOI: 10.1016/j.ydbio.2010.01.039

[27] Ignatius MS, Unal Eroglu A, Malireddy S, Gallagher G, Nambiar RM, Henion PD. Distinct functional and temporal requirements for zebrafish Hdac1 during neural crest-derived craniofacial and peripheral neuron development. PLoS One. 2013;**8**(5):e63218. DOI: 10.1371/journal.pone.0063218

[28] Krull CE. Segmental organization of neural crest migration. Mechanisms of Development. 2001;**105**:37-45

[29] Bronner-Fraser M, Stern C. Effects of mesodermal tissues on avian neural crest cell migration. Developmental Biology. 1991;**143**:213-217

[30] Pettway Z, Guillory G, Bronner-Fraser M. Absence of neural crest cells from the region surrounding implanted notochords in situ. Developmental Biology. 1990;**142**:335-345

[31] Erickson CA, Duong TD, Tosney KW. Descriptive and experimental analysis of the dispersion of neural crest cells along the dorsolateral path and their entry into ectoderm in the chick embryo. Developmental Biology. 1992;**151**(1):251-272

[32] Kasemeier-Kulesa JC, Kulesa PM, Lefcort F. Imaging neural crest cell dynamics during formation of dorsal root ganglia and sympathetic ganglia. Development. 2005;**132**(2):235-245. DOI: 10.1242/dev.01553

[33] Dyachuk V, Furlan A, Shahidi MK, Giovenco M, Kaukua N, Konstantinidou C, Pachnis V, Memic F, Marklund U, Müller T, Birchmeier C, Fried K, Ernfors P, Adameyko I. Neurodevelopment. Parasympathetic neurons originate from nerve-associated peripheral glial progenitors. Science. 2014;**345**(6192):82-87. DOI: 10.1126/science.1253281

[34] Holzschuh J, Barrallo-Gimeno A, Ettl AK, Durr K, Knapik EW, Driever W. Noradrenergic neurons in the zebrafish hindbrain are induced by retinoic acid and require tfap2a for expression of the neurotransmitter phenotype. Development. 2003;**130**(23):5741-5754

[35] Holzschuh J, Hauptmann G, Driever W. Genetic analysis of the roles of Hh, FGF8, and nodal signaling during catecholaminergic system development in the zebrafish brain. Journal of Neuroscience. 2003;**23**(13):55. DOI: 10.1242/dev.00816

[36] Zhang S, Su Y, Gao J, Zhang C, Tanaka H. A potential inhibitory function of draxin in regulating mouse trunk neural crest migration. In Vitro Cellular & Developmental Biology-Animal. 2017;**53**(1):43-53. DOI: 10.1007/s11626-016-0079-0

[37] Ezin M, Barembaum M, Bronner ME. Stage-dependent plasticity of the anterior neural folds to form neural crest. Differentiation. 2014;**88**(2-3):42-50. DOI: 10.1016/j.diff.2014.09.003

[38] Serralbo O, Marcelle C. Migrating cells mediate long-range WNT signaling. Development. 2014;**141**(10):2057-2063. DOI: 10.1242/dev.107656

[39] Ridenour DA, McLennan R, Teddy JM, Semerad CL, Haug JS, Kulesa PM. The neural crest cell cycle is related to phases of migration in the head. Development. 2014;**141**(5):1095-1103. DOI: 10.1242/dev.098855

[40] Shyamala K, Yanduri S, Girish HC, Murgod S. Neural crest: The fourth germ layer. Journal of Oral and Maxillofacial Pathology. 2015;**19**(2):221-229. DOI: 10.4103/0973-029X.164536

[41] Thomas P. Endocrine Gland Development and Disease. Burlington: Elsevier Science. Academic Press, Cambridge, Massachusetts, US, 2013. p. 241. ISBN: 9780123914545

[42] Moore KL, Dalley AF, Agur AM. Clinically Oriented Anatomy. 7th ed. Philadelphia, Pennsylvania, US: Lippincott Williams & Wilkins; 2013. pp. 294-298. ISBN: 978-1-4511-8447-1

[43] Kay SM, Flageole H. Adrenal Glands. Medscape, 2015. http://emedicine.medscape.com/article/940347-overview [Accessed: August 1, 2015]

[44] Dunn, R. B.; Kudrath, W.; Passo, S.S.; Wilson, L.B. (2011). "10". Kaplan USMLE Step 1 Physiology Lecture Notes. pp. 263-289.endothelial cells: roles of PPAR alpha and NF-kappaB.Vascul Pharmacol. **48**(2-3): 76-84

[45] Sapru HN, Siegel A. Essential Neuroscience. Hagerstown, MD: Lippincott Williams & Wilkins; 2007. ISBN: 0-7817-9121-9

[46] Goldstein DS, Kopin IJ. Evolution of concepts of stress. Stress. 2007;**10**(2):109-120. DOI: 10.1080/10253890701288935

[47] Weems CF, Silverman WK. An integrative model of control: Implications for understanding emotion regulation and dysregulation in childhood anxiety. Journal of Affective Disorders. 2006;**91**(2-3):113-124. DOI: 10.1016/j.jad.2006.01.009

[48] Melmed S, Polonsky KS, Larsen PR, Kronenberg HM. Williams Textbook of Endocrinology. 12th ed. London, UK: Saunders; 2011. ISBN: 978-1437703245

[49] Whitehead SA, Nussey S. Endocrinology: An Integrated Approach. Oxford: BIOS; 2001. p. 122. ISBN: 1-85996-252-1

[50] Colledge NR, Walker BR, Ralston SH, editors. Davidson's Principles and Practice of Medicine. Illustrated by Robert Britton. 21st ed. Edinburgh: Churchill Livingstone/Elsevier; 2010. pp. 768-778. ISBN: 978-0-7020-3085-7

[51] Henry G, Alan JF, Daniel R. Psychology. 6th ed. NY, US: W. W. Norton & Company; 2004. ISBN: 0-393-97767-6

[52] García AG, García de Diego AM, Gandía L, Borges R, García Sancho J. Calcium signaling and exocytosis in adrenal chromaffin cells. Physiological Reviews. 2006;**86**(4):1093-1131. DOI: 10.1152/physrev.00039.2005. PMID: 17015485

[53] Schoenwolf GC, Belyl SB, Brauer PR, Francis-West PH. Development of suprarenal gland. In: Larsen's Human Embryology. 4th ed. Churchill Livingstone, 2008, eBook ISBN: 9780323286190, eBook ISBN: 9781437700909, eBook ISBN: 9780323240116; 2009

[54] Coupland RE, Kent C, Kent SE. Normal function of extra-adrenal chromaffin tissues in the young rabbit and guinea-pig. Journal of Endocrinology. 1982;**92**(3):433-442

[55] Galan-Rodriguez B, del-Marco A, Flores JA, Ramiro-Fuentes S, Gonzalez-Aparicio R, Tunez I, Tasset I, Fernandez-Espejo E. Grafts of extra-adrenal chromaffin cells as aggregates show better survival rate and regenerative effects on Parkinsonian rats than dispersed cell grafts. Neurobiology of Disease. 2008;**29**(3):529-542. DOI: 10.1016/j.nbd.2007.11.009

[56] Unsicker K, Zwarg U, Habura O. Electron microscopic evidence for the formation of synapses and synaptoid contacts in adrenal medullary grafts. Brain Research. 1977;**120**(3):533-539

[57] Hoshi N, Hitomi J, Kusakabe T, Fukuda T, Hirota M, Suzuki T. Distinct morphological and immunohistochemical features and different growth rates among four human neuroblastomas heterotransplanted into nude mice. Medical Molecular Morphology. 2008;**41**(3):151-159. DOI: 10.1007/s00795-008-0407-x

[58] Hirose T, Kannuki S, Nishida K, Matsumoto K, Sano T, Hizawa K. Anaplastic ganglioglioma of the brain stem demonstrating active neurosecretory features of neoplastic neuronal cells. Acta Neuropathologica. 1992;**83**(4):365-370

[59] Bilke S, Chen QR, Westerman F, Schwab M, Catchpoole D, Khan J. Inferring a tumor progression model for neuroblastoma from genomic data. Journal of Clinical Oncology. 2005;**23**(29):7322-7331. DOI: 10.1200/JCO.2005.03.2821. [Epub: September 6, 2005]

[60] Zhu S, Lee JS, Guo F, Shin J, Perez-Atayde AR, Kutok JL, Rodig SJ, Neuberg DS, Helman D, Feng H, Stewart RA, Wang W, George RE, Kanki JP, Look AT. Activated ALK collaborates with MYCN in neuroblastoma pathogenesis. Cancer Cell. 2012;**21**(3):362-373. DOI: 10.1016/j.ccr.2012.02.010

[61] Neuhaus JF, Baris OR, Hess S, Moser N, Schröder H, Chinta SJ, Andersen JK, Kloppenburg P, Wiesner RJ. Catecholamine metabolism drives generation of mitochondrial DNA deletions in dopaminergic neurons. Brain. 2014;**137**(Pt 2):354-365. DOI: 10.1093/brain/awt291. [Epub: October 24, 2013]

[62] Albino D, Brizzolara A, Moretti S, Falugi C, Mirisola V, Scaruffi P, Di Candia M, Truini M, Coco S, Bonassi S, Tonini GP. Gene expression profiling identifies eleven DNA repair genes down-regulated during mouse neural crest cell migration. International Journal of Developmental Biology. 2011;**55**(1):65-72. DOI: 10.1387/ijdb.092970da

[63] Cheung NV, Kushner BH, Kramer K. Monoclonal antibody based therapy of neuroblastoma. Hematology/Oncology Clinics of North America. 2001;**15**(5):853-866

[64] Saarinen UM, Coccia PF, Gerson SL, et al. Eradication of neuroblastoma cells in vitro by monoclonal antibody and human complement: Method for purging autologous bone marrow. Cancer Research. 1985;**45**(11):5969-5975

[65] Conti A, Maestroni GJ, Cosentino M, Frigo GM, Lecchini S, Marino F, Bombelli R, Ferrari M, Brivio F, Roselli MG, Lissoni P. Evidence for a neuroimmunomodulatory and a hematopoietic role of the Luschka's coccygeal body. Neuroendocrinology Letters. 2000;**21**(5):391-403

[66] Rahemtullah A, Szyfelbein K, Zembowicz A. Glomus coccygeum: Report of a case and review of the literature. American Journal of Dermatopathology. 2005;**27**(6):497-499

[67] Kim HS, Yang SH, Park HJ, Park HB, Cho HS. Glomus tumor as a cause of coccydynia. Skeletal Radiology. 2013;**42**(10):1471-1473. DOI: 10.1007/s00256-013-1654-z. [Epub: June 4, 2013]

[68] Gatalica Z, Wang L, Lucio ET, Miettinen M. Glomus coccygeum in surgical pathology specimens: Small troublemaker. Archives of Pathology and Laboratory Medicine. 1999;**123**(10):905-908

[69] Albrecht S, Zbieranowski I. Incidental glomus coccygeum. When a normal structure looks like a tumor. American Journal of Surgical Pathology. 1990;**14**(10):922-924

[70] Santos LD, Chow C, Kennerson AR. Glomus coccygeum may mimic glomus tumour. Pathology. 2002;**34**(4):339-343

[71] Vergote I, Amant F, Berteloot P, Van Gramberen M. Laparoscopic lower para-aortic staging lymphadenectomy in stage IB2, II, and III cervical cancer. International Journal of Gynecological Cancer. 2002;**12**(1):22-26

[72] Tosun M, Soysal Y, Mas NG, Karabekir HS. Comparison of the effects of 13-cis retinoic acid and melatonin on the viabilities of SH-SY5Y neuroblastoma cell line. Journal of Korean Neurosurgical Society. 2015;**57**(3):147-151. DOI: 10.3340/jkns.2015.57.3.147

[73] Köpf-Maier P. Wolf-Heidegger's Atlas of Human Anatomy. 6th ed. Karger (Berlin) Karger AG; Basel, 2005. ISBN: 978-3-8055-7667-3