

# We are IntechOpen, the world's leading publisher of Open Access books Built by scientists, for scientists

6,900

Open access books available

185,000

International authors and editors

200M

Downloads

Our authors are among the

154

Countries delivered to

TOP 1%

most cited scientists

12.2%

Contributors from top 500 universities



WEB OF SCIENCE™

Selection of our books indexed in the Book Citation Index  
in Web of Science™ Core Collection (BKCI)

Interested in publishing with us?  
Contact [book.department@intechopen.com](mailto:book.department@intechopen.com)

Numbers displayed above are based on latest data collected.  
For more information visit [www.intechopen.com](http://www.intechopen.com)



---

# Interventional Techniques for Head and Neck Cancer Pain

---

Victor M. Silva Ortíz, Guillermo E. Aréchiga Ornelas,  
José A. Flores Cantisani,  
Juan Ignacio Reyes Torres and  
Fernando Cantú Flores

Additional information is available at the end of the chapter

<http://dx.doi.org/10.5772/intechopen.69655>

---

## Abstract

One of the most feared consequences of cancer is the possibility of severe and uncontrolled pain in patients with advanced cancer. Patients with head and neck cancer (HNC) have the highest prevalence of pain among patients with cancer, and it is often one of the major reasons for seeking care. A subspecialty approach that incorporates anatomical and technical knowledge to alleviate pain through minimally invasive procedures is relatively recent. The purpose of this chapter is to present different interventional techniques which are used for the treatment of pain in HNC patients when drug treatment is unsuccessful.

**Keywords:** head, neck, cancer pain, neuropathic pain, interventional pain, pain management

---

## 1. Introduction

Interventional procedures in the treatment of head and neck cancer (HNC) pain have been proposed in the past 25 years due to the greater knowledge of the mechanisms of action of pain and its physiological and anatomical basis. There has been development of new techniques to treat refractory pain and treatment strategies with an integral view of the problem. In addition to the progress of knowledge and development of techniques and technologies, education and pain medicine certification programs have been developed around the world [1].

Pain and symptoms associated with HNC is a challenge due to the rich innervation and loss of function caused by tumor invasion or by the treatment of cancer [2].

---

Pain is the first symptom in 20–50% of patients with cancer; however, in patients with HNC, it can become as high as 85%. Of this, 93% are mixed (nociceptive and neuropathic) and 30% are neuropathic pain due to tumor involving tissues or metastatic disease. In up to 85% of patients, pain is the main cause of medical attention [3]. Compared to other types of cancer, the highest incidence of pain in patients with HNC is due to the intense innervation of anatomical structures.

Common neuropathic syndromes associated with cancer are chemotherapy-induced neuropathy, tumor invasion (leptomeningeal metastases), neuralgias (trigeminal neuralgia or postherpetic neuropathy, glossopharyngeal neuralgia), radiculopathies and plexopathies, paraneoplastic sensory neuropathies, Horner's syndrome, postsurgery neuropathies, and postradiotherapy neuropathies [4, 5].

HNC is generally a disfiguring disease. In addition, it impairs the quality of life (QOL) of patients because it interferes with speech, swallowing, and chewing, the key factors in the patient's autonomy [6].

Not all HNC patients who have pain are due to cancer. Sometimes, it occurs due to medical or surgical treatment. Some studies report cancer-related pain in 52% of the hospitalized patients, of which 50% was due to surgery and 29% directly related to the tumor [7].

One of the adverse effects associated with HNC treatment is orofacial pain. Oral mucositis is the most frequent complaint impairing the QOL of the patient. This is mediated by elevated inflammatory factors, which play a central role in the activation of cytokines, such as TNF- $\alpha$ , that is known to be involved in mediation of neuropathic pain and hyperalgesia. Combined chemotherapy and radiation therapy results in increased frequency, severity and duration of mucositis. The treatment given to patients with HNC represents an important impact on the development of pain and the magnitude of it [7, 2].

Radiotherapy is another important cause of pain in HNC, because it creates a hypoxic environment, and hypoxic nerves are more vulnerable to neuropathic pain. In long term, chronic hypoxia leads to fibrosis in perineural tissues and causes late onset neuropathic pain, even in cancer-free survivors [7, 2].

Approximately 50% of HNC patients report orofacial pain before radiation therapy, 81% during, and 70% at the completion of treatment. Thirty-six percent of HNC patients report pain after 6 months of treatment, and 30% experience pain beyond 6 months. The severity of pain varies among different disease sites and over the treatment course [8]. Pain intensity usually stays the highest during disease treatment (surgery, chemotherapy, radiotherapy) and may take 6 months or more to reach initial levels (pre-treatment).

## **2. Factors associated with head and neck cancer pain**

### **2.1. Age and gender**

Age is an important factor in pain perception, according to studies comparing age groups. The group of patients who reported pain was younger than 65 years. A higher pain scale among females were reported compared to males, however, significantly higher levels of pain

among males compared to female was reported also. There are some other factors associated with pain such as improper oral hygiene, depression, and anxiety. The presence of metallic taste was seen as a predictor of spontaneous pain.

## **2.2. Cancer-related factors**

Patients with tumors in the oral cavity have a lower QOL, as well as worse pain, compared to other sites. Patients with end-stage tumors report greater pain compared to stages I and II, as well as an increase in spontaneous pain in patients with nodal disease [8].

## **3. Interventional management for HNC patients**

Trigeminal (CNV) and facial (CNVII) nerves are by far the most frequently affected cranial nerves, alone or in combination. The predilection for these two specific nerves is explained by their wide anatomic distribution in the craniofacial territory and their rich anastomotic connections.

The supply of opioid drugs is insufficient in some countries, or not all the population has access to it; for this reason, it is necessary to have an interventional tool to manage cancer pain. There is a good evidence for the “early integration” of interventional pain treatments for carefully selected head and neck cancer patients, at the same time or even before starting strong opioids.

## **4. Sphenopalatine ganglion (SPG) block**

SPG is located within a triangular structure with a superior base called pterygopalatine fossa, which has a close relationship with the maxillary nerve and very close to the sphenopalatine foramen [9]. It is a complex neural center with multiple connections to trigeminal, facial, and sympathetic systems and consists of somatosensory, sympathetic, and parasympathetic fibers.

The ganglion is located just below the maxillary nerve and receives three nerve roots: The sensory root of the sphenopalatine branches from the maxillary nerve, the motor root from the intermediate nerve (part of the facial nerve) through the major petrosal nerve, and the sympathetic root from the internal carotid plexus.

In 1908, Sluder proposed an inflammatory reaction in the territory of pterygopalatine fossa that may be involved in certain cases of unilateral facial pain associated with rhinorrhea, lacrimation and mucosal congestion. Ruskin later described the blocking technique with local anesthetic to treat a variety of conditions associated with headache [10].

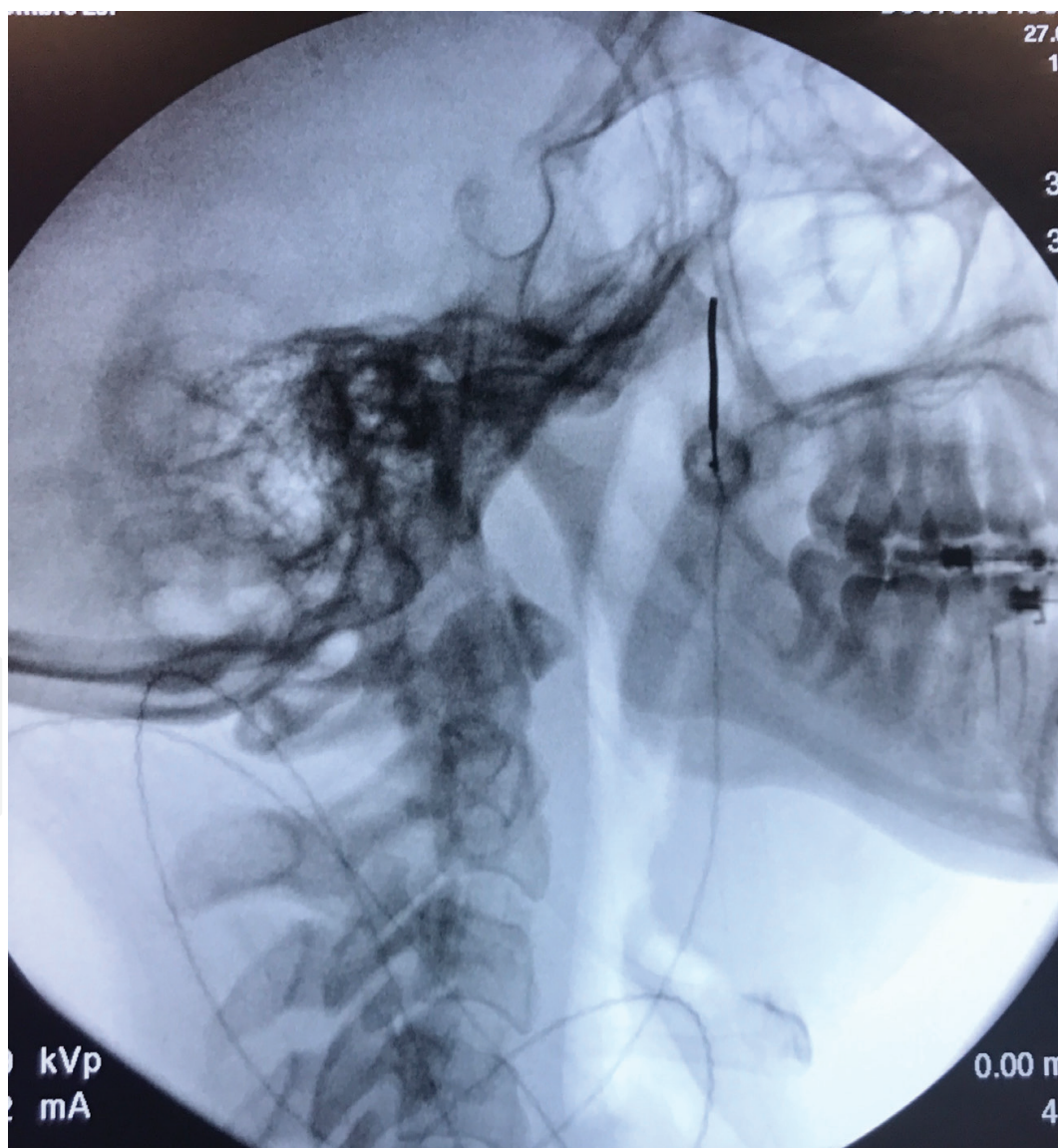
### **4.1. Indications for SPG block**

Some of the indications for the SPG block are trigeminal neuralgia, persistent idiopathic facial pain (previously referred to as atypical facial pain), acute migraine, acute and chronic cluster

headache, SP neuralgia, herpes zoster involving the head, and a variety of other facial neuralgias, including tumor invasion.

Sphenopalatine ganglion neuralgia consists mainly of neuropathic symptoms, but is accompanied by sensory, motor, and gustatory manifestations. It is common for the symptoms to be episodes of vasomotor hyperactivity such as lacrimation, discharge and inflammation of the nasal mucosa, and alteration of gustatory sensation of the palate and oropharynx.

The procedure consists of accessing the pterygopalatine fossa by placing local anesthetic with or without steroids, radiofrequency ablation, or pulsed radiofrequency. It may be used for diagnosis or treatment of the conditions described above. It is mandatory that these procedures are performed under radiographic imaging. It is essential that the pterygopalatine fossa is clearly visualized and confirmed before starting the procedure [11]. (See **Figure 1**).



**Figure 1.** Sphenopalatine ganglion block.

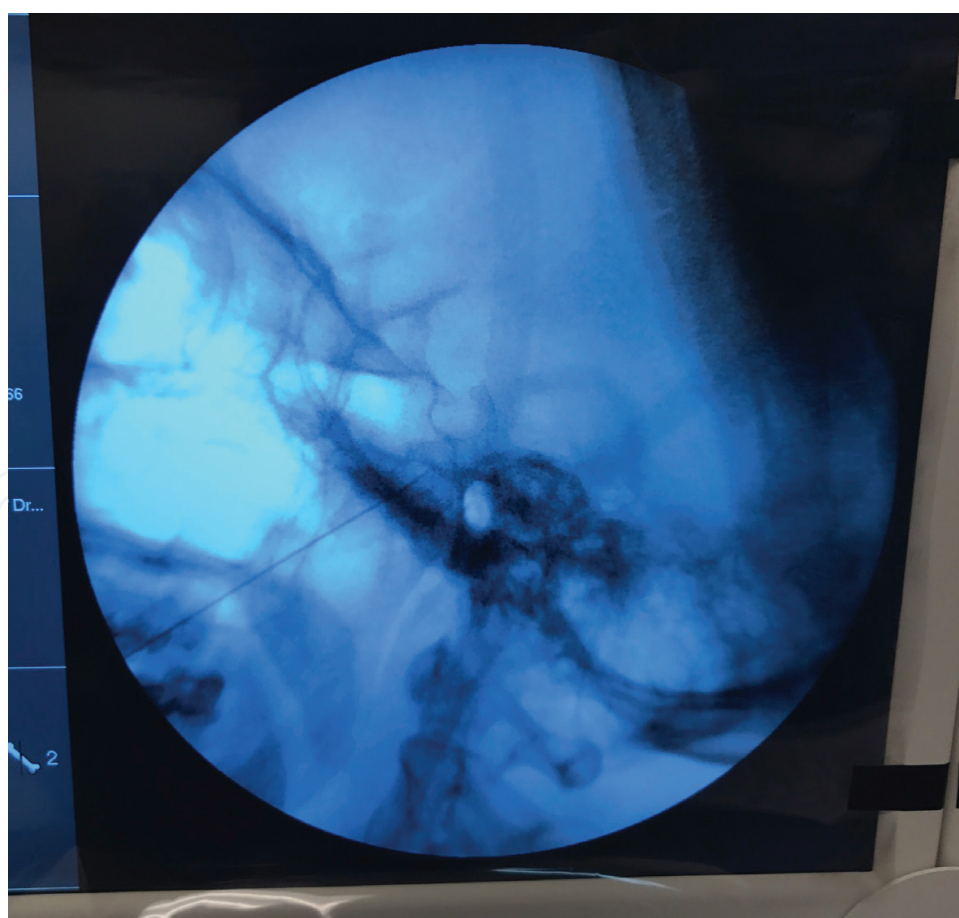


## 5. Trigeminal ganglion block (Gasserian ganglion)

The trigeminal nerve is the most developed and extensive cranial nerve with a large territory of distribution. This nerve consists of sensitive fibers (touch, pain, temperature) and motor of the face (chewing). It originates in the posterior fossa and lies in the Meckel's cavity (medial cranial fossa), from which originate their three terminal branches: ophthalmic nerve (V1), maxillary (V2), and mandibular nerve (V3).

There are several causes of secondary trigeminal neuralgia, which are tumors compressing the trigeminal nerve, vascular compressions in close relation with the nerve, or tumors in cerebellopontine angle.

The typical clinical presentation of trigeminal neuralgia is sudden, unilateral electrical shock-like pain dispersed among pain-free intervals along the side of the face. Paroxysmal attacks are frequently triggered by chewing, brushing teeth, laughing, talking, and even smiling. It is often referred to as the most excruciating pain syndrome known today affecting quality of life. In contrast, clinical criteria of atypical facial pain consist of persistent facial pain that does not have the characteristics of cranial neuralgias and cannot be attributed to a different disorder [12].



**Figure 2.** Gasserian ganglion block.

An approach is with fluoroscopy in oblique submental view. In this technique, foramen ovale is visualized; usually medially to the mandibular process, and then the needle is advanced toward the foramen, first in submental view and then in the lateral view to control depth.

One technique used to selectively injure the branches of the trigeminal nerve is continuous radiofrequency. This method allows identifying the affected branch by sensory and motor stimulation with conscious sedation. It is a percutaneous technique using the approach described by Hartel through the foramen ovale. An electrode is introduced through the needle (with an active tip of 2–5 mm) to make the lesion (ranges from 60–90°C). The deliberately damaged nerve is then no longer able to transmit nociceptive signals.

The potential risks of trigeminal rhizotomy include, but are not limited to, facial numbness spreading beyond the required area [causing corneal anesthesia (6%) with its risk of ulceration], weakness of chewing (4%), and a rare chance of neuropathic pain (1%, anesthesia dolorosa) [13].

There is extensive evidence of the use of continuous radiofrequency for the treatment of trigeminal neuralgia, indicated acute pain relief in 97.6% of patients and continued complete pain relief at 5-year follow-up in 57.7% of patients. The effectiveness of pulsed radiofrequency (PRF) for trigeminal neuralgia is still under debate [13]. (See **Figure 2**)

## 6. Glossopharyngeal nerve block

The glossopharyngeal nerve (GPN) is an important consideration as a pain generator or modulator in cases of pain of the face and neck. Although uncommon as an etiology of head and neck pain (0.57–1.3% of cases of facial pain), tumor invasion can lead to glossopharyngeal neuralgia, like cerebellopontine angle tumors [14].

Glossopharyngeal neuralgia is characterized by unilateral paroxysmal pain in the oropharynx, nasopharynx, larynx, base of the tongue, tonsillar region, and lower jaw and can also radiate to the ipsilateral ear. These attacks are excruciatingly painful and typically described as sharp, stabbing, “shocks of electricity” the attacks usually last for seconds to 2 minutes. It is characteristic that there are triggers such as chewing, yawning, or stimulation in the oral mucosa [15].

### 6.1. Indications for GPN block

GPN block is beneficial in alleviating pain due to orofacial cancer. It is used for the treatment of glossopharyngeal neuralgia refractory to medical management and for those who are not surgical candidates. Diagnostic GPN block should be considered first to predict the response to radiofrequency or neurolysis in intractable glossopharyngeal neuralgia and cancer-related pain syndromes.

#### 6.1.1. Technique

The patient is placed supine with the head rotated slightly opposite from the affected side. The styloid process is used to identify the course of the GPN, just equidistant to mastoid

process and angle of the mandible. Once the styloid apophysis is visualized, the needle is contacted and carefully redirected posteriorly and the contrast medium is injected under continuous “live” fluoroscopy.

Complications are secondary to the close proximity to the internal carotid artery (ICA) and internal jugular vein (IJV) as well as the vagus, accessory, and hypoglossal nerves at the styloid process.

Accidental puncture of the ICA or the IJV can lead to vessel trauma and hematoma formation. Dysphagia can result from blockade of the glossopharyngeal nerve that provides motor innervations to the stylopharyngeus muscle. Blockade of the spinal accessory and hypoglossal nerves can result in temporary weakness of the trapezius muscle and the tongue, respectively. Inadvertent intravascular injection may lead to seizures or cardiovascular collapse. Blockade of the vagus nerve can lead to bradycardia, asystole, reflex tachycardia, and syncope as well as dysphonia secondary to vocal cord paralysis [15].

## **7. Stellate ganglion block**

There are three cervical sympathetic chains: upper cervical ganglion, middle cervical ganglion, and lower cervical ganglion. These ganglions are all connected together. The stellate ganglion is composed of the fusion of the inferior cervical chain and the first thoracic ganglion, this happens in the 80% of the people; in the rest, the first thoracic ganglion is called stellate ganglion [16]. It is located above the muscle longus colli, and this in turn is in the anterolateral aspect of the C6 vertebra.

### **7.1. Indications for stellate ganglion block**

Complex regional pain syndrome (CRPS) I and II, vascular insufficiency—Raynaud’s syndrome, vasospasm, vascular disease, postherpetic neuralgia and acute herpes zoster, phantom pain, postmastectomy pain, quinine poisoning, hyperhidrosis of upper extremity, cardiac arrhythmias, angina, vascular headaches, neuropathic pain syndromes, including central pain, cancer pain (neuropathic pain syndromes in cancer pain), atypical facial pain, and trigeminal neuralgia.

### **7.2. Ultrasound technique**

There are many techniques described for stellate ganglion block. We will describe the ultrasound guided block, because this technique allows us to directly visualize the vascular structures, thyroid tissue, vertebral artery, pleura, esophagus, and nerve structures, which are important for the success of the procedure and avoiding catastrophic complications.

Ultrasound-guided C6 stellate ganglion block (C6-SGB) was first described by Kapral et al. [17]. There is a significant variation in the anatomy of stellate ganglion at the level of C<sub>6</sub> and C<sub>7</sub>. Ultrasound-guided lateral approach increases the efficacy of SGB by deposition of drug subfascially with real-time imaging.



A high-frequency linear ultrasound transducer is placed over the medial border of the sternocleidomastoid muscle in the transverse position at the level of the cricoid notch (approximately the C6 level). The tip of the needle is placed in the facial plane where the sympathetic chain runs, deep to the prevertebral fascia contributing the posterior fascial layer of the carotid sheath, and superficial to the fascia investing the longus colli muscle. Using ultrasound guidance, the needle can be placed closer to the target in the correct fascial plane, which will minimize the amount of local anesthetic needed and thus improve patient safety [16].

The ultrasound images at this level should reveal the C6 vertebral body with the Chassaignac or the carotid tubercle, the C6 nerve root, the carotid artery, the longus colli muscle, and the short posterior tubercle. If the carotid artery blocks access to the cervical sympathetic chain, the ultrasound transducer can be slowly moved laterally to help delineate a more lateral needle trajectory to avoid the carotid artery.

*Complications:* Bleeding/hematoma, pneumothorax, hemothorax, vertebral artery injury or inadvertent injection, inadvertent injection into neuraxis, esophageal trauma, tracheal trauma, phrenic nerve injury, brachial plexus injury, recurrent laryngeal nerve injury, and postsympathectomy syndrome.

## 8. Vertebroplasty for cancer-related cervical vertebral compression fractures

Percutaneous vertebroplasty (PVP) was initially described by Galibert et al. [18] as a treatment for vertebral hemangioma. Later, it was gaining popularity for the treatment of pain of vertebral origin as metastasis or fractures by compression.

The most common targets of spinal metastasis are thoracic vertebrae (60–80%), followed by lumbar (20%) and cervical spine (10%). Although cervical metastases are less prevalent than thoracic and lumbar spine, PVP procedure in cervical vertebrae remains technical challenging, because of the anatomical structures of the neck. The approach can result in serious complications [19].

PVP was recently suggested as an alternative treatment for spinal metastatic patients who were intolerable to surgery and radiotherapy. It is now a well-established procedure comprising a percutaneous injection of a biomaterial, usually polymethyl methacrylate (PMMA), into vertebral body. In most cases, this procedure significantly relieves pain and stabilizes the vertebral body. A significant decrease in visual analogue scale (VAS) and QOL was reported in late-stage cancer patients with multiple cervical spinal metastases, with PVP. The grade of evidence for the treatment of vertebral fractures associated with metastatic disease is 2B + [3].

## 9. Intrathecal drug delivery systems (IDDS)

The use of intrathecal therapy [IT] to treat patients with cancer pain has increased since its inception in the 1980s. By positioning a catheter in the cerebral spinal fluid, IT therapy may be

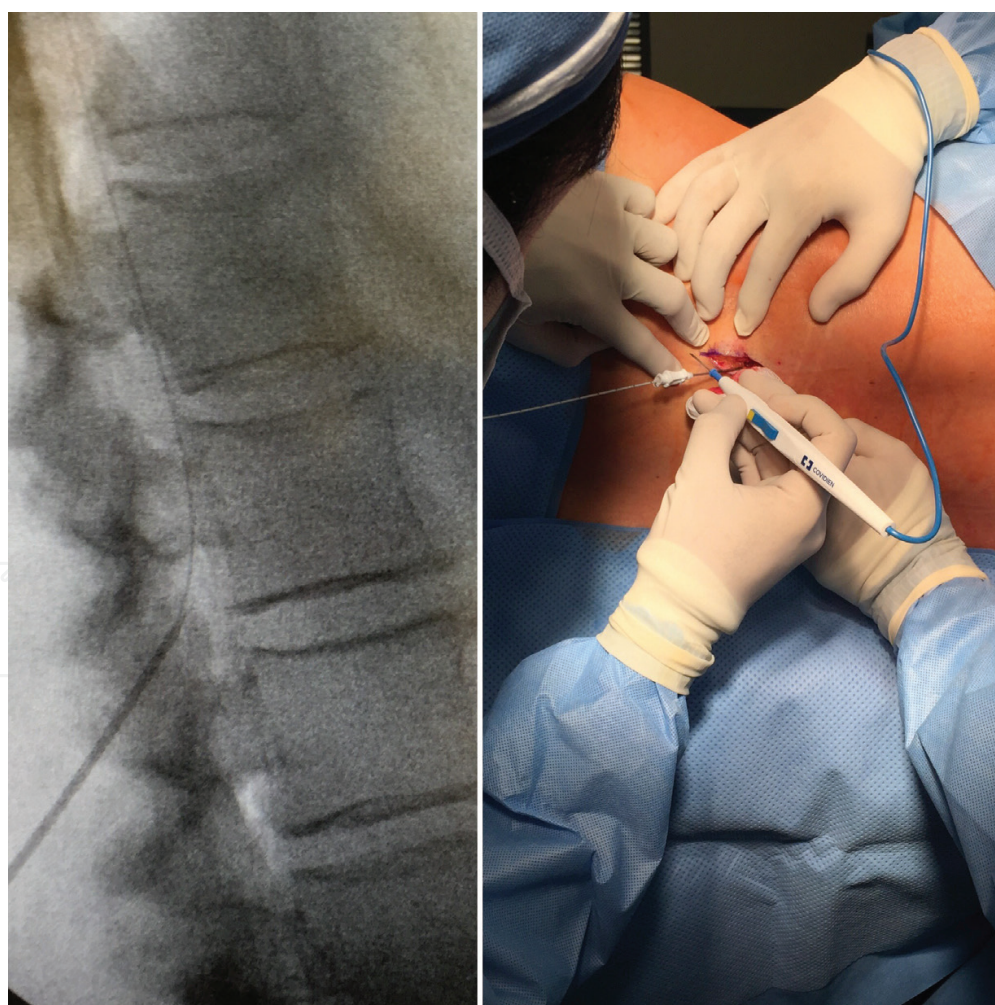
advantageous over traditional routes because it reduces systemic exposure to the drug and its metabolites as the medication is administered directly to the central nervous system.

To reduce the risk of infection in a long-term intrathecal therapy, it is necessary to implant the device subcutaneously. Occasionally, an intrathecal drug delivery test may be performed by an external catheter. In this way, the infusion of the permanent device is simulated and the dose of the opioid is titrated [20]. This treatment is effective to treat both neuropathic and nociceptive pain of oncological and non-oncological origin.

Related to HNC pain, the ideal opioid for intrathecal infusion should be hydrosoluble, with the intention of having a greater rostral migration.

There are studies that report improvement in pain, mood, function, as well as, an improvement in depression and anxiety in cancer patients at a follow-up of 36 months among patients undergoing intrathecal opioid therapy.

The potential complications of IDDS include opioid-induced hyperalgesia, hypotension, sedation, respiratory depression, inflammatory mass “granuloma at the tip of the catheter,”



**Figure 3.** Intrathecal therapy.

hypogonadotropic hypogonadism, and immunologic compromise. The potential for these consequences can be diminished with careful dosing and titration. The patient should be monitored 24 hours after increasing the dose to decrease the risk of respiratory depression and mortality (See **Figure 3**).

## 10. Peripheral nerve blocks, cervical epidural, and medial branch block

Occipital neuralgia is a debilitating disorder first described in 1821 as recurrent headaches localized in the occipital region. Other symptoms that have been associated with this condition include paroxysmal burning and aching pain in the distribution of the greater, lesser, or third occipital nerves.

### 10.1. The greater occipital nerve

The HNC-associated headache may be due to entrapment of great occipital nerve (GON), third occipital nerve (TON), or irritation of either of them due to tumor invasion [21, 22]. There are different structures in the cervical region that can cause head and neck pain, due to tumor invasion. The cervicogenic headache is a secondary headache associated with the first cervical segments.

Occipital nerve block is an effective therapeutic tool in treating a variety of headache disorders including occipital neuralgia, migraine, cluster headaches and tumor invasion. The mechanism of action is a result of blockade of nociceptive afferent fibers supplying the posterior head and upper cervical region (C1–C3) which join trigeminal fibers at the trigeminocervical complex [21, 22].

Occipital nerve block and C2–C3 medial branch can be used to treat cervicogenic headache and cancer-related cervical pain, using corticosteroids or radiofrequency. They can be performed percutaneously with an insulated cannula, applying local heat to the sensitive branch with the intention of diminishing the sensitivity. Both nerve blocks are easy to perform and well tolerated with a few side effects.

## 11. Botulinum neurotoxin (BoNT)

Botulinum neurotoxin derived from *Clostridium botulinum*, not only has been used for cosmetic purposes but also therapeutically for focal dystonia, spasticity, and chronic migraine. There is some evidence that it inhibits the release of peripheral neurotransmitters and inflammatory mediators from sensory nerves; so, its spectrum as a potential treatment for neuropathic pain has grown.

The main mechanism of BoNT is the inhibition of acetylcholine (Ach) release at presynaptic nerve terminals, resulting in a reduction of muscle fiber activity, and the innervated structure becomes paralyzed [23]. It has also been suggested that BoNT acts by inhibiting neurogenic inflammation

by interfering with local release of neurotransmitters, such as calcitonin gene-related peptide, substance P and glutamate, as well as expression of transient receptor potential v member 1 (TRPV1).

BoNT is injected into painful areas of the body. Injection techniques primarily include either intradermal or subcutaneous injections. It is important to mention that there are different reports of BoNT administration in patients with trigeminal neuralgia and other neuralgias in the head and face with significant improvement in VAS and QOL.

## 12. Conclusions

The increasing need for adequate pain control has led us to enter into interventional pain management. There is good evidence of early integration of interventional treatments in cancer pain [24]. The field of interventional pain management grows very fast throughout the world and is a tool that every physician involved in treatment of cancer must value and offer to patients for a more comprehensive management of the disease.

## Author details

Victor M. Silva Ortiz<sup>1\*</sup>, Guillermo E. Aréchiga Ornelas<sup>2</sup>, José A. Flores Cantisani<sup>3</sup>, Juan Ignacio Reyes Torres<sup>4</sup> and Fernando Cantú Flores<sup>1</sup>

\*Address all correspondence to: [drvictorsilva@gmail.com](mailto:drvictorsilva@gmail.com)

1 Pain Management and Palliative Care Department, Hospital Zambrano Hellion, Monterrey, Mexico

2 Pain Management and Palliative Care Department, Hospital General Occidente, Guadalajara, Mexico

3 Pain and Palliative Care, ISSSTELEON, Monterrey, Mexico

4 Pain Management and Palliative Care Department, ISSSTE, Saltillo, Mexico

## References

- [1] Soto E, Bobr V, Bax JA. Interventional techniques for headaches. *Techniques in regional anesthesia and pain management*. 2012;**16**:30-40
- [2] Epstein JB, Wilkie DJ, Fischer DJ, Kim YO, Villines D. Neuropathic and nociceptive pain in head and neck cancer patients receiving radiation therapy. *Head & Neck Oncology*. 2009;**1**:26 DOI: 10.1186/1758-3284-1-26
- [3] Bhatnagar S, Gupta M. Evidence-based clinical practice guidelines for interventional pain management in cancer pain. *Indian Journal of Palliative Care*. 2015;**21**:137-147



- [4] Kurita GP, Ulrich A, Jensen TS, Werner MU, Sjøgren P. How is neuropathic cancer pain assessed in randomised controlled trials? *Pain*. 2012;**153**:13-17
- [5] Yalcin EES. Neuropathic cancer pain: What we are dealing with? How to manage it? *OncoTargets and Therapy*. 2014;**7**:599-618
- [6] Kolokythas A, Connelly ST, Schmidt BL. Validation of the University of California San Francisco oral cancer pain questionnaire. *Journal of Pain*. 2007;**8**(12):950-953
- [7] Astrup GL, Rustøen T, Miaskowski C, Paul SM, Bjordal K. Changes in and predictors of pain characteristics in patients with head and neck cancer undergoing radiotherapy *Pain*. 2015;**156**:967-979
- [8] Macfarlane TV, Wirth T, Ranasinghe S, Ah-See KW, Renny N, Hurman D. Head and neck cancer pain: Systematic review of prevalence and associated factors. *Journal of Oral & Maxillofacial Research*. 2012;**3**(1):e1
- [9] Blier Z. Physiology of the sphenopalatine ganglion. *American Journal of Physiology*. 1930;**93**:398-406
- [10] Piagkou M, Demesticha T, Troupis T, Vlasik K, Skandalakis P, Makri A, Mazarakis A, Lappas D, Piagkos G, Johnson EO. The pterygopalatine ganglion and its role in various pain syndromes: From anatomy to clinical practice. *Pain Practice*. 2012;**12**(5):399-412
- [11] Nader A., Kendall MC, De Oliveira GS, Chen JQ, Vanderby B, Rosenow JM, Bernard R, Bendok BK. Ultrasound-guided trigeminal nerve block via the pterygopalatine fossa: An effective treatment for trigeminal neuralgia and atypical facial pain. *Pain Physician*. 2013;**16**:E537-E545
- [12] Zakrzewska JM, Jassim S, Blum JS. A prospective, longitudinal study on patients with trigeminal neuralgia who underwent radiofrequency thermocoagulation of the Gasserian ganglion. *Pain*. 1999;**79**:51-58
- [13] Son B-C, Kim H-S, Kim II-S, Yang S-H, Lee SW. Percutaneous radiofrequency thermocoagulation under fluoroscopic image-guidance for idiopathic trigeminal neuralgia. *Journal of Korean Neurosurgical Society*. 2011;**50**:446-452
- [14] Mehio A-K, Shah SK. Alleviating Head and Neck Pain. *Otolaryngologic Clinics of North America*. 2009;**42**:143-159 DOI: 10.1016/j.otc.2008.09.013
- [15] Ažman J, Pintaric TS, Cvetko E, Vlassakov K. Ultrasound-Guided glossopharyngeal nerve block. A cadaver and a volunteer sonoanatomy study. *Regional Anesthesia and Pain Medicine*. 2017;**42**:252-258
- [16] Narouze S. Ultrasound-Guided stellate ganglion block: Safety and efficacy. *Current Pain and Headache Reports*. 2014;**18**:424. DOI: 10.1007/s11916-014-0424-5
- [17] Kapral S, Krafft P, Gosch M. Ultrasound imaging for stellate ganglion block: Direct visualization of puncture site and local anesthetic spread: A pilot study. *Regional Anesthesia and Pain Medicine*. 1995;**20**(4):323-328



- [18] Galibert P, Deramond H, Rosat P, Le Gars D. Preliminary note on the treatment of vertebral angioma by percutaneous acrylic vertebroplasty. *Neurochirurgie*. 1987;**33**(2):166-168
- [19] Health Quality Ontario. Vertebral Augmentation Involving Vertebroplasty or Kyphoplasty for Cancer- Related Vertebral Compression Fractures: A Systematic Review. Ontario Health Technology Assessment Series. 2016;**16**(11):1-202
- [20] Deer TR, Smith HS, Burton AW, Pope JE, Doleys DM, Levy RM, Staats PS, Wallace M, Webster LR, Rauck R, Cousins M. Comprehensive consensus based guidelines on intrathecal drug delivery systems in the treatment of pain caused by cancer pain. *Pain Physician*. 2011;**14**:E283–E312
- [21] Wahezi SE, Silva K, Shaparin N, Lederman A, Emam M, Haramati N, Downie S. Currently recommended TON injectate volumes concomitantly block the GON: Clinical implications for managing cervicogenic headache. *Pain Physician*. 2016;**19**:E1079-E1086
- [22] Nagar VR, Birthi P, Grider JS, Asopa A. Systematic review of radiofrequency ablation and pulsed radiofrequency for management of cervicogenic headache. *Pain Physician*. 2015;**18**:109-130
- [23] Oh H-M, Chung ME. Botulinum toxin for neuropathic pain: A review of the literature. *Toxins*. 2015;**7**:3127-3154. DOI: 10.3390/toxins7083127
- [24] Sommer CL, Wallace MS, Cohen S, Kress M. Pain 2016: Refresher Courses. 16<sup>th</sup> world congress on pain. IASP Press, Whashington D.C. 2016

