

We are IntechOpen, the world's leading publisher of Open Access books Built by scientists, for scientists

6,900

Open access books available

186,000

International authors and editors

200M

Downloads

Our authors are among the

154

Countries delivered to

TOP 1%

most cited scientists

12.2%

Contributors from top 500 universities



WEB OF SCIENCE™

Selection of our books indexed in the Book Citation Index
in Web of Science™ Core Collection (BKCI)

Interested in publishing with us?
Contact book.department@intechopen.com

Numbers displayed above are based on latest data collected.
For more information visit www.intechopen.com



Surgical Anatomy of the Groin

Kamer Tomaoglu

Additional information is available at the end of the chapter

<http://dx.doi.org/10.5772/intechopen.69448>

Abstract

Most surgeons are familiar with the inguinal anatomy from the anterior perspective. With the advent of laparoscopic techniques for inguinal hernia repair, it became important to understand the inguinal anatomy from the preperitoneal view for a posterior approach to the inguinal region. The purpose of this chapter is to describe the anatomic landmarks of the groin region.

Keywords: anatomy, groin, surgery

1. Introduction

The inguino-femoral region extends to above and under the line of Malgaigne. It composes the borderline region between anterolateral abdominal wall and upper portion of the triangle of Scarpa [1, 2]. It represents an important structure, which is a passage zone between the abdominal area, the external genital region, and the root of lower extremity. Two pedicles, the spermatic cord (or the round ligament of uterus) and the iliofemoral vascular pedicle cross the inguino-femoral region. It is equally a zone of embryologic importance, characterized by the evolution of peritoneo-vaginal channel, the testicular descent, and rarely an ectopic engagement of ovaries [2–4].

The groin is the region where most hernias of the abdominal wall occur. Inguinal hernia repair is the most commonly performed operation worldwide. Approximately 75% of abdominal wall hernias occur in the groin [5, 6]. Its surgical interest is evident which we understand easily by the consecutive diverse technical discussions after the apparition of the Shouldice Hospital technique, considered by many authors as a return to the “starting point” [7, 8].

2. History

In the sixteenth century, Fallope described the “inguinal ligament.” Later on, Ambroise Paré tried to classify different hernias. In the eighteenth century, Poupart and Littre summarized the knowledge on hernia anatomy. Littre described the hernia of intestinal diverticulum (Meckel’s diverticulum), which was called Littre’s hernia later on. Scarpa, in 1812 published the famous “*Traité des hernies*” first in Italian language and later in French with illustrations of the inguino-femoral triangle. From surgical point of view, “*Traité des hernies*” was very rudimentary, only the hernias with failure of taxis were operated on. Intestinal interminable fistulas were frequently present in survived patients. The cauterization was sometimes used, without any considerable amelioration of the results [2, 3, 6].

Modern history of hernia cure begins with Bassini who described in 1886, the anatomic procedure of radical cure of inguinal hernia [9]. This was the first modern operation, based on a perfect anatomic analysis of the region. In the twentieth century, the modifications of Bassini’s operation and McVay and Anson [16] revised the ideas of Lotheissen and insisted on the interest of low fixation, to the Cooper’s ligament, underlying the importance of anatomic unity of the region while performing the surgical treatment of both inguinal and femoral hernias simultaneously [1–3].

Beginning from 1953, the Shouldice technique emerged in Toronto, which realized a retrofunicular suturing of the transversalis fascia, thus claiming to obtain maximum solidity [10].

Fruchaud, in 1956, published the classic “*Anatomie des hernies de l’aîne*”, which was based upon the structural unity of the inguino-femoral region which was centered on myopectineal orifice. Nyhus and Condon published the book “*Hernia*” in 1978.

In the early 1980s, Lichtenstein popularized the tension-free repair, supplanting the tissue-based repairs with prosthetic materials for inguinal floor reconstruction [11].

With the advent of minimally invasive surgery, since the initial description by Ger, inguinal hernia repair underwent its most recent transformation.

3. Embryology

Very early during the embryonic development, the peritoneal cavity presents two inferior diverticula, which protrude through the inguinal canal and become the processus vaginalis. They extend toward the scrotal draft or the major labium preceding the topographic gonadal evolution, which explains the possibility of congenital hernias associated to gonadal ectopies. During the normal course of development, the testes descend from the intra-abdominal space into the scrotum in the third trimester, a relative movement which is closely linked to the development of scrotal and lumbar ligaments. The gonads slide to the posterior of the peritoneo-vaginal canal to be placed under its inferior border, thus realizing the draft of the vaginal serosal layer.

As a rule, the peritoneo-vaginal canal closes before birth. The closure abnormalities of the peritoneo-vaginal canal or the equivalent Nuck's canal may explain the different modalities of intrafunicular indirect hernias predominant in young patients. The partial permeability of the proximal portion of the canal explains the congenital hernias found at birth or becomes evident during the first crisis. A total permeability results in a communicating hernia in which the visceral organs may be engaged descending to the testicular level, even contacting the testicle. Residual or "suspended" permeability explains the frequency of small hernia accompanying cordon cysts.

Indirect hernias frequently appear following an effort as a late manifestation of a congenital abnormality. In certain cases, the peritoneo-vaginal canal descends to the testicular level without communicating with the vaginalis.

The ductus deferens conserves its close relationship with the serous diverticulum, so it is mandatory to be vigorous during the resection of the indirect hernia sac, especially in infants. The ovaries exceptionally may be engaged into the inguinal trajectory, or even may be present in the major labium, giving rise to an intraparietal ectopy. So, one should be prudent not to blindly resect an inguinal mass in a female patient, misdiagnosing it as a simple lipoma.

According to Russel (1906), all indirect hernias are in fact congenital abnormalities. This opinion was controverted, many authors admitting that the simple fossa at the origin of the peritoneo-vaginal canal on the abdominal side, under the influence of parietal insufficiency may distend into the spermatic cord. On the other hand, in some male or female patients, the persistent permeability of peritoneo-vaginal canal may exist without any manifestation of hernia.

4. Architecture

The inguinofemoral region is constructed "around an orifice", which is named the Fruchaud's orifice. Fruchaud emphasized the fact that all hernias of the groin originate within a single weak area, the myopectineal orifice, which is subdivided as inguinal and femoral by the inguinal ligament representing the terminal part of the aponeurosis of the external oblique muscle. The muscles of the anterolateral abdominal wall are arranged in two layers, the aponeurosis of external oblique muscle anteriorly and the transversalis fascia and its reinforcements posteriorly [1, 2, 12].

Fascia transversalis is the principal structure of regional stability. The opening of the deep inguinal ring of the inguinal canal is at this level. The inguinal canal has three passages—the deep inguinal ring situated above and laterally, the myopectineal orifice in the middle, and the superficial inguinal ring (annulus superficialis) situated below and medially, thus forming a chicane first described by Ombredane. Each one of these three passages plays an important role in visceral contention. The importance of this chicane is even ameliorated by its transverse location in space, the ectomorph (longilineal), slender individuals being more prone to the development of inguinal hernias compared to the endomorph (brevilineal) ones, both in males and females [1, 3, 4].

5. The myopectineal orifice

The myopectineal orifice is bounded below by the anteroinferior part of the coccyx, the horizontal part of pubic bone, lined in its upper part by the ligament of Cooper; above by the conjoint tendon of internal oblique and transverse muscles; and medially by the lateral border of rectus abdominis and the overlying pyramidalis muscles (**Figure 1**). The myopectineal orifice is subdivided into two regions, femoral below and inguinal above by the inguinal ligament. So, there is a relationship between direct and femoral hernia, one pushing anteriorly and the second one inferiorly [13].

5.1. The bony construction

The inguinofemoral region is constructed at the anterior border of the iliac bone, which presents from above to downward the anterior superior iliac spine, an unnamed notch; the anterior inferior iliac spine, the iliopubic eminence, and the pectineal surface of the superior ramus of the pubic bone, bounded behind by the pecten of the pubis and medially by the pubic tubercle. The pubic bone is lined in its upper part by the pectineal ligament of Cooper [14].

The pelvic skeleton plays an important role in the occurrence of hernia by its general morphology, besides participating in the constitution of the myopectineal orifice. As already mentioned, ectomorph (longilineal) individuals are more predisposed to hernia

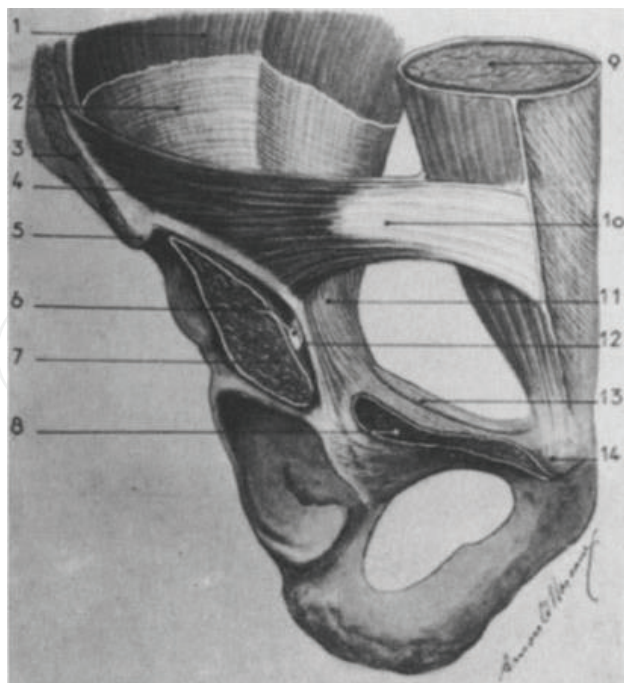


Figure 1. The myopectineal orifice: 1 = iliacus muscle; 2 = fascia iliaca; 3 = external oblique muscle; 4 = internal oblique muscle; 5 = superior iliac spine; 6 = femoral nerve; 7 = iliopsoas muscle; 8 = pectineus muscle; 9 = rectus muscle; 10 = internal oblique muscle; 11 = iliopectineal tract; 12 = fascia iliaca; 13 = Cooper's ligament; 14 = pubic tubercle.

formation. The angle of Radojevic is formed by the intersection of the line of Malgaigne and the horizontal line uniting both the anterior superior iliac spines (**Figure 2**). This angle differs between 25 and 35°, the more the value of the angle, the more is the possibility of hernia formation. The distance between the superior border of pubic symphysis and the bi-spinal line may be substituted though, for example, 6 cm of distance giving approximately an angle of 30° [14].

5.2. Inferior attachments

These are in fact the anatomic structures on which we rely habitually for passing the sutures while performing hernia surgery.

5.2.1. Inguinal ligament

The inguinal ligament was initially described as an autonomous ligament uniting the anterior superior iliac spine to the pubic spine and winding around a center constructed by autonomous fibers of the lower part of the external oblique muscle aponeurosis. The question is that whether this is a true or discrete fibrous structure. The existence of the inguinal ligament was questioned by many authors, especially by Winckler, who demonstrated that the so-called inguinal ligament was only the inferior folded border of aponeurosis of the external oblique muscle. It may frequently be weakened, the direction of fibers constituting it are parallel to each other and may be frayed under the tension of sutures [15].

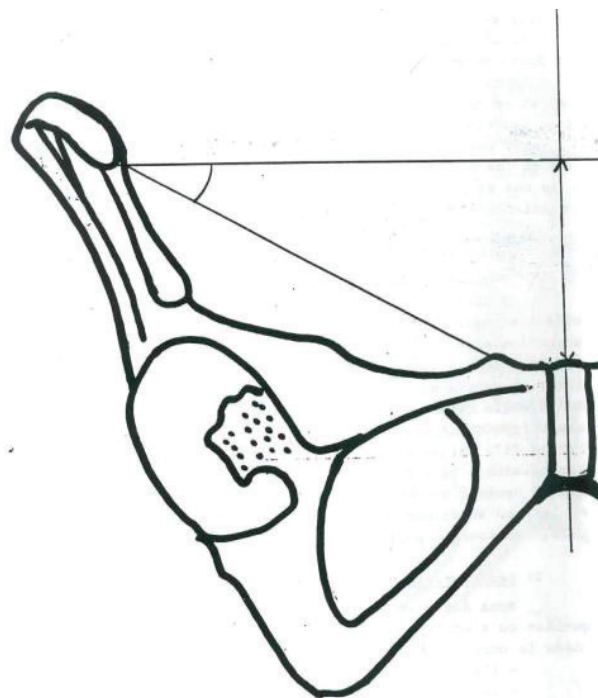


Figure 2. Radojevic angle.

5.2.2. The iliopubic tract (*bandelette of Thomson*)

Under the name “bandelette of Thomson” is described as the fibrous structures situated posterior to the lower free margin of the inguinal ligament, which are in fact the condensations of the transversalis fascia. It is to Alex Thomson that we owe the description of this fibrous structure. This tract is nearly parallel to the anterior aspect of the thigh. The fibers of the bandelette are parallel to the superior border of the anterior vascular sheath, enlarging considerably posteriorly and superiorly to attach between two bundles of the ligament of Cooper on the internal third of the crest of the pubic bone and on the lateral half of the anterior border of the superior aspect of the body of the pubis. This bandelette, with its own fibers of the lateral half of the iliofemoral-vascular fascia, is named the iliopubic tract (**Figure 3**).

For certain authors, these are the structures that we should rely on while passing the stitches more than the inguinal ligament, such as the conception of McVay and Anson [16].

5.2.3. The annexes of inguinal ligament: Iliopectineal bandelette, ligament of Gimbernat

The iliopectineal tract extends from one-third external part of the inguinal ligament to the iliopectineal (iliopubic) eminence of the pubic bone. This structure does not have any direct relationship with the inguinal ligament, it is a reinforcement of the internal border of iliac fascia, which slides under the inguinal ligament to which it closely adheres. The iliopectineal ligament separates the two passages situated under the inguinal ligament. The femoral nerve passes just lateral to it, whereas the femoral artery and the vein pass medially. Thus, the iliopectineal ligament separates the femoral nerve from the femoral artery.

The ligament of Gimbernat is placed medial to this vascular gap.

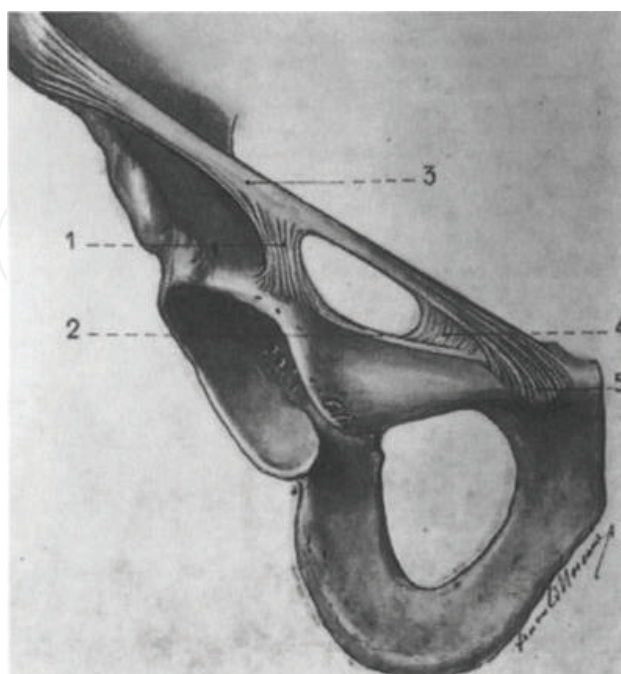


Figure 3. Anterior border of the iliac bone: 1 = iliopectineal tract; 2 = Cooper's ligament; 3 = iliopubic tract; 4 = Gimbernat's ligament; 5 = pubic tubercle.

This ligament presents a resistant external border, important in strangulation of femoral hernias. Between the femoral vein and the ligament of Gimbernat, extends a fibrous layer into which passes the lymphatics of the inferior extremities. This structure is called the femoral septum, which in fact is the inferior expansion of the transversalis fascia [15, 16].

5.2.4. Cooper's ligament (pectineal ligament)

The Cooper's ligament lines the superior border of the pubic bone between the pubic spine and the iliopectineal eminence. This ligament joins the inguinal ligament medially where it forms the lacunar ligament of Gimbernat but diverges laterally from it when runs in a much deeper position. The pectineal ligament is a heterogeneous structure comprising of three layers. It is formed by a superficial fibrous layer where the vertical fibers of the aponeurosis of the pectineal muscle and transverse fibers are running along the innominate line of the pelvis overlap. The middle, muscular layer is formed by the fibers of the pectineus muscle. The deep layer is in continuity with the periosteum of the superior pubic ramus.

Very thick and displaying an extreme degree of mechanical resistance medially, weakens while passing under the femoral vein. At this point, it becomes dangerous to pass stitches because of the close relationship with the femoral vein. The sutures that are sufficiently strong, passing from the Cooper's ligament, placed near the contact of pubic bone may virtually lift up the whole body. The Mc Vay procedure relies on this resistance, which automatically closes the inguinal and femoral passages when the sutures are in place [1, 16].

5.3. Internal border of the myopectineal orifice

The rectus abdominis muscle of the abdomen, very large, superiorly narrows until 4 cm at the inferior part just above the pubis terminating by a short tendon extending from the pubic symphysis to the pubic tubercle. At this level, the muscle does not contain any fibrous intersections. On its anterior face, habitually it is covered by the pyramidal muscle of the abdomen, which extends from the middle part of the median line to the horizontal branch of the pubis. The sheath of the rectus abdominis muscle is constituted anteriorly by the aponeurotic layers of the external oblique, internal oblique, and transverse muscles whereas posteriorly, below the level of the arc of Douglas, the posterior sheath consists of only the transversalis fascia, which is thickened at this level [17].

The rectus muscle may be mobilized and lowered laterally and inferiorly either to the inguinal ligament or to the Cooper's ligament. This maneuver is facilitated by incisions of relaxation on the anterior face of the rectus abdominis muscle (Mc Vay incision).

5.4. Superior border

The conjoint tendon (tendo conjunctivus) is made up of the transverse fibers of the internal oblique muscle anteriorly and the transverse muscle posteriorly extending from one-third external part of the inguinal ligament to the anterior face of rectus abdominis muscle. This muscle plan is fixed laterally to the iliac fascia. The muscular fibers, which are detached from the infero-external part wrap up the spermatic cord constituting the cremaster muscles, considerably thickening the origin of the spermatic cord [15].

5.5. Weak points of the myopectineal orifice

The myopectineal orifice is subdivided by some anatomic structures, such as the inguinal ligament, the inferior epigastric vessels, and the umbilical artery, into four regions, of which three of them are above and one is below the inguinal ligament.

Above the inguinal ligament, inside the umbilical artery, a hernia may be present between the posterior face of the rectus abdominis muscle and the umbilical artery. These are very rare hernias called the internal oblique hernias.

Between the umbilical artery and the epigastric vessels, the myopectineal orifice makes a gap. The only anatomic structure which may resist at this level is the transversalis fascia. This is the site of direct hernia frequently seen after 50 years of age.

Outside the epigastric vessels, passes the spermatic cord where a patent peritoneo-vaginal canal may exist, the site of development of external (indirect) hernias.

Below the inguinal ligament, between the vessels and the ligament of Gimbernath is located the femoral weak point, where femoral hernias are encountered [18].

6. The transversalis fascia

The transversalis fascia covers the totality of the myopectineal orifice, leaving just enough space for the passage of grand pedicles.

The transversalis fascia is not a true muscular aponeurosis, but in fact a fibrous layer situated between the deep face of the transverse muscle to which it adheres strongly and in front of the fatty tissue of fascia propria separating it from the peritoneal serosal layer.

The transversalis fascia is insignificant in the superior part of the abdomen, it becomes thicker below the layer of the arc of Douglas, where it gets the qualities of a true aponeurosis. Below the conjoint tendon level, the transversalis fascia continues to be frequently reinforced by the arciform fibrous bands, which are parallel to the transverse muscle fibers. It occupies the inguinal triangle of the myopectineal orifice and continues toward the posterior face of the rectus abdominis muscle. Outside and upward it forms a fibrous layer on which the cremaster muscles are attached. Likewise the deep inguinal ring is formed under which the inferior epigastric vessels pass. The fascia transversalis attaches to the posterior border of the inguinal ligament laterally and continues downward to form the femoral septum, and finally attaches strongly to the deep layer of the Cooper's ligament [16].

6.1. The reinforcements of the transversalis fascia

6.1.1. The ligament of Hesselbach

The ligament of Hesselbach or the interfoveolar ligament is a reinforcement of the transversalis fascia, which makes an upward-looking curve at the inferior border of the deep inguinal ring. Medially, it begins from the arc of Douglas, passes under the deep inguinal

ring and ascends laterally to be vanished in the deep face of the transverse muscle toward the anterosuperior iliac spine. The internal part of the ligament interferes with the fibrous sheet of the epigastric vessels. The ligament stretches by the contraction of the transverse muscle thus narrowing the deep ring of the inguinal canal opposing to the protrusion of visceral organs. It is probably a residual muscle because it is accompanied by some muscle fibers.

6.1.2. *The ligament of Henle*

The ligament of Henle is composed of fibers, which leave the external border of the rectus abdominis muscle and cover the internal part of the inguinal ligament. It continues below by the ligament of Gimbernat. Frequently, the ligament of Henle is not well identified. It is probably a residual muscle, like the ligament of Hesselbach [2, 15–18].

6.2. Aponeurotic layer of the external oblique muscle

The external oblique muscle extends from the posteroinferior costal intersections to the anterosuperior iliac spine. At the inguinal level, the muscle is represented only by an aponeurotic layer, which by its inferior border constructs the inguinal ligament extending from the anterosuperior iliac spine to the pubic spine. The fibers which are attached to the pubic spine are thicker and they form the lateral edge of the superficial ring of the inguinal canal (lateral crus). Other fibers, separated from the lateral edge of the superficial ring attach to the pubic symphysis and even transverse the midline. This is the internal edge or the medial crus. Between these two pillars opens the superficial orifice (superficial annulus) into which passes the spermatic cord.

Incisions performed in the direction of fibers of this aponeurosis of external oblique a little above the level of inguinal ligament and opening the superficial inguinal ring is indispensable for anterior approach of myopectineal orifice and the spermatic cord. The during hernia cure, the closure of the external oblique aponeurosis in front of the spermatic cord reestablishes the inguinal chicane. Certain authors (Jaboulay) place the sutures of external oblique aponeurosis in retrofunicular position, leaving likewise the spermatic cord under the skin [3, 16].

6.3. The skin and the subcutaneous tissue

The subcutaneous fascia of Camper lies in front of the external oblique aponeurosis, which is a lamellar organization of adipose tissue forming the suspensor ligament of penis in the midline.

In the same adipose tissue is found the superficialis fascia, which sometimes may be well organized to be mistaken as external oblique aponeurosis. Between the subcutaneous fascia and the superficialis fascia, an arterial network made up of small branches of arteries and specially, a venous network which converges toward the saphenous vein are present.

6.4. Posterior structures: Fascia propria, prevesical umbilical aponeurosis, peritoneum

The transversalis fascia layer is separated from the peritoneum by an adipose space, more or less thicker depending on the individual. This layer extends laterally to the Retzius space.

This space which is opened during the incision of the transversalis fascia above the Cooper's ligament is called the Bogros's space (**Figures 4, 5**). This space contains bulky anastomotic veins between the external iliac vein and the inferior epigastric vein. Hemorrhages during the dissection of this area may be quite difficult to control. The arteries named "corona mortis" may follow the ligament of Cooper posteriorly, which may be a cause of hemorrhages [3, 13, 19].

On the midline, the adipose tissue may hide the superolateral part of the urinary bladder, which may be engaged in a direct hernia or a femoral hernia.

Posterior to the fatty layer on the midline suspends the residual cords of ourach, in general well identified on the one-third inferior part, but tapering toward the umbilicus and the umbilical artery (corda arteria umbilicalis), which is located just lateral to it. These structures converge toward the umbilicus and unite by an aponeurosis called the umbilico-prevesical aponeurosis.

The parietal peritoneum covers these structures to form three fossae, which are important in the laparoscopic or the posterior approach of the groin region.

Between the ourach and the umbilical artery, the "internal inguinal fossa" where very rare internal inguinal hernias may occur; between the umbilical artery and the epigastric vessels or the "middle inguinal fossa" (fovea inguinalis medialis) where direct inguinal hernias may occur; and finally lateral to the epigastric vessels the "external inguinal fossa" (fovea inguinalis lateralis) where indirect inguinal hernias may occur.

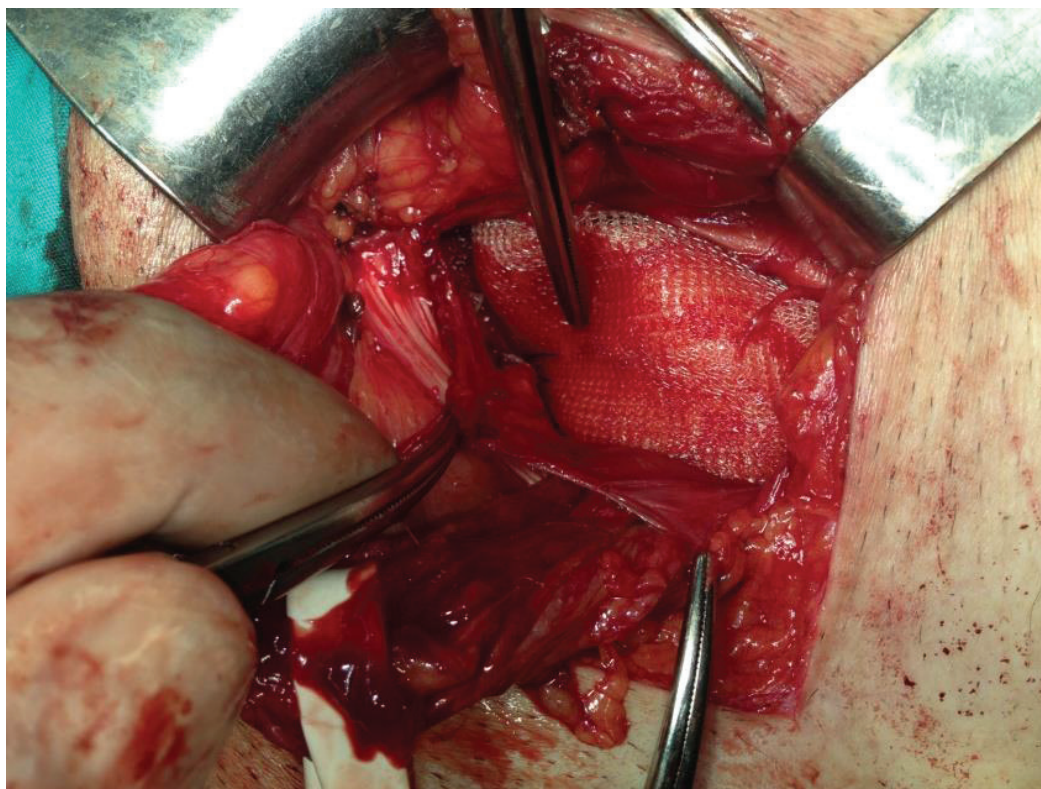


Figure 4. Mesh placement in preperitoneal space by anterior approach.

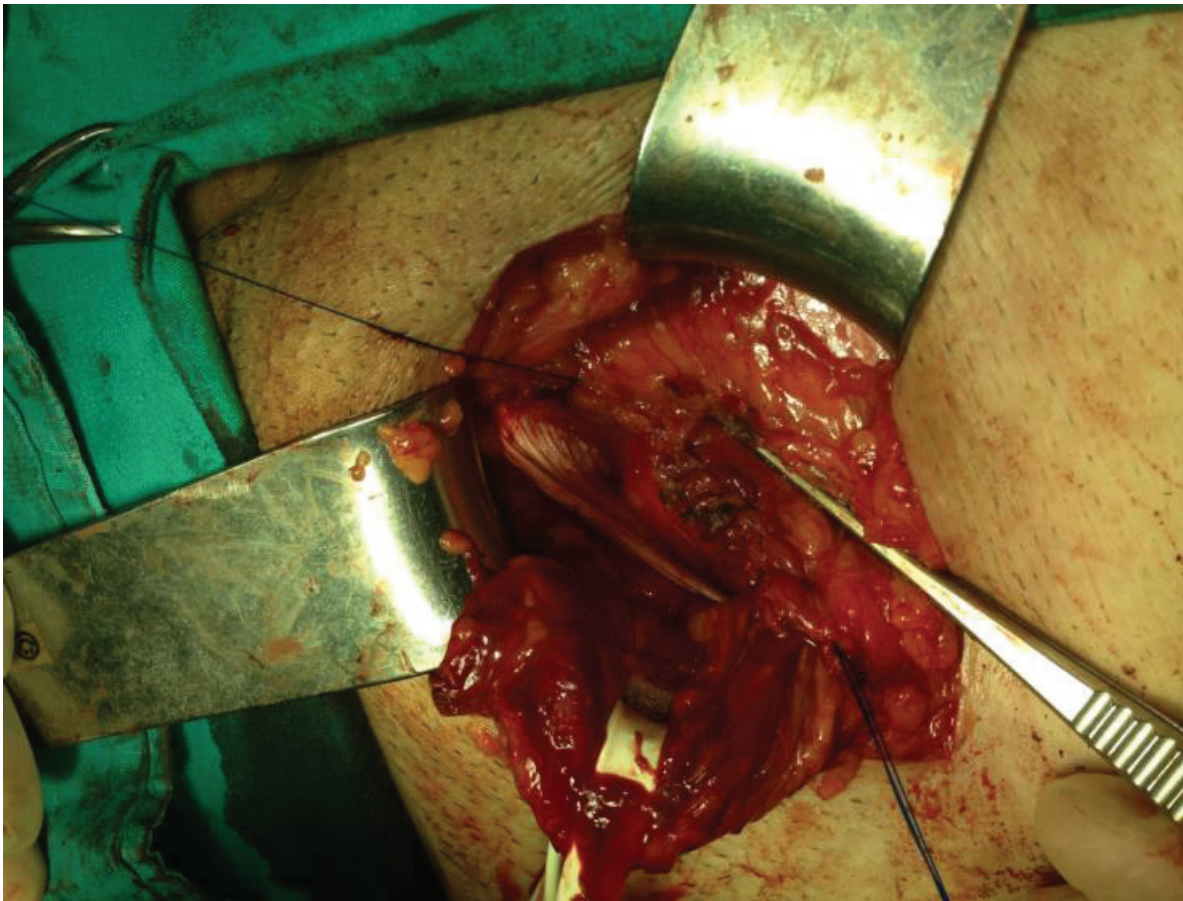


Figure 5. Closure of transversalis fascia after mesh placement in the preperitoneal space.

7. Vascularization

The vascularization of the superficial layers is abundant, which is supplied by the ramification of the superficial iliac circumflex vessels and the superficial epigastric vessels. The veins in the subcutaneous adipose tissue are particularly abundant. They join the saphenous vein inferiorly.

The lymphatic drainage of the anterolateral abdominal wall, the umbilical region, and sometimes even the mammary glands is toward the inguinal ganglions. This fact may explain some minimal lymphatic infections, which may be encountered after surgical cure of inguinal hernia.

The arterial blood supply of deep layers emerges from the deep circumflex iliac artery, the epigastric artery, and its branches, obturatorice-epigastric anastomoses connected to the descending branch of the epigastric artery, which follows the posterior face of the rectus abdominis muscle below the arc of Douglas.

The vascularization at the femoral level is reassured by the external pudendal arteries emerging from the femoral artery which are directed toward the internal and superior thigh, scrotum, or the labium majus.

The inferior epigastric vein, which is separated internally from the inferior epigastric artery before joining the femoral vein forms a unique trunk of about 3 cm. The femoral vein constitutes the principle surgical danger in this region [4, 12, 15].

8. Innervation

Numerous nerves exist in the inguinofemoral region. Their injury or capture between the sutures explains the relative frequency of the extremely invalidating postoperative pain. The reoperations or the attempt of neurolysis do not always ameliorate the situation. The two principle nerves of the region are the abdominogenital and the genitofemoral nerves.

8.1. Abdominogenital nerves

Iliohypogastric and ilioinguinal nerves arise from the lumbar plexus (level L1), follow a path between the external oblique and transverse muscles. Both nerves arrive the inguinal region just inside the anterosuperior iliac spine, they pierce the internal oblique muscle and follow a course parallel to the superficial fibers of the conjoint tendon. The anastomotic branches may exist between the two nerves. The ilioinguinal nerve, following the anterosuperior part of the spermatic cord, exits through the superficial inguinal ring and descends to the testicles. It supplies somatic sensation to the skin of the upper and medial thigh and innervates the base of the penis and labium majus in females. The nerve or one of its branches may be injured or entrapped between the sutures during hernia surgery [2, 4, 13].

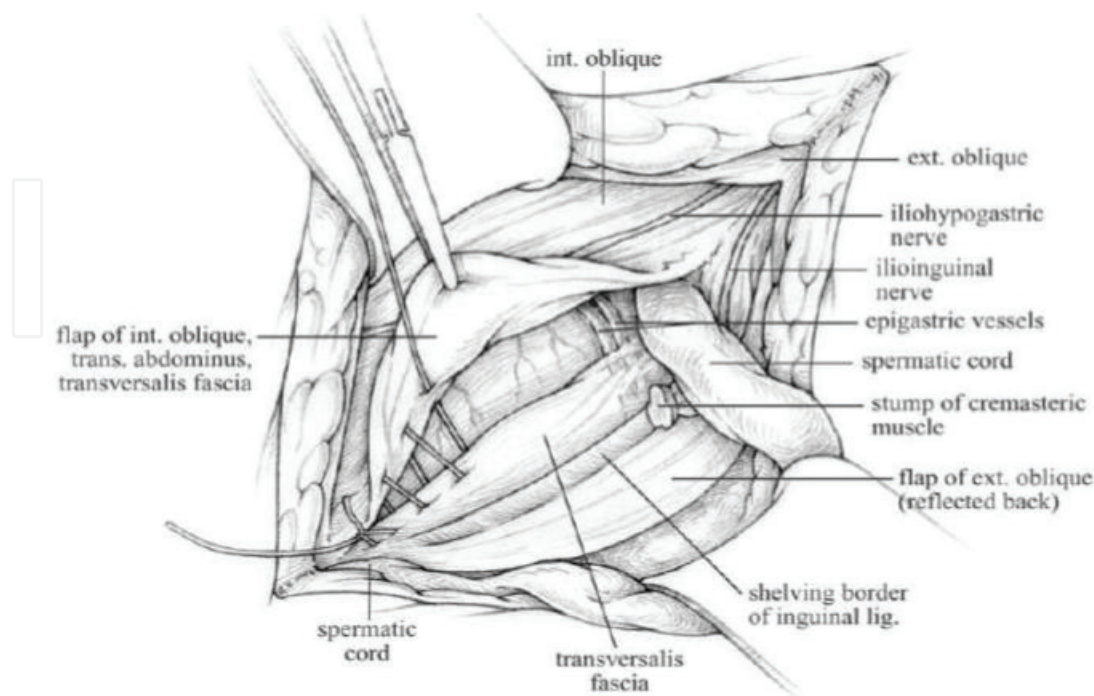


Figure 6. Inguinal anatomy anterior view.

8.2. Genitofemoral nerve

The genitofemoral nerve arises from L1-L2, follows the sheath of the psoas muscle, and divides into two branches. The femoral branch courses along the femoral sheath, descends to the thigh, supplying the skin of the upper anterior thigh. The genital branch reaches the spermatic cord at the level of the deep inguinal ring, lateral to the inferior epigastric vessels. During the dissection of the upper part of the spermatic cord, this nerve may be injured. Below, the nerve follows the inferior and deep part of the spermatic cord and finally gives branches to genital teguments. It may be injured during the dissection of the hernia sac or the cremaster muscle, which itself is innervated by the nerve [2, 4, 13].

8.3. Other nerves of the region

The lateral femoral cutaneous nerve, the femoral nerve, and the obturator nerve are exceptionally injured during hemostatic maneuvers in the adipose tissue of the space of Bogros. The lateral femoral cutaneous nerve arises from L2-L3, emerges lateral to the psoas muscle toward the anterior superior iliac spine. It then passes inferior to the inguinal ligament (**Figure 6**) [2, 4, 13].

9. The Nyhus classification system

The Nyhus classification categorizes hernia defects by location, size, and type [1].

Type I is an indirect hernia, the internal abdominal ring is normal, seen typically in infants, children, and young adults.

Type II is an indirect hernia, the internal ring is enlarged without impingement on the floor of the inguinal canal, which does not extend to the scrotum.

Type IIIA is a direct hernia, of which the size is not taken into account.

Type IIIB is an indirect hernia that has enlarged enough to encroach upon the posterior inguinal wall. The indirect sliding, pantaloon, or scrotal hernias are usually placed in this category because they are commonly associated with the extension to the direct space.

Type IIIC is a femoral hernia.

Type IV corresponds to recurrent hernia, modifiers A–D are sometimes added, which correspond to indirect, direct, femoral, and mixed, respectively.

10. Surgical approaches

10.1. Inguinal incision

Inguinal incision is placed on the half-distance between the external border of the rectus abdominis muscle and the inguinal ligament. This incision may equally be made 2 cm above

the line of Malgaigne. The inguinal incision permits the surgical treatment of all the varieties of inguinal or femoral nonstrangulated hernias. Likewise, the hernia sac is approached on the level above its collar. This approach is used in several operations, such as Mc Vay, Bassini, Shouldice, Lichtenstein, and so on (**Figures 6 and 7**).

10.2. Vertical approach

Vertical approach is frequently used for femoral hernias. The incision is traced internal to the femoral vessels, which ascend a couple of centimeters above the inguinal ligament. The approach to the inguinal ligament, which may eventually be sectioned, or the Cooper's ligament is possible with this incision, which is the incision of choice for strangulated femoral

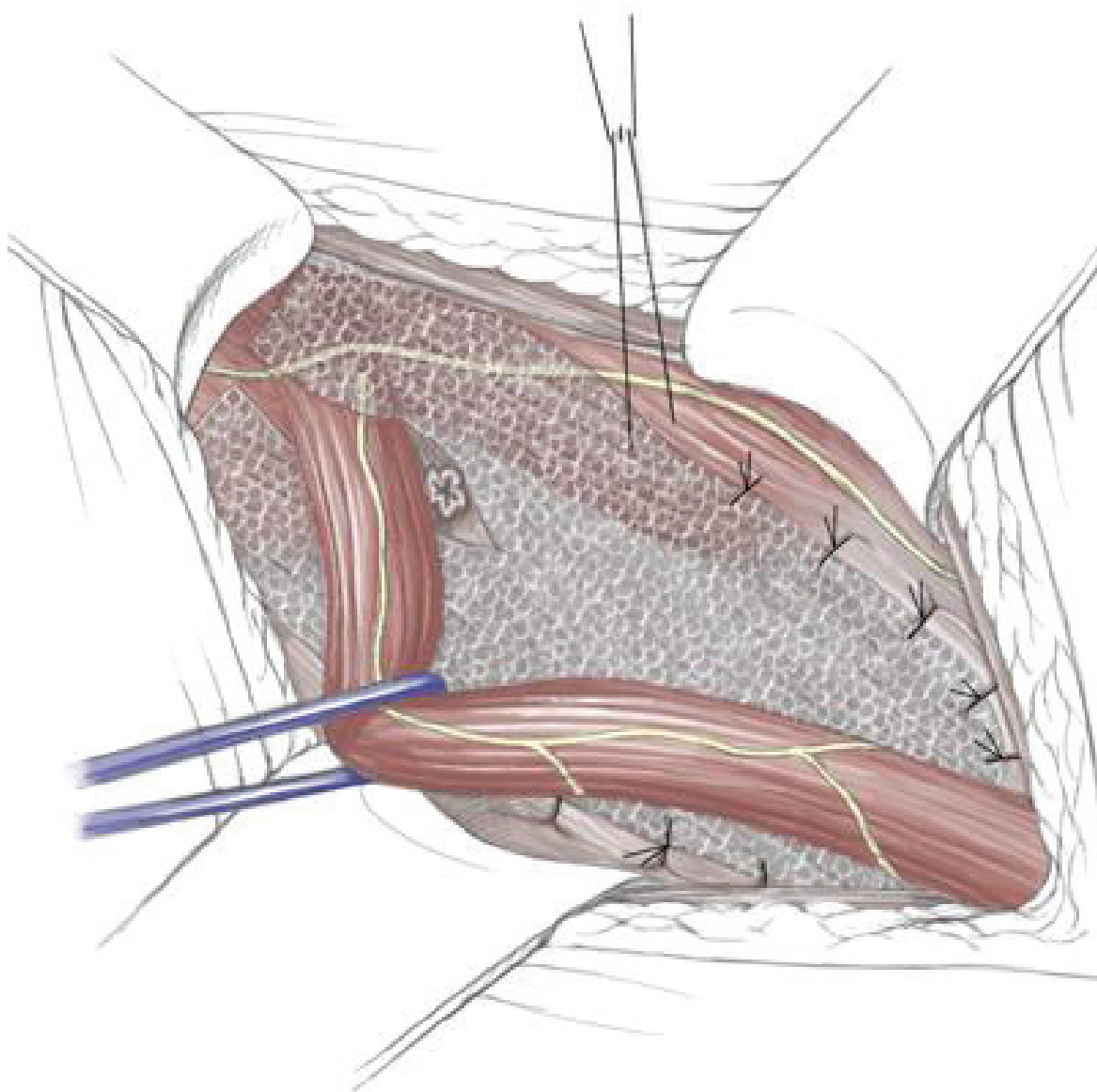


Figure 7. Lichtenstein's operation.

hernias. Direct approach of the hernia sac and verification of its contents and their reintegration in the abdominal cavity are possible.

10.3. Inguinal horizontal approach

The inguinal horizontal approach is comparable to the horizontalized Mc Burney incision, which gives rise to the direct approach of the peritoneum and dissecting the peritoneum inferiorly, the origin of the hernia sac may be identified facilitating its simple ligation without dissecting the spermatic cord. This approach is recommended in infants where the testicular pedicle is particularly fragile.

10.4. Infraumbilical extraperitoneal median incision

This longitudinal incision, after a blunt lateral dissection of preperitoneal space, makes it possible to see till the iliac vasculature. Likewise, the treatment of bilateral inguinal hernias is possible by ligation and section, to mobilize and dissect the spermatic cord and to place a synthetic mesh between the posterior face of the muscles and the peritoneum. This incision was introduced by Stoppa for the treatment of bilateral recurrences of inguinal hernias [20, 21].

10.5. Laparoscopic approach

The laparoscopic approach to hernia repair provides a posterior perspective to the peritoneal and preperitoneal spaces. The parietal peritoneum covers the deep layer of the abdominal wall above the inguinal ligament. On the midline suspends the residual cords of ourach or the *median umbilical ligament* which extends from the fundus of the bladder to the umbilicus. Corda arteria umbilicalis or the *medial umbilical ligament*, which covers the distal portion of the umbilical artery, is located just lateral to the precedent. The *lateral umbilical ligament* is the fold of peritoneum around the epigastric vessels.

These folds delineate three shallow fossae on either side of the midline: Supravesical, medial, and lateral fossae. Very rarely, internal inguinal hernias may occur in the supravesical fossa. The medial fossa is the region where direct hernias are encountered. The lateral fossa which lies lateral to the inferior epigastric vessels corresponds to the deep inguinal ring, the location of indirect hernias. Bogros's preperitoneal space, which contains preperitoneal fat and areolar tissue, is situated between the peritoneum and the posterior lamina of the transversalis fascia. The medial aspect of this space which corresponds to the superior region of the bladder is known as the space of Retzius.

The Cooper's ligament is viewed roughly in a horizontal direction. The bandelette of Thomson may be visualized in thin individuals after mobilization of the peritoneum.

The vascular space is situated between the posterior and anterior laminae of the transversalis fascia, and it houses the inferior epigastric vessels. The inferior epigastric artery supplies the rectus abdominis. It is derived from the external iliac artery, and it anastomoses with the superior epigastric, a continuation of the internal thoracic artery. The epigastric veins course parallel to

the arteries within the rectus sheath, posterior to the rectus muscles. Inspection of the internal inguinal ring will reveal the deep location of the inferior epigastric vessels.

The nerves pass from under or through the bandelette of the Thomson lateral to the external inguinal fossa and the spermatic vessels. The nerves of interest in the inguinal region are the ilioinguinal, iliohypogastric, genitofemoral, and lateral femoral cutaneous nerves.

The preperitoneal anatomy seen in laparoscopic hernia repair led to the characterization of important anatomic areas of interest, known as the “triangle of doom,” the “triangle of pain,” and the “circle of death.”

The triangle of doom is bordered medially by the vas deferens and laterally by the vessels of the spermatic cord, the summit of the triangle corresponding to the deep inguinal ring. The contents of the space include the external iliac vessels, the deep circumflex iliac vein, the femoral nerve, and the genital branch of the genitofemoral nerve.

The triangle of pain is a region bordered by the iliopubic tract above and the gonadal vessels below. The lateral femoral cutaneous, femoral branch of the genitofemoral, and femoral nerves may be injured in this region.

The circle of death (corona mortis) refers to the anastomotic branches of vasculature in this region formed by the common iliac, internal iliac, obturator, inferior epigastric, and external iliac vessels.

Author details

Kamer Tomaoglu

Address all correspondence to: kamertom@hotmail.com

Department of General Surgery, S.P. Hospital, Istanbul, Turkey

References

- [1] Nyhus LM, Condon RE, editors. Hernia. Philadelphia: JB Lippincott Company; 1995
- [2] Skandalakis LJ, Colborn GL. Surgical anatomy of the abdominal wall. 14. ed Vol 1, Bölüm 9, PMP Co, Athens: 2004, s. 395-491
- [3] Skandalakis LJ. Abdominal wall and hernias. In: Skandalakis JE, editor. Surgical Anatomy. 14th ed., Vol. 1, Bölüm 9. Athens: PMP Co; 2004. pp. 395-491
- [4] Wantz GE. Atlas of Hernia Surgery. New York: Raven Press; 1991
- [5] Skandalakis LJ. Modern Hernia Repair. Vol. 1. London: Catagologing Publishing; 1992

- [6] Wantz GE. Abdominal wall hernias. In: Schwartz SI, editor. Principles of Surgery. 7th ed., Vol. 2, Bölüm 34. Singapore: McGraw Hill Co; 1999. pp. 1585-1611
- [7] Glassow WF. A comparison of the Shouldice and Cooper ligament repair for adult inguinal hernias. The American Journal of Surgery. 1976;**131**:306-311
- [8] Nordin P, Bartelmess P, Jansson C, Svensson C, Edlund G. Randomized trial of Lichtenstein versus Shouldice hernia repair in general surgical practice. British Journal of Surgery. 2002;**89**:45-49
- [9] Bassini E. Nuovo metodo sulla cura radicale dell' ernia inguinale. Archives of Italian surgical society 1887;**4**:80
- [10] Shouldice EE. The treatment of hernia. Ontario Medical Review. 1953;**96**:1-14
- [11] Lichtenstein IL, Shulman AG, Amid PK, et al. The tension free hernioplasty. American Journal of Surgery. 1989;**157**:188-192
- [12] Cooper A. The Anatomy and Surgical Treatment of Abdominal Hernia. London: Longman and Co.; 1804
- [13] Fruchaud H. Anatomie chirurgicale des hernies de l'aine. Paris: G. Doin; 1956
- [14] Radojevic S. Anatomie chirurgicale de la region inguinale. Acta Anatomica. 1962;**50**: 208-263
- [15] Gray FJ. The applied anatomy of the inguinal region. Australian and New Zealand Journal of Surgery. 1961;**30**:183-190
- [16] Mcvay CB, Anson BJ. Aponeurotic and fascial continuities in the abdomen, pelvis and thigh. Anatomical Record. 1940;**76**:213-231
- [17] Romanes GJ, editor. Cunningham's Textbook of Anatomy. 10th ed. London: Oxford University Press; 1964. p. 302
- [18] Chandler SB, Schadewald M. Studies on the inguinal region. I. The conjoined aponeurosis versus the conjoined tendon. Anatomical Record. 1944;**89**:339-343
- [19] Masereeuw J. Contributions to the structural anatomy of the inguinal region. Acta Anatomica. 1966;**64**:179-197
- [20] Stoppa R. Traitement par voie préperitonéale des hernies de l'aine de l'adulte. Encycl Medico Chir Tech Chir. 2000;**1**:40-115
- [21] Wantz GE. Une technique de hernioplastie propéritonéale. Le renforcement unilatéral du sac viscéral par grande prothèse de Mersilène. Chirurgie. 1993-1994;**119**:321-326

