

We are IntechOpen, the world's leading publisher of Open Access books Built by scientists, for scientists

6,900

Open access books available

186,000

International authors and editors

200M

Downloads

Our authors are among the

154

Countries delivered to

TOP 1%

most cited scientists

12.2%

Contributors from top 500 universities



WEB OF SCIENCE™

Selection of our books indexed in the Book Citation Index
in Web of Science™ Core Collection (BKCI)

Interested in publishing with us?
Contact book.department@intechopen.com

Numbers displayed above are based on latest data collected.
For more information visit www.intechopen.com



Congenital Diseases of Esophagus

Mehrdad Hosseinpour and Bahareh Ahmadi

Additional information is available at the end of the chapter

<http://dx.doi.org/10.5772/intechopen.69577>

Abstract

Esophageal atresia (EA) presents some of the greatest technical hurdles that pediatric has to face. Postnatally, the classical clinical presentation of an infant with EA is an abnormally mucousy infant who is drooling excessive amount of saliva. Diagnosis confirmed when an orogastric tube cannot be passed through the mouth into the stomach. Examination should assess the as cardiac, anal limb. The purpose of the surgery is to divide the trachea esophageal fistula (TEF) and to restore esophageal continuity blind-ending upper esophageal. Achalasia is an uncommon disorder of esophagus dysmotility. Patients typically present with a history of progressively worsening dysphagia that begins with solid foods. The initial diagnosis test in child with dysphasia is usually a contrast esophagogram. Classic findings include a dilated, dysmotile esophagus and a bird's beak deformity at the gastroesophageal junction. The main treatments of achalasia are esophageal myotomy, balloon dilation or botulism toxin. Esophageal diverticula are often first suspected on Chest X ray(CXR) due to presenting symptoms. These lesions can cause wheezing, dyspnea, hemoptysis and recurrent pneumonia due to airway compression and dysphasia due to esophagus compression. These duplications should be further investigated by CT scan or Magnetic resonance imaging (MRI). The preferred method of treatment is thoracoscopy or thoracotomy.

Keywords: esophageal atresia, esophageal diverticula, achalasia

1. Esophageal atresia

1.1. Embryology

Esophageal atresia (EA) and trachea esophageal fistula (TEF) are important human birth defects of unknown etiology and represent a challenge to the pediatric surgeons. The great

majority of cases of EA and TEF occur as sporadic events. However, there is emerging evidence of an important role for genetic factors.

Embryologically, the respiratory system is derived from the foregut endoderm with the appearance of the laryngo tracheal groove in the ventral floor of the foregut, just caudal to the level of the pharynx [1].

In broad terms, there have been two contrasting theories to explain how the respiratory foregut separates from the gastrointestinal foregut.

In first theory, the respiratory system develops as a result of rapid outgrowth from the original foregut tube [2], but in an alternative theory, there is active growth of a mesenchymal septum which develops in the coronal plane and, as a result, separates the foregut lumen into ventral (respiratory) and dorsal (gastrointestinal) structures [3]; however, direct evidence of septum formation has been lacking, casting doubt on this theory.

The separate process occurs in human embryo between 28 and 37 days of postfertilization. A number of theories have been put forward for disturbed TE malformation, which themselves reflect the theories of normal development.

In first theory, the normal development of trachea is the result of rapid longitudinal growth of the tracheal primordium away from the foregut, and TE malformation is caused by a failure of tracheal growth, the result of which is a compensatory overgrowth of the undivided foregut with the bronchopulmonary buds originating directly from the foregut [4].

In second theory, failure of separate process of ventral trachea and dorsal esophagus is the main cause of TE malformations [5].

Interestingly, EA is not a part of this initial malformation. Atretic proximal esophagus is a result of late rearrangement of the cranial foregut, resulting in a blind-ending structure.

Finally, genetic models show that the expression of some factors is fundamental for separation of anterior foregut and loss of this dorsoventral boundary expression domains disrupts the physical separation of the foregut [3].

1.2. History and classification

The first survivors of EA and TEF were not recorded until 1939 with Leven and Ladd achieving success with staged esophageal repair. Cameron Haight is fully credited with the first successful primary repair and survival of a 12-day-old female neonate [6].

In 1929, Vogt proposed the first anatomical classification of EA and TEF, based on radiological and postmortem findings. **Figure 1** and **Table 1** show a working classification based on the frequency of each anomaly (gross classification).

1.3. Associated anomalies

EA can be divided clinically into isolated EA and syndromic EA, occurring at the same rate. The most frequent associated malformations encountered in syndromic EA are [7]:

Cardiac (20–30%)

Vertebra (10–15%)

Limb (5–19%)

Anorectal (15–25%)

Renal (5–14%)

Nonrandom association has been documented as well. Two of these are the VACTERL (Vertebral, Anorectal, Cardiac, Tracheo-Esophageal, Renal and Limb abnormalities) and CHARGE association (Coloboma, Heart defects, Atresia of choan, developmental Retardation, Genital hypoplasia and Ear deformities).

1.4. Clinical presentation

A newborn with EA is often noted to have difficulty clearing saliva. Episodes of coughing, choking and even transient cyanosis may be observed.

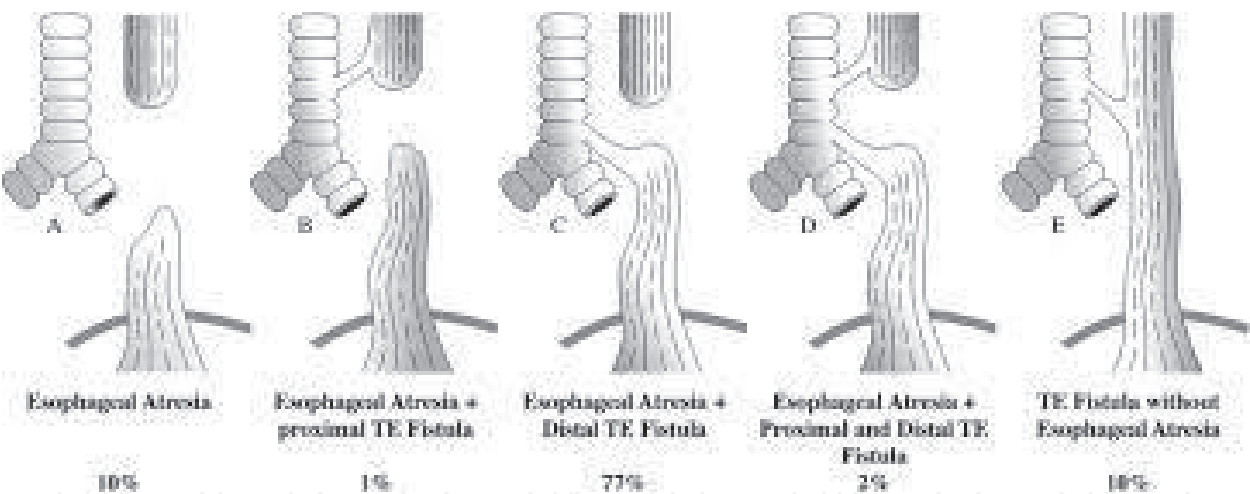


Figure 1. Schematic presentations of EA and TEF.

Type C	85%	EA and distal TEF
Type A	7%	Isolated EA
Type E	4%	TEF without EA
Type D	3%	EA and proximal and distal fistula
Type B	1%	EA proximal fistula

Table 1. Gross classification of EA and TEF.

1.5. Diagnosis

1.5.1. Antenatal

1. Polyhydramnios
2. Absence of stomach bubble in sonography

1.5.2. Postnatal

The diagnosis of EA and TEF is confirmed by the failure of passage of a firm nasogastric tube. Coiling of the tube can be demonstrated in plain chest and abdominal X-ray (**Figure 2**). Presence of gas-filled intestine loops below the diaphragm is a landmark of associated TEF. In isolated EA, a featureless gasless abdominal X-ray is observed.

1.6. Preoperative preparation

After a complete physical examination, routine blood work including cross match should be performed.

Other evaluations are included as:

1. Preoperative echocardiogram (to assess for major structural abnormalities, the position of aortic arch)
2. VACTERL workup
3. Genetic consultation

1.7. Operative technique

Extrapleural approach through the right fourth intercostal space allows the identification of azygos vein, TEF and upper pouch. Division of TEF and primary anastomosis of the esophagus are essential elements of operative technique. TEF is identified along the vagus nerve. TEF is encircled by tape and divided nearly trachea and closed. One-layer stitch anastomosis is the most standard procedure for end-to-end anastomosis [8].

1.8. Postoperative care

The infant should be nursed in the intensive care unit following repair of EA and TEF. Intravenous fluids and broad spectrum antibiotics are continued. Weaning from ventilation need not to be unduly prolonged in the stable infants with satisfactory anastomosis. In most cases, transanastomotic tube feeding can be commenced after 48 h and slowly increased as tolerated by the infant.

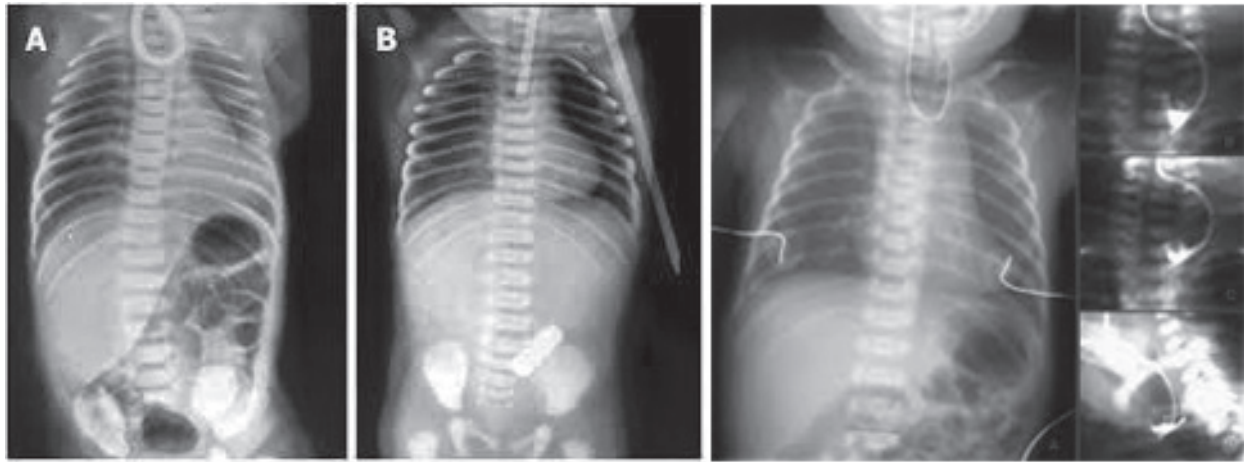


Figure 2. Example of a CXR demonstrating EA.

2. Achalasia

2.1. Embryology

Achalasia is an uncommon disorder of esophageal dysmotility, with an annual incidence of only one in 100,000 individuals.

Achalasia is derived from Greek word, meaning ‘no relaxation’ of the lower esophageal sphincter (LES). It is suggested that the cause of achalasia is ischemia following excessive rotation of the gut as a volvulus in utero in the embryo which selectively destroys ganglion cells [9]. Other tissues recover but neurons do not regenerate, leaving denervated gut forever.

In normal swallowing, coordinate peristaltic contractions of the esophageal body and transient relaxation of the LES cause the antegrade propulsion of ingested foods.

In patients with achalasia, this normal relaxation fails to occur. Patients with achalasia often have a reduced number of ganglion cells, and the ganglion cells are surrounded by an inflammatory infiltrate. It seems that the primary pathology must be in the wall of the gut and not in the CNS. This ganglion cell loss is best seen in Auerbach’s plexus between the esophageal muscle layers.

In second theory, an autoimmune mechanism, which is the progressive partial destruction of the ganglion cells and the inhibitory neurons that normally mediate LES relaxation, is the main cause of Achalasia.

2.2. History

Achalasia/cardiospasm was first described by Sir Thomas Wills in 1672. In 1881, Von Mikulicz described the disease as a functional problem, but Heller (1913) was the first surgeon to perform esophagomyotomy successfully [10].

2.3. Associated anomalies

Achalasia in children has been associated with trisomy 21, triple-A syndrome (achalasia, alacrima and AcTH insensitivity) and familial dysautonomia, but most are sporadic.

2.4. Clinical presentation

In pediatric practice, most achalasia is reported during adolescence, more often in boys. Typical symptoms include dysphagia, vomiting or regurgitation of food, chest pain and weight loss or failure to thrive. Adolescents with achalasia usually suffer from halitosis. In children, respiratory symptoms consistent with aspiration may occur.

Bronchiectasis has also been reported due to recurrent aspiration specially in Down's syndrome cases.

2.5. Diagnosis

2.5.1. Contrast study

The initial test in the child with dysphagia is usually contrast esophagogram in supine and upright positions. Classic findings include a dilated esophagus and a 'bird beak' deformity at the gastro-intestinal junction (GEJ) (**Figure 3**). In long standing disease, the progressively redundant esophagus can adopt a sigmoid shape.

2.5.2. Manometry

The standard test for achalasia remains manometry. Pressure recording shows absent or diminished peristalsis in the upper esophagus, elevated LES pressures, and minimal or absent LES relaxation.

2.5.3. Endoscopy

Endoscopy may demonstrate pooling of retained fluid within the esophagus and stasis-induced inflammation. Although mild resistance is encountered in endoscopy, but it can be passed in to the stomach, ruling out of mechanical stricture.

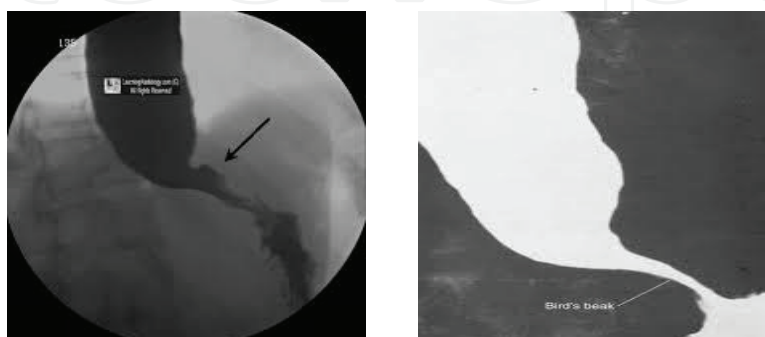


Figure 3. Esophagogram demonstrating the 'bird's beak' deformity of achalasia.

2.6. Nonoperative management

2.6.1. Balloon dilation

Balloon dilation of the LES is the most common nonoperative management in achalasia in children; however, symptomatic relief is transient, and thus, repeated dilations are required.

2.6.2. Intrasphincteric toxin injection

Botulinum toxin injection lowers Les pressure by inhibiting acetylcholine release from nerve endings. This effect is also transient, requiring repeated injection [11].

2.7. Operative technique (modified Heller's cardiomyotomy)

Cardiomyotomy for achalasia requires division of the lower esophageal sphincter. This can be accomplished with a thoracic or abdominal approach, open or minimally invasively, with or without a concomitant antireflux procedure [12, 13].

3. Esophageal diverticulum

Esophageal diverticulum is a sac or pouch that protrudes from the esophageal wall, and it is rare in children. It is thought to be caused by an increase in the intraesophageal pressure associated with either distal esophageal motility disorders or periesophageal inflammation [14].

Esophageal diverticulum characterized according to their pathogenesis as either traction or pulsion. Traction diverticula are true that occur in the mid esophagus secondary to inflammation process in the mediastinum causing an external force on the esophagus.

Pulsion diverticula is a pseudodiverticulum. There are two types of pulsion diverticula: Zenker diverticula and epiphrenic diverticula. Epiphrenic diverticula occur with increased pressure against the upper and lower esophagus sphincters.

Zenker diverticulum (ZD) is a false diverticulum of the posterior esophagus between the cricopharynx and inferior constrictor. This area of anatomical weakness is known as Killian's triangle. ZD occurs with high intraluminal pressure created during swallowing [15]. ZD is more likely to occur with increased size of Killian's triangle [16]. Majority of these cases involve anatomical esophageal deformities or iatrogenic injury in the early postnatal period [17].

Esophageal diverticulum is classified into three categories according to the site of development: pharyngoesophageal diverticulae, bifurcation diverticulae and epiphrenic ones [18].

Pediatric esophageal diverticula were classified according to their physiology by Meadows in 1970 [16]. He described nine types of diverticula in children and infants: cricopharyngeal diverticulum, pulsion diverticulum (Zenker types), duplication of esophagus (epiphrenic and nonepiphrenic), traction diverticulum from the middle third of the esophagus, diverticulum

arising in scar tissue, false diverticulum above a congenital stenosis, and traumatic pseudo-diverticulum after trachea esophageal fistula repair. Only nonepiphrenic duplication, traumatic, pulsion and congenital diverticula may involve the pharyngoesophageal junction.

Duplication of the esophagus results from a defect in tabulation of esophagus in division of the embryonic foregut [19]. These duplication cysts consist of double layers of smooth muscle that are covered with epithelium. Two-third of them are located in lower third and one-third in the upper/middle third of esophagus [20]. Mostly, they do not communicate with esophagus wall but the duplication cysts as a separate malformation locate along or in continuity with native esophagus [21].

Esophageal duplication cysts can be associated with other congenital anomalies such as small intestinal duplication, esophageal atresia, trachea esophageal fistula, and spinal abnormalities including scoliosis, hemivertebra and fusion [19, 22].

Traumatic pharyngeal pseudodiverticulum is caused in neonates by traumatic catheterization through the esophagus causing perforation of the pharynx and incorrect insertion of a nasogastric tube [23, 24].

Congenital pharyngoesophageal diverticulum is a true diverticulum that contains all normal esophageal musculomucosal layers. Few cases are reported that allow no valid conclusions as to their etiology [25].

Pulsion diverticulum is rare in children, and the reported cases were 6-month- to 10-year-old children. Some related mechanisms include incoordination between movement of food out of the mouth and relaxation of the cricopharyngeal, motility disorder and developmental muscle weakness [16, 26, 27]. No clinical or radiological differences exist between pharyngoesophageal diverticulum and pulsion diverticulum; both are posterior diverticulum that only distinguished by histological exams [28].

Chronic impaction of the foreign body has been proposed as the activating factor of pharyngoesophageal diverticula [27]. Foreign body ingestion is frequent in children, especially between 6 months and 3 years of age [29]. Majority of them travel the gastrointestinal tract without any adverse effects [30]. The cricopharyngeal sphincter is a well-known area of upper digestive tract, narrowing where foreign bodies are likely to get blocked. It is hypothesized that chronic impaction of the foreign body at the level of the cricopharyngeal muscle-induced muscle hypertonia responsible for the development of the pouch [28].

3.1. History

- (1) Gastrointestinal symptoms: gagging, dysphagia, odynophagia, vomiting, regurgitation, dysphagia, failure to thrive, anorexia, epigastric pain, gastrointestinal hemorrhage, halitosis and poor feeding [31, 32].
- (2) Respiratory symptoms: choking, cyanosis [17], dyspnea, wheeze, cough, stridor, respiratory distress [31], recurrent bronchiolitis, pneumonia and aspiration [32].

3.2. Diagnosis

- Barium swallow
- CT scan
- Esophageal endoscopy

3.3. Treatment

The management of esophageal diverticula includes both conservative and surgical treatments. If the child is asymptomatic, conservative treatment and careful follow-up are recommended. However, when the patient has complications related to esophageal diverticula, then surgical treatment is considered [33].

The traditional surgical treatment for esophageal diverticula is either a diverticulectomy or a diverticulopexy. However, in recent years, minimally invasive surgery such as thoracoscopic or laparoscopic treatment has become popular.

Recently, flexible endoscopy using CO₂ laser technique has been developed for the treatment of esophageal diverticula [34].

3.4. Postoperative care

Most of patients show no symptoms and are discharged from the hospital. In some center, esophageal endoscopy is done after months, later to show existence of narrowing or residual diverticulum in esophagus.

Author details

Mehrdad Hosseinpour* and Bahareh Ahmadi

*Address all correspondence to: meh_hosseinpour@yahoo.com

Imam Hossein Children Hospital, Isfahan University of Medical Sciences, Isfahan, Iran

References

- [1] Ten Have-Opbroek AAW. Lung development in the mouse embryo. *Experimental Lung Research*. 1991;**17**:111-130
- [2] Sasaki T, Kusafuka T, Okada A. Analysis of the development of normal foregut and tracheoesophageal fistula in an adriamycin rat model using three-dimensional image reconstruction. *Surgery Today*. 2001;**31**(2):133-139

- [3] Ioannides AS, Copp AJ. Embryology of oesophageal atresia. *Seminars in Pediatric Surgery*. 2009;**18**(1):2-11
- [4] Merei J, Hasthorpe S, Farmer P, Huston JM. Relationship between esophageal atresia with tracheoesophageal fistula and vertebral anomalies in mammalian embryo. *Journal of Pediatric Surgery*. 1998;**33**(1):58-63
- [5] Williams AK, Quan QB, Beasley SW. Three dimensional imaging clarifies the process of tracheoesophageal separation in the rat. *Journal of Pediatric Surgery*. 2003;**38**(2):173-177
- [6] Harmon C, Coran A. Congenital anomalies of the oesophagus. In: Coran A, Adzick NS, Krummel T, editors. *Paediatric Surgery*. Philadelphia: Elsevier; 2012. p. 892
- [7] Baird R, Laberge JM. Esophageal atresia and tracheoesophageal fistula. In: Mattei P, editor. *Fundamental of Paediatric Surgery*. Philadelphia: Springer; 2011. pp. 257-267
- [8] Taguchi T. Standard operation for esophageal atresia. In: Taguchi T, Iwanaka T, Okamatsu T, editors. *Operative General Surgery in Neonates and Infants*. Japan: Springer; 2016. pp. 95-100
- [9] Franklin AL, Petrosyan M, Kane TD. Childhood achalasia: A comprehensive review of disease, diagnosis and therapeutic management. *World Journal of Gastrointestinal Endoscopy*. 2014;**6**(4):105-111
- [10] Moreau P. Achalasia. In: Parikh DH, Crabbe DC, Auldist AW, Rothenberg SS, editors. *Paediatric Thoracic Surgery*. London: Springer; 2009. pp. 335-340
- [11] Hurwitz M, Bahar RJ, Ament ME, et al. Evaluation of the use of botulinum toxin in children with achalasia. *Journal of Pediatric Gastroenterology and Nutrition*. 2000;**30**:509-514
- [12] Nau P, Rattner D. Laparoscopic Heller myotomy as the gold standard for treatment of achalasia. *Journal of Gastrointestinal Surgery*. 2014;**18**(12):2201-2207
- [13] Patti MG, Albanese CT, Holcom GW III, et al. Laparoscopic Heller myotomy and Dor fundoplication for esophageal achalasia in children. *Journal of Pediatric Surgery*. 2001;**36**:1248-1251
- [14] Van der Peet DL, Klinkenberg-Knol EC, Berends FJ, Cuesta MA. Epiphrenic diverticula: Minimal invasive approach and repair in five patients. *Diseases of the Esophagus*. 2001;**14**:60-62
- [15] Rush LV, Stingily CR. Congenital diverticulum of the esophagus: Case report. *Southern Medical Journal*. 1929;**22**:546
- [16] Meadows JA. Esophageal diverticula in infants and children. *Southern Medical Journal*. 1970;**63**:691-694
- [17] Lindholm EB, Hansbourg F, Upp JR, Cilloniz R, Lopo J. Congenital esophageal diverticulum — a case report and review of literature. *Journal of Pediatric Surgery*. 2013;**48**:665-668
- [18] Akagi M, Sugano S, Kato I. Two cases of esophageal diverticula. *Acta Oto-Laryngologica*. 1996;**522**:138-141

- [19] Ratan ML, Anand R, Mittal SK, Taneja S. Communicating oesophageal duplication: A report of two cases. *Gut*. 1988;**29**(2):254-256
- [20] Lio R, Aler DG. Duplication cysts: Diagnosis, management, and the role of endoscopic ultrasound. *Endoscopic Ultrasound*. 2017;**3**(3):152-160
- [21] Wootton-Gorges SL, Eckel GM, Poulos ND, Kappler S, Milstein JM. Duplication of the cervical esophagus: A case report and review of the literature. *Pediatric Radiology*. 2002;**32**:533-535
- [22] Sethi GK, Marsden J, Johnson D. Duplication cysts of the esophagus. *South Medical Journal*. 1974;**67**:616-618
- [23] Ducharme JC, Bertrand R, Debie J. Perforation of the pharynx in the newborn: A condition mimicking esophageal atresia. *Canadian Medical Association Journal*. 1971;**104**(9):785-787
- [24] Wang B, Hunter WJ, Bin-Sagheer S, et al. Rare potential pitfall in endoscopic ultrasound-guided fine needle aspiration biopsy in gastric duplication cyst: A case report. *Acta Cytologica*. 2009;**53**:219-222
- [25] Pal K, Alwabari A, Abdulatif M. Traumatic pharyngeal pseudodiverticulum mimicking esophageal atresia. *Indian Journal of Pediatrics*. 2007;**74**(2):195-196
- [26] Theander G. Congenital posterior midline pharyngo-esophageal diverticula. *Pediatric Radiology*. 1973;**1**(3):153-155
- [27] Dokucu AI, Fabre M, Otçu S, Sari UI, Onen A, Oztrk H, et al. Zenker's diverticulum in childhood: A new case. *European Journal of Pediatric Surgery*. 2000;**10**(3):191-193
- [28] Kobayashi T. Esophageal foreign bodies in children. *International Journal of Pediatric Otorhinolaryngology*. 1984;**7**(2):193-198
- [29] Patron V, Gody B, Aubry K, Jegoux F. Endoscopic treatment of pharyngo-esophageal diverticulum in child. *International Journal of Pediatric Otorhinolaryngology*. 2010;**74**:694-697
- [30] Little DC, Shah SR, St Peter SD, Calkin CM, Morrow SE. Esophageal foreign bodies in the pediatric population: Our first 500 cases. *Journal of Pediatric Surgery*. 2006;**41**:914-918
- [31] McGahren ED. Esophageal foreign bodies. *Pediatrics in Review*. 1999;**20**:129-133
- [32] Arana A, Hauser B, Hachimi-Idrissi S, et al. Management of ingested foreign bodies in childhood and review of the literature. *European Journal of Pediatrics*. 2001;**160**:468-472
- [33] Arboya JL, Fazzi JGF, Mayhoral J. Congenital esophageal cysts: Case report and review of the literature. *American Journal of Gastroenterology*. 1984;**79**:177-182
- [34] Nishimoto Y, Taguchi T, Ogita K, Hashizume M. Endoscopic diverticulotomy for symptomatic paediatric esophageal diverticula. *Pediatric Surgery International*. 2005;**21**:50-53

