

We are IntechOpen, the world's leading publisher of Open Access books Built by scientists, for scientists

6,900

Open access books available

185,000

International authors and editors

200M

Downloads

Our authors are among the

154

Countries delivered to

TOP 1%

most cited scientists

12.2%

Contributors from top 500 universities



WEB OF SCIENCE™

Selection of our books indexed in the Book Citation Index
in Web of Science™ Core Collection (BKCI)

Interested in publishing with us?
Contact book.department@intechopen.com

Numbers displayed above are based on latest data collected.
For more information visit www.intechopen.com



Treatment Considerations for Missing Teeth

Abdolreza Jamilian, Alireza Darnahal,
Ludovica Nucci, Fabrizia D'Apuzzo and
Letizia Perillo

Additional information is available at the end of the chapter

<http://dx.doi.org/10.5772/intechopen.69543>

Abstract

Specific terms are used to describe the nature of tooth agenesis. Hypodontia is most frequently used when describing the phenomenon of congenitally missing teeth. Many other terms to describe a reduction in the number of teeth appear in the literature: oligodontia, anodontia, aplasia of teeth, congenitally missing teeth, absence of teeth, agenesis of teeth and lack of teeth. The term hypodontia is used when one to six teeth, excluding third molars, are missing, and oligodontia when more than six teeth are absent (excluding the third molars). The long-term management of hypodontia in the aesthetic zone is a particularly challenging situation. Although there are essentially two distinct approaches to manage this problem, that is space closure or opening for prosthetic replacements, implant or autotransplantation. These patients often manifest with many underlying skeletal and dental problems and a multidisciplinary approach for management of this condition is recommended. Two treatment approaches including space closure and space reopening are described in details in this chapter.

Keywords: hypodontia, missing teeth, implant, orthodontic space closure, space reopening

1. Introduction

Missing is one of the most dental anomalies in practice of dentistry and they may affect the self-esteem and social well-being of the patients. This condition is often complicated by dental anomalies associated with hypodontia such as impacted teeth, microdontia, delayed eruption and taurodontism. Hypodontia reportedly affects between 3 and 8% of the population. Hypodontia is a common problem seen by the general dentist and is usually referred to the orthodontist [1, 2]. Agenesis means that a dental bud fails to develop or is not present at birth.

This problem leaves an empty space in the arch which causes plentiful problems. Specific terms have been used to describe the nature of tooth agenesis.

- Anodontia is named complete absence of teeth.
- Hypodontia means missing teeth, but usually less than six teeth.
- Oligodontia or partial anodontia is defined absence of six or more teeth.

Anodontia and oligodontia are rare; however, hypodontia is relatively a common problem. Many other terms are also used to describe a reduction in the number of teeth in the literature such as aplasia of teeth, agenesis of teeth, absence of teeth, lack of teeth and congenitally missing teeth [3, 4].

The aims of this chapter are as follows:

- To determine the prevalence of hypodontia
- To assess the etiology of hypodontia
- To diagnose the problem
- To plan the treatment
- To decide the open or close space in the dentition

2. Prevalence of hypodontia

Hypodontia in primary dentition arises in 0.1–0.9% of the population, with equal frequencies in both males and females. This problem is more common in the upper jaw and it is frequently related with the upper lateral incisor in the primary dentition. As a general rule, when the primary tooth is missing, its permanent counterpart will be missing [1]. Hypodontia in the permanent dentition occurs with equal rate in the upper and lower arches and usually affects the third molar. The type of agenesis in dentition and prevalence of missing vary with racial and ethnic groups. However, females are more frequently affected [2]. Prevalences of hypodontia vary between 1.6 and 9.6% across the world with exclusion of the third molars. Prevalence of agenesis differs between continents and races. The occurrence of missing permanent teeth, excluding the third molar is 3.4% in Swiss, 4.4% in the USA, 6.1% in Sweden, 8% in Finland and 9.6% in Austria with exclusion of third molar. Japanese people have the highest rates of agenesis both in primary and permanent dentition. Australian Aborigines and African Blacks might have a low rate of missing teeth. The rate of agenesis in Indians has been reported less than 1% [3, 4]. The prevalence of third molar missing has been reported of 9–37% [2]. Hall [5] reported that upper lateral incisors are the most agenesis teeth (not including third molars). Missing of the upper lateral incisor is also related to anomalies such as agenesis of other permanent teeth, undersized maxillary lateral incisors (peg laterals), palatally position of canines and distal displacement of lower second premolars [6–8]. Agenesis may arise in isolation, or as part of a syndrome. Dental anomalies, especially hypodontia, have frequently been found in children who also have cleft lip and cleft palate or a syndrome [9–11].

3. Etiology of hypodontia

Heredity and familial distribution are two of the possible factors associated with congenitally missing teeth. Shapira, et al. stated [12], 'Congenital partial anodontia appears to be the result of one or more point mutations in a closely linked polygenic system, most often transmitted in an autosomal dominant pattern incomplete penetrance and variable expressivity'. Genetics has a crucial role in hypodontia, as confirmed by the studies on monozygotic twins. The pattern of agenesis can differ between monozygotic twins, this issue possibly pointing to additional underlying mechanisms such as epigenetic factors, which might be implied occurrence of two anomalies simultaneously [13]. Genetic, epigenetic and environmental factors contribute to the development of hypodontia. It has been shown that genetics has a predominant role in the etiology of missing teeth [14]. Infection, trauma and drugs, as well as genes associated with syndromes play a crucial role in hypodontia. Agenesis may be an isolated condition or a dental appearance of special syndromes such as cleft lip and palate [9, 15, 16] and ectodermal dysplasia [17]. The isolated one can follow autosomal recessive, dominant, or X-linked patterns of inheritance [18]. Some studies showed that some anomalies such as bimaxillary retrusion, mandibular prognathism, decreased maxillary jaw size and reduced vertical facial dimension in patients affected with hypodontia [19, 20]. In hereditary cases, missing has greater incidence when the dental germ is developing after the adjacent tissues have closed the space needed for the tooth development. Other scientists reported that delays in tooth development and reductions in tooth size correlate with agenesis [21]. Both of these might agree with the terminal reduction theory. Moreover, it has also been reported that anterior agenesis may depend more on genes while posterior missing might be sporadic [22].

4. Diagnosis

Dental agenesis is categorized according to the number of missing teeth, less than three and six missing teeth are defined as mild and moderate, respectively. Clinical evaluation, radiographic and dental cast examinations are required for proper diagnosis. The third molar germ calcification initiates at the age of about 7.5 and in very few people, it starts at the age 9.5. Thus, by including patients younger than 9, researchers might overestimate the missing of the third molars. This might explain the high occurrence of agenesis in third molars which has been reported by some studies.

5. Treatment plan

Treatment needs an interdisciplinary approach including operative dentistry, paediatric dentistry, orthodontics and prosthodontics. Early extraction of primary canines might guide the eruption of the permanent canine into the proper position in cases with missing maxillary

lateral and impaction of upper canine. The amount of crowding, type of malocclusion, facial profile, age of the patient, periodontal conditions, bone volume in alveolar process, vertical or horizontal growth pattern, craniofacial morphology and the number of missing teeth should be considered in treatment plan. There are two treatment plans that include space reopening or space closing. Space can be reopened for implant insertion, auto transplantation and prosthetic restoration. Another treatment plan is space closing which can be done by fixed orthodontics.

6. Space closure versus space opening

Missing of maxillary incisors during the teenage years is a severe problem and often requires a challenging treatment plan. There are several solutions for treatment of lacking maxillary incisors including crown and bridge, resin bonded bridgework, removable partial dentures, osseointegrated implants, auto transplantation, orthodontic space closure [23–27]. Each of these methods has their own advantages and disadvantages; however, opening the space followed by implant insertion and space closure are the most common treatment options for tooth replacement. Implant insertion is an optimal treatment plan with obtaining an ideal occlusion and the indisputable advantage of avoiding any damage to the adjacent teeth [23, 28].

Space closing by mesial movement of the posterior teeth is a vital approach and it provides major satisfactory aesthetic and functional long-term results. Moreover; the result of space closure and all of the changes in the long term will be natural. It is clear that when implant or any prostheses are used, some changes could happen in the presence of a foreign body [26, 29, 30]. On the other hand, shorter and easier orthodontic treatment by implant insertion makes the space opening a favourable treatment approach for replacing missing teeth. Nevertheless, opening the space and implant insertion have some disadvantages. Implant insertion is contraindicated in growing patients. Implant must be postponed until the growth is ceased. If the implant is used at about 18 years of age, the neighbouring teeth and surrounding alveolar bone may continue to erupt. This eruption results in infraocclusion of the implant site. There will be a big discrepancy in vertical dimension between the gingival margin of the implanted tooth and the gingival margin of the neighbouring teeth. This side effect may appear in few years after implant insertion in young adult patients and the implant becomes submerged [31–34]. In patients where maxillary and mandibular incisors are not in contact with each other, the amount of extrusion might be 0/2–0/3 mm per year. Implant acts like an ankylosed teeth and its status cannot change in contrast to their adjacent teeth; thus, small displacement of neighbouring teeth after implant insertion can cause aesthetic complications [35–37]. Infra-positioned implant results in an unlevelled of gingival margins. This issue is a problematic challenge especially in patients with a high smile line. Thus, it is better not to use implant in cases with ‘gummy smile’ or vertical growth pattern patients [26]. Furthermore, it has been reported that more than 50% of single-implant crowns at 4-year follow-ups have some

extent of blue colouring of the gingiva [38]. Some other side effects such as bleeding on probing, gingivitis, increased probing depth, periodontitis, Peri-implantitis and progressive loss of marginal bone support of the implant, have also been shown in cases with implant insertion [36, 39–41]. Besides, the most problematic issue of the space opening is that the teenagers must wait many years after completion of orthodontic treatment for implant insertion. During this interim phase, the patients must use temporary crowns or restorations that often causes many difficulties and displacements both on implant site and adjacent teeth. On the other hand, orthodontic space closure is a practical and safe procedure that could achieve better long-term results. Moreover, none of the stated drawbacks have been found in orthodontic space closure [29, 42, 43]. Nevertheless, orthodontic space closure has its own disadvantages. Concerns may be related to the complexity of treatment, the risk for reopening of space, increased functional force on the first premolar roots [44]. Attempts for closing the space of upper incisors will tend to retract the anterior teeth, which may be favourable in class II division I malocclusion with maxillary protrusion. Space closure in the maxillary arch may well provide reduction of an increased overjet. However, space closing may be undesirable in class III malocclusion with maxillary deficiency. Moreover, space closure of a missing upper lateral incisor results in the canine being displaced mesially into contact with the central incisor. In this case, the canine is more prominent, wider and darker than the lateral incisor. Canine can be reshaped by selective grinding of the cusp tip and it needs rebuilding by composite materials like lateral incisor. In cases with increased overjet or crowding extraction of the contralateral lateral incisor may help to maintain symmetry and correct the dental midline. Space reopening is usually the best treatment option where orthodontic treatment does not need to use the space to relieve the crowding. In this case, any attempt to close the space results in an unfavourable effect. The major disadvantage of space reopening is that it requires a foreign body such as permanent prosthesis or implant. The optimal space required for the prosthesis or implant is usually determined by two factors. The first one is occlusion and the second is aesthetic. Ideal overjet and overbite must be provided along with good Class I malocclusion at the end of the treatment. A maxillary lateral incisor should be two thirds of the width of the maxillary central incisor. Providing of these conditions may be difficult due to anchorage problems associated with reduced numbers of teeth in hypodontia patients. In cases with extensive space or early loss of teeth which have resulted in alveolar atrophy, space closure will not be desirable. The position of the roots of the neighbouring teeth should be estimated radiographically in space opening cases. Therefore, not only adequate space must be provided for replacement of the crown but also the roots of neighbouring teeth should be parallel or slightly divergent to create adequate space for implant insertion [45, 46]. **Figures 1–3** show a patient immediately after implant insertion and **Figures 4–6** show the same patient after 5 years. However, these images illustrate that some changes such as infraocclusion and periodontal problems can be seen in implant site after 5 years. **Figures 7 and 8** show a patient with missing both maxillary lateral incisors treated by orthodontic space closure. **Figures 9 and 10** show the same patient 5 years after completion of treatment. These pictures demonstrate that the dentition, periodontal status have not been changed after 5 years in space closure.

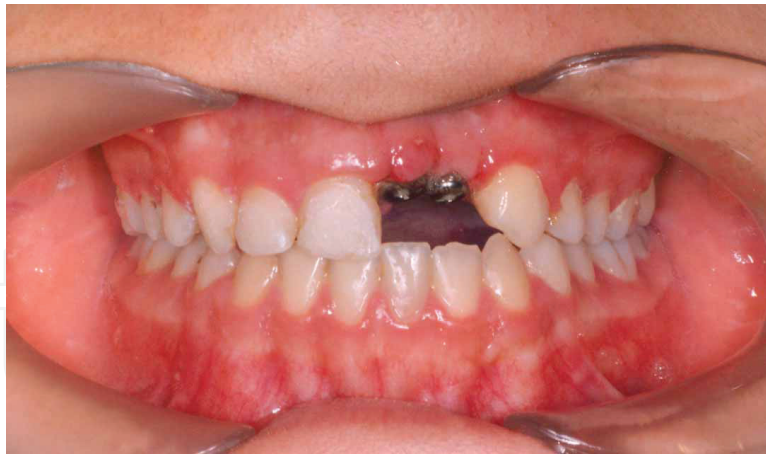

Figure 1. A patient immediately after implant abutment insertion.

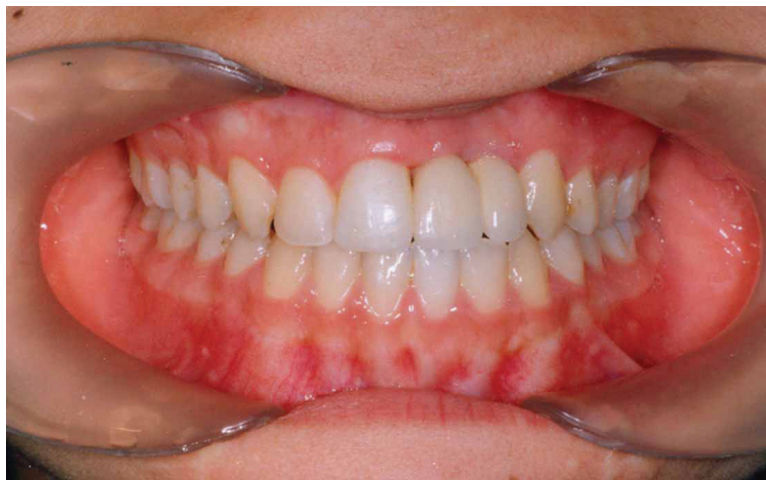

Figure 2. A patient immediately after implant insertion.

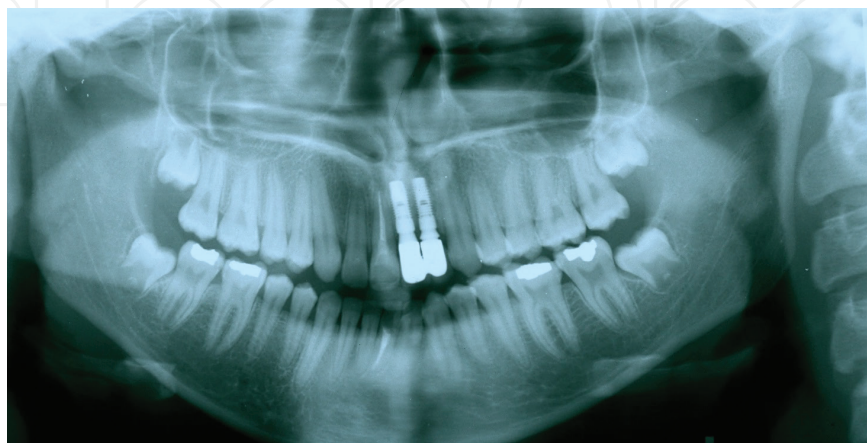

Figure 3. OPG (Orthopantomogram) of the same patient.

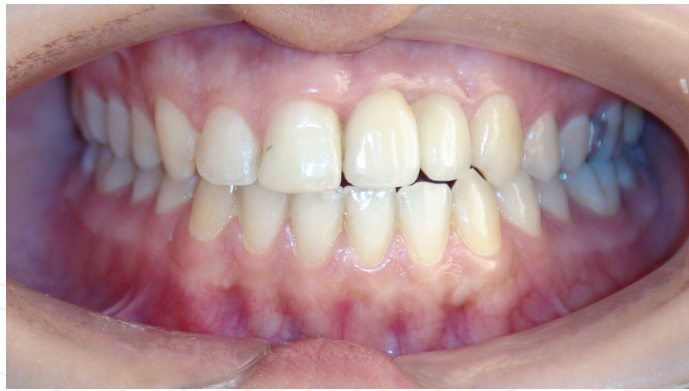

Figure 4. Same patient after 5 years.

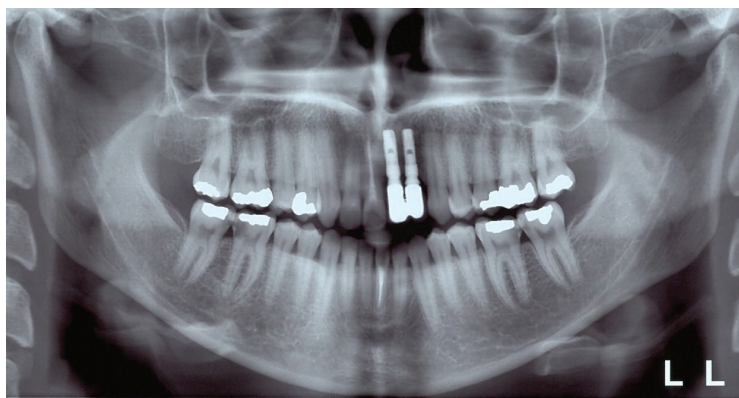

Figure 5. OPG of the same patient after 5 years.

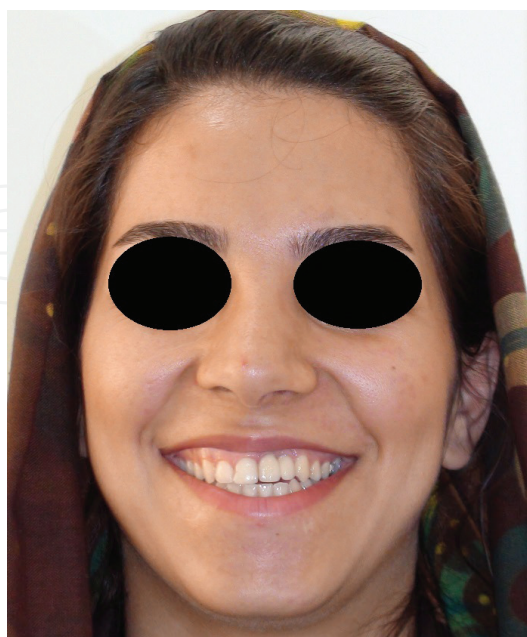

Figure 6. Frontal view of the patient after 5 years.

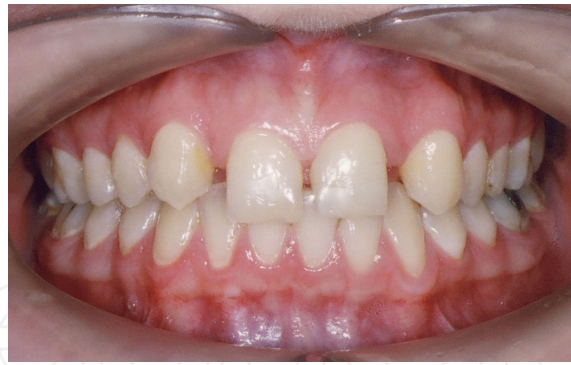

Figure 7. A patient with missing maxillary lateral incisors.

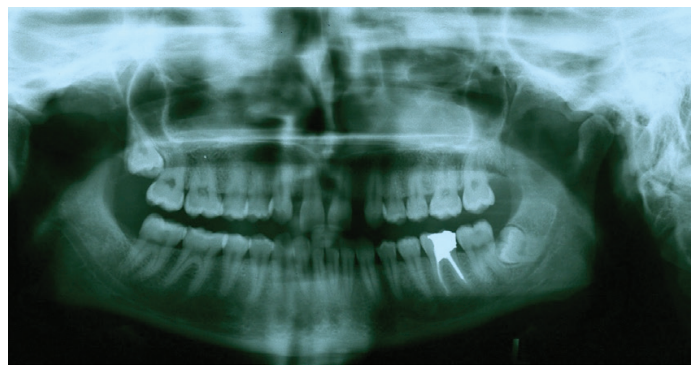

Figure 8. OPG of the patient with missing maxillary incisors.

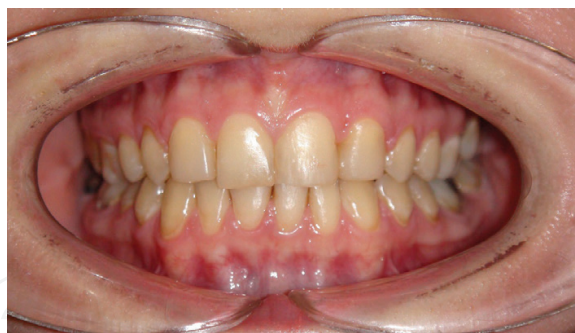

Figure 9. Same patient 5 years after orthodontic space closure.

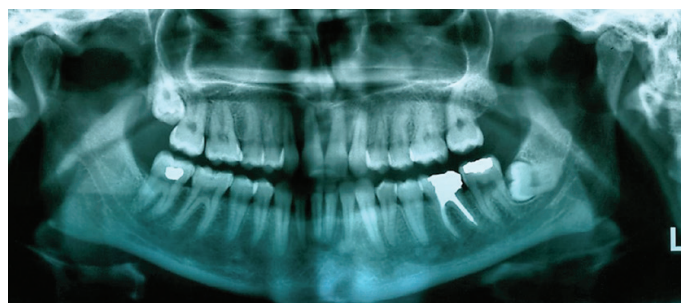


Figure 10. OPG of the same patient 5 years after orthodontic space closure.

7. Conclusion

The main advantage of the space closure to implants can be followed as:

- The whole treatment can be finished immediately after completion of orthodontics in space closure cases. This issue is a vital interest for teenager patients.
- Better long-term aesthetic results can be provided in space closure due to lack of infraocclusion, blue colouring of the gingiva and periodontal problems.
- Gingivitis, periodontitis, and other periodontal problems will not occurring space closure because the tooth has displaced along with its surrounding tissues and its bone.
- Use of other prosthetic replacement for the missing incisor by partial denture or bonded bridges could require further treatments to substitute the restorations.
- Orthodontic space closure will decrease the financial charge for the patient.

Author details

Abdolreza Jamilian^{1*}, Alireza Darnahal², Ludovica Nucci³, Fabrizia D'Apuzzo³ and Letizia Perillo³

*Address all correspondence to: info@jamilian.net

1 Department of Orthodontics, Tehran Dental Branch, Craniomaxillofacial Research Center, Islamic Azad University, Tehran, Iran

2 Tehran Dental Branch, Craniomaxillofacial Research Center, Islamic Azad University, Tehran, Iran

3 Multidisciplinary Department of Medical-Surgical and Dental Specialties, Second University of Naples, Naples, Italy

References

- [1] Polder BJ et al. A meta-analysis of the prevalence of dental agenesis of permanent teeth. *Community Dentistry and Oral Epidemiology*. 2004;**32**(3):217-226
- [2] Jamilian A et al. Hypodontia and supernumerary and impacted teeth in children with various types of clefts. *American Journal of Orthodontics and Dentofacial Orthopedics*. 2015;**147**(2):221-225
- [3] Vastardis H. The genetics of human tooth agenesis: New discoveries for understanding dental anomalies. *American Journal of Orthodontics and Dentofacial Orthopedics*. 2000;**117**(6):650-656
- [4] Jamilian A, Perillo L, Rosa M. Missing upper incisors: A retrospective study of orthodontic space closure versus implant. *Progress in Orthodontics*. 2015;**16**:2

- [5] Hall RK. Congenitally missing teeth—A diagnostic feature in many syndromes of the head and neck. *Journal of the International Association of Dentistry for Children*. 1983;**14**(2):69-75
- [6] Aasheim B, Ogaard B. Hypodontia in 9-year-old Norwegians related to need of orthodontic treatment. *Scandinavian Journal of Dental Research*. 1993;**101**(5):257-260
- [7] Guttal KS et al. Frequency of developmental dental anomalies in the Indian population. *European Journal of Dentistry*. 2010;**4**(3):263-269
- [8] Carter NE et al. The interdisciplinary management of hypodontia: Orthodontics. *British Dental Journal*. 2003;**194**(7):361-366
- [9] Muller TP et al. A survey of congenitally missing permanent teeth. *Journal of the American Dental Association*. 1970;**81**(1):101-107
- [10] Garib DG et al. Agenesis of maxillary lateral incisors and associated dental anomalies. *American Journal of Orthodontics and Dentofacial Orthopedics*. 2010;**137**(6):732 e1-6; discussion 732-3
- [11] Peck S, Peck L, Kataja M. Concomitant occurrence of canine malposition and tooth agenesis: Evidence of orofacial genetic fields. *American Journal of Orthodontics and Dentofacial Orthopedics*. 2002;**122**(6):657-660
- [12] Shapira Y, Lubit E, Kuftinec MM. Hypodontia in children with various types of clefts. *Angle Orthodontist*. 2000;**70**(1):16-21
- [13] Jamilian A, Showkatbakhsh R, Boushehry MB. The effect of tongue appliance on the nasomaxillary complex in growing cleft lip and palate patients. *Journal of the Indian Society of Pedodontics and Preventive Dentistry*. 2006;**24**(3):136-139
- [14] Jamilian A, Nayeri F, Babayan A. Incidence of cleft lip and palate in Tehran. *Journal of the Indian Society of Pedodontics and Preventive Dentistry*. 2007;**25**(4):174-176
- [15] Graber LW. Congenital absence of teeth: A review with emphasis on inheritance patterns. *Journal of the American Dental Association*. 1978;**96**(2):266-275
- [16] Backman B, Wahlin YB. Variations in number and morphology of permanent teeth in 7-year-old Swedish children. *International Journal of Paediatric Dentistry*. 2001;**11**(1):11-7
- [17] Mirabella AD, Kokich VG, Rosa M. Analysis of crown widths in subjects with congenitally missing maxillary lateral incisors. *European Journal of Orthodontics*. 2012;**34**(6):783-787
- [18] Srivastava D et al. Use of anterior maxillary distraction osteogenesis in two cleft lip and palate patients. *National Journal of Maxillofacial Surgery*. 2015;**6**(1):80-83
- [19] Jamilian A et al. Cleft sidedness and congenitally missing teeth in patients with cleft lip and palate patients. *Progress in Orthodontics*. 2016;17:14
- [20] Lexner MO et al. Anomalies of tooth formation in hypohidrotic ectodermal dysplasia. *International Journal of Paediatric Dentistry*. 2007;**17**(1):10-18

- [21] Ahmad W et al. A locus for autosomal recessive hypodontia with associated dental anomalies maps to chromosome 16q12.1. *American Journal of Human Genetics*. 1998;**62**(4):987-991
- [22] Tavajohi-Kermani H, Kapur R, Sciote JJ. Tooth agenesis and craniofacial morphology in an orthodontic population. *American Journal of Orthodontics and Dentofacial Orthopedics*. 2002;**122**(1):39-47
- [23] Endo T et al. Hypodontia patterns and variations in craniofacial morphology in Japanese orthodontic patients. *Angle Orthodontist*. 2006;**76**(6):996-1003
- [24] Goya HA et al. An orthopantomographic study of hypodontia in permanent teeth of Japanese pediatric patients. *Journal of Oral Science*. 2008;**50**(2):143-150
- [25] Galluccio G, Pilotto A. Genetics of dental agenesis: Anterior and posterior area of the arch. *European Archives of Paediatric Dentistry*. 2008;**9**(1):41-45
- [26] Rupp RP, Dillehay JK, Squire CF. Orthodontics, prosthodontics, and periodontics: A multidisciplinary approach. *General Dentistry*. 1997;**45**(3):286-289
- [27] Ghassemi M et al. Orthodontic treatment after autotransplantation. *Angle Orthodontist*. 2011;**81**(4):721-725
- [28] Zachrisson BU, Stenvik A, Haanaes HR. Management of missing maxillary anterior teeth with emphasis on autotransplantation. *American Journal of Orthodontics and Dentofacial Orthopedics*. 2004;**126**(3):284-288
- [29] Zachrisson BU, Rosa M, Toreskog S. Congenitally missing maxillary lateral incisors: Canine substitution. *Point*. *American Journal of Orthodontics and Dentofacial Orthopedics*. 2011;**139**(4):434, 436, 438 passim
- [30] Showkatbakhsh R, Jamilian A. Opening or closing space for replacing upper incisors. Two case reports. *Revista Española de Ortodoncia*. 2010;**40**:181-185
- [31] Zachrisson BU. Planning esthetic treatment after avulsion of maxillary incisors. *Journal of the American Dental Association*. 2008;**139**(11):1484-1490
- [32] Nordquist GG, McNeill RW. Orthodontic vs. restorative treatment of the congenitally absent lateral incisor—Long term periodontal and occlusal evaluation. *Journal of Periodontology*. 1975;**46**(3):139-143
- [33] Robertsson S, Mohlin B. The congenitally missing upper lateral incisor. A retrospective study of orthodontic space closure versus restorative treatment. *European Journal of Orthodontics*. 2000;**22**(6):697-710
- [34] Bernard JP et al. Long-term vertical changes of the anterior maxillary teeth adjacent to single implants in young and mature adults. A retrospective study. *Journal of Clinical Periodontology*. 2004;**31**(11):1024-1028
- [35] Kuijpers MA, de Lange J, van Gool AV. Maxillofacial growth and dental implants in the maxillary anterior region. *Nederlands Tijdschrift Voor Tandheelkunde*. 2006;**113**(4):130-133

- [36] Jemt T et al. Changes of anterior clinical crown height in patients provided with single-implant restorations after more than 15 years of follow-up. *International Journal of Prosthodontics*. 2006;**19**(5):455-461
- [37] Spear FM, Mathews DM, Kokich VG. Interdisciplinary management of single-tooth implants. *Seminars in Orthodontics*. 1997;**3**(1):45-72
- [38] Oesterle LJ, Cronin RJ Jr. Adult growth, aging, and the single-tooth implant. *International Journal of Oral & Maxillofacial Implants*. 2000;**15**(2):252-260
- [39] Thilander B, Odman J, Lekholm U, Orthodontic aspects of the use of oral implants in adolescents: A 10-year follow-up study. *European Journal of Orthodontics*. 2001;**23**(6):715-731
- [40] Chang M et al. Implant supported single-tooth replacements compared to contralateral natural teeth. Crown and soft tissue dimensions. *Clinical Oral Implants Research*. 1999;**10**(3):185-194
- [41] Dueled E et al. Professional and patient-based evaluation of oral rehabilitation in patients with tooth agenesis. *Clinical Oral Implants Research*. 2009;**20**(7):729-736
- [42] Fransson C et al. Extent of peri-implantitis-associated bone loss. *Journal of Periodontology*. 2009;**36**(4):357-363
- [43] Paolantonio M et al Clinical, microbiologic, and biochemical effects of subgingival administration of a Xanthan-based chlorhexidine gel in the treatment of periodontitis: A randomized multicenter trial. *Journal of Periodontology*. 2009;**80**(9):1479-1492
- [44] Rosa M, Zachrisson BU. Integrating space closure and esthetic dentistry in patients with missing maxillary lateral incisors. *Journal of clinical orthodontics*. 2007;**41**(9):563-73; quiz 424
- [45] Thordarson A, Zachrisson BU, Mjor IA. Remodeling of canines to the shape of lateral incisors by grinding: A long-term clinical and radiographic evaluation. *American Journal of Orthodontics and Dentofacial Orthopedics*. 1991;**100**(2):123-132
- [46] Czochrowska EM et al. Outcome of orthodontic space closure with a missing maxillary central incisor. *American Journal of Orthodontics and Dentofacial Orthopedics*. 2003;**123**(6):597-603