

We are IntechOpen, the world's leading publisher of Open Access books Built by scientists, for scientists

6,900

Open access books available

186,000

International authors and editors

200M

Downloads

Our authors are among the

154

Countries delivered to

TOP 1%

most cited scientists

12.2%

Contributors from top 500 universities



WEB OF SCIENCE™

Selection of our books indexed in the Book Citation Index
in Web of Science™ Core Collection (BKCI)

Interested in publishing with us?
Contact book.department@intechopen.com

Numbers displayed above are based on latest data collected.
For more information visit www.intechopen.com



Rational Approach to a Patient with Suspected Primary Aldosteronism

Tomaz Kocjan

Additional information is available at the end of the chapter

<http://dx.doi.org/10.5772/66965>

Abstract

Primary aldosteronism (PA) is the most common form of secondary hypertension that causes higher morbidity and mortality than equally severe essential hypertension. Bilateral PA should be treated medically with spironolactone or eplerenone, the mineralocorticoid receptor antagonists (MRA), while unilateral laparoscopic adrenalectomy is recommended for unilateral disease. Surgery cures hypertension in around 40% of patients with confirmed PA and reliably demonstrated unilateral autonomous aldosterone secretion by adrenal venous sampling (AVS). Regardless of its diagnostic value, AVS has several drawbacks, in particular high cost and invasiveness. Furthermore, only a limited number of referral centers worldwide routinely carry out the procedure. On the other hand, a small number of studies that compared the effects of surgery and MRA on the incidence of cardiovascular and renal outcomes in patients with PA found no difference between the two therapeutic options. In addition, spironolactone has been recently found to be the most effective add-on drug for the treatment of resistant hypertension. Therefore, rational selection of patients with suspected PA for AVS and surgery is of utmost importance.

Keywords: adrenalectomy, adrenal venous sampling, hypertension, mineralocorticoid receptor antagonists, primary aldosteronism

1. Introduction

Primary aldosteronism (PA) is a group of disorders in which aldosterone production is inappropriately high for sodium status, relatively autonomous and nonsuppressible by sodium loading. Such inappropriate production of aldosterone causes hypertension, sodium retention, suppression of plasma renin, and increased potassium excretion [1]. Once thought to be rare, PA is now considered the most common form of secondary hypertension with an

estimated prevalence of 4.3% in primary care and of 9.5% among referred hypertensive patients [2]. Accumulated experimental and clinical evidence clearly shows that prolonged exposure to elevated aldosterone levels causes excess cardiovascular and renal damage which is partly independent of blood pressure (BP) levels [3]. Consequently, this endocrine condition is far from being benign, and patients with PA appear to have higher rates of cardiac arrhythmia, coronary heart disease, heart failure, stroke, proteinuria, and renal impairment compared to matched patients with essential hypertension (EH) [4–6]. Their cardiovascular mortality might be also increased [7]. Targeted treatment of PA is possible and is of obvious benefit to affected patients.

The Endocrine Society now explicitly recognizes PA as a major public health issue and recommends extensive screening for this disorder using the plasma aldosterone/renin ratio (ARR) in high-risk populations, including patients with sustained BP more than 150/100 mm Hg, resistant hypertension, spontaneous or diuretic-induced hypokalemia, adrenal incidentaloma, or sleep apnea. Most patients with a positive ARR should undergo one or more confirmatory tests to definitively confirm or exclude the diagnosis. Then lateralization of the source of the excessive aldosterone secretion is critical to guide the management of confirmed PA because unilateral adrenalectomy in patients with unilateral disease results in the normalization of hypokalemia; hypertension is also improved or even cured. In bilateral PA medical therapy with spironolactone or other mineralocorticoid receptor antagonists (MRA) is the treatment of choice. Unilateral disease may also be treated medically if the patient declines or is not a candidate for surgery. The first step in subtype classification is adrenal computed tomography (CT). Finally, all but few surgical candidates need cumbersome adrenal venous sampling (AVS) to reliably distinguish between unilateral and bilateral adrenal disease and to decide for optimal treatment [1].

These guidelines place a high value on avoiding the risk associated with missing a diagnosis of unilateral PA and thus the opportunity of possibly curative intervention by unilateral adrenalectomy and a lower value on avoiding the risks of exposing patients with bilateral PA (who are candidates for medical treatment) to additional diagnostic testing. As the global burden of PA seems to be very high and the recommended diagnostic procedures are complex and costly, consistent translation of the guidelines into clinical practice might not be possible even in the most affluent healthcare systems. Hence, rational approach to a patient with suspected PA seems the only option, and it will be briefly reviewed here. Several clinical situations will be presented, in order to show the different ways of medical decision-making in using the guidelines and to help the clinicians to apply these guidelines to their patients with suspected or confirmed PA.

2. Patients with suspected PA

When resources are limited, the clinician might not be able to measure plasma aldosterone concentration (PAC) and renin to determine ARR. Such patients should be treated with an MRA if they have reasonable renal function because PA is very common [2]. Moreover, there is ample, published supportive data that spironolactone is an excellent antihypertensive agent

in patients with hypertension and without PA [8, 9]. Spironolactone has even been recently found to be the most effective add-on drug for the treatment of resistant hypertension [10]. Therefore, some experts propose inclusion of a low-dose MRA (spironolactone 12.5/25 mg daily or equivalent doses of another antagonist) as part of first-line therapy for all hypertensive subjects [11].

The Endocrine Society now similarly recommends medical treatment including an MRA, if an ARR-positive patient is unwilling or unable to undergo further investigations [1]. Older patients with multiple medical comorbidities who are at high surgical risk and those with short life expectancy should be included in this group [12]. Pure aldosterone-secreting adrenocortical carcinomas are exceptionally uncommon [13]; however, some form of adrenal imaging might be considered for these patients, except in cases with long-standing and mild (e.g., normokalemic) disease.

Notably, MRA, amiloride, triamterene, and potassium-wasting diuretics should be withdrawn for at least 4 weeks before ARR testing. A washout of all interfering antihypertensive medications such as angiotensin-converting enzyme inhibitors, angiotensin receptor blockers, dihydropyridine calcium channel antagonists, and beta-adrenergic blockers is feasible in patients with mild hypertension but is potentially problematic in others and is often not required if the results of ARR on the above agents are clearly diagnostic. If all potentially problematic agents cannot be safely withdrawn, an ARR should be performed and the results considered in the light of the potential confounding factors [1]. In case of very low renin levels, care should be taken to avoid overinflating ARR. Only a certain minimum value of renin can be included in the ratio. This value is often fixed at 0.2 ng/ml/h for plasma renin activity (PRA) and at 0.36 ng/ml for direct renin activity (DRA). Elderly patients and individuals of African origin usually have low renin values, and the precautions described are vital in such cases [14].

3. Patients with confirmed PA

Spontaneous hypokalemia, plasma renin below detection levels, and PAC > 20 ng/dL (>550 pmol/L) may be sufficient for the diagnosis of PA [1]. For patients without these laboratory characteristics who are undergoing confirmatory testing without MRA and thiazide diuretics, additional extensive medication switching is not always needed, because it appears that more severely excessive aldosterone overproduction (e.g., post-saline infusion test (SIT) PAC ≥ 8.6 ng/dL (>240 pmol/L)) may not be effectively suppressed by less interfering chronic antihypertensive drugs. When PA is less severe, reproducibility of confirmatory tests performed without recommended drug withdrawal is much less than optimal [15].

Patients with confirmed PA and excluded adrenocortical carcinoma by CT should not be coerced into considering AVS and surgery if they prefer not to undergo the procedures, given that there is reasonable evidence to suggest that lifelong treatment with MRA is a valid alternative to surgery. Treatment choice should, therefore, be primarily driven by the preferences of the well-informed patient. Candidates for surgery should be told that the presence of an

adrenal adenoma poses no risk in terms of cancer [12]. In patients with an onset of confirmed PA earlier than 20 years of age and in those who have a family history of PA or stroke at a young age (<40 years), genetic testing for familial hyperaldosteronism type 1 (FH-I) [glucocorticoid remediable aldosteronism (GRA)] is suggested. When confirmed, FH-I should be always treated medically [1].

3.1. Medical therapy vs. surgery

In the absence of RCTs comparing surgical and medical treatment of PA may prove difficult, as a recent systematic review found. The existing studies were all carried out in a limited number of centers and were usually dealing with relatively small number of patients. Their main aim was to compare patients with PA and those with EH, but they failed to predefine medical treatment for target BP and dose or type of medication. When surgery was found the superior approach in those studies over the medical treatment of patients, it was often with groups that received no MRA or low doses of it (in some cases treatment was not reported). Furthermore, two different forms of PA, the unilateral disease and the bilateral disease, that may not be fully comparable were treated as a single one in the majority of the studies, since surgical procedures were mostly performed on patients with the former type of PA and medical treatment was delivered predominantly to those with the latter form [16]. This limits the usefulness of the results obtained, since it must be noted that patients with bilateral PA are in general less responsive to monotherapy with MRA than those with unilateral PA [17]. Comparisons between surgically and medically treated patients with PA should, therefore, be interpreted with caution [16].

The effects on improvement of BP and hypokalemia were similar in surgically and medically treated patients in six studies, and surgery was reported to be superior in another six studies [16]. Of note, in German Conn's registry, the observed all-cause mortality following adrenalectomy was reduced compared with medical treatment [7]. However, several outcome variables in PA with regard to end-organ damage appear to improve to a comparable level after medical and surgical treatment. A meta-analysis of long-term studies which included 355 patients with PA and median follow-up of 4 years showed that reduction of left ventricular mass was not different after adrenalectomy or medical treatment with MRA [18]. Furthermore, when comparing the incidence of combined cardio- and cerebrovascular events comprising myocardial infarction, stroke, any type of revascularization procedure, and sustained arrhythmias in treated patients with PA and matched controls with EH, the benefits of PA treatment were similar for specific drugs and surgery [5, 19]. Spironolactone, when uptitrated as needed and tolerated, is as effective as surgery in correcting the relative glomerular hyperfiltration and microalbuminuria of patients with PA [12]. Comparable improvement in sensitivity to insulin and glucose metabolism in surgically and medically treated PA was also reported [20]. No significant difference in prevalence of depression and anxiety was found 5.4 years after initiation of MRA treatment or 4.3 years after unilateral adrenalectomy in patients with PA [21]. Remission of bilateral PA may occur in some patients after long-term MRA treatment [22] and exceptionally also in unilateral disease [23].

On the other hand, patients treated medically need more antihypertensive drugs and require a longer follow-up and more clinical visits at specialized referral centers than those treated

surgically [24]. Quality of life seems to be worse in medically treated patients with PA and improves more slowly and to a lesser degree than with surgical treatment [25]. Side effects are common in patients receiving treatment with MRA, especially spironolactone, contributing to increased healthcare consumption and increased risk of noncompliance [16]. Consequently, at least in terms of ongoing antihypertensive medication requirements and quality of life, clinical responses to unilateral adrenalectomy in patients with unilateral PA are superior to those in patients with bilateral PA treated medically. Therefore, unilateral disease in appropriately selected patients is generally recommended to be treated surgically [26]. Adrenalectomy for PA is also less expensive than long-term medical treatment for patients with PA with a life expectancy of more than 25 years, performing AVS in all patients and adrenalectomy in those displaying lateralization than not carrying out AVS and providing lifelong drug treatment for all patients [27].

3.2. Selection of patients for AVS and surgery

Laparoscopic adrenalectomy, using transperitoneal or retroperitoneal approaches, is the preferred therapeutic strategy for unilateral PA [28]. It has a morbidity of 5–14%, a mortality below 1%, and a mean hospital stay around 3 days. Adrenalectomy generally results in the normalization of aldosterone secretion and serum potassium (96–100%); however, patients should be warned that hypertension is not always cured [29]. Based on 2482 patients from 16 studies, BP was normalized in a mean of 42% (range 20–72%) of patients [16]. Of note, older studies with a “cure” rate as high as 56–77% used the cure threshold of BP < 160/95 mm Hg, which is clearly still in the hypertensive range [1].

3.2.1. Predictors of cure or persistent hypertension

Whether hypertension can be successfully cured or whether it is likely to persist can be inferred from predictors that have been extensively studied. At least one multivariate analysis found the following statistically significant predictors of hypertension persistence after adrenalectomy in patients with unilateral PA: advanced age, male gender, longer hypertension duration, higher BMI, more drug classes, higher preoperative BP, higher 24-h urinary aldosterone/active renin ratio, lower estimated GFR, higher serum potassium concentrations, or evidence of arteriolosclerosis [29]. Recently, higher renal resistive index calculated by Doppler ultrasonography has been also reported to predict worse postoperative BP outcome in PA [30]. On the other hand, a positive predictive factor for cure is histologically verified aldosterone-producing adenoma [16], especially if harboring somatic KCNJ5 (inwardly rectifying potassium channel, subfamily J, member 5 gene) mutations [31]. Recently, a study based on German Conn’s registry found out that PA patients with post-SIT PAC > 10 ng/dL (>280 pmol/L) showed a better outcome after adrenalectomy regarding blood pressure, potassium normalization, and reduction in the number of antihypertensive drugs. On the other hand, low post-SIT PAC levels of 5–10 ng/dL (140–280 pmol/L) were an indicator of less successful outcome, so the authors suggested that post-SIT PAC is a predictor for the remission probability of PA post adrenalectomy [32]. Interestingly, diagnosis of unilateral PA confirmed by AVS was never found to be a predictor of good outcome after surgery, and patients with a higher lateralization index on AVS do not have a better outcome [29]. Contralateral

suppression on AVS correlated with good BP and biochemical outcomes from surgery in some [33, 34], but not in all studies [35].

Few prediction models have been developed to help clinicians to objectively inform patients of likely clinical outcomes before surgical intervention. The aldosteronoma resolution score (ARS) was composed of four readily available clinical predictors (two or fewer antihypertensive medications, body mass index ≤ 25 kg/m², duration of hypertension ≤ 6 years, and female sex) to identify individuals at low or high likelihood of complete resolution of hypertension. However, even if none of these features were present in an individual patient, he still had a 25% probability of being completely cured by an adrenalectomy in the validation cohort [36]. A better option to predict BP cure after adrenalectomy might present a novel nomogram that has been recently developed in Japan. The included factors are the duration of hypertension, number of antihypertensive drug classes used, and age and sex for an individual patient [37]. When selecting patients for surgery, one should not attach excessive importance to these hypertension cure predictors. Namely, several of the studies conducted could not ascertain the link between these predictors and the eventual cure of the hypertension. In addition, some studies suffered from small sample sizes used in their multivariate analysis approach [29]. Factors predictive of the persistence of hypertension after adrenalectomy should not, therefore, be used as exclusive arguments for or against surgery in individual cases.

The most common reasons for persistently increased BP after adrenalectomy are coexistent EH and older age and/or longer duration of hypertension [1]. A significant number of patients who are not cured by adrenalectomy for PA will still benefit from surgery. Even if hypertension persists, the patient will experience a significant decrease in BP and/or treatment requirements. Adrenalectomy usually produces a large decrease in systolic BP (typically -25 to -40 mm Hg) and in the number of antihypertensive medications prescribed (typically -1 to -2 drug classes). Additionally, the focus on hypertension cure obscures the likely cure of hypokalemia and the normalization of aldosterone secretion which probably has BP-independent benefits [29].

3.2.2. Subtype diagnosis

Subtype diagnosis is required only if surgery is being considered. Adrenal venous sampling (AVS) is currently regarded as the only reliable method to distinguish bilateral from unilateral PA [38]. In order to avoid an unnecessary or an inappropriate adrenalectomy, in principle, AVS should be performed in all patients with PA who want to pursue surgical cure. AVS is preceded by CT not only to exclude large masses that may represent adrenocortical carcinoma (**Figure 1**) but also to assist the interventional radiologist (and surgeon) where anatomically appropriate [1].

Generally, adrenal CT is not accurate in distinguishing between unilateral and bilateral disease and might have misdiagnosed the type of PA in 37.8% of patients when AVS was used as the criterion standard test for diagnosing laterality of aldosterone secretion (**Figure 2**) [38].

Morphology does not predict biochemical function, and many aldosteronomas are very small with up to 42% of them being <6 mm in diameter (**Figure 3**) [39].

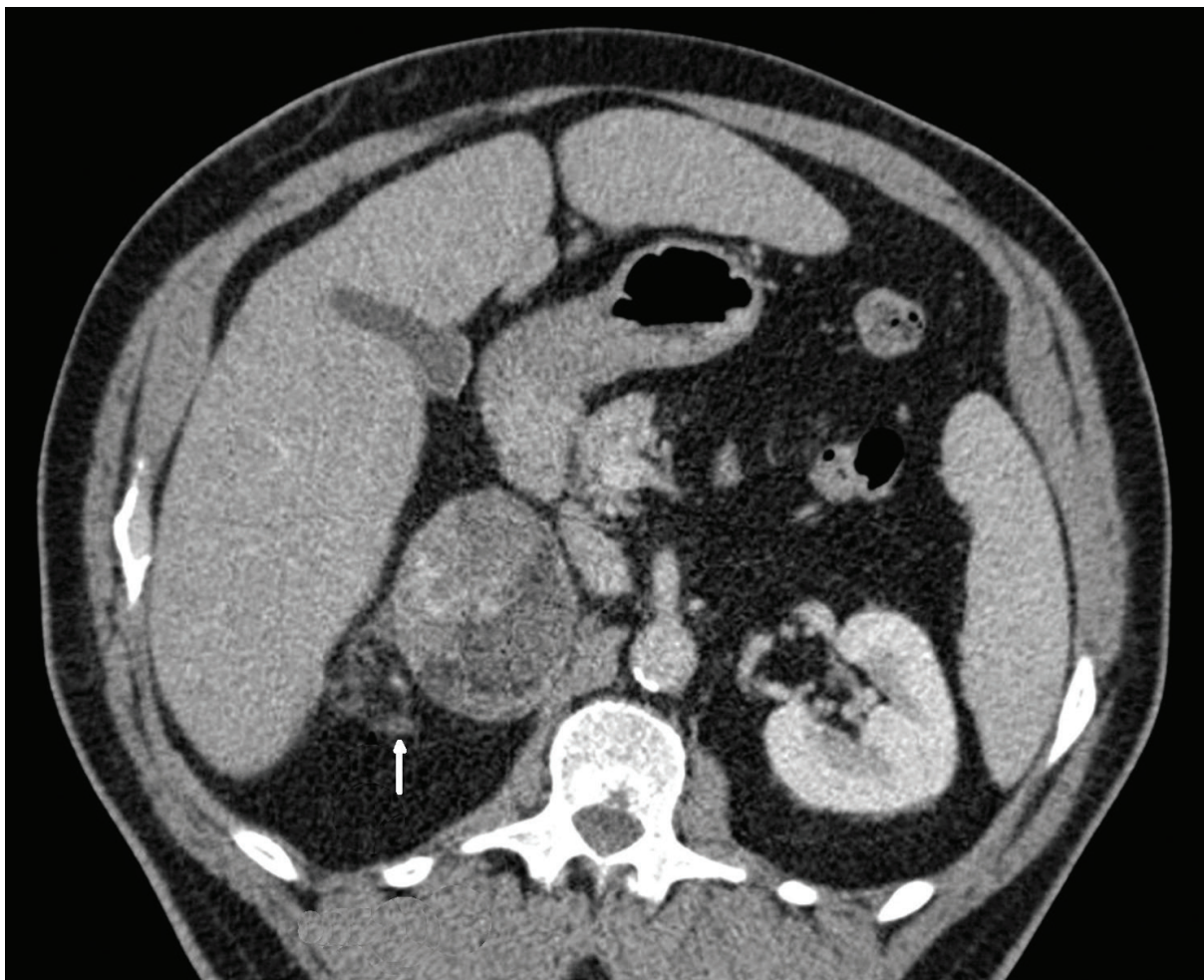


Figure 1. Adrenocortical carcinoma with mineralocorticoid activity in right adrenal gland showing typical heterogeneous appearance and local invasion (arrow) (CT scan).

However, a recent, rigorously conducted randomized controlled trial that compared the outcome of CT-based management with AVS-based management for 200 patients with PA found no difference between the groups with regard to the intensity of antihypertensive drug treatment, mean blood pressure, the proportion of patients reaching target blood pressure (<135/85 mm Hg), quality of life, or adverse events after 1 year. Moreover, there was no difference in the frequency of adrenalectomy and no statistically significant difference in biochemical failure in operated patients (11% in the AVS group vs. 20% in the CT group; $p = 0.25$) [40]. The outcome of this study is unexpected and challenges current guidelines. It is, however, important to consider that more than 70% of patients with PA present with normokalemia. This is a patient group not covered by the trial, and caution should be used in generalizing these findings [41]. In addition, when considering persistent vs. resolved PA, a nonsignificant trend in favor of AVS was found that might become statistically significant in a larger cohort [40].

Regardless of its diagnostic value, AVS has several drawbacks, in particular the lack of a standardized procedure, variable handling of cutoffs, high cost, and invasiveness. It has a

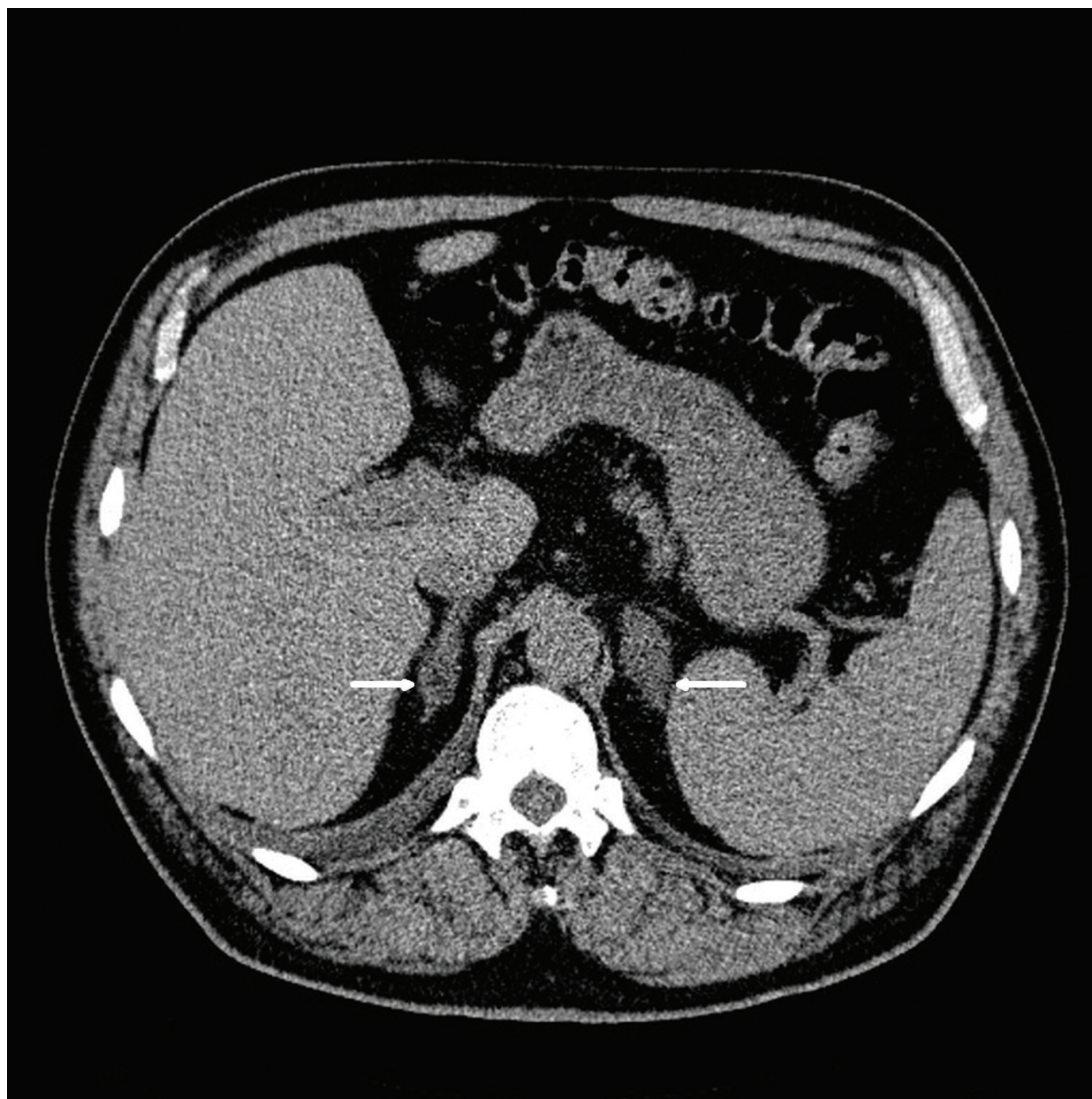


Figure 2. Bilaterally enlarged adrenal glands with aldosterone-producing adenoma (20 mm) on the right and hormonally inactive incidentaloma (30 mm) on the left (arrows) (CT scan).

reputation as a technically difficult procedure with the average success rate for cannulating the right adrenal vein of only 74% [42]. The addition of rapid intra-procedural measurement of adrenal vein cortisol concentrations is useful in centers with low success rates [43], and accuracy of catheter placement can be also improved with C-arm CT [44]. With experience the success rate can be improved to 90–96% [45]. The risk of adrenal hemorrhage can be minimized by employing a radiologist skilled in the technique, avoiding adrenal venography and limiting the use of contrast to the smallest amounts necessary to assess the catheter tip position. At centers with experienced AVS radiologists, the complication rate is 2.5% or lower [46]. More recent studies, report, however, a substantially lower rate of complications

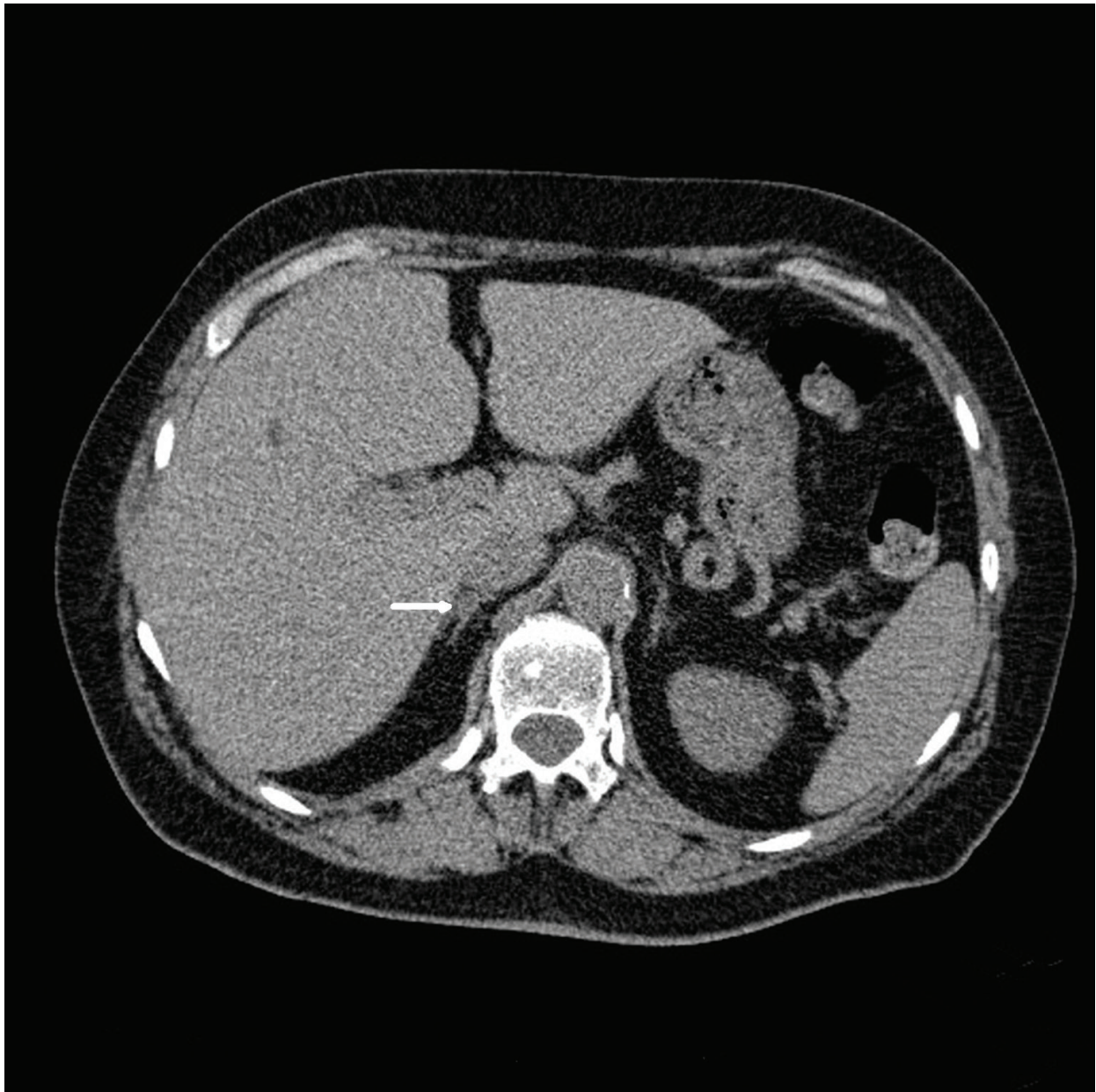


Figure 3. Tiny aldosterone producing adenoma (6 mm) in right adrenal gland (arrow) (CT scan).

of between 0.2 and 0.9%. Only a limited number of referral centers worldwide routinely carry out the procedure (**Figure 4**).

The Adrenal Vein Sampling International Study (AVIS) which explored AVS practice in 20 centers from Asia, Australia, the USA, and Europe confirmed that AVS was under-utilized with marked variation in techniques and interpretation of results and therefore highlighted a clear need for definitive guidelines on the use and interpretation of AVS in identifying unilateral aldosterone excess [47]. Importantly, different sets of criteria used to interpret AVS in different institutions translate into heterogeneous classifications and hence management decisions, for patients with PA [48]. Recently, many of these issues have been addressed by several opinion papers [26, 49]. An expert consensus statement

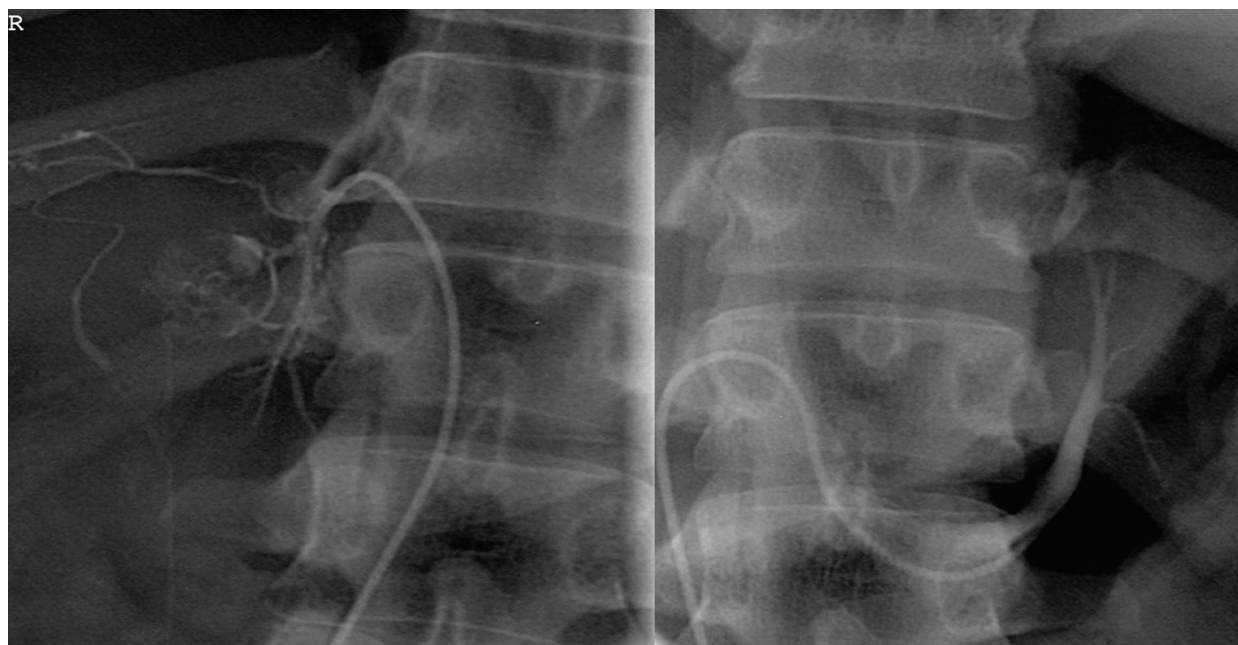


Figure 4. Adrenal venous sampling (AVS) showing right (R) and left adrenal veins.

was also reached on a number of key issues, including the preparation of the patients for the AVS, the procedure for its optimal performance, and the interpretation of its results for diagnostic purposes even in the most challenging cases [50].

Still, the most important prerequisite for overall clinical success is the selective use of AVS that should be based on patient preferences, patient age, clinical comorbidities, and the clinical probability of finding unilateral PA (**Table 1**) [45].

Most appropriate candidates for AVS are patients who desire surgery and are considered to have a high probability of unilateral PA. They have severe hypertension; higher plasma (>25 ng/dL (694 pmol/L)), and urinary (>30 μ g/24 h (83 nmol/d)) levels of aldosterone; are younger (<50 years old); and have more frequent hypokalemia than those with bilateral PA [42]. For example, in a large prospective study of the prevalence of PA in 1125 hypertensive patients, spontaneous hypokalemia <3.5 mmol/L was found in only 17% of patients with bilateral PA compared to about one-half of patients with unilateral disease [51]. In another smaller study, hypokalemia (<3.6 mmol/L) was present in 74.2% of patients with unilateral PA and in 30.8% of patients with bilateral PA [52]. However, these factors are not absolute predictors of unilateral vs. bilateral adrenal disease [42].

SIT is probably the most widely used diagnostic confirmatory test for PA due to feasibility, low cost, and good compliance [1]. It is a reliable alternative to the more expensive and complex fludrocortisone suppression test [53]. There is also some evidence to support its significance for distinguishing unilateral from bilateral disease. Traditionally, it was assumed that aldosterone secretion in patients with unilateral PA appears to be relatively autonomous in response to sodium loading. On the other hand, the ability to influence aldosterone secretion was assumed to be less affected in patients with bilateral PA. Through a working, though abnormal feedback mechanism, they presumably responded

No AVS → adrenalectomy	AVS → adrenalectomy when proven unilateral PA	No AVS → medical treatment
Adrenal tumor on CT with malignant features (e.g., possible adrenocortical carcinoma) [1]	Patient preference for surgical treatment	Patient preference for medical treatment
Age < 35 years with severe PA and an unilateral adrenal macroadenoma with normal contralateral gland [1, 70]	High clinical probability of unilateral PA (e.g., severe hypertension, hypokalemia, higher basal, or post-SIT PAC, age < 50 years) [32, 42]	Patient not suitable for surgery (e.g., older age and/or multiple comorbidities)
	Positive clinical prediction score for unilateral PA [63, 67]	Positive clinical prediction criterion for bilateral PA [68]
	Persistent hypertension less likely [12, 16, 29, 36, 37]	Persistent hypertension more likely [12, 16, 29, 36, 37]
	Higher peripheral plasma 18-oxocortisol [59]	Positive genetic testing for FH-I [1]

Note: PAC, plasma aldosterone concentration; SIT, saline infusion test; FH-I, familial hyperaldosteronism type I.

Table 1. Selective use of adrenal venous sampling (AVS) in primary aldosteronism (PA).

to progressive sodium loading with decreased levels of aldosterone secretion [54]. In fact, when compared to patients with unilateral PA, such patients showed a greater level of reduction of aldosterone after SIT in a study that comprised 100 hypertensive subjects [53]. By contrast, in the PAPY study, no such differences of post-SIT aldosterone cutoffs were detected [55]. However, recent data from German Conn's registry found out that PA patients with post-SIT PAC > 10 ng/dL (>280 pmol/L) had more often unilateral disease with larger aldosteronomas and more severe clinical manifestations, while low post-SIT PAC levels of 5–10 ng/dL (140–280 pmol/L) were an indicator of more frequent bilateral disease [32]. Similarly, PAC after shortened SIT at 2 h was significantly higher in patients with unilateral PA than in those with bilateral PA; however, receiver-operated characteristic (ROC) curve analyses did not yield 100% specificity and sensitivity [56]. Apparently, post-SIT PAC levels provide additional useful information for the subtype classification, but cannot replace AVS as a reference test.

As unilateral disease is reported to be generally more sensitive to ACTH than bilateral PA, several groups explored significance of adrenocorticotropin stimulation test with or without dexamethasone suppression in determining the subtype of PA. PAC level after ACTH stimulation was effective for the diagnosis of unilateral PA. The diagnostic accuracy was around 80–90%, so this test might be used to select patients who have high probability of unilateral disease and definitely require AVS [57, 58].

Apparently, measurement of peripheral plasma 18-oxocortisol could contribute to the clinical determination between unilateral and bilateral PA. The degree of separation between the two subtypes in the study was considerable, with less than 40% of patients not able to be allocated to one or the other [59]. However, until these data are reproduced elsewhere, this surrogate may guide the clinician in selecting patients for AVS but should not be used to direct surgical management [1].

Another approach might be the preselection of patients by mass spectrometry-based peripheral venous steroid profiling for subtyping of PA, on the basis of a report showing that correct classification of 80% of cases of unilateral vs. bilateral PA was possible by the use of a combination of steroids in peripheral plasma [60]. Combining imaging information with steroid profiles might become a future strategy to spare patients who are likely to have bilateral disease from invasive and costly procedures and to select patients with a high likelihood of having unilateral PA for direct surgery or AVS [41].

Contrary to the increased PAC sensitivity to small changes in angiotensin II concentrations, induced by standing upright, which was observed in patients with bilateral PA, no such enhancement was found in those with unilateral PA where PAC displayed diurnal variation. This finding served as a basis for posture simulation test [1]. Unfortunately, some aldosteronomas are also sensitive to angiotensin II, and some patients with bilateral PA have diurnal variations in aldosterone secretion, so this test is generally not useful for subtype diagnosis [52]. It may probably serve only an ancillary role if positive for unilateral PA in those patients for whom AVS was unsuccessful and CT shows a unilateral adrenal mass [1].

3.3. Alternatives to AVS

There is a persistent, ongoing search for reliable alternative methods to recognize unilateral PA and to identify suitable candidates for adrenalectomy without AVS but with very limited success.

3.3.1. Nuclear imaging

(6 β -131 I) Iodomethyl-19-norcholesterol (NP-59) scintigraphy, performed with dexamethasone suppression, has the theoretical advantage of correlating function with anatomical abnormalities. However, the sensitivity of this test is poor in adenomas smaller than 1.5 cm in diameter, so it rarely plays a role in subtype evaluation [1]. (11)C-Metomidate PET-CT has been presented as a sensitive and specific noninvasive alternative to AVS in the management of PA (**Figure 5**) [61].

These data have not been confirmed by subsequent studies. Moreover, metomidate has low selectivity for aldosterone synthase (CYP11B2) over 11 β -hydroxylase (CYP11B1), which affects its specificity for visualization of aldosterone-producing adenomas [41]. A new pre-clinical study reported on (18)F-CDP2230, a specific aldosterone synthase tracer with a high selectivity for imaging zona glomerulosa that might become a promising tool for detecting unilateral subtypes of PA in the future [62].

3.3.2. Clinical prediction scores

Identification of unilateral PA with the help of a clinical prediction score has been proposed. According to the original study, the score exhibits 100% specificity for unilateral disease if either serum potassium concentration is lower than 3.5 mmol/L or an estimated glomerular filtration rate equals or exceeds 100 mL/min/1.73 m², while at the same time, a unilateral adenoma of at least 8 mm in size has to be identifiable on a CT scan. Authors suggested that 30% percent of the included patients would have been appropriately diagnosed as lateralized

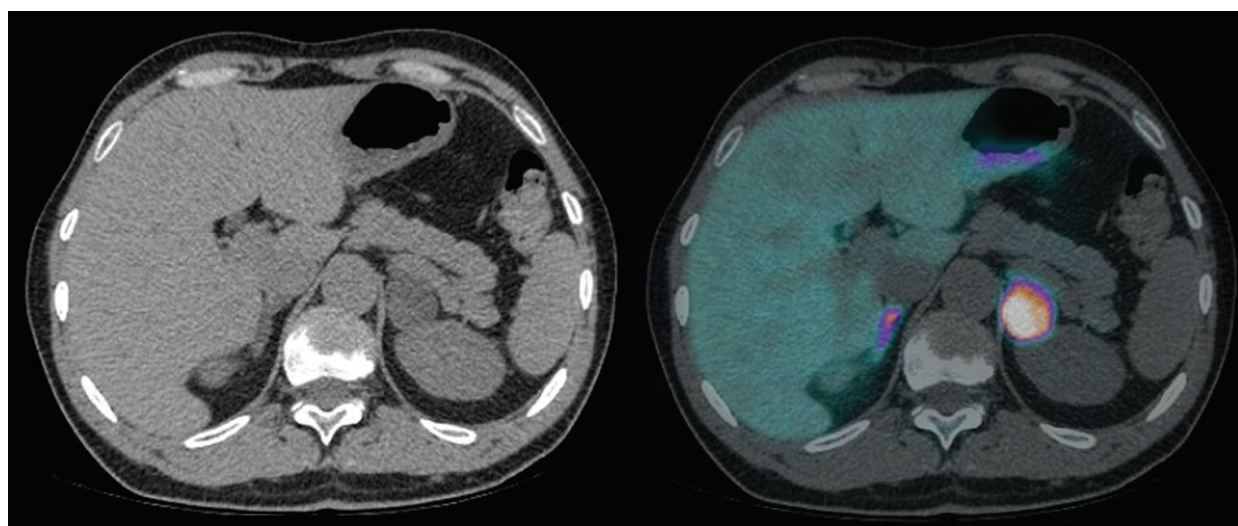


Figure 5. A relatively large nodule (30 mm) in left adrenal gland (CT scan) with high tracer uptake on $(11)\text{C}$ -metomidate PET-CT scan identified as aldosterone-producing adenoma.

based on these criteria without AVS [63]. But when later validated against international databases in three separate studies, the proposed score's specificity was seen to drop to between 80 and 88.5%, making its reliability questionable [64–66]. A different recently developed subtype prediction score incorporated PAC, serum potassium, and ARR in a post-captopril challenge test but failed to achieve 100% specificity for unilateral PA even within the test group [67].

Therefore, most previous attempts to predict unilateral PA without AVS ultimately failed and could have led to wrong decisions for adrenalectomy. It might be more reasonable to avoid AVS only when this would not permanently influence clinical management. Patients with bilateral disease have the most prevalent form of PA and are usually treated medically, so we recently suggested that identification of patients with bilateral PA might be the right approach to decide for or against AVS. We conducted a retrospective diagnostic study at our center, in order to find variables associated with nonlateralized AVS. Combining the identified predictors, namely, serum potassium ≥ 3.5 mmol/L, post-SIT aldosterone < 18 ng/dL (< 500 pmol/L), and either no or bilateral tumor found on CT imaging into a single criterion for predicting nonlateralized AVS seemed a better approach than establishing another score with uncertain validity. In patients with bilateral PA, the sensitivity of the combined criterion was determined to be modest (28.2%), but the approach yielded perfect specificity and therefore a positive predictive value of 100% [68]. If this rule is validated on an independent sample, patients with all three incorporated variables that are readily available and intuitively associated with bilateral PA by themselves [32, 42, 52] could avoid AVS and immediately start with medical treatment. Last but not least, it is important to emphasize that even if the proposed criterion proved wrong in some cases, its use would still be perfectly safe for the patient, because it does not attempt to predict unilateral PA as some other authors unsuccessfully did [63, 67]. While adrenalectomy is not without risk and its effects cannot be reversed, medical treatment could be stopped anytime, and the patient could proceed to AVS and surgery if clinically plausible. Although potentially optimal, surgery is not mandatory for PA caused by

unilateral disease, and the option of medical treatment with MRA should be discussed with all patients [12].

3.4. Patients with PA proceeding to surgery without AVS

It is not possible to avoid AVS in most individuals with PA who are candidates for surgery [1]. There are few exceptions to this rule. In the past, it was proposed by the Mayo Clinic group that in patients younger than 40 years with severe PA, marked spontaneous hypokalemia, and a clearly visible unilateral adrenal cortical macroadenoma (>1 cm and <2 cm in diameter) in imaging, AVS is not necessary [69]. Unfortunately, more recent data from the same authors showed some false positives even in this age group, and CT imaging was 100% concordant with AVS only in a small subgroup of patients with PA, who were younger than 35 years of age [70]. Similarly, in German Conn's registry, it was not possible to rely on imaging alone after classification of patients with an age of 40 years or younger. On the other hand, the clinical prediction score for unilateral PA [63] achieved a specificity of 100% when used in the same cohort [64].

4. Conclusion

A careful selection of patients for AVS is possible and should be ideally undertaken in all patients with PA who pursue the surgical management except in infrequent younger patients with Conn's adenoma who could probably proceed directly to unilateral adrenalectomy. Naturally, AVS is not needed in some patients who prefer medical therapy over an adrenalectomy and in those who are not suitable for surgery due to comorbidities or age. If validated on an independent sample, our simple clinical prediction criterion could accurately determine a subset of patients with bilateral PA who should avoid unnecessary AVS and immediately commence with medical treatment. In addition, a careful identification of prospectively evaluated factors associated with long-term BP control after adrenalectomy should guide preoperative individual patient counseling and ultimate decision for or against AVS and surgery.

Author details

Tomaz Kocjan

Address all correspondence to: tomaz.kocjan@kclj.si

Department of Endocrinology, Diabetes and Metabolic Diseases, University Medical Centre Ljubljana, Ljubljana, Slovenia

References

- [1] Funder JW, Carey RM, Mantero F, Murad MH, Reincke M, Shibata H, et al. The management of primary aldosteronism: case detection, diagnosis, and treatment: an endocrine society clinical practice guideline. *J Clin Endocrinol Metab.* 2016;101:1889-916.

- [2] Hannemann A, Wallaschofski H. Prevalence of primary aldosteronism in patient's cohorts and in population-based studies--a review of the current literature. *Horm Metab Res.* 2012;44:157-62.
- [3] Rossi G-P, Sechi LA, Giacchetti G, Ronconi V, Strazzullo P, Funder JW. Primary aldosteronism: cardiovascular, renal and metabolic implications. *Trends Endocrinol Metab TEM.* 2008;19:88-90.
- [4] Savard S, Amar L, Plouin P-F, Steichen O. Cardiovascular complications associated with primary aldosteronism: a controlled cross-sectional study. *Hypertension.* 2013;62:331-6.
- [5] Mulatero P, Monticone S, Bertello C, Viola A, Tizzani D, Iannaccone A, et al. Long-term cardio- and cerebrovascular events in patients with primary aldosteronism. *J Clin Endocrinol Metab.* 2013;98:4826-33.
- [6] Reincke M, Rump LC, Quinkler M, Hahner S, Diederich S, Lorenz R, et al. Risk factors associated with a low glomerular filtration rate in primary aldosteronism. *J Clin Endocrinol Metab.* 2009;94:869-75.
- [7] Reincke M, Fischer E, Gerum S, Merkle K, Schulz S, Pallauf A, et al. Observational study mortality in treated primary aldosteronism: the German Conn's registry. *Hypertens.* 2012;60:618-24.
- [8] Ouzan J, Pérault C, Lincoff AM, Carré E, Mertes M. The role of spironolactone in the treatment of patients with refractory hypertension. *Am J Hypertens.* 2002;15:333-9.
- [9] Eide IK, Torjesen PA, Drolsum A, Babovic A, Lilledahl NP. Low-renin status in therapy-resistant hypertension: a clue to efficient treatment. *J Hypertens.* 2004;22:2217-26.
- [10] Williams B, MacDonald TM, Morant S, Webb DJ, Sever P, McInnes G, et al. Spironolactone versus placebo, bisoprolol, and doxazosin to determine the optimal treatment for drug-resistant hypertension (PATHWAY-2): a randomised, double-blind, crossover trial. *Lancet.* 2015;386:2059-68.
- [11] Funder JW. Primary aldosteronism: clinical lateralization and costs. *J Clin Endocrinol Metab.* 2012;97:3450-2.
- [12] Steichen O, Lorthioir A, Zinzindohoue F, Plouin P-F, Amar L. Outcomes of drug-based and surgical treatments for primary aldosteronism. *Adv Chronic Kidney Dis.* 2015;22:196-203.
- [13] Ng L, Libertino JM. Adrenocortical carcinoma: diagnosis, evaluation and treatment. *J Urol.* 2003;169:5-11.
- [14] Rossi GP. A comprehensive review of the clinical aspects of primary aldosteronism. *Nat Rev Endocrinol.* 2011;7:485-95.
- [15] Solar M, Malirova E, Ballon M, Pelouch R, Ceral J. Confirmatory testing in primary aldosteronism: extensive medication switching is not needed in all patients. *Eur J Endocrinol.* 2012;166:679-86.

- [16] Muth A, Ragnarsson O, Johannsson G, Wängberg B. Systematic review of surgery and outcomes in patients with primary aldosteronism. *Br J Surg*. 2015;102:307-17.
- [17] Karagiannis A, Tziomalos K, Kakafika AI, Athyros VG, Harsoulis F, Mikhailidis DP. Medical treatment as an alternative to adrenalectomy in patients with aldosterone-producing adenomas. *Endocr Relat Cancer*. 2008;15:693-700.
- [18] Marzano L, Colussi G, Sechi LA, Catena C. Adrenalectomy is comparable with medical treatment for reduction of left ventricular mass in primary aldosteronism: meta-analysis of long-term studies. *Am J Hypertens*. 2015;28:312-8.
- [19] Catena C, Colussi G, Nadalini E, Chiuch A, Baroselli S, Lapenna R, et al. Cardiovascular outcomes in patients with primary aldosteronism after treatment. *Arch Intern Med*. 2008;168:80-5.
- [20] Catena C, Lapenna R, Baroselli S, Nadalini E, Colussi G, Novello M, et al. Insulin sensitivity in patients with primary aldosteronism: a follow-up study. *J Clin Endocrinol Metab*. 2006;91:3457-63.
- [21] Apostolopoulou K, Künzel HE, Gerum S, Merkle K, Schulz S, Fischer E, et al. Gender differences in anxiety and depressive symptoms in patients with primary hyperaldosteronism: a cross-sectional study. *World J Biol Psychiatry*. 2014;15:26-35.
- [22] Fischer E, Beuschlein F, Degenhart C, Jung P, Bidlingmaier M, Reincke M. Spontaneous remission of idiopathic aldosteronism after long-term treatment with spironolactone: results from the German Conn's Registry. *Clin Endocrinol (Oxf)*. 2012;76:473-7.
- [23] Yoneda T, Demura M, Takata H, Kometani M, Karashima S, Yamagishi M, et al. Unilateral primary aldosteronism with spontaneous remission after long-term spironolactone therapy. *J Clin Endocrinol Metab*. 2012;97:1109-13.
- [24] Kline GA, Pasiaka JL, Harvey A, So B, Dias VC. Medical or surgical therapy for primary aldosteronism: post-treatment follow-up as a surrogate measure of comparative outcomes. *Ann Surg Oncol*. 2013;20:2274-8.
- [25] Ahmed AH, Gordon RD, Sukor N, Pimenta E, Stowasser M. Quality of life in patients with bilateral primary aldosteronism before and during treatment with spironolactone and/or amiloride, including a comparison with our previously published results in those with unilateral disease treated surgically. *J Clin Endocrinol Metab*. 2011;96:2904-11.
- [26] Stowasser M. Adrenal venous sampling for differentiating unilateral from bilateral primary aldosteronism: still the best, but could be better. *Hypertension*. 2015;65:704-6.
- [27] Reimel B, Zanolco K, Russo MJ, Zarnegar R, Clark OH, Allendorf JD, et al. The management of aldosterone-producing adrenal adenomas – does adrenalectomy increase costs?. *Surgery*. 2010;148:1178-85; discussion 1185.
- [28] Iacobone M, Citton M, Viel G, Rossi GP, Nitti D. Approach to the surgical management of primary aldosteronism. *Gland Surg*. 2015;4:69-81.

- [29] Steichen O, Zinzindohoué F, Plouin P-F, Amar L. Outcomes of adrenalectomy in patients with unilateral primary aldosteronism: a review. *Horm Metab Res.* 2012;44:221-7.
- [30] Iwakura Y, Ito S, Morimoto R, Kudo M, Ono Y, Nezu M, et al. Renal resistive index predicts postoperative blood pressure outcome in primary aldosteronism. *Hypertension.* 2016;67:654-60.
- [31] Arnesen T, Glomnes N, Strømsøy S, Knappskog S, Heie A, Akslen LA, et al. Outcome after surgery for primary hyperaldosteronism may depend on KCNJ5 tumor mutation status: a population-based study from Western Norway. *Langenbecks Arch Surg.* 2013;398:869-74.
- [32] Weigel M, Riester A, Hanslik G, Lang K, Willenberg HS, Endres S, et al. Post saline infusion test aldosterone levels indicate severity and outcome in primary aldosteronism. *Eur J Endocrinol.* 2015;172:443-50.
- [33] Umakoshi H, Tanase-Nakao K, Wada N, Ichijo T, Sone M, Inagaki N, et al. Importance of contralateral aldosterone suppression during adrenal vein sampling in the subtype evaluation of primary aldosteronism. *Clin Endocrinol (Oxf).* 2015;83:462-7.
- [34] Wolley MJ, Gordon RD, Ahmed AH, Stowasser M. Does contralateral suppression at adrenal venous sampling predict outcome following unilateral adrenalectomy for primary aldosteronism? A retrospective study. *J Clin Endocrinol Metab.* 2015;100:1477-84.
- [35] Monticone S, Satoh F, Viola A, Fischer E, Vonend O, Bernini G, et al. Aldosterone suppression on contralateral adrenal during adrenal vein sampling does not predict blood pressure response after adrenalectomy. *J Clin Endocrinol Metab.* 2014;99:4158-66.
- [36] Zarnegar R, Young WF, Lee J, Sweet MP, Kebebew E, Farley DR, et al. The aldosteronoma resolution score: predicting complete resolution of hypertension after adrenalectomy for aldosteronoma. *Ann Surg.* 2008;247:511-8.
- [37] Utsumi T, Kamiya N, Endo T, Yano M, Kamijima S, Kawamura K, et al. Development of a novel nomogram to predict hypertension cure after laparoscopic adrenalectomy in patients with primary aldosteronism. *World J Surg.* 2014;38:2640-4.
- [38] Kempers MJ, Lenders JW, van Outheusden L, van der Wilt GJ, Kool LJS, Hermus AR, et al. Systematic review: diagnostic procedures to differentiate unilateral from bilateral adrenal abnormality in primary aldosteronism. *Ann Intern Med.* 2009;151:329-37.
- [39] Omura M, Sasano H, Fujiwara T, Yamaguchi K, Nishikawa T. Unique cases of unilateral hyperaldosteronemia due to multiple adrenocortical micronodules, which can only be detected by selective adrenal venous sampling. *Metabolism.* 2002;51:350-5.
- [40] Dekkers T, Prejbisz A, Kool LJS, Groenewoud HJMM, Velema M, Spiering W, et al. Adrenal vein sampling versus CT scan to determine treatment in primary aldosteronism: an outcome-based randomised diagnostic trial. *Lancet Diabetes Endocrinol.* 2016;4:739-46.
- [41] Reincke M. Adrenal vein sampling for subtyping in primary aldosteronism. *Lancet Diabetes Endocrinol.* 2016;4:718-9.

- [42] Young WF. Minireview: primary aldosteronism--changing concepts in diagnosis and treatment. *Endocrinology*. 2003;144:2208-13.
- [43] Betz MJ, Degenhart C, Fischer E, Pallauf A, Brand V, Linsenmaier U, et al. Adrenal vein sampling using rapid cortisol assays in primary aldosteronism is useful in centers with low success rates. *Eur J Endocrinol*. 2011;165:301-6.
- [44] Park SI, Rhee Y, Lim JS, Park S, Kang SW, Lee MS, et al. Right adrenal venography findings correlated with C-arm CT for selection during C-arm CT-assisted adrenal vein sampling in primary aldosteronism. *Cardiovasc Intervent Radiol*. 2014;37:1469-75.
- [45] Young WF, Stanson AW. What are the keys to successful adrenal venous sampling (AVS) in patients with primary aldosteronism?. *Clin Endocrinol (Oxf)*. 2009;70:14-7.
- [46] Daunt N. Adrenal vein sampling: how to make it quick, easy, and successful. *Radiographics*. 2005;25 Suppl 1:S143-58.
- [47] Rossi GP, Barisa M, Allolio B, Auchus RJ, Amar L, Cohen D, et al. The Adrenal Vein Sampling International Study (AVIS) for identifying the major subtypes of primary aldosteronism. *J Clin Endocrinol Metab*. 2012;97:1606-14.
- [48] Lethielleux G, Amar L, Raynaud A, Plouin P-F, Steichen O. Influence of diagnostic criteria on the interpretation of adrenal vein sampling. *Hypertension*. 2015;65:849-54.
- [49] Monticone S, Viola A, Rossato D, Veglio F, Reincke M, Gomez-Sanchez C, et al. Adrenal vein sampling in primary aldosteronism: towards a standardised protocol. *Lancet Diabetes Endocrinol*. 2015;3:296-303.
- [50] Rossi GP, Auchus RJ, Brown M, Lenders JWM, Naruse M, Plouin PF, et al. An expert consensus statement on use of adrenal vein sampling for the subtyping of primary aldosteronism. *Hypertension*. 2014;63:151-60.
- [51] Rossi GP, Bernini G, Caliumi C, Desideri G, Fabris B, Ferri C, et al. A prospective study of the prevalence of primary aldosteronism in 1,125 hypertensive patients. *J Am Coll Cardiol*. 2006;48:2293-300.
- [52] Mulatero P, Bertello C, Rossato D, Mengozzi G, Milan A, Garrone C, et al. Roles of clinical criteria, computed tomography scan, and adrenal vein sampling in differential diagnosis of primary aldosteronism subtypes. *J Clin Endocrinol Metab*. 2008;93:1366-71.
- [53] Mulatero P, Milan A, Fallo F, Regolisti G, Pizzolo F, Fardella C, et al. Comparison of confirmatory tests for the diagnosis of primary aldosteronism. *J Clin Endocrinol Metab*. 2006;91:2618-23.
- [54] Holland OB, Brown H, Kuhnert L, Fairchild C, Risk M, Gomez-Sanchez CE. Further evaluation of saline infusion for the diagnosis of primary aldosteronism. *Hypertension*. 1984;6:717-23.
- [55] Rossi GP, Belfiore A, Bernini G, Desideri G, Fabris B, Ferri C, et al. Prospective evaluation of the saline infusion test for excluding primary aldosteronism due to aldosterone-producing adenoma. *J Hypertens*. 2007;25:1433-42.

- [56] Nanba K, Tsuiki M, Umakoshi H, Nanba A, Hirokawa Y, Usui T, et al. Shortened saline infusion test for subtype prediction in primary aldosteronism. *Endocrine*. 2015;50:802-6.
- [57] Sonoyama T, Sone M, Miyashita K, Tamura N, Yamahara K, Park K, et al. Significance of adrenocorticotropin stimulation test in the diagnosis of an aldosterone-producing adenoma. *J Clin Endocrinol Metab*. 2011;96:2771-8.
- [58] Jiang Y, Zhang C, Wang W, Su T, Zhou W, Jiang L, et al. Diagnostic value of ACTH stimulation test in determining the subtypes of primary aldosteronism. *J Clin Endocrinol Metab*. 2015;100:1837-44.
- [59] Satoh F, Morimoto R, Ono Y, Iwakura Y, Omata K, Kudo M, et al. Measurement of peripheral plasma 18-oxocortisol can discriminate unilateral adenoma from bilateral diseases in patients with primary aldosteronism. *Hypertension*. 2015;65:1096-102.
- [60] Eisenhofer G, Dekkers T, Peitzsch M, Dietz AS, Bidlingmaier M, Treitl M, et al. Mass spectrometry-based adrenal and peripheral venous steroid profiling for subtyping primary aldosteronism. *Clin Chem*. 2016;62:514-24.
- [61] Burton TJ, Mackenzie IS, Balan K, Koo B, Bird N, Soloviev DV, et al. Evaluation of the sensitivity and specificity of (11)C-metomidate positron emission tomography (PET)-CT for lateralizing aldosterone secretion by Conn's adenomas. *J Clin Endocrinol Metab*. 2012;97:100-9.
- [62] Abe T, Naruse M, Young WF, Kobashi N, Doi Y, Izawa A, et al. A novel CYP11B2-specific imaging agent for detection of unilateral subtypes of primary aldosteronism. *J Clin Endocrinol Metab*. 2016;101:1008-15.
- [63] Küpers EM, Amar L, Raynaud A, Plouin P-F, Steichen O. A clinical prediction score to diagnose unilateral primary aldosteronism. *J Clin Endocrinol Metab*. 2012;97:3530-7.
- [64] Riester A, Fischer E, Degenhart C, Reiser MF, Bidlingmaier M, Beuschlein F, et al. Age below 40 or a recently proposed clinical prediction score cannot bypass adrenal venous sampling in primary aldosteronism. *J Clin Endocrinol Metab*. 2014;99:E1035-9.
- [65] Venos ES, So B, Dias VC, Harvey A, Pasioka JL, Kline GA. A clinical prediction score for diagnosing unilateral primary Aldosteronism may not be generalizable. *BMC Endocr Disord*. 2014;14:94.
- [66] Sze WCC, Soh LM, Lau JH, Reznick R, Sahdev A, Matson M, et al. Diagnosing unilateral primary aldosteronism - comparison of a clinical prediction score, computed tomography and adrenal venous sampling. *Clin Endocrinol (Oxf)*. 2014;81:25-30.
- [67] Nanba K, Tsuiki M, Nakao K, Nanba A, Usui T, Tagami T, et al. A subtype prediction score for primary aldosteronism. *J Hum Hypertens*. 2014;28:716-20.
- [68] Kocjan T, Janez A, Stankovic M, Vidmar G, Jensterle M. A new clinical prediction criterion accurately determines a subset of patients with bilateral primary aldosteronism before adrenal venous sampling. *Endocr Pract*. 2016;22:587-94.

- [69] Young WF, Stanson AW, Thompson GB, Grant CS, Farley DR, van Heerden JA. Role for adrenal venous sampling in primary aldosteronism. *Surgery*. 2004;136:1227-35.
- [70] Lim V, Guo Q, Grant CS, Thompson GB, Richards ML, Farley DR, et al. Accuracy of adrenal imaging and adrenal venous sampling in predicting surgical cure of primary aldosteronism. *J Clin Endocrinol Metab*. 2014;99:2712-9.

IntechOpen

IntechOpen