

We are IntechOpen, the world's leading publisher of Open Access books Built by scientists, for scientists

6,900

Open access books available

186,000

International authors and editors

200M

Downloads

Our authors are among the

154

Countries delivered to

TOP 1%

most cited scientists

12.2%

Contributors from top 500 universities



WEB OF SCIENCE™

Selection of our books indexed in the Book Citation Index
in Web of Science™ Core Collection (BKCI)

Interested in publishing with us?
Contact book.department@intechopen.com

Numbers displayed above are based on latest data collected.
For more information visit www.intechopen.com



Examining Left Axis Deviation

Madhur Dev Bhattarai

Additional information is available at the end of the chapter

<http://dx.doi.org/10.5772/intechopen.69435>

Abstract

Axis deviation indicates possible presence of various conditions. It also affects the QRS and T morphologies. The limits of axis deviations are as such arbitrary and the approximate degree of axis itself can be easily determined. Various conditions often shift the QRS axis without fulfilling the defined limits of deviations in the initial stage. The associations with various conditions may be missed if such partial shift of the axis is disregarded. Isolated left axis deviation is relatively common in the general population and left anterior fascicular conduction delay is the most common cause of such isolated leftward shift of axis. Vulnerability of left anterior fascicle to interruption makes it likely to be affected by both atherosclerosis and fibrodegeneration. Glucose intolerance may increase the risk of both atherosclerosis and fibrodegeneration. The association of glucose intolerance with leftward shift of axis has been increasingly noticed. Research studies to get further evidences are required; however, utilizing the already available evidences to protect the susceptible population is equally essential. Documenting the approximate degree itself of the axis is the bottom line to study the association with the levels of various possible risk factors like glycated hemoglobin.

Keywords: ECG axis, left axis deviation, left anterior fascicular block, glucose intolerance, diabetes, diabetes prevention, indigenous population, ageing, Bachmann's bundle, neuropathy, white matter hyperintensities

1. Introduction

The limits for mean frontal plane QRS axis deviations are considered variedly [1–11] and are necessarily arbitrary [5]. In this chapter, determination of left axis deviation and its effects on QRS-T morphology and its causes will be discussed. The left axis deviation and leftward shift of axis have been increasingly noticed in asymptomatic relatively younger adults with diabetes. Next in the chapter, the epidemiology, pathogenesis, correlation with other related factors, and implications of the possible association between glucose intolerance and left axis deviation will be discussed.

2. The conducting system of the heart

In the heart, apart from ordinary myocardium and supporting fibrous skeleton, there are small groups of specialized neuromuscular cells in the myocardium which initiate and conduct cardiac electrical impulse [9, 12]. **Figure 1** shows the different parts of the specialized cardiac conducting system from the sinus node to the atrioventricular (AV) node with three internodal tracts in-between and then from the AV node to the His-Purkinje system [9, 12]. The atria and the ventricles are separated by a ring of fibrous tissue, which does not conduct electrical impulse. Thus, the electrical activity from the atria can only spread to the ventricles through the atrioventricular node and the atrioventricular bundle. Atrioventricular bundle (Bundle of His) originates from atrioventricular node and divides at the upper end of the ventricular system into right and left bundle branch [12]. The right

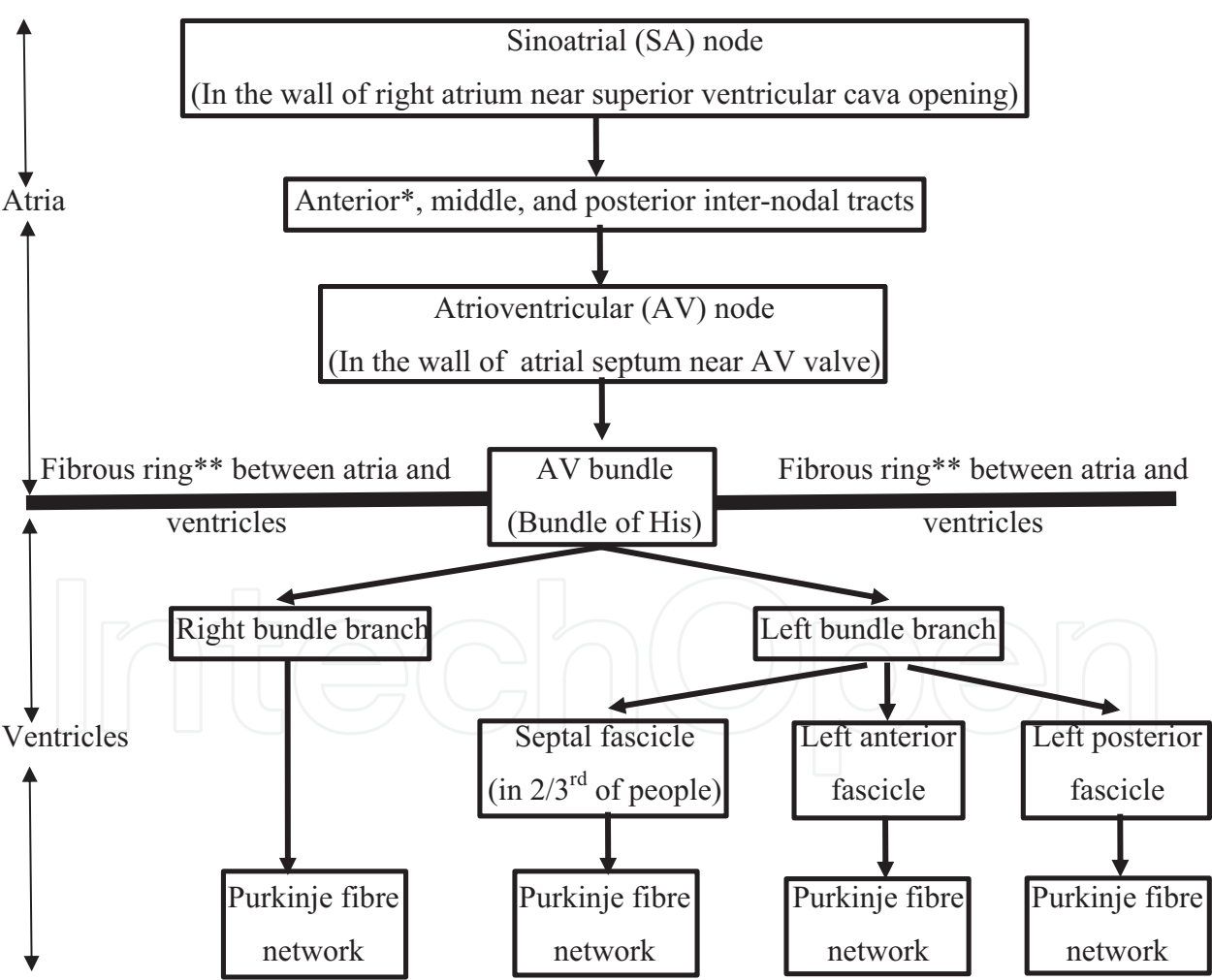


Figure 1. Different parts (shown in the boxes) of specialized cardiac conducting system from the sinoatrial node to the His-Purkinje system.

*Interatrial tract or the Bachmann’s bundle is a branch of the anterior internodal tract to the left atrium which serves as the preferential path for electrical activation of the left atrium.

**Fibrous ring does not conduct electrical impulse.

bundle branch does not divide, but the left bundle branch further divides into three separate fascicles, namely septal (median or medial) fascicle, left anterior fascicle, and left posterior fascicle. Right bundle branch and different fascicles of left bundle branch ultimately break up within the ventricular myocardium into fine fibers as the network of Purkinje fibers [12]. The left anterior fascicular block (or the left anterior hemiblock) causes left axis deviation and the left posterior fascicular block (or left posterior hemiblock) causes right axis deviation. Isolated left posterior fascicular block is extremely rare [2, 5]. Septal fascicle is found in nearly two-thirds of people [13]. Delay or block of left septal fascicle may occur in diabetes, Chagas disease, and various cardiac diseases and may manifest in the ECG with prominent R waves in leads V1–V3, loss of septal Q waves, initial q waves in leads V1 and V2, and normal QRS axis [2]. However, the term left septal fascicular block is not recommended because of the lack of universally accepted criteria [3].

3. The normal mean frontal plane QRS axis range

An electrocardiogram is a record of the origin and propagation of the electric action potential through heart muscle. Depolarization spreads throughout the heart to stimulate the myocardium to contract and the vector demonstrates the direction in which depolarization is moving. The general, mean, or dominant direction of all these vectors is known as the mean vector and is expressed electrocardiographically as the mean QRS axis [2] which is located by degrees [1]. The direction of the mean QRS axis on the frontal plane is known as the mean frontal plane QRS axis and is determined by the six frontal plane limb leads; they are three standard bipolar limb leads I, II, and III and three augmented unipolar limb leads aVR, aVL, and aVF. The frontal plane limb leads are conventionally represented on a hexaxial reference system (**Figure 2**).

In most normal adults, the mean QRS vector points downward and to the left [1] with the electric axis of the QRS complex almost parallel to the anatomic base-to-apex axis of the heart in the direction of the lead II [6]. Most normal frontal plane QRS axes in the adults are directed within a narrower range between $+40^\circ$ and $+60^\circ$ [2], around 5 o'clock position [7] (**Figure 2**). Such range has been reported particularly at sea level from studies of axes conducted at different altitudes [14, 15]. Leads I and aVF, II and aVL, and III and aVR are at right angles to each other; that is, each of the pair is the right-angled partner leads. The concept of the right-angled partner leads (**Figure 2**) is helpful to quickly find the lead with the relatively tall R wave after looking at the lead with the equiphasic QRS complex. Coincidentally, but useful for remembering easily the pairs of the right-angled partner leads, the letters F, L, and R of the augmented limb leads are in the increasing alphabetic order like the numbers I, II, and III of the bipolar limb leads.

There are variations not only in the conventionally considered limits of normal axis and left, right, and extreme axis deviations in the adults but also in the nomenclature of the deviations and in the use of positive and negative signs of the degrees of the axis. The indicated limits of normal axis and left, right, and extreme axis deviations in the adults by various publications are shown below; for example

- **Normal axis** as 0° to $+90^\circ$ [1, 2], -30° to $+90^\circ$ [4, 6, 7, 10], and -30° to $+100^\circ$ [5, 9, 16].
- **Left axis deviation** as 0° to -90° [1, 2] and -30° to -90° [4–6, 10] with axis between 0° and -30° as *slight left axis deviation* [2], and between -30° and -45° as *moderate*, and between -45° and -90° as *marked left axis deviations* [3].
- **Right axis deviation** as $+90^\circ$ to 180° [2–4, 6], $+90^\circ$ to $+150^\circ$ [11], $+100^\circ$ to 180° [5, 16], $+110^\circ$ to 180° [9], $+90^\circ$ to -150° [10], and $+90^\circ$ to -90° [7].
- **Extreme axis deviation** as -90° to 180° [1, 2, 4–6] and -90° to -149° [10].

The extreme axis deviation [4–6] has also been

- included under right axis deviation [7],
- called as the northwest region axis [2], extreme right axis deviation [1], and extreme left axis deviation [9], and
- even indicated as the marked left or right axis deviation [5].

Similarly, there are variations in the use of + and – signs. For 180° ,

- many use \pm [2, 6, 9],
- some use both $+180^\circ$ and -180° in their axis range figure [7],
- others use + sign [5], and
- still others use no + or – sign to 180° [4, 16].

For other positive axis degrees many use + signs [2, 5–7, 9, 16] and some do not use + sign [3, 4].

In this chapter, + sign has been used for positive degree and – sign for negative degree. As 0° and 180° are common to both positive and negative degree sides and there is no other similar degree to cause confusion, no sign has been indicated for 0° and 180° .

The consensus in these issues will help the communication among clinicians and between students and teachers especially during the examination of the student. However, even the consensually defined limits of normal axis and left, right, and extreme axis deviations should not make the clinicians and researchers to disregard the leftward or rightward shift of the axis from its usual range of degree (between $+40^\circ$ and $+60^\circ$) in the adults (**Figure 2**). Otherwise the important correlation of the shift of axis with the patients' clinical condition or with the various factors in the research study may be missed; this is also further discussed later. With the possibility of easy determination of the approximate degree of axis by any clinicians and researches (see Section 4) and with the support of the computer interpretation of ECG readings at hand, the approximate degrees of the axis should be recorded.

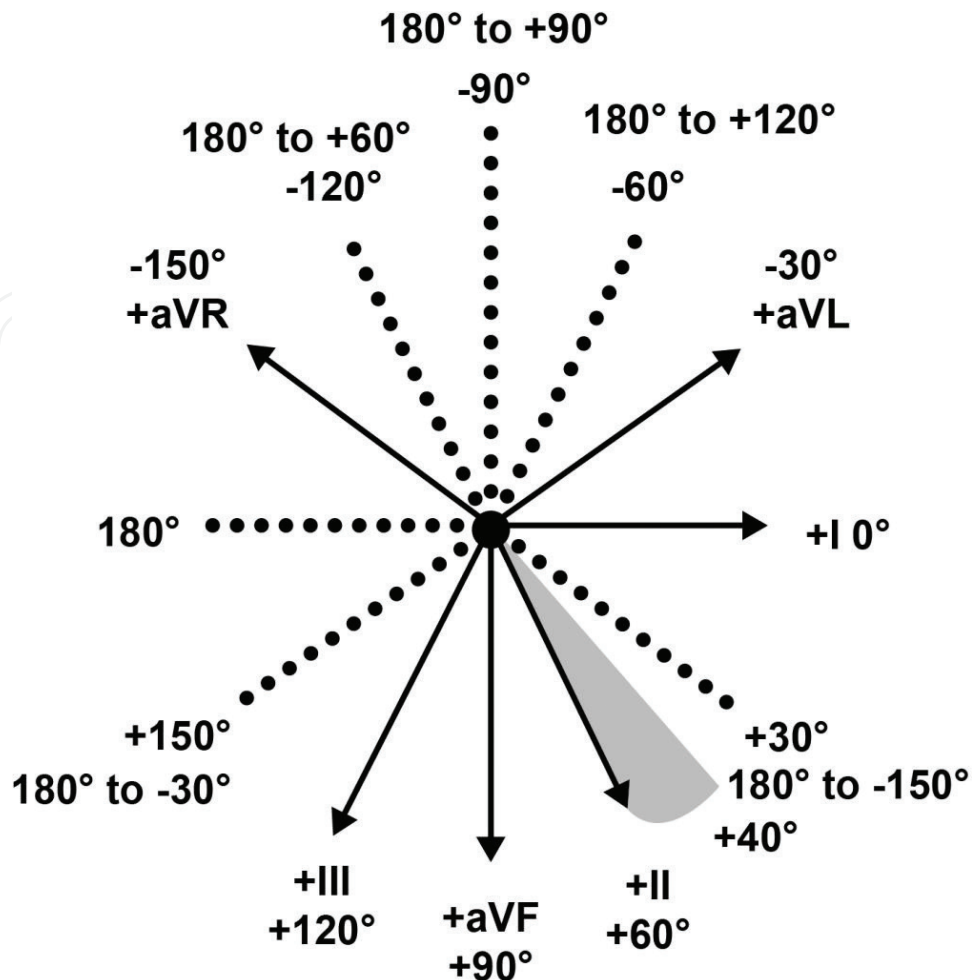


Figure 2. The frontal plane limb leads conventionally represented on a hexaxial reference system showing the range of degrees (between $+40^\circ$ and $+60^\circ$) of most normal frontal QRS axes in the adults (shown as the shaded area). Note: **The positive and negative poles of each lead:** The arrow head on the solid line designates the positive pole of the corresponding lead axis and the dotted line the negative pole. **The 30° differences:** There are 30° differences between the positive or negative poles of the nearby leads. **The right-angled partner leads:** Leads I and aVF, II, and aVL, and III and aVR are at right angles to each other and the axis causing equiphasic deflections of QRS complex in one lead will cause maximum upward and downward deflections in the opposite ends of the other partner lead at right angle.

4. Determination of frontal plane QRS axis

4.1. Method of determining the approximate degree of mean axis

When depolarization moves in a direction with the cardiac axis toward the positive pole of a lead, the deflection recorded by the lead is upward (positive), if it is away from the positive pole it is negative (downward) and if it is perpendicular to the orientation of a lead the deflection recorded by the lead is isoelectric or equiphasic (QR or RS) QRS with equal magnitudes of upward (positive) and negative (downward) deflection [5]. The leads between the one recording the equiphasic (QR or RS) deflection and the other recording the maximum upward deflection will record the increasing degree of upward deflection; this area can be designated as “positive-half area of the mean axis” (Figure 3). Similarly, the leads

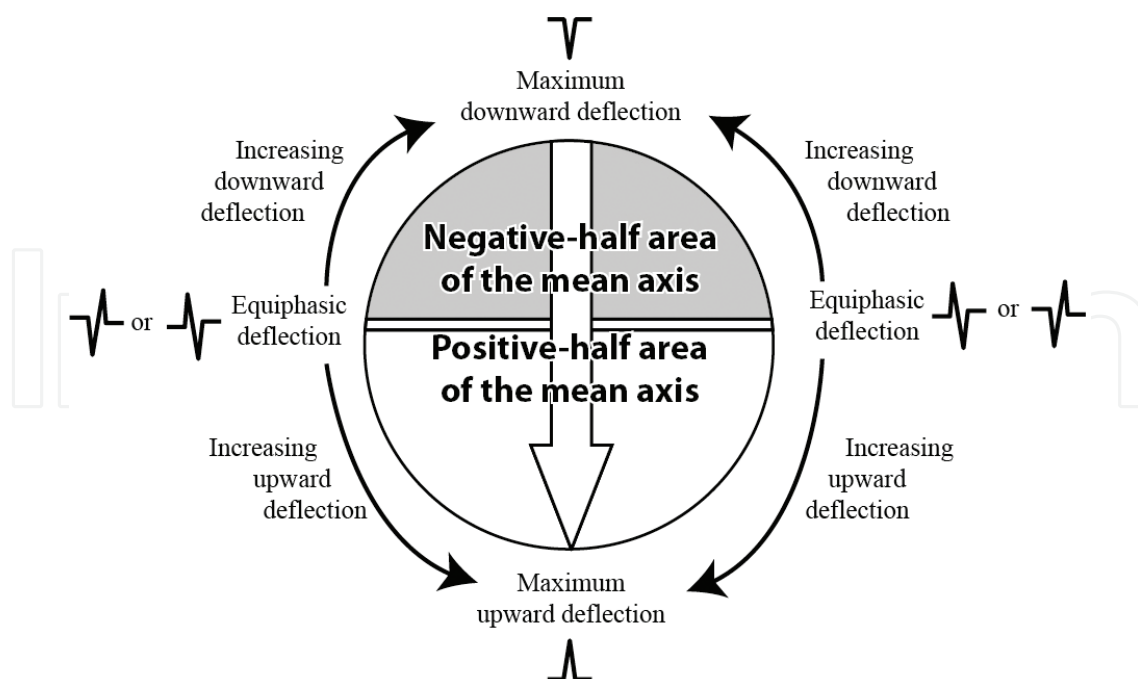


Figure 3. Varying degrees of upward or downward deflections recorded by different leads at various places in relation to the direction of cardiac axis (shown as the big central arrow). The leads in the “positive-half area of the mean axis” and “negative-half area of the mean axis” will record predominantly positive and negative QRS complex, respectively, increasingly so as per the distance from the points of equiphase deflection (QR or RS).

between the one recording the equiphase (QR or RS) deflection and the other recording the maximum downward deflection will record the increasing degree of downward deflection; this area can be designated as “negative-half area of the mean axis.” The mean QRS axis can, thus, be determined on the basis of one or both of the two rules [5]. As a general rule the mean QRS points

- midway between the axes of two extremity leads that show tall R waves of equal amplitude, and
- at 90° (right angle) to any extremity lead that shows a biphasic (QR or RS) complex and in the direction of leads that show relatively tall R waves [5].

With these considerations, the mean frontal plane QRS axis can be determined with an error of 10–15° [5]. Thus, to determine the approximate degree of axis, one has to find the lead in which the QRS complex is most equiphase (QR or RS); the axis is directed perpendicular to this lead (**Figure 4**). If the lead with clear equiphase QRS complex is not seen, then the lead having the QRS with the largest positive amplitude should be looked for. If there are two nearby leads which have almost equal tall R wave, the axis is mostly directed in between them (**Figure 4**).

The degree of the mean axis can be further reconfirmed by considering whether it is in accord or not with the QRS direction and amplitude in other leads in the areas in front of the line of the equiphase complex, that is, in the *positive-half area of the mean axis* (**Figure 3**), and/or behind the line of the equiphase complex, that is, in the *negative-half area of the mean axis*. This

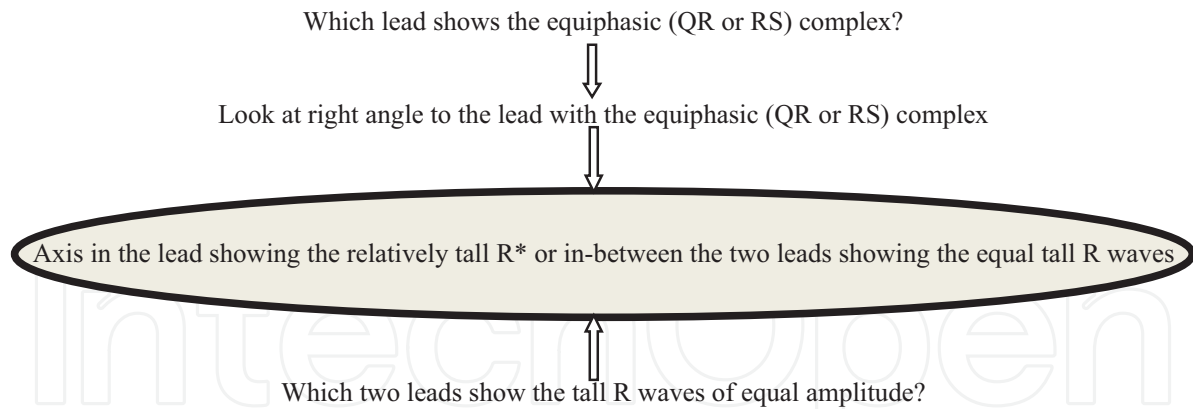


Figure 4. Method of determination of the approximate degree of the frontal plane QRS axis—The degree of the mean axis can be further reconfirmed by considering whether it is in accord or not with the QRS direction and amplitude in other leads in the areas in front of and/or behind the line of the equiphasic complex. *For example, if the relatively tall R wave is in the lead aVL the axis is approximately -30° , if in I it is 0° , if in II it is $+60^\circ$, if in aVF it is $+90^\circ$, if in III it is $+120^\circ$, and if in aVR it is -150° .

method is perhaps the most appropriate observational technique to follow in the routine setting. The other method of the mean axis determination by plotting the net height or depth of two standard bipolar (not the augmented) limb leads [8, 9] is generally not practiced.

Sometimes an electrocardiogram with indeterminate QRS axis is encountered. In indeterminate QRS axis, the algebraic sum of major positive and major negative QRS waves is zero in each of leads I, II, and III, or the information from these three leads is incongruous [10]. In the absence of a dominant QRS deflection, as in an equiphasic QRS complex, the axis is said to be indeterminate [9]. The separate determination of the axes of the initial and later part of QRS complex may indicate, or help to correlate with, other findings. For example, in right bundle branch block (RBBB) the axis determination is of importance in diagnosing associated left anterior or posterior fascicular block, as right bundle branch on its own will not cause axis deviation. In right bundle branch block, estimating the frontal plane QRS based on the first 80–100 ms of the QRS deflection, primarily reflecting activation of the left ventricle, may help [4]. For left bundle branch block (LBBB) and other intraventricular delays, the entire QRS or just the initial 80–100 ms can be used [4].

4.2. An example of determination of the mean axis

An ECG with the recordings of the limb leads in an asymptomatic person is shown in **Figure 5** with left axis deviation. The QRS complex in II (which is at $+60^\circ$ in the hexaxial reference system) is most equiphasic; thus, the axis will be 90° to it, either in -30° or $+150^\circ$ (**Figure 2**). Since R wave in the lead aVL is positive and has almost the largest R wave amplitude, it dictates the direction of the vector. Thus, the QRS axis is leftward between around -30° . However, if we look carefully the lead II is not exactly equiphasic but it has slightly more negative complex especially the second QRS complex, so the lead II lies in the “negative-half area of the mean axis” (**Figure 3**). Similarly, the lead aVR is also near equiphasic with slightly more negative QRS complex, that is, the lead aVR is also in the “negative-half area of the mean axis” (**Figure 3**). As the

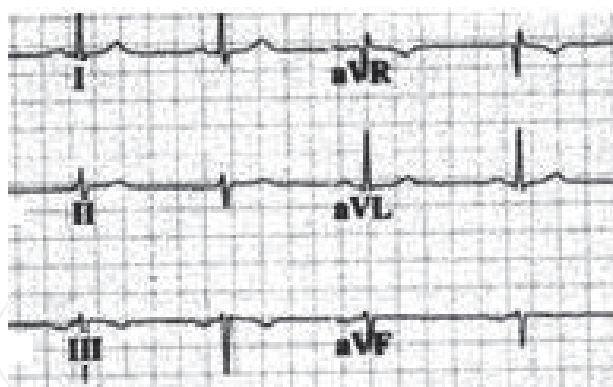


Figure 5. An electrocardiogram recording of the limb leads in an asymptomatic person.

lead II has slightly less negative QRS complex than the lead aVR, the lead II is slightly nearer to the mean axis than the aVR. So the mean axis is most likely around -40° .

In this example, we have determined the mean axis by first looking at the lead with the equiphasic QRS complex as described in **Figure 4** and later also reconfirm the degree of the mean axis by considering whether the QRS direction and amplitude in the leads in the *negative-half area* of the mean axis are in accord or not with it. As discussed above, the approximate determination of the axis with such method entails an error of $10\text{--}15^\circ$ [5]. Moreover, minor degrees of change in the height of QRS complex may also occur due to the difference in the relative voltage and magnitude of the bipolar and augmented unipolar leads [9] or due to cardiac or respiratory movement.

4.3. Other axes

When cardiac axis is referred, it usually indicates the mean frontal plane QRS axis. But there are also other axes to consider, for example, T wave and P wave axes. Though even axis of ST segment [2] and the QRS axis in the horizontal plane [1, 6, 9] are also discussed, such axes are not used in the routine ECG interpretation. The axes of T wave and P wave are also not routinely determined. However, in the computer interpretation in modern electrocardiogram tracings the axes of P and T waves are now easily available. Thus, routine consideration of T and P wave axes is possible and may be helpful. T wave axis is discussed later in Section 5.3. The normal mean manifest *frontal plane P wave axis is also directed generally within the region of $+40^\circ$ to $+60^\circ$ [2] with the normal limits between 0° and $+75^\circ$ [6]. The axis of P wave is affected by different conditions [2, 6], for example,*

- $+60^\circ$ to $+90^\circ$ or even more to right axis deviation in acquired right heart diseases including due to chronic obstructive pulmonary disease (COPD) with tall upright P wave in II, aVF, and III leads with near equiphasic or equiphasic P waves in lead I,
- $+45^\circ$ to -30° in left atrial diseases with upright in I and aVL leads, and
- -80° to -90° in the retrograde activation of the atria by an impulse from AV node or below with inverted P wave in II, aVF, and III leads.

4.4. Usefulness and limitations of the computer interpretations in modern electrocardiograms

The computer interpretations in modern electrocardiogram tracings help to note if anything is missed or to crosscheck the findings. But that does not decrease the responsibility of the physicians. In the textbook on electrocardiogram prepared on behalf of the council on clinical cardiology of the American Heart Association, it is emphasized: *“Even though computer interpretations of ECGs are readily available, the clinician’s role as overseer and final interpreter has not and must not be diminished”* [9]. On the other hand, one should also not totally ignore the computer interpretations. The computer interpretations are particularly useful for *rate, axes of QRS, P and T waves, intervals and amplitude, or voltage and duration of different waves*. Though in the computer interpretation the range of normal values is not given, the possible abnormal findings are indicated. The overall computer interpretation in the modern electrocardiogram machines, however, cannot incorporate the various clinical conditions to be considered in each individual patient. The rhythm, P, QRS, and T wave morphology, and ST segment need to be given particular attention by the clinicians and the conclusion should be drawn considering all the clinical conditions of the individual patient.

5. Effect of axis deviation on QRS-T morphology

5.1. Variations in the QRS pattern and usually negative waves in aVR

The QRS pattern in the extremity leads may vary considerably from one normal subject to another depending on the electrical axis of the QRS, which describes the mean orientation of the QRS vector with reference to the six frontal plane leads [16]. The effects on QRS and T morphologies by different frontal plane QRS axes may thus cause confusion in the interpretation of ECG. A shift, even a pronounced one, of the heart to the right due to pneumothorax or pleural effusion, however, does not necessarily affect the frontal plane QRS axis [17]. The effect of axis in the QRS and T morphologies can also be utilized for the efficient interpretation of electrocardiogram. The frontal plane QRS axis in most people are directed away from aVR, thus in the lead aVR the QRS complex is mostly negative. Marked left axis ($<-60^\circ$) or right axis ($>+120^\circ$) or extreme axis deviation will cause positive QRS complex in aVR. And the dominantly upright QRS as well as P waves in aVR along with the inverted ones in leads I and aVL indicate the presence of reversal of the left and right arm electrodes or rarely the dextrocardia, a common form of cardiac malposition [2, 18]. Thus, while interpreting any ECG it is helpful to look first at aVR to quickly detect the incorrectly placed arm electrodes or the marked left or right axis deviation.

5.2. An example of the effect on QRS complex due to left axis deviation

The ECG with the recordings of the limb leads shown in **Figure 5** is used as an example to discuss the effect of left axis deviation on the appearance of QRS complex. In the ECG shown in **Figure 5**, the QRS complexes in III and aVF appear mostly negative raising the possibility

of inferior wall ischemia. But this pattern in the asymptomatic person is most likely due to the frontal plane mean axis being at around -40° . The equiphasic points for this mean axis of -40° are at right angle, that is, at $+50^\circ$ and at -130° . The leads aVF and III are away from the equiphasic point at $+50^\circ$ toward the opposite pole of mean axis in the “negative-half area of the mean axis” (**Figure 3**) and are recording the increasingly negative QRS complex. Thus, the QRS complexes in III and aVF appear mostly negative. An ECG with right axis deviation is similarly likely to cause predominantly negative QRS complex in the leads I and aVL.

5.3. An example of the effect on T wave due to left axis deviation

Similarly the T waves in leads aVF and III in the ECG in **Figure 3** appear flat or inverted raising the possibility of inferior wall ischemia. However, as a rule the mean T wave axis and the mean QRS axis normally point in the same general (but not identical) direction [5]. Thus, in general when the main QRS deflection is positive (upright), the T wave is normally also positive [5] and vice versa. *In the adult, the QRS-T angle normally does not exceed 45° in the frontal plane [6]. When the angle is greater than 60° , the electrocardiogram is abnormal and disease is usually present [2].* In the ECG in **Figure 5**, the mean axis is directed at around -40° with the QRS complexes in III and aVF appearing more negative. In the asymptomatic person with this ECG, the mean frontal plane T wave axis is likely to be directed as the mean frontal plane QRS axis with the T wave appearing flat or inverted like the QRS complex. The T wave axis given in the computer interpretation in the modern electrocardiogram may provide additional information to correlate with the clinical condition of the patient.

5.4. The variations in the QRS-T pattern and its implications

The mean axis of the QRS complex causing the variations in the QRS-T pattern is just one of the many factors to do so. Minor degrees of or apparent ST segment or T wave changes can also occur due to many general medical or cardiac conditions other than the ischemic ones. Various such conditions related to each individual patient are not incorporated in the computer interpretation of the ECG tracing. The clinician has to correlate the ECG findings with the clinical conditions of the patient.

The US Preventive Services Task Force (USPTF) recommends against screening with resting or exercise ECG for the prediction of coronary heart disease events in asymptomatic adults at low risk for coronary heart disease events. The USPSTF concludes that the current evidence is insufficient to assess the balance of benefits and harms of screening with resting or exercise ECG for the prediction of coronary heart disease events in asymptomatic adults at intermediate or high risk for coronary heart disease events [19]. The overall risk for a serious adverse event, one that requires hospitalization or causes sudden death, with exercise ECG is estimated to be up to 1 in 10,000 tests [20].

Moreover, up to 71% of asymptomatic adults with abnormal exercise treadmill ECG results have no angiographically demonstrable coronary artery stenosis [21] and revascularization as such has also not been shown to reduce coronary heart disease events in asymptomatic persons [19]. And the risk for any serious adverse event from angiography is up to 1.7%, including risk for death (0.1%), myocardial infarction (0.05%), stroke (0.07%), or arrhythmia

(0.4%) [19, 22]. Such complications are more likely in the countries where the skills of angiography and angioplasty are not certified with appropriate criteria (considering *the learning curve* required for the particular skill) and in the situation where *the volume of the procedures* performed by the operator or in the institutions are not sufficient.

6. Causes of left axis deviation

The conditions which are likely to fulfill the criteria of the defined cut-off points and are conventionally considered as the causes of left axis deviation [1, 2, 4–8, 17] are shown in **Table 1**. An individual patient may have more than one medical condition; in such conditions, the resultant axis deviation may not reflect the typical pattern of one cause.

Axis deviation in conditions like right bundle branch block (RBBB) and left bundle branch block (LBBB) also depends on their underlying causes. LBBB is commonly a sign of organic heart disease [2] and most patients with LBBB have underlying left ventricular hypertrophy [5]. Thus, left axis deviation is usually seen in LBBB. Though LBBB is even emphasized to be always a sign of heart disease usually of the left ventricle [7], it is rarely seen in normal individuals without any organic heart disease [5]. Some other congenital heart diseases where left axis deviation is seen include

- tricuspid atresia,
 - single ventricle,
 - congenitally corrected transposition of the great arteries, and
 - double outlet right ventricle with infracristal ventricular septal defect [17].
-
- Left anterior fascicular block (left anterior hemiblock) (see **Table 2**)
 - Inferior wall myocardial infarction
 - Left ventricular hypertrophy due to various causes
 - Left bundle branch block (see text)
 - Ventricular tachycardia from a focus in the apex of the left ventricle
 - Pacing from the apex of the right or left ventricle
 - Primum atrial septal defect and endocardial cushion defect
 - Other congenital heart diseases (see text)
 - Wolff-Parkinson-White (WPW) syndrome: Less common type (previously called type B) affecting the right-sided accessory bypass pathways
 - Hyperkalemia
 - Emphysema and chronic obstructive pulmonary disease in about 10% (see text)
-

Table 1. Causes of left axis deviation.

In chronic obstructive pulmonary disease (COPD) with development of pulmonary hypertension, the frontal plane QRS axis shifts to the right side, even to $+150^\circ$ [2]. In very severe cases, extreme axis deviation may occur. Occasionally, in about 10% cases, there may be left axis deviation, the frontal plane QRS axis being directed upwards and to the left in the vicinity of -60° to -90° [2]. The exact mechanism is uncertain, but it is also supposed to be an *axis illusion* and the term *pseudo-left axis deviation* has also been applied [17]. In an individual patient with COPD, the presence of left axis deviation rather points out the need to look for other conditions, especially coronary heart disease, due to the common etiological factor of smoking shared by both diseases.

7. The leftward shift of axis

While enumerating the causes of axis deviation there may be confusion to

- whether the conditions mentioned are just likely to shift the axis toward one or other side of the usual normal axis between $+40^\circ$ and $+60^\circ$ (**Figure 2**) but within the conventionally considered limits or
- whether the conditions mentioned shift the axis frankly toward the right or left side fulfilling the defined limits of the axis deviations.

There are different physiological and pathological conditions which may shift the axis to one side or the other.

7.1. Effect of breathing

When a person breathes in, the diaphragm descends and the heart becomes more vertical and QRS electrical axis generally shifts toward right side, and when the person breathes out, the diaphragm ascends, heart assumes a more horizontal position, and the axis shifts toward the left side [5]. This may be more pronounced in maximum inspiration and expiration.

7.2. Body habitus and obesity

The mean frontal plane electrical axis also depends on body habitus [3]. The axes are more vertical in thin individuals and more horizontal in heavy individuals [6]. Obesity may deviate the frontal plane QRS axis toward the left side but not further to the left than 0° and a left axis deviation to -30° or further leftwards in an obese person probably represents a pathological abnormality [2, 23].

7.3. Pregnancy

A small rightward QRS axis shift may occur in the first trimester [24]. Similarly, some degree of leftward shift of QRS axis by about $15-30^\circ$ has been reported in the third trimester of pregnancy by different studies [24–26] and the axis shifting back to normal side after delivery [26].

However, in some cases of pregnancy, a slight rightward shift of QRS axis (within the normal range) may occur at full term [27]. It is emphasized that pregnancy is not associated with left axis deviation or any significant change of QRS axis [2]. Thus, in general some degree of leftward shift of QRS axis may occur in the third trimester of pregnancy. However, an isolated rightward QRS axis change may be encountered in normal pregnant patients and cannot be viewed as a definite abnormality or used as a sole criterion for heart disease [24].

7.4. The causes of left axis deviation

The conditions which are likely to fulfill the criteria of the defined cut-off points and are conventionally considered as the causes of left axis deviation [1, 2, 4–8, 17] (**Table 1**) may also not fulfill the defined criteria especially in the initial stages but they may shift the axis to one side from its usual range of the degrees between $+40^\circ$ and $+60^\circ$ (**Figure 2**). Most causes of left axis deviation (**Table 1**) are well-known clinical entities. Isolated left axis deviation and leftward shift of axis have been increasingly noticed by the author especially in relatively young adults with diabetes. There are many points to consider regarding leftward shift of axis and particularly the isolated left anterior fascicular block.

8. The isolated left anterior fascicular conduction delay

There are different causes of left axis deviation (**Table 1**). Left axis deviation may also occur in the absence of apparent cardiac disease and it is not necessarily a sign of significant underlying heart disease [5]. Left axis deviation is relatively common with advancing age even in the absence of clinically overt heart disease and rare during early adult years [17, 28–40]. In a population-based study of the people 20 years and above, almost half of the people with left axis deviation had isolated left axis deviation without evidence of heart diseases [28]. Left anterior fascicular block is the most common cause of left axis deviation [2]. The classical criteria of left anterior fascicular block are frontal plane axis between -45° and -90° , qR pattern in lead aVL, R peak time in lead aVL of 45 ms or more, and QRS duration less than 120 ms [3]. There are different causes of left anterior fascicular block or conduction delay [2, 5, 17, 27] (**Table 2**). In neuromuscular diseases like myotonia dystrophica, the involvement appears to be in the cardiac conduction system as a sort of nonmyopathic manifestations [17]. Hyperkalemia as well as a sudden increase in serum potassium levels are sometimes accompanied by left axis deviation ascribed to left anterior fascicular block due to changes in resting membrane potential and transmembrane potassium gradient; similar mechanism is held responsible for the generalized QRS widening with hyperkalemia [17].

The finding of isolated left anterior fascicular block is a very common, nonspecific abnormality [5]. The QRS axes which range from 0° to -30° probably reflect minor degrees of left anterior fascicular block or incomplete left anterior fascicular block [2]. An axis of $+29^\circ$ is also considered as already reflecting some degree of left axis deviation [2]. Complete block of conduction in the left anterior fascicle is not necessary to produce left axis deviation; presumably, all that is required

Clinical cardiac diseases	Other conditions
<ul style="list-style-type: none">• Coronary heart disease• Left ventricular hypertrophy• Chronic cardiac failure• Cardiomyopathies• Aortic valve diseases• Various congenital heart diseases• Cardiac surgery (especially aortic valve surgery)• Infiltrative diseases• Focal pathological lesions	<ul style="list-style-type: none">• Ageing• Atherosclerosis• Long-standing hypertension• Other secondary degenerative disorders of the conduction system• Primary sclerodegenerative disorders, for example, Lenegre disease or Lev disease• Congenital isolated left anterior fascicular block• Neuromuscular diseases like myotonia dystrophica, peroneal muscular atrophy, limb-girdle dystrophy• Rarely in hyperkalemia

Table 2. Causes of left anterior fascicular block or conduction delay.

is enough delay in anterior fascicular conduction to result in the activation of the anterior left ventricular solely via the posterior fascicle [17]. In fascicular block, left axis deviation can be interpreted as either delayed conduction or complete block in the left anterior fascicle [17], which may explain the leftward shift of axis from minor degrees to frank left axis deviation.

9. Vulnerability of left anterior fascicle

The left anterior fascicle is more vulnerable to interruption than the left posterior fascicle because of many reasons [2, 17] (**Table 3**). The left anterior fascicle is often supplied by septal branch of descending artery only or by septal branch of descending artery and atrioventricular node artery or rarely by atrioventricular node artery alone [17]. A total occlusion of the left anterior descending artery may cause a subsequent right bundle branch block with left anterior fascicular block [1]. This is one of the reasons for the frequent manifestation of right bundle branch block with left anterior fascicular block [2].

	Left anterior fascicle	Left posterior fascicle
Length and width	Relatively long and thin	Relatively short and thick
Blood supply	Mostly single blood supply (see text)	Dual blood supply
Proximity to aortic valve	Closer (so likely to be affected by aortic valve disease and surgery)*	Further away from aortic valve*

*Left anterior fascicle is situated superiorly and left posterior fascicle inferiorly.

Table 3. Reasons of left anterior fascicular being more vulnerable to interruption than the left posterior fascicle.

10. Isolated left anterior fascicular conduction delay due to atherosclerosis and degenerative conditions

The causes and clinical significance of left axis deviation have always been of interest since the early days of electrocardiography [17]. In regards to the causation of isolated left anterior fascicular delayed conduction or block, the possible mechanisms are fibrosis related to atherosclerosis and degenerative conditions [17]. The vulnerability of left anterior fascicle to interruption (**Table 3**) indicates the possibility of atherosclerosis with resultant coronary heart diseases. The possibility has, thus, been pointed out that left anterior fascicular block which occurs in the elderly may be due to subclinical coronary artery disease [2]. Ischemic heart disease in its own right causes fibrosis that partially or completely interrupts conduction in one or more fascicles [17]. On the other hand, fibrosis and degenerative disorder of the anterior fascicle of left bundle branch are postulated to be the cause of left axis deviation in the older population without associated cardiovascular abnormalities [17, 37–41]. The ECG trend of the gradual leftward migration of the frontal QRS axis has been concluded to be a common sequel of aging, independent of the population prevalence of coronary atherosclerosis. Thus, isolated, age-related degenerative disease is also considered to cause a variety of infranodal conduction defects that are unrelated to coexisting myocardial disease or coronary artery obstruction, which may be negligible or absent [17].

Interatrial conduction block by fibrosis: It is interesting to note here that the association between conduction delays and block in Bachmann's bundle (**Figure 5**) and atrial fibrillation has been reported [42]. The Bachmann's bundle is recognized as a muscular bundle and shares electrophysiological properties of both Purkinje and atrial fibers; it is not surrounded by a fibrous tissue sheath. Fibrosis of the interatrial tract or Bachmann's bundle has been suggested as the mechanism underlying interatrial conduction block. Areas of conduction block may not be confined to Bachmann's bundle alone [42]. The association of such changes with the left axis deviation and left anterior fascicular conduction delay deserves study.

11. Left axis deviation and glucose intolerance

In a study of almost the entire population aged 16 years and above in a town in 1959–1960 among people with left axis deviation, more than 25%, and among those less than 40 years of age, 36–40%, have hyperglycemia with blood glucose value above the 80th percentile for the age group [32]. Similarly, in another study of people with diabetes and control group, diabetic men have more leftward frontal QRS axis than their nondiabetic counterparts when the effect of confounding factors (age, obesity, coronary heart disease, hypertension, and drugs) was taken into account [43]. In a population study, among people with isolated left axis deviation almost half (47.4%) of the persons less than 40 years age have blood glucose in the upper quintile values in comparison to 20.7% of those more than 50 years [28]. In a study of asymptomatic people aged 30 years or more not on any medication attending

outdoor clinics for health checkup, the mean (SD) values of fasting plasma glucose are 101.0 ± 18.3 mg/dL in the slight left axis deviation group with QRS axis 0° to -30° (mean age 40.3 ± 8.5) and 122.9 ± 27.5 mg/dL in moderate-to-marked left axis deviation group with QRS axis -30° to -90° (mean age 54.5 ± 6.3). The frequency of glucose intolerance is 48.9% in the slight left axis deviation group with QRS axis 0° to -30° and 84.9% in moderate-to-marked left axis deviation group with QRS axis -30° to -90° , the difference being significant after conditioning the effects of age and sex ($P \leq 0.03$) and after conditioning the effect of BP ($P = 0.02$) [44, 45]. In a recent study with 85% of participants less than 55 years of age, left axis deviation was present in 8% of control group and 43.3% of type 2 diabetes [46]. The frequency of left axis deviation in the control nondiabetic group mostly below the age of 55 years in this report is also relatively high. The control group, though do not have diabetes, may have higher level of glucose or glycated hemoglobin (HbA1c) which could be related to the increasing glucose intolerance in the population now.

12. Why glucose intolerance as a cause of left anterior fascicular conduction delay was not much reported in earlier reports?

12.1. Difficulty in conducting fasting and 2-hour glucose estimation for diagnosis in the studies

In many reports of different findings in ECG of varied populations, plasma glucose estimation was mostly not done [29, 31, 33–40]. Conducting fasting and 2-hour glucose estimation in the field situation may not be easy as people have to come in the fasting state and wait for further 2 hours after taking glucose. Glycated hemoglobin (HbA1c) has been recently recommended for diagnosis of glucose intolerance.

12.2. A relatively new phenomenon

The epidemic of glucose intolerance in the world is relatively a new phenomenon starting since the latter half of twentieth century [47, 48]. It is now increasingly affecting the younger population [47]. The situation of the epidemic of diabetes could have led to observe and report the association of glucose intolerance and left axis deviation in relatively younger people more explicitly now [45, 46].

12.3. Data collection only as the normal axis or as the left axis deviation mostly with -30° to -90°

In most studies, including that of people with hyperglycemia or diabetes, only the presence of left axis deviation with QRS frontal plane axis -30° to -90° is considered [29–34, 36–39, 49], not the leftward shift of axis from its usual normal position (**Figure 2**), and thus the lower range of leftward shift is likely to be missed. The process of gradual shifting of the ECG axis toward left could be associated with the period of exposure to different grades and combination of

the related factors like increasing age, glucose level, and other factors. Focusing only on the left axis deviation criteria as -30° to -90° by the studies also appears as one reason of dearth of evidences about the association of different degrees of QRS axis with possible factors. The arbitrary limits of the axis deviations have already been discussed.

13. Left axis deviation in school children in indigenous population

High prevalence of left axis deviation, 6–9-fold higher than the control group, in healthy American-Indian Navajo and Apache school children has been reported, the possible cause of which was considered unexplained [50]. Mean frontal plane QRS axis between -1° and -90° was present in 19% of the Navajo and 12% of the Apache school children. The prevalence of the lesser degree of leftward shift of axis is also likely to be higher. Even the lesser degree of leftward shift of axis is also quite significant in children as compared to adults, as the normal QRS axis is more on the right in children. For example, in the neonate the normal frontal plane QRS axis is between $+60^\circ$ and $+190^\circ$, and the axis then shifts to the left and by ages 1–5 years, it is generally between $+10^\circ$ and $+110^\circ$. Between 5 and 8 years of age, the normal QRS axis may extend to $+140^\circ$, and between ages 8 and 16 years, the range of normal QRS extends to $+120^\circ$ [3]. The indigenous populations like the American-Indian are the ones who are affected the most since the middle of the twentieth century by the global diabetes epidemic [47, 48], and there is high prevalence of diabetes in the American-Indian indigenous population affecting even children [47, 51]. The high prevalence of leftward shift of axis in the children in such population is most likely related to the glucose intolerance which needs to be studied.

14. Brain white matter hyperintensities and left anterior fascicular block similarly related to glucose intolerance

White matter of the brain consists mostly of glial cells and myelinated axons for the transmission of neuronal electrical activity. With the wide availability of magnetic resonance imaging, there is often incidental discovery of white matter lesions appearing as hyperintensities on T2 weighted image [52, 53]. Pathological findings in the regions of white matter hyperintensities include myelin pallor, tissue rarefaction associated with loss of myelin and axons, and mild gliosis [52]. The factors associated with the brain white matter hyperintensities include ageing, hypertension, and diabetes [52, 53], as in the case of left anterior fascicular block. It may be relevant to note here that neuropathy, including the autonomic one, is a well-known common complication of diabetes and it may also be linked with, for example, as a later clinical manifestation of, white matter hyperintensities. A new study shows that even the impaired fasting glycemia, with the fasting plasma glucose below the diabetic range, is associated with a higher burden of brain white matter hyperintensities [54]. Among the people with isolated left axis deviation almost half of the persons less than 40 years of age have blood glucose in

the upper quintile values [28]. Left anterior fascicle is similarly involved in the *transmission of cardiac electrical activity* and its vulnerability to the interruption (**Table 3**) could make it likely to be susceptible to oxidative injury due to the accumulation of various metabolic products of hyperglycemia.

Hyperglycemia is associated with fibrodegeneration of the left anterior fascicle, brain white matter, and other tissues. Chronic hyperglycemia affects various growth factors including fibroblast, collagen, fibronectin, contractile proteins, and extracellular matrix proteins in the body through different mechanisms. The various possible mechanisms of hyperglycemia leading to complications include nonenzymatic glycosylation, polyol pathway, abnormal microvascular blood flow, thickening and leakage of basement membrane of blood vessels, formation of reactive oxygen species, formation of vascular endothelial growth factors, and overproduction of superoxide by the mitochondrial electron chain [11, 12, 55]. Ageing associated with the fibrodegeneration of various tissues also involves insulin signaling pathways, reactive oxygen species, and oxidative damage at number of sites [55]. The final pathways of mechanism of complications and fibrodegeneration of various tissues due to hyperglycemia and ageing appear similar. Ageing is a known risk factor of glucose intolerance. And looking at the similar final pathways of mechanisms of complications and fibrodegeneration of the tissues in hyperglycemia and ageing, there could also be reciprocal relation between the two conditions.

15. Future perspectives— from research and public health point of views

From the point of view of leftward shift of axis, correlation of various degrees of frontal plane QRS axis (not just the presence or absence of left axis deviation) with fasting and 2-hour glucose and/or glycated hemoglobin levels

- in the general population [45],
- in the children of the indigenous population where left axis is observed [50], and
- in the people with higher brain white matter hyperintensities [52–54] (along with magnetic resonance imaging of heart and/or nerve conduction studies and/or tests of autonomic neuropathy)

will help to provide further evidences and thus to correlate various factors with leftward shift of axis and glucose intolerance. The value of research lies in its utility. In the situation of pandemic of glucose intolerance also affecting the leftward shift of axis in younger population, to utilize the already available evidences especially of the risk of obesity or glucose intolerance in the offspring of mother with obesity or with undernutrition [56], the control programs to protect the susceptible populations need to be implemented [47] (**Table 4**). In the background of inherent insulin resistance during pregnancy and increasing age of mothers, maintenance of the optimum prepregnancy weight in the population appears to be the key in hand in the control program of diabetes epidemic [47]. This will also help to benefit the children of the indigenous population where the research on left axis deviation and diabetes has been conducted.

	Examples in the communicable disease	Possible examples in diabetes**
Prevention programs for individuals	<ul style="list-style-type: none"> • Immunization • Personal protective measures • Chemprophylaxis 	<ul style="list-style-type: none"> • Primary prevention programs • Campaign and programs to help achieve by the people the recommended body mass index of the respective populations
Control programs to protect the other susceptible populations*	<ul style="list-style-type: none"> • Isolation • Quarantine • Vector control (e.g., mosquito control for various diseases, cyclops control for guinea worm, chicken and poultry culling for avian influenza) • Treatment of case (e.g., tuberculosis) and carrier 	<p>Campaign and programs for</p> <ul style="list-style-type: none"> • Maintenance of optimal prepregnancy body weight, as per the recommended body mass index of the respective populations, especially in the affluent and/or urban parts of the societies and • Nutritional support for the girls and women of childbearing age in rural and poorer sections of the societies

*The vulnerable populations to be protected by the control program of diabetes include the offspring of malnourished or overweight mothers.

**National and international health and diabetes agencies should clearly spell out the control programs, with appropriate budget allocation, for control of diabetes epidemic to protect the progeny.

Table 4. Examples of prevention and control programs in the communicable diseases as a model for similar strategies for individuals and susceptible populations in diabetes epidemic.

16. Conclusion

The frontal plane QRS axis and especially the left axis deviation have always been the areas of interest in electrocardiogram. There are different physiological and pathological conditions which affect the axis and the axis shift itself also affects the QRS and ST morphologies. The approximate degree of axis can be easily determined by observing the electrocardiogram. Most causes of left axis deviation are well-known clinical entities. Isolated left axis deviation and leftward shift of the axis have increasingly been reported to be possibly associated with glucose intolerance. There are reasons why such association was previously not reported. The left anterior fascicle is as such vulnerable to interruption. The possible relation of glucose intolerance with brain white matter hyperintensities and even ageing also indicate the need to conduct research in these areas. However, the already available evidences should also be simultaneously utilized to protect the susceptible population. The bottom line of the frontal plane QRS axis is to record the actual degrees of the axes (not just the presence or absence of normal axis or left, right, or extreme axis deviations) and correlate the changes in the degrees of axis with the levels of the various possible factors in the individual patient or the study populations.

Author details

Madhur Dev Bhattarai

Address all correspondence to: mdb@ntc.net.np

Nepal Diabetes Association, Kathmandu, Nepal

References

- [1] Dubin D. Rapid Interpretation of EKGs. 6th ed. Tampa: Cover Publishing Co; 2000
- [2] Narasimhan C, Franchis J. Leo Shamroth—An Introduction to Electrocardiography. 8th ed. New Delhi: Wiley; 2013
- [3] Surawicz B, Childers R, Deal BM, Gettes LS. AHA/ACCF/HRS recommendations for the standardization and interpretation of the electrocardiogram Part III: Intraventricular conduction disturbances. *Circulation*. 2009;**119**:e235-e240
- [4] Prutkin JM. Basic principles of ECG analysis. UpToDate. 2017, Feb
- [5] Goldberger Z, Shvilkin A, Goldberger AL. Goldberger's Clinical Electrocardiography—A Simplified Approach. 8th ed. Philadelphia: Elsevier/Saunders; 2013
- [6] Wegner GS, Strauss DG. Marriott's Practical Electrocardiography. 12th ed. New Delhi: Wolters Kluwer Health/Lippincott Williams and Wilkins; 2014
- [7] Hampton JR. The ECG Made Easy. 8th ed. Edinburg: Elsevier/Churchill Livingstone; 2013
- [8] Goldman MJ. Principles of Clinical Electrocardiography. 11th ed. California: Lange Medical Publications/Maruzen Asia; 1982
- [9] Akhtar M (Prepared on behalf of the Council on Clinical Cardiology of the American Heart Association). Examination of the Heart—The Electrocardiogram. Dallas: American Heart Association; 1990
- [10] Blackburn H, Keys A, Simonson E, Rautharju P, Punsar S. The electrocardiographic in population studies—A classification system. *Circulation*. 1960;**21**:1160-1175
- [11] Kumar, Clark. Kumar and Clark's Clinical Medicine. 9th ed. Edinburgh: Elsevier; 2017. pp. 944-947, 1264-1273
- [12] Waugh A, Grant A. Ross and Wilson's Anatomy and Physiology in Health and Illness. 11th ed. Edinburgh: Churchill Livingstone/Elsevier; 2010. pp. 80-83
- [13] Sauer WH. Left anterior fascicular block. UpToDate. 2017
- [14] Pryour, Weaver, Blount. Electrocardiographic observations of 493 residents living at high altitude (10,150 feet). *American Journal of Cardiology*. 1965;**16**(4):494-499

- [15] Raynaud, Valeix, Drouet, Escourrou, Durand. Electrocardiographic observations in high altitude residents of Nepal and Bolivia. *International Journal of Biometerology*. 1981;**25**(3):205-217
- [16] Kasper DL, Fauchi AS, Hauser SL, Longo DL, Jameson JL, Loscalzo J. *Harrisons' Principles of Internal Medicine*. 19th ed. New York: McGraw Hill Education; 2015. pp. 1450-1459, 1481, 2423-2430
- [17] Perloff JK, Roberts NK, Cabeen WR. Left axis deviation: A reassessment. *Circulation*. 1979;**60**(1):12-21
- [18] Eldridge J, Richley D, Egglett C. *Clinical Guidelines by Consensus: Recording a Standard 12-lead Electrocardiogram*. London: Society for Cardiological Science and Technology; 2017
- [19] Mayer VA (on behalf of the US Preventive Services Task Force). Screening for coronary heart disease with electrocardiography: U.S. Preventive Services Task Force Recommendation Statement. *Annals of Internal Medicine*. 2012;**157**:7
- [20] Myers J, Arena R, Franklin B, Pina I, Kraus WE, McInnis K, et al. American Heart Association Committee on Exercise, Cardiac Rehabilitation, and Prevention of the Council on Clinical Cardiology, the Council on Nutrition, Physical Activity, and Metabolism, and the Council on Cardiovascular Nursing. Recommendations for clinical exercise laboratories: A scientific statement from the American Heart Association. *Circulation*. 2009;**119**:3144-3161. [PMID: 19487589]
- [21] Hopkirk JA, Leader S, Uhl GS, Hickman Jr JR, Fischer J. Limitation of exercise-induced R wave amplitude changes in detecting coronary artery disease in asymptomatic men. *Journal of the American College of Cardiology*. 1984;**3**:821-826. [PMID: 6693653]
- [22] Noto Jr TJ, Johnson LW, Krone R, Weaver WF, Clark DA, Kramer Jr JR, et al. Cardiac catheterization 1990: A report of the Registry of the Society for Cardiac Angiography and Interventions (SCA&I). *Catheterization and Cardiovascular Diagnosis*. 1991;**24**:75-83. [PMID: 1742788]
- [23] Zack PM, Wiens RD, Kennedy HL. Left axis deviation and adiposity: The US Health and Nutrition Examination Survey. *The American Journal of Cardiology*. 1984;**53**:1129
- [24] Wegner NK. The ECG in normal pregnancy. *Archives of Internal Medicine*. 1982;**142**:1088
- [25] Madras V, Challa N. Electrocardiographic variations during three trimesters of normal pregnancy. *International Journal of Research in Medical Sciences*. 2015;**3**(9):2218-2222
- [26] Goloba M, Nelson S, Macfarlane. The electrocardiogram in pregnancy. *Computing in Cardiology*. 2010;**37**:693-696
- [27] Schwartz DB, Schamroth L. The effect of pregnancy on the frontal plane QRS axis. *Journal of Electrocardiology*. 1979;**12**:1129
- [28] Ostrander LD. Left axis deviation: Prevalence, associated conditions, and prognosis: An epidemiological study. *Annals of Internal Medicine*. 1971;**75**(1):23-28

- [29] Kitchin AH, Lowther CP, Milne JS. Prevalence of clinical and electrocardiographic evidence of ischaemic heart disease in the older population. *British Heart Journal*. 1973;**35**(9):946-953
- [30] de Bacquer D, de Baker G, Kornitzer M. Prevalences of ECG findings in large population based samples of men and women. *Heart*. 2000;**84**(6):625-633
- [31] Lakkireddy DR, Clark RA, Mohiuddin SM. Electrocardiographic findings in patients >100 years of age without clinical evidence of cardiac disease. *The American Journal of Cardiology*. 2003;**92**(10):1249-1251
- [32] Ostrander LD, Brandt RL, Kjelsberg MO, Epstein FH. Electrocardiographic findings among the adult population of a natural community, Tecumseh, Michigan. *Circulation*. 1965;**31**:888-898
- [33] Hingorani P, Natekar M, Deshmukh S, Karnad DR, Kothari S, Narula D, Lokhandwala Y. Morphological abnormalities in baseline ECGs in healthy normal volunteers participating in phase I studies. *The Indian Journal of Medical Research*. 2012;**135**:322-330
- [34] Hiss RG, Lamb LE. Electrocardiographic findings in 122,043 individuals. *Circulation*. 1962;**25**:947-961
- [35] Mason JW, Ramseth DJ, Chanter DO, Moon TE, Goodman DB, Mendzelevski B. Electrocardiographic reference ranges derived from 79,743 ambulatory subjects. *Journal of Electrocardiology*. 2007;**40**(3):228-234
- [36] Bahl OP, Walsh TJ, Massie E. Left axis deviation: An electrocardiographic study with post-mortem correlation. *British Heart Journal*. 1969;**31**(4):451-456
- [37] Grayzel J, Neyshaboori M, Paramw NJ. Left-axis deviation: Etiologic factors in one-hundred patients. *American Heart Journal*. 1975;**89**(4):419-427
- [38] Corne RA, Beasmish RE, Rollwagen RL. Significance of left anterior hemiblock. *British Heart Journal*. 1978;**40**(5):552-557
- [39] Grant RP. Left axis deviation: An electrocardiographic-pathological correlation study. *Circulation*. 1956;**14**(2):233-249
- [40] Das G. Left axis deviation—A spectrum of intraventricular conduction block. *Circulation*. 1976;**53**(6):917-919
- [41] Bradlow BA. The importance of abnormal left axis deviation in life assurance. *South African Medical Journal*. 1973;**47**(20):877-881
- [42] van Campenhout MJH, Yaksh A, Kik C, de Jaegere PP, Yen S, Allessie MA, de Groot NMS. Bachmann's Bundle—A key player in the development of atrial fibrillation. *Circulation Arrhythmia and Electrophysiology*. 2013;**6**:1041-1046
- [43] Uusitupa M, Mustonen J, Siitonen O, Pyorala K. Quantitative electrocardiographic and vectorcardiographic study on newly-diagnosed non-insulin-dependent diabetic and non-diabetic control subjects. *Cardiology*. 1988;**75**(1):1-9

- [44] Paudyal A (under the guidance of Bhattarai MD). Correlation of normal QRS duration left axis deviation in ECG with clinical and investigation parameters in patients without cardiac symptoms [thesis for MD in Internal Medicine]. Kathmandu: National Academy of Medical Sciences; 2008
- [45] Paudyal A, Bhattarai MD, Karki BB, Bajracharya MR, Rajouria AD, Pradhan A. Left axis deviation in electrocardiogram with normal QRS duration in ambulatory adults without cardiac symptoms: A possible marker of glucose intolerance. *Journal of Nepal Medical Association*. 2013;**52**(192):557-562. PMID: 25327226
- [46] Helaihil AF, Hatim I, Abed AH. Isolated left axis deviation in diabetic patients. *Journal of Pharmacy*. 2015;**5**(3):36-45
- [47] Bhattarai MD. Three patterns of rising type 2 diabetes prevalence in the world: need to widen the concept of prevention in individuals into control in the community. *Journal of Nepal Medical Association*. 2009;**48**(174):173-179. PMID: 20387365
- [48] Bhattarai MD. Response to Donovan et al. Does exposure to hyperglycaemia in utero increase the risk of obesity and diabetes in the offspring. *Diabetic Medicine*. 2016;**33**:5. dme.12980. PMID:26435160
- [49] Pfister R, Cairns R, Erdmann E, Schneider CA (on behalf of the PROactive investigators). Prognostic impact of electrocardiographic signs in patients with type 2 diabetes and cardiovascular diseases: Results from the PROactive study. *Diabetic Medicine*. 2011;**28**(10):1206-1212
- [50] Ewy GA, Okada RD, Marcus FI, Goldberg SJ, Phibbs BP. Electrocardiographic axis deviation in Navajo and Apache Indians. *Chest*. 1979;**75**(1):54-58
- [51] Gohdes D, Kaufman S, Valway S. Diabetes in American Indians: An overview. *Diabetes Care*. 1993;**16**(1):239-243
- [52] Debette S, Markus HS. The clinical importance of white matter hyperintensities on brain magnetic resonance imaging: Systemic review and meta-analysis. *British Medical Journal*. 2010;**341**:c3666. PMID: 20660506
- [53] Murray AD, Staff RT, Shenkin SD, Deary IJ, Starr JM, Whalley LJ. Brain white matter hyperintensities: Relative importance of vascular risk factors in nondemented elderly people. *Radiology*. 2005;**237**(1):251-257. PMID: 16126931
- [54] White Matter Lesions Linked to Rising Plasma Glucose. *Medscape*. Atlanta: WebMD; Nov 24, 2015
- [55] Walker BR, Colledge NR, Ralston SH, Penman ID. *Davidson's Principles and Practice of Medicine*. 22nd ed. Edinburgh: Elsevier/Churchill Livingstone; 2014. pp. 168-170, 532-534
- [56] Ozanne SE, Constancia M. Mechanisms of disease: The developmental origin of disease and the role of the epigenotype. *Nature Clinical Practice Endocrinology & Metabolism*; 2007;**3**:539-546

