

We are IntechOpen, the world's leading publisher of Open Access books Built by scientists, for scientists

6,900

Open access books available

185,000

International authors and editors

200M

Downloads

Our authors are among the

154

Countries delivered to

TOP 1%

most cited scientists

12.2%

Contributors from top 500 universities



WEB OF SCIENCE™

Selection of our books indexed in the Book Citation Index
in Web of Science™ Core Collection (BKCI)

Interested in publishing with us?
Contact book.department@intechopen.com

Numbers displayed above are based on latest data collected.
For more information visit www.intechopen.com



Biliary Complications of Hepatic Hydatid Cyst Surgery and Prevention Methods

Can Konca and Deniz Balci

Additional information is available at the end of the chapter

<http://dx.doi.org/10.5772/intechopen.69031>

Abstract

Cystic echinococcosis is still one of the main reasons for liver surgery especially in endemic areas. The most common complication of liver hydatid cyst is cystobiliary communication (CBC). Preoperative or intraoperative diagnosis of CBC is essential for the treatment, since it leads to postoperative bile leakage and fistula formation eventually without intervention. Predictive factors such as cyst size, history of jaundice, and degenerated cysts are described for preoperative evaluation. Further preoperative study can be performed for diagnosis in their presence. At the intraoperative phase, every effort should be performed for diagnosis. There are several methods for the investigation of CBC. When a CBC is found, it is also essential to evaluate the biliary system as well. By this way, postoperative complication rates can be lowered. Biliary leakage and fistula formation are the most common postoperative complication of liver hydatid surgery and they are the main reasons of morbidity and mortality. Their rates can be lowered by knowing how to interfere for the treatment. As a result, every effort should be made to detect and prevent these complications during the evaluation and management of cystic echinococcosis.

Keywords: hydatid cyst, hydatid surgery, bile leakage, bile fistula, biliary complication, prevention, echinococcus

1. Introduction

Cystic echinococcosis (CE) affects liver in approximately 70% of the cases and is still one of the main indications for liver surgery in endemic areas [1]. Reported CE-related mortality rates are between 0.5 and 4%, majority of which are mainly a consequence of the complications [1, 2].

In the past decades, surgery was the only treatment method for hepatic hydatid cysts [3]. With the advancements in medical and percutaneous therapy techniques, surgery is reserved mainly for the complicated hydatid cysts and cysts classified as CE2 or CE3B according to the World Health Organization Informal Working Group on Echinococcosis (WHO-IWGE) classification [1–4].

There are two modalities for surgery: radical and conservative approaches. Pericystectomy (**Figure 1**) and hepatectomy are examples for radical surgery, which aim a complete excision of the cyst and the pericyst [5]. They have lower complication (0–26%) and recurrence (0–3%) rates than the conservative methods [1, 6], but their usage is limited by the anatomic localization and multiplicity of the cysts, since especially in centrally located or bilobular disease, the extent of the surgery exceeds the purpose of the treatment of a benign disease. Also, hepatobiliary surgical expertise and longer operation time are needed for radical surgery, which can be a limitation in endemic regions. By contrast, conservative approaches such as partial pericystectomy (also known as unroofing) with drainage or omentoplasty (**Figure 2**) require less experience and shorter duration of operation. However, their complication and recurrence rates are higher [5]. Simply, they aim to remove the germinal and laminar membrane along with the cystic content and excise the pericystic membrane as much as possible without parenchymal dissection [5]. They have morbidity rates between 6 and 47% and recurrence rates between 4 and 25% [6].

Postoperative bile leakage and fistula formation are a result of cystobiliary communication (CBC) due to intrabiliary rupture (IBR) of the cyst, and this is most common complication of liver surgery for hydatid cyst [7]. Incidence of postoperative bile leakage is between 2.5 and 28.6%. When the postoperative bile leakage is drained externally and persists for more than 10 days, this is called biliary fistula. It is the major cause of morbidity and is encountered in 1–25% of the cases [6, 8]. In the absence of adequate internal or external drainage, bilioma, biliary abscesses, or biliary peritonitis may develop, which can lead to sepsis resulting in serious morbidity and even mortality. Postoperative biliary fistula is the major cause of prolonged hospitalization and complications requiring intervention after hydatid surgery. However, fistulas may close spontaneously in the first postoperative week. It can be classified as “low-flow fistula” if the daily drainage volume is less than 300 ml/day or “high-flow fistula” if more than 300 ml/day [8, 9]. If the fistula persists more than 3 weeks or is a high-flow fistula, then endoscopic or surgical intervention should be considered rather than a conservative approach [8, 10, 11].

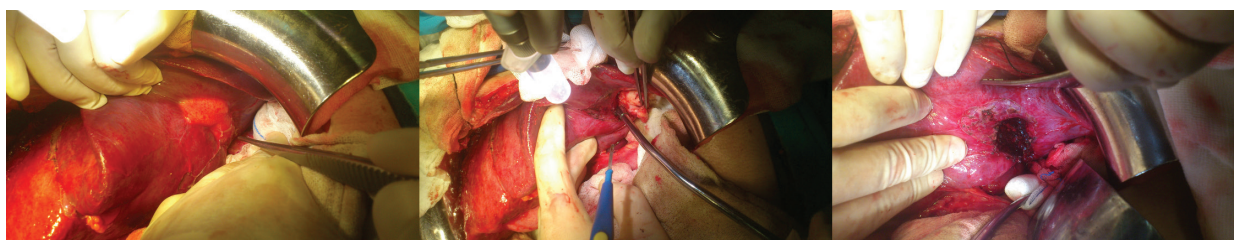


Figure 1. Pericystectomy procedure.

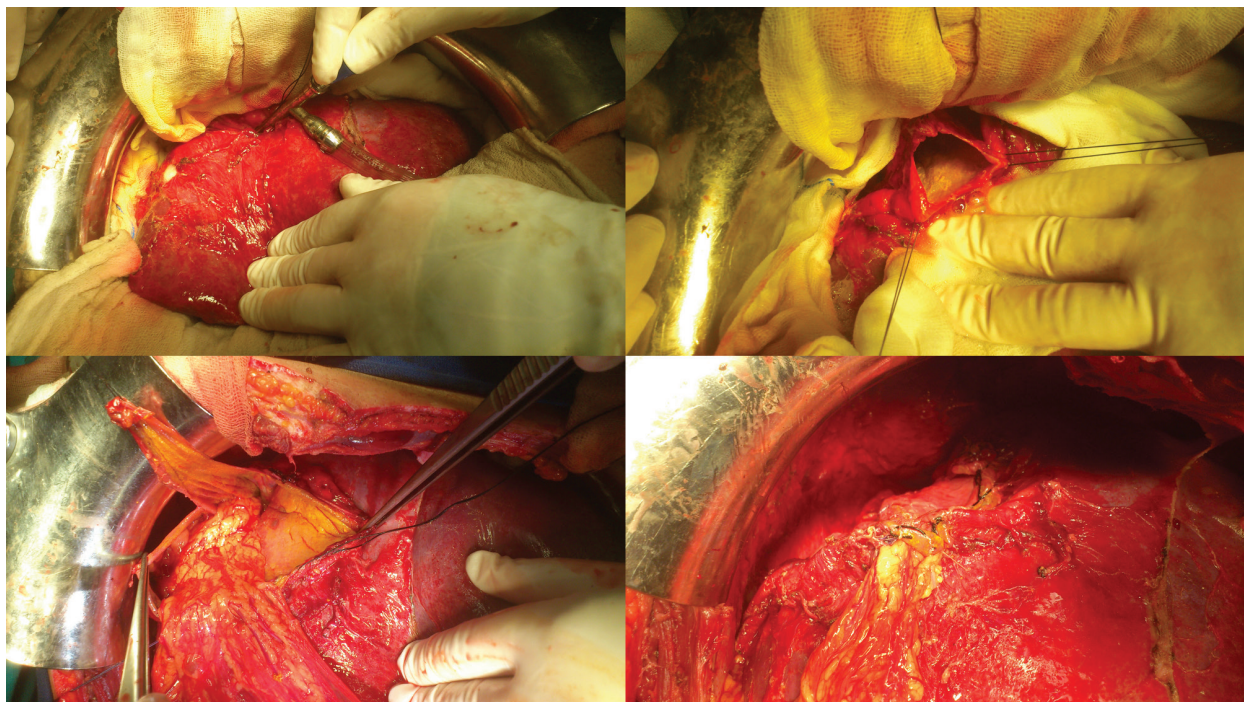


Figure 2. Partial pericystectomy with omentoplasty.

The most common complication of CE is a cystobiliary communication occurring in about 60% of the complicated patients [7]. Two theories have been proposed for pathogenesis: the first is progressive necrosis developing on the wall of biliary duct due to the compression of the hydatid cyst. Such necrosis may lead to a communication between the cyst and the biliary system. The second one suggests that small biliary radicals, which are trapped in the pericystic membrane, become atrophic due to the cystic pressure and rupture eventually [11]. Even though some studies stated communication rates up to 90% during the cysts evolution, the reported incidence of clinical CBC is only 13–37% [8, 11].

There are two types of CBC, **frank** (major, ≥ 5 mm) and **occult** (minor, < 5 mm) CBC [6]. Frank CBC is a wide communication between the cyst and the biliary system. Since intracystic pressure is higher than the biliary pressure, frank CBC allows the cystic contents such as daughter cysts or membrane fragments to enter the biliary system and leads to clinical symptoms like **obstructive jaundice, cholangitis, cyst infection, or anaphylaxis**. Its incidence varies between 3 and 17% in liver hydatid cyst patients [6, 11]. If frank CBC is wider than 5 mm, cystic contents can be seen in the bile ducts during the preoperative evaluation in up to 65% of the patients [11]. Therefore, frank CBC can be diagnosed preoperatively, and treatment can be planned accordingly. By contrast, occult CBC is a smaller communication between the cyst and the biliary radicals. Its incidence varies between 10 and 37% of the patients with liver hydatid cyst [6, 12]. It is usually asymptomatic at the preoperative period, and thus, it is difficult to diagnose. So, careful intraoperative evaluation and postoperative follow-up are needed to overcome the consequences of this morbidity. It is reported that lower postoperative morbidity and bile leakage rates are achieved when the diagnosis is made in the pre- or intraoperative periods [11, 13].

2. Preoperative evaluation

Preoperative evaluation for CBC is essential for liver hydatid surgery, since diagnosis directly affects the treatment plan and the surgical outcome. Diagnosing a frank CBC is easy when a patient presents with symptoms of cholangitis and obstructive jaundice. However, occult CBC is usually asymptomatic and clinical suspicion is essential for its diagnosis. There are few studies investigating the predictive factors for CBC. While Akcan et al. reported that older age, larger cysts, and presence of multiple and bilobar cysts are associated with increased intrabiliary rupture rates, El Nakeeb et al. suggested that only the cyst size (>10 cm) is a significant predictor for CBC, regardless of the type [10, 14]. Because clinical presentation differs between frank and occult CBC, preoperative evaluation will be discussed separately.

2.1. Frank CBC evaluation

Frank CBC can be diagnosed preoperatively. In an unruptured cyst, the intracystic pressure is between 30 and 80 cm H₂O, while the normal intrabiliary pressure is 15 and 20 cm H₂O. When a frank CBC develops, intracystic materials like daughter cysts and membrane fragments, along with the hydatid fluid, enter the biliary ducts as a consequence of the pressure gradient toward the biliary system [8]. Hydatid material in the bile ducts leads to clinical symptoms. Obstructive jaundice can be seen in 57–100% and cholangitis in 20–37% of the patients. Without treatment, both may lead to sepsis and death, with mortality rates as high as 50% [12]. Acute pancreatitis, acute cholecystitis, and, as a late complication, biliary cirrhosis have also been reported [15–17].

In 30–74% of the cases, diagnosis can be made by ultrasonography (US) [11]. Irregular linear echogenic structures without acoustic shadowing in bile duct and a dilated biliary system are ultrasonographic findings in cases with intrabiliary-ruptured frank CBC [6]. The sensitivity of computed tomography (CT) for the diagnosis of frank CBC is 75% [11]. Hydatid materials in the bile ducts or a cystic wall defect due to a frank CBC can be seen via CT. In 75% of the cases, cyst wall discontinuity can be seen as a direct sign of CBC [18]. Magnetic resonance cholangiopancreatography (MRCP) is another alternative and more effective method for the preoperative diagnosis of the suspected cases [18]. For frank CBC diagnosis, MRCP has 92% sensitivity and 83% specificity [11].

There are some clinical predictors described for the presence of frank CBC (Table 1) [12]. In our review of 301 cases, our analysis also showed that a high preoperative alkaline phosphatase (ALP), history of cholangitis, and a larger cyst diameter (>10 cm) were significantly more common in patients who developed postoperative biliary fistula (PBF) [19].

History of jaundice
Central location of large cysts >10 cm
Presence of suggestive USG findings
Type IV (Gharbi classification) or CE4 (WHO-IWGE Classification) cyst on USG

Table 1. Clinical predictors of frank CBC.

In cases of clinical suspicion and presence of predictive factors, further studies can be planned such as MRCP or endoscopic retrograde cholangiopancreatography (ERCP). Because MRCP is a noninvasive test, it can be used as a primary method for the diagnosis. After confirmation of CBC diagnosis, ERCP can also be used for treatment [20].

ERCP can be used for both diagnostic and therapeutic purposes. It has 86–100% diagnostic sensitivity for frank CBC. It serves for (i) the treatment of acute conditions to defer for elective surgery, (ii) decreasing the postoperative complication rates and achieving shorter postoperative hospitalization time, and (iii) evacuation of biliary and cystic hydatid contents [20]. ERCP with endoscopic sphincterotomy (ES) is the first line of treatment for patients presenting with jaundice or findings of IBR [11]. In case of documented CBC, it helps with planning the elective surgery and prevention of intraoperative common bile duct exploration during the operation [10–12]. Additionally, lower postoperative biliary fistula rates were reported with preoperative ERCP with ES [11]. Performing ERCP with ES prior to surgery decreases the risk from 11.1 to 7.6% for postoperative biliary fistula [21]. It was also reported that 25% of the patients with frank CBC have been cured with ERCP without the need for further surgery [20]. In addition to ES, extraction with balloon or basket catheter, nasobiliary drainage, and biliary stenting can be used as therapeutic tools during ERCP [20].

2.2. Occult CBC evaluation

Occult CBC is hard to diagnose preoperatively since a small communication usually cannot be seen on radiologic studies [12, 22, 23]. Most of the cases are asymptomatic until surgery or postoperative period when it presents as bile leakage and fistula. The flow gradient of contents is toward the biliary system in an unruptured cyst. As a result, small biliary radicals are compressed with the pressure and remain silent until the gradient is reversed. The median intracystic pressure is around 25 mm Hg (range, 5–55 mm Hg) and there is a positive correlation between cyst size and pressure in viable cysts. Manometric studies indicate that the sphincter of Oddi pressure (basal 10 mmHg, peak 124 mmHg) is higher than the normal common bile duct pressure (10 mmHg). According to the LaPlace Law, the expansion of the cyst due to increased intracystic pressure results in an increased cyst diameter, which causes increased tension on the cyst wall containing the neighboring bile ducts. The pressure dynamics arising from higher intracystic pressures than the resting bile duct pressure may explain how the cyst communicates with the biliary system as the pericyst becomes thinner and thinner, eventually eroding into the bile ducts and leading to the development of an IBR [19]. During an operation with conservative approach, bile staining of the cystic content during first aspiration cannot be seen in most cases. Once the gradient is reversed with aspiration and evacuation of the cystic content, bile leakage begins [8]. So, the principal evaluation of occult CBC must be undertaken during surgery. Even with an attempt to control a detected BF intraoperatively, there might be a significant failure rate if that was used as the only method to control the cyst-biliary communication [19].

However, there are some clinical predictors described for the presence of occult CBC (**Table 2**) [8, 12]. Taking these predictors into consideration, a clinical suspicion can further lead to evaluation for an occult CBC. However, unlike frank CBC, diagnostic sensitivity of MRCP and ERCP is low [12]. In cases with high suspicion, preoperative ERCP with ES can be done

to decrease the postoperative leakage rate and to determine the biliary anatomy [20]. Yet, this is not a standard therapeutic modality.

A diagnostic and therapeutic algorithm for preoperative evaluation of CBC can be seen in **Figure 3**.

History of nausea and vomiting	
ALP level >144 U/L	
gamma-glutamyltransferase (GGT) level >34.5 U/L	
Total bilirubin level >0.8 mg/dL	
Direct bilirubin level >0.4 mg/dL	
Eosinophil rate >0.09	
Cyst diameter >8.5 cm	
Multilocular cysts (Gharbi type III)	
Degenerate cysts (Gharbi type IV or WHO-IWGE CE4)	
*The data in this table are derived from different studies having common and uncommon predictive parameters and among similar parameters, ones with the lowest cut-offs were selected to aim for the widest patient range [8, 12].	

Table 2. Clinical predictors of occult CBC*.

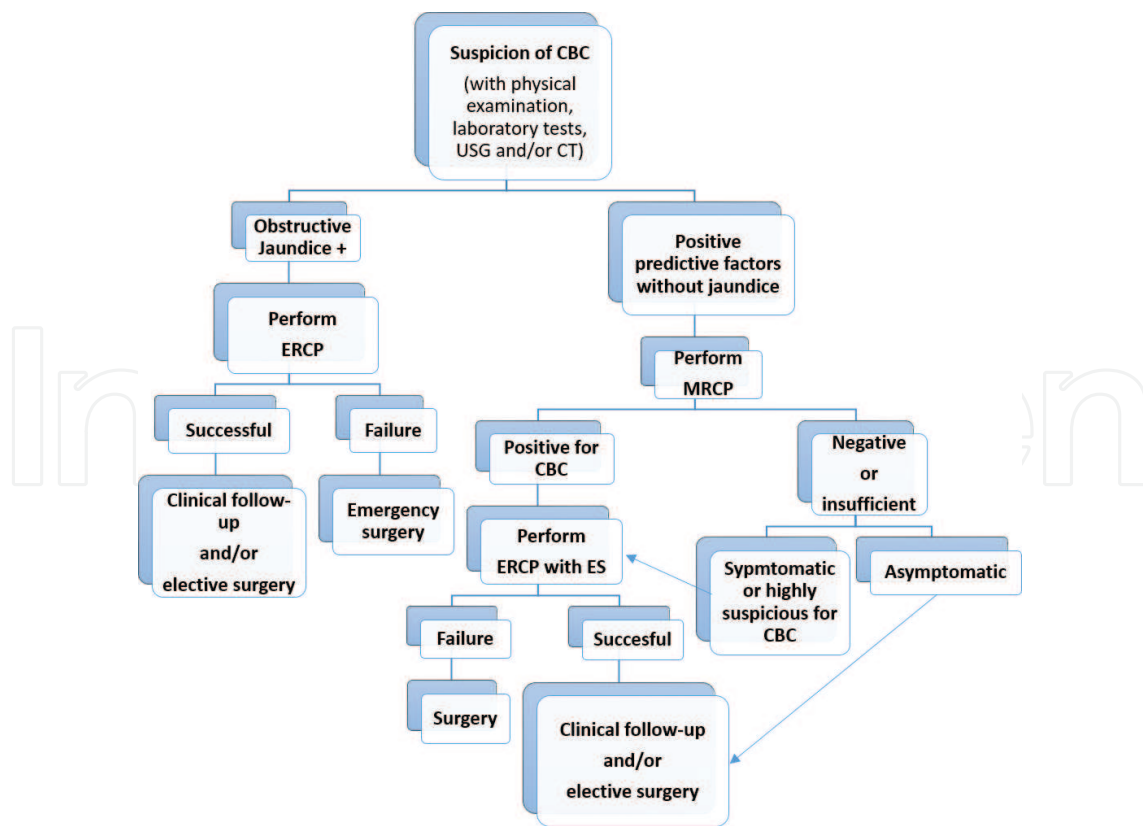


Figure 3. Diagnostic and therapeutic algorithm for preoperative evaluation of CBC.

3. Operative decision making

Radical surgical techniques should be undertaken whenever feasible because of their lower postoperative morbidity and recurrence rates [5, 8, 11]. In the last decade, major liver surgery became much more safer with very low morbidity and mortality rates. The decision making is usually complex with various factors interplaying different roles. Patient-related factors with general condition and comorbidities, liver parenchymal quality (steatosis, age, diabetes, etc.), and center expertise are leading factors. On the other hand, these factors, taken together, may pose a higher risk for a benign disease unless complicated [11]. As a result, conservative approaches are still the most common method applied, especially in the endemic regions [8]. Among all the conservative methods, partial cystectomy with omentoplasty has the lowest reported postoperative leakage rate [1, 24]. In our center, we favor anatomical liver resections whenever feasible, especially in patients with frank CBC.

4. Intraoperative evaluation

Frank CBC is usually easy to diagnose intraoperatively. The communication should be sutured whenever feasible. If it is diagnosed with MRCP or ERCP preoperatively, it is essential to understand the type and anatomical location of the communication of the duct with the cyst. If the frank communication is related with the primary or secondary biliary pedicles, suture closure of the communication could lead to biliary obstruction for distal branches [12]. In such cases, conversion to radical surgery, biliary drainage procedures like t-tube drainage or choledochoduodenostomy or postoperative ERCP and ES with or without biliary stenting/nasobiliary drainage should be considered [11]. In patients with frank CBC without preoperative evaluation, cholangiography or choledochoscopy can be performed before and after the evacuation of hydatid material in bile ducts. After that, placing a t-tube and closure over t-tube or decompression through cystic duct can be preferred [8, 11]. It is reported that when a communication is wider than 5 mm, hydatid material in biliary system can be seen in 65% of the cases [25]. For that reason, an intraoperative cholangiography via the communication, cystic duct, or common bile duct can be done in patients without preoperative ERCP [12].

Careful evaluation should be done to diagnose occult CBC. At the first aspiration of the hydatid cyst fluid, bile staining should be checked. If the fluid is positive for bile, a surgeon should avoid using scolical agents to prevent sclerosing cholangitis [2, 6, 11]. After evacuation of the hydatid material in the cyst cavity, careful inspection for bile leakage should be done inside the cavity. Using a coloring scolical agent like povidone iodine can be a handicap for this purpose [8]. On the other hand, using a non-coloring scolical agent like hypertonic saline or chlorhexidine may increase diagnostic accuracy. If a communication is found, it should be sutured [11].

Surgical telescopes with $2.5 \times$ or $3.5 \times$ magnification can enhance the quality of inspection. In cases of negative inspection for bile leakage, there are several methods for additional evaluation. The simplest method is filling the cavity with gauze [8]. In addition, manual clamping of the main bile duct can provoke bile staining through the communication by increasing

intrabiliary pressure. When discovered, occult CBCs should also be sutured. Another method described especially for large and multilobar cysts, which can be at difficult locations for inspection, is using a videotelescope [26]. The rotation and magnification abilities of the videotelescope facilitate a more precise diagnosis, especially in multilobar and deep localized cavities. Endoscopic instruments can also be used for suturation of unreachable communications [26].

When bile staining is present but the communication cannot be localized, there are two options: external drainage from cavity can be performed and postoperative ERCP with ES can be scheduled or, as a more invasive option, methylene blue or air injection with or without intraoperative cholangiography can be performed [11, 12]. In such cases, cholangiography can be performed via cystic duct or main bile duct [12]. A cholecystectomy is needed to perform a transcystic cholangiography. If the patient has cholelithiasis or the gallbladder wall constitutes the cyst wall, then transcystic approach should be preferred. Otherwise, cholangiography through the main duct with a thin-needled syringe—like insulin syringe—should be done. Separately, or in addition to cholangiography, methylene blue or air injection through cholangiography access should be done for detecting the localization of the communication [11, 12, 27]. With methylene blue injection, covering of the cavity with gauze technique can be used for localization. If air injection is preferred, filling the cavity with saline should be done. Next, air bubbles in the cavity must be checked for the presence of a communication.

If a frank or occult CBC has been detected intraoperatively and the patient has not been evaluated preoperatively with MRCP or ERCP, cholangiography should be performed for the presence of hydatid material in the biliary system. In cases with hydatid material, choledochotomy should be done and after evacuation of the hydatid material, t-tube drainage should be performed for further access and evaluation. In cases of biliary stricture, choledochoduodenostomy may be preferred. Intraoperative ERCP can be a less invasive approach in available centers [14, 20].

In all cases that underwent conservative hydatid liver surgery, continuous suturation of pericystectomy line can be used to eliminate the risk of leakage from biliary radicals at pericystic wall and an external drainage catheter should be placed at the entrance or in the cavity to avoid the risk of uncontrolled postoperative biliary leakage and biliary peritonitis.

In some series, fibrin sealant usage to prevent postoperative biliary leakage is used, but controversial results have been reported. Therefore, efficacy of fibrin sealant is still questionable [5, 9].

5. Postoperative evaluation

A close follow-up should be done at the postoperative period for complications. In acute conditions, necessary interventions should be planned promptly. Emergency laparotomy is indicated if the patient has biliary peritonitis. Peritoneal irrigation, correction of leakage by suturation or more radical methods as needed and maintaining an adequate external drainage

should be performed accordingly. If bile leakage persists after the operation, ERCP with ES and biliary stenting should be considered [20].

In cases of postoperative jaundice, first therapeutic modality should be ERCP with ES and evacuation of the hydatid contents within the bile ducts [20]. If ERCP fails, then bile duct exploration with t-tube drainage or choledochoduodenostomy should be considered.

Biliomas should be evaluated with percutaneous drainage first. When biliary leakage persists, then ERCP with ES should be scheduled [20].

The most common postoperative complication of hydatid liver surgery is bile leakage and fistula formation as mentioned before. In such cases, every effort should be made at the pre-operative and intraoperative period to decrease its rates. When postoperative bile fistula is present, it is essential to determine the flow rate of fistula. In low-flow fistulas (flow rate of <300 ml/day), conservative follow-up for 3 weeks is appropriate since most of low-flow fistulas close spontaneously in this period [8, 9]. If the fistula persists after 3 weeks, then ERCP

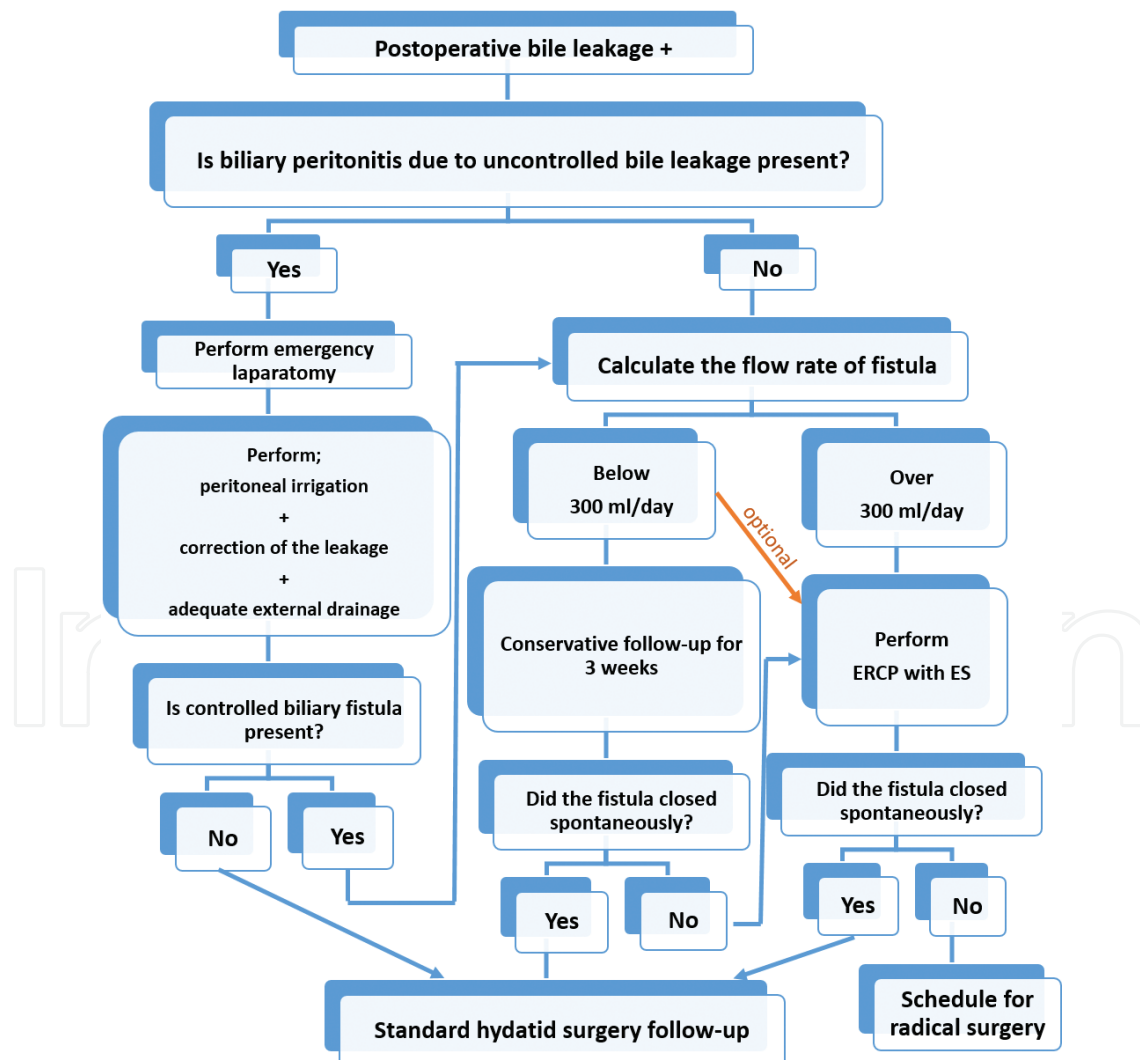


Figure 4. Therapeutic algorithm for postoperative bile leakage.

with ES should be planned [8, 10, 11]. In high-flow fistulas (>300 ml/day), spontaneous closure of the fistula is unlikely; thus, ERCP with ES should be performed without delay [8, 20]. The success rate of ERCP is very high (90%) [11]. Most of the fistulas close in the first week after ERCP [8]. Spontaneous closure of a fistula from a calcified cyst wall is usually unexpected [2]. In our series, PBF occurred in 46 (16%) patients, despite preoperative and operative efforts to prevent this complication. The fistula closed spontaneously in only 12 (26%) of the patients with PBF without further intervention, confirming that patients with PBF often have a complicated postoperative course, requiring multiple endoscopic and other interventional procedures with serious morbidity and mortality [19].

In a small group of patients in whom all interventions fail, as repeated ERCP and stenting, radical surgery could be an alternative for the correction of the leakage [6, 28]. A therapeutic algorithm for postoperative bile leakage evaluation is offered in **Figure 4**.

6. Conclusion

Hydatid liver surgery is still one of the main indications for liver surgery in endemic regions. It is hard to refer all patients to an experienced hepatobiliary surgery center due to high volume of disease in those regions. As a result, conservative methods are still preferred therapeutic modalities for many surgeons.

Cystobiliary communication is the most common complication of hydatid liver disease. Without appropriate evaluation and intervention, this will eventually lead to postoperative bile leakage and fistula formation, a major cause of morbidity and mortality. By that means, every effort should be made to detect and prevent these complications during the evaluation and management of cystic echinococcosis liver disease.

Author details

Can Konca¹ and Deniz Balci^{2*}

*Address all correspondence to: denizbalci1@yahoo.com

¹ Department of General Surgery, Ankara University School of Medicine, Ankara, Turkey

² Department of General Surgery and Transplantation Division of Hepatopancreatobiliary Surgery, Ankara University School of Medicine, Ankara, Turkey

References

- [1] Mihmanli M, Idiz UO, Kaya C, Demir U, Bostanci O, Omeroglu S, Bozkurt E. Current status of diagnosis and treatment of hepatic echinococcosis. *World Journal of Hepatology*. 2016;8(28):1169-1181

- [2] Brunetti E, Kern P, Vuitton DA, Writing Panel for the WHO-IWGE. Expert consensus for the diagnosis and treatment of cystic and alveolar echinococcosis in humans. *Acta Tropica*. 2010;**114**(1):1-16
- [3] Junghanss T, da Silva AM, Horton J, Chiodini PL, Brunetti E. Clinical management of cystic echinococcosis: State of the art, problems, and perspectives. *American Journal of Tropical Medicine and Hygiene*. 2008;**79**(3):301-311
- [4] Guidelines for treatment of cystic and alveolar echinococcosis in humans. WHO Informal Working Group on Echinococcosis. *Bulletin of the World Health Organization*. 1996;**74**(3):231-242
- [5] Gomez IGC, Lopez-Andujar R, Belda Ibanez T, Ramia Angel JM Moya Herraiz A, Orbis Castellanos F, Pareja Ibars E, San Juan Rodriguez F. Review of the treatment of liver hydatid cysts. *World Journal of Gastroenterology*. 2015;**21**(1):124-131
- [6] Sozuer E, Akyuz M, Akbulut S. Open surgery for hepatic hydatid disease. *International Surgery*. 2014;**99**(6):764-769
- [7] Chautems R, Buhler LH, Gold B, Giostra E, Poletti P, Chilcott M, Morel P, Mentha G. Surgical management and long-term outcome of complicated liver hydatid cysts caused by *Echinococcus granulosus*. *Surgery*. 2005;**137**(3):312-316
- [8] Demircan O, Baymus M, Seydaoglu G, Akinoglu A, Sakman G. Occult cystobiliary communication presenting as postoperative biliary leakage after hydatid liver surgery: Are there significant preoperative clinical predictors? *Canadian Journal of Surgery*. 2006;**49**(3):177-184
- [9] Atahan K, Kupeli H, Deniz M, Gur S, Cokmez A, Tarcan E. Can occult cystobiliary fistulas in hepatic hydatid disease be predicted before surgery? *International Journal of Medical Sciences*. 2011;**8**(4):315-320
- [10] El Nakeeb A, Salem A, El Sorogy M, Mahdy Y, Ellatif MA, Moneer A, Said R, El Ghawalby A, Ezzat H. Cystobiliary communication in hepatic hydatid cyst: Predictors and outcome. *The Turkish Journal of Gastroenterology: The Official Journal of Turkish Society of Gastroenterology*. 2017;**28**:125-130
- [11] Ramia JM, Figueras J, De la Plaza R, Garcia-Parreno J. Cysto-biliary communication in liver hydatidosis. *Langenbeck's Archives of Surgery*. 2012;**397**(6):881-887
- [12] Atli M, Kama NA, Yuksek YN, Doganay M, Gozalan U, Kologlu M, Daglar G. Intrabiliary rupture of a hepatic hydatid cyst: Associated clinical factors and proper management. *Archives of Surgery*. 2001;**136**(11):1249-1255
- [13] Prousalidis J, Kosmidis C, Kapoutzis K, Fachantidis E, Harlaftis N, Aletras H. Intrabiliary rupture of hydatid cysts of the liver. *The American Journal of Surgery*. 2009;**197**(2):193-198
- [14] Akcan A, Sozuer E, Akyildiz H, Ozturk A, Atalay A, Yilmaz Z. Predisposing factors and surgical outcome of complicated liver hydatid cysts. *World Journal of Gastroenterology*. 2010;**16**(24):3040-3048

- [15] Kattan YB. Intrabiliary rupture of hydatid cyst of the liver. *Annals of the Royal College of Surgeons of England*. 1977;**59**(2):108-114
- [16] Saez-Royuela F, Yuguero L, Lopez-Morante A, Perez-Alvarez JC, Martin-Lorente JL, Ojeda C. Acute pancreatitis caused by hydatid membranes in the biliary tract: Treatment with endoscopic sphincterotomy. *Gastrointestinal Endoscopy*. 1999;**49**(6):793-796
- [17] Abou-Khalil S, Smith BM, MacLean JD, Poenaru D, Fried GM, Bret P, Barkun AN. Acute cholecystitis and cholangitis caused by *Echinococcus granulosus*. *The American Journal of Gastroenterology*. 1996;**91**(4):805-807
- [18] Ormeci N, Kir M, Coban S, Emrehan Tuzun A, Ekiz F, Erdem H, Palabiyikoglu M, Dokmeci A. The usefulness of endoscopic retrograde cholangiopancreatography and (99m)Tc-labeled albumin macroaggregates in diagnosing hydatid disease fistulae. *Digestive Diseases and Sciences*. 2007;**52**(6):1410-1414
- [19] Zeybek N, Dede H, Balci D, Coskun AK, Ozerhan IH, Peker S, Peker Y. Biliary fistula after treatment for hydatid disease of the liver: When to intervene. *World Journal of Gastroenterology*. 2013;**19**(3):355-361
- [20] Dolay K, Akbulut S. Role of endoscopic retrograde cholangiopancreatography in the management of hepatic hydatid disease. *World Journal of Gastroenterology*. 2014;**20**(41):15253-15261
- [21] Galati G, Sterpetti AV, Caputo M, Adduci M, Lucandri G, Brozzetti S, Bolognese A, Cavallaro A. Endoscopic retrograde cholangiography for intrabiliary rupture of hydatid cyst. *The American Journal of Surgery*. 2006;**191**(2):206-210
- [22] Ozaslan E, Bayraktar Y. Endoscopic therapy in the management of hepatobiliary hydatid disease. *Journal of Clinical Gastroenterology*. 2002;**35**(2):160-174
- [23] Spiliadis C, Georgopoulos S, Dailianas A, Konstantinidis A, Rimikis M, Skandalis N. The use of ERCP in the study of patients with hepatic echinococcosis before and after surgical intervention. *Gastrointestinal Endoscopy*. 1996;**43**(6):575-579
- [24] Montes A, Yuzer Y, Ozbal O, Coker A, Ilter T, Musoglu A. Omentoplasty versus introflexion for hydatid liver cysts. *Journal of the Royal College of Surgeons of Edinburgh*. 1993;**38**(2):82-85
- [25] Zaouche A, Haouet K, Jouini M, El Hachaichi A, Dziri C. Management of liver hydatid cysts with a large bilocystic fistula: Multicenter retrospective study. *Tunisian Surgical Association. World Journal of Surgery*. 2001;**25**(1):28-39
- [26] Ozmen MM, Coskun F. New technique for finding the ruptured bile duct into the liver cysts: Scope in the cave technique. *Surgical Laparoscopy, Endoscopy & Percutaneous Techniques*. 2002;**12**(3):187-189
- [27] Kayaalp C, Sengul N, Akoglu M. Importance of cyst content in hydatid liver surgery. *Archives of Surgery*. 2002;**137**(2):159-163
- [28] Akcakaya A, Sahin M, Karakelleoglu A, Okan I. Endoscopic stenting for selected cases of biliary fistula after hepatic hydatid surgery. *Surgical Endoscopy and Other Interventional Techniques*. 2006;**20**(9):1415-1418