

# We are IntechOpen, the world's leading publisher of Open Access books Built by scientists, for scientists

6,900

Open access books available

186,000

International authors and editors

200M

Downloads

Our authors are among the

154

Countries delivered to

TOP 1%

most cited scientists

12.2%

Contributors from top 500 universities



WEB OF SCIENCE™

Selection of our books indexed in the Book Citation Index  
in Web of Science™ Core Collection (BKCI)

Interested in publishing with us?  
Contact [book.department@intechopen.com](mailto:book.department@intechopen.com)

Numbers displayed above are based on latest data collected.  
For more information visit [www.intechopen.com](http://www.intechopen.com)



---

# Portal Vein Thrombosis in Patients with Liver Cirrhosis

---

Anca Trifan, Carol Stanciu and Irina Girleanu

Additional information is available at the end of the chapter

<http://dx.doi.org/10.5772/intechopen.68929>

---

## Abstract

The myth that patients with liver cirrhosis are “auto-anticoagulated” is outdated, and evidence shows that these patients frequently experience thrombosis. Portal vein thrombosis (PVT), although considered as rare, it gradually increases complications that are more likely to occur during late-stage liver cirrhosis. The aim of this chapter is to perform a review of nonmalignant portal vein thrombosis in cirrhosis, in terms of prevalence, pathogenesis, diagnosis, clinical course, and management. Studies were identified by a search strategy using MEDLINE and EMBASE databases. For the MEDLINE search, we used the following terms: (“liver cirrhosis” [MeSH Terms] OR “cirrhosis” [All Fields] OR “cirrhosis” [All Fields]) AND (“portal vein” [MeSH Terms] OR “portal vein” [All Fields]) AND (“Thrombosis” [MeSH Terms]). For the EMBASE search, we used the following terms: (cirrhosis OR phrase liver cirrhosis) AND (phrase thrombosis/OR phrase vein thrombosis/OR phrase thrombosis prevention/OR phrase portal vein thrombosis/OR phrase liver vein thrombosis/OR phrase mesenteric vein thrombosis/OR thrombosis). Studies were considered eligible if they referred to any aspect of prevalence, pathophysiology, clinical presentation, diagnosis and management, or therapy of PVT in cirrhosis. We put forward possible responses to these unsettled issues starting with prevalence, pathogenesis, and treatment options.

**Keywords:** liver cirrhosis, portal vein thrombosis, treatment

---

## 1. Introduction

Portal vein thrombosis (PVT) is frequently associated with cirrhosis, mostly in patients with advanced liver disease or hepatocellular carcinoma (HCC). The physiopathology of PVT

development is still under debate, and at the moment, there is a lot of controversy regarding the most efficient treatment. Moreover, the outcome in cirrhotics with PVT awaiting a liver transplant or the influence of thrombosis on posttransplant survival and morbidity is still unknown.

## 2. Epidemiology of portal vein thrombosis in liver cirrhosis

PVT is rarely diagnosed in the general population, the prevalence as reported by autopsy-based studies being up to 1% [1]. Genetic or acquired thrombophilia, myeloproliferative diseases, acute pancreatitis, acute cholecystitis, or other inflammations in the abdominal cavity are the main causes of noncirrhotic PVT [2].

In cirrhosis, PVT prevalence varies between 0.6 and 28% depending on the diagnostic method: imaging exam, during surgery for liver transplantation, or autopsy reports [3–5]. In the last years, PVT prevalence has increased as a result of the widespread use of imaging techniques, such as Doppler ultrasonography, computed tomography, or magnetic resonance, but its exact value is still not known. Studies based on ultrasonography results reported a prevalence of 10–28% in cirrhotic patients, excluding those with HCC [2]. The prevalence of PVT in liver transplant candidates is similar to that in other cirrhotic patients with the same degree of liver disease, although MELD and Child-Pugh scores were higher in patients with PVT, confirming the fact that PVT prevalence increases with the severity of liver cirrhosis. Thus, PVT prevalence is low (1%) in compensated liver cirrhosis and up to 28% in decompensated liver cirrhosis [6–8]. Association between liver cirrhosis and malignancies, especially HCC, may increase PVT prevalence up to 44% [6].

If data on the prevalence of PVT are frequently reported, those on the incidence, however, are quite scanty. Maruyama et al. in a retrospective analysis of 150 patients with cirrhosis, followed up for a median period of 66 months, reported a cumulative overall incidence of PVT of 12.8% at 1 year, 18.6% at 3 years, 20% at 5 years, and 38.7% at 8–10 years [9]. Moreover, the incidence of PVT in patients awaiting liver transplant was reported to be 7% after one-year follow-up [10].

## 3. Pathogenesis of portal vein thrombosis in cirrhosis

Pathogenesis of PVT in patients with cirrhosis still remains uncertain, although some authors consider PVT a complication of liver disease. However, its development is unpredictable and the risk factors are not well recognized. According to Virchow's triad, venous thrombosis is the result of the coexistence of low blood flow, endothelial injury, and a hypercoagulable state. For these reasons, PVT in cirrhosis could be developing as a consequence of portal hypertension, associated with endothelial dysfunction and a relative hypercoagulable state [11, 12].

Portal hypertension is characterized by a reduced portal flow due to increased intrahepatic vascular resistance. This phenomenon is further increased as liver disease progresses [13], representing one of the risk factors that determine the increased incidence of PVT in advanced liver disease as compared to early compensated cirrhosis. This hypothesis was confirmed in one prospective study, which demonstrated that the reduced portal flow velocity below 15 cm/s was the only independent variable correlated with the risk of developing PVT at 1-year follow-up [13].

Advanced cirrhosis is associated with profound and complex coagulation defects, involving procoagulant and anticoagulant factors, fibrinolytic system, and platelets number and function [12]. The net result of all of these defects may be a prothrombotic state, which is likely to be related with the increased endothelial synthesis of von Willebrand factor (vWf) and an increased level of factor VIII, combined with low levels of hepatic anticoagulation agents such as antithrombin III, protein C and S [14, 15].

A number of different inherited and acquired disorders have been also considered as predisposing factors for PVT in patients with cirrhosis, although with variable degree of evidence [16–18]. One study found antiphospholipids antibodies in more than half of cirrhotic patients with PVT [19], whereas variable association of newly recognized risk factors for inherited thrombosis such as the Q506 polymorphism in the gene coding for factor V or the G20210A change in the prothrombin gene (PTHR A20210) has been reported in patients with cirrhosis complicated by PVT [16, 20, 21]. None of these changes were confirmed as independent risk factors for PVT in liver cirrhosis. PAI-1 4G-4G and MTHFR 677TT screening of patients could be useful, especially in alcoholic or cryptogenic cirrhosis, to identify patients in which new drug therapies based on the inhibition of the hepatic stellate cell activation could be easily assessed [22].

Thrombocytopenia was considered for a long time a risk factor for bleeding in patients with liver cirrhosis, but recent reports did not confirm this hypothesis. Some studies showed abnormalities of platelet aggregation in patients with cirrhosis [23, 24], which was attributed to decreased serum levels of clotting factors [23], impaired production of thromboxane A<sub>2</sub> and arachidonic acid, or impairment in adhesion molecules [25, 26]. This theory was confirmed by multiple electrode aggregometry, which demonstrated a decreased aggregation activity of platelets, although this phenomenon was not observed under stimulation by ristocetin. This finding implies that the cause of platelet hyporeactivity does not lie in defective transmembrane or postmembrane signaling pathway, while platelet activity was positively correlated with the number of platelets. Interestingly, platelet activity was significantly lower in the PVT group than in the non-PVT group, although the platelet count was not significantly different in either group. A clear reason for this finding was not given, and it is suggested that adaptive changes in platelet function occur after the development of PVT [27]. Some studies consider the degree of thrombocytopenia to be an independent risk factor for PVT, which may seem paradoxical since low platelet count should logically predispose to bleeding. Possibly, as cirrhosis and portal hypertension progress, the resultant decrease in portal flow outweighs a protective effect of low platelet count against thrombosis [27].

Another factor associated with PVT development in liver cirrhosis is endothelial dysfunction. Portal hypertension and inversion of portal vein flow are among the factors associated with endothelial dysfunction. Endotoxemia is another factor that contributes to endothelial dysfunction in cirrhotic patients with PVT. The biological consequences of systemic endotoxemia are low-grade inflammation and peripheral vasodilatation [27]. *In vitro* studies have revealed that lipopolysaccharides, even in low concentrations, may stimulate vWf release from the endothelium [14]. Moreover, Violi et al. provided evidence of a direct correlation between endotoxemia and the ongoing prothrombotic state in the portal venous system [28]. Therefore, it is plausible that endotoxemia, in combination with the coexisting increased vWf release frequently found in cirrhosis, together with portal hypertension may trigger prothrombotic mechanisms, the development of endotoxemia being a surrogate marker of disease severity in patients with cirrhosis [29].

Besides the common risk factors for PVT, other predisposing conditions such as variceal sclerotherapy, liver malignancy, abdominal surgery, or sepsis were described. The roles of sclerotherapy and cyanoacrylate glue injection as potential trigger factors for PVT are controversial, but they were reported in the literature [30]. Such associations could occur as a result of selection bias in patients with more severe portal hypertension. Surgical procedures for portal hypertension were also associated with an increased incidence of PVT [31, 32]. Among them, pericardial devascularization with splenectomy, and splenorenal shunts are associated with an increased risk of PVT [33].

Along with the sluggish portal flow [19] and the presence of liver malignancies (i.e., hepatocellular carcinoma), other acquired local (abdominal surgery, trauma or bacterial infection, and portacaval shunts), or general (sepsis and myeloproliferative disorders) factors have been claimed as possible causes of PVT in patients with liver cirrhosis [12–16].

The main consequences of PVT are related to the extension of the thrombus and include intestinal ischemia and acute/chronic portal hypertension. Gastrointestinal bleeding due to portal hypertension following PVT has been reported as a major cause of death in patients with cirrhosis [34]. The pathogenesis of PVT in such patients remains unclear, although decreased portal vein blood flow, a hypercoagulable state, and systemic inflammation may be of importance. Despite the great number of risk factors for PVT in liver cirrhosis, thrombosis itself should be considered a multifactorial disease, and the likelihood of developing PVT increases in direct proportion to the number of risk factors present in each patient.

#### 4. Diagnosis of portal vein thrombosis

PVT diagnosis in cirrhotic patients involves clinical suspicion with further imagistic confirmation. According to the moment of diagnosis, this particular type of venous thrombosis could be classified as:

- *acute*: sudden formation of a thrombus within the portal vein, with or without involvement of the mesenteric and/or splenic vein [35];
- *chronic*: the obstructed portal vein is replaced by collateral veins bypassing the thrombosed vein [36].



#### 4.1. Clinical presentation

PVT is frequently diagnosed in asymptomatic cirrhotic patients by routine abdominal ultrasound (US). In most of these cases, PVT is chronic with partial obstruction. Acute partial or total PVT is frequently symptomatic, and it is associated with decompensation or further decompensation of liver disease.

The symptoms and signs of acute PVT could be represented by severe abdominal or lumbar pain with sudden onset, progressive over days, without peritoneal signs when the superior mesenteric vein is involved, functional ileus, ascites, or variceal bleeding. The majority of the patients with acute PVT associate systemic inflammatory response syndrome in the absence of sepsis. If the symptoms are not resolved in 5–7 days or liver cirrhosis is complicated by further decompensation and clinical deterioration, mesenteric vein involvement with complete loss of blood flow should be suspected.

Chronic PVT is asymptomatic in most cases. The pain is a sign of mesenteric vein thrombosis and bowel ischemia. Although there is a minimal change in the hepatic arterial blood supply, the portal pressure is increased, with the development of portosystemic collaterals and an increased risk of variceal bleeding. This fact supports the Baveno VI recommendations stating that it is mandatory to perform screening endoscopy in all patients diagnosed with chronic PVT within 6 months from the acute episode if a complete recanalization of thrombosis is not achieved [36]. A total of 22% of patients without varices at initial endoscopy will develop this condition in 3 years [37]. Therefore, a follow-up endoscopy should be performed in subjects without varices at the baseline [36].

With regard to primary prevention of bleeding, no randomized controlled trial compared the effectiveness of nonselective beta-blockers versus endoscopic band ligation in PVT. In this scenario, as well as in the context of the acute bleeding and secondary prophylaxis, Baveno VI recommends following the guidelines on PH in cirrhosis [36]. Besides prehepatic portal hypertension, portal cholangiopathy is another context associated with chronic PVT. Patients develop jaundice, abdominal pain, and episodes of cholangitis.

#### 4.2. Imaging evaluation: abdominal ultrasound

When PVT is suspected, ultrasound is the first-line imaging method to be used, since it holds an accuracy ranging from 88 to 98% for the detection of PVT with a sensitivity and specificity of 80–100% in the majority of studies [38, 39]. The sensitivity of ultrasound is particularly high in complete PVT, while the risk of false-negative results occurs only in incomplete PVT [40] and isolated superior mesenteric vein thrombosis [38]. In two-dimensional (2-D) Gray-Scale ultrasonography, a thrombus appears as a hypo/isoechoic material occupying part of (partial thrombosis) or the entire vessel (complete thrombosis). The normal portal vein can be eventually replaced by multiple tortuous vessels with hepatopetal flow, a condition named as “cavernomatous transformation” or “cavernoma,” easily detected with Doppler ultrasound. Color/power and pulsed Doppler should be mandatorily used to confirm whether the vessel has a remnant blood flow, to help differentiate high-degree partial thrombosis from complete thrombosis. The reliability of ultrasonography in the detection of PVT improves with the operator’s experience, and whenever PVT is clinically suspected, ultrasonography

should be performed by experienced operators [41]. Ultrasonography suffers from other limitations such as reduced visualization in obese individuals and in case of abundant bowel gas, and impossibility to assess bowel ischemia. This should be suspected in case of ascites and/or high blood lactate levels. Ultrasound is sufficient to diagnose PVT in patients with a good acoustic window, but when ultrasonography is insufficient, a second-line cross-sectional imaging method should be considered to confirm or exclude the diagnosis.

#### **4.3. Imaging evaluation: computed tomography and magnetic resonance**

Contrast-enhanced four phase (pre-contrast, arterial, portal, and late) CT (CECT) and contrast-enhanced MRI (CEMRI) can be used, with CT is preferred in unstable patients with acute abdominal symptoms. Advantages of MR and CT over US include the possibility of detecting bowel ischemia, septic foci and intraabdominal malignancies, and higher sensitivity in the detection of thrombosis in the splenic and superior mesenteric vein. Among the well-known drawbacks of CT are exposure to ionizing radiation, the risk of allergic reactions, and nephrotoxicity. CEMRI is also contraindicated in patients with acute renal failure because of the risk of nephrogenic systemic fibrosis. Once PVT is diagnosed, CECT or CEMRI is mandatory to evaluate the extent of thrombosis and to allow a detailed mapping of portosystemic collaterals, crucial to the planning of interventions aimed at recanalizing the portal venous system. It should be considered that clinical consequences of PVT mainly depend on the number of vessels completely occluded [42], as well as the degree of collateralization in chronic cases. Furthermore, the presence of ascites is a predictor of the lack of response to anticoagulation and should be reported [42]. Several classification/staging systems have been developed, but they rely heavily on anatomical considerations. The most commonly cited and used in clinical trials is the one proposed by Yerdel et al. [43]. However, there is no validated classification to be used in clinical practice in order to personalize risk assessment and guide therapy [44].

Both Doppler ultrasonography and multiphasic-computed tomography have high sensitivity and specificity for PVT detection [45]. Doppler US is highly accurate in detecting thrombosis involving the trunk of the portal vein and intrahepatic branches, also providing additional information regarding the portal flow and its direction. CT is better at assessing the superior mesenteric vein, spontaneous portosystemic shunts, renal veins, and the inferior vena cava. While a CT exam is generally performed at the time of initial evaluation for liver transplant, Doppler ultrasound is appropriate for follow-up imaging as it can be performed repetitively and does not have the risks of intravenous iodine contrast and radiation.

#### **4.4. Imaging evaluation: malignant versus nonmalignant PVT**

Patients with cirrhosis or neoplastic disease may develop either benign or malignant PVT. In patients with HCC, it is essential to radiologically distinguish tumor invasion of the main trunk or the branches of the portal vein as the cause for PVT versus bland thrombus in the portal vein because this could determine the proper therapeutic approach and their prognosis.

This is not without implications since the major vascular tumoral invasion is an absolute contraindication to transplant, while bland PVT in the presence of HCC needs to be approached similarly to a non-HCC setting [45]. Tumor-related PVT is usually detected in portal vein branches adjacent to and in direct continuity of the tumor, and is often associated with a high alpha-fetoprotein level.

Until recently, imaging differentiation of the benign from the malignant PVT has depended on the findings of contrast enhancement and luminal expansion on abdominal ultrasound, CT, or MRI. Signs of malignant PVT on ultrasound include an expansive aspect mass inside the lumen, with heterogeneous aspect and disruption of portal vein walls. Color/power-Doppler ultrasound shows signs of neovascularization within the mass, and pulsed Doppler could confirm arterial flow with a high resistance index associated with malignant PVT. One of the most sensitive and with small additionally methods for malignant PVT diagnosis is contrast ultrasound. In contrast to bland PVT, which remains unenhanced in all phases, a malignant PVT shows the same contrast-behavior as HCC—rapid wash-out (hypoperfusion in comparison to the rest of the liver parenchyma) in the portal/late phase.

Enhancement or an increase in density or intensity on CT or MRI, respectively, after contrast administration could also establish the diagnosis of malignant PVT. Conversely, absent enhancement confirms bland thrombus.

Careful screening for PVT is important in all patients with cirrhosis and in those under evaluation for liver transplantation. Repeated imaging at specified intervals—usually every 3 months, during the pretransplant waiting period—is also recommended in order to detect thrombosis that may develop during follow-up [7]. Patients who develop unexplained worsening of liver functions or gastrointestinal bleeding despite adequate prophylaxis should also be evaluated for PVT of recent onset.

## 5. Management of portal vein thrombosis

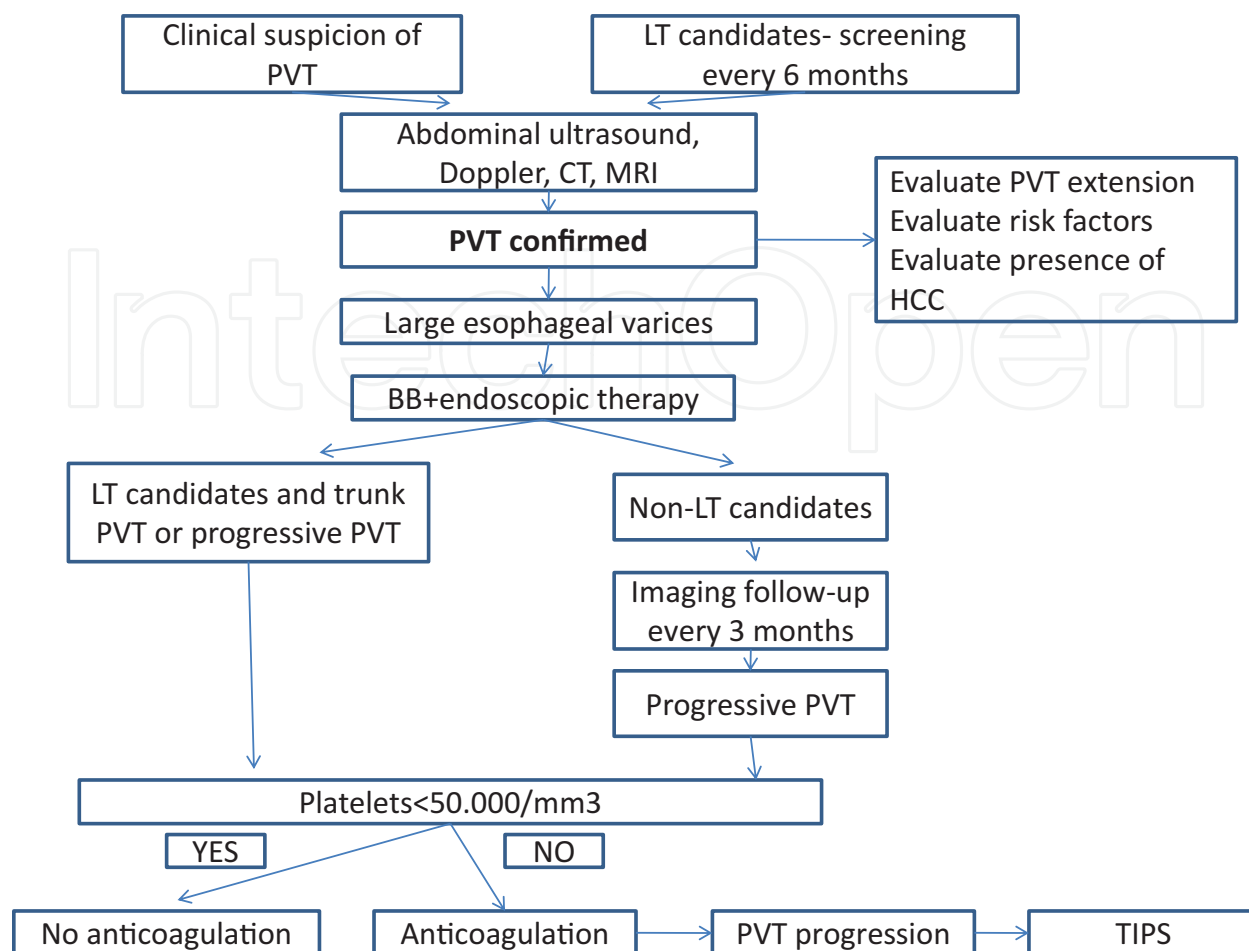
Nowadays, there are two main possibilities of PVT treatment: anticoagulation with low-molecular-weight heparin (LMWH) or oral anticoagulants, and transjugular intrahepatic portosystemic shunt (TIPS). The best therapeutic solution is still under debate, but the final goal is to prevent PVT extension to the mesenteric veins and achieve PVT recanalization (**Figure 1**).

### 5.1. Anticoagulant treatment for PVT in cirrhotic patients

Anticoagulant treatment in cirrhotic patients who are not on a liver transplant list may be considered if the superior mesenteric vein is involved or the patient carries a known prothrombotic condition [36].

Some studies have reported that spontaneous recanalization of the portal vein in the absence of an anticoagulant treatment is unusual. In the study by Francoz et al., no patient achieved recanalization in the absence of anticoagulation, while 42% achieved recanalization while





**Figure 1.** Algorithm for the diagnosis and management of PVT in liver cirrhosis.

under anticoagulant therapy [46]. Senzolo et al. reported thrombus progression in 75% of patients who did not receive anticoagulant treatment, compared to only 15% of treated patients [47].

There are limited studies reporting on the use of anticoagulation for PVT in patients with cirrhosis. In all these studies, complete recanalization has been described in 33–45% of cases, while partial portal vein recanalization was observed in 15–35% of cases [46, 48, 49]. In a study by Senzolo et al., prospectively enrolling 56 individuals (35 treated and 21 controls), complete recanalization was achieved in 36% of subjects and partial recanalization in 27%, after therapy with LMWH (mean 5.5 months) [47]. The time between diagnosis and anticoagulation—under 6 months—was the most important factor positively associated with portal vein recanalization. In a study from Spain, by Delgado et al., including 55 cirrhotic patients, the majority of them (75%) diagnosed with partial PVT, complete portal vein recanalization was achieved in 45% of cases after a median duration of therapy of 6.3 months with vitamin K antagonists (VKA) or LMWH [48]. In this study, the only predictive factor for achieving complete portal vein recanalization was also early initiation of anticoagulation therapy after diagnosis, in less than 14 days.

Nowadays, there are no clear data regarding the duration of anticoagulant treatment, although Amitrano et al. treated 28 patients with LMWH and demonstrated that after 6 months, complete portal vein recanalization was achieved in 33% of cases and partial portal vein recanalization was observed in 50%. In individuals with partial response to therapy, anticoagulant treatment was continued for more than 6 months, and 86% of these patients achieved complete recanalization [50].

The rate of PVT recanalization depends not only on the time of PVT diagnosis, but also on the type of PVT in most of the cases: complete or partial, tumoral or nontumoral. As shown by most studies, recanalization is uncommon in patients with complete thrombosis, but anticoagulation is still indicated in order to prevent the extension of the thrombus [46–50]. However, it is unclear what proportion of these patients would have recanalized spontaneously and, more importantly, whether they derived any clinical benefit from anticoagulation. This hypothesis was raised by other studies with conflicting results. Maruyama et al. reported a spontaneous improvement in 47.6%, unchanged appearance in 45.2%, and progression in only 7.2%. There was no significant difference in the natural course of thrombosis, based on the degree of obstruction or the location of the thrombus, and recurrence of PVT after spontaneous resolution was observed in 21.4% [9]. Our data also confirmed Maruyama's study results. We demonstrated that in most of the cirrhotic patients diagnosed with PVT, the thrombus remained with the same dimensions or disappeared without any therapeutical intervention [51].

For cirrhotic patients diagnosed with PVT awaiting for a liver transplant, it is important to achieve recanalization and thus achieve a physiological portal vein anastomosis in order to ensure portal flow to the graft. Transplanting patients with PVT extended to the superior mesenteric vein or with extensive portal vein thrombosis is associated with higher morbidity and mortality, PVT being a predictor of posttransplant mortality in some studies [43, 52, 53].

An important objective in the management of PVT in cirrhotic patients awaiting liver transplantation is to achieve recanalization for the end-to-end portal vein anastomosis to be surgically possible. Another objective is to prevent extension of the thrombus to the splenic and superior mesenteric vein, since these veins can also be used to restore portal flow to the graft in case the main portal vein is thrombosed. In the event that neither the portal vein nor the superior mesenteric vein can be used, nonanatomical techniques to restore portal flow are possible, but these are associated with increased morbidity and mortality. Francoz et al. compared 19 individuals with cirrhosis and PVT on the waiting list for liver transplantation who received anticoagulation therapy (VKA) with 10 individuals not receiving therapy. A total of 42% of treated individuals achieved complete PV recanalization. None of the untreated patients had recanalization, and, in fact, PVT progressed in 60 % in the untreated group. Moreover, anticoagulation therapy did not increase blood loss during liver transplantation [46].

The rationale for treating PVT in patients with cirrhosis is that it increases morbidity compared to matched cirrhotics without PVT, although there is controversy regarding the influence of PVT on the natural course of liver cirrhosis. PVT has been reported to be independently associated with a higher risk of failure in controlling acute variceal bleeding as well as rebleeding [44]. The occurrence of PVT has also been shown to increase mortality, which has been observed even

in patients with lower Child-Pugh scores [46]. Recanalization of PVT has also been reported to reduce esophageal variceal pressure, improving morbidity, and mortality rates [44].

There are no clear recommendations for an optimal anticoagulation regimen for the treatment of PVT in patients with cirrhosis. Monitoring of anticoagulation regimen is complex in the cirrhotic patient and, therefore, choosing between different anticoagulants (LMWH, VKA, or the new oral anticoagulants) is a difficult decision. LMWH is less practical for patients, since it necessitates daily subcutaneous injections, although it does not affect INR values and, consequently, does not interfere with MELD or Child scoring. There is, however, limited information on the pharmacodynamic profile of LMWH in cirrhotic individuals.

Cirrhotic patients often have an increased volume of distribution because of fluid overload, and this makes it difficult to determine the optimal dose of LMWH. Moreover, the major route of *elimination* of the LMWH is through the *kidneys*, and, since many patients with cirrhosis have renal insufficiency, the half-life of LMWH is increased. The only method of LMWH treatment monitoring validated until known is by determining the anti-Xa activity, but this method is unreliable in cirrhosis [35, 55].

The primary problem with VKA is determining the adequate anticoagulation in patient with cirrhosis who already has an altered abnormal prothrombin time. Most studies have targeted an INR of 2–3 [54]. Based on an empirical experience not relying on randomized studies, if the baseline INR is over 2, it is difficult to determine if a given dose of VKA ensures adequate anticoagulation. It may also be difficult to determine the optimal INR target for dose adjustment. There is also a potential risk of further lowering of protein C levels with the use of VKA, and this could theoretically increase the prothrombotic imbalance of individuals with cirrhosis.

The new oral anticoagulants—thrombin inhibitors and inhibitors of activated factor X such as dabigatran and rivaroxaban—offer the advantage of oral administration, the absence of laboratory monitoring, and an antithrombin-independent mechanism of action [54]. However, there are a few reports regarding their use in cirrhotic patients, most of them isolated cases. One of the major disadvantages of these new anticoagulants was the absence of an antidote. This problem was solved for dabigatran and also for rivaroxaban, which could be the new class of anticoagulants preferred in PVT treatment. In cirrhotic patients, it may be necessary to reverse anticoagulation during episodes of inadvertent bleeding or at the time of surgery. While the effect of VKA can be expertly reversed by fresh-frozen plasma or prothrombin complex concentrate, there is no potent and rapidly acting antidote to reverse the effect of LMWH or the newer thrombin inhibitors.

Even if the anticoagulant treatment seems to be the same in patients with liver cirrhosis, it is uncertain whether it is beneficial to anticoagulate asymptomatic patients who are detected with PVT incidentally on imaging [35, 55].

The impact of PVT on the natural history of cirrhosis remains a matter of great debate, and the clinical benefits of PV recanalization have fully demonstrated [50]. Despite this, there is evidence that cirrhotic individuals with PVT awaiting for liver transplantation should be treated with anticoagulation therapy because complete or partial portal vein recanalization has been associated with a better 2-year survival rate after liver transplantation (82–83%) compared to

individuals with complete PVT (50%) [46]. Other situations where anticoagulation is expected to be beneficial are cirrhotic patients with acute PVT with extension to the superior mesenteric vein [35, 55]. Cirrhotic patients with well-documented prothrombotic disorder should obviously be considered for anticoagulation. Patients with cavernomatous transformation of the portal vein have been excluded from most trials since such patients are not expected to benefit from anticoagulation.

## 5.2. TIPS and thrombolysis for PVT in cirrhotic patients

The use of transjugular intrahepatic portosystemic shunt (TIPS) has also been reported to recanalize the portal vein and also prevent rethrombosis by restoring portal flow through the shunt [56–59]. TIPS insertion and recanalization is associated with mechanical thrombectomy. However, in such cases, TIPS is expected to be technically challenging with a higher failure rate and should be attempted only in experienced centers. Systemic or *in situ* thrombolysis has been reported in cirrhotic patients with PVT [60]. In noncirrhotic patients with acute PVT, rates of recanalization have been dismal with attempted thrombolysis. There has also been a high incidence of major bleeding [60]. There are no data to support this option in this setting. TIPS promotes the dissolution or decrease in PVT, splenic, or mesenteric veins, in the US population of patients with predominantly compensated liver cirrhosis of various etiologies [57, 58].

## 6. Portal vein thrombosis and liver transplantation

Most of the studies on liver transplant patients with PVT revealed higher technical difficulties and mortality, postoperative complications, in the PVT group compared with those without PVT. The higher morbidity and mortality is multifactorial and is related to a more complex surgical procedure, increased requirement of blood transfusions, higher risk of complications such as primary nonfunction or dysfunction, hepatic artery thrombosis, postoperative pancreatitis, sepsis, or renal failure [61, 62]. Moreover, there is a high risk of 9–42% of PVT rethrombosis [63]. Patients with Child-Pugh class C cirrhosis, complete PVT, and alcoholic etiology of hepatic disease have a higher risk of PVT rethrombosis after liver transplant. Of a pooled total of 169 patients with partial PVT, 7 (4%) developed rethrombosis in contrast with 14 of 114 patients with complete PVT (12.3%) [63].

The main treatment indication is early anticoagulation with low-molecular-weight heparin unless it is contraindicated for surgical reasons, although randomized controlled trials are lacking. Moreover, there is no consensus on how long anticoagulation should be continued posttransplant. In the absence of prothrombotic state, there is no evidence that pretransplant PVT justifies long-term anticoagulation posttransplantation. Mortality is related to the grade of preoperative PVT. The 30-day mortality in patients undergoing liver transplantation with or without PVT has been reported as 10.5% versus 7.7%, respectively [63]. The 1-year mortality was also reported to be significantly higher in a systematic review according to the presence (18.8%) or absence (15.3%) of PVT [63]. The 30-day mortality has been reported to vary between 3.8% for grade 1 and 2 PVT, and going up to 27% for grade 4 PVT [64]. Preoperative

PVT seems to influence early outcome more than long-term results, with the maximum decrease in survival occurring in the first year, and medium-term results with or without PVT appearing to be comparable if early mortality is excluded [65].

For many years, PVT had been considered as an absolute contraindication to liver transplantation [66]. The first successful surgery for complete PVT was reported by Shaw et al. in 1985 [66]. Nowadays, the innovations in surgical techniques have made it possible to overcome problems due to PVT during transplantation. The stage of liver disease and the collateral circulation increase the complexity of surgical techniques and pose a challenge for the surgery, because it is very important to have an adequate portal inflow of the graft to maintain the liver function.

In order to establish if the patient has a surgical indication, preoperative assessment must evaluate the correct stage and grade of PVT based on a spiral CT scan or a magnetic resonance venogram. For surgical purposes, Yerdel et al. have classified PVT into four grades [43]:

Grade 1: Partially thrombosed portal vein, where the thrombus occupies less than 50% of the lumen.

Grade 2: More than 50% occlusion of the portal vein, including total occlusions, with or without extension into the superior mesenteric vein.

Grade 3: Complete thrombosis of both the portal vein and the proximal superior mesenteric vein.

Grade 4: Complete thrombosis of the portal vein, proximal, and distal superior mesenteric vein.

There are several available surgical techniques for PVT reconstruction during liver transplant surgery. All the techniques vary according to the degree and the anatomical spread of the PVT [65].

1. Portal vein thrombectomy (for Yerdel grade 1 and 2 PVT) and direct anastomosis of donor and recipient portal vein. A recent study suggested that 75–90% of transplants performed in patients with PVT, and the thrombosis could be managed only by thrombectomy [61]. After completion of the thrombectomy, adequate flow in the recipient portal vein or superior mesenteric vein must be confirmed by releasing the vascular clamp before proceeding with the anastomosis.
2. In cases of Yerdel grade 2 or grade 3 occlusions, an anastomosis may be required between the graft portal vein and the recipient superior mesenteric vein. The anastomosis uses a section of the donor iliac vein as a graft. The presence of a large collateral vein may provide an alternative portal inflow, although extraanatomical vessels are more fragile and prone to thrombosis.
3. Arterialization of the portal vein: anastomosis of the graft portal vein to the recipient arterial inflow.
4. Portacaval hemitransposition: an anastomosis of the graft portal vein is made to the supra-renal recipient inferior vena cava. The disadvantage of classic portacaval hemitransposition



is the persistence of portal hypertension associated with an increased risk of bleeding from gastroesophageal varices, which may occur in up to 50% of such cases [65].

Rodriguez-Castro, in a systematic review, reported that among 49 patients with portacaval hemitransposition, 20% had episodes of variceal bleeding, 58% had persistent ascites, and 26% presented with renal dysfunction after liver transplantation [66]. An alternative to portacaval hemitransposition is renoportal transposition, where the recipient portal vein is anastomosed to the left renal vein [65].

## 7. Conclusion

PVT is a highly heterogeneous entity regarding its underlying risk factors and the association with liver cirrhosis independently of the disease stage. Although significant advances have been made in the field of PVT associated with liver cirrhosis in recent years, many important questions still remain unanswered. Most critical issue that requires future studies is the influence of PVT on natural course of liver cirrhosis according to the new classification, and it has to establish the risk-benefit ratio of anticoagulant treatment in different groups of patients, including the role of the new oral anticoagulant.

## Abbreviations

PVT	Portal vein thrombosis
LT	Liver transplant
CT	Computed tomography
MRI	Magnetic resonance imaging
BB	Beta-blockers
TIPS	Transjugular portosystemic shunt
HCC	Hepatocellular carcinoma

## Author details

Anca Trifan<sup>1,2\*</sup>, Carol Stanciu<sup>2</sup> and Irina Girleanu<sup>1,2</sup>

\*Address all correspondence to: [ancatrifan@yahoo.com](mailto:ancatrifan@yahoo.com)

1 “Grigore T. Popa” University of Medicine and Pharmacy, Iași, Romania

2 Institute of Gastroenterology and Hepatology, Iași, Romania

## References

- [1] Kumar A, Sharma P, Arora A. Review article: Portal vein obstruction-epidemiology, pathogenesis, natural history, prognosis and treatment. *Alimentary Pharmacology & Therapeutics*. 2015;**41**:276-292
- [2] Tsochatzis EA, Senzolo M, Germani G, et al. Systematic review: Portal vein thrombosis in cirrhosis. *Alimentary Pharmacology & Therapeutics*. 2010;**31**:366-374
- [3] Blachier M, Leleu H, Peck-Radosavljevic M, et al. The burden of liver disease in Europe: A review of available epidemiological data. *Journal of Hepatology*. 2013;**58**:593-608
- [4] Amitrano L, Guardascione MA, Brancaccio V, et al. Risk factors and clinical presentation of portal vein thrombosis in patients with liver cirrhosis. *Journal of Hepatology*. 2004;**40**:736-741
- [5] Nery F, Chevret S, Condat B, et al. Causes and consequences of portal vein thrombosis in 1,243 patients with cirrhosis: Results of a longitudinal study. *Hepatology*. 2015;**61**:660-667
- [6] Raja K, Jacob M, Asthana S. Portal vein thrombosis in cirrhosis. *Journal of Clinical and Experimental Hepatology*. 2014;**4**:320-331
- [7] Francoz C, Valla D, Durand F. Portal vein thrombosis, cirrhosis, and liver transplantation. *Journal of Hepatology*. 2012;**57**:203-212
- [8] Kinjo N, Kawanaka H, Akahoshi T, et al. Portal vein thrombosis in liver cirrhosis. *World Journal of Hepatology*. 2014;**6**:64-71
- [9] Maruyama H, Okugawa H, Takahashi M, Yokosuka O. De novo portal vein thrombosis non virus-related cirrhosis: Predictive factors and long-term outcomes. *The American Journal of Gastroenterology*. 2013;**108**(4):568-574
- [10] Cagin IF, Atayan Y, Erdogan MA et al. Incidence and clinical presentation of portal vein thrombosis in cirrhotic patients. *Hepatobiliary & Pancreatic Diseases International*. 2016;**15**:499-503
- [11] Primignani M. Portal vein thrombosis, revisited. *Digestive and Liver Disease*. 2010;**42**:163-170
- [12] Tripodi A, Mannucci PM. The coagulopathy of chronic liver disease. *The New England Journal of Medicine*. 2011;**365**(2):147-156
- [13] Zocco MA, Di Stasio E, De Cristofaro R, et al. Thrombotic risk factors in patients with liver cirrhosis: Correlation with MELD scoring system and portal vein thrombosis development. *Journal of Hepatology*. 2009;**51**:682-689
- [14] Ferro D, Quintarelli C, Lattuada A, et al. High plasma levels of von Willebrand factor as a marker of endothelial perturbation in cirrhosis: Relationship to endotoxemia. *Hepatology*. 1996;**23**:1377-1383

- [15] Tripodi A, Nstee QM, Soogaard KK, et al. Hypercoagulability in cirrhosis: Causes and consequences. *Journal of Thrombosis and Haemostasis*. 2011;**9**(9):1715-1723
- [16] Amitrano L, Brancaccio V, Guardascione MA, et al. Inherited coagulation disorders in cirrhotic patients with portal vein thrombosis. *Hepatology*. 2000;**31**:345-348
- [17] Dentali F, Galli M, Gianni M, et al. Inherited thrombophilic abnormalities and risk of portal vein thrombosis. A meta-analysis. *Journal of Thrombosis and Haemostasis*. 2008;**99**:675-682
- [18] Tripodi A, Primignani M, Lemma L, et al. Evidence that low protein C contributes to the procoagulant imbalance in cirrhosis. *Journal of Hepatology*. 2013;**59**:265-270
- [19] Amitrano L, Ames PR, Guardascione MA, et al. Antiphospholipid antibodies and antiphospholipid syndrome: Role in portal vein thrombosis in patients with and without liver cirrhosis. *Clinical and Applied Thrombosis/Hemostasis*. 2011;**17**:367-370
- [20] Qi X, Ren W, De Stefano V, Fan D. Associations of coagulation Factor V Leiden and prothrombin G20210A mutations with Budd-Chiari syndrome and portal vein thrombosis: A systematic review and meta-analysis. *Clinical Gastroenterology and Hepatology*. 2014;**12**(11):1801-12.e7
- [21] Janssen HL, Meinardi JR, Vleggaar FP, et al. Factor V Leiden mutation, prothrombin gene mutation, and deficiencies in coagulation inhibitors associated with Budd-Chiari syndrome and portal vein thrombosis: Results of a case-control study. *Blood*. 2000;**96**:2364-2368
- [22] D'Amico M, Pasta F, Pasta L. Thrombophilic genetic factors PAI-1 4G-4G and MTHFR 677TT as risk factors of alcohol, cryptogenic liver cirrhosis and portal vein thrombosis, in a Caucasian population. *Gene*. 2015;**568**:85-88
- [23] Northup PG, Sundaram V, Fallon MB, et al. Hypercoagulation and thrombophilia in liver disease. *Journal of Thrombosis and Haemostasis*. 2008;**6**:2-9
- [24] Ikura Y, Nakamichi T, Matsumoto S, et al. Hepatic aggregation of activated platelets contributes to the development of thrombocytopenia in cirrhosis. *Hepatology*. 2010;**52**:895A
- [25] Laffi G, La Villa G, Pinzani M, Ciabattini G, et al. Altered renal and platelet arachidonic acid metabolism in cirrhosis. *Gastroenterology*. 1986;**90**:274-282
- [26] Laffi G, Cominelli F, Ruggiero M, et al. Altered platelet function in cirrhosis the liver: Impairment of inositol lipid and arachidonic acid metabolism in response to agonists. *Hepatology*. 1988;**8**:1620-1626
- [27] Wosiewicz P, Zorniak M, Hartleb M et al. Portal vein thrombosis in cirrhosis is not associated with intestinal barrier disruption or increased platelet aggregability. *Blood*. 2016;**40**:722-729
- [28] Violi F, Ferro D, Basili S, Saliola M, et al. Association between low-grade disseminated intravascular coagulation and endotoxemia inpatients with liver cirrhosis. *Gastroenterology*. 1995;**109**:531-539

- [29] Lin RS, Lee FY, Lee SD, et al. Endotoxemia in patients with chronic liver diseases: Relationship to severity of liver diseases, presence of esophageal varices, and hyperdynamic circulation. *Journal of Hepatology*. 1995;**22**:165-172
- [30] Politoske D, Ralls P, Korula J. Portal vein thrombosis following endoscopic variceal sclerotherapy. Prospective controlled comparison in patients with cirrhosis. *Digestive Diseases and Sciences*. 1996;**41**:185-190
- [31] Li DX, Tang Z, Qiu XG. A study on the mechanism of acute portal vein thrombosis after pericardial devascularization with splenectomy for the treatment of portal hypertension. *Chinese Journal of Integrative Medicine*. 2003;**3**:008
- [32] Wu G, Li JS, Tao T, et al. Analysis on the risk factors of portal vein thrombosis after the operation in patients with portal hypertension. *Journal of Chongqing Medical University*. 2012;**4**:027
- [33] Zhou GW, Li HW. Surgical therapy for portal hypertension in patients with cirrhosis in China: Present situation and prospects. *Chinese Medical Journal*. 2009;**122**:1483-1485
- [34] Senzolo M, Garcia-Pagan JC. Incidence and natural course of portal vein thrombosis in cirrhosis. *The American Journal of Gastroenterology*. 2013;**108**:1807-1808
- [35] DeLeve LD, Valla DC, Garcia-Tsao G, et al. Vascular disorders of the liver. *Hepatology*. 2009;**49**(5):1729-1764
- [36] de Franchis R, Baveno VI. Expanding consensus in portal hypertension: Report of the Baveno VI consensus workshop: Stratifying risk and individualizing care for portal hypertension. *Journal of Hepatology*. 2015;**63**:743-752
- [37] Noronha Ferreira C, Seijo S, Plessier A, et al. Natural history and management of esophagogastric varices in chronic noncirrhotic, nontumoral portal vein thrombosis. *Hepatology*. 2016;**63**:1640-1650
- [38] Bach AM, Hann LE, Brown KT, et al. Portal vein evaluation with US: Comparison to angiography combined with CT arterial portography. *Radiology*. 1996;**201**:149-154
- [39] Chawla Y, Kumar S. Portal venous flow in Budd–Chiari syndrome. *Indian Journal of Gastroenterology: Official Journal of the Indian Society of Gastroenterology*. 1998;**17**:37
- [40] Danila M, Sporea I, Popescu A, et al. Portal vein thrombosis in liver cirrhosis—the added value of contrast enhanced ultrasonography. *Journal of Medical Ultrasound*. 2016;**18**:218-233
- [41] Sabba C, Merkel C, Zoli M, et al. Interobserver and interequipment variability of echo-Doppler examination of the portal vein: Effect of a cooperative training program. *Hepatology*. 1995;**21**:428-433
- [42] Plessier A, Darwish-Murad S, Hernandez-Guerra M, et al. Acute portal vein thrombosis unrelated to cirrhosis: A prospective multicenter follow-up study. *Hepatology*. 2010;**51**:210-218

- [43] Yerdel MA, Gunson B, Mirza D, et al. Portal vein thrombosis in adults undergoing liver transplantation: Risk factors, screening, management, and outcome. *Transplantation*. 2000;**69**:1873-1881
- [44] Sarin SK, Philips CA, Kamath PS, et al. Toward a comprehensive new classification of portal vein thrombosis in patients with cirrhosis. *Gastroenterology*. 2016;**151**:574-577, e3
- [45] Piscaglia F, Gianstefani A, Ravaioli M, et al. Criteria for diagnosing benign portal vein thrombosis in the assessment of patients with cirrhosis and hepatocellular carcinoma for liver transplantation. *Liver Transplantation*. 2010;**16**:658-667
- [46] Francoz C, Belghiti J, Vilgrain V, et al. Splanchnic vein thrombosis in candidates for liver transplantation: Usefulness of screening and anticoagulation. *Gut*. 2005;**54**:691-697
- [47] Senzolo M, Sartori M, Rossetto V, et al. Prospective evaluation of anticoagulation and transjugular intrahepatic portosystemic shunt for the management of portal vein thrombosis in cirrhosis. *Liver International*. 2012;**32**:919-927
- [48] Delgado MG, Seijo S, Yepes I, et al. Efficacy and safety of anticoagulation on patients with cirrhosis and portal vein thrombosis. *Clinical Gastroenterology and Hepatology*. 2012;**10**:776-783
- [49] Huard G, Bilodeau M. Management of anticoagulation for portal vein thrombosis in individuals with cirrhosis: A systematic review. *International Journal of Hepatology*. 2012;**2012**:672986
- [50] Amitrano L, Guardascione MA, Menchise A, et al. Safety and efficacy of anticoagulation therapy with low molecular weight heparin for portal vein thrombosis in patients with liver cirrhosis. *Journal of Clinical Gastroenterology*. 2010;**44**:448-451
- [51] Girleanu I, Stanciu C, Cojocariu C, et al. Natural course of nonmalignant partial portal vein thrombosis in cirrhotic patients. *Saudi Journal of Gastroenterology*. 2014;**20**: 288-292
- [52] Englesbe MJ, Kubus J, Muhammad W, et al. Portal vein thrombosis and survival in patients with cirrhosis. *Liver Transplantation*. 2010;**16**:83-90
- [53] Doenecke A, Tsui TY, Zuelke C, et al. Pre-existent portal vein thrombosis in liver transplantation: Influence of preoperative disease severity. *Clinical Transplantation*. 2010;**24**:48-55
- [54] Lisman T, Kamphuisen PW, Northup PG, Porte RJ. Established and new-generation antithrombotic drugs in patients with cirrhosis –possibilities and caveats. *Journal of Hepatology*. 2013;**59**:358-366
- [55] Valla DC. Thrombosis and anticoagulation in liver disease. *Hepatology*. 2008;**47**:1384-1393
- [56] Han G, Qi X, He C, et al. Transjugular intrahepatic portosystemic shunt for portal vein thrombosis with symptomatic portal hypertension in liver cirrhosis. *Journal of Hepatology*. 2011;**54**:78-88



- [57] Perarnau JM, Bajou A, D'Alteroche L, et al. Feasibility and long term evolution of TIPS in cirrhotic patients with portal thrombosis. *European Journal of Gastroenterology & Hepatology*. 2010;**22**:1093-1098
- [58] Senzolo M, Burra P, Patch D, Burroughs AK. Tips for portal vein thrombosis in cirrhosis: Not only unblocking a pipe. *Journal of Hepatology*. 2011;**55**:945-946
- [59] Senzolo M, Tibbals J, Cholongitas E, et al. Transjugular intrahepatic portosystemic shunt for portal vein thrombosis with and without cavernous transformation. *Alimentary Pharmacology & Therapeutics*. 2006;**23**:767-775
- [60] De SA, Moscatelli R, Catalano C, et al. Systemic thrombolysis of portal vein thrombosis in cirrhotic patients: A pilot study. *Digestive and Liver Disease*. 2010;**42**:451-455
- [61] Llado L, Fabregat J, Castellote J, et al. Management of portal vein thrombosis in liver transplantation: Influence on morbidity and mortality. *Clin Transplantation*. 2007;**21**:716-721
- [62] Gimeno FA, Calvo J, Loinaz C, et al. Comparative analysis of the results of orthotopic liver transplantation in patients with and without portal vein thrombosis. *Transplantation Proceedings*. 2005;**37**:3899-3903
- [63] Rodriguez-Castro KI, Porte RJ, Nadal E, et al. Management of nonneoplastic portal vein thrombosis in the setting of liver transplantation: A systematic review. *Transplantation*. 2012;**94**:1145-1153
- [64] Ceulemans B, Aerts R, Monbaliu D, et al. Liver transplantation using cavoportal transposition: An effective treatment in patients with complete splanchnic venous thrombosis. *Transplantation Proceedings*. 2005;**37**:1112
- [65] Ponziani FR, Zocco MA, Campanale C, et al. Portal vein thrombosis: Insight into pathophysiology, diagnosis, and treatment. *World Journal of Gastroenterology*. 2010;**16**:143-155
- [66] Shaw Jr BW, Iwatsuki S, Bron K, Starzl TE. Portal vein grafts in hepatic transplantation. *Surgery, Gynecology & Obstetrics*. 1985;**161**:66-68