

We are IntechOpen, the world's leading publisher of Open Access books Built by scientists, for scientists

6,900

Open access books available

186,000

International authors and editors

200M

Downloads

Our authors are among the

154

Countries delivered to

TOP 1%

most cited scientists

12.2%

Contributors from top 500 universities



WEB OF SCIENCE™

Selection of our books indexed in the Book Citation Index
in Web of Science™ Core Collection (BKCI)

Interested in publishing with us?
Contact book.department@intechopen.com

Numbers displayed above are based on latest data collected.
For more information visit www.intechopen.com



Ocular Manifestations of Behçet's Disease

Esra Sahli and Ozlem Gurbuz-Koz

Additional information is available at the end of the chapter

<http://dx.doi.org/10.5772/intechopen.69049>

Abstract

Behçet's disease (BD) is a multisystemic autoimmune inflammatory disorder characterized by oral aphthous lesions, genital ulcerations, iridocyclitis with hypopyon, and skin lesions. While ocular manifestations occur in nearly 50% of the patients with Behçet's disease, ocular involvement is the initial manifestation in only less than 20% of the patients. Ocular Behçet's disease clinically presents iridocyclitis with or without hypopyon, vitritis, retinitis, occlusive retinal vasculitis, and cystoid macular edema. However, anterior uveitis is usually the only initial ocular manifestation; the most common form is panuveitis. The usual course of the disease is characterized by recurrent inflammatory periods. Recurrent inflammatory attacks may result in irreversible damage and significant visual loss. Early and effective treatment is required to prevent ocular morbidity. Recent developments in the treatment of ocular Behçet's disease like biological agents are promising with a rapid effect and high remission rates.

Keywords: behçet's disease, iridocyclitis, retinal vasculitis, retinitis, immunosuppressants, biological agents

1. Introduction

Behçet's disease (BD) is a multisystemic autoimmune inflammatory disorder characterized by oral aphthous lesions, genital ulcerations, iridocyclitis with hypopyon, and skin lesions. It often involves the central nervous system, cardiovascular system, gastrointestinal system, and joints as well. An enhanced or dysregulated immune response triggered by environmental factors in immunogenetically susceptible individuals plays a major role in etiopathogenesis of the disease [1].

The prevalence of BD is higher in Eastern Mediterranean and Eastern Asia countries than in Northern European countries and the USA. The highest disease incidence has been reported

in Turkey as 20–421 per 100,000 people [2]. The prevalence rate in Japan is reported as 1/10,000 [3]. Studies from Iran, Greece, and the USA indicate 16–100 per 100,000 people, 6 per 100,000 people, and 4 per 1,000,000 people, respectively [4–6].

BD is an obliterative and necrotizing systemic vasculitis that involves different organ systems. Occlusive vasculitis is a characteristic of BD that is not typically seen in other forms of uveitis. It affects both arteries and veins. Its histopathological appearance is characterized by non-granulomatous inflammation with perivascular T lymphocytes and neutrophil infiltration and increased expression of adhesion molecules. Local expression of proinflammatory cytokines including tumor necrosis factor- α (TNF- α), interleukin-1-beta (IL-1 β), and interleukin-8 (IL-8); increased circulating immune complexes; endothelial dysfunction; and abnormal coagulation system play role in the pathogenesis of BD-associated vasculitis [7].

Diagnosing BD can be challenging since there are no specific laboratory tests or pathognomonic findings. The diagnosis relies mainly on clinical findings. Positive skin pathergy test and positive of HLA-B51 values can help verify the diagnosis, but these are not used exclusively for BD diagnosis. The most commonly used diagnostic criterion is defined by the International Study Group for BD. Recurrent oral ulcer that occurs at least three times a year, is mandatory for the diagnosis. In addition, two of the four major symptoms, including eye lesion, recurrent genital ulcers, skin lesions, and a positive pathergy test, are sufficient for the diagnosis of BD [8]. According to Behçet's Disease Research Committee of Japan, there are four major and five minor criteria. The major criteria include recurrent aphthous ulcers, skin findings (similar of those erythema nodosum or acne and a pathergy test), genital ulcers, and ocular involvement. The minor criteria include arthritis, intestinal ulcers, epididymitis, vascular disease, and neuropsychiatric involvement. This diagnostic system requires only one major symptom in addition to typical ocular symptoms for the diagnosis of ocular BD [9, 10].

2. Ocular involvements of Behçet's disease

BD has wide range of clinical manifestations. While ocular manifestations occur in nearly 50% of the patients with BD (50–70% of affected men and 20–30% of affected women), ocular involvement is the initial manifestation in less than 20% of the patients [11]. BD has been reported as the most common diagnosis (32.2%) among patients with uveitis in Turkey and the third most common cause of noninfectious uveitis, following sarcoidosis and Vogt-Koyanagi-Harada disease, in Japan [12, 13].

Ocular findings generally occur within the first 2–4 years of the disease. In 80% of the patients, the manifestations are bilateral [14]. According to a study with a large patient group, the ratio of bilaterality was found 80% among men and 64% among women in the beginning of the disease. However, at the end of a 20-year follow-up, the ratio increased to 87% among men and 71% among women [15].

The gender seems to affect the clinical manifestations and prognosis. The disease usually has a more severe course in men with a younger age of onset. Isolated anterior uveitis has a higher

frequency in females than in males. Males have greater visual morbidity because of the higher incidence of vitritis, retinitis, retinal vasculitis (RV), and retinal hemorrhages than females. The course of BD may also vary due to geographical ethnic factors and individual characteristics [14]. Although several familial cases and a pair of monozygotic twins correspondent for BD have been reported, no consistent inheritance pattern has been confirmed [16].

The most common form of BD is panuveitis. The usual course of the disease is characterized by recurrent inflammatory periods. Early recognition of ocular involvement is important, as uveitis management differs from extraocular involvements with high ocular morbidity. Despite modern treatment modalities, the disease still carries poor visual prognosis.

The ocular symptoms are usually first manifested during the third or fourth decade of life. The primary manifestation can be unilateral in 50–87% of patients and occurs usually as an anterior uveitis. Later in nearly two-thirds of the cases, it changes to bilateral panuveitis with a chronic relapsing course. Panuveitis is seen significantly more often in men than in women [3, 16, 17].

The diagnosis of ocular BD is done based on clinical findings obtained from slit-lamp biomicroscopy and ophthalmoscopy. In addition, fluorescein angiography (FA) and indocyanine green angiography (ICGA) examinations are seen to be helpful in the diagnosis [17].

Ocular BD clinically presents iridocyclitis with or without hypopyon, vitritis, retinitis, occlusive RV, and cystoid macular edema (CME). Band keratopathy, glaucoma, vitreoretinal hemorrhage, posterior vitreous detachment, macular degeneration, epiretinal membrane, vein occlusion, and phthisis of the eye may also be observed as complications of ocular BD [18].

During acute inflammation, diffuse infiltration of neutrophils and lymphocytes in the iris, ciliary body, and choroid is seen. After recurrences, increased collagen can lead to iris atrophy, posterior synechiae, cyclitic membrane formation, and the thickening of the choroid. In the retina, infiltration of leukocytes and plasma cells in and around blood vessels and into retinal tissue appears, histopathologically. Veins are more affected than arteries. During the inflammation, retinal vascular endothelial cells become swollen; neutrophil migration and thrombus formation are also seen. In more advance cases, fibrosis of blood vessels and complete vascular obliteration may be present. Rods and cones get destroyed. Fibrosis of the inner nuclear layer appears; however, the destruction of retinal pigment epithelium is minimal. The optic nerve vessels can be affected and can result in optic neuritis, ischemia, and finally optic atrophy [16].

In addition, recurrences are very common, and the recurrent attacks of ocular inflammation may result in severe ocular damage. BD may produce permanent vision loss in up to 20% of affected individuals. The poor long-term visual outcome is usually related to glaucoma, cataract, and RV [15].

Uveitis in BD may involve the anterior and/or the posterior segment of the eye. The location of the inflammation is important both therapeutically and prognostically. If the lesions affect the posterior segment, vision loss is usually permanent and significant. The most common presentation of BD is bilateral non-granulomatous panuveitis with RV.

3. Anterior segment involvement

Anterior uveitis is usually the only initial ocular manifestation in patients with BD, and it can occur as an isolated finding in about 10% of the patients. This presentation is more common in females. Anterior uveitis, also known as iridocyclitis, is limited to the iris and the vitreous. The inflammatory response in the anterior chamber is of non-granulomatous nature. Although ocular BD is characterized by explosive acute hypopyon uveitis, a more common presentation is iridocyclitis without hypopyon, which is seen in two-thirds of the cases [17, 19].

Patients' complaints are often redness, pain in the globe, photophobia, tearing, and blurred vision. Slit-lamp biomicroscopic examination reveals conjunctival injection, perilimbal flush, cells and flare in the anterior chamber, keratic precipitates, and hypopyon. Disruption of the blood-aqueous barrier results in aqueous flare and cells, which are the two inflammatory parameters of anterior chamber inflammation. Cells in the aqueous humor can be detected as particles identified by backscattering light from the incoming beam with slit-lamp biomicroscopy. Grading systems have been developed to standardize quantification of cells and flare in the anterior chamber, based on slit-lamp examination. Increased protein content of the aqueous humor produces flare. It can be measured by laser flare photometry, which is an objective quantitative method. Yalcindag et al. reported that flare levels in the aqueous humor were correlated with fluorescein leakage on FA and suggested that higher flare values were associated with poor vision [20]. Keratic precipitate is an inflammatory cellular deposit seen usually on the lower part of the corneal endothelium. These precipitates are composed of the aggregation of polymorphonuclear cells and lymphocytes. They are fine, irregular, and almost always nonpigmented. Hypopyon is formed by the accumulation of cells and fibrin in the lower part of the anterior chamber of the eye. It is seen as a whitish or grayish fluid (**Figure 1**). Hypopyon includes mostly polymorphonuclear cells. Hypopyon typically freely moves and slowly shifts with gravity according to head position within minutes as opposed to the sticky hypopyon of HLA-B27-associated uveitis. The presence of hypopyon without ciliary injection is called

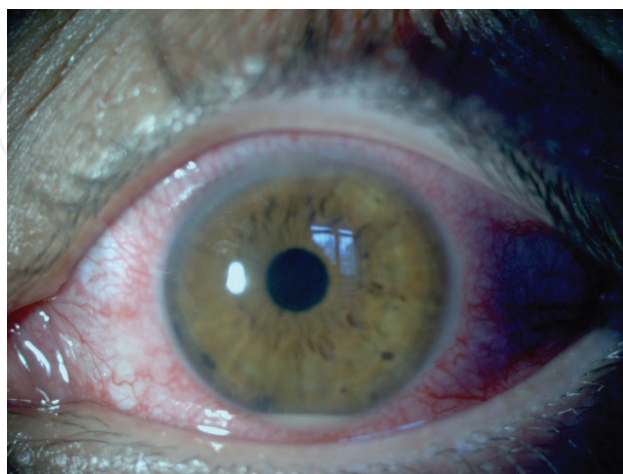


Figure 1. Hypopyon in a patient with Behçet's disease.

“cold hypopyon.” A small layer of leucocytes can be observed in the anterior chamber angle by gonioscopy and is called angle hypopyon. The eye can be seen white despite inflammatory reaction in the anterior chamber. The hypopyon can be overlooked during the eye examination because this finding is transient. At the same time, hypopyon nowadays is less commonly seen because of earlier and more aggressive treatments. In the convalescent period of uveitis with hypopyon, slightly thickened pigment particles presenting as multiple dark brown spots can be seen in the inferior angle [17, 21].

The anterior uveitis appears very rapidly; its nature is explosive. It may get resolved spontaneously within 2–3 weeks even if it is not treated. Almost all nonpermanent inflammatory findings may disappear after each attack. Recurrent inflammatory attacks can result in structural changes of the anterior segment of the eye including posterior synechiae, iris atrophy, and peripheral anterior synechiae. Posterior synechiae are the adhesion between the posterior iris and the anterior lens surface. Pigment epithelial cells can be seen on the lens surface when the pupil is dilated (**Figure 2**). Mydriatic agents and topical corticosteroids are useful in breaking and preventing the formation of posterior synechiae. Posterior synechiae may be segmental or annular. Seclasio pupillae, 360° adhesions of pupillary margin to anterior capsule of the lens, and oclusio pupillae, the presence of a fibrovascular membrane across the pupil, may also be seen (**Figure 3**). Peripheral anterior synechiae, adhesion between the anterior iris and cornea, may be seen in result of the dense inflammation. Peripheral anterior synechiae and iris bombe formation associated with seclusion of pupilla may cause secondary glaucoma. Neovascularization of the iris may be seen secondary to occlusive RV.

The other anterior segment changes include episcleritis, scleritis, conjunctivitis, conjunctival ulcerations, and subconjunctival hemorrhages, keratitis, and rarely extraocular muscle paralysis.

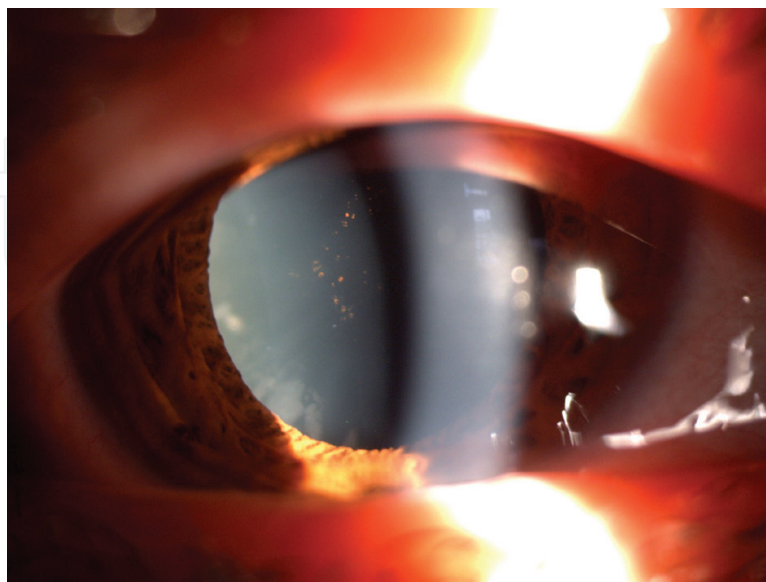


Figure 2. Pigment epithelial cells on the lens surface when pupil is dilated in a patient with Behçet's disease.

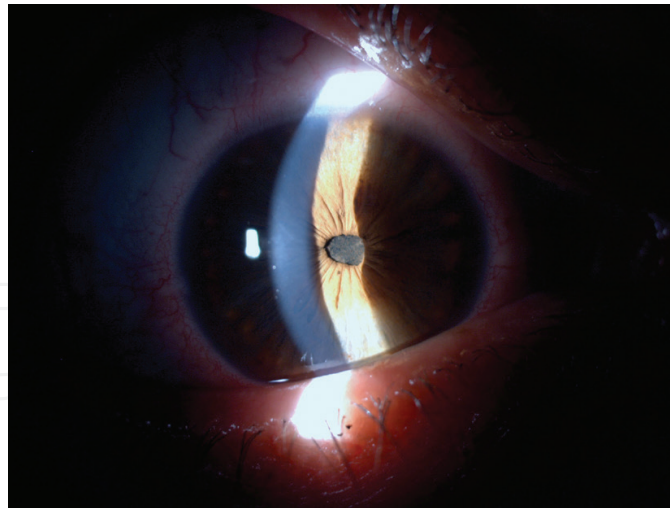


Figure 3. Posterior synechiae formation secondary to anterior uveitis in a patient with Behçet's disease.

4. Posterior segment involvement

The most common posterior segment findings are vitritis and RV. They are found in nearly 90% of Behçet patients with uveitis. However, an isolated vitritis, white cell infiltration of the vitreous body, is not a characteristic of BD. Increased vascular permeability of the retina, choroid, and ciliary body vessels results in cells in the vitreous and vitreous haze. White cell infiltration in the vitreous ranges from variable number of cells suspended in the vitreous fibrils to a dense plasmoid reaction in the acute phase. Vitreous haze is usually a proteinous material. It is important to follow up because it demonstrates the posterior segment activation. Even though the presence of vitreous cells is considered as the evidence of activation, they may also be seen as the persistent opacities in the vitreous cavity. They can be displaced by movements of the head easily and can be evaluated with slit-lamp biomicroscopy. Vitritis may last in a chronic smoldering course. In most cases, posterior vitreous detachment occurs at an early stage of ocular disease (92%) [22].

The essential manifestation of the posterior segment in patients with ocular BD is an occlusive and necrotizing RV. RV is defined as a disruption in the blood-retinal barrier and results in retinal vascular leakage on FA and perivascular infiltrates on dilated fundus examination in addition to the presence of other signs of intraocular inflammation such as cell infiltration into the vitreous, anterior chamber, retina, or choroid [23]. RV occurs as recurrent vaso-occlusive episodes that lasts for weeks. Active periods are then followed by periods of relative quiescence.

In most patients, RV mainly affects the retinal veins, which is pathognomonic for BD. In addition to this, BD is the only systemic vasculitis affecting small- and medium-sized arteries and also veins. Venous and capillary dilatation with engorgement may also be seen (**Figure 4**) [21].

Retinal vasculitis can be concluded as a finding such as an intraretinal hemorrhage or cotton wool exudate. Intraretinal hemorrhage indicates an abnormality of retinal vessel wall. Cotton wool

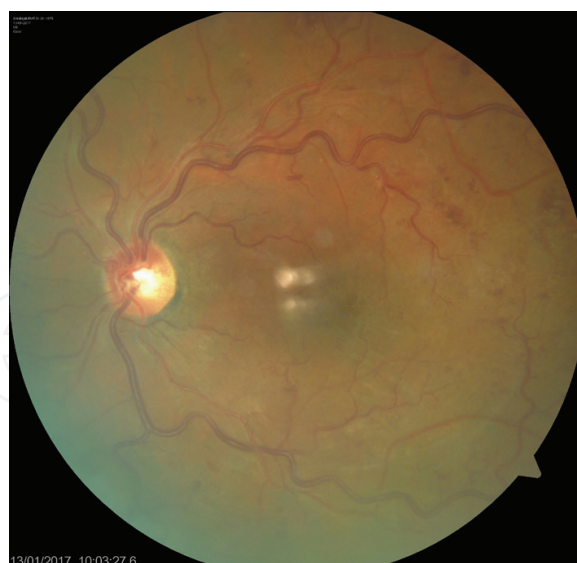


Figure 4. Fundus photograph of a patient with Behçet's disease showing diffuse retinal vasculitis.

exudates indicate local retinal ischemia caused by occlusive vasculitis. In BD with RV, patchy perivascular sheathing and whitish yellow exudates surrounding retinal hemorrhages are often observed. Severe RV can result in ischemic changes due to vascular occlusion. Choroidal vascular involvement also occurs, and choroidal infarcts can also be seen [14, 16, 24].

Based on necrotizing obliterative vasculitis, neovascularization of the optic disc and peripheral retina can cause retinal detachment with or without vitreous hemorrhage. The process could be summarized as follows: vascular occlusion causes retinal hypoxia, which stimulates the neovascularization of the optic disc and elsewhere. Both of them can rupture and cause vitreous hemorrhage. Vitreous hemorrhage may organize with transvitreal membrane formation, which may exert traction on the retina. This traction may lead to rhegmatogenous or combined tractional-rhegmatogenous retinal detachment [1, 15].

Retinitis is the next most common posterior segment manifestation. Retinitis is evidenced by soft infiltrates. These soft exudates resolve spontaneously in a few weeks, but diffuse vitreous opacity may stay for a few months [1].

Inflammatory cell infiltrations that affect the superficial and deep layers of the retina and hemorrhages coexisting with infiltration appear in occasional cases. In the acute disease transient, superficial white infiltrates that heal without scarring may be observed. Exudative retinal detachment may also appear after acute retinitis. Retinal atrophy can occur following the resolution of retinal exudates and hemorrhage [1].

Retinal edema is present in 20–75% of cases especially in the macula. Cystoid or diffuse macular edema caused by vascular leakage is one of the most important findings [15]. Optical coherence tomography (OCT) imaging reveals retinal thickening and is useful for follow-up. Thrombosis of the central retinal vein or its branches may be seen, but they are the less common findings. Occlusion of the central retinal artery is extremely rare. Bilateral retinal vein thromboses and bilateral posterior ischemic optic neuropathy have been reported [25, 26].

The optic nerve is affected in at least one-fourth of patients with BD. This condition may either present as an isolated papillitis or as a finding of sagittal sinus thrombosis due to neurological involvement of BD. Papillitis with optic disc hyperemia and blurring of the margins is the most common involvement of the optic nerve. Optic disc edema may occur as a result of the microvasculitis of the arterioles supplying the optic disc. While it is not seen very often, it can lead to progressive optic atrophy [15].

End-stage disease is characterized by optic atrophy, gliosis and sheathing, and attenuation of retinal vessels and ghost vessels. Destructive and recurrent attacks of uveitis especially with posterior segment involvement may result in permanent damage in the sensory retina, causing irreversible loss of vision.

5. Complementary imaging modalities and laboratory tests

Fluorescein angiography is essential and gold standard in evaluating the activity and the extent of the vasculitis in Behçet patients. FA demonstrates fluorescein staining on the vessel wall and/or fluorescein leakage from the vessel, which shows increased vascular permeability caused by the breakdown of the inner blood-retinal barrier, in RV.

If the posterior segment of the eye is involved, FA may reveal macular hyperfluorescence or perivascular staining with dye leakage from the dilated retinal capillaries even before retinal perivasculitis can be detected ophthalmoscopically [17]. FA provides a significant contribution in detecting vascular leakage, demonstrating the presence of macular edema, capillary non-perfusion, occlusion of the retinal vessels, collateral formation, and neovascularization in BD (**Figure 5**). Atmaca reported that FA revealed fluorescein leakage from retinal vessels in 6.3% of Behçet patients who had no vision loss or no abnormal findings on fundus examination, in 1989 [27].

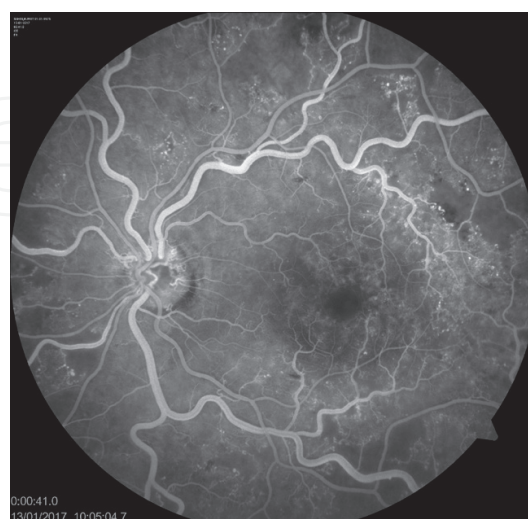


Figure 5. Fluorescein angiography of a patient with Behçet's disease revealing diffuse fluorescein leakage from retinal vessels and cystoid macular edema.

“Fern-like fluorescein leakage” due to inflammation at retinal capillaries is clearly demonstrated on the mid-phase FA, and it is a characteristic finding and the most frequent fluorescein angiographic appearance of BD (**Figure 6**). Fluorescein leakage from retinal capillaries is seen not only during the inflammatory period but also during the apparently quiescent periods between attacks. It may be the only sign of persistent inflammation in the posterior segment during clinically inactive periods. These findings have a high diagnostic value in BD [13, 19].

Determination of FA findings is important to evaluate the severity of the disease and the response to the treatment. All classifications were based on the late phase of angiogram. FA findings are classified based on the extent of the vascular leakage as focal and diffuse, according to macular involvement as incomplete perifoveal hyperfluorescence, mild 360° hyperfluorescence, moderate 360° hyperfluorescence (nearly 1 disc diameter across), and severe 360° hyperfluorescence (nearly 1.5 disc diameter across). Corresponding to optic disc hyperfluorescence in the late angiographic phases, the findings can be categorized as none (normal exiting of fluorescein and normal staining of the sclera rim), partial, diffuse without blurring of the disc margin, and diffuse with blurring of the disc margin [28].

Kim et al. investigated whether there is correlation between FA findings and visual acuity (VA) in Behçet patients with RV. Retinal vascular leakage, optic disc hyperfluorescence, and macular leakage were seen to be associated with a decreased VA [29].

Visualization of the peripheral retina by an ultrawide-field retinal imaging system may be useful to diagnose and monitor RV in Behçet patients and in the treatment of the disease. Conventional fundus cameras can capture only 30–60° of the fundus at a time and cannot image the entire retina simultaneously. The ultrawide-field imaging system provides 200° of photographic and angiographic views of the ocular fundus [30]. Improved visualization of the peripheral retina by ultrawide-field imaging has demonstrated that peripheral RV could be detected in 85% of eyes that did not have ophthalmoscopic evidence [31].

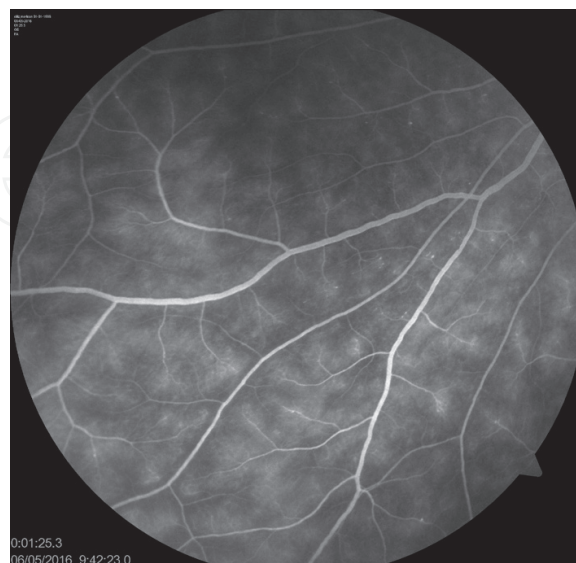


Figure 6. “Fern-like” fluorescein leakage from peripheral retinal vessels on fluorescein angiography.

Choroidal and retinal pigment epithelial changes are rarely seen in ocular BD. The BD patients with choroidal abnormalities could only be evaluated with ICGA and not with fundus examination or FA [32]. In these cases, ICGA may have an advantage over FA in showing lesions, choroidal vessel leakage, irregular filling of the choriocapillaris, and choroidal filling defects. ICGA was demonstrated with no clinically useful information on disease activity and monitoring the disease. ICGA is used to evaluate choroidal involvement in inflammation of the posterior segment [32, 33]. Since the choroidal infarcts are probably more common than they are usually estimated, simultaneous ICGA and FA would be useful for examining choroidal involvement in BD.

OCT provides both high-resolution cross-sectional imaging of the retina and quantitative measurement of the retinal thickness. For the detection and follow-up of macular edema in BD, OCT and FA are both necessary and complementary. The integrity of junctions between inner and outer segments of the photoreceptors (ISOS line) and the cone outer segment tip line (interdigitation zone) are correlated with visual function and prognosis in patients with uveitic macular edema, and these zones are best evaluated by OCT [34, 35].

Transient retinal infiltrates, which are commonly seen during exacerbations of Behçet's uveitis, are indicated as focal retinal thickening; increased hyper-reflectivity with blurring, especially of inner retinal layers; and optical shadowing by spectral-domain OCT. In Behçet's uveitis, retinal infiltrates rapidly resolve without any apparent retinochoroidal scarring. However, inner retinal atrophy is seen in the spectral-domain OCT sections [34].

Recently, the assessment of choroidal thickness has been possible by the enhanced depth imaging (EDI) mode of spectral-domain OCT in patients with Behçet's uveitis. Ishikawa et al. and Kim et al. reported that subfoveal choroidal thickness was significantly higher during an acute attack of Behçet's uveitis than in remission. Their choroid was found thicker than that of healthy control subjects not only during an attack of Behçet's uveitis but also during remission of the disease [36, 37].

Elevated erythrocyte sedimentation rate, positive C-reactive protein, and increased peripheral blood leukocytes, which are nonspecific factors indicative of immune system activation, may be abnormal during the acute phase of BD. The other acute phase reactants such as pro-perdin factor-b and alpha-1-acid glycoprotein may also be elevated [16].

6. Management of ocular Behçet's disease

Behçet's uveitis has a remitting and relapsing course, and recurrent inflammatory attacks may result in irreversible damage and significant visual loss. It is one of the most difficult forms of uveitis to treat. The aim of the treatment should be to obtain a rapid resolution of inflammation, to prevent or at least reduce the frequency of attacks, and to avoid complications. There is no standard treatment protocol. The choice of therapy is based on the severity of the disease. Combination therapy is required in most of the patients. Early and aggressive treatment should be administered whenever following features are present: male sex, young age, characteristic geographical origin, complete BD (the presence of oral and genital ulcer, ocular and skin findings simultaneously or at different times), posterior segment and bilateral

involvement, and central nervous system or vascular involvement [4]. The therapy in BD should be highly effective for preferably manifestations, should effect rapidly, have fewer side effects, and should be as cheap as possible.

6.1. Corticosteroid therapy

Local and systemic steroids especially during attacks are used very commonly. Corticosteroids help suppress the ocular inflammation rapidly but have potential side effects including glaucoma and cataract.

In the treatment of anterior uveitis, topical corticosteroid drops (prednisolone acetate, dexamethasone phosphate) should be used to suppress the inflammatory response. It can be discontinued upon vanishing the anterior chamber cells after nearly 6–8 weeks of application. Relapses and severe exacerbations may develop when dose is lowered. Therefore, stepwise tapering the corticosteroid dose is needed. Corticosteroid-induced ocular hypertension and cataract development are possible risks of the treatment. Topical nonsteroidal anti-inflammatory drugs such as indomethacin, diclofenac, and flurbiprophen could be added to topical corticosteroids to potentiate the corticosteroid activity. Topical mydriatic and cycloplegic agents should be added twice or three times a day (tropicamide 1%, cyclopentolate 1%, and phenylephrine 2.5 and 10%) in order to relieve photophobia, pain, and discomfort and prevent synechiae formation [38, 39].

Patients with severe anterior uveitis unresponsive to topical treatment may benefit from subtenon or subconjunctival injections of depot corticosteroids such as triamcinolone acetonide or methylprednisolone acetate every 2–4 weeks for 4–5 times. Depot steroids ensure long-lasting suppression of the inflammation. However side effects such as conjunctival hemorrhage or scarring, encapsulated cyst, ptosis, and accidental eye perforation may occur. Subconjunctival corticosteroid injection can be administered for treating hypopyon and severe anterior segment inflammation with fibrin clotting [38, 39].

When topical and local administration is not effective, a short course of oral corticosteroids (prednisolone, 1–2 mg/kg/day), colchicine, or methotrexate may be used in addition. High-dose systemic corticosteroids are used for the treatment of severe posterior uveitis and panuveitis attacks. Intravenous pulse methylprednisolone (1 g/day) is usually administered for 3 consecutive days to obtain a rapid anti-inflammatory effect. Then oral prednisone (1–1.5 mg/kg/day) is given in a single morning dose and slowly tapered to a maintenance dose of 7.5 mg/day or less after complete resolution of active inflammation. If exacerbation is encountered under the dose of 0.5 mg/kg/day, steroid may be stopped, and another immunosuppressant agent can be started. Long-term treatment with systemic corticosteroid should not be preferred. Elevation of intraocular pressure (IOP), cataract, cushingoid state, GI ulcers, osteoporosis, diabetes mellitus, and exacerbations of infections are some of the important side effects of systemic corticosteroid treatment [17, 38, 39].

6.2. Immunomodulatory therapy

Behçet patients with acute and severe posterior segment involvement may benefit from systemic corticosteroid treatment in early stages. The prolonged use of systemic corticosteroids

must be avoided, because severe rebound attacks can occur during tapering the dose. Despite the fact that corticosteroids alone have failed to prevent vision loss in patients with BD, their immediate anti-inflammatory effect is useful while waiting for the immunosuppressant agents to effect fully. The corticosteroids should be tapered rapidly within weeks and immunosuppressant agents should start. A single long-term immunosuppressant agent is initially administered as monotherapy for at least 6–12 months. Conventional immunosuppressive agents that have been used for the treatment of BD uveitis with posterior segment involvement include antimetabolites (methotrexate, azathioprine, mycophenolate), calcineurin inhibitors (cyclosporine A, tacrolimus, sirolimus), and alkylating agents (chlorambucil, cyclophosphamide). If the disease does not respond to these drugs, the dose is increased or the drug is changed to another one. The combination of two cytotoxic immunosuppressants (methotrexate, azathioprine, chlorambucil, and cyclophosphamide) can be tried in patients with severe RV [17, 38].

In selected patients, low-dose corticosteroids, at the dose of equal or less than 10 mg/day, may be required chronically in combination with immunosuppressants for controlling uveitis. This combination is beneficial for reducing the adverse effects of either immunosuppressants or corticosteroids.

6.2.1. Azathioprine

Azathioprine is an antimetabolite drug that interferes with purine incorporation into DNA and affects rapidly proliferating cells such as activated lymphocytes [16]. Azathioprine can be administered alone or in combination with corticosteroids and other immunosuppressives at the dose of 2–2.5 mg/kg/day. Important side effects of Azathioprine are fever, reversible bone marrow suppression, hepatotoxicity, hyperuricemia, pancreatitis, and increasing risk of malignancies. Complete blood count (CBC) and liver function tests (LFT) should be performed every 2 weeks for the first month and then once every 3 months [17]. The patients who initially received azathioprine treatment especially within 2 years after disease onset have a better visual prognosis and less risk of new eye disease [40].

6.2.2. Methotrexate

Methotrexate is an antimetabolite drug that prevents the activation of folic acid, necessary for synthesis of DNA. Methotrexate is suggested at the dose of 7.5–20 mg/week perorally. Gastrointestinal upset, bone marrow suppression, hepatorenal toxicity, central nervous system toxicity, sterility, alopecia, and anorexia are potential side effects of methotrexate. CBC and LFT should be ordered every 2 weeks for the first month and then once a month [17].

6.2.3. Mycophenolate mofetil

Mycophenolate mofetil is an antimetabolite drug that blocks DNA synthesis by the inhibition of enzyme inosine monophosphate dehydrogenase. It does not inhibit the early production of cytokines of T-helper-cell clones (Th0 and Th2); it acts synergistically with other immunosuppressive agents [16]. Larkin and Lightman reported successfully treated Behçet patients by adding mycophenolate mofetil to their combination of steroid and cyclosporine [41].

6.2.4. Cyclosporine A

Cyclosporine A is a noncytotoxic immunomodulatory agent, which selectively and reversibly inhibits T-helper-lymphocyte-mediated immune responses. It binds to and inhibits calcineurin by forming cyclosporine-cyclophilin complex. Calcineurin catalyzes reactions necessary for early activation of T cells and production and expression of cytokines such as IL-2 [42]. Cyclosporine A has been shown to reduce frequency and severity of uveitis attacks and is administered at the dose of 3–5 mg/kg/day in two divided doses. It induces rapid suppression of intraocular inflammation. Cyclosporine A is safer than the cytotoxic agents in the management of posterior segment manifestations and inflammatory recurrences, and it is usually combined with systemic corticosteroids [43]. Cyclosporine A is shown to provide rapid improvement in VA and decrease in the frequency and severity of ocular attacks in ocular Behçet patients in three randomized controlled trials [44–46].

After corticosteroids are withdrawn, cyclosporine A is tapered down 10% of dose every month to the minimum effective dose to control the disease. But even at low doses, long-term treatment is limited to the development of side effects, including hypertension, nephrotoxicity, arrhythmia, headache, gum hyperplasia, hirsutism, female reproductive disorder, diabetes, hepatotoxicity, and myelosuppression. Rebound attacks may occur following discontinuation or even during tapering of the dose. Cyclosporine A is demonstrated to be associated with an increased risk of parenchymal neuro-Behçet's disease and is contraindicated in patients with neurological involvement [17, 38].

6.2.5. Tacrolimus (FK-506)

Tacrolimus suppresses CD4⁺ T lymphocytes similar to cyclosporine A. However, it has a better safety profile than cyclosporine. Favorable results in 75% of patients with refractory uveitis, who had been using corticosteroids, colchicine, cyclophosphamide, and cyclosporine, have been reported by the Japanese FK-506 Study Group on Refractory Uveitis [47]. However, the use of tacrolimus on the treatment of ocular BD is very limited.

6.2.6. Chlorambucil

Chlorambucil is a slow-acting alkylating agent. The usual dose of chlorambucil is 0.1 mg/kg/day. Immunosuppressive effect of chlorambucil appears in 1–3 months of therapy [16]. Chlorambucil has been reported to provide even a durable remission after its discontinuation, but its potential serious side effects including an increasing risk of malignancy and azoospermia in men have limited its use in ocular BD. It is suggested only as the last option before the biological agents are available [38].

6.2.7. Cyclophosphamide

Cyclophosphamide is a fast-acting alkylating agent. It can be administered orally or intravenously. The recommended dose of cyclosporine is 1–2 mg/kg/day, which may be increased to 3–4 mg/kg/day for several weeks in selected, severe cases only. For long-term treatment, the dose must be adjusted according to the therapeutic response, renal function, and leukocyte

count. The intravenous administration is indicated in cases like patients with occlusive RV where a fast onset of therapeutic effect is important to preserve VA. A bolus of 15–20 mg/kg is given every 3–4 weeks [48].

It has been reported that cyclophosphamide showed favorable results in controlling uveitis, preventing ocular attacks, and maintaining a good VA for a long time in patients with BD. There are also reports demonstrating that cyclophosphamide therapy is superior to steroids and cyclosporine in the management of ocular BD [43, 48, 49].

6.3. Biological agents

Severe RV secondary to BD is often treated with monoclonal antibody against TNF- α or IFN- α in some centers. Some authors prefer to use biological agents alone because of less risk of side effects and infection and less cost, but usually the authors add anti-TNF therapy to antimetabolites and then consider discontinuation of the antimetabolite therapy gradually in a period of 6–12 months, if complete control of ocular inflammation is achieved.

6.3.1. Antitumor necrosis factor agents

Several studies suggest a central pathogenic role of TNF- α in the pathogenesis of BD uveitis. TNF- α is produced by mononuclear cells in the peripheral blood as part of the inflammatory cascade in BD. Levels of TNF- α and soluble TNF receptors are elevated in serum and aqueous humor in patients with BD [50–52].

Currently, available anti-TNF- α agents include etanercept (a recombinant fusion protein, combining 2 human p75 TNF- α receptors linked to the Fc domain of human IgG1), infliximab (a mouse-human chimeric monoclonal IgG1 anti-TNF- α antibody), and adalimumab (a fully humanized monoclonal IgG1 anti-TNF- α antibody). Although it is useful in the management of many rheumatologic diseases, etanercept does not seem to be an effective treatment for ocular BD [16].

Refractory ocular involvement is the main indication for anti-TNF treatment in BD; the beneficial effects of these agents have been reported in extraocular manifestations such as gastrointestinal, vascular, and neurological manifestations of BD as well [53, 54].

6.3.1.1. Infliximab

Infliximab (Remicade, Bausch & Lomb, Rochester, New York, USA) is a chimeric monoclonal antibody directed against TNF- α . It neutralizes membrane-bound TNF- α and soluble TNF- α , suppresses the production of TNF- α by macrophages and lymphocytes, and induces T_{reg} cells that acquire suppressive function in the periphery. It is administered as intravenous infusions, at the dose of 5 mg/kg (3–10 mg/kg) at weeks 0, 2, and 6 and then every 8 weeks.

Infliximab is used in refractory sight-threatening cases. Regarding the safety profile, infliximab therapy is well tolerated with few adverse events including opportunistic infections, lupus-like reactions, multiple sclerosis, dyspnea, and hypotension and increased risk of malignancy.

Infliximab has been found to be efficient and well tolerated in ocular BD. Patients with two or more attacks of active posterior or panuveitis in a year and patients with chronic CME are likely to benefit biological agents. It is demonstrated that significant decrease in inflammation, improved VA, reduced ocular complications, and the number of relapses were observed in infliximab compared with corticosteroid and immunosuppressive therapy [55–57].

Summarizing recent reports evaluating the effect of repetitive infliximab therapy in BD, clinical responses to the therapy were achieved in 90, 89, 100, and 91% of patients with resistant mucocutaneous, ocular, gastrointestinal, and central nervous system involvement, respectively [58].

6.3.1.2. Adalimumab

Adalimumab (Humira, Abbvie Inc., North Chicago, IL, USA) is a fully recombinant human immunoglobulin G1 monoclonal antibody that specifically binds to membrane and soluble human TNF- α with high affinity and inhibits its binding to TNF receptors. Adalimumab is suggested to be administered at a dose of 40 mg/week, subcutaneously. In patients with sight-threatening Behçet's uveitis who were switched from infliximab to adalimumab, improvement in VA, decreasing in recurrences, and even complete resolution of inflammation have been demonstrated [59–61].

6.3.1.3. Golimumab

Another TNF- α inhibitor, golimumab, is a fully human monoclonal antibody with reduced immunogenicity. It has an advantage of longer half-life that allows monthly subcutaneous injections. Few data are available evaluating the efficacy of golimumab in BD uveitis [62].

6.3.2. Interferon-alpha

Interferon-alpha (IFN- α) is a natural cytokine produced by plasmacytoid dendritic cells. It induces T helper type 1 cells, T cytotoxic cells, and natural killer cells and increases the production of anti-IL-1 receptor antagonist. Interferons can influence both innate and adaptive immune responses [16, 38]. It is generally administered subcutaneously with a dose 3–6 million IU, most often three times weekly. IFN- α should not be used in pregnant patients. Immunosuppressive drugs should be stopped completely before the initiation of IFN- α . Systemic corticosteroids should be tapered to a dose of 10 mg prednisolone equivalent per day as soon as possible because of the antagonistic effect of corticosteroids [63, 64]. Adverse effects of IFN- α including flu-like reactions (90%), fever, mild leucopenia (30%), alopecia (10%), depression (8%), and thyroiditis are common. Gastrointestinal disturbances, increase of liver enzymes, transient paresthesia, and epilepsy may also be seen [64–66].

IFN- α is recommended for the treatment of severe eye involvement of BD by European League against Rheumatism (EULAR) in the light of several uncontrolled studies demonstrating a fast onset of action and high remission rates. The remission may persist after withdrawal of the agent. IFN- α has been included in the EULAR recommendation equal to TNF- α blockers [67]. It works fast enough to be used in the acute phase of BD with panuveitis and/or RV

unresponsive to at least one immunosuppressive drug. A quick response within 2–4 weeks, complete or partial remission of uveitis, is achieved in almost all patients with BD [64, 68–70].

IFN- α has been shown to improve VA, resolve vitritis, and control RV and CME in most cases with BD [66, 68–70]. A reperfusion of occluded retinal vessels and complete regression of retinal neovascularization has been demonstrated with IFN- α . These effects may prevent the vision loss because occlusive vasculopathy develops despite the use of immunosuppressants [71, 72].

It is suggested that long-term remission seems to be associated with higher doses of IFN- α , but not with longer treatment durations. But IFN- α treatment with high initial doses, such as 3–6 million IU per day, may cause more side effects such as depression [64].

6.3.3. Interleukin-1 inhibition

IL-1 β is a potent proinflammatory cytokine that is involved in the early response of the immune system in conditions of infection and tissue injury. In autoinflammatory disorders, IL-1 blockade results in a rapid and continuous reduction of disease manifestations. Serum levels of IL-1 β and IL-1 receptor antagonist were found to be significantly higher in Behçet patients [38, 73, 74].

The three anti-IL-1 agents that have been used in BD are IL-1 receptor antagonist anakinra, anti-IL-1 β monoclonal antibody canakinumab, and recombinant humanized anti-IL-1 β gevokizumab. A retrospective multicenter study reported the efficacy and safety of anakinra and canakinumab in BD. Anakinra and canakinumab were well tolerated with no serious adverse effects except injection site reactions caused by anakinra. These agents should be interpreted with caution because of unavailability of controlled study [75].

IL-1 inhibition is a promising target in managing BD. The pathogenic, clinical, and therapeutic data supporting the use of IL-1 inhibitors in BD has been reviewed very recently. Anti-IL-1 therapy might also be a safer option than anti-TNF- α treatment because of lower risk of opportunistic infections such as tuberculosis [76, 77].

6.4. Intravitreal therapies

Intravitreal injections have advantage of avoiding systemic adverse events and disadvantages of decreased risk associated with intraocular administration and the absence of systemic benefits in patients with extraocular manifestations. When ocular inflammation is unilateral or asymmetric or when systemic administration is less desirable like during pregnancy, intravitreal injections may be preferable [39].

6.4.1. Intravitreal triamcinolone acetonide

Intravitreal triamcinolone acetonide (IVTA) has been administered in Behçet patients with CME, sight-threatening uveitis, or resistant posterior uveitis. Anatomical improvement and increase in VA have been demonstrated. Intravitreal treatment has been enabled tapering the dose of systemic medications. Triamcinolone acetonide is administered 4 mg (0.1 ml) intravitreally. Intravitreal triamcinolone is an effective, short-term therapeutic option. Repeated injections are usually needed. IVTA has no significant systemic side effects, but elevation of IOP and cataract progression is not rare. These side effects are limiting its efficacy and repeatability [78–82].

6.4.2. Intravitreal dexamethasone implant

Intravitreal dexamethasone implant (Ozurdex, Allergan Inc., Irvine, California, USA) has been shown to be effective in controlling intraocular inflammation and achieving reduction of central macular thickness in noninfectious intermediate and posterior uveitis in several studies. Therefore, the number of administration required in patients with uveitis is still controversial [83–85].

It was demonstrated that intravitreal dexamethasone implant has a side effect profile which include cataract formation with an incidence of 15% and IOP elevation with an incidence of 23% in patients with noninfectious uveitis [83].

6.4.3. Intravitreal fluocinolone acetonide implant

A long-term slow-release intravitreal fluocinolone acetonide implant (Retisert, Bausch & Lomb, Rochester, New York, USA) has been used in uveitis, and its efficacy and safety have been assessed by multicenter randomized clinical studies. Retisert is implanted surgically; it is placed through a pars plana incision and sutured to the sclera. It releases 0.59 mg of fluocinolone acetonide at a constant rate during 3 years [86, 87].

In a multicenter trial that compared fluocinolone acetonide implant with aggressive oral systemic therapy in patients with intermediate and posterior panuveitis, no significant difference between groups was found in VA, but the implant was found better and faster in controlling inflammation [88]. Another multicenter randomized study confirmed the superiority of the implant to control intraocular inflammation over standard systemic treatment in resistant noninfectious posterior uveitis.

6.4.4. Intravitreal antitumor necrosis factor

Intravitreal infliximab in the dose of 1–1.5 mg/0.05 ml and frequency of three times at 6-week intervals has been found to be effective and well tolerated. In the studies investigating the efficacy of intravitreal infliximab administration in patients with chronic noninfectious uveitis, improvement in vision, reduction in central foveal thickness, and reduction in inflammation have been demonstrated. Some cases have been reported such as vitreous opacifications and newly onset of severe panuveitis as adverse events after intravitreal infliximab. Infliximab has been suggested to be a promising agent for refractory eye disease in combination with other immunosuppressants. It is important to be cautious for reactivation of tuberculosis [89–94].

6.4.5. Intravitreal anti-VEGF agents

There are several studies that compared the use of intravitreal bevacizumab (IVB) with IVTA in the literature. IVTA was found superior to IVB in visual improvement and decreasing macular thickness in refractory uveitic CME [95, 96]. Conversely, Bae et al. concluded that IVB is a well-tolerated and effective supplementary therapy for persistent uveitic CME, especially in Behçet patients [97].

7. Prognosis and complications

Despite the use of steroids, immunomodulatory and biological agents, some patients may have poor final VA. Twenty-five percent to fifty percent of the patients have best corrected VA less than 20/200 after 5 years [98]. Aqueous protein and cells in anterior chamber, posterior synechiae formation, hypopyon, cataract formation, vitreous cells and exudates, posterior vitreous detachment, and CME may cause transient decrease in VA. Optic atrophy and resistant uveitic glaucoma may result in permanent visual loss at end-stage disease.

Attacks of RV, retinitis, retinal neovascularization, and vitritis lead to vitreous hemorrhage and retinal atrophy. In advance cases, fibrotic, attenuated retinal arterioles; narrowed and occluded “silver wired” vessels; alterations of retinal pigment epithelium; chorioretinal scars; and optic atrophy may be seen.

Inflammation and treatment modalities that are used in BD may cause complications. Complicated cataract and secondary glaucoma are usually associated with inflammation and steroid use. Repeated intraocular inflammation can lead to secondary glaucoma. Both open-angle and angle-closure glaucoma or even pupillary block may be seen. Retinal ischemia can cause neovascular glaucoma. Neovascular glaucoma appears in nearly 6% of patients with BD. Ciliary body involvement can cause a decrease in intraocular pressure, and finally phthisis bulbi may occur [15].

Vitreous hemorrhages are seen frequently in Behçet patients with severe retinal involvement. It can lead to organization with membrane formation, causing retinal holes and subsequent retinal detachment. Phthisis bulbi may finally occur. If the vitreous hemorrhage does not resolve spontaneously, it may be treated with pars plana vitrectomy.

Epiretinal membrane, membrane-shaped fibrosis especially in the macular region, is caused by posterior segment inflammation. Inflammation condensed over the macula and fibrous band between the posterior vitreous and retina result in macular hole formation. In the patients with epiretinal membrane, if the vision is seriously affected, the membrane may be removed surgically [16].

Recent advances in ophthalmic imaging methods have allowed to a better definition of visual prognosis in ocular BD. Identification of the high-risk group and the use of effective biologic agents as first line treatment will improve the prognosis in this potentially blinding disease.

Author details

Esra Sahli* and Ozlem Gurbuz-Koz

*Address all correspondence to: esracansizoglu@gmail.com

Ankara Numune Education and Research Hospital, Ankara, Turkey

References

- [1] Ohno S, Namba K, Takemoto Y. Behçet's disease. In: Zierhut M, Pavesio C, Ohno S, Orefice F, Rao NA, editors. *Intraocular Inflammation*. 1st ed. Germany: Springer-Verlag Berlin Heidelberg; 2016. pp. 785-801. DOI: 10.1007/978-3-540-75387-2.ch.66.
- [2] Yazıcı Y, Yurdakul S, Yazıcı H. Behçet's syndrome. *Current Rheumatology Reports*. 2010;**12**:429-435. DOI: 10.1007/s11926-010-0132-z
- [3] Mishima S, Masuda K, Izawa Y, et al. Behçet's disease in Japan: Ophthalmological aspect. *Transactions of the American Ophthalmological Society Journal*. 1979;**77**:225-279
- [4] Davatchi F, Shahram F, Akbarian M, et al. The prevalence of Behçet's disease in Iran. In: Nasution AR, Darmawan J, Isbagio H, editors. *Proceedings of the 7th APLAR Congress of Rheumatology*. Japan KK: Churchill Livingstone; 1992. pp. 95-98
- [5] Palimeris G, Papakonstantinou P, Mantas M. The Adamantiades-Behçet's syndrome in Greece. In: Saari KM, editor. *Uveitis Update*. Amsterdam: Excerpta Medica; 1984. p. 321
- [6] O'Duffy JD. Behçet's disease. In: Kelly WN, Harris ED, Ruddy S, Sledge CB, editors. *Textbook of Rheumatology*. Philadelphia: WB Saunders; 1985. pp. 1174-1178
- [7] Takeno M, Kariyone A, Yamashita N, et al. Excessive function of peripheral blood neutrophils from patients with Behçet's disease and from HLA-B51 transgenic mice. *Arthritis and Rheumatism*. 1995;**38**:426-433
- [8] International Study Group for Behçet's Disease. Criteria for diagnosis of Behçet's disease. *Lancet*. 1990; **335**:1078-1080
- [9] Behçet's Disease Research Committee of Japan. Behçet's disease: Guide to diagnosis of Behçet's disease. *Japanese Journal of Ophthalmology*. 1974;**18**:291-294
- [10] Lehner T, Barnes CM. Criteria for diagnosis and classification of Behçet's syndrome. In: Lehner T, Barnes CM, editors. *Behçet's Syndrome. Clinical and Immunological Features*. London: Academic Press. 1979:1-9
- [11] Alpsoy E, Donmez L, Onder M, et al. Clinical features and natural course of Behçet's disease in 661 cases: A multicenter study. *The British Journal of Dermatology*. 2007;**157**:901-906. DOI: 10.1111/j.1365-2133.2007.08116.x
- [12] Çakar Özdal MP, Yazici A, Tüfek M, Öztürk F. Epidemiology of uveitis in a referral hospital in Turkey. *Turkish Journal of Medical Sciences*. 2014;**44**:337-342
- [13] Goto H, Mochizuki M, Yamaki K, Kotake S, Usui M, Ohno S. Epidemiological survey of intraocular inflammation in Japan. *Japanese Journal of Ophthalmology*. 2007;**51**:41-44. DOI: 10.1007/s10384-006-0383-4
- [14] Tugal-Tutkun I, Onal S, Altan-Yaycioglu R, et al. Uveitis in Behçet disease: An analysis of 880 patients. *American Journal of Ophthalmology*. 2004;**138**:373-380. DOI: 10.1016/j.ajo.2004.03.022

- [15] Kural-Seyahi E, Fresko İ, Seyahi N, et al. The long-term mortality and morbidity of Behçet's syndrome: A 2-decade outcome survey of 387 patients followed at a dedicated center. *Medicine*. 2003;**82**:60-76
- [16] Zafirakis P, Foster CS. Adamantiades-Behçet's disease. In: Foster CS, Vitale A, editors. *Diagnosis and Treatment of Uveitis*. 2nd ed. New Delhi: Jaypee Brothers Medical Publishers Ltd; 2013. pp. 857-886
- [17] Zierhut M, Stübiger N, Deuter C. Behçet's disease. In: Pleyer U, Mondino B, editors. *Essentials in Ophthalmology: Uveitis and Immunological Disorders*. 1st ed. Berlin: Springer-Verlag Berlin Heidelberg; 2005. pp. 173-200. DOI: 10.1007/3-540-26752-2.ch12
- [18] Evereklioglu C. Ocular Behcet disease: Current therapeutic approaches. *Current Opinion in Ophthalmology*. 2011;**22**:508-516. DOI: 10.1097/ICU.0b013e32834bbe91
- [19] Namba K, Goto H, Kaburaki T, et al. A major review: Current aspects of ocular Behçet's disease in Japan. *Ocular Immunology and Inflammation*. 2015;**23**:1-23. DOI: 10.3109/09273948.2014.981547
- [20] Yalcindag FN, Kiziltunc PB, Savku E. Evaluation of intraocular inflammation with laser flare photometry in Behçet uveitis. *Ocular Immunology and Inflammation*. 2017;**25**:41-45. DOI: 10.3109/09273948.2015.1108444
- [21] Pantanelli SM, Khalifa YM. Retinal manifestations of autoimmune and inflammatory disease. *International Ophthalmology Clinics*. 2012;**52**:25-46. DOI: 10.1097/IIO.0b013e31823bbbe9
- [22] Horiuchi T, Yoneya S, Numaga T. Vitreous involvement may be crucial in the prognosis of Behçet's disease. In: Blodi F, Brancato R, Cristini T, et al, editors. *Acta XXV Concilium Ophthalmologicum*. Rome: Kugler Ghedini;1986. pp. 2624-2631
- [23] Rosenbaum JT, Sibley CH, Lin P. Retinal vasculitis. *Current Opinion in Rheumatology*. 2016;**28**:228-235. DOI: 10.1097/BOR.0000000000000271
- [24] Stübiger N, Zierhut M, Kötter I. Ocular manifestations in Behçet's disease. In: Zierhut M, Ohno S, editors. *Immunology of Behçet's Disease*. Lisse, Netherlands: Swets & Zeitlinger; 2003. pp. 36-45
- [25] Abu El-Asrar A, Almomen AM, Alamro S, Tabbara LK. Bilateral central retinal vein thrombosis in Behcet's disease. *Clinical Rheumatology*. 1996;**15**:511-513
- [26] Lim JW, Kang SH. A case of Behçet's disease complicated by bilateral posterior ischemic optic neuropathy. *International Ophthalmology*. 2011;**31**:157-160. DOI: 10.1007/s10792-011-9415-2
- [27] Atmaca LS. Fundus changes associated with Behçet's disease. *Graefes Archive for Clinical and Experimental Ophthalmology*. 1989;**27**:340-344
- [28] Tugal-Tutkun I, Herbort CP, Khairallah M, Mantovani A. Interobserver agreement in scoring of dual fluorescein and ICG inflammatory angiographic signs for the grading of

- posterior segment inflammation. *Ocular Immunology and Inflammation*. 2010;**18**:385-389. DOI: 10.3109/09273948.2010.489730
- [29] Kim M, Kwon HJ, Choi EY, et al. Correlation between fluorescein angiographic findings and visual acuity in Behçet retinal vasculitis. *Yonsei Medical Journal*. 2015;**56**:1087-1096. DOI: 10.3349/ymj.2015.56.4.1087
- [30] Tugal-Tutkun I, Cakar Ozdal P, Oray M, Onal S. Review for diagnostics of the year: Multimodal imaging in Behçet uveitis. *Ocular Immunology and Inflammation*. 2017;**25**:7-19. DOI: 10.1080/09273948.2016.1205100
- [31] Mesquida M, Llorenç V, Fontenla JR, et al. Use of ultra-wide-field retinal imaging in the management of active Behçet retinal vasculitis. *Retina*. 2014; **34**:2121-2127. DOI: 10.1097/IAE.0000000000000197
- [32] Matsuo T, Sato Y, Shiraga F, et al. Choroidal abnormalities in Behcet disease observed by simultaneous indocyanine green and fluorescein angiography with scanning laser ophthalmoscopy. *Ophthalmology*. 1999;**106**:295-300. DOI: 10.1016/S0161-6420(99)90069-6
- [33] Atmaca LS, Sonmez PA. Fluorescein and indocyanine green angiography findings in Behcet disease. *The British Journal of Ophthalmology*. 2003;**87**:1466-1468
- [34] Onal S, Tugal-Tutkun I, Neri P, Herborn C. Optical coherence tomography imaging in uveitis. *International Ophthalmology*. 2014;**34**(2):401-435. DOI: 10.1007/s10792-013-9822-7
- [35] Tortorella P, D'Ambrosio E, Iannetti L, et al. Correlation between visual acuity, inner segment/outer segment junction, and cone outer segment tips line integrity in uveitic macular edema. *BioMed Research International*. 2015;**2015**:853728. doi:10.1155/2015/853728
- [36] Ishikawa S, Taguchi M, Muraoka T, et al. Changes in subfoveal choroidal thickness associated with uveitis activity in patients with Behçet's disease. *The British Journal of Ophthalmology*. 2014;**98**(11):1508-1513. DOI: 10.1136/bjophthalmol-2014-305333
- [37] Kim M, Kim H, Kwon HJ, et al. Choroidal thickness in Behcet's uveitis: An enhanced depth imaging-optical coherence tomography and its association with angiographic changes. *Investigative Ophthalmology & Visual Science*. 2013;**54**(9):6033-6039. DOI: 10.1167/iovs.13-12231
- [38] Zierhut M, Abu El-Asrar AM, Bodaghi B, Tugal-Tutkun I. Therapy of ocular Behçet disease. *Ocular Immunology and Inflammation*. 2014;**22**:64-76. DOI: 10.3109/09273948.2013.866257
- [39] Fabiani C, Alio JL. Local (topical and intraocular) therapy for ocular Adamantiades- Behçet's disease. *Current Opinion in Ophthalmology*. 2015;**26**:546-552. DOI: 10.1097/ICU.0000000000000210
- [40] Hamuryudan V, Ozyazgan Y, Hizli N, et al. Azathioprine in Behçet's syndrome: Effects on long-term prognosis. *Arthritis and Rheumatism*. 1997;**40**:769-774. DOI: 10.1002/1529-0131(199704)40:4<769::AID-ART24>3.0.CO;2-E

- [41] Larkin G, Lightman S. Mycophenolate mofetil: A useful immunosuppressive in inflammatory eye diseases. *Ophthalmology*. 1999;**106**:370-374
- [42] Siga NH, Dumont FJ. Cyclosporine, FK-506, and rapamycin: Pharmacologic probes of lymphocyte signal transduction. *Annual Review of Immunology*. 1992;**10**:519-560. DOI: 10.1146/annurev.iy.10.040192.002511
- [43] Foster CS, Baer JC, Raizman MB. Therapeutic responses to systemic immunosuppressive chemotherapy agents in patients with Behçet's syndrome affecting the eyes. In: O'Duffy JD, Kokmen E, editors. *Behçet's Disease: Basic and Clinical Aspects*. New York: Marcel Dekker; 1991. pp. 581-588
- [44] Ozyazgan Y, Yurdakul S, Yazici H, et al. Low dose cyclosporin A versus pulsed cyclophosphamide in Behçet's syndrome: A single masked trial. *The British Journal of Ophthalmology*. 1992;**76**:241-243
- [45] Masuda K, Nakajima A, Urayama A, et al. Double-masked trial of cyclosporin versus colchicines and long-term open study of cyclosporin in Behçet's disease. *Lancet*. 1989;**1**:1093-1096
- [46] BenEzra D, Cohen E, Chajek T, et al. Evaluation of conventional therapy versus cyclosporin A in Behçet's syndrome. *Transplantation Proceedings*. 1988;**20**:136-143
- [47] Mochizuki M, Masuda K, Sakane T, et al. A multicenter clinical open trial of FK 506 in refractory uveitis, including Behçet's disease. Japanese FK 506 Study Group on refractory uveitis. *Transplantation Proceedings*. 1991;**23**:3343-3346
- [48] Thureau SR, Wildner G. Immunomodulatory therapy. In: Pleyer U, Mondino B, editors. *Essentials in Ophthalmology: Uveitis and Immunological Disorders*. 1st ed. Berlin: Springer-Verlag Berlin Heidelberg; 2005. pp. 255-270. DOI:10.1007/3-540-26752-2.ch16
- [49] Fain O, Du LTH, Wechsler B. Pulse cyclophosphamide in Behçet's disease. In: O'Duffy JD, Kokmen E, editors. *Behçet's Disease: Basic and Clinical Aspects*. New York: Marcel Dekker; 1991. pp. 569-573
- [50] Misumi M, Hagiwara E, Takeno M, et al. Cytokine production profile in patients with Behçet's disease treated with infliximab. *Cytokine*. 2003;**24**:210-218
- [51] Evereklioglu C, Er H, Turkoz Y, Cekmen M. Serum levels of TNF-alpha, sIL-2R, IL-6, and IL-8 are increased and associated with elevated lipid peroxidation in patients with Behçet's disease. *Mediators of Inflammation*. 2002;**11**:87-93. DOI: 10.1080/09629350220131935
- [52] Santos Lacomba M, Marcos Martin C, et al. Aqueous humor and serum tumor necrosis factor-alpha in clinical uveitis. *Ophthalmic Research*. 2001;**33**:251-255. DOI: 55677
- [53] Hatemi G, Seyahi E, Fresko I, et al. One year review 2016: Behçet's syndrome. *Clinical and Experimental Rheumatology*. 2016;**34**:10-22
- [54] Fujikawa K, Aratake K, Kawakami A, et al. Successful treatment of refractory neuro-Behçet's disease with infliximab: A case report to show its efficacy by magnetic resonance

- imaging, transcranial magnetic stimulation and cytokine profile. *Annals of the Rheumatic Diseases*. 2007;**66**:136-137. DOI: 10.1136/ard.2006.056804
- [55] Accorinti M, Pirraglia MP, Paroli MP, et al. Infliximab treatment for ocular and extraocular manifestations of Behçet's disease. *Japanese Journal of Ophthalmology*. 2007;**51**:191-196. DOI: 10.1007/s10384-006-0425-y
- [56] Tabbara KF, Al-Hemidan AI. Infliximab effects compared to conventional therapy in management of retinal vasculitis in Behçet disease. *American Journal of Ophthalmology*. 2008;**146**:845-850. DOI: 10.1016/j.ajo.2008.09.010
- [57] Yamada Y, Sugita S, Tanaka H, et al. Comparison of infliximab versus ciclosporin during the initial 6-month treatment period in Behçet disease. *The British Journal of Ophthalmology*. 2010;**94**:284-288. DOI: 10.1136/bjo.2009.158840
- [58] Arida A, Fragiadaki K, Giavri E, Sfikakis PP. Anti-TNF agents for Behçet's disease: Analysis of published data on 369 patients. *Seminars in Arthritis and Rheumatism*. 2011;**41**:61-70. DOI: 10.1016/j.semarthrit.2010.09.002
- [59] Mushtaq B, Saeed T, Situnayake RD, Murray PL. Adalimumab for sight-threatening uveitis in Behçet's disease. *Eye*. 2007;**21**:824-825. DOI: 10.1038./sj.eye.6702352
- [60] Bawazeer A, Raffa LH, Nizamuddin SH. Clinical experience with adalimumab in the treatment of ocular Behçet disease. *Ocular Immunology and Inflammation*. 2010;**18**:226-232. DOI: 10.3109/09273948.2010.483314
- [61] Olivieri I, Leccese P, D'Angelo S, et al. Efficacy of adalimumab in patients with Behçet's disease unsuccessfully treated with infliximab. *Clinical and Experimental Rheumatology*. 2011;**29**:S54-S57. 75
- [62] Santos Gomez M, Calvo Rio V, Blanco R, et al. The effect of biologic therapy different from infliximab or adalimumab in patients with refractory uveitis due to Behçet's disease: Results of a multicentre open-label study. *Clinical and Experimental Rheumatology*. 2016;**34**:34-40
- [63] Deuter CME, Kötter I, Wallace GR, et al. Behçet's disease: Ocular effects and treatment. *Progress in Retinal and Eye Research*. 2008;**27**:111-136. DOI: 10.1016/j.preteyeres.2007.09.002
- [64] Kötter I, Gü naydin I, Zierhut M, Stübiger N. The use of interferon a in Behçet disease: Review of the literature. *Seminars in Arthritis and Rheumatism*. 2004;**33**:320-355
- [65] Deuter CM, Kötter I, Günaydin I, et al. Efficacy and tolerability of interferon alpha treatment in patients with chronic cystoid macular oedema due to non-infectious uveitis. *The British Journal of Ophthalmology*. 2009;**93**:906-913. DOI: 10.1136/bjo.2008.153874
- [66] Bodaghi B, Gendron G, Wechsler B, et al. Efficacy of interferon alpha in the treatment of refractory and sight threatening uveitis: A retrospective monocentric study of 45 patients. *The British Journal of Ophthalmology*. 2007;**91**:335-339. DOI: 10.1136/bjo.2006.101550

- [67] Hatemi G, Silman A, Bang D, et al. EULAR recommendations for the treatment of Behçet disease. *Annals of the Rheumatic Diseases*. 2008;**67**:1656-1662. DOI: 10.1136/ard.2007.080432
- [68] Kötter I, Deuter C, Stübiger N, Zierhut M. Interferon-a (IFN-a) application versus tumor necrosis factor-a antagonism for ocular Behçet's disease: Focusing more on IFN. *The Journal of Rheumatology*. 2005;**32**:1633
- [69] Kötter I, Zierhut M, Eckstein AK, et al. Human recombinant interferon alpha-2a for the treatment of Behçet's disease with sight threatening posterior or panuveitis. *The British Journal of Ophthalmology*. 2003;**87**:423-431
- [70] Tugal-Tutkun I, Güney-Tefekli E, Urgancioglu M. Results of interferon-alfa therapy in patients with Behçet uveitis. *Graefe's Archive for Clinical and Experimental Ophthalmology*. 2006;**244**:1692-1695. DOI: 10.1007/s00417-006-0346-y
- [71] Tugal-Tutkun I, Onal S, Altan-Yaycioglu R, Kir N, Urgancioglu M. Neovascularization of the optic disc in Behçet's disease. *Japanese Journal of Ophthalmology*. 2006;**50**(3):256-265. DOI: 10.1007/s10384-005-0307-8
- [72] Gueudry J, Wechsler B, Terrada C, et al. Long-term efficacy and safety of low-dose interferon alpha2a therapy in severe uveitis associated with Behçet disease. *American Journal of Ophthalmology*. 2008;**146**:837-844. DOI: 10.1016/j.ajo.2008.08.038
- [73] Yosipovitch G, Sholat B, Bshara J, Wysenbeek A, Weinberger A. Elevated serum interleukin 1 receptors and interleukin 1B in patients with Behçet's disease: Correlations with disease activity and severity. *Israel Journal of Medical Sciences*. 1995;**31**:345-348
- [74] Düzgün N, Ayaslioglu E, Tutkak H, Aydintug OT. Cytokine inhibitors: Soluble tumor necrosis factor receptor 1 and interleukin-1 receptor antagonist in Behçet's disease. *Rheumatology International*. 2005;**25**:1-5. DOI: 10.1007/s00296-003-0400-6
- [75] Emmi G, Talarico R, Lopalco G, et al. Efficacy and safety profile of anti-interleukin-1 treatment in Behçet's disease: A multicenter retrospective study. *Clinical Rheumatology*. 2016;**35**:1281-1286. DOI: 10.1007/s10067-015-3004-0
- [76] Vitale A, Rigante D, Lopalco G, et al. Interleukin-1 inhibition in Behçet's disease. *The Israel Medical Association Journal*. 2016;**18**:171-176
- [77] Dinarello CA. The many worlds of reducing interleukin-1. *Arthritis and Rheumatism*. 2005;**52**:1960-1967. DOI: 10.1002/art.21107
- [78] Karacorlu M, Mudun B, Ozdemir H, et al. Intravitreal triamcinolone acetonide for the treatment of cystoid macular edema secondary to Behçet disease. *American Journal of Ophthalmology*. 2004;**138**:289-291
- [79] Atmaca LS, Yalcindag NF, Ozdemir O. Intravitreal triamcinolone acetonide in the management of cystoid macular edema in Behçet's disease. *Graefe's Archive for Clinical and Experimental Ophthalmology*. 2007;**245**:451-456. DOI: 10.1007/s00417-006-0514-0

- [80] Ohguro N, Yamanaka E, Otori Y, et al. Repeated intravitreal triamcinolone injections in Behçet disease that is resistant to conventional therapy: One year results. *American Journal of Ophthalmology*. 2006;**141**:218-220. DOI: 10.1016/j.ajo.2005.08.013
- [81] Tuncer S, Yilmaz S, Urgancioglu M, Tugal-Tutkun TI. Results of intravitreal triamcinolone acetonide (IVTA) injection for the treatment of panuveitis attacks in patients with Behçet disease. *Journal of Ocular Pharmacology and Therapeutics*. 2007;**23**:395-401. DOI: 10.1089/jop.2007.0015
- [82] Park UC, Park JH, Yu HG. Long-term outcome of intravitreal triamcinolone acetonide injection for the treatment of uveitis attacks in Behçet disease. *Ocular Immunology and Inflammation*. 2014;**22**:27-33. DOI: 10.3109/09273948.2013.829109
- [83] Lowder C, Belfort R Jr, Lightman S, et al. Dexamethasone intravitreal implant for noninfectious intermediate or posterior uveitis. *Archives of Ophthalmology*. 2011;**129**:545-553. DOI: 10.1001/archophthalmol.2010.339
- [84] Khurana RN, Porco TC. Efficacy and safety of dexamethasone intravitreal implant for persistent uveitis cystoid macular edema. *Retina*. 2015;**35**:1640-1646. DOI: 10.1097/IAE.0000000000000515
- [85] Zarranz-Ventura J, Carreno E, Johnston RL, et al. Multicenter study of intravitreal dexamethasone implant in noninfectious uveitis; indications, outcomes, and reinjection frequency. *American Journal of Ophthalmology*. 2014;**158**:1136-1145. DOI: 10.1016/j.ajo.2014.09.003
- [86] Jaffe GJ, Martin D, Callanan D, et al. Fluocinolone acetonide implant (Retisert) for noninfectious posterior uveitis: Thirty-four week results of a multicenter randomized clinical study. *Ophthalmology*. 2006;**113**:1020-1027. DOI: 10.1016/j.opthta.2006.02.021
- [87] Sangwan VS, Pearson PA, Paul H, Comstock TL. Use of the fluocinolone acetonide intravitreal implant for the treatment of noninfectious posterior uveitis: 3-year results of a randomized clinical trial in a predominantly Asian population. *Ophthalmology and Therapy*. 2015;**4**:1-19. DOI: 10.1007/s40123-014-0027-6
- [88] Kempen JH, Altaweel MM, Holbrook JT, et al. Randomized comparison of systemic anti-inflammatory therapy versus fluocinolone acetonide implant for intermediate, posterior, and panuveitis: The multicenter uveitis steroid treatment trial. *Ophthalmology*. 2011;**118**:1916-1926. DOI: 10.1016/j.opthta.2011.07.027
- [89] Giganti M, Beer PM, Lemanski N, et al. Adverse events after intravitreal infliximab (Remicade). *Retina*. 2010;**30**:71-80. DOI: 10.1097/IAE.0b013e3181bcef3b
- [90] Pulido JS, Pulido JE, Michet CJ, Vile RG. More questions than answers: A call for a moratorium on the use of intravitreal infliximab outside of a well-designed trial. *Retina*. 2010;**30**:1-5. DOI: 10.1097/IAE.0b013e3181cde727
- [91] Hamza MME, Macky TA, Sidky MK, et al. Intravitreal infliximab in refractory uveitis in Behçet's disease: A safety and efficacy clinical study. *Retina*. 2016;**36**:2408-2416. DOI: 10.1097/IAE.0000000000001109

- [92] Farvardin M, Afarid M, Mehryar M, Hosseini H. Intravitreal infliximab for the treatment of sight-threatening chronic noninfectious uveitis. *Retina*. 2010;**30**:1530-1535. DOI: 10.1097/IAE.0b013e3181d3758a
- [93] Farvardin M, Afarid M, Shahrzad S. Long-term effects of intravitreal infliximab for treatment of sight-threatening chronic noninfectious uveitis. *Journal of Ocular Pharmacology and Therapeutics*. 2012;**28**:628-631. DOI: 10.1089/jop.2011.0199
- [94] Markomichelakis N, Delicha E, Masselos S, et al. Intravitreal infliximab for sight-threatening relapsing uveitis in Behçet disease: A pilot study in 15 patients. *American Journal of Ophthalmology*. 2012;**154**:534-541. DOI: 10.1016/j.ajo.2012.03.035
- [95] Lasave AF, Zeballos DG, El-Haig WM, et al. Short-term results of a single intravitreal bevacizumab (avastin) injection versus a single intravitreal triamcinolone acetonide (kenacort) injection for the treatment of refractory noninfectious uveitic cystoid macular edema. *Ocular Immunology and Inflammation*. 2009;**17**:423-430. DOI: 10.3109/09273940903221610
- [96] Soheilian M, Rabbanikhah Z, Ramezani A, et al. Intravitreal bevacizumab versus triamcinolone acetonide for refractory uveitic cystoid macular edema: A randomized pilot study. *Journal of Ocular Pharmacology and Therapeutics*. 2010;**26**:199-206. DOI: 10.1089/jop.2009.0093
- [97] Bae JH, Lee CS, Lee SC. Efficacy and safety of intravitreal bevacizumab compared with intravitreal and posterior sub-tenon triamcinolone acetonide for treatment of uveitic cystoid macular edema. *Retina*. 2011;**31**:111-118. DOI: 10.1097/IAE.0b013e3181e378af
- [98] Kacmaz RO, Kempen JH, Newcomb C, et al. Ocular inflammation in Behcet disease: Incidence of ocular complications and of loss of visual acuity. *American Journal of Ophthalmology*. 2008;**146**:828-836. DOI: 10.1016/j.ajo.2008.06.019