

# We are IntechOpen, the world's leading publisher of Open Access books Built by scientists, for scientists

6,900

Open access books available

186,000

International authors and editors

200M

Downloads

Our authors are among the

154

Countries delivered to

TOP 1%

most cited scientists

12.2%

Contributors from top 500 universities



WEB OF SCIENCE™

Selection of our books indexed in the Book Citation Index  
in Web of Science™ Core Collection (BKCI)

Interested in publishing with us?  
Contact [book.department@intechopen.com](mailto:book.department@intechopen.com)

Numbers displayed above are based on latest data collected.  
For more information visit [www.intechopen.com](http://www.intechopen.com)



---

# Sudden Death due to Diseases of the Adrenal Glands and Paraganglia

---

Silvia Damiana Visonà, Luca Tajana and Antonio Osculati

Additional information is available at the end of the chapter

<http://dx.doi.org/10.5772/intechopen.69416>

---

## Abstract

Coroners and pathologists commonly evaluate unexpected deaths due to diseases of the adrenal glands and paraganglia, which are, unfortunately, not rare in their totality. Although cardiac causes are the main cause of sudden death, endocrine conditions can produce sudden, unexpected deaths that need further investigation, especially in younger patients. This chapter focuses on the issue of sudden death due to diseases involving adrenal glands and paraganglia. The main causes of sudden death due to adrenal gland pathology will be examined, paying particular attention to the pathophysiology of sudden death, macroscopic and microscopic characteristics and their correlation with clinical features. These issues are of great interest, especially considering the clinical impact of sudden death and its rarity among patients with adrenal gland diseases. The forensic pathologist's examination is extremely important in determining the cause of death and findings not clinically observable and can contribute to the improvement of the clinical and surgical approach in treating such patients.

**Keywords:** adrenal glands, paraganglia, sudden death, Addison's disease, Cushing's syndrome, pheochromocytoma, paraganglioma

---

## 1. Introduction

Coroners and pathologists are frequently presented with unexpected and sudden deaths, which are, unfortunately, not rare. The definition of sudden death suggested by the World Health Organization is a death occurring within 24 h from the onset of symptoms. However, for most clinicians and pathologists, this interval is too long with many regarding sudden death within one hour from the onset of illness [1]. Cardiovascular, central nervous system

and respiratory diseases account for the majority of unexpected natural deaths. Heart diseases are the main cause of sudden death and most investigated. However, in cases of an unexpected death in young and apparently healthy patients, many other medical conditions need to be considered.

Forensic pathologists have a pivotal role in investigating sudden deaths, as autopsies are often performed. One reason is that in many jurisdictions, death may only be certified by an attending physician if he or she has recently seen the patient and it is clear that their death was caused by a potentially lethal disease. When death cannot be certified by an attending physician, the patient case is referred for medicolegal investigation. Under these circumstances, the role of the forensic pathologist is twofold: to determine the cause and manner of death and initiate a multidisciplinary process in order to prevent further deaths in existing family members (especially in the case of familial diseases) or in other patients suffering from a similar disorder. Lastly, an autopsy is often ordered by a prosecutor if medical malpractice is suspected, especially if the death occurred at a hospital.

The forensic pathologist's examination is extremely important since providing a cause of death and other findings previously not known can contribute to the improvement of clinical and surgical management of such patients, and help avoid this undesired outcome in other similar cases. Sudden deaths from adrenal diseases are rare compared to other causes, extremely difficult to recognize clinically, and often discovered at autopsy by thorough postmortem investigations.

In this chapter, diseases of the adrenal gland and paraganglia that can cause sudden death will be discussed, including the clinical correlation and pattern, as well as the mechanism and presentation of death.

## **2. Corticoadrenal hypofunction and sudden death**

When dealing with a sudden death in an otherwise healthy individual, adrenocortical insufficiency should always be considered. This condition is very difficult to recognize clinically, since signs and symptoms are nonspecific, and as such, it is often encountered in forensic practice, as the cause of unexpected death. A careful investigation of the adrenal glands is essential, especially if underlying diseases of the cardiovascular and nervous system exists. An autopsy is commonly ordered when medical mistakes are suspected including late or misdiagnosis. In such circumstances, assessment of clinical condition before death, when possible, through an accurate anamnesis collected from the relatives of the decedent, and their correlation with the macroscopic and microscopic postmortem pattern is paramount.

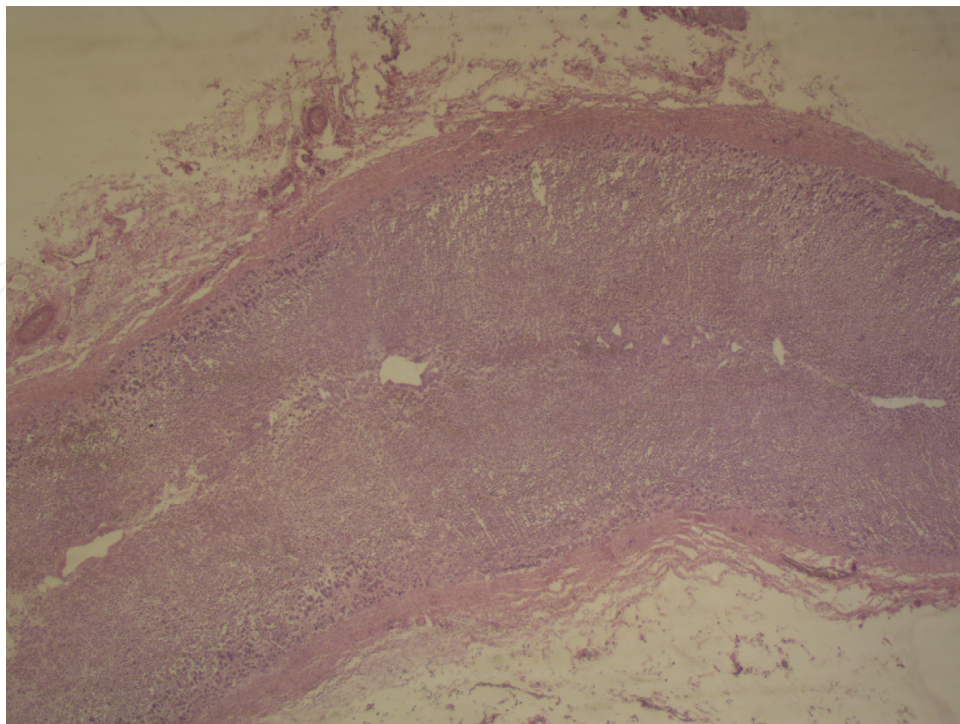
Adrenal insufficiency is an infrequent cause of sudden death and occurs most frequently in individuals treated for other critical conditions where impairment of corticoadrenal function often occurs. Nevertheless, it is well known that adrenal insufficiency can remain clinically silent until abrupt adrenal decompensation takes place and the patient dies suddenly. In fact, >90% of the adrenal cortex bilaterally must be nonfunctional before any clinical manifestation by infective, inflammatory, or neoplastic processes manifests and causes sudden death [2].

Both Addison's disease (primary corticoadrenal insufficiency due to bilateral destruction or damage to the adrenal cortex) and secondary hypocortisolism (ACTH hypoproduction) result in the lack of hormone production that can lead to sudden death. Regardless of the cause, the acute adrenal crisis is characterized by a shock-like condition due to electrolyte deficit with acidosis, vomiting, diarrhea, hemorrhage, and numbness. Death is often caused by hyponatremia, the result of aldosterone deficiency, leading to cerebral and pulmonary edema.

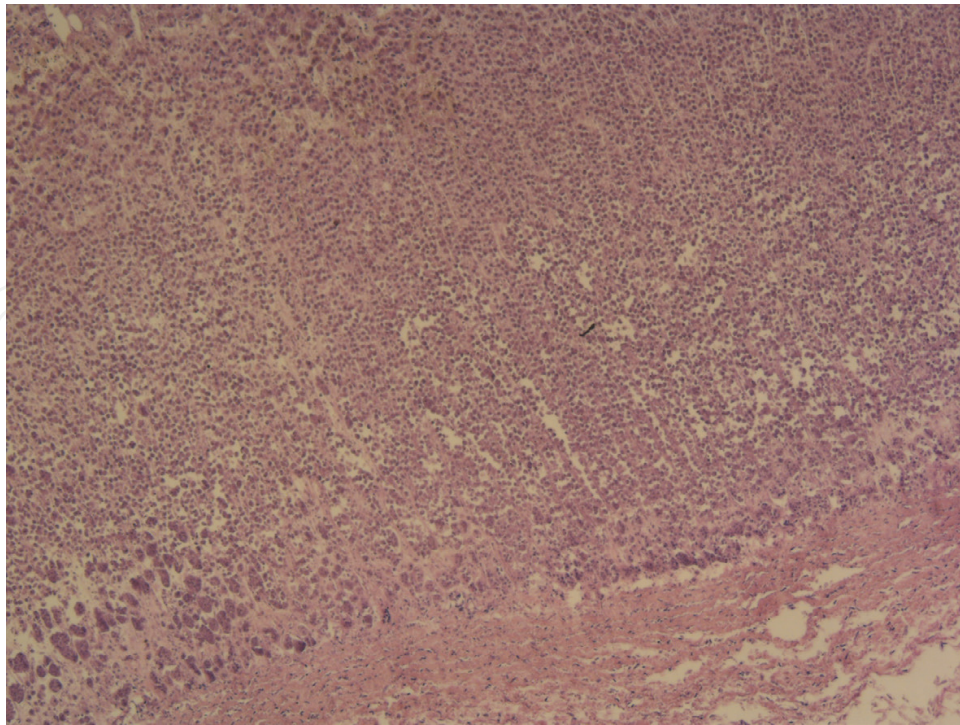
Forensic pathologists may encounter cases of decedents with already known Addison's disease in which an unknown stress, such as superimposed disease or a stimulating event, has triggered a lethal adrenal crisis. In such instances, it can be challenging to identify the precipitating event, which most commonly is an infection or surgical procedure [2].

At autopsy, decedents who suffered from chronic adrenocortical insufficiency are often slim and cachectic with a brownish skin pigmentation also seen in anorexia nervosa. Generally, pathologic findings at autopsy may include a low combined weight and atrophy making the adrenal glands difficult to detect. For this reason, multiple slides of the fatty tissue surrounding the superior pole of each kidney should be taken for histologic examination. The microscopic appearance of adrenal gland tissue shows atrophy of adrenal cortical cells, and a collapsed vascular reticulin framework (**Figures 1 and 2**).

Only a few sudden deaths due to an endocrine imbalance in an individual previously known to have been treated for adrenocortical insufficiency are found in the literature. A reported case of a 50-year-old man, whose medical history was significant for Addison's disease, was found dead in a hotel room [3]. Taking into account this man's circumstances, medical history, and



**Figure 1.** Atrophy of the adrenal cortex (secondary to craniocencephalic trauma), H&E, 12×.



**Figure 2.** Atrophy of the adrenal cortex (secondary to cranioencephalic trauma) H&E, 60×.

autopsy findings, cause of death was attributed to acute adrenal crisis secondary to gland hypofunction and insufficiency. Adrenocortical insufficiency can be due to many causes including autoimmune gland destruction, infection, and hemorrhage.

### 2.1. Autoimmune adrenalitis

In industrialized countries, adrenal insufficiency is mostly caused by an autoimmune disease that is particularly challenging to evaluate in postmortem investigation as typical macroscopic findings reveal difficult to detect adrenal glands with markedly reduced size [2]. Histologically, in autoimmune adrenalitis, adrenal glands show significant reduction of cortical parenchyma and lymphocytic and plasma cell infiltration (almost exclusively in the cortical region) associated with the destruction of cortical cells. The major difference between Addison's disease caused by tuberculosis and autoimmune adrenalitis is that in the former, there is the destruction of the whole gland, whereas in the latter, only the cortex is involved. Typically, the dimension of the adrenal glands is markedly reduced and sometimes undetectable. Microscopically, the cortex is generally atrophied and replaced by islands of large eosinophilic cells, but no fibrosis is seen, even though the residual vascular reticulin framework can be observed. Occasionally, there is moderate infiltration, mainly composed by lymphocytes, with some involvement of the medulla that is otherwise normal. Inflammation is often accompanied by fibrosis [4]. Histologic features seen in autoimmune adrenalitis include the enlargement of surviving cells that also show nuclear atypia, probably due to prolonged ACTH stimulation [2].

There are a few cases describing autoimmune adrenalitis as a cause of sudden death in the literature. In one case report, a 12-year-old girl hospitalized following a 2-day history of recurrent vomiting was given the misdiagnosis of diabetic ketoacidosis [5]. She died shortly after hospitalization. The diagnosis of autoimmune Addison's disease was rendered at autopsy based on histology. Microscopic examination revealed depletion and atrophy of the adrenal cortex with enlargement, eosinophilia of surviving cortical cells, and prominent round cell infiltrates composed mostly of lymphocytes. In addition, there was mild chronic lymphocytic thyroiditis. Other organs were unremarkable except for marked pulmonary congestion and edema with early basal pneumonic changes and cerebral edema.

Undeniably, histopathology is essential for the diagnosis of autoimmune adrenalitis, and examination of postmortem blood, particularly of serum cortisol levels, should be included in the investigation. The availability of appropriately stored antemortem serum samples is of great importance, and cortisol is sufficiently stable in postmortem blood [6]. Levels of cortisol, 17-hydroxycorticosterone, aldosterone, and dehydroepiandrosterone in postmortem serum from femoral blood and urine (in combination with other biochemical investigation) allow for the differentiation between ketoacidosis and adrenocortical insufficiency [7]. An additional examination for adrenal autoantibodies on postmortem serum can be conducted [2].

## 2.2. Tuberculosis and other infections involving adrenal glands

About 10% of Addison's disease cases have an infectious etiology [8]. HIV/AIDS and opportunistic infections such as cytomegalovirus are the most commonly cited causes, following tuberculosis. Currently, adrenal tuberculosis has generally considered a disease of immigrants from endemic areas, immunocompromised or destitute individuals. In the past, tuberculosis was the most common cause of adrenocortical insufficiency and remains the primary cause in the developing countries where it accounts for about 20–30% of cases of Addison's disease. Various fungi including *Cryptococcus*, *Histoplasma*, *Coccidioides*, and *Paracoccidioides* also infect the adrenal glands as reported in several published case reports. It is well known that *Mycobacterium tuberculosis* complex spreads to the adrenal glands hematogenously. Clinical manifestations may take 3 years to become apparent, and asymptomatic infection is not uncommon [8].

The only case report, to the authors' knowledge, of sudden death due to isolated adrenal tuberculosis was reported in 1985 [9]. The patient with a history of a disseminated carcinoma of the prostate presented with normal blood pressure, lack of skin pigmentation, and normal electrolytes. He died suddenly after being admitted to a hospital for investigation of pleural thickening. The autopsy revealed that his adrenal glands were both completely replaced by caseous material containing acid-fast bacilli. There was no evidence of tuberculosis in any other organs.

Another important issue regarding the adrenal glands concerns HIV infection. Apart from direct infection, opportunistic infections and antiretroviral medications also have a significant effect on the adrenal glands. Adrenal insufficiency is prevalent in 17% of patients admitted with AIDS [10]. In a forensic context, when dealing with an unexpected death in a subject previously known as having HIV, adrenal insufficiency should be considered and properly investigated.

The histopathology and morphologic assessment of the adrenal glands were investigated in 128 autopsied patients who died from AIDS [11]. Interestingly, alteration of the adrenal glands was observed in 99.2% of these decedents with various patterns of disease and different pathogens. Inflammatory infiltrates, mostly with a predominance of mononuclear cells, were observed in 99.2% of the cases. The medulla was almost always involved. Fibrosis, necrosis, neoplasia, and hemorrhage were also detected.

Human cytomegalovirus (CMV) has been frequently identified as a cause of adrenal insufficiency, especially in patients with HIV/AIDS. In one report, CMV-infected normal human adrenocortical cells and induced cytopathic changes [12]. CMV also acts as an inducer of steroidogenesis, which may explain the discordance between the high rates of CMV adrenalitis in immunosuppressed patients in autopsy studies and the relatively rare diagnosis of adrenal insufficiency antemortem. Interestingly, while adrenalitis may be the sole manifestation, the disease is usually disseminated. CMV typically affects the cortex-medulla junction [11].

Many other rare infections can affect the adrenal glands. Addisonian crisis has been reported in patients afflicted with such pathogens as: *histoplasma capsulatum* (commonly in HIV patients with clinical manifestation similar to tuberculosis), *paracoccidiomycosis* (endemic in several South American countries where adrenal insufficiency has been reported in 2.9–48.2% of patients), viruses (herpes simplex, Epstein Barr, CMV), and, very rarely, other bacteria and parasites [8].

### 2.3. Hemorrhage

Among the causes of adrenal insufficiency, bilateral adrenal hemorrhage is most frequently encountered in forensic practice. It is of particular interest because it is often clinically silent until the patient's condition worsens abruptly and results in sudden death. Various clinical signs and symptoms occur in the early stages of adrenal hemorrhage, including sudden or gradual back pain, epigastralgia and nonspecific conditions such as fatigue, fever, tachycardia, nausea, vomiting, dizziness, and hypotension. Adrenal insufficiency may also exhibit hyponatraemia, hyperkalemia, and hypoglycemia due to increased ACTH and decreased cortisol levels.

Bilateral adrenal hemorrhage can be due to many causes and can be classified as traumatic or nontraumatic. The exact mechanism of nontraumatic adrenal hemorrhage is still unclear. Adrenal vascularities are referred to as an 'adrenal dam' because adrenal glands have sufficient vascularity, but easily become hemorrhagic and embolic due to their anatomical configuration. An extremely high rate of blood flow, the arterial network that abruptly transitions to a capillary plexus, and, above all, the drainage by a single, central vein are certainly anatomical factors of importance [13].

Most cases of nontraumatic adrenal hemorrhage are related to stress due to infection, sepsis (Waterhouse-Friderichsen syndrome), surgery, thermal injuries, coagulopathic and thromboembolic disorders, neonatal stress, tumor metastasis to the adrenal glands [14], antiphospholipid syndrome [15], or idiopathic [16]. Interestingly, adrenal hemorrhage resulting in acute adrenal insufficiency has been reported to be a rare complication of anticoagulant therapy [17].

Bilateral adrenal hemorrhage has also been reported as a life-threatening complication of anaphylactic shock [18].

Adrenal hemorrhage at autopsy is not necessarily associated with sepsis, although it is the most frequent cause. This pathologic finding is much more common as a contributor to mortality, and a significant number of ill patients could be saved if such diagnosis was suspected antemortem. As they reside in a relatively protected location of the retroperitoneum, adrenal gland hemorrhage related to trauma is usually associated with other conspicuous intra-abdominal injuries [13].

In septic patients, the involvement of the adrenal glands seems to have a critical role in determining prognosis. A Mayo Clinic study revealed that corticosteroid treatment in situations of severe stress or sepsis had little effect on outcome (9% vs. 6% survival with and without corticosteroid treatment, respectively), in sharp contrast to adrenal hemorrhage occurring post-operatively as well as in the antiphospholipid-antibody syndrome [19]. In a study conducted on mice, there was a strong and significant correlation between mortality and adrenal inflammation, but not with plasma cytokine concentration or systemic inflammation [20]. This study demonstrated that adrenal inflammation during sepsis is associated with increased cell death, adrenal hemorrhage, and inadequate ACTH response.

The majority of reports cite massive adrenal hemorrhage as the most common nontraumatic cause of sudden death associated with sepsis, which is consistent with the authors' experience. Adrenal hemorrhage and insufficiency is classically associated with meningococcemia as part of the Waterhouse-Friderichsen syndrome. This catastrophic syndrome is characterized by overwhelming bacterial infection, classically *Neisseria meningitidis* septicemia, but also caused by other highly virulent organisms, e.g. *Haemophilus influenzae*, hemolytic *streptococcus*, and *pneumococcus* [21]. Patients typically present with a sudden onset of a rapidly progressive illness and hypotension leading to shock, cyanosis, petechial rash, rapidly developing adrenocortical insufficiency associated with massive bilateral adrenal hemorrhage, and death usually within 24 h [13, 21]. In spite of treatment with sulphonamides, antibiotics, and steroids, the prognosis is still extremely poor.

Examining the autopsy records from their institution, the authors found six patient cases in which adrenal hemorrhage was the cause of a sudden death. The age incidence varied from a 40-week old fetus to a 45-year-old man described as follows:

- (1) A 1-year-old child with a few hour history of high fever referred to a hospital for difficulty breathing; he arrived dead at the hospital. Histology showed bilateral, massive adrenal hemorrhages. *Meningococci* were isolated from blood cultures performed before death.
- (2) A 45-year-old man, with a 12-hour history of diarrhea and vomiting, suddenly died at the Emergency Department that he visited for a purple spot on his forehead. Postmortem examination revealed massive bilateral adrenal hemorrhage, but no microorganism was isolated.
- (3) A 19-year-old man, with high fever of a few hours, arrived dead at the hospital. No microorganisms were isolated, but the postmortem histopathology revealed massively hemorrhagic adrenal glands, cerebral and meningeal hyperemia, and spots.

- (4) Intrauterine fetal death of a fetus at term (40 weeks of gestation) due to *Streptococcus agalactiae* sepsis. Histopathology showed complete hemorrhagic necrosis of both adrenal glands.
- (5) A 6-month-old girl who was brought to the Emergency Department with a high fever, and after few hours later, suddenly died.
- (6) A 28-year-old woman who died suddenly from fulminant meningitis.

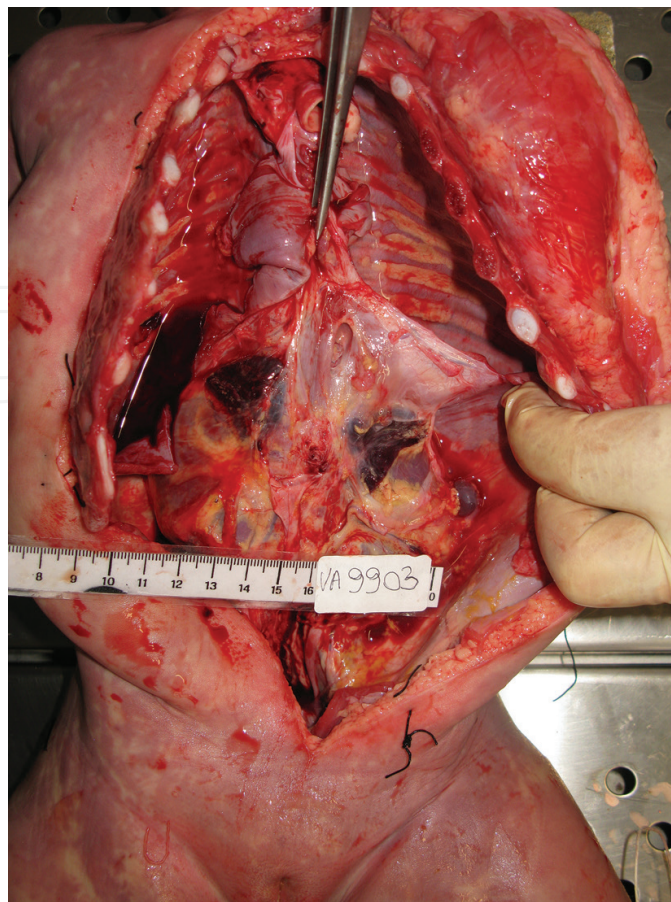
This case of the 28-year-old woman who died from fulminant meningitis is of particular interest because of the typical fulminant presentation. Her anamnesis was completely negative. She was admitted to the Emergency Department presenting with fever, rigors, nausea, and vomiting. A physical examination performed revealed no significant findings, except for abdominal tenderness and inflammation of the pharynx. The patient was discharged, but she persisted in having a high fever (40°C) and vomiting. She returned to the same hospital and was admitted to the Department of Medicine. At the time of admission, blood samples were taken for microbiological testing, and antibiotic therapy (3 g of ampicillin and 2 g of cefotaxime) was administered. About 2 h after admission, the woman became hypotensive, had difficulty breathing, and developed mild rigor nuchalis and diffuse petechiae. She was brought to the Intensive Care Unit, where she died 2 h later. Group C *N. meningitidis* was detected in her blood cultures taken before death. At autopsy, massive bilateral adrenal hemorrhage and diffuse petechiae were identified. Bacterial cultures of the postmortem blood samples (confirmed by PCR analysis) confirmed the woman's death due to fulminant sepsis from group C *N. meningitidis*.

Another characteristic case involves a 6-month-old girl who presented to the Emergency Department with a high fever (up to 39°C). A few hours later, she developed cyanosis and dyspnea and died suddenly. At forensic autopsy, performed 7 days after death, macroscopic examination revealed pulmonary edema and bilateral adrenal hemorrhage (**Figures 3–5**).

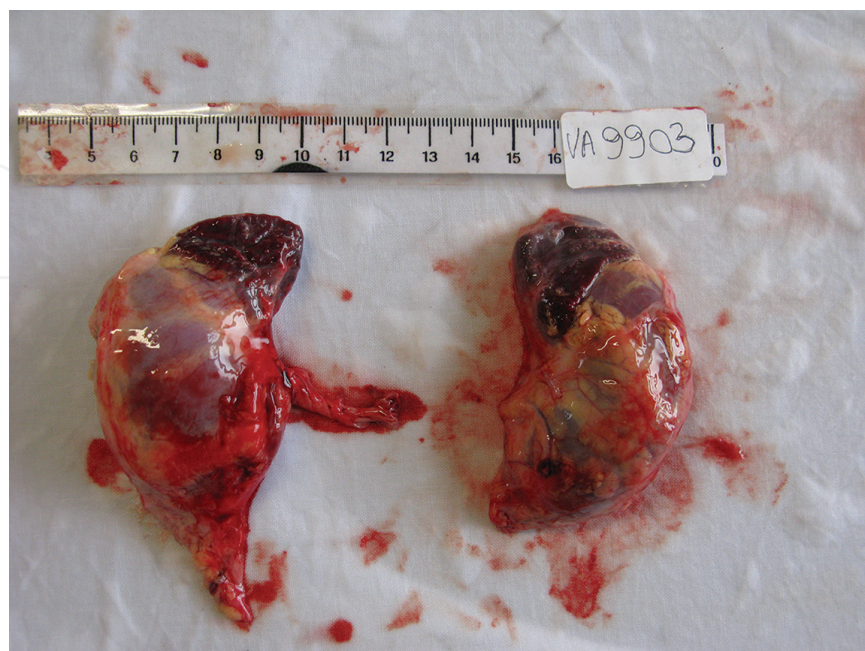Before an autopsy, blood (from neck vessels) and cerebrospinal fluid (through lumbar puncture) samples were collected with a sterile technique for subsequent microbiologic examination. *N. meningitidis* grew in cultures of blood and cerebrospinal fluid samples after incubation for 48 h, thus providing the postmortem diagnosis of sepsis due to *N. meningitidis*. The main microscopic finding was massive hemorrhage of the adrenal glands (**Figures 6 and 7**).

Premortem diagnosis was not possible because the fulminant disease had caused the baby to die too quickly. Indeed, detection of *N. meningitidis* in postmortem cultures determined the cause of death.

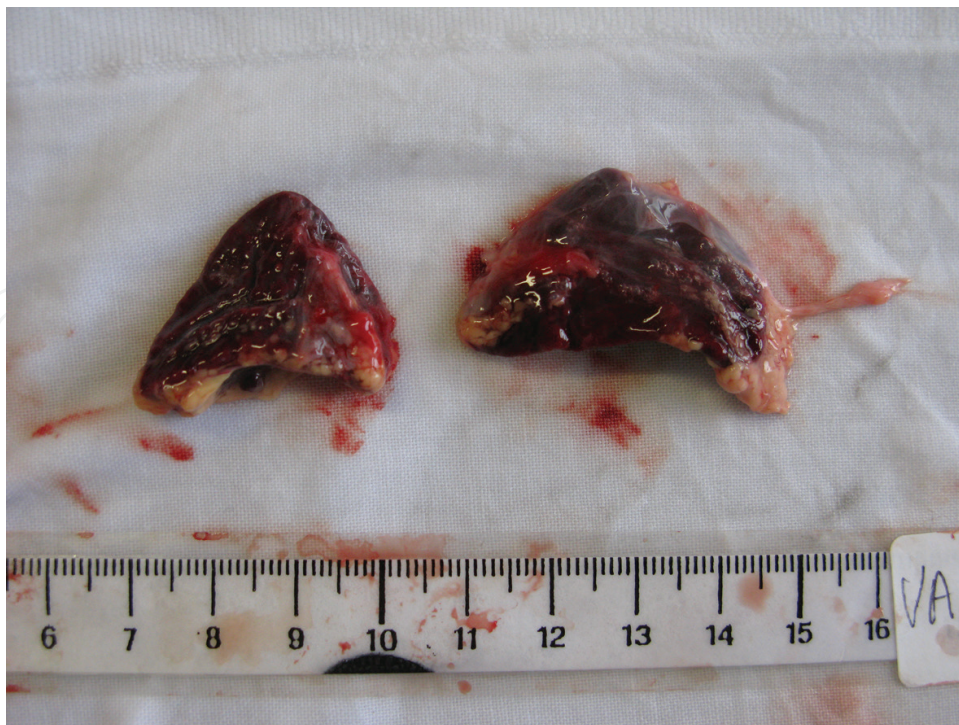The two aforementioned case reports are worthy of attention because they demonstrate the rapid course of Waterhouse-Friderichsen syndrome, leading to sudden death before a clinical or microbiologic diagnosis can be made. Diagnosis of adrenal hemorrhage is often complicated by its nonspecific presentation, but it should nevertheless be considered as a possible cause of back pain in the setting of an acute illness, especially in the absence of other obvious causes. Appropriate hydrocortisone replacement therapy should be based on the patient's symptoms and their daily needs. Moreover, individuals with adrenal insufficiency should be made aware of how to detect an imminent adrenal crisis, and how to adjust their dose of hydrocortisone accordingly [17]. Although prognosis can be extremely poor, if a proper diagnosis is promptly rendered, the patient can be successfully treated [16].



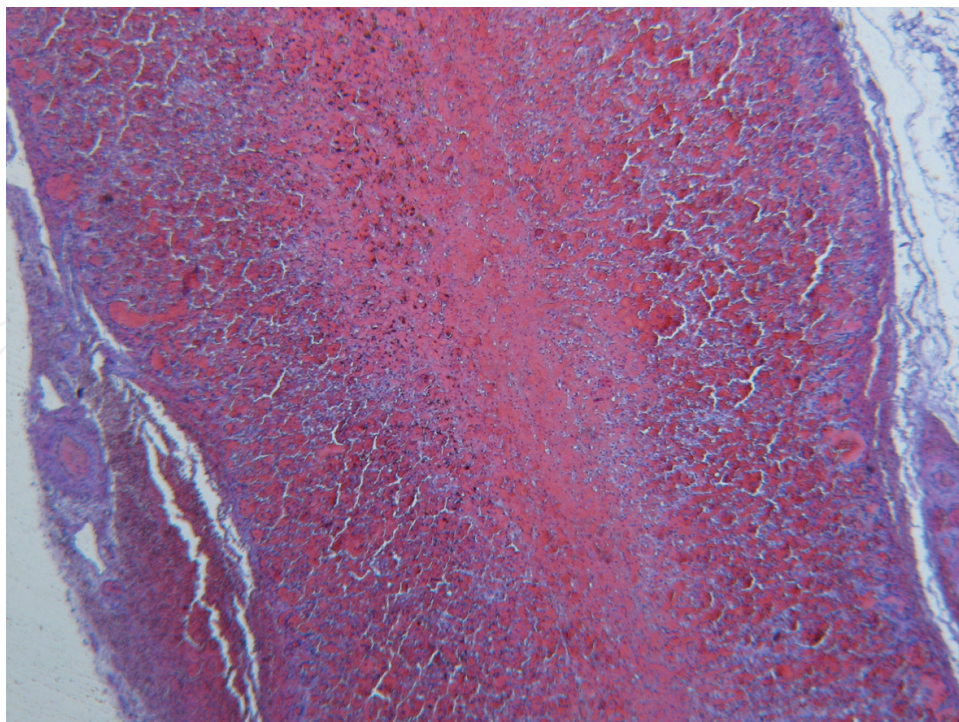
**Figure 3.** Hemorrhagic adrenal glands before their isolation and removal.



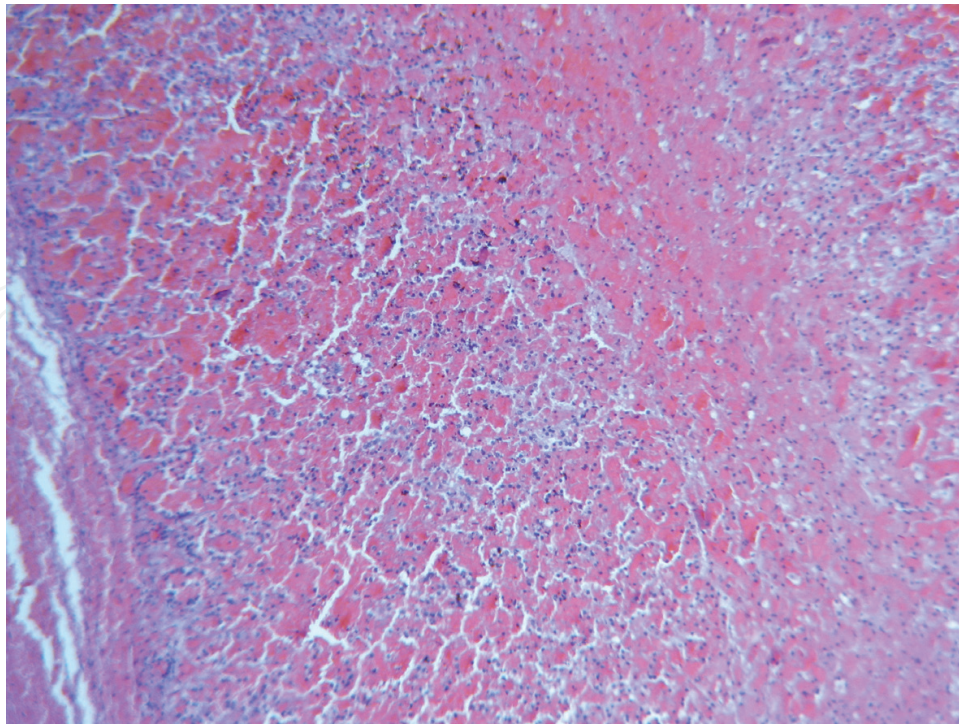
**Figure 4.** Hemorrhagic adrenal glands before their isolation from the kidneys.



**Figure 5.** Isolated hemorrhagic adrenal glands.



**Figure 6.** Massive hemorrhage of the adrenal glands, H&E, 12×.



**Figure 7.** Massive hemorrhage of the adrenal glands, H&E, 60×.

### 3. Hypercortisolism

Cushing's disease and syndrome are associated with an increased morbidity compared to the general population, related to central obesity, insulin resistance, diabetes mellitus, hypertension, hyperlipidemia and osteoporosis, all due to cortisol hypersecretion. There is also an increased cardiovascular risk profile. Moreover, psychiatric disorders have been documented in these patients, ranging from anxiety to major depression [22]. The immunosuppressive effect of cortisol is also associated with an increased susceptibility to infections. Regarding children, despite advances in early diagnosis and treatment of pediatric Cushing's syndrome, a 2.5% mortality rate was identified in a recent study carried out in a large cohort of children referred to an experienced, tertiary care referral center for this condition [23].

Sudden death due to Cushing's disease is very rare but occasionally reported in the literature. In one case report, a woman with previously suspected Cushing's disease presented with atypical psychosis followed by sudden death [24]. The death occurred while the patient was undergoing clinical studies in an endocrine unit, because of suspected Cushing's disease based on physical examination revealing abdominal striae, hirsutism, amenorrhea, acne and buffalo hump, biochemical studies demonstrating hypercortisolism, and CT scan revealing enlarged adrenal glands. An autopsy revealed a small chronic ulcer in the gastric antrum with acute extension into an artery. A basophil pituitary adenoma was also noted weighing 2.1 g. The adrenal glands were both hyperplastic weighing 10 g. The cause of death was determined to be gastrointestinal bleed from an acute ulcer, which was related to the Cushing's disease.

In another interesting case report, a patient was resuscitated from three episodes of ventricular fibrillation secondary to serious hypokalemia caused by lung carcinoma secreting adrenocorticotrophic hormone (ACTH) [25]. This description represents another potential cause of sudden death in patients who may have Cushing's syndrome, which may cause multiple clinical and biochemical derangements.

These two case reports highlight sudden death among patients with differing presentations of Cushing's disease and syndrome. Postmortem investigations are of great importance in determining the cause of death, in which Cushing's syndrome might be previously unknown, and its presentation atypical. Among the causes of sudden death, hypercortisolism must be excluded. It is essential to note the clinical presentation of Cushing's, which includes moon facies, buffalo hump, purple abdominal striae, truncal obesity, hirsutism, weight gain, hypertension, diabetes, and muscular weakness. Typical autopsy findings include enlargement of the pituitary gland and/or the adrenal glands. Alterations encountered in the adrenal glands, in order of frequency, reveal diffuse or isolated hyperplasia (always bilateral), adenoma or carcinoma (usually unilateral). Microscopic examinations are also essential to render the postmortem diagnosis [38].

## 4. Tumors

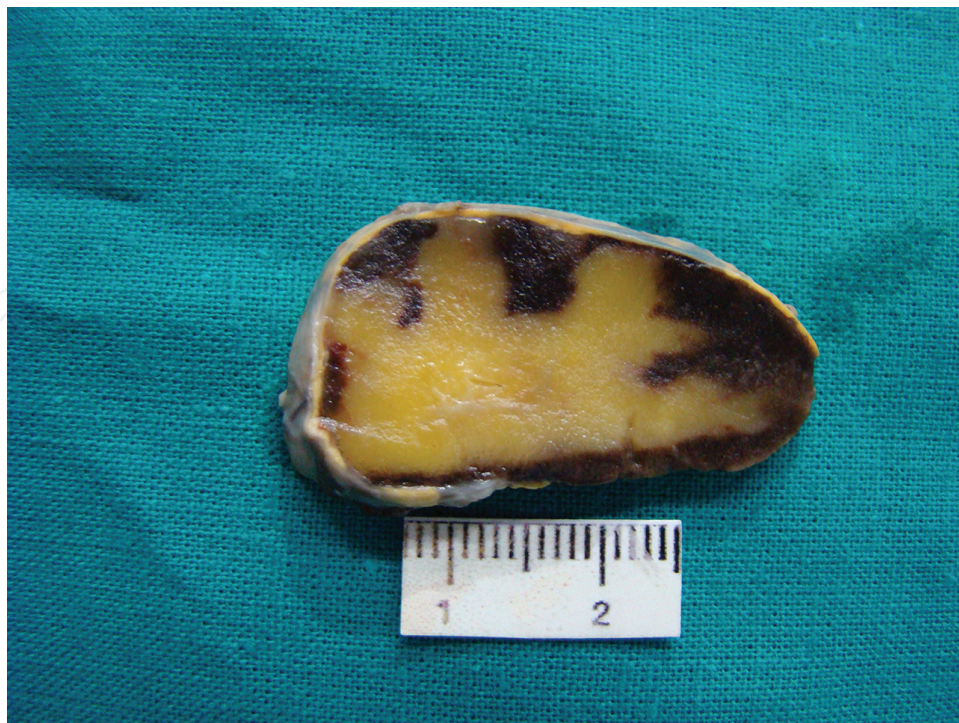Among those that affect the adrenal glands, neuroendocrine tumors are strongly related to the sudden death of patients, characterized by adrenaline or noradrenaline secretion with dire consequences on the cardiovascular system. Other neoplasms can cause Addison's disease in patients, potentially leading to sudden death, because they replace the entire parenchyma of the adrenal gland. Adrenal involvement by tumors arising from other sites most commonly causes adrenal insufficiency.

An interesting example of a benign adrenal tumor that can lead to sudden death is a myelolipoma (**Figures 8–10**).

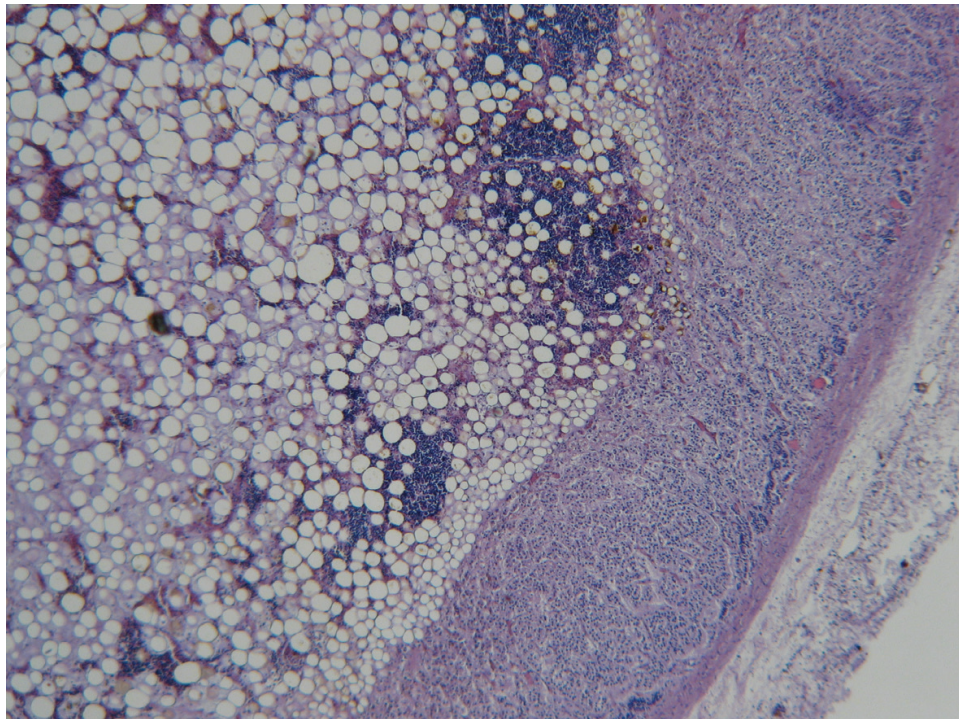
Myelolipoma is a tumor-like growth composed of mature fat tissue and bone marrow elements that occur in adrenal glands as an isolated soft tissue mass. These benign tumors may be associated with endocrine disorders such as hermaphroditism, Cushing's disease, Addison's disease, and obesity of unknown cause. Although giant myelolipomas have been reported in the literature, these tumors rarely measure >5 cm [26].

### 4.1. Pheochromocytomas and paragangliomas

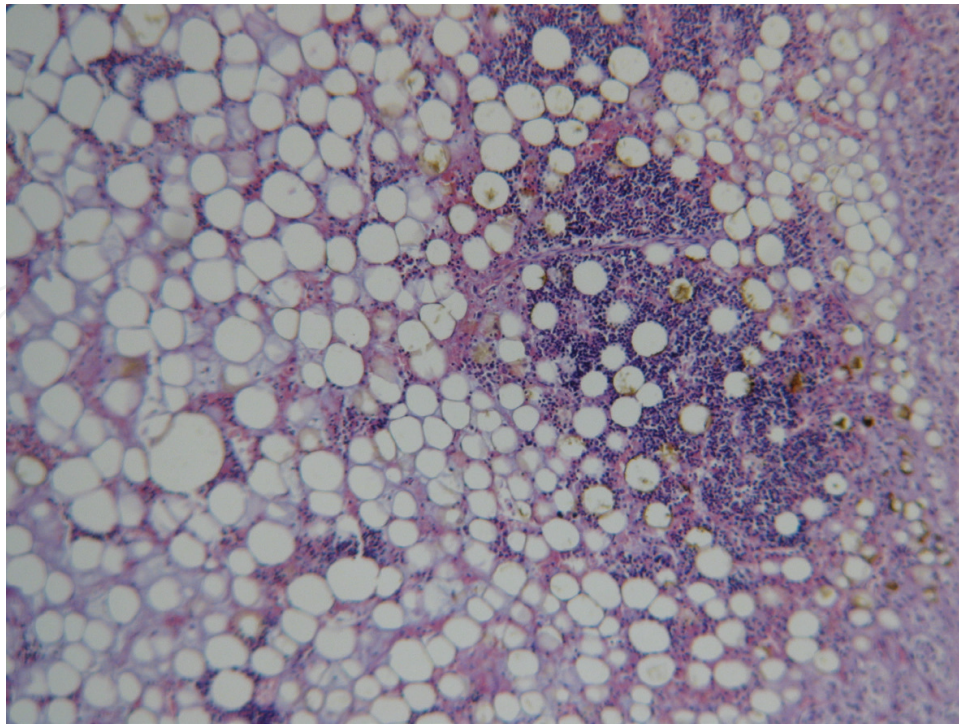
Pheochromocytomas and paragangliomas are neuroendocrine tumors derived from chromaffin cells. Generally, they are rare with a prevalence estimated between 1:6500 and 1:2500, and an annual incidence in the United States of 500–1600 cases per year [27]. In patients with hypertension, they occur in about 0.05–0.1% of them. However, half of all patients have paroxysmal hypertension or normotension, and this probably accounts for only 50% of people harboring pheochromocytoma or paraganglioma. Moreover, their incidence may be even



**Figure 8.** Macroscopic appearance of myelolipoma.



**Figure 9.** Microscopic appearance of myelolipoma, H&E, 60×.



**Figure 10.** Microscopic appearance of myelolipoma, H&E, 120×.

higher due to the lack of diagnosis until postmortem examination; a review of autopsy cases from Australia found that 0.05% of decedents had underlying and unrecognized pheochromocytoma or paragangliomas [28].

Pheochromocytomas that grow within the adrenal medulla are the most common sympathetic ganglia-derived tumors. Conversely, paragangliomas that comprise 10–18% of all chromaffin tumors arise from the neural crest cells [29] and may derive from both parasympathetic and sympathetic ganglia. Head and neck paragangliomas originate from the parasympathetic chain (e.g. carotid body and glomus jugulotympanicus). Sympathetic-derived paragangliomas are located in the mediastinum and subdiaphragmatic regions; they are rare in comparison with parasympathetic-derived tumors.

The classic symptoms of catecholamine hypersecretion consist of headaches, sweating, and palpitations, but many patients present with sustained or paroxysmal hypertension. It has been reported, however, that pheochromocytomas associated with neurofibromatosis type 1 can present with hypotension [30]. Weight loss, myocardial infarction, hyperglycemia, panic attacks, osteolytic bone metastasis, fever, and Raynaud's phenomenon are other classical manifestations of catecholamine-secreting paragangliomas, but only about one-third of patients demonstrate these findings [29], and many paragangliomas are not discovered until autopsy.

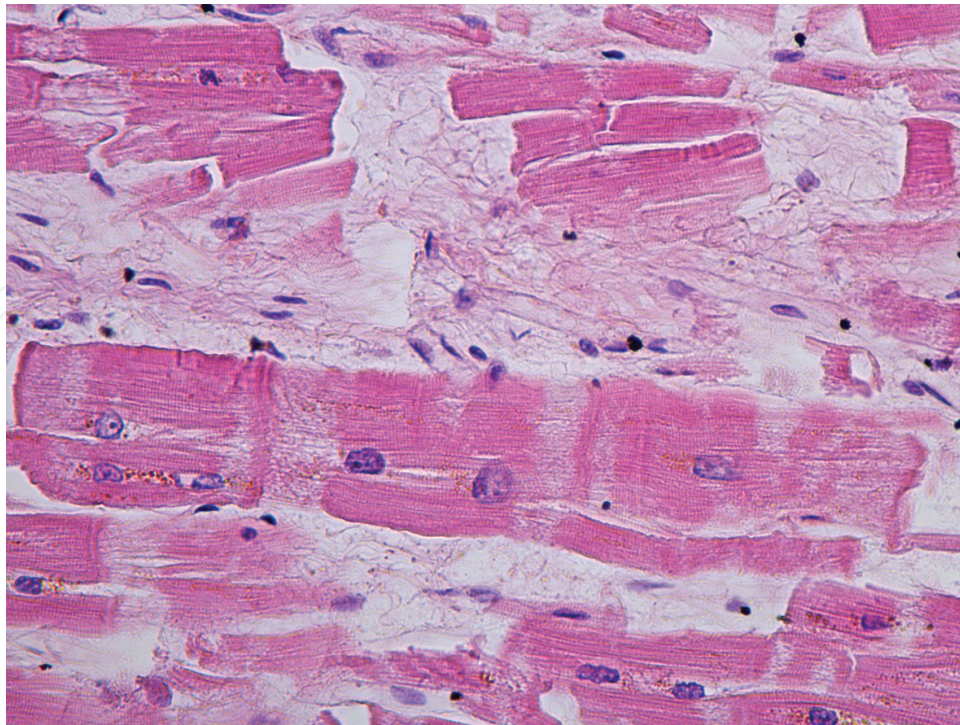
Sudden death due to catecholamine-secreting tumors is very rare, and only a few isolated cases have been reported. The first reported case involves a 42-year-old woman with a 24 h history

of vomiting who died suddenly. At postmortem, a 665 g pheochromocytoma was discovered at autopsy [31]. Since then, several case reports of sudden death in young and old patients harboring underlying pheochromocytomas have been described [32–36]. Interestingly, all of these patients had no history of hypertension or heart disease.

Surprisingly, large tumors, in which many of the catecholamines are metabolized internally and released mostly as by-products such as metanephrine and vanillyl mandelic acid (VMA), are more likely to be asymptomatic [29]. Patients with paragangliomas usually have classic symptoms or unusually labile hypertension that requires medical management; clinical presentation is often the main clue of a pheochromocytoma or paraganglioma, and diagnosis is usually based on the biochemical evidence of catecholamine tumor production (24-h urine metanephrines). Most updated guidelines recommend biochemical tests in symptomatic patients, patients with an adrenal incidentaloma, and patients with a hereditary risk for developing a pheochromocytoma or paraganglioma [27]. If not accompanied by any symptoms, paragangliomas, especially if located in an unusual site, can be easily missed or treated incorrectly as a benign renal or pararenal cyst. In one case report, the first manifestation of such tumor was a massive release of noradrenaline after percutaneous alcohol injection, which was performed to ablate a presumed cyst [37].

The differential diagnosis between pheochromocytoma and paraganglioma can be challenging if the tumor is located close to the upper renal pole. The first consideration is anatomic; it is well known that retroperitoneal paragangliomas can occur anywhere along the paravertebral sympathetic chain, sometimes close to the adrenal gland [38]. During the autopsy, it is important to very carefully explore the adrenal gland, or if a paraganglioma, it must be well preserved. If the tumor and adrenal gland are separate entities, and each one presents with its own capsule, pheochromocytoma can be ruled out, since it arises inside the parenchyma of the adrenal gland. A physiologic and biochemical difference between both tumors exists since pheochromocytomas and paragangliomas can secrete either adrenaline or noradrenaline. Nevertheless, pheochromocytomas produce mainly adrenaline and noradrenaline in minor quantity from the adrenal medulla, and therefore, shows a positive staining for both phenylethanolamine N-methyltransferase (the enzyme which catalyzes the synthesis of adrenaline from noradrenaline), and for dopamine-beta-hydroxylase, that is involved in both catecholamine synthetic chains. In the case of negative staining for phenylethanolamine-N-methyltransferase, and positive staining for dopamine-beta-hydroxylase, the tumor predominantly secretes noradrenaline consistent for a paraganglioma.

In cases of sudden death due to catecholamine-secreting tumors, the external examination is often unremarkable. The decedent may be thin, but not frequently. The autopsy may reveal a tumor within the adrenal gland (pheochromocytoma) or separate from it (paraganglioma). Remarkably, paragangliomas have been found in practically every site along the sympathetic chain [38], even in the organ of Zuckerkandl [39]. Histology commonly reveals cerebral and lung congestion and edema; fibers fragmentation and many contraction bands at the myocardium (**Figure 11**).



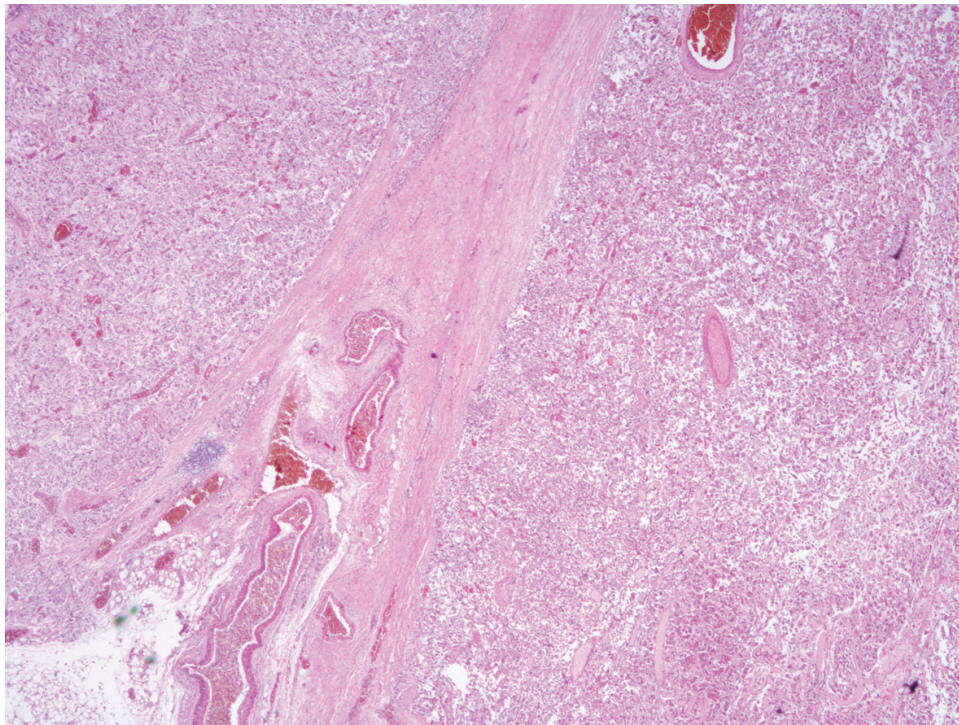
**Figure 11.** Myocardium, HE, 400×.

Both paragangliomas and pheochromocytomas are microscopically characterized by nests of large polygonal cells containing round and small nuclei, separated by highly vascularized fibrous septa (**Figures 12 and 13**).

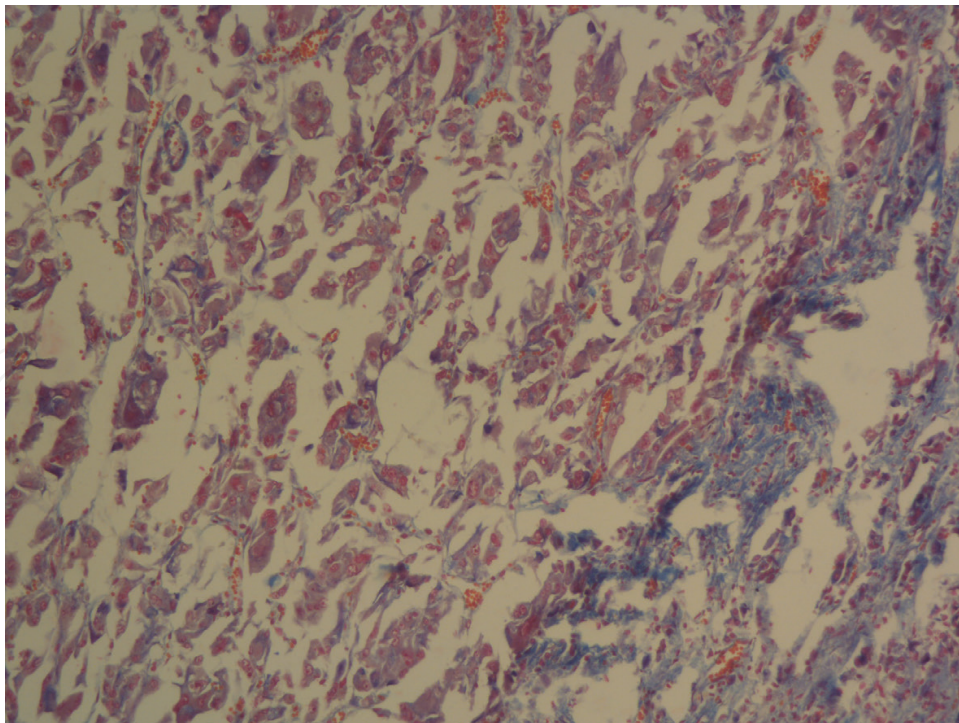
Immunohistochemical examinations show chromaffin cells, chromaffin-A positive (**Figure 14**), containing enzymes involved in the synthesis of catecholamines (**Figure 15**). Chromogranin-A, which is produced only by endocrine and neuroendocrine cells, is the main soluble protein in neurosecretory granules, being co-stored and secreted with catecholamines. Another useful marker for chromaffin tumors is S100 protein (**Figure 16**), a protein specific for cells derived from the neural crest.

#### 4.2. Embryonal neural tumors

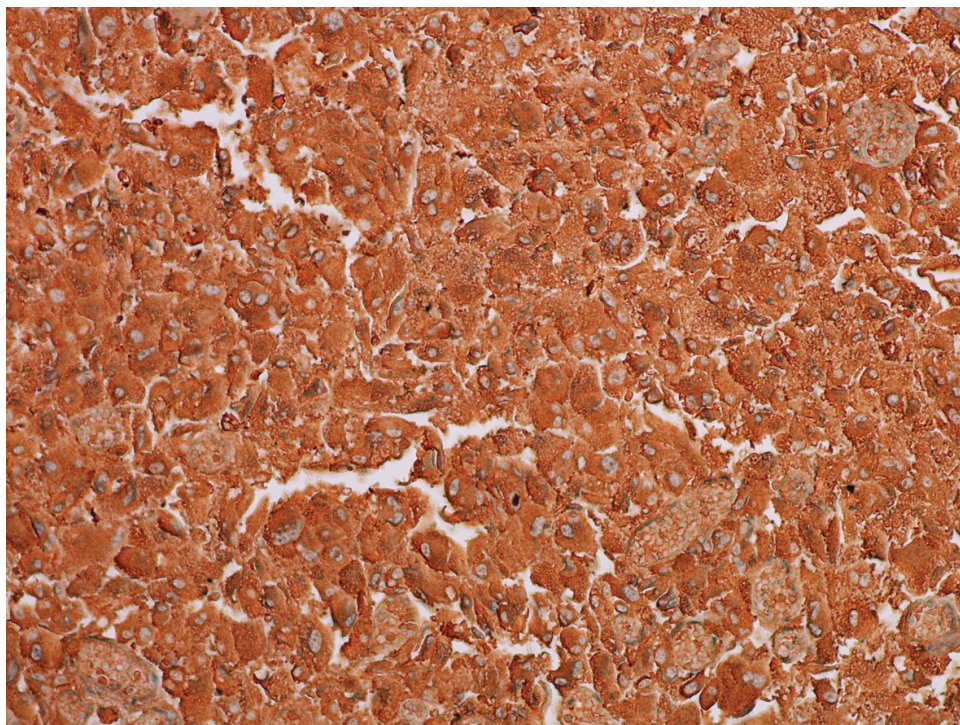
This category encompasses neuroblastoma, ganglioneuroblastoma, and ganglioneuroma. To the authors' knowledge, there is only one case report in the literature regarding sudden death due to one of these tumors. In this sudden death of a 2-year-old child due to an unrecognized neuroblastoma, the autopsy revealed a relatively isolated adrenal mass with associated retroperitoneal hemorrhage. Microscopically, the right adrenal gland was largely composed of necrotic tissue, with only rare residual viable neoplastic cells peripherally and associated hemorrhage. Based on the gross, microscopic and microbiological findings, it was determined that the child developed rapidly lethal hemorrhagic and septic complications from an adrenal gland neuroblastoma [40].



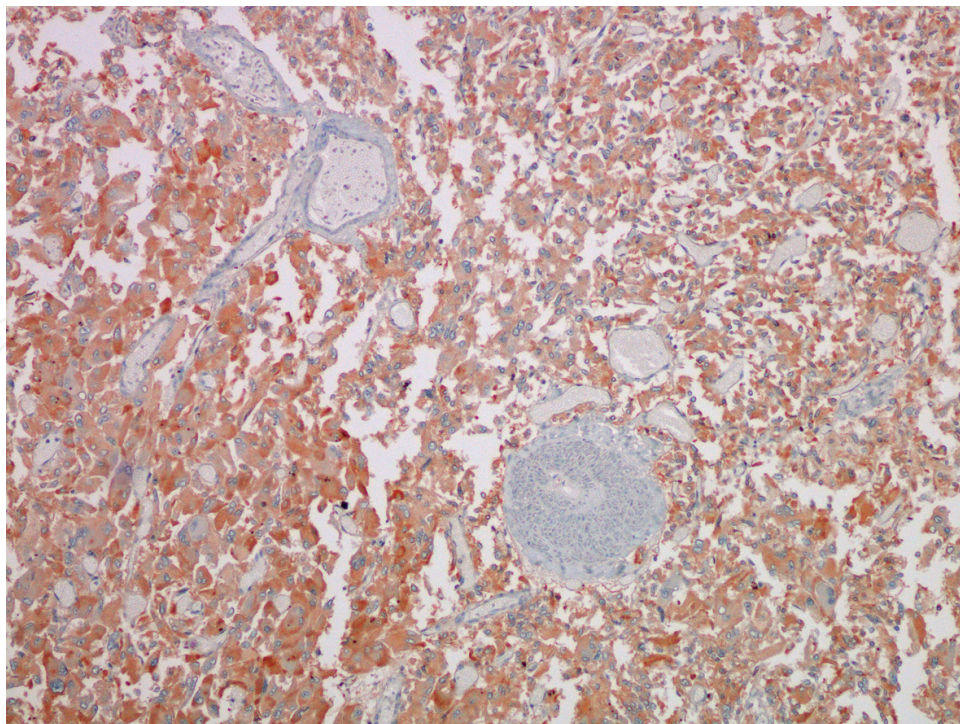
**Figure 12.** Paraganglioma, H&E, 20×.



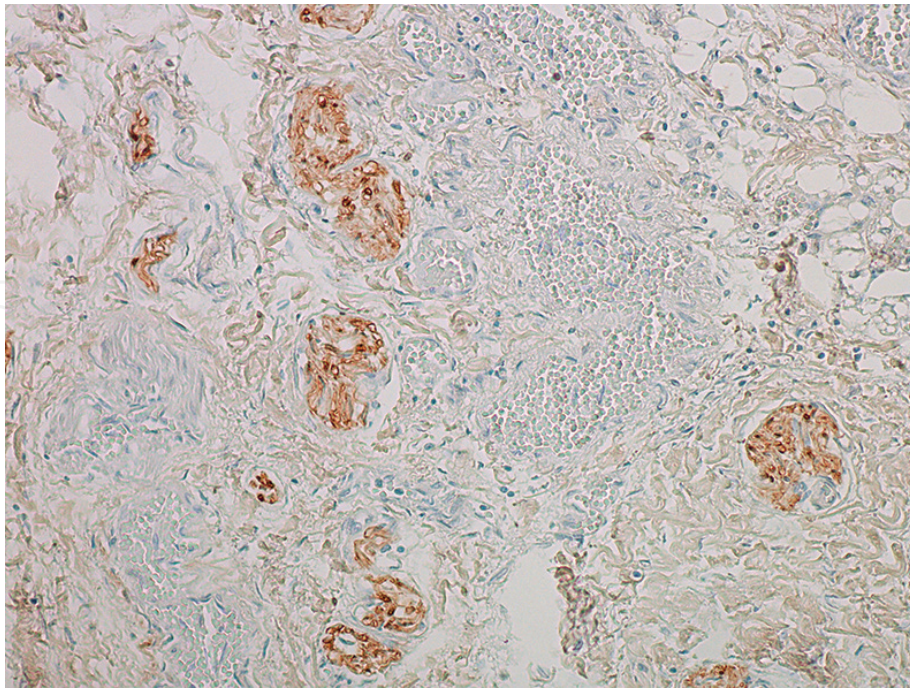
**Figure 13.** pheochromocytoma, H&E, 120×.



**Figure 14.** Antichromogranin-A, 200×. Strong positivity.



**Figure 15.** Antidopamine-beta-hydroxylase staining, 100×.



**Figure 16.** Anti-S100 protein staining, 100×.

## 5. Conclusion

This chapter provides a forensic perspective concerning sudden death due to adrenal gland diseases. Considered rare, it is seldom discussed in the literature but nevertheless encountered in clinical and forensic practice. The leading cause of sudden death related to adrenal gland disease is neuroendocrine tumors derived from chromaffin cells such as pheochromocytoma and paraganglioma, followed by adrenal hypofunction due to adrenal hemorrhage. It is imperative for both clinicians and pathologists alike to consider these diseases in daily practice. In the forensic investigations performed in cases of sudden unexpected death, especially in young individuals, a thorough examination of the adrenal glands must be performed, including macroscopic observation, as well as the microscopy using traditional stainings, such as H&E and immunohistochemistry. Conversely, if hemorrhagic in presentation, microbiologic examination of the adrenal glands should be performed in order to identify any underlying infection or sepsis.

## Author details

Silvia Damiana Visonà\*, Luca Tajana and Antonio Osculati

\*Address all correspondence to: [sd.visona@studenti.uninsubria.it](mailto:sd.visona@studenti.uninsubria.it)

Department of Public Health, Experimental and Forensic Medicine, University of Pavia, Pavia, Italy

## References

- [1] Saukko P, Knight B. Knight's Forensic Pathology. 3rd ed. In: Arnold L, editor. 2004
- [2] Burke MP, Opeskin K. Adrenocortical insufficiency. *The American Journal of Forensic Medicine and Pathology*. Mar 1999;**20**(1):60–65
- [3] Govi A, Fersini F, Tsokos M. Sudden death due to acute adrenal crisis. *Forensic Science, Medicine, and Pathology*. Sep 2015;**11**(3):445–447
- [4] Dettmeyer RB. *Forensic Histopathology Fundamentals and Perspectives*. Berlin Heidelberg: Springer-Verlag; 2011
- [5] Al Sabri AM, Smith N, Busuttil A. Sudden death due to auto-immune Addison's disease in a 12-year-old girl. *International Journal of Legal Medicine*. 1997;**110**(5):278–280
- [6] Clapper A, Nashelsky M, Dailey M. Evaluation of serum cortisol in the postmortem diagnosis of acute adrenal insufficiency. *The American Journal of Forensic Medicine and Pathology*. Jun 2008;**29**(2):181–184
- [7] Palmiere C, de Froidmont S, Mangin P, Werner D, Lobrinus JA. Ketoacidosis and adrenocortical insufficiency. *Journal of Forensic Sciences*. Jul 2014;**59**(4):1146–1152
- [8] Upadhyay J, Sudhindra P, Abraham G, Trivedi N. Tuberculosis of the adrenal gland: A case report and review of the literature of infections of the adrenal gland. *International Journal of Endocrinology*. 6 Aug 2014;**2014**:876037
- [9] Ward S, Evans CC. Sudden death due to isolated adrenal tuberculosis. *Postgraduate Medical Journal*. Jul 1985;**61**(717):635–636
- [10] Hofbauer LC, Heufelder AE. Endocrine implications of human immunodeficiency virus infection. *Medicine*. Sep 1996;**75**(5):262–278
- [11] Rodrigues D, Reis M, Teixeira V, Silva-Vergara M, Filho DC, Adad S, et al. Pathologic findings in the adrenal glands of autopsied patients with acquired immunodeficiency syndrome. *Pathology—Research and Practice*. 2002;**198**(1):25–30
- [12] Trevisan M, Matkovic U, Cusinato R, Toppo S, Palù G, Barzon L. Human cytomegalovirus productively infects adrenocortical cells and induces an early cortisol response. *Journal of Cellular Physiology*. Dec 2009;**221**(3):629–641
- [13] Tormos LM, Schandl CA. The significance of adrenal hemorrhage: Undiagnosed Waterhouse-Friderichsen syndrome, a case series. *Journal of Forensic Sciences*. Jul 2013;**58**(4):1071–1074
- [14] Sahasrabudhe N, Byers R. Massive haemorrhagic adrenal metastases leading to sudden death: A case report. *BMJ Case Reports* [Internet]. 14 Apr 2009;**2009**. DOI: <http://dx.doi.org/10.1136/bcr.06.2008.0190>
- [15] Michon A, Darnige L, Pouchot J, Arlet J-B. Catastrophic antiphospholipid syndrome presenting with bilateral massive adrenal haemorrhage. A case report. *Joint Bone Spine*. Jul 2015;**82**(4):288–289

- [16] Ogino J, Toda J, Onitsuka S, Hashimoto N. Idiopathic bilateral adrenal haemorrhage related to acute adrenal insufficiency. *BMJ Case Reports* [Internet]. 31 May 2013;**2013**. DOI: <http://dx.doi.org/10.1136/bcr-2013-009626>
- [17] McGowan-Smyth S. Bilateral adrenal haemorrhage leading to adrenal crisis. *BMJ Case Reports* [Internet]. 26 Jun 2014;**2014**. DOI: <http://dx.doi.org/10.1136/bcr-2014-204225>
- [18] Lefevre N, Delaunay L, Hingot JL, Bonnet F. Bilateral massive adrenal haemorrhage complicating anaphylactic shock: A case report. *Intensive Care Medicine*. May 1996;**22**(5): 447–449
- [19] Vella A, Nippoldt TB, Morris JC 3rd. Adrenal hemorrhage: A 25-year experience at the Mayo clinic. *Mayo Clinic Proceedings*. Feb 2001;**76**(2):161–168
- [20] Jennewein C, Tran N, Kanczkowski W, Heerdegen L, Kantharajah A, Dröse S, et al. Mortality of septic mice strongly correlates with adrenal gland inflammation. *Critical Care Medicine*. Apr 2016;**44**(4):e190-e199
- [21] Fox B. Disseminated intravascular coagulation and the Waterhouse-Friderichsen syndrome. *Archives of Disease in Childhood*. Oct 1971;**46**(249):680–685
- [22] Graversen D, Vestergaard P, Stochholm K, Gravholt CH, Jørgensen JOL. Mortality in Cushing's syndrome: A systematic review and meta-analysis. *European Journal of Internal Medicine*. Apr 2012;**23**(3):278–282
- [23] Gkourogianni A, Lodish MB, Zilbermint M, Lyssikatos C, Belyavskaya E, Keil MF, et al. Death in pediatric Cushing syndrome is uncommon but still occurs. *European Journal of Pediatrics*. Apr 2015;**174**(4):501–507
- [24] Gerson SN, Miclat R. Cushing disease presenting as atypical psychosis followed by sudden death. *The Canadian Journal of Psychiatry*. Apr 1985;**30**(3):223–224
- [25] Scott BD, Friday KJ. Cushing's syndrome presenting as sudden death. *American Heart Journal*. Feb 1988;**115**(2):487–488
- [26] Yildiz L, Akpolat I, Erzurumlu K, Aydin O, Kandemir B. Giant adrenal myelolipoma: Case report and review of the literature. *Pathology International*. Jun 2000;**50**(6):502–504
- [27] Lee JA, Duh Q-Y. Sporadic paraganglioma. *World Journal of Surgery*. May 2008;**32**(5):683–687
- [28] Abadin SS, Ayala-Ramirez M, Jimenez C, Dickson PV, Liang Y, Lazar AJ, et al. Impact of surgical resection for subdiaphragmatic paragangliomas. *World Journal of Surgery*. Mar 2014;**38**(3):733–741
- [29] Chen H, Sippel RS, O'Dorisio MS, Vinik AI, Lloyd RV, Pacak K, et al. The North American neuroendocrine tumor society consensus guideline for the diagnosis and management of neuroendocrine tumors: Pheochromocytoma, paraganglioma, and medullary thyroid cancer. *Pancreas*. Aug 2010;**39**(6):775–783
- [30] Cecchi R, Frati P, Capri O, Cipolloni L. A rare case of sudden death due to hypotension during cesarean section in a woman suffering from pheochromocytoma and neurofibromatosis. *Journal of Forensic Sciences*. Nov 2013;**58**(6):1636–1639

- [31] Vallance WB. Sudden death from an asymptomatic phaeochromocytoma. *British Medical Journal*. 23 Mar 1957;**1**(5020):686–687
- [32] Verzeletti A, Amariti ML. Sudden death from an asymptomatic phaeochromocytoma: A case report. *Journal of Forensic and Legal Medicine*. May 2011;**18**(4):180–181
- [33] Preuss J, Woenckhaus C, Schwesinger G, Madea B. Non-diagnosed pheochromocytoma as a cause of sudden death in a 49-year-old man: A case report with medico-legal implications. *Forensic Science International*. 27 Jan 2006;**156**(2-3):223–228
- [34] Primhak RA, Spicer RD, Variend S. Sudden death after minor abdominal trauma: An unusual presentation of phaeochromocytoma. *British Medical Journal*. 11 Jan 1986;**292**(6513):95–96
- [35] Chiu C-C, Chen Y-C, Teng T-H, Yang L-H, Chen Y-P, Siao F-Y. Sudden cardiac arrest after minor abdominal trauma: A successful resuscitation in a patient with haemorrhagic phaeochromocytoma. *Resuscitation*. Nov 2009;**80**(11):1323–1324
- [36] Osculati A, Motta M. Morte improvvisa associata a feocromocitoma. *Medicina Legale Quaderni Camerti*. 1999; anno XXI
- [37] Andrello L, Visonà SD, Osculati A. A case of sudden death after ultrasound-guided percutaneous alcohol injection of a paraganglioma mis-diagnosed as a peri-renal cyst. *Forensic Science International*. Aug 2015;**253**:e20-e24
- [38] Rosai J. Rosai and Ackerman's Surgical Pathology. Vol. 1. Mosby, St. Louis, MO, USA, 2004
- [39] Sperry K, Smialek JE. Sudden death due to a paraganglioma of the organs of Zuckerkandl. *The American Journal of Forensic Medicine and Pathology*. Mar 1986;**7**(1):23–29
- [40] Park KU, Prahlow JA. Sudden death due to adrenal neuroblastoma: Child abuse mimic? *Forensic Science, Medicine, and Pathology*. Mar 2011;**7**(1):47–52

IntechOpen