

We are IntechOpen, the world's leading publisher of Open Access books Built by scientists, for scientists

6,900

Open access books available

185,000

International authors and editors

200M

Downloads

Our authors are among the

154

Countries delivered to

TOP 1%

most cited scientists

12.2%

Contributors from top 500 universities



WEB OF SCIENCE™

Selection of our books indexed in the Book Citation Index
in Web of Science™ Core Collection (BKCI)

Interested in publishing with us?
Contact book.department@intechopen.com

Numbers displayed above are based on latest data collected.
For more information visit www.intechopen.com



Radioprotective Effect of Vitamin C as an Antioxidant

Tetsuo Yamamoto and Manabu Kinoshita

Additional information is available at the end of the chapter

<http://dx.doi.org/10.5772/intechopen.68988>

Abstract

Vitamin C is known as a potent antioxidant. We studied vitamin C as a radioprotective agent, focusing on its antioxidative effect. When the body is exposed to radiation, free radicals and reactive oxygen species (ROS) are produced and oxidize cell components, resulting in cell damage. Vitamin C has the potential to scavenge these radical products, thereby protecting against radiation-induced cell damage. We investigated the effects of vitamin C on radiation-induced gastrointestinal (GI) syndrome in mice. The mice received whole-body irradiation followed by bone marrow transplantation 24 h after exposure. Despite avoiding bone marrow failure, the mice eventually died of GI syndrome. Pretreatment with *per os* administration of high-dose vitamin C effectively mitigated radiation-induced GI syndrome and improved mouse survivals, while *per os* post-treatment with vitamin C was ineffective, presumably due to impaired absorption from the radiation-damaged intestine. We also investigated the effect of post-exposure treatment with intraperitoneal administration of vitamin C on radiation-induced bone marrow dysfunction in mice. Intraperitoneal administration with high-dose vitamin C, even at 24 h after whole-body irradiation, was still effective in avoiding bone marrow dysfunction, thereby increasing mouse survival after radiation. In conclusion, administration of high-dose vitamin C effectively reduced the radiation lethality in mice.

Keywords: antioxidant, radioprotectant, acute radiation syndrome, gastrointestinal syndrome, hematopoietic syndrome

1. Introduction

Since the discovery of radiation at the end of nineteenth century, radiation has been used in various fields, such as medicine, industrials, and agriculture among others. While such efforts

have dramatically improved our level of living, radiation has also unfortunately been used to develop nuclear weapons. In addition, accidents have occurred at nuclear power plants that have resulted in catastrophic disasters [1–5]. Because of the accident at Fukushima Dai-ichi Nuclear Power Plant in Japan, many residents near the nuclear plant had to be evacuated and still cannot return to their homes [6].

Ionizing radiation affects the human body in two ways. It affects the body directly by cutting DNA chains, resulting in cell injuries. To reduce the direct radiation damage, lead is used to protect from gamma rays, and water or boron is also used to protect from neutrons. Physical protection is essential to prevent the direct effects of radiation. It also affects the body indirectly, as when radiation hits water molecules in host cells, it produces large amounts of free radicals and reactive oxygen species (ROS), which then oxidize the cell components, resulting in cell injuries [7–10] (Figure 1).

To reduce/mitigate the indirect effects of radiation, it is essential to scavenge the generated free radicals or ROS [11, 12]. As host cells have abundant antioxidative enzymes by nature, free radicals and ROS generated under normal conditions are easily scavenged. However, if a body is exposed to radiation and exaggerated amounts of free radicals and ROS are produced, they cannot be entirely scavenged by intrinsic antioxidative enzymes. In such a situation, the administration of an antioxidative product can facilitate scavenging and prevent cell damage due to radiation. Many antioxidative products are reported to have radioprotective effects [13–17]. In this section, we describe the radioprotective effects of vitamin C, which is one of the strongest antioxidative agents [18–20] (Figure 1).

Vitamin C was originally discovered as a medical treatment for scurvy. It has several pharmacological actions, including an antioxidative effect. Nowadays, vitamin C is widely used as an additive in many foods. Although most animals can synthesize vitamin C by themselves, some primates, including human have lost the ability to produce vitamin C and so need to consume it in some form [21, 22].

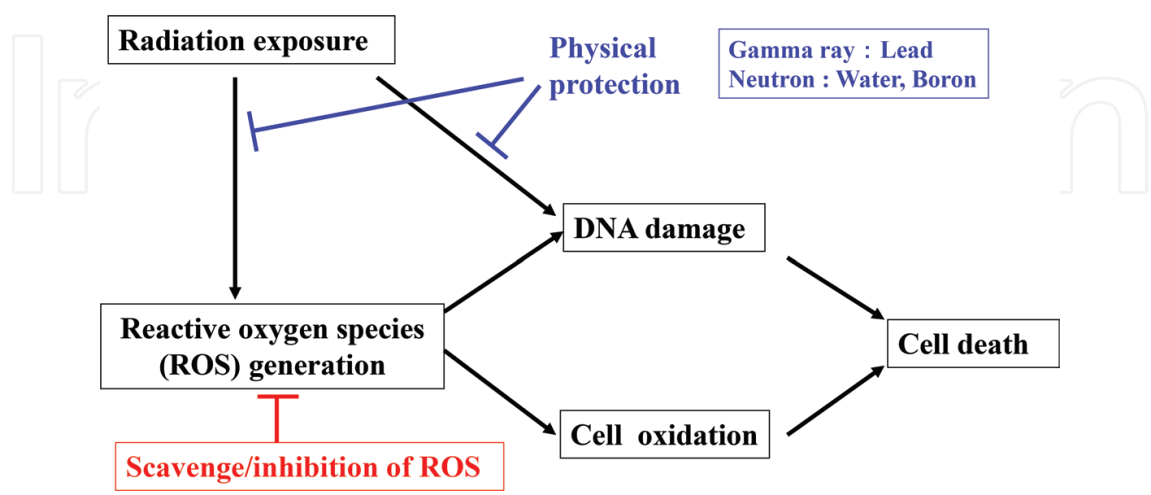


Figure 1. Our strategy for the protection against radiation injury.

Acute radiation syndrome occurs when a host is exposed to high-dose radiation in a short period of time. This syndrome can develop even in animals (e.g., mice) that can synthesize vitamin C by themselves, as deficiency of antioxidants necessarily occurs after massive radiation exposure. Hematological syndrome, gastrointestinal (GI) syndrome, and demagogical syndrome are highly frequent symptoms. The pathophysiology of acute radiation syndrome is basically caused by a stem cell disorder, which has a short cycle of cell turn over [23, 24].

Our group investigated the antioxidative effect of vitamin C on irradiated hosts using a mouse model.

2. Effects of pretreatment with *per os* (p.o.) administration of vitamin C on GI syndrome in whole-body-irradiated mice

We investigated the effect of vitamin C on radiation-induced GI syndrome in mice receiving whole-body irradiation (WBI). We found that pretreatment with vitamin C significantly improved the GI syndrome, thereby rescuing mice that had undergone bone marrow transplantation from lethal radiation exposure [18].

2.1. Bone marrow transplantation alone cannot rescue mice from WBI at 14 Grays

When the mice were exposed to WBI at 6–14 Gray (Gy), 80% of mice survived after WBI at 6 Gy, but no mice survived at doses of ≥ 8 Grays (Gy) (**Figure 2A**). However, when the mice received bone marrow transplantation (BMT) at 24 h after WBI, their mortality were drastically reduced and most mice survived (8 and 10 Gy, 100% survival; 12 Gy, 75% survival). After exposure of WBI at 8–12 Gy, the mice presumably died of bone marrow dysfunction, namely hematopoietic syndrome, and thereby BMT was effective in these mice. Nevertheless, BMT was not effective in the mice after WBI at 14 Gy (**Figure 2B**).

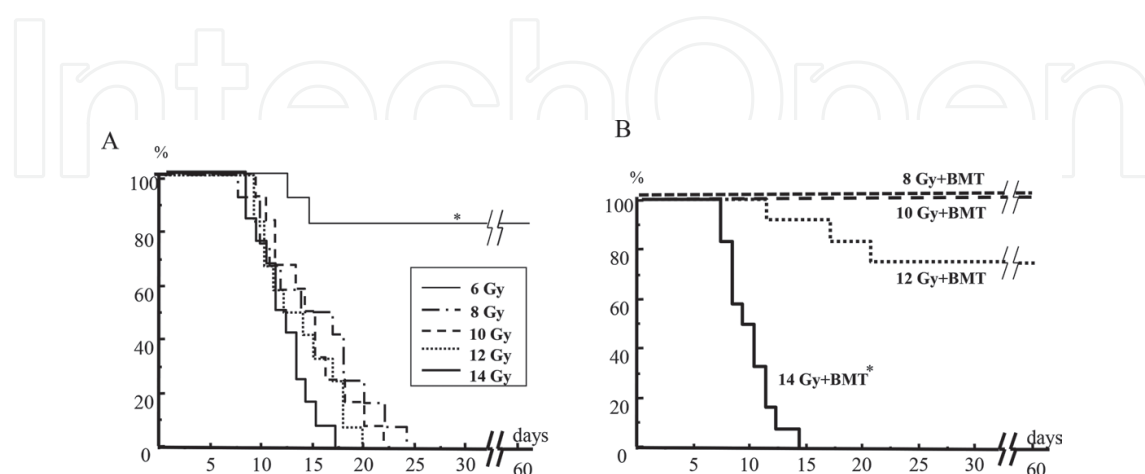


Figure 2. The mouse survival after WBI (A) and the effect of BMT on the survival after WBI (B) [18].

2.2. Whole-body-irradiated mice at 14 Gy showed marked denudation of the intestinal mucosa and bone marrow aplasia

By the pathological examination, severe bone marrow aplasia was observed in mice at 7 days after WBI at 8 Gy compared to unirradiated control mice (0 Gy) (**Figures 3A-a, B-a**), although their intestinal mucosae were still intact even after 8 Gy radiation exposure (**Figures 3A-b, c, B-b, c**). However, when the mice were expose to WBI at 14 Gy, marked denudation of the intestinal mucosae were observed in them at 7 days after irradiation (**Figures 3C-b, c**, arrow-heads) accompanied with severe bone marrow aplasia (**Figure 3C-a**). These mice suffered from the radiation-induced GI damage and presumably died of this GI damage after WBI at 14 Gy, despite rescuing bone marrow failure by BMT.

2.3. Pretreatment but not posttreatment with vitamin C improved the mouse survival after 14-Gy WBI, in combination with BMT

To examine the dose response effects of vitamin C on the irradiated mice, we p.o. administered 1.5, 15, 150 and 1500 mg/kg/day of vitamin C for 3 days before 14-Gy WBI to mice, followed by BMT at 24 h after radiation. Pretreatment with 150 mg/kg/day of vitamin C was able to rescue some subjected mice (42% survival), while other doses of pretreatment with vitamin C

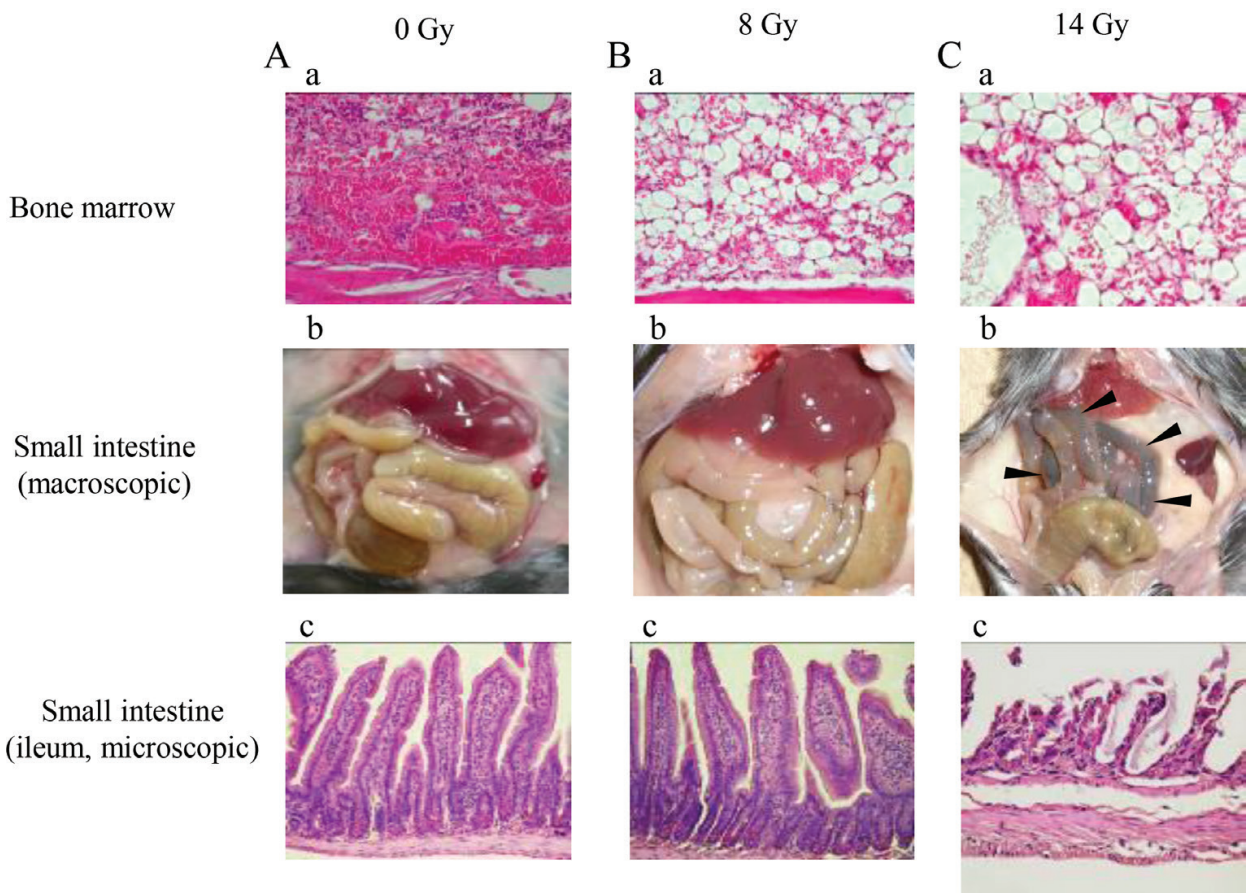


Figure 3. Radiation-induced damage to the bone marrow and small intestine in mice 7 days after radiation [18].

rescued no mice. Pretreatment with 1500 mg/kg/day of vitamin C also did not improve the mouse survival after WBI at 14 Gy. Such a massive administration of vitamin C may be conversely harmful for the host. We next studied the effect of posttreatment with vitamin C on the irradiated mice. Mice were p.o. administered with 150 mg/kg/day of vitamin C for 3 days after 14-Gy WBI and received BMT. Posttreatment with vitamin C did not affect the survival (0% survival) (**Figure 4**), although the pretreatment with the same doses of vitamin C was effective. When the mice were only pretreated with vitamin C and did not receive BMT, no mice survived after 14-Gy WBI (**Figure 4**). Of note: these mice died of bone marrow aplasia after radiation, not GI damage.

2.4. Pretreatment with vitamin C markedly improved the radiation-induced intestinal damage, thereby rescuing mice from lethal WBI at 14 Gy, in combination with BMT

BMT following 14-Gy WBI remarkably improved bone marrow aplasia in the mice 7 days after radiation. However, these mice showed severe degenerative changes in the intestinal mucosa (**Figures 5A-a, b**). Pretreated with vitamin C for 3 days before 14-Gy WBI without BMT markedly improved the mucosal degeneration in the intestine but did not improve the bone marrow aplasia in mice (**Figures 5B-a, b**). Notably, when mice were pretreated with vitamin C and received BMT following 14-Gy WBI, marked improvements in both bone marrow aplasia and intestinal mucosal degeneration were noted (**Figure 5C-b**).

2.5. Pretreatment with vitamin C prevented the intestinal tissue damage of the mice receiving 14-Gy WBI followed by BMT

The mice showed significantly lower villus heights and crypt counts per circumference in the intestine after 14-Gy WBI (but not those receiving 8-Gy WBI) (**Figure 6A, B**). Although

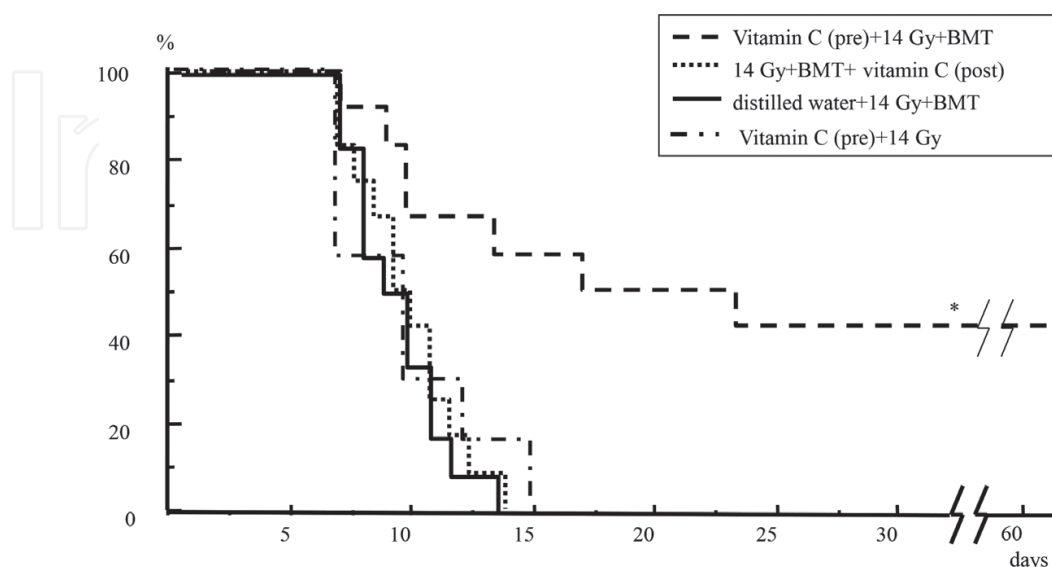


Figure 4. The effect of pre and posttreatment with vitamin C on the mouse survival after WBI [18].

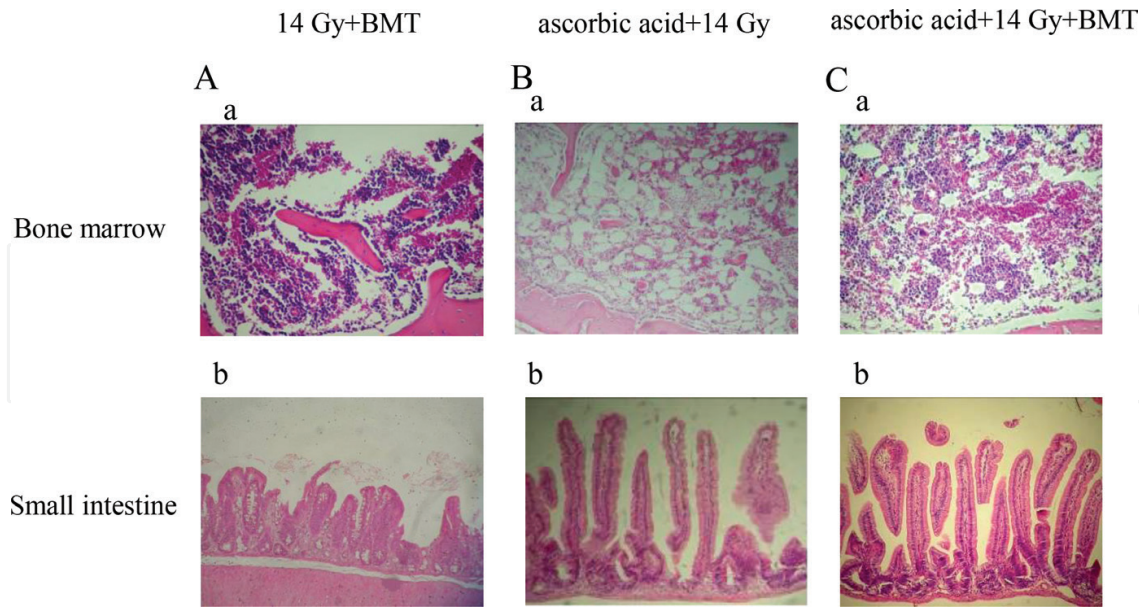


Figure 5. The effect of pretreatment with vitamin C or BMT following WBI on the bone marrow or small intestine in irradiated mice [18].

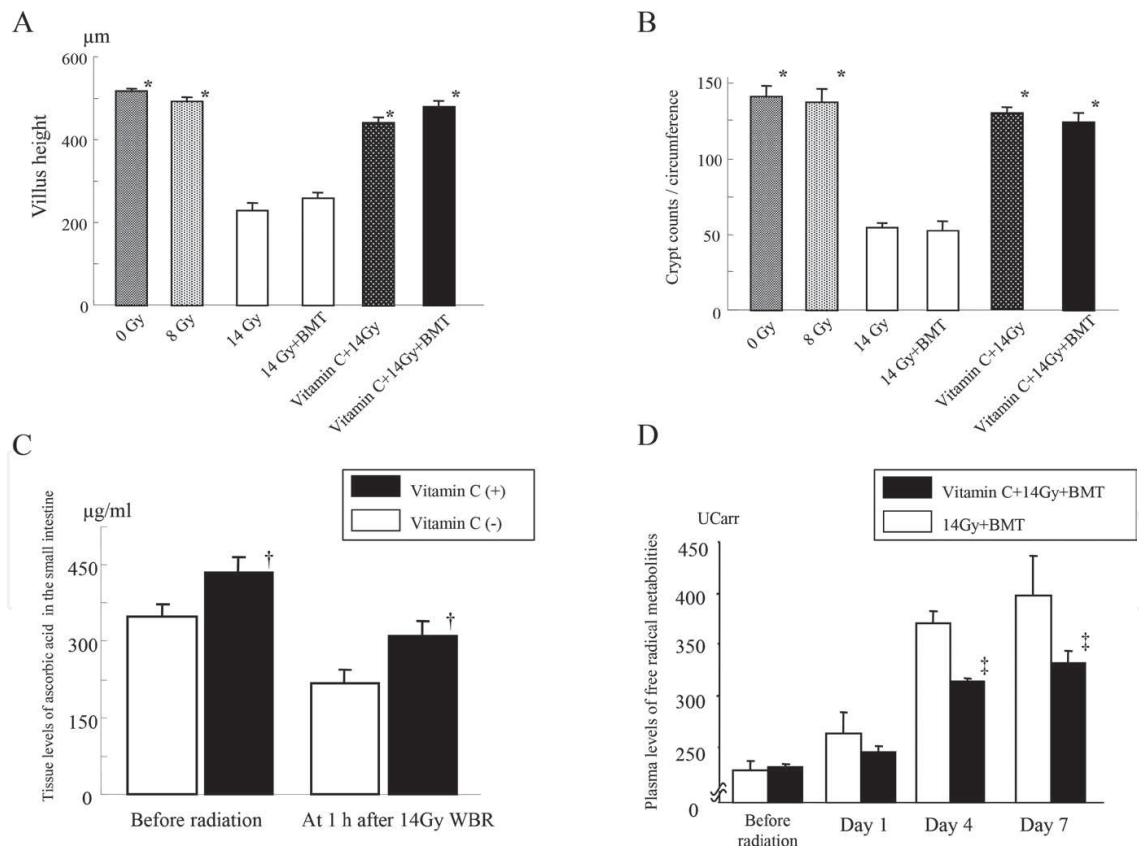


Figure 6. Villus height (A), and crypt counts (B) of the small intestine in mice. The tissue vitamin C levels in the small intestine (C), and the production of free radical metabolites in mice irradiated at 14 Gy (D) [18].

treatment with BMT alone following 14-Gy WBI did not affect these degenerative changes, pretreatment with vitamin C markedly improved them (**Figure 6A, B**). Both the mice that were pretreated with vitamin C and received BMT following 14-Gy WBI also showed significant improvements (**Figure 6A, B**).

2.6. Oral administration of vitamin C increased the tissue concentration of vitamin C in the small intestine

Per os administration of vitamin C for 3 days significantly increased the plasma concentrations of vitamin C in the treated mice than that of untreated controls (57 ± 11 versus 30 ± 8 μmL , $P < 0.05$). Next, the vitamin C levels in tissues of small intestine were examined. To measure vitamin C levels in tissue of small intestine, a sample of small intestine (0.7 g) was removed from each mouse immediately after sacrifice and homogenized in 5.4% metaphosphoric acid (9.8 g). Vitamin C levels of the homogenate supernatant were measured in the SRL laboratory (Tokyo, Japan) using high performance liquid chromatography (HPLC). Pretreatment with vitamin C significantly increased the tissue concentrations of vitamin C in the small intestine just before radiation (**Figure 6C**). Interestingly, the tissue vitamin C levels were decreased at 1 h after radiation in not only vitamin C-pretreated mice but also in untreated control mice (**Figure 6C**), indicating the critical consumption of tissue vitamin C by irradiation. Nevertheless, the mice pretreated with vitamin C still showed significantly higher tissue vitamin C levels than the untreated control mice (**Figure 6C**).

2.7. Pretreatment with vitamin C suppressed a radiation-induced increase in the free radical metabolites in mouse plasma

To measure free radical metabolites in the plasma, we used the d-ROMs test (Diacron, Grosseto, Italy). It is a spectrophotometric method that assesses overall oxidative stress by measuring total hydroperoxide levels, given that hydroperoxides are intermediate oxidative products of lipids, peptides, and amino acids. We diluted 0.02 mL plasma in 1 mL acetate-buffered solution. Hydroperoxide groups react with the transition metal ions liberated from the proteins in the acidic medium, and are converted to alkoxyl and peroxy radicals according to the Fenton reaction. These newly formed radicals, the quantities of which are directly proportional to those of the peroxides, were trapped chemically with 0.02 mL chromogen (N,N-diethyl-para-phenylenediamine), leading to the formation of a radical cation of this chromogen. The purple color resulting from this reaction over time was monitored in a spectrophotometer (Wismarll FRAS4, Tokyo, Japan) at 505 nm. The results of this method were expressed in conventional units (Carratelli units [UCarr]). Although free radical metabolites gradually increased in the plasma of untreated mice after radiation, pretreatment with vitamin C significantly suppressed the increase in free radical metabolites at 4 and 7 days after radiation (**Figure 6D**). Posttreatment with vitamin C did not suppress the increase in free radical metabolites in mice.

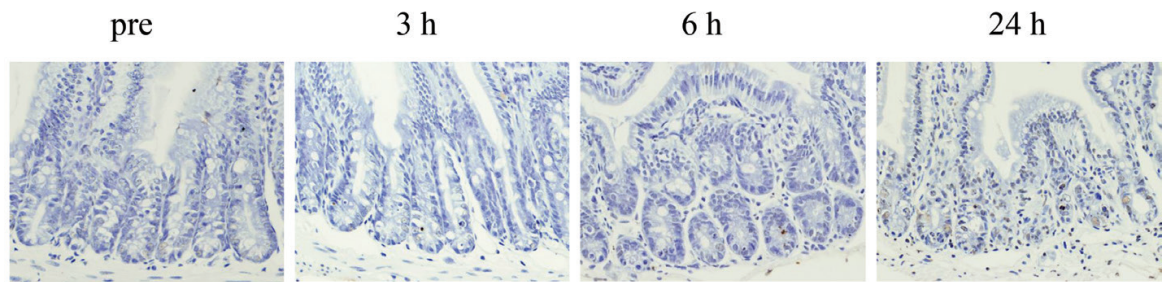
2.8. Pretreatment with vitamin C suppressed the radiation-induced DNA damage in the crypt epithelial cells of the mouse’s small intestine

To examine the effect of pretreatment with vitamin C on the DNA damage in the mouse’s small intestine after WBI, antisingle stranded (ss) DNA was stained in the samples of small intestine, using polyclonal rabbit anti-ssDNA (A4506, DAKO, Glostrup, Denmark). In the mice without vitamin C pretreatment, the number of positive-stained cells for ssDNA increased in the epithelial crypts of the small intestine at 6 h after radiation and further increased at 24 h (**Figure 7**). In contrast, pretreatment with vitamin C significantly suppressed the increase in ssDNA positive-stained cells (**Figure 7**). In these mice, the epithelial cells in the crypts of small intestines only showed slightly positive staining for ssDNA at 24 h after radiation (**Figure 7**). Radiation-induced DNA damage of the mouse intestinal crypt cells may be effectively inhibited by pretreatment with vitamin C.

3. The drastic effect of combination therapy with p.o. administration of vitamin C on the GI syndrome in mice receiving abdominal radiation

Although the survival rates of the mice receiving WBI at 14 Gy followed by BMT were increased by pretreatment with vitamin C, more than half of the mice still died of radiation-induced GI damage. We therefore modified the administration manner of vitamin C in order to augment its radioprotective potential.

Vitamin C (+)



Vitamin C (-)

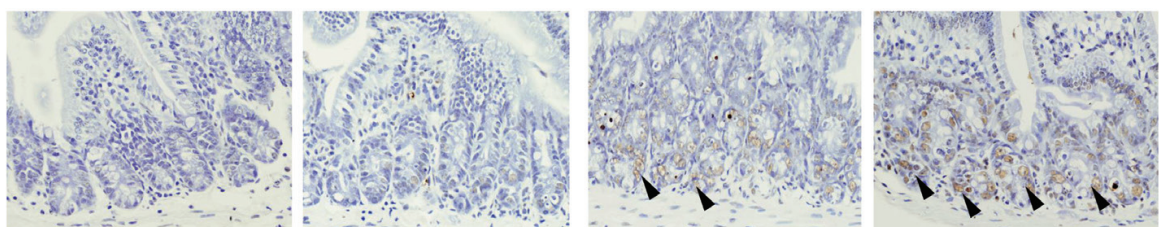


Figure 7. Radiation-induced DNA damage in the small intestines of mice irradiated with 14 Gy [18].

We used an abdominal radiation model that was not complicated with bone marrow damage. Therefore, this model does not require murine sacrifice as a donor of bone marrow cells and is able to simplify the effects of the injury and treatment. In addition, abdominal radiation is frequently performed on patients suffering from abdominal malignancy. It is therefore rational to research and develop an effective therapy for radiation-induced GI damage using a model of abdominal radiation. Although posttreatment with vitamin C alone was ineffective in our previous study, combined therapy of pre and posttreatment with vitamin C improved the survival rates slightly after abdominal radiation. We also added one-shot engulfment (boosting) of vitamin C 8 h before radiation in order to effectively increase the tissue vitamin C levels at the time of radiation exposure. As a result, we were able to elicit a remarkable radioprotective effect against radiation-induced lethal GI damage (100% survival) by combination therapy.

3.1. Abdominal radiation at 10–12 Gy was not lethal for mice, while the same radiation doses of WBI were lethal

As we described above, no mice survived after WBI at doses of ≥ 8 Gy (**Figure 2A**). In contrast, all mice survived after abdominal radiation even at 10 Gy, but no mice survived after abdominal radiation at ≥ 13 Gy (**Figure 8**).

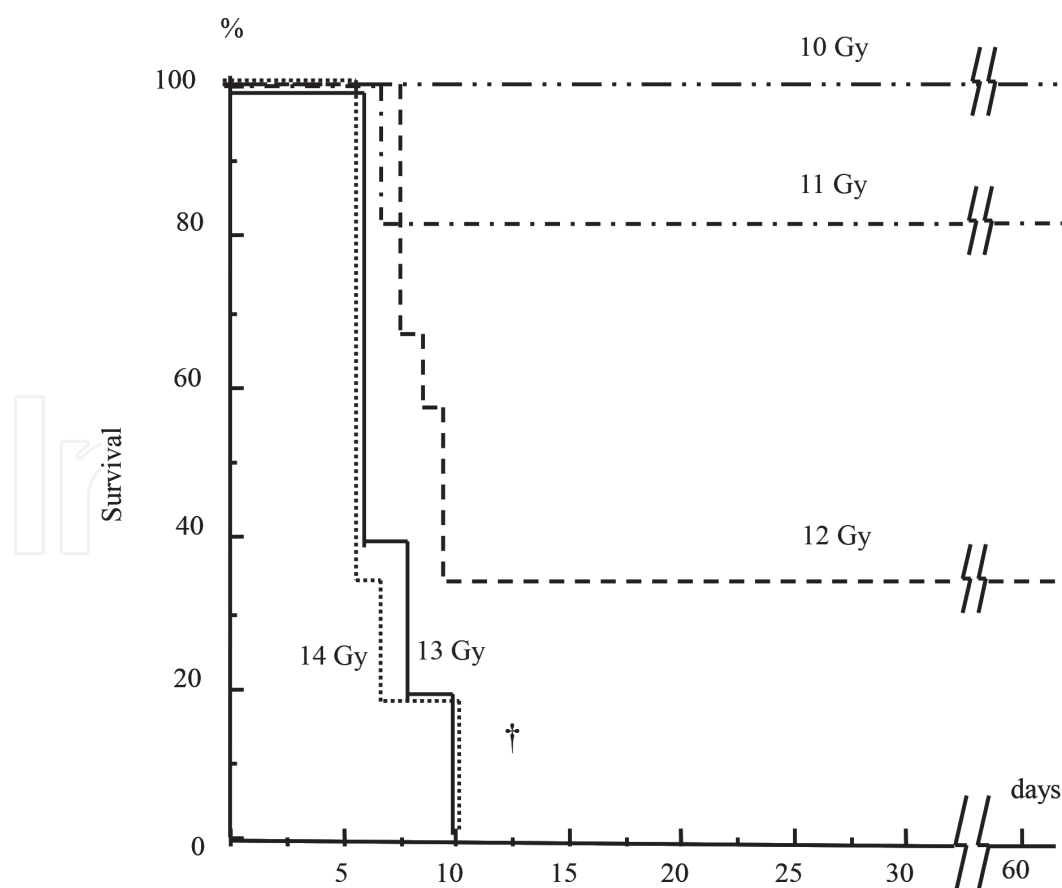


Figure 8. The survival of mice after abdominal radiation [19].

3.2. Abdominal radiation at 13 Gy caused lethal GI damage without inducing bone marrow aplasia

Severe bone marrow aplasia was observed in the lumbar vertebrae, the sternum, and the femur in mice at 7 days after WBI at 8 Gy (**Figure 9**). In contrast, the mice after abdominal radiation at 13 Gy retained a substantial number of bone marrow cells in the sternum and femur but not in the lumbar vertebrae that was directly exposed to a substantial dose during abdominal radiation (**Figure 9**). Bone marrow function may persist even after lethal abdominal radiation (13 Gy). However, marked denudation of the gastrointestinal mucosa, especially the ileac mucosa, was observed in the mice at 7 days after abdominal radiation at 13 Gy (**Figure 9**). In contrast, the mice receiving lethal WBI at 8 Gy did not show such severe intestinal damage (**Figure 9**). Abdominal radiation thus induced severe GI damage but not extensive bone marrow damage in mice.

3.3. Abdominal radiation at 13 Gy restored the white blood cell (WBC) counts but not the plasma citrulline levels in mice

WBC counts transiently decreased at 1–3 days after abdominal radiation at 11–13 Gy but increased in mice beyond 5 days after abdominal radiation (**Figure 10A**). The mice receiving

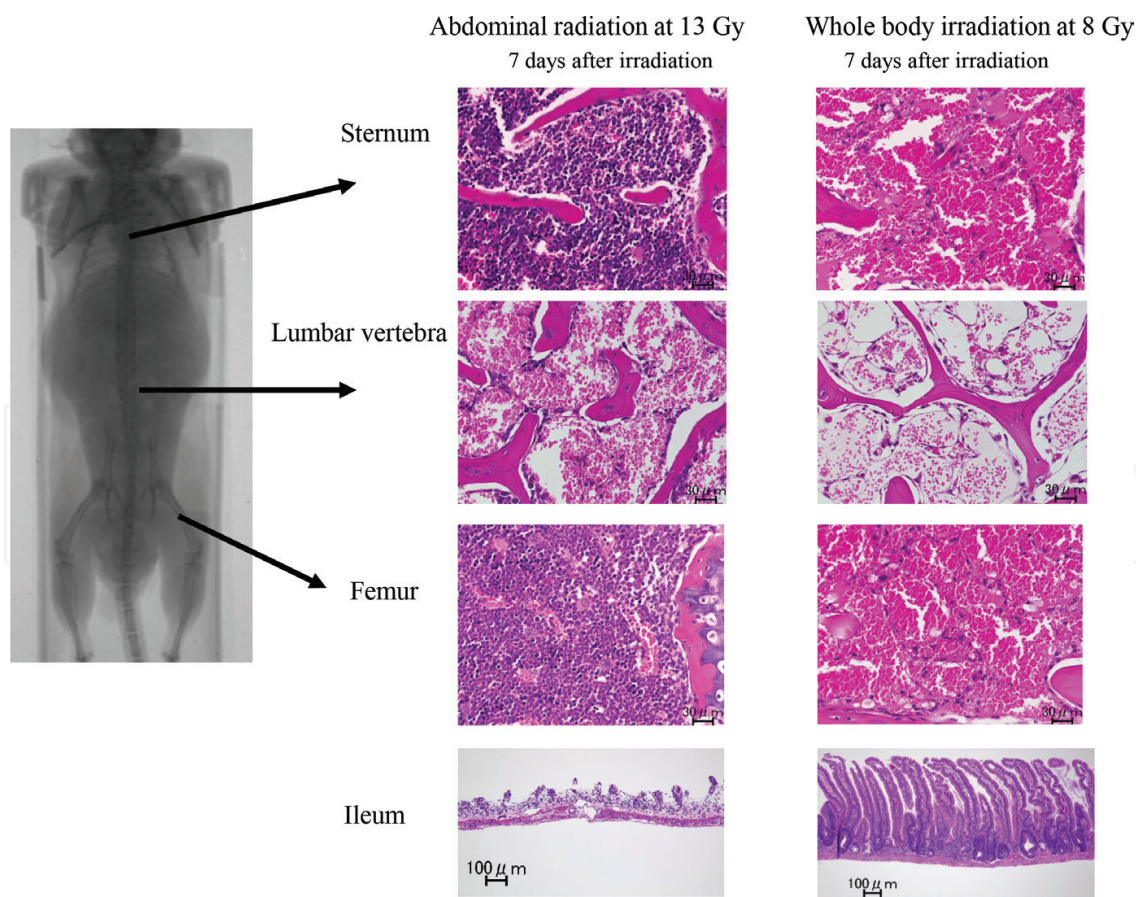


Figure 9. The pathological findings of the bone marrow and ileum in mice after abdominal radiation at 13 Gy or WBI at 8 Gy [19].

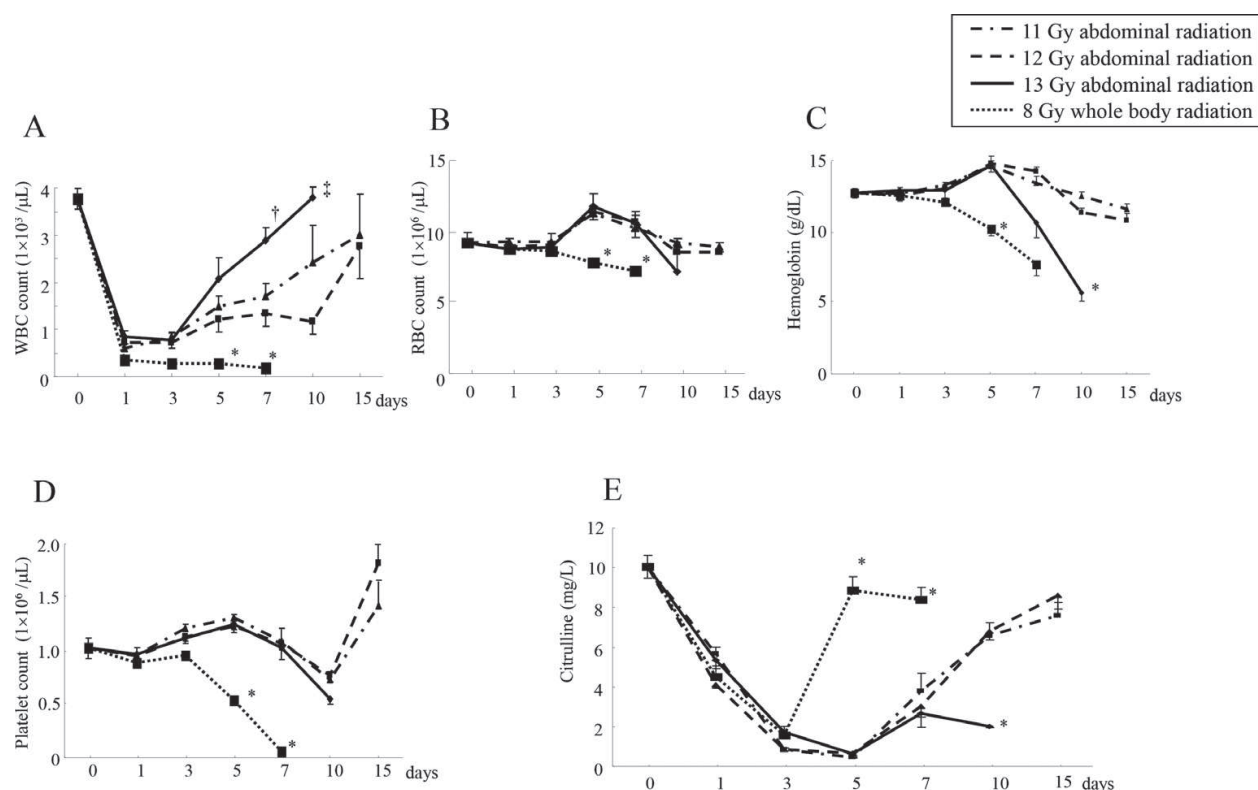


Figure 10. The changes in the hematological parameters and plasma citrulline levels after abdominal radiation [19].

WBI at 8 Gy did not show such a restoration of the WBC counts and eventually died of irreversible lethal bone marrow damage (**Figure 10A**). The red blood cell (RBC) counts as well as the hemoglobin (Hb) levels were also increased around 5–7 days after abdominal radiation at 11 and 12 Gy (**Figure 10B, C**), whereas such increases in the RBC counts or Hb levels were not observed in the mice after 8-Gy WBI (**Figure 10B, C**). Interestingly, the mice showed severe anemia, as assessed by the RBC counts and Hb levels, at 10 days after abdominal radiation at 13 Gy due to gastrointestinal bleeding and subsequently died (**Figure 10B, C**). The platelet counts did not obviously decrease after abdominal radiation at 11–13 Gy, while in contrast, those counts markedly decrease after WBI at 8 Gy (**Figure 10D**). Abdominal radiation, even at 13 Gy (which is lethal), may not cause severe suppression of the bone marrow cells in mice. Plasma citrulline level was measured using a fully automated amino acid analyzer (JLC-500/V2, Nihon Denshi, Tokyo, Japan). It can be reportedly utilized as a biomarker of intestinal failure after massive resection of the small intestine. Therefore, the changes in the plasma levels may be an effective biomarker of radiation-induced GI syndrome [19]. Although the plasma citrulline levels were decreased in mice around 3–7 days after abdominal radiation at 11 and 12 Gy, they recovered 10 days after radiation exposure (**Figure 10E**). However, the mice receiving abdominal radiation at 13 Gy did not show restoration of the citrulline levels at 10 days (**Figure 10E**). Since their intestinal mucosae were also severely impaired at that point (**Figure 9**), the plasma citrulline levels after abdominal radiation may reflect the change in the intestinal degradation. In line with this finding, the mice receiving WBI at 8 Gy showed significant restoration of the plasma citrulline levels at 5–7 days (**Figure 10E**) without any intestinal damage (**Figure 9**).

3.4. Combination therapy with vitamin C drastically improved the mouse survival after abdominal radiation

Per os administration of vitamin C for 3 days before irradiation (Plan I, **Figure 11**) rescued only 20% of mice from lethal abdominal irradiation at 13 Gy (**Figure 12**). Engulfment of vitamin C at 8 h before radiation (Plan II, **Figure 11**) also rescued 20% of mice from abdominal radiation at 13 Gy (**Figure 12**). We tried the engulfment of vitamin C at 2 h before radiation in the mice, but their survival was <10%, suggesting that an interval of 2 h was too short to sufficiently increase the vitamin C levels in the mice. We next examined the p.o. administration of vitamin C for 3 days and engulfment 8 h before radiation in mice (Plan III, **Figure 11**). Nevertheless, the survivals of these mice were still 20% (**Figure 12**). As expectedly, posttreatment with p.o. administration of vitamin C was ineffective (0% survival, **Figure 12**). However interestingly, when we tried combination treatment before and after radiation in mice (Plan V, **Figure 11**), their survival rates increased to 40% (**Figure 12**). Notably, when the one-shot engulfment (8 h before radiation) of vitamin C was added to the oral administration for 10 days before/after radiation (Plan VI, **Figure 11**), the mouse survival was drastically increased to 100% survival after abdominal radiation (**Figure 12**).

3.5. Combination therapy with vitamin C effectively increased the tissue vitamin C levels in the small intestine of mice

Pretreatment with vitamin C for 3 days before radiation significantly increased the vitamin C levels in the intestinal tissue just before radiation, and also the administration of engulfing

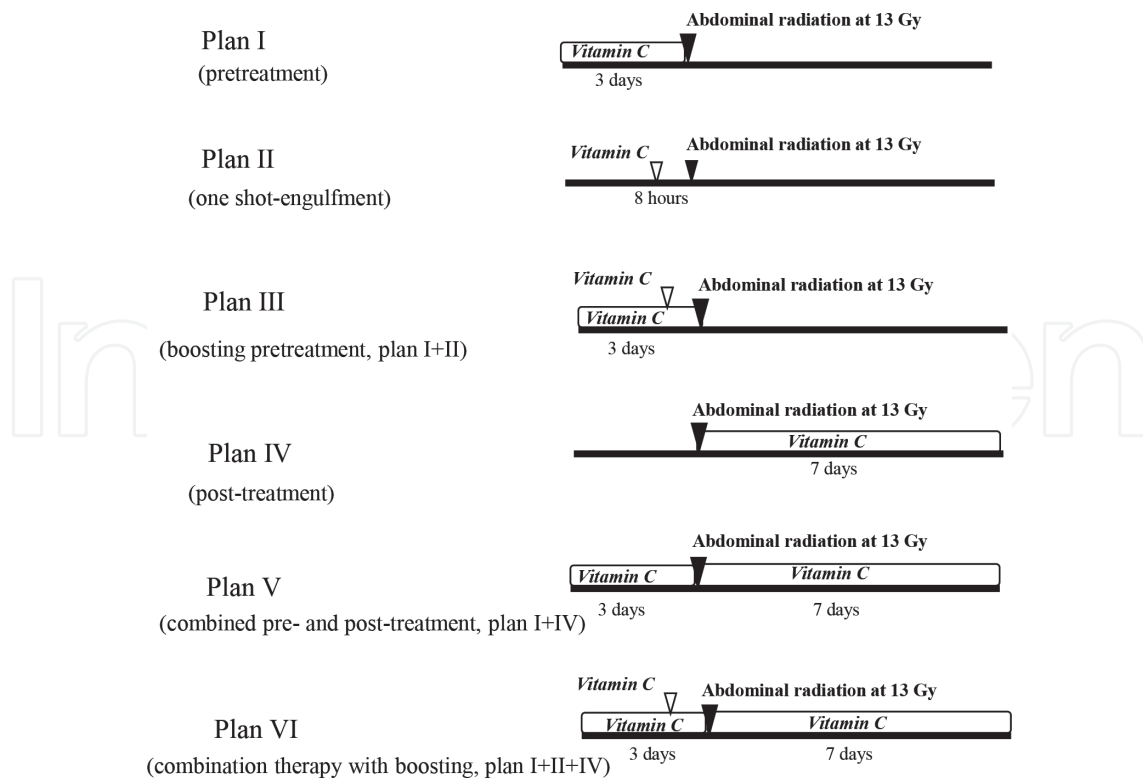


Figure 11. The experimental design for abdominal radiation and the treatments with vitamin C [19].

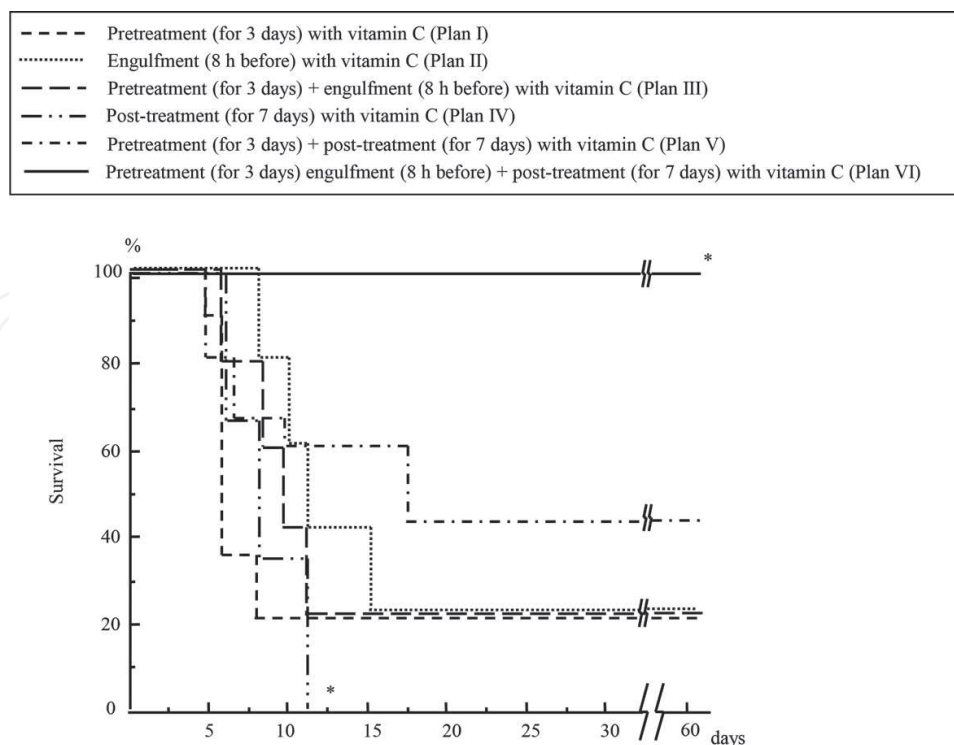


Figure 12. The effects of treatment with vitamin C on the survival of mice receiving abdominal radiation [19].

vitamin C at 8 h before radiation tended to increase the tissue vitamin C levels, but not significantly (**Table 1**). Interestingly, boosted pretreatment with vitamin C (oral intake for 3 days and engulfment at 8 h before radiation) further increased the tissue vitamin C levels in the intestine just before radiation (**Table 1**). However, there were no significant differences in the plasma vitamin C levels among these mouse groups (**Table 1**). Boosted p.o. pretreatment with vitamin C effectively increased the tissue vitamin C levels in the small intestine just before radiation.

3.6. Combination therapy with vitamin C restored the intestinal damage while reducing the elevation of free radical metabolite levels after abdominal radiation in mice

Combination therapy with p.o. administration of vitamin C for 10 days before/after radiation and one-shot engulfment at 8 h before radiation (Plan VI, **Figure 11**) significantly restored the intestinal damage in mice after abdominal radiation at 13 Gy (**Figure 13A**). This combination therapy with vitamin C also suppressed the positive TUNEL (terminal deoxynucleotidyltransferase-mediated dUTP nick end labeling) staining in the ileac mucosa in mice at 12 h after abdominal radiation at 13 Gy (**Figure 13B**). TUNEL staining was performed using an *in-situ* apoptosis detection kit (MK500, Takara, Tokyo Japan). Vitamin C may suppress the radiation-induced apoptosis in the intestinal mucosa. Consistently, combination therapy with vitamin C also restored the villus height of the ileac mucosa beyond 7 days after abdominal radiation (**Figure 14A**) and restored the plasma citrulline levels (**Figure 14B**). Thus, a certain relationship was suggested between the plasma citrulline levels and intestinal damage. This regiment of vitamin C treatment drastically improved the radiation-induced intestinal damage, resulting in an improvement in mouse survival after lethal abdominal radiation

Groups	Vitamin C levels	
	Tissue level of the small intestine (mg/L)	Plasma (mg/L)
No treatment with vitamin C	22.8 ± 2.0	5.2 ± 0.5
Engulfment (8 h before) with vitamin C	27.1 ± 1.4	5.2 ± 0.9
Pretreatment (for 3 days) with vitamin C	30.5 ± 1.6 [†]	6.2 ± 0.7
Pretreatment (for 3days) + engulfment (8 h before) with vitamin C	36.1 ± 1.7 *	6.3 ± 0.6

Mice received the indicated treatments with vitamin C. The small intestine and plasma were obtained from the mice just before radiation. Data are shown as means ± SE (standard error) from n=5 in each group. *p<0.01 vs. no treatment and engulfment (8h) and p<0.05 vs. pretreatment (3 days), and [†]p<0.01 vs. no treatment [19].

Table 1. Vitamin C levels in the small intestine and plasma after the treatments with vitamin C.

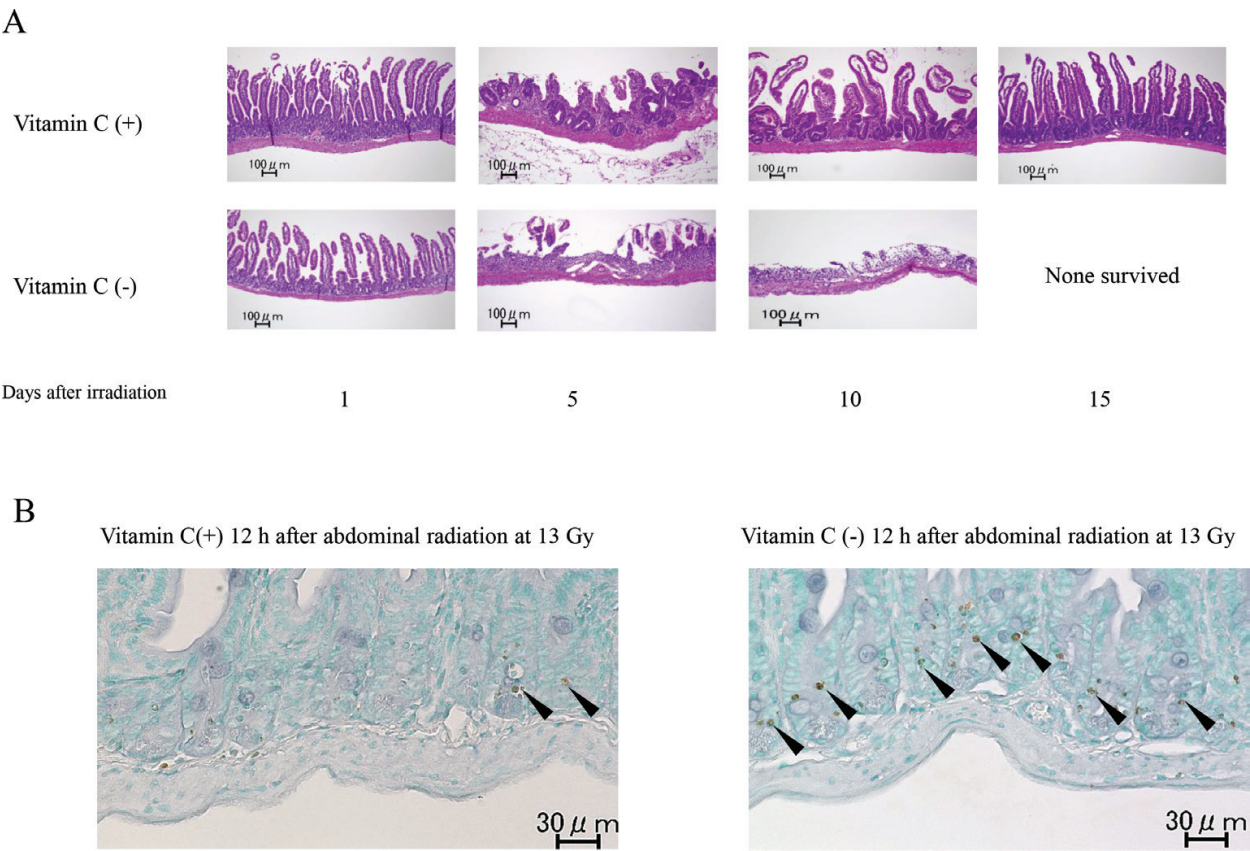


Figure 13. The changes in the intestinal mucosa of the irradiated mice with or without vitamin C treatment [19].

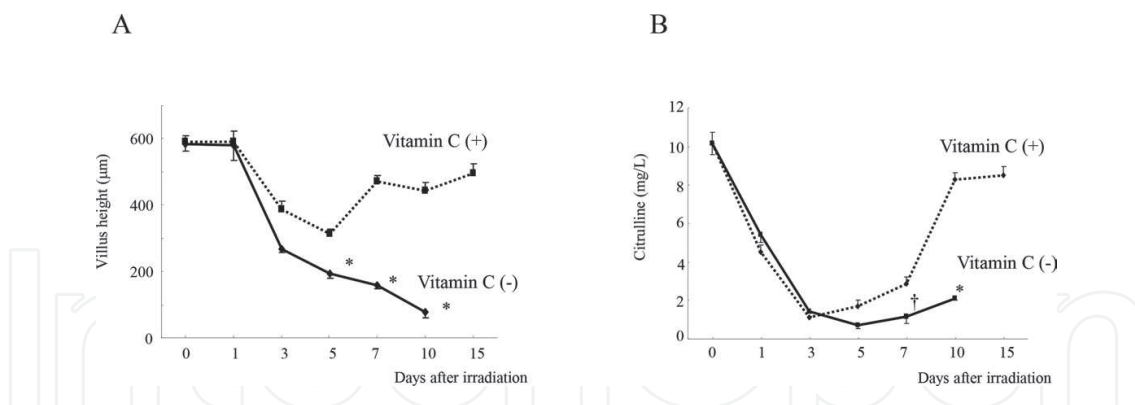


Figure 14. The changes in the villus height and plasma citrulline levels in the irradiated mice with and without vitamin C treatment [19].

4. The effect of postexposure treatment with intraperitoneal administration of vitamin C on the bone marrow dysfunction in mice after WBI

Considering the practical applications of vitamin C, such as in treating those affected by nuclear accidents, postexposure treatment is crucial for patients suffering from radiation exposure. However, it can be difficult for the patients to take high-dose vitamin C orally after radiation exposure, because the GI tract may already be damaged by radiation. Intravenous (or intraperitoneal; in case of mice) administration is preferred.

We therefore investigated the effects of postexposure treatment with intraperitoneal (i.p.) vitamin C on mice after irradiation. We found that the postexposure treatment with vitamin C reduced radiation-induced apoptosis in bone marrow cells and restored the hematopoietic function, thereby reducing the mortality in irradiated mice. Interestingly, postexposure treatment with vitamin C was effective even 24 h after radiation exposure. Large amounts of vitamin C (3 g/kg) were needed to improve the radiation-induced mortality in mice. We next examined the effects of divided i.p. administration of high-dose vitamin C. Divided i.p. administration with vitamin C (1.5 g/kg \times 2, immediately after and 24 h after radiation) was effective in treating irradiated mice. The administration of high-dose vitamin C may be useful for mitigation therapy even after exposure [20].

4.1. Postexposure treatment with i.p. administration of vitamin C improved the survival of whole-body-irradiated mice

When the mice were exposed to 7 Gy-WBI, their survival rate was 67%. However, postexposure treatment with 3 g/kg of vitamin C immediately after WBI at 7 Gy rescued all of the subject mice (100% survival) (**Figure 15A**). Nevertheless, either 1 or 2 g/kg of vitamin C was ineffective (**Figure 15A**). A substantial dose of vitamin C (3 g/kg) was needed to induce a mitigating effect against radiation-induced lethality. This postexposure treatment with 3 g/kg of vitamin C

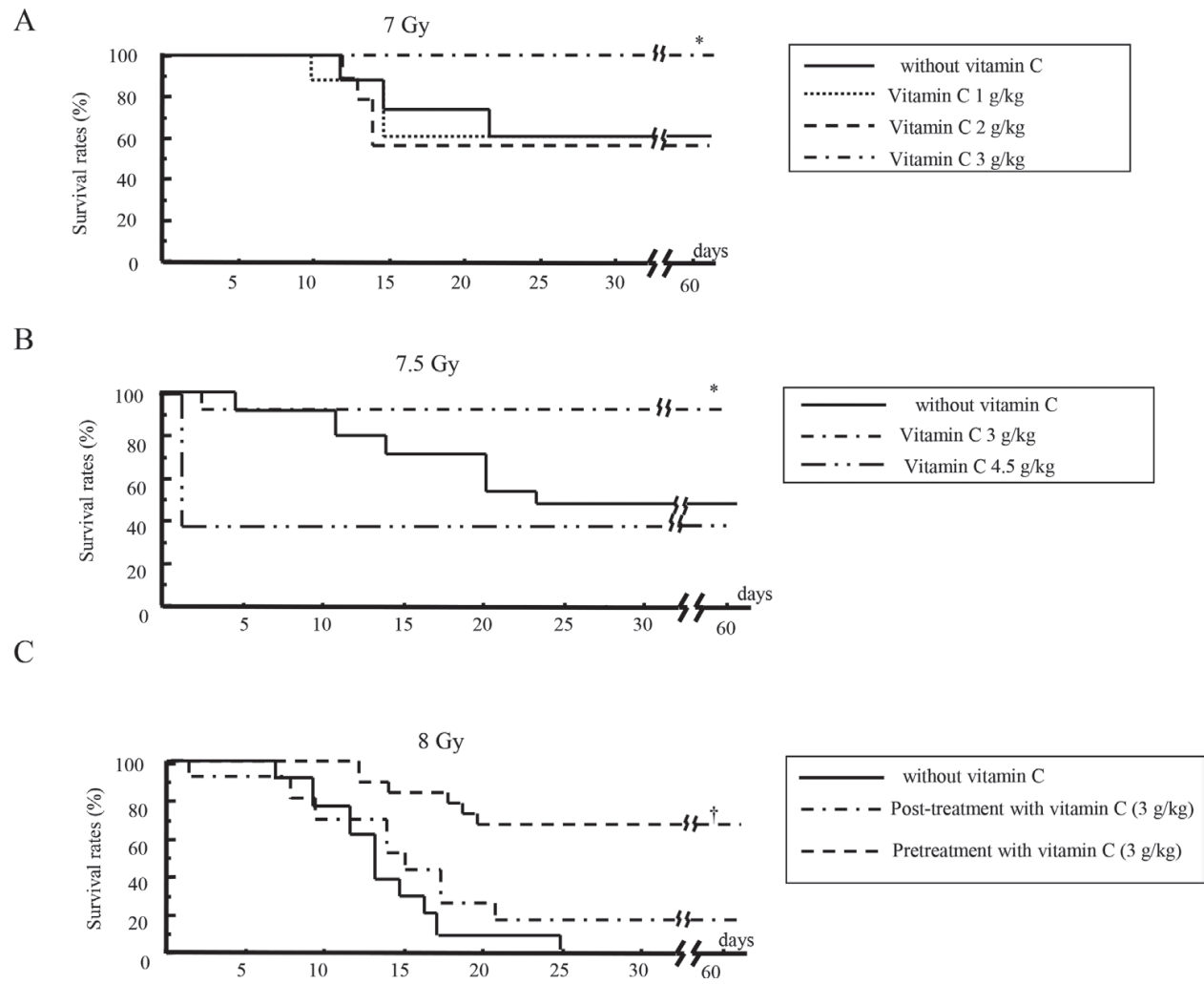


Figure 15. The survival of mice that received postexposure treatment with vitamin C after WBI at 7 (A), 7.5 (B), and 8 Gy (C) [20].

also significantly improved the mouse survival after 7.5-Gy WBI (**Figure 15B**). However, treatment with 4.5 g/kg of vitamin C conversely reduced the mouse survival after 7.5-Gy WBI (**Figure 15B**). With this treatment, 60% of mice died within 1 day after vitamin C treatment following radiation. The massive administration of vitamin C may be harmful for these irradiated mice, as more than half of the mice died within 1 day of the administration of 4.5 g/kg vitamin C, even in the absence of irradiation (**Figure 15B**). As expected, pretreatment with 3 g/kg of vitamin C rescued 65% of mice after lethal 8-Gy WBI, although the postexposure treatment with vitamin C (3 g/kg) rescued 20% of mice (**Figure 15C**), confirming that pretreatment with vitamin C had a potent radioprotective effect. Postexposure treatment with 4 g/kg of vitamin C as well as 4.5 g/kg markedly reduced the mouse survival at 1 day after 8-Gy WBI (13 and 0%, respectively), suggesting a harmful effect due to the extremely high-dose of vitamin C.

4.2. Postexposure treatment with vitamin C restored the bone marrow functions in mice after WBI

Postexposure treatment with 3 g/kg of vitamin C did not restore the WBC counts, RBC counts, Hb levels, or platelet counts in mice until 14 days after WBI at 7.5 or 8 Gy, but markedly

restored these hematological parameters at 3 weeks after WBI (**Figure 16**). Lethal 8-Gy WBI had severely damaged bone marrow cells at 14 days after radiation (**Figure 17A, C**). However, postexposure treatment with 3 g/kg vitamin C rescued a portion of the bone marrow cells from the lethal radiation at 14 days after exposure (**Figure 17B, D**), despite still suppression of hematological parameters (**Figure 16**, right column). Immunohistochemical staining of caspase-3 was performed using polyclonal rabbit anticaspase-3 antibody (Asp175, Cell Signaling Technology, Inc. Danvers, MA). Caspase-3-positive cells increased in the bone marrow 6 h after WBI at 8 Gy (**Figure 17E**, indicated by arrows). However, postexposure treatment with 3 g/kg of vitamin C reduced the caspase-3 positive cells (**Figure 17F**). Postexposure treatment with vitamin C may suppress radiation-induced apoptotic cell death in the bone marrow.

4.3. Postexposure treatment of vitamin C increased the plasma vitamin C and biological antioxidant potential (BAP) levels in mice after WBI

Intraperitoneal administration with 3 g/kg vitamin C markedly increased the plasma vitamin C levels in mice with and without 7.5-Gy WBI at 30 min and 1 h after administration (**Table 2**), and the levels were then decreased at 2 h (irradiated mice, 120 ± 38 ; nonirradiated mice, 188 ± 27 $\mu\text{g/L}$ at 2 h). The vitamin C levels in the plasma were measured by the SRL laboratory (Tokyo, Japan) using HPLC. The ferric-reducing ability in plasma was also measured spectrophotometrically using the BAP test (Diacron, Grosseto, Italy). In brief, a colored solution containing ferric ions is reduced to ferrous ions by reduction of the sample, and the antioxidant activity of the sample is proportional to the measured decrease in absorbance. The BAP assays were performed on the FRAS 4 analyzer (Wismarll FRAS 4, Tokyo, Japan) according to the manufacturer's protocols.

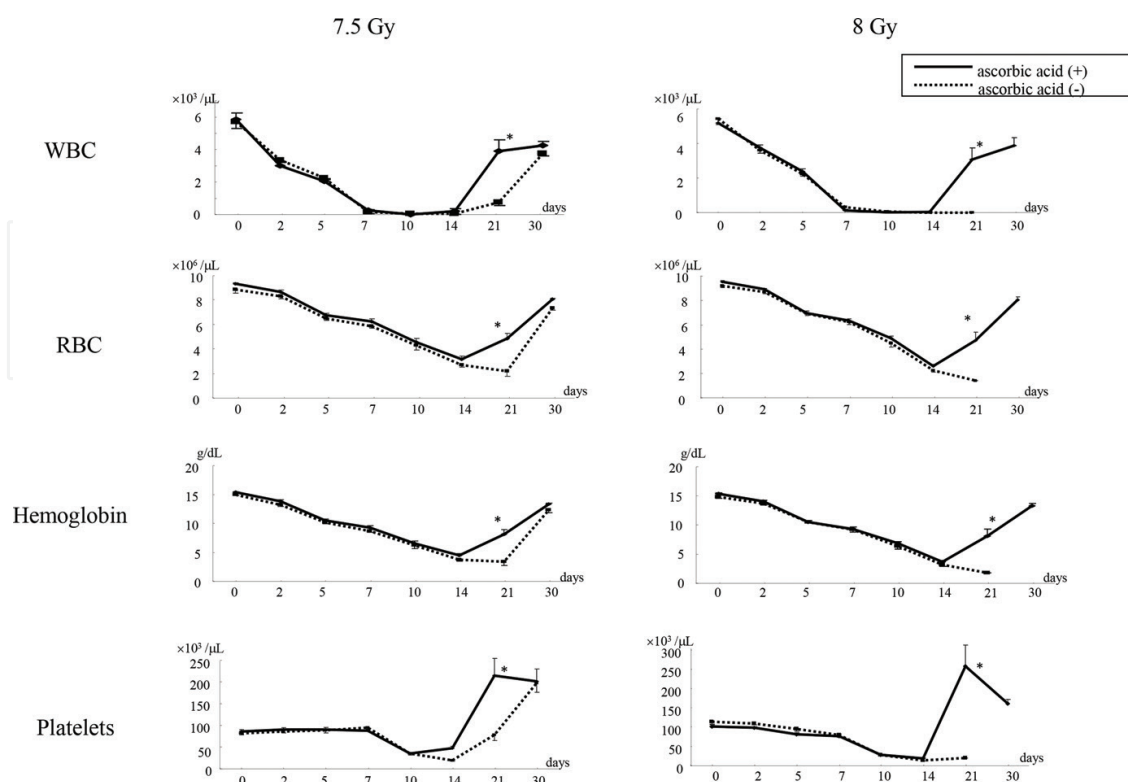


Figure 16. Changes in hematological parameters after irradiation of mice [20].

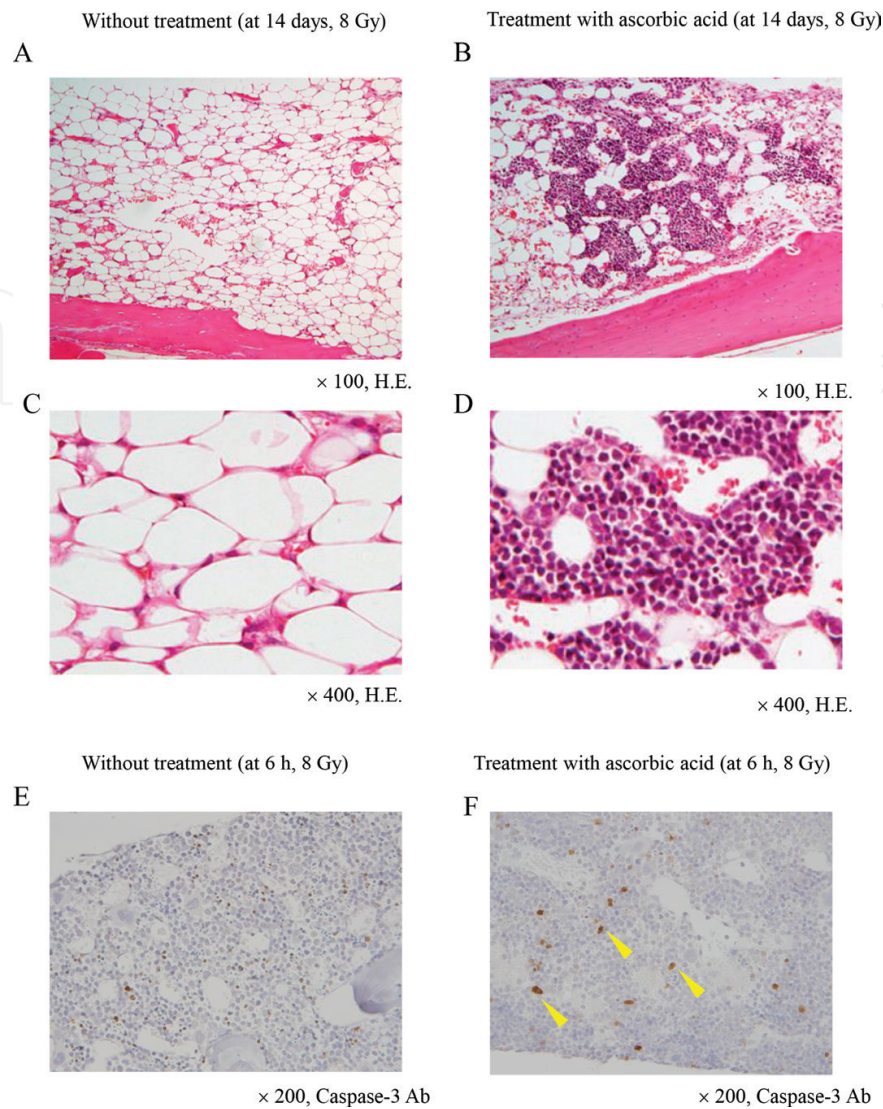


Figure 17. Histological findings in the bone marrow of irradiated mice [20].

Radiation	Treatment	Plasma vitamin C levels (µg/L)		Plasma BAP levels (mMol/L)	
		30 min after administration	1 h after administration	30 min after administration	1 h after administration
7.5 Gy	Vitamin C (+)	3659 ± 382*	1,878 ± 419*	30.1 ± 2.1*	5.7 ± 0.8*
	Vitamin C (–)	2.6 ± 0.7	1.7 ± 0.2	3.1 ± 0.1	3.4 ± 0.1
Nonradiation	Vitamin C (+)	3287 ± 520*	940 ± 128	28.3 ± 2.4*	5.3 ± 0.8
	Vitamin C (–)	1.2 ± 0.2		3.0 ± 0.1	

Mice received WBI at 7.5 Gy or did not. Subsequently, 3 g/kg of vitamin C or saline was administered to the mice. Data shown are mean ± SE from five mice.

* $p < 0.01$ vs. vitamin C (–) [20].

Table 2. Plasma levels of vitamin C after radiation with or without vitamin C treatment.

These plasma BAP levels were markedly increased at 30 min after i.p. administration with vitamin C in both irradiated and nonirradiated mice (**Table 2**). Intraperitoneal administration of vitamin C potentially induced antioxidant capability in mice, even after irradiation. Whereas, these increased plasma BAP levels reduced to normal levels in both irradiated and nonirradiated mice at 2 h after i.p. administration of vitamin C (**Table 2**).

4.4. Postexposure treatment of vitamin C at 24 h after radiation was still effective in irradiated mice

To examine how long we could delay postexposure treatment with vitamin C after radiation exposure, vitamin C was administered to mice at 1, 6, 12, 24, 36 or 48 h after 7.5-Gy WBI. As a result, treatment with vitamin C up to 24 h after radiation effectively increased the survival of irradiated mice, although the treatment beyond 36 h postirradiation was ineffective (**Figure 18B**).

4.5. Divided i.p. administration with vitamin C (1.5 g/kg \times 2, immediately after and 24 h after radiation) was effective in irradiated mice

Considering a clinical application of vitamin C, a single administration with 3 g/kg of vitamin C appeared to be too high a dose for mice to tolerate, although nonirradiated mice did not die after this dose. The efficacy of two treatments of vitamin C was then examined (1.5 g/kg \times 2, immediately after radiation and 24 h after, 3 g/kg in total). This divided i.p. administration with vitamin C markedly increased the survival of mice after WBI at 7.5 Gy (**Figure 19A**),

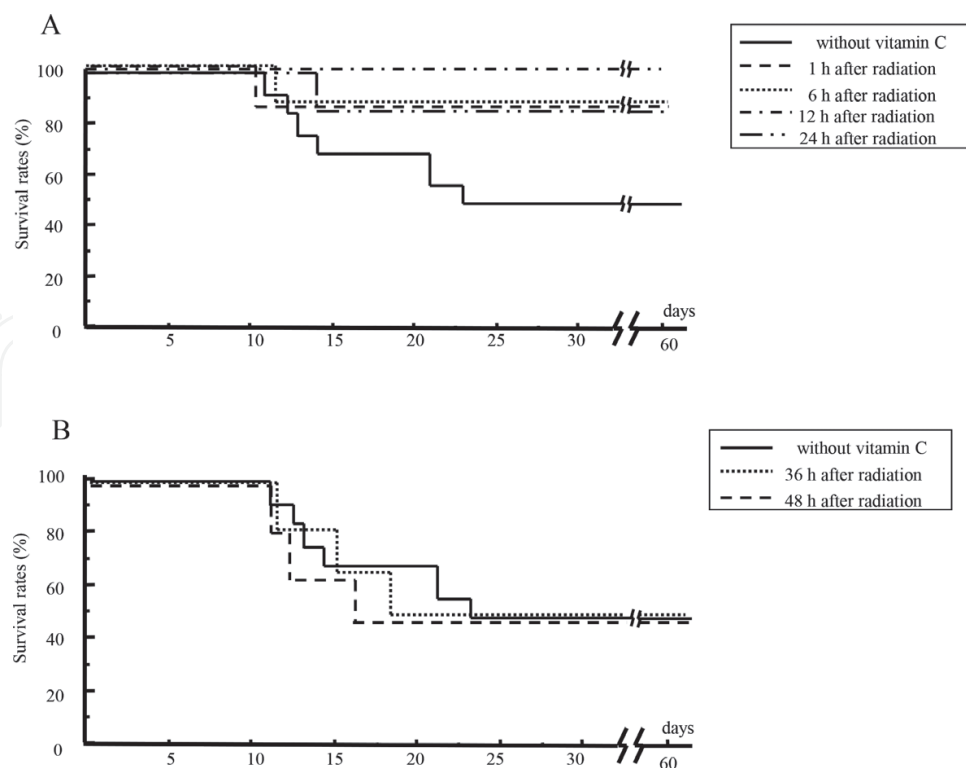


Figure 18. The mouse survival as a function of the time of postexposure treatment with vitamin C [20].

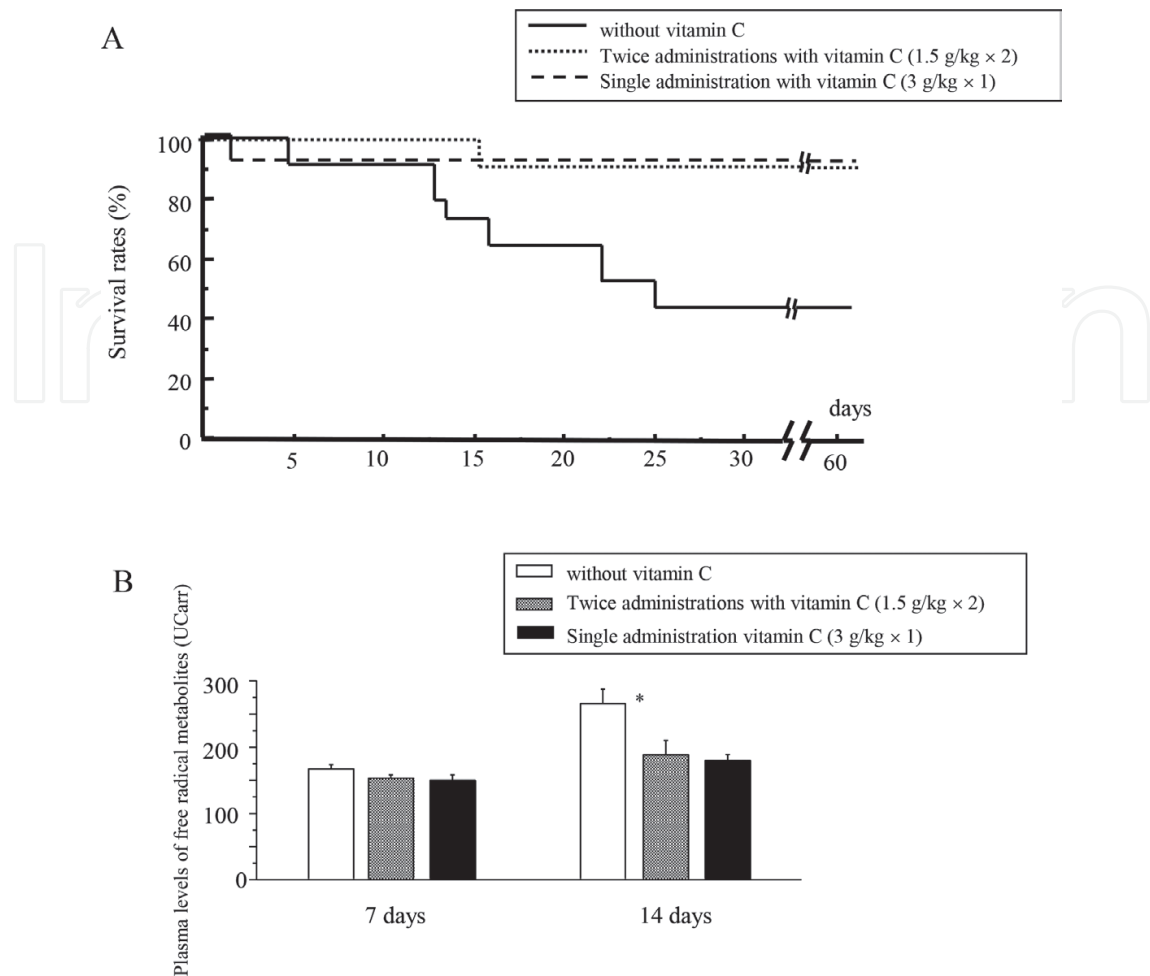


Figure 19. The survival of mice following one or two treatments with vitamin C (3 g/kg) after WBI and, plasma levels of free radical metabolites were also measured 7 and 14 days after WBI [20].

despite either single injection with 1.5 g/kg of vitamin C immediately after or 24 h after radiation was ineffective. In addition, divided i.p. administration with vitamin C (1.5 g/kg × 2) as well as a single administration (3 g/kg) suppressed the elevation of the plasma free radical metabolite levels after radiation (**Figure 19B**), suggesting that radiation-induced free radical productions may be effectively reduced.

5. Conclusions

Vitamin C is a strong antioxidative agent with potent radio-protective effects. In addition, vitamin C is a water-soluble vitamin and can be easily and safely excreted into the urine and can be excessively ingested. When bodies are exposed to radiation, the exposure evokes free radicals and ROS, which oxidize cell components, resulting in impairment of host cells. Antioxidants such as vitamin C protect hosts from radiation damage by scavenging such radical products. However, large doses of vitamin C are required to induce this radio-protective effect. We treated irradiated mice with p.o. administration with 150 or 250 mg/kg/day of vitamin C for

7–10 days [18, 19]. We also delivered i.p. administration with 3 g/kg of vitamin C to mice for postexposure treatment [20]. Because the daily requirement of doses of vitamin C is several milligrams per kilogram order in humans, several hundred to thousand times the doses of vitamin C were administered p.o. or i.p. to the mice in our studies.

A number of reports have described high-dose vitamin C therapy for the common cold, thermal injury, and malignant tumors, among other ailments [21, 25, 26]. In these reports, no severe side effects were observed by p.o. administration with high-dose vitamin C, although diarrhea or loose stool was occasionally noted. This is presumed to be osmotic diarrhea. In our unpublished data, when human volunteers took 5 g of vitamin C orally, approximately 7% of them had diarrhea or loose stool. The intravenous administration of high-dose vitamin C is widely used as a complementary and alternative medicine for various patients [27]. However, we should practice caution when administering gram-orders of vitamin C to patients [28]. Nephropathy due to oxalate, one of the main metabolites of vitamin C, has been reported in patients with renal impairment after the massive administration of vitamin C [29–31]. Patients with glucose-6-phosphate dehydrogenase deficiency also reportedly developed intravascular hemolysis after receiving massive administration of vitamin C [32, 33]. However, a recent clinical study has shown that the intravenous administration of 1.5 g/kg of vitamin C thrice weekly is safe and nontoxic in cancer patients, when patients with renal failure or glucose-6-deficiency were excluded [34].

We believe that vitamin C is a practical radioprotectant, as it is not expensive to synthesize and does not induce serious side effects, even if administered at a high dose. Indeed, several first responders dispatched to the Fukushima Dai-ichi Nuclear Power Plant Accident took vitamin C before their mission. Fortunately, no responders were exposed to high-dose radiation or developed acute radiation syndrome, but this prevented any evaluation of the effectiveness of vitamin C for preventing acute radiation syndrome; notably, though, no one reported any side effects.

If we use radiation or radioactive substance properly, it is an effective and a useful tool for us. However, fears still exist about misuse of this tool by someone with evil thought. In addition, we should always keep in mind that the human make mistakes without malice. We must prepare for radiological accidents without demanding any sacrifice by first responders.

Author details

Tetsuo Yamamoto¹ and Manabu Kinoshita^{2*}

*Address all correspondence to: manabu@ndmc.ac.jp

1 Military Medicine Research Unit, Test and Evaluation Command, Ground Self-Defense Force, Setagaya, Tokyo, Japan

2 Department of Immunology and Microbiology, National Defense Medical College, Tokorozawa, Saitama, Japan

References

- [1] Talbott EO, Youk AO, McHugh KP, Shire JD, Zhang A, Murphy BP, et al. Mortality among the residents of the three mile island accident area: 1979-1992. *Environmental Health Perspectives*. 2000;**108**(6):545-551
- [2] Baranov A, Gale RP, Guskova A, Piatkin E, Selidovkin G, Muravyova L, et al. Bone marrow transplantation after the Chernobyl nuclear accident. *The New England Journal of Medicine*. 1999;**321**(4):205-212. DOI: 10.1056/NEJM/198907273210401
- [3] Beresford NA, Fesenko S, Konoplev A, Skuterud L, Smith JT, Voigt G. Thirty years after the Chernobyl accident: What lessons have we learnt? *Journal of Environmental Radioactivity*. 2016;**157**:77-89. DOI: 10.1016/j.jenvrad/201602003
- [4] Akashi M, Hiramata T, Tanosaki S, Kuroiwa N, Nakagawa K, Tsuji H, et al. Initial symptoms of acute radiation syndrome in the JCO criticality accident in Tokai-mura. *Journal of Radiation Research*. 2001;**42**:S157-166
- [5] Hiramata T, Tanosaki S, Kandatsu S, Kuroiwa N, Kamada T, Tsuji H, et al. Initial medical management of patients severely irradiated in the Tokai-mura criticality accident. *British Journal of Radiology*. 2003;**76**(904):246-253. DOI: 10.1259/bjr/82373369
- [6] Yasui S. Lessons learned: medical and health care management for emergency workers at the TEPCO Fukushima Daiichi APP accident. *Journal of Occupational and Environmental Hygiene*. 2014;**11**(5):49-58. DOI: 10.1080/15459624.2014.880445
- [7] Scholes G. Radiation effects on DNA. The Silvanus Thompson Memorial Lecture. April 1982. *British Journal of Radiology*. 1982;**56**:221-231. DOI: 10.1259/0007-1285-56-664-221
- [8] Prise FM, Davies S, Michael BD. A comparison of the chemical repair rates of free radical precursors of DNA damage and cell killing in Chinese hamster V79 cells. *International Journal of Radiation Biology*. 1992;**61**:721-728
- [9] Straub JM, New J, Hamilton CD, Lominska C, Shnyder Y, Thomas SM. Radiation-induced fibrosis: mechanisms and implications for therapy. *Journal of Cancer Research and Clinical Oncology*. 2015;**141**(11):1985-1994. DOI: 10.1007/s00432-015-1974-6
- [10] Ogawa Y. Paradigm shift in radiation biology/radiation oncology-exploitation of the "H₂O₂ effect" for radiotherapy using low-IET (linear energy transfer) radiation such as X-rays and high-energy electrons. *Cancers*. 2016;**8**(28):E28. DOI: 10.3390/cancers8030028
- [11] Koyama S, Kodama S, Suzuki K, Matsumoto T, Miyazaki T, Watanabe M. Radiation-induced long-lived radicals which cause mutation and transformation. *Mutation Research*. 1998;**421**(1):45-54
- [12] Pisani A, Riccio E, Andreucci M, Faga T, Ashour M, Di iNuzzi A, et al. Role of reactive oxygen species in pathogenesis of radiocontrast-induced nephropathy. *BioMed Research International*. 2013;**2013**:868321. DOI: 10.1155/2013/868321

- [13] Guelman LR, Cabana JI, del Lujan Pagotto RM, Zieher LM. Ionizing radiation-induced damage on developing cerebellar granule cells cultures can be prevented by an early amifostine post-treatment. *International Journal of Developmental Neuroscience*. 2005;**23**(1):1-7. DOI: 10.1016/j.ijdevneu.2004.10.001
- [14] Hensley ML, Schuchter LM, Lindley C, Meropol N, Cohen GI, Broder G, et al. American society of clinical oncology clinical practice guidelines for the use of chemotherapy and radiotherapy protectants. *Journal of Clinical Oncology*. 1999;**17**(10):3333-3355. DOI: 10.1200/JCO.1999.17.10.3333
- [15] Jia D, Koonce NA, Griffin RJ, Jackson C, Corry PM. Prevention and mitigation of acute death of mice after abdominal irradiation by the antioxidant N-acetyl-cysteine (NAC). *Radiation Research*. 2010;**173**(5):579-589. DOI: 10.1667/RR2030.1
- [16] Archambeau JO, Tovmasyan A, Pearlstein RD, Crapo JD, Batinic-Haberle I. Superoxide dismutase mimic, MnTE-2-PyP(5+) ameliorates acute and chronic proctitis following focal proton irradiation of the rat rectum. *Redox Biology*. 2013;**25**(1):599-607. DOI: 10.1016/j.redox.2013.10.002
- [17] Khan S, Adhikari JS, Rizvi MA, Chaudhury NK. Radioprotective potential of melatonin against ⁶⁰Co gamma-ray-induced testicular injury in male C57BL/6 mice. *Journal of Biomedical Science*. 2015;**22**(61):1-15. DOI: 10.1186/s12929-015-0156-9
- [18] Yamamoto T, Kinoshita M, Shinomiya N, Hiroi S, Sugasawa H, Matsushita Y, et al. Pretreatment with ascorbic acid prevents lethal gastrointestinal syndrome in mice receiving a massive amount of radiation. *Journal of Radiation Research (Tokyo)*. 2010;**51**(2):145-156. DOI: 10.1269/jrr.09078
- [19] Ito Y, Kinoshita M, Yamamoto T, Sato T, Obara T, Saitoh D, et al. A combination of pre- and post-exposure ascorbic acid rescues mice from radiation-induced lethal gastrointestinal damage. *International Journal of Molecular Science*. 2013;**14**:19618-19635. DOI: 10.3390/ijms141019618
- [20] Sato T, Kinoshita M, Yamamoto T, Ito M, Nishida T, Takeuchi M, et al. Treatment of irradiated mice with high-dose ascorbic acid reduced lethality. *PLoS One*. 2015;**10**(2):e0117020. DOI: 10.1371/journal.pone.0117020
- [21] Cameron E, Pauling L. Supplemental ascorbate in the supportive treatment of cancer: Reevaluation of prolongation of survival times in terminal human cancer. *Proceedings of the National Academy of the United States of America*. 1978;**75**(9):4538-4542
- [22] Carr AC, Vissers MCM. Synthetic or food-derived vitamin C—Are they equally bioavailable?. *Nutrients*. 2013;**5**:4284-4304. DOI: 10.3390/nu5114284
- [23] Bolis G, Zanaboni F, Vanoli P, Russo A, Franchi M, Scarfone G, et al. The impact of whole-abdomen radiotherapy on survival in advanced ovarian cancer patients with minimal residual disease after chemotherapy. *Gynecological Oncology*. 1990;**39**(2):150-154

- [24] MacVittie TJ. Therapy of radiation injury. *Stem Cells*. 1997;**15**(Suppl 2):263-268. DOI: 10.1002/stem.5530150735
- [25] Cameron E, Pauling L. Supplemental ascorbate in the supportive treatment of cancer: Prolongation of survival times in human cancer. *Proceedings of the National Academy of the United States of America*. 1976;**73**(9):4538-4542
- [26] Levine M, Conry-Cantilena C, Wang Y, Welch RW, Washko PW, Dhariwal KR, et al. Vitamin C pharmacokinetics in healthy volunteers: Evidence for a recommended dietary allowance. *Proceedings of the National Academy of the United States of America*. 1996;**93**(8):3704-3709
- [27] Padayatty SJ, Sun AY, Chen Q, Espey MG, Drisko J, Levine M. Vitamin C: Intravenous use by complementary and alternative medicine practitioners and adverse effects. *PLoS One*. 2010;**5**(7):e11414. DOI: 10.1371/journal.pone.0011414
- [28] Stephanson CM, Levin RD, Spector T, Lis CG. Phase 1 clinical trial to evaluate the safety, tolerability, and pharmacokinetics of high-dose intravenous ascorbic acid in patients with advanced cancer. *Cancer Chemotherapy and Pharmacology*. 2013;**72**(1):139-146. DOI: 10.1007/s00280-013-2179-9
- [29] McAllister CJ, Scowden EB, Dewberry FL, Richman A. Renal failure secondary to massive infusion of vitamin C. *Journal of the American Medical Association*. 1984;**252**(13):1684
- [30] Lawton JM, Conway LT, Crosson JT, Smith CL, Abraham PA. Acute oxalate nephropathy after massive ascorbic acid administration. *Archives of Internal Medicine*. 1985;**145**(5):950-951
- [31] Wong K, Thomson C, Bailey RR, Mcdiarmid S, Gardner J. Acute oxalate nephropathy after a massive intravenous dose of vitamin C. *Australian and New Zealand Journal of Medicine*. 1994;**24**(4):410-411
- [32] Campbell GD Jr, Steinberg MH, Bower JD. Letter: Ascorbic acid-induced hemolysis in G-6-PD deficiency. *Annals of Internal Medicine*. 1975;**82**(6):810
- [33] Rees DC, Kelsey H, Richards JD. Acute haemolysis induced by high dose ascorbic acid in glucose-6-phosphate dehydrogenase deficiency. *British Medical Journal*. 1993;**306**(6881):841-842
- [34] Hoffer LJ, Levine M, Assouline S, Melnychuk D, Padayatty SJ, Rosadiuk K, et al. Phase 1 clinical trial of i.v. ascorbic acid in advanced malignancy. *Annals of Oncology*. 2008;**19**(11):1969-1974. DOI: 10.1093/annonc/mdn377