

We are IntechOpen, the world's leading publisher of Open Access books Built by scientists, for scientists

6,900

Open access books available

185,000

International authors and editors

200M

Downloads

Our authors are among the

154

Countries delivered to

TOP 1%

most cited scientists

12.2%

Contributors from top 500 universities



WEB OF SCIENCE™

Selection of our books indexed in the Book Citation Index
in Web of Science™ Core Collection (BKCI)

Interested in publishing with us?
Contact book.department@intechopen.com

Numbers displayed above are based on latest data collected.
For more information visit www.intechopen.com



Mesencephalon; Midbrain

Ayla Kurkcuoglu

Additional information is available at the end of the chapter

<http://dx.doi.org/10.5772/intechopen.68767>

Abstract

The mesencephalon is the most rostral part of the brainstem and sits above the pons and is adjoined rostrally to the thalamus. It comprises two lateral halves, called the cerebral peduncles; which is again divided into an anterior part, the crus cerebri, and a posterior part, tegmentum. The tectum is lay dorsal to an oblique coronal plane which includes the aqueduct, and consist of pretectal area and the corpora quadrigemina. In transvers section, the cerebral peduncles are seen to be composed of dorsal and ventral regions separated by the substantia nigra. Tegmentum mesencephali contains red nucleus, oculomotor nucleus, trochlear nucleus, reticular nuclei, medial lemnisci, lateral lemnisci and medial longitudinal fasciculus. In tectum, the inferior colliculus and superior colliculus have main nucleus, which are continuous with the periaqueductal grey matter. The mesencephalon serves important functions in motor movement, particularly movements of the eye, and in auditory and visual processing. The mesencephalic syndrome cause tremor, spastic paresis or paralysis, opisthotonos, nystagmus and depression or coma. In addition cranial trauma, brain tumors, thiamin deficiency and inflammatory or degenerative disorders of the mesencephalon have also been associated with the mid-brain syndrome.

Keywords: the midbrain, mesencephalon, crus cerebri, substantia nigra, tectum

1. Introduction

The nervous system has two components, namely the central nervous system and the peripheral nervous system. The central nervous system is composed of brain and spinal cord. The peripheral nervous system consists of sensory neurons, ganglia and nerves connecting with each other and with the central nervous system. The brain is a component of the central nervous system. It contains three basic subdivisions, namely the cerebral hemispheres, brainstem and cerebellum (**Figure 1**) [1, 2].

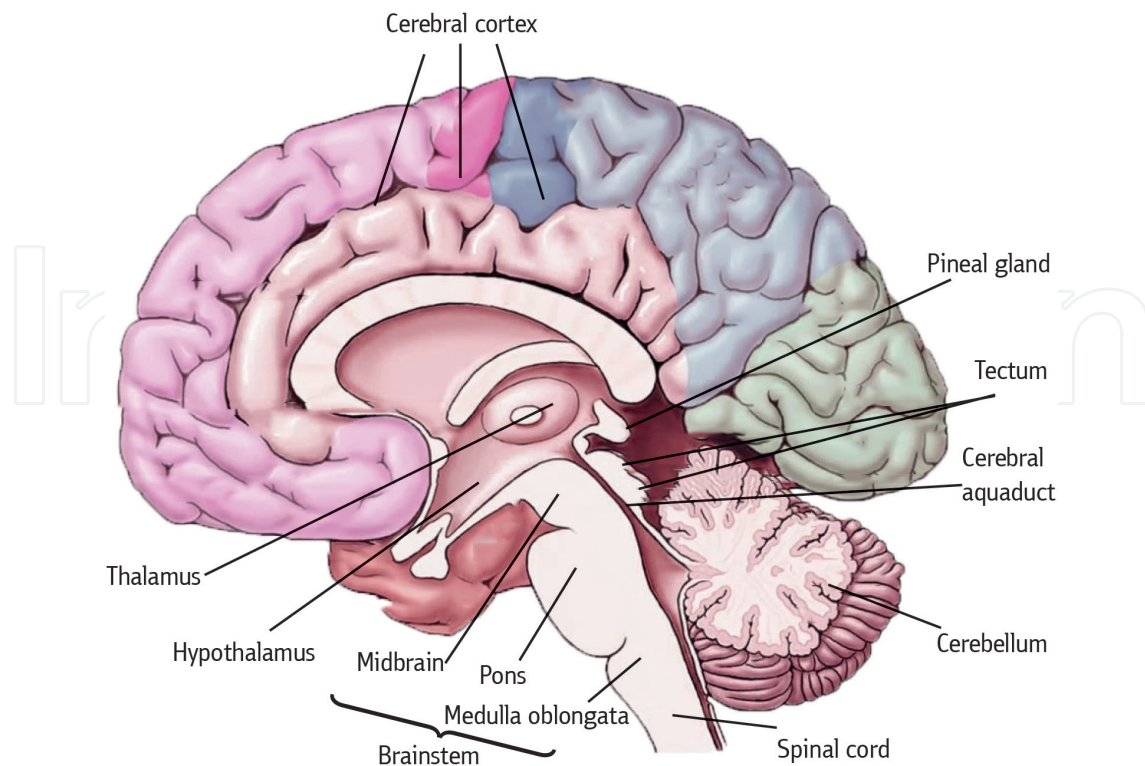


Figure 1. Mid-sagittal section of the brain.

2. Embryology

Embryologically, the central nervous system can be divided into five continuous parts (**Figure 1**). From rostral to caudal, they are [3, 4]:

- The cerebrum (telencephalon) becomes two cerebral hemispheres. The surface of these hemispheres consists of gyri and sulci, and the hemispheres are partially separated by a deep longitudinal fissure.
- The diencephalon is hidden from view in the adult brain by the cerebral hemispheres. It consists of the thalamus, hypothalamus, and other related structures and classically is considered to be the most rostral part of the brainstem.
- The mesencephalon (midbrain), which is the first part of the brainstem seen when an intact adult brain is examined, located at the junction between and in both middle and posterior cranial fossae.
- The metencephalon gives rise to the cerebellum and the pons.
- The myelencephalon (medulla oblongata), the caudal most part of the brainstem, ends at the foramen magnum.

Closure of the neural tube first occurs in the region where the earliest somites appear; closure spreads cranially and caudally. The unfused regions of the neural tube are known

as the cranial and caudal neuropores. Even before the closure of the neuropores (24 days of gestation for the cranial neuropore, and 26 days of gestation for the caudal neuropore), some fundamental subdivisions in the early nervous system have become manifest. The future spinal cord and brain are recognizable, and within the brain the forebrain (prosencephalon), midbrain (mesencephalon), and hindbrain (rhombencephalon) can be distinguished [4]. A prominent force in shaping the early nervous system is the overall bending of the cephalic end of the embryo into a “C” shape. Associated with this bending is the appearance of a prominent cephalic flexure of the brain at the level of the mesencephalon at the end of the third week. At the beginning of the fifth week, a cervical flexure appears at the boundary between the hindbrain and the spinal cord. By week 5, the original three-part brain has become subdivided further into five parts. The mesencephalon, which is sharply bent by the cephalic flexure, remains undivided and tubular in its overall structure [2, 4].

3. Anatomy

3.1. External features of the midbrain

The midbrain is the short, constricted portion, which connects the pons and cerebellum with the thalamus and cerebral hemispheres. It is the smallest part of the brainstem, not more than 2 cm in length, and most of it lies in the posterior cranial fossa [3, 5].

On the anterior surface of the midbrain are located the cerebral peduncles, separated by the interpeduncular fossa. The cerebral peduncle is two large bundles of fibers on each side of the midline. In addition, it is again divided into an anterior part, *the crus cerebri*, and a posterior part, *tegmentum mesencephali*, by a pigmented band of gray matter called *substantia nigra*. *The crura cerebri* are superficially corrugated and emerge from the cerebral hemispheres. They converge as they descend and meet as they enter the pons, where they form the caudolateral boundaries of the interpeduncular fossa. Two crura are separate, whereas the tegmental parts are united and traversed by the cerebral aqueduct that connects the third and fourth ventricles [1, 2]. The oculomotor nerve (CN III) emerges from the medial aspect of the cerebral peduncle of the same side. Exiting from the interpeduncular fossa near the junction of the pons and midbrain are the oculomotor nerves. This cranial nerve supplies all but two of the extraocular muscles. The crus cerebri embraces a midline depression called the interpeduncular fossa. The basilar artery divides in the interpeduncular fossa into right and left posterior cerebral arteries at the level of the tentorial incisura. The superior cerebellar and posterior cerebral arteries run laterally around the ventral (basilar) crural surfaces. The trochlear and oculomotor nerves lie between two arteries. In the depths of the interpeduncular fossa can be seen numerous small holes. These holes represent the entry point of the posterior cerebral artery. Because of its appearance, this region is usually referred to as the posterior perforated substance [6–8].

On the posterior surface of the midbrain are four prominent rounded elevations, the inferior and superior colliculi one on each side. Collectively, four colliculi are called as *tectum* (corpora quadrigemina). The superior and inferior colliculi are separated by a cruciform sulcus. The

upper limit of the sulcus expands into a depression for the pineal gland. Median frenulum veli is prolonged from its caudal end down over the superior medullary velum. The superior colliculi are larger and darker than the inferior colliculi, and associated with visual responses. The inferior colliculi are smaller, and associated with auditory pathways. Each colliculus is laterally related to ridges called superior brachium and inferior brachium, coming from respective colliculi. Superior brachium connects the superior colliculus to lateral geniculate body. Inferior brachium connects the inferior colliculus to medial geniculate body. The trochlear nerves (CN IV) arise from the dorsal midbrain, caudal to the inferior colliculi and pass inferiorly around the lateral side of the midbrain. The trochlear nerve is the only cranial nerve that exits from the dorsal surface of the brainstem. The midbrain serves important functions in motor movement, particularly movements of the eye, and in auditory and visual processing [1, 2, 7].

3.2. Internal structure of the midbrain

On transverse section, the cerebral peduncles are seen to be composed of dorsal and ventral regions separated by *substantia nigra*. On each side, the dorsal region is *tegmentum*, and the ventral part is the *crus cerebri*. Cerebral peduncles are the major pathways of motor neurons out of the cortex. The *tegmentum* is between the *substantia nigra* and the *aqueductus mesencephali*. It also refers to the corresponding regions in the medulla and pons. *Tectum mesencephali*, located dorsal to the *aqueductus mesencephali*, contains two superior colliculi and two inferior colliculi (Figures 2 and 3) [1, 2, 6].

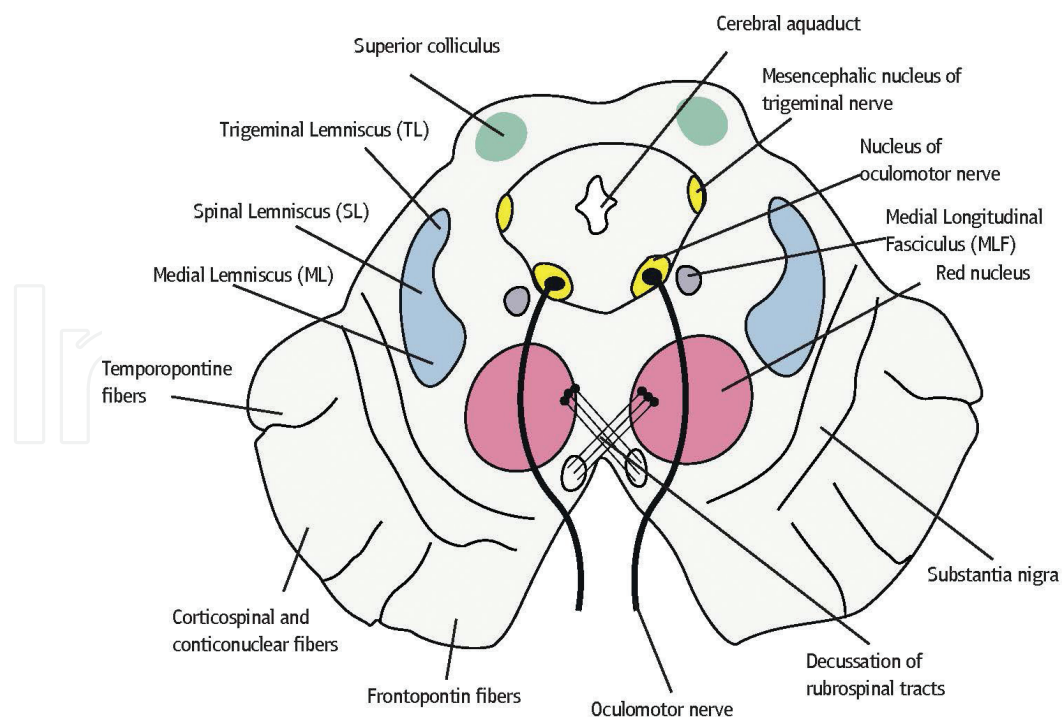


Figure 2. Cross section through superior colliculus.

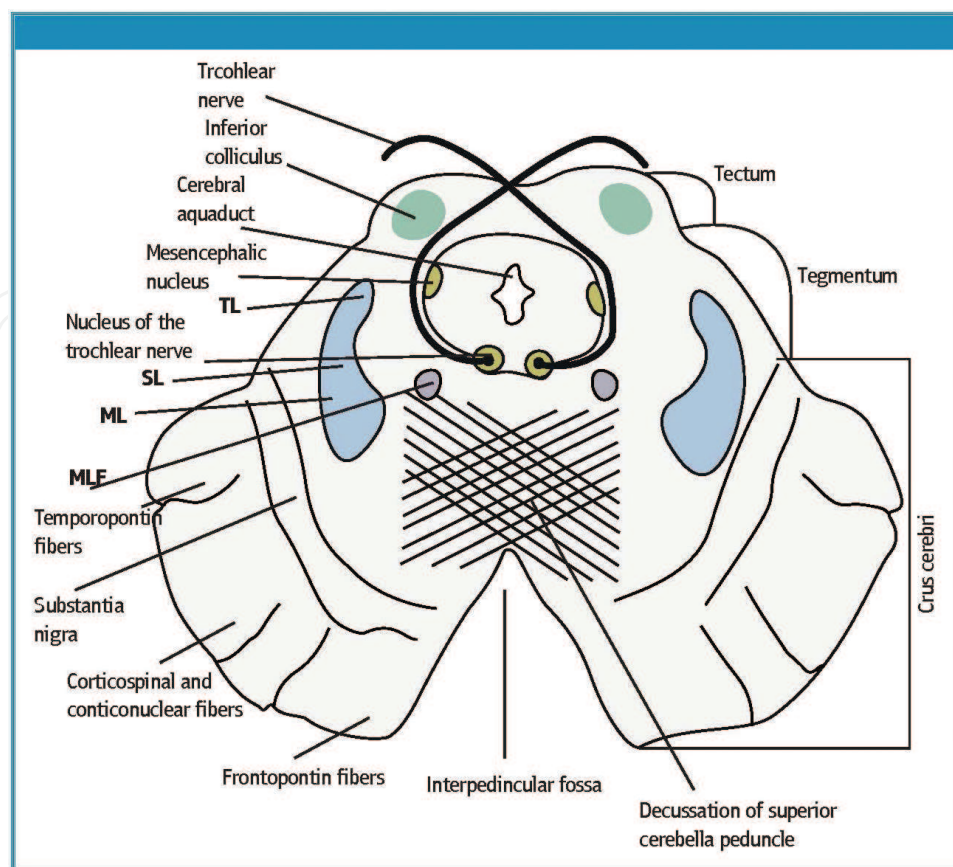


Figure 3. Cross section through inferior colliculus.

3.2.1. *Crura cerebri (the cerebral peduncles, pedunculus cerebri)*

The most ventral part of the midbrain contains a massive band of descending corticofugal fibers, the crus cerebri. Each crus cerebri is semilunar in section. It contains corticonuclear, corticospinal and corticopontine fibres. Corticonuclear fibers (the corticobulbar fibers) originate in the primary motor cortex. They descend through the genu of the internal capsule, and down to the midbrain. In the midbrain, the middle third of the crus cerebri contains the corticobulbar and corticospinal fibers. The corticobulbar fibers end in the motor nuclei of the cranial nerves and other brainstem nuclei. The corticospinal fibers are white matter motor pathways starting at the cortex, and they travel through the posterior limb of the internal capsule. They enter the cerebral peduncle at the base of the midbrain, then pass through the brainstem, from the pons and then to the medulla. Corticospinal neurons synapse directly onto alpha motor neurons in the spinal cord for direct muscle control. Corticopontine fibers arise in the cerebral cortex and form two groups, both of which end in pontine nuclei. The frontopontine fibers arise from the cells of the frontal lobe, and end in the nuclei of the pons, the temporopontine fibers, which are largely from the posterior region of the temporal lobe, traverse the internal capsule, but occupy the lateral sixth of the ipsilateral crus [1, 5, 7].

3.2.1.1. *Substantia nigra*

The pigmented substantia nigra, the largest single nuclear mass in the midbrain, is connected massively with the basal ganglia, but it has other projections as well it is considered to subserve a motor function. It looks like a darkened streak in unstained brain tissue; this is where it gets its name, which is Latin for “black substance.” Although it is often referred to as one structure, the substantia nigra is actually made up of two anatomically and functionally distinct portions: the substantia nigra pars compacta and the substantia nigra pars reticulata [2, 3]. Neurons in the pars compacta are much more densely packed together (or compact) than those in the pars reticulata. The compact zone appears as an irregular band of closely packed, large polygonal or pyramidal cells containing granules of melanin pigment. The reticular zone, also known as the stratum intermedium, lies close to the crus cerebri, and is composed of irregular shaped scattered cells that are rich in iron, but they do not contain melanin pigment. Most of the dopamine neurons of the brain originate in the midbrain and are found in either the substantia nigra or the ventral tegmental area, which is located adjacent to the substantia nigra [6, 8]. These dopamine neurons, however, are found predominantly in the substantia nigra pars compacta. The pars reticulata is instead populated largely by GABA neurons. Lesions of the substantia nigra or dopamine deficiencies result in Parkinson’s disease. Although it is still not clear what exactly causes neurodegeneration in Parkinson’s disease, when a significant number of these neurons have died, the individual will likely start to experience movement-related problems such as tremor, rigidity, slowing of movements, and postural instability—all hallmark symptoms of Parkinson’s disease [9].

Afferent fibers to the substantia nigra arise mainly from the caudate nucleus and the putamen. The efferent fibers of the substantia nigra project to the striatum and certain thalamic nuclei.

3.2.2. *Mesencephalic tegmentum*

Mesencephalic tegmentum is between the substantia nigra and the cerebral aqueduct. It usually contains ascending fiber tracts, cranial nerve nuclei, and the reticular formation nuclei.

The structures in this section are listed below:

3.2.2.1. *Red nucleus*

The red nucleus is paired, oval shaped, and approximately 5 mm in diameter, midline structure that appears red in a freshly dissected specimen. This unique appearance has been attributed to high vascularity of the structure in addition to the high level of iron pigments in the cytoplasm of its constituent neurons. It blends rostrally with the nearby reticular formation and interstitial nucleus. The nucleus consists of a large and ovoid column of cells extending from the caudal margin of the superior colliculus into the caudal diencephalon, and it appears as a circular mass which is traversed by the fibers of the oculomotor nerve [1, 3, 7].

Afferent fibers projecting to the red nucleus are derived from two principal sources, the cerebellar nuclei (approximately half of the fibers arising from the dentate nucleus pass rostrally beyond the red nucleus, cerebellorubral fibers), and the cerebral cortex (mainly from

the precentral gyrus, corticorubral fibers). Fibers of the superior cerebellar peduncle, arising from the dentate, globose and emboliform nuclei, undergo a complete decussation in the caudal midbrain, and both enter and surround the contralateral red nucleus.

The efferent fibers of the red nucleus continue through the spinal cord, the brainstem and the cerebellum. Rubrospinal fibers issue from the medial margin of the red nucleus. The fibers decussate and then run obliquely laterally in the ventral tegmental decussation (of Forel), ventral to the tectospinal decussation and dorsal to the medial lemniscus. Some efferent axons from a rubrobulbar tract to motor nuclei of the trigeminal, facial, oculomotor, trochlear and abducens nerves. Uncrossed descending rubral efferents, from the parvocellular part of the nucleus, enter the central tegmental tract and project to the dorsal lamella of the principal inferior olivary nucleus. These fibers are referred to as rubro-olivary fibers Physiology [3, 6, 7].

In humans, the lesions of a rubrospinal system are described as producing a syndrome characterized by contralateral motor disturbances that are variously designated as tremor, ataxia and choreiform activity and ipsilateral oculomotor palsy [1, 10].

3.2.2.2. Decussation of the superior cerebellar peduncle

All fibers of the superior cerebellar peduncle decussate at levels through the inferior colliculus. The decussation of superior cerebellar peduncle is the crossing of fibers of the superior cerebellar peduncle across the midline. It comprises the cerebellothalamic tract, which arises from the dentate nucleus, as well as the cerebellorubral tract, which arises from the globose and emboliform nuclei and project to the contralateral red nucleus to eventually become the rubrospinal tract [2, 7, 8].

It is important as an anatomical landmark, as lesions above it cause contralateral cerebellar signs, while lesions below it cause ipsilateral cerebellar signs.

3.2.2.3. Trochlear nucleus

The nucleus of the trochlear nerve is small and nearly circular and is on a level with a plane carried transversely through the upper part of the inferior colliculus. Root fibers emerging from the nucleus curve dorsolaterally and caudally in the outer margin of the central gray decussate completely in the superior medullary velum and from the dorsal surface of the brainstem caudal to the inferior colliculus [1, 2]. Root fibers emerging from the nucleus curve dorsolaterally and caudally in the outer margin of the central gray decussate completely in the superior medullary velum and exit from the dorsal surface of the brainstem caudal to the inferior colliculus. And then, it curves around the lateral surface of the brainstem, passes between the superior cerebellar and posterior cerebral arteries, and enters the cavernous sinus. It innervates the superior oblique muscle that serves to: intort the eye when abducted, and depress the eye when adducted. The trochlear nerve (CN IV) is the smallest nerve in terms of the number of axons it contains, and it has the longest length intracranially [1, 3, 5]. There are two major clinical syndromes that can manifest through damage to the trochlear nerve:

1. Vertical diplopia: Injury to the trochlear nerve causes weakness of downward eye movement with consequent vertical diplopia.
2. Torsional diplopia: Weakness of intorsion results in torsional diplopia, in which two different visual fields, tilted with respect to each other, are seen at the same time. To compensate, patients with trochlear nerve palsies tilt their heads to the opposite side in order to fuse the two images into a single visual field.

The clinical syndromes may originate from both peripheral and central lesions. A peripheral lesion is damage to the bundle of nerves, in contrast to a central lesion, which is damage to the trochlear nucleus [8, 10].

A lesion of the trochlear nucleus affects the contralateral eye. Lesions of all other cranial nuclei affect the ipsilateral side [10].

3.2.2.4. *Parabigeminal nucleus*

Ventrolateral to the inferior colliculus is a fairly well-defined zone known as the parabigeminal area. It is between the lateral lemniscus and the inferior colliculus and the surface of the brainstem that contains the parabigeminal nucleus. Some of the superior collicular efferents pass to the parabigeminal nucleus. Studies have shown that the parabigeminal nucleus is active with fixed or moving objects. In addition, the parabigeminal nucleus plays a role in assessing the vision together with the colliculus superior [2, 3, 7].

3.2.2.5. *Posterior commissure*

The posterior commissure is located in the inferior pineal lamina and lies rostral to the superior colliculus at the place where the cerebral aqueduct becomes the third ventricle. It is one of the commissural fibers of the brain known to be important in the pupillary light reflex. Various nuclei are associated with the posterior commissure. The best known of them is the interstitial nucleus of the posterior commissure, nucleus of Darkschewitsch; another one is the interstitial nucleus of Cajal. Fibers from the olivary nucleus cross on the opposite side and give collaterals to the visceral nuclei of the oculomotor complex (Edinger-Westphal nucleus) [2, 3, 11]. Some fibers are believed to be derived from the posterior part of the thalamus and from the superior colliculus and to continue directly to the medial longitudinal fasciculus. Fibers from the thalamic, pretectal, tectal region, and the habenular nuclei are known to connect with the posterior commissure, but they have not been shown anatomically.

Lesions in the nuclei of the posterior commissure, interrupting fibers from the intersititial nuclei of Cajal, produce bilateral eyelid retraction and impairment of vertical eye movements [12].

3.2.2.6. *Pretectal area and pretectal nucleus*

The pretectal region lies rostral to the superior colliculus at levels of the posterior commissure and rostrally by the habenular trigone, and laterally by the pulvinar thalami. This area is

composed of several distinct cell groups, most of which are related to the visual system. The nuclei of the pretectal area include pretectal olivar nucleus, medial, anterior and posterior pretectal nuclei, and optic tract nucleus [2, 13].

Afferents come from the lateral root of the optic tract from the retina, occipital cortical fields via the superior quadrigeminal brachium and the superior colliculus. Efferents go to the ipsilateral and contralateral accessory oculomotor nucleus and superior colliculus. They have bilateral efferent connections with the Edinger-Westphal nucleus of the oculomotor nuclear complex by way of which they mediate the pupillary light reflex. The efferent fibers reach both Edinger-Westphal nuclei. The decussate fibers pass ventral to the aqueduct or through the posterior commissure. In this way, sphincter pupillae contract in both eyes in response to impulses from either eye. Therefore, only relatively large lesions involving multiple structures in the pretectum appear to impair the pupillary light reflex [2, 8, 13].

3.2.2.7. *Medial longitudinal fasciculus*

The medial longitudinal fasciculus is situated in the brainstem, and it is a set of crossed fibers with ascending and descending fibers. The medial longitudinal fasciculus is a heavily myelinated composite tract lying near the midline, ventral to the periaqueductal gray matter. It links three main nerves which control eye movements including saccades (rapid refixations), that is, the oculomotor, trochlear and the abducent nerves, as well as the vestibulocochlear nerve. It interconnects the oculomotor, trochlear, abducens, Edinger-Westphal, vestibular, reticular and spinal accessory nuclei, coordinating conjugate eye movements and associated movements of the neck and head, including semicircular- and otolith-mediated ocular motor reflexes [1, 12, 14]. The medial longitudinal fasciculus provides a neural mechanism for simultaneous contraction of the lateral rectus muscle on the one side, and the medial rectus muscle on the opposite side, required for conjugate lateral gaze. It also forms a major component of the optokinetic and vestibulo-ocular reflexes.

The most commonly recognized syndrome that results from the medial longitudinal fasciculus damage is internuclear ophthalmoparesis, which is characterized by slowing or limitation of adduction (on the same side as the medial longitudinal fasciculus lesion) during horizontal eye movements. In patients with internuclear ophthalmoparesis, the contralateral abducting eye will usually exhibit a disassociated horizontal nystagmus, although this does not always occur [13, 15].

3.2.2.8. *Oculomotor nucleus*

The oculomotor nucleus is on the level of colliculus superior. The upper end of the nucleus approaches the bottom of third ventricle in the vicinity of commissura caudalis and the lower end the top of colliculus inferior, lying adjacent to the inner ventral edge of stratum griseum centrale surrounding aqueductus mesencephali. The nucleus of the oculomotor nerve is about 10-mm long. The oculomotor nuclear complex containing subnuclei that give rise to the axons of the oculomotor nerve, both motor and parasympathetic fibers, is situated at the midline, at the level of the superior colliculus

in the midbrain tegmentum [8]. The complex including the somatic portion is formed by multipolar motor neurons, and the parasympathetic portion is formed by oval or fusiform preganglionic cells, on each side of the median raphe. The somatic portion consists of the lateral somatic cell column and the caudal central nucleus. It is divided into the principal, intrafascicular and extrafascicular parts. The principal part is subdivided into the dorsal, intermediate and ventral portions. Isolated multipolar neurons are also found in the periaqueductal gray matter, the interstitial nucleus of Cajal, the Edinger-Westphal nucleus, and the fiber bundles of the oculomotor nerve. These cells most likely represent the displaced motor neurons of the oculomotor nerve. The Edinger-Westphal nucleus consists of the rostral, ventral and dorsal parts [16]. The lateral somatic cell columns innervate the extraocular muscles. The dorsal column innervates the inferior rectus muscle. The intermediate cell column innervates the inferior oblique muscle, and the ventral cell column supplies fibers to the medial rectus muscle. A cell column medial to both dorsal and intermediate cell column is referred to as the medial cell column, and it innervates the superior rectus muscle. The caudal central oculomotor nucleus is a midline somatic cell group found only in the caudal third of the complex, and it innervates the levator palpebrae muscle. As a result, the oculomotor nuclear complex innervates all extraocular muscles except the lateral rectus and the superior oblique, supplies the levator palpebrae muscle, and provides preganglionic parasympathic fibers to the ciliary ganglion [17]. Visceral nuclei of the oculomotor nuclear complex consist of two distinct nuclear groups which are in continuity rostrally, and often are collectively referred to as the Edinger-Westphal nucleus. Its afferent inputs come from the pretectal nuclei bilaterally and mediate the pupillary light reflex. In addition, they come from the visual cortex, mediating accommodation. Efferent fibers relay through the ciliary ganglion and synapse upon postganglionic neurons, which give rise to the short ciliary nerves. The postganglionic fibers innervate the ciliary body, concerned with the mechanism of accommodation, and the sphincter of the iris [1, 17, 18].

Oculomotor nerve palsy results in weakness of the medial rectus, inferior rectus, superior rectus, inferior oblique, and levator palpebrae, leading to an eye that is “out and down “. The oculomotor nerve also carries parasympathetic innervation to the pupil, responsible for pupil constriction. Oculomotor palsy may therefore leave the pupil dilated. Nuclear lesions usually occur due to small regions of infarction, and often there are no other neurological symptoms. In ventral midbrain, lesions are due to [HYPERLINK “https://radiopaedia.org/articles/benedikt-syndrome”](https://radiopaedia.org/articles/benedikt-syndrome) Benedikt syndrome and [HYPERLINK “https://radiopaedia.org/articles/weber-syndrome”](https://radiopaedia.org/articles/weber-syndrome) Weber syndrome [2, 5, 19, 20].

Pupillary light reflex consists of a simultaneous and equal constriction of the pupils in response to illumination of one or the other eye. The afferent axons of retinal ganglion cells pass into the optic nerve and decussate in the chiasm, and pass with the optic tract to the midbrain. The pupillary fibers do not synapse with the visual fibers in the lateral geniculate body, but pass to the pretectal nuclei at the level of the superior colliculus with intercalated fibers that pass as the efferent pupillary pathway to the Edinger-Westphal nucleus of the oculomotor nerve on both sides. Preganglionic parasympathetic fibers run in the oculomotor nerve as it leaves the brainstem. The fibers pass downward to lie inferiorly in the

inferior division of the third nerve as it enters the orbit. These fibers synapse in the ciliary ganglion and give rise to postganglionic parasympathetic myelinated short ciliary nerves [1,19, 20, 21].

The accommodation-convergence reaction occurs when gaze is shifted from a distant object to a near one. The accommodation reflex has its afferent input from the primary visual pathway; sequentially retina, optic nerve, optic chiasm, optic tract, lateral geniculate body, optic radiation, visual cortex and area 17. The peristriate area 19 interprets accommodation, and sends signals via the Edinger-Westphal nucleus and the oculomotor nerve to the ciliary muscle, the medial rectus muscle and the sphincter pupillae muscle [20, 21].

3.2.2.9. *Mesencephalic reticular formation*

The mesencephalic reticular formation is less extensive than the pontine reticular formation caudal to it. It is a neuronal structure located in the core of the brainstem, its caudal boundary crosses of the superior cerebellar peduncle, and extends rostrally to the thalamic reticular nucleus. It is reciprocally interconnected with the superior colliculus. Even though detailed studies have indicated that the red nucleus is recognized as a distinctive part of the reticular formation, the principal reticular nuclei of the mesencephalon are: 1. The pedunculopontine nucleus, 2. The nucleus cuneiformis, and 3. The nucleus subcuneiformis. Original function is defined as a part of the reticular activating system. There is clear evidence showing that there are subgroups of cells that participate in the control of saccadic and vergence eye movements. The mesencephalic reticular formation has two major subdivisions. The posterior commissure in the sub-human primate serves to separate the mesencephalic reticular formation into rostral and caudal regions. The cells of the rostral portion of the mesencephalic reticular formation are associated with the control of vertical eye movements, while neurons in the caudal region also called as the central mesencephalic reticular formation are more closely associated with the control of horizontal eye movements [1, 7, 22].

3.2.2.10. *Interpeduncular nuclei*

It is a ventral nucleus of the midbrain tegmentum lying between the right and left substantia nigrae, which cap the two cerebral peduncles. The interpeduncular nucleus receives axons from the habenula, and it sends axons dorsally, to the midbrain raphe nuclei. The pathways described above constitute a part of the complex system by which impulses related to the limbic system are projected to midbrain levels [1–4].

3.2.2.11. *The mesencephalic nucleus of the trigeminal nerve*

The mesencephalic nucleus of the trigeminal nerve that is composed of large unipolar neurons forms a slight cell column near the lateral margin of the central gray of the upper part of the cerebral aqueduct. The nucleus extends from the level of the motor nucleus into the rostral midbrain. The cell bodies located in mesencephalic nucleus of the trigeminal nerve are actually connected to primary sensory fibers primarily coming from masticatory muscles. This is the only place in the

nervous system where the cell bodies of primary afferent fibers are found in the central nervous system rather than in ganglia outside of it. It houses proprioception for all muscles of the head and face. This nucleus has connections to the motor nucleus of the trigeminal nerve [1, 3, 13].

Afferent fibers of the mesencephalic nucleus of the trigeminal nerve convey proprioceptive impulses (kinesthesia and pressure) from the teeth, periodontium, hard palate, muscles of mastication and joint capsules. The mesencephalic nucleus of the trigeminal nerve receives afferent impulses from stretch receptors in the muscles of mastication. The jaw proprioception pathway consists of sensory pseudounipolar neurons. Their peripheral processes consist of stretch receptors that terminate in the muscles of mastication. Their central processes bifurcate to send a branch to the principal sensory nucleus, and another branch to the rostral portions of the spinal nucleus. Second-order neurons from these nuclei project to the ventral posteromedial nucleus of the thalamus, which in turn projects to Brodmann's area 3a on the medial surface of the primary somatosensory cortex in the parietal lobe where position sense of the mandible enters conscious awareness. Although proprioceptive information is generally processed by the mesencephalic neurons, their receptors, and their central connections, some proprioception is relayed from the temporomandibular joint, and extraocular muscle spindles [2–5, 13].

3.2.2.12. Sensory tracts of the tegmentum

Medial lemniscus: It is formed by the crossings of internal arcuate fibers, composed of axons of nucleus cuneatus and nucleus gracilis. It ascends from the lemniscal decussation on each side, as a flattened tract near the median raphe. This large ascending fiber bundle can be readily followed through the brainstem to its termination in the ventral posterolateral nucleus of the thalamus. On the transverse section of the midbrain, the medial lemniscus is dorsal in tegmentum. Medial lemniscus is important for somatosensation from the joints and skin, and therefore, lesions of the medial lemnisci cause an impairment of vibratory and touch-pressure sense [1, 2, 5].

Lateral lemniscus: The lateral lemniscus projects to the contralateral side from the dorsal cochlear nucleus. The ventral cochlear nuclei project to the superior olivary nuclei on both sides as well as into the lateral lemniscus on each side. Thus, the lateral lemniscus contains axons originating from cells in the dorsal and ventral cochlear nuclei and in the superior olivary nucleus. The lateral lemniscus terminates in the central nucleus of the inferior colliculus. The principal ascending auditory pathway in the brainstem courses rostrally in the lateral part of the tegmentum [3, 6, 13].

3.2.3. Tectum

The tectum is located in the dorsal part of the midbrain, below the diencephalon. The name comes from the Latin word for "roof." Tectum is composed of a set of *colliculi superior* and *colliculi inferior*, which resemble small lumps and are responsible for initial processing of sensory information from the eyes and ears. Tectum is responsible for visual and auditory reflexes [3, 5, 13].

3.2.3.1. Superior colliculi

The superior colliculus refers to the rostral bump on the lateral side of the midbrain. It receives afferents from a number of sources including the retina, spinal cord, inferior colliculus and

occipital and temporal cortices. Collicular efferents pass to retina, lateral geniculate nucleus, pretectum, parabigeminal nucleus, thalamus and spinal cord. They pass through the pulvinar relay to primary and secondary visual cortices. The tectobulbar and tectospinal tracts start from neurons in the superior colliculi and sweep ventrally round the central gray matter to decussate ventral to the oculomotor nuclei and medial longitudinal fasciculi as part of the dorsal tegmental decussations (of Meynert) (**Figure 2**). The superior colliculus is not restricted to a visual role alone. It also helps orientation of the eyes and head. Part of the colliculus sticks out in the direction of the spinal cord region. This key projection helps the head to respond to different sensory stimuli. The superior colliculus is concerned primarily with the detection of the direction of movement of object in the visual fields, and in this way, it facilitates visual orientation, searching and tracking [1, 2, 8].

The collicular stimulation produces contralateral head movement as well as movements involving the eyes, trunk and limbs, which implicates the superior colliculus in complex integration between vision and widespread body activity.

3.2.3.2. *Inferior colliculi*

The inferior colliculus is a part of the midbrain that serves as a main auditory (sound) center for the body (**Figure 3**). It consists of a compact nucleus of gray substance containing large and small multipolar nerve cells, and more or less completely surrounded by white fibers derived from the lateral lemniscus. Its primary roles are signal integration, frequency recognition, and pitch discrimination. It also processes sensory signals from the superior colliculi, located above it. The inferior colliculi is the relay station for Auditory Pathway. It receives fibers from the lateral lemniscus, the opposite inferior colliculus, the ipsilateral medial geniculate body and the auditory cortex. Most efferent fibers travel via the inferior brachium to the ipsilateral medial geniculate body. Some colliculogeniculate fibers do not relay in the geniculate body, but continue, with those that do, via the auditory radiation to the auditory cortex area. In few, they pass to the opposite inferior colliculus and the superior colliculus [2, 5, 8].

In experimental animals, lesions of either the inferior colliculus or its brachium produce defects in tonal discrimination, sound localization and auditory reflex. The effects of such lesions are poorly documented in humans (**Table 1**) [23].

4. Blood supply of the midbrain

The brain receives blood from two sources: the internal carotid arteries and the vertebral arteries. The internal carotid arteries arise at the point in the neck where the common carotid arteries bifurcate. It branches to form two major cerebral arteries (terminal branches): the anterior and middle cerebral arteries. The vertebral arteries (right and left) arise from the subclavian artery. They come together on the ventral surface of the brain-stem at the level of the pons to form the midline basilar artery. The basilar artery joins the blood supply from the internal carotids in an arterial ring called the circle of Willis. Conjoining two major sources of cerebral vascular supply via the circle of Willis presumably improves the chances of any region of the brain continuing to receive blood if one

of the major arteries becomes occluded. The basilar artery undergoes bifurcation at the site of midbrain, forming two posterior cerebral arteries. Both posterior cerebral arteries travel around the cerebral peduncles, and branch into the midbrain forming a series of slender, long penetrating arteries that are responsible for supplying blood to the thalamus and hypothalamus [2, 3, 8, 24].

The mesencephalon receives its blood supply principally from branches of the basilar artery, although branches of the internal carotid also contribute. The main vessels supplying this portion of the brainstem include:

- 1. The posterior cerebral artery (terminal branch of the basilar artery)
- 2. The superior cerebellar artery (branch of the basilar artery)
- 3. Branches of the posterior communicating artery (branch of the internal carotid artery)
- 4. Branches of the anterior choroidal artery (branch of the internal carotid artery)

Numerous veins of the mesencephalon arise from capillaries and, in general, run near the arteries. These veins form an extensive peripheral plexus in the pia and are collected by the basal veins which drain into either the great cerebral vein (Galen) or the internal cerebral veins [1, 2, 8].

5. Lesions of the midbrain (midbrain lesions)

Lesions of the midbrain are described in the following (Table 1) [2, 13, 24, 25].

	Lesions	Symptoms
Parinaud’s syndrome (dorsal midbrain syndrome)	It localizes pathology to impingement of or origin in the tectal plate, most frequently due to a posterior commissure or pineal region mass (typically solid tumors rather than pineal cysts) (Figure 4)	Convergence-retraction nystagmus pupillary light-near dissociation upward gaze palsy, often manifesting as diplopia
Benedict syndrome (paramedian midbrain syndrome)	It is a rare form of posterior circulation stroke of the brain,	Oculomotor nerve (CN III) palsy
	A lesion within the tegmentum of the midbrain can produce this syndrome (Figure 5)	Cerebellar ataxia including tremor Neuroanatomical structures affected include: red nucleus, corticospinal tracts, brachium conjunctivum, the superior cerebellar peduncle decussation
Weber’s syndrome	Paramedian infarct of midbrain,	The lesioned substantia nigra causes contralateral parkinsonism

	Lesions	Symptoms
(Superior alternating hemiplegia)	A lesion within the crus cerebri of the midbrain can produce this syndrome (Figure 6)	<p>Damage to the corticobulbar tract will produce difficulty with contralateral lower facial muscles and hypoglossal nerve functions</p> <p>Damage to the corticospinal tract will produce contralateral hemiparesis and typical upper motor neuron findings</p> <p>Damage to the oculomotor nerve fibers lead to ipsilateral oculomotor nerve palsy with a drooping eyelid and fixed wide pupil pointed down and out this leads to diplopia</p>

Table 1. Lesions of the midbrain.

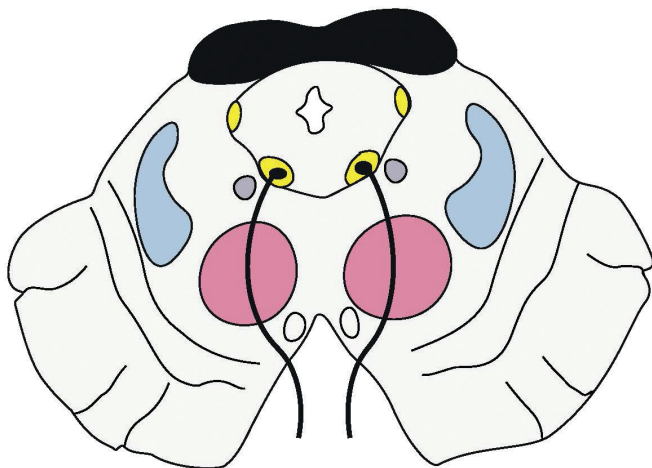

Figure 4. Parinaud’s syndrome (dorsal midbrain syndrome).

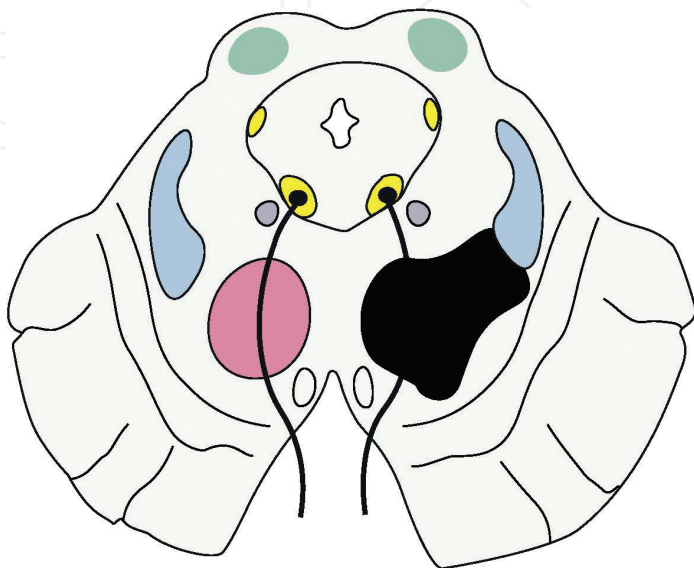


Figure 5. Benedict syndrome (paramedian midbrain syndrome).

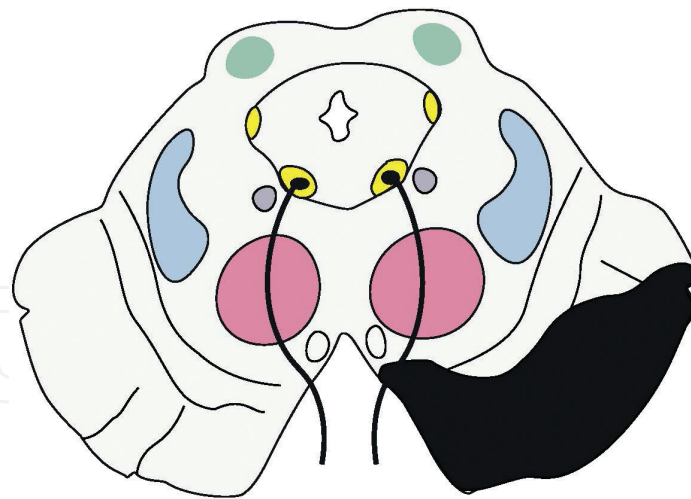


Figure 6. Weber's syndrome (superior alternating hemiplegia).

Author details

Ayla Kurkcuoglu

Address all correspondence to: kayla@baskent.edu.tr; kurkcuoglua@hotmail.com.tr

Department of Anatomy, Faculty of Medicine, Baskent University, Baglica, Ankara, Turkey

References

- [1] Carpenter MB. Human Neuroanatomy. 7th ed. Baltimore, USA: Williams & Wilkins; 1976. Pp. 657-662
- [2] Moore KL, Dalley AF. Clinical Oriented Anatomy. 5th ed. Philadelphia: Lippincott Williams and Wilkins; 2002. pp. 929-935
- [3] Gray's Anatomy. The Anatomical Basis of Clinical Practice. 39th ed. USA: Elsevier Crushill Livingstone; 2005. pp. 340-349
- [4] Carlson BM. Human Embryology and Developmental Biology. 4th ed. Mosby Elsevier; 2009. Pp. 239-245
- [5] Martin HJ. Neuroanatomy Text and Atlas. 2nd ed. 1996. pp. 522-525
- [6] Brodal P. The Central Nervous System: Structure and Function. New York: Oxford University Press; 2004
- [7] Patestas MA, Gartner LP. A Textbook of Neuroanatomy. John Wiley & Sons; 2016. p. 328

- [8] Brodal P. Neurological Anatomy. 3rd ed. New York; 1981. pp. 533-534
- [9] <http://www.neuroscientificallychallenged.com/blog/know-your-brain-substantia-nigra>
- [10] <https://www.boundless.com/physiology/textbooks/boundless-anatomy-and-physiology-textbook/peripheral-nervous-system-13/cranial-nerves-131/trochlear-iv-nerve-701-8443/>
- [11] Ozdemir NG. The anatomy of the posterior commissure. Turk Neurosurg. 2015;**25**(6):837-43. DOI: 10.5137/1019-5149.JTN.12122-14.2
- [12] Carpenter MB, Peter P. Accessory oculomotor nuclei in the monkey. The Journal für Hirnforschung. 1970;**12**:405-418
- [13] Snell RS. Clinical Anatomy by Systems. Baltimore: Lippincott Williams and Wilkins; 2007. pp. 557-570
- [14] Paul R. Spinal Tracts—Descending/Motor Pathways Essential Clinical Anatomy of the Nervous System, Chapter 9. 2015. pp 161-176. DOI: <http://dx.doi.org/10.1016/B978-0-12-802030-2.00009-1>
- [15] Frohman TC, Galetta S, Fox R, Solomon D, Straumann D, Filippi M, Zee D, Frohman EM. Pearls & Oy-sters. The medial longitudinal fasciculus in ocular motor physiology. Neurology. 2008, 22;**70**(17):e57-67. DOI: 10.1212/01.wnl.0000310640.37810.b3
- [16] Donzelli R, Marinkovic S, Brigante L, Nikodijevic I, Maiuri F, de Divitiis O. The oculomotor nuclear complex in humans. Microanatomy and clinical significance. Surgical and Radiologic Anatomy. 1998;**20**(1):7-12
- [17] Saiyo A. Microscopical study of oculomotor nucleus in human adult. The Tohoku Journal of Experimental Medicine. 1953;**5**:3-4
- [18] Purves D, Augustine GJ, Fitzpatrick D. Neuroscience. 2nd ed. Sunderland (MA): Sinauer Associates; 2001
- [19] Kaufman, Paul L, Levin, Leonard A, Alm, Albert. Adler's Physiology of the Eye. Elsevier Health Sciences; 2011. p. 508
- [20] Lo CP, Huang CF, Hsu CC. Neuroimaging of isolated and non-isolated third nerve palsies. The British Journal of Radiology. 2012;**85** (1012):460-467. DOI: 10.1259/bjr/38090653AkdalG
- [21] Waugh A, Grant A. Anatomy and Physiology in Health and Illness. 11th ed. Toronto: Churchill Livingstone Elsevier; 2010. pp. 147-154
- [22] Binder DM, Hirokawa N, Windhorst U. Mesencephalic Reticular Formation (MRF). Encyclopedia of Neuroscience. 2009. pp. 2339-2339. DOI: 10.1007/978-3-540-29678-2_3444
- [23] <http://www.healthline.com/human-body-maps/inferior-colliculus>

- [24] Ruchalski K, Hathout GM. A medley of midbrain maladies: A brief review of midbrain anatomy and syndromology for radiologists. *Radiology Research and Practice*. Volume 2012, Article ID 258524, 11 pages. DOI: 10.1155/2012/258524
- [25] Kutluk K, Men S, Yaka E. Benedikt and “plus-minus lid” syndromes arising from posterior cerebral artery branch occlusion. *Journal of the Neurological Sciences*. 2004;**228**(1):105-107. DOI: 10.1016/j.jns.2004.09.029. PMID 15607218