

We are IntechOpen, the world's leading publisher of Open Access books Built by scientists, for scientists

6,900

Open access books available

185,000

International authors and editors

200M

Downloads

Our authors are among the

154

Countries delivered to

TOP 1%

most cited scientists

12.2%

Contributors from top 500 universities



WEB OF SCIENCE™

Selection of our books indexed in the Book Citation Index
in Web of Science™ Core Collection (BKCI)

Interested in publishing with us?
Contact book.department@intechopen.com

Numbers displayed above are based on latest data collected.
For more information visit www.intechopen.com



Surgical Treatment of Angio-Behçet

Genadi Georgiev Genadiev, Lorenzo Mortola,
Roberta Arzedi, Giuseppe Deiana,
Francesco Spanu and Stefano Camparini

Additional information is available at the end of the chapter

<http://dx.doi.org/10.5772/intechopen.68664>

Abstract

Patients with Behçet's disease are at risk for multiple vessel-related complications including thromboses, stenoses, occlusions, and aneurysms. Surgical treatment of Angio-Behçet brings numerous challenges due to the peculiarities of the disease process and the high rate of complications. Recurrent vascular episodes are also quite common and Behçet patients require rigorous follow-up. In this review, we focus on the manifestations of Behçet's disease involving the venous system and the systemic arterial vasculitis focusing on the indications, workup, and techniques for surgical treatment. Several case studies from our own experience are presented together with supporting diagnostic imaging and the decision process whether to intervene is discussed. Although open surgery remains a valid option, new endovascular techniques are rapidly advancing and offer excellent results with important decrease in morbidity and mortality even in highly compromised patients.

Keywords: vascular, arterial, venous, EVAR, TEVAR, aneurysm, thrombosis

1. Introduction

Patients with Behçet's disease (BD) are at risk for multiple vessel-related complications including thromboses, stenoses, occlusions, and aneurysms. Venous involvement is predominant in comparison with arterial involvement (4:1) [1]. Recurrent vascular episodes are quite common with incidence of up to 23% after 2 years and up to 40% at 5 years [2]. Calamia et al. have proposed a classification of the vascular lesions of the great vessels [3] (**Table 1**).

Vascular arterial manifestations of Behçet's disease are observed in 7–29% of patients affected from this disease and arterial lesions represent 15% of all vascular lesions in BD [4, 5]. Arterial

Systemic arterial vasculitis
Aneurysms
Stenoses/occlusions
<i>Pulmonary arterial vasculitis</i>
Aneurysms
Stenoses/occlusions
<i>Venous occlusions</i>
Superficial venous thrombosis
Deep venous thrombosis
Cerebral venous thrombosis
Budd-Chiari syndrome
Portal vein thrombosis
Right ventricular thrombosis
Pulmonary emboli
<i>Varices</i>

Table 1. Classification of the vascular lesions of the great vessels.

lesions pose a greater risk and are associated with a large impact on the prognosis due to the severity of complications [6]. Most common arterial lesions observed in BD are occlusions/stenosis and aneurysms/pseudoaneurysms. Though theoretically any arterial vessel can be affected by these lesions, most commonly affected segments are, in order of frequency, abdominal aorta, pulmonary, femoral, popliteal, and carotid arteries [7]. Clinical presentation varies and can include acute or chronic limb ischemia, aneurysmal thromboses or rupture, and stroke [4]. Rupture is the most frequent complication of aneurysms and the most common cause of vascular-related death in BD [8]. Arterial involvement can be recurrent and is often associated with venous involvement; aneurysms can develop at various sites simultaneously and may be associated to occlusive lesions even in the same patient [9, 10]. Pulmonary arterial lesions are most frequently associated to venous thrombosis [11].

Surgical treatment of arterial manifestations of BD bears many pitfalls, since the obliterative endarteritis of vasa vasorum causes thickening of the medial layer and splitting of elastin fibers. Therefore, anastomotic pseudoaneurysms are likely to form, as well as pseudoaneurysms at the site of puncture in case of angiography or endovascular treatment; furthermore, early graft occlusion may occur [4, 8, 12].

For these reasons, invasive treatment should not be performed in the acute and active phases of the disease when inflammation is at its peak. The evaluation of disease's activity is usually based on relapsing symptoms, ESR (erythrocyte sedimentation rate), and serum levels of CRP (C-reactive protein) [13, 14].

Endovascular treatment can be an effective and safe alternative to open surgery, with less postoperative complications, faster recovery time, and reduced need for intensive care, while offering patency rates and procedural success rates comparable with those of surgery [15, 16]. This notwithstanding, long-term results of endovascular treatment in BD are still to be determined.

2. Venous involvement

Superficial vein thrombosis (SVT) has been found by some to be the dominant lesion (up to 53% of the patients), whereas others have found deep vein thrombosis (DVT) to be more prevalent (up to 80%) although still highly correlating with SVT [16–18]. Duplex ultrasound (DUS) is the diagnostic modality of choice allowing for differentiation between a recent (hypoechoic) and old (hyperechoic in the context of wall thickening) thrombus. Treatment is mainly medical, although there is considerable debate as to the use of anticoagulants, antiplatelet, or fibrinolytic agents. The European League Against Rheumatism (EULAR) does not recommend their use as the thrombus usually adheres firmly to the vessel wall and does not result in emboli which would explain the low incidence of pulmonary embolism [19].

Superior vena cava thrombosis can be observed in about 2.5% of the cases and can also be secondary to axillary or subclavian vein thrombosis [3]. Superior vena cava syndrome, which results from complete or partial obstruction of venous return from the upper body, can be asymptomatic or can present with dyspnea, facial swelling, head fullness, cough, arm swelling, chest pain, dysphagia, and pleural effusions. Obstruction of venous flow can also be a result of lumen reduction due to thickening of the vessel wall without evidence of thrombosis. The preferred diagnostic modality is chest computed tomography (CT). Magnetic resonance imaging (MRI) has increased sensitivity in establishing the thrombus extension particularly toward the heart.

Case 1 (Figure 1): A 20-year-old male patient with BD presents with ill-defined abdominal pain. A CT scan is performed showing a partial filling defect in the suprahepatic portion of the inferior vena cava, just distal to the right atrium. The hepatic veins were patent and venous flow through the partially

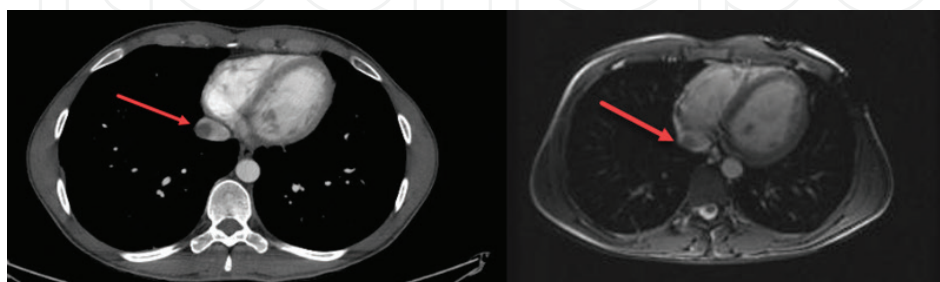


Figure 1. CT scan and Gd-DPTA MRI scan in a 20-year-old male BD patient showing inferior vena cava thrombosis in its supradiaphragmatic segment.

obstructed IVC was maintained. The patient was treated with oral anticoagulation therapy for 6 months, undergoes frequent follow-up visits, and is currently asymptomatic.

Inferior vena cava thrombosis can be found in up to a third of the patients with BD [3, 17]. Budd-Chiari syndrome is a complication resulting from the thrombosis of the retrohepatic portion of the IVC. DUS can be useful in the diagnosis and CT and MRI can help further define asymmetry in hepatic perfusion [20].

Portal vein thrombosis is another common finding in Behçet's syndrome occurring in approximately 9.2% of the patients and rapidly giving way to cavernous transformation characterized by numerous collaterals at the hepatic hilum and around the thrombosed portal branches [3, 21, 22]. Portal vein thromboses could present as ascites, splenomegaly, hepatomegaly, and hepatic infarction. Mesenteric ischemic involvement can also lead to infectious portal vein thromboses and liver abscesses.

Surgical treatment in venous thrombosis is limited to portocaval shunting in Budd-Chiari syndrome. Transjugular intrahepatic portocaval shunt (TIPS) can be performed if the vena cava is patent. Thrombolytic therapy can be considered in the acute phase involving the vena cava or portal vein with direct infusion of urokinase or tissue plasminogen activator (tPA) [23].

2.1. Abdominal aortic aneurysm

An abdominal aortic aneurysm (AAA) is defined as an abdominal aortic diameter of 3.0 cm or more in either anterior-posterior or transverse planes [24]. A pseudoaneurysm is defined as a tear through the layers of the arterial wall resulting in hematoma formation outside the vessel, circumscribed by periarterial tissue, with a persistent communication between the artery and the newly formed cavity.

While in atherosclerotic disease the indication to the treatment of AAA is dependent on the aneurysmal size because of the direct relationship between this parameter and the risk of rupture, in BD aneurysms should be repaired as soon as possible because of high rupture risk due to the underlying aortitis [13, 25]. Most frequently, the aneurysm is located below the emergency of renal arteries, but every segment of the aorta can be affected, and the shape is usually saccular [13].

AAAs are usually asymptomatic and may go unnoticed until symptoms develop in the late stages of the disease, such as compression of nearby structures, back pain, erosion of vertebral bodies, and hydronephrosis. At physical examination, a mesogastric pulsatile swelling can be observed.

The most dangerous complication of AAAs is rupture, defined as bleeding outside the adventitia of a dilated aortic wall, rapidly leading to death of the patient if a repair is not performed quickly. Rupture can occur in retroperitoneal cavity, with peritoneal tissue providing tamponade and thus reducing the volume of blood loss. Symptoms of ruptured AAA include abdominal acute pain and abdominal swelling, femoral arteries pulselessness and acute lower limbs ischemia, embolic events, and signs of hemorrhagic shock [16, 26].

2.2. Imaging

Diagnosis can be confirmed by DUS, which is noninvasive, is cheap, and has high sensitivity and specificity for the detection of AAAs. Ultrasound is limited in the definition of infra- and suprarenal borders of the aneurysm, presence of periaortic disease, and of evaluation of iliac arteries aneurysms. Angiography is not usually recommended as routine imaging modality for AAAs. Additionally, patients affected from BD are more prone to undergo postangiography complications like pseudoaneurysm formation at the site of puncture [4, 26]. Computed tomography angiography (CTA) is a fast, reliable, and reproducible method for preoperative study of abdominal aortic aneurysms, providing detailed anatomical information like aortic diameters and segment lengths, as well as three-dimensional (3D) reconstructions and post-processing. These parameters are particularly needed in case an endovascular aortic repair (EVAR) is being planned. Magnetic resonance angiography (MRA) is also a reliable imaging method, but is more expensive and time consuming compared to CTA [18, 26].

2.3. Preoperative assessment

Medical optimization according to best current evidence is mandatory before arterial surgery, and in BD it includes the pre- and postoperative administration of glucocorticoids and immunosuppressive agents in order to minimize postoperative complications like anastomotic pseudoaneurysm formation [12, 27]. All patients should have an evaluation of their respiratory function, and they should be referred to the specialist in order to optimize respiratory function prior to surgery if needed. In case of smokers, smoking cessation is mandatory. Ischemic cardiac events are a major cause of perioperative morbidity and mortality in aortic and peripheral surgery, accounting for 10–40% of perioperative death due to myocardial infarction. Cardiac risk assessment is crucial. Detailed patient's medical history should be collected, a resting ECG should be performed in all patients, and further investigations such as stress echo or coronary angiography should be performed if needed [26]. Renal function should also be assessed prior to surgery, whether open or endovascular. Serum creatinine has to be measured and glomerular filtration rate (eGFR) estimated. If needed, patients should be referred to a renal physician for optimization of medications and of renal function prior to surgery [26]. Preoperative assessment should include a specialist vascular anesthetist's evaluation for both general (required for open surgery) and local anesthesia (could be considered in EVAR) [26].

2.4. Open infrarenal AAA repair technique

Open aortic aneurysm repair is usually performed through transperitoneal or retroperitoneal approach, depending on the specific patient's needs, on the location of the aneurysm, and on the surgeon expertise. For infrarenal AAA repair, midline laparotomy is the most usual approach, consisting of a vertical incision from the xiphoid process to the pubic symphysis, the extension depending on the involvement of the iliac arteries. After viscera exploration and retraction, the retroperitoneum is incised on the left of the midline, identifying the left renal vein and the proximal aortic neck.

A cornerstone to the surgical treatment of arterial involvement in BD is to perform the anastomosis, whenever possible, in a macroscopically disease-free neck, as far as possible from the inflamed segment [25]. The dissection continues vertically toward the right iliac artery. For complete left iliac artery's exposure, the dissection of mesosigmoid ligament is required. Once the proximal and distal neck of the aneurysm are identified and dissected, heparin is administered and the aorta is clamped proximally and distally to the aneurysm, extending to the iliac arteries if needed. The aneurysm is incised longitudinally, the mural thrombus is removed, and lumbar arteries' ostiums are sutured if bleeding. Inferior mesenteric artery may be ligated or reimplanted, depending on the adequacy of collateral circulation. An adequate sized tubular or bifurcated graft is then sutured with a continuous nonabsorbable monofilament suture to the proximal neck (**Figure 2**). Prosthetic or omentum wrapping on the proximal aortic anastomotic site is described in order to prevent anastomotic false aneurysm formation, which occurs in 10–50% of the cases [13, 25].

2.5. Endovascular aortic repair

Case 2 (Figure 3): A 45-year-old male BD patient presents with pulsatile abdominal mass. Duplex ultrasound and a contrast CT scan reveal the presence of an infrarenal abdominal aortic aneurysm with bulging of the posterolateral wall at the iliac bifurcation. The patient is successfully treated with a modular aortobisiliac endograft.

EVAR is reported to be an effective and safe alternative to open repair for aortic aneurysms in BD, since the absence of anastomosis prevents the formation of pseudoaneurysms at their sites [14, 25]. Patients affected from BD may be better candidates for endovascular treatment than patients affected from atherosclerotic disease: they usually are younger, have smaller aneurysms, fewer comorbidities, and better renal function [28]. These characteristics positively affect the outcomes of endovascular interventions in BD: technical success rate is high due to the nonatherosclerotic nature of the lesions that implies easier introduction and navigation of endovascular devices inside vessels, mortality rate is lower (0.6 vs. 3.5%), and postoperative hospital stay is shorter when compared to open repair [13, 16]. Preoperative imaging is essential to EVAR in order to evaluate if the anatomical requirements for the endovascular repair are met: proximal neck diameter ≤ 32 mm, proximal neck length ≥ 10 mm, proximal neck

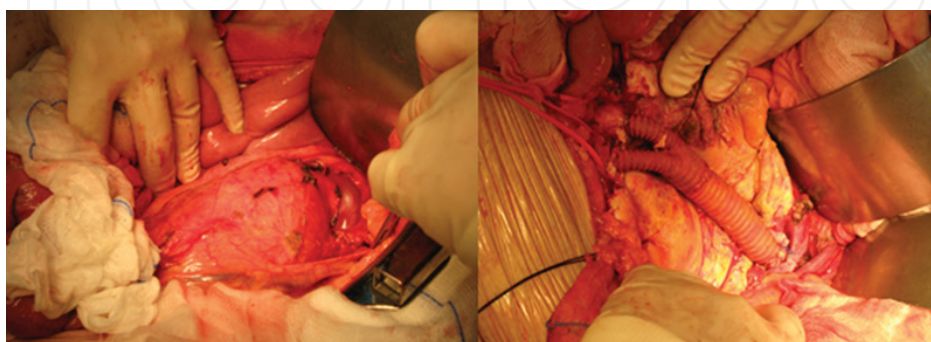


Figure 2. Open repair of a 78-mm abdominal aortic aneurysm (left) in a 42-year-old male BD patient with an aortobisiliac graft (right).

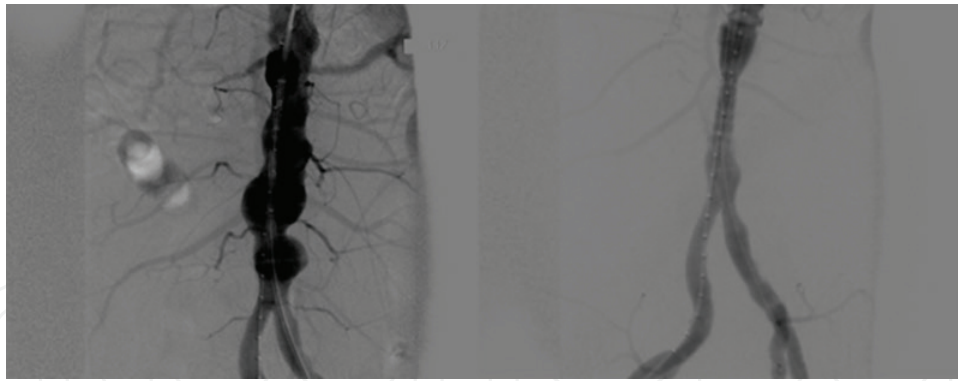


Figure 3. Endovascular repair (EVAR) of an infrarenal AAA (left) with an aortobisiliac endograft (right).

angulation $\leq 90^\circ$ [29, 30]. Since the potential proximal progression of the disease, we suggest to consider a proximal neck length of at least 15 mm, thus preventing proximal leakage subsequent to the proximal expansion of the aneurysmatic sac. Anatomical features of iliac-femoral arteries are also to be evaluated. In BD, it is rare to find narrow, calcified, and tortuous arteries like in atherosclerosis; however, femoral arteries must be of adequate size since the endoprosthesis delivery system is introduced through these arteries. Nowadays, low-profile devices are available, with an outer diameter of 14F (1 F = 0.33 mm), allowing EVAR to be performed in a large percentage of patients [31].

2.5.1. Technique

The patient is placed in supine position. Bilateral femoral access can be obtained via surgical cutdown or percutaneous femoral artery puncture. The artery is punctured using Seldinger's technique after systemic heparinization. Under fluoroscopic guidance, an introducer is placed and a starter, hydrophilic guidewire, is advanced across the lesion and substituted with a stiff guidewire; the latter requires straightening tortuosity of the access vessel and improving the tracking capabilities of the introduced catheters and devices. On the contralateral access, an angiographic catheter is placed in aorta proximally to the aneurysm. Most of commercially available aortic endoprosthesis are modular, composed of a main bifurcated body, a contralateral branch, and in some cases an ipsilateral branch. Angiography is performed and renal arteries visualized. The main body of the endograft is then introduced and placed just below the emergency of the renal arteries; in cases of short proximal neck or juxta/suprarenal aneurysms, fenestrated and branched endografts are available. After placing the main body, the contralateral limb is progressed on a stiff guidewire through contralateral access and placed under fluoroscopic guidance. The aim of the endograft implantation is to exclude the aneurysmal sac from the blood flow, leading to its shrinkage.

2.5.2. Complications

Endoleaks are a primary complication of EVAR. Endoleaks can be defined as residual leakage of blood into the aneurysm and may lead to sac expansion and rupture. Endoleaks have been classified into five categories according to the site of leakage (**Table 2**). Type I endoleaks

I	Ineffective seal	IA	Proximal
		IB	Distal
		IC	Iliac occluder devices
II	Collateral flow inside the sac	IIA	Inferior mesenteric artery
		IIB	Lumbar arteries
III	Structural deficit	IIIA	Modular disconnect
		IIIB	Endograft rupture
IV			Graft porosity
V			Endotension

Table 2. Types of endoleak.

occur for incomplete sealing in the proximal- or distal-landing zone of the graft. The high-pressure flow seen in this complication exposes the patient to immediate risk of rupture and therefore should be treated promptly. Type II endoleaks occur as a result of collateral backflow into the aneurysm from branch vessels such as the inferior mesenteric or lumbar arteries. Type II low-flow endoleaks usually disappear on subsequent follow-up scans but as much as 25% require correction which can be performed with open, laparoscopic, or endovascular approach. Type III endoleaks occur in between the modular components of the endograft or through tears or defects in the graft and can usually be repaired by positioning additional cuffs or covered stents inside the graft. Type IV endoleaks occur through porosities in the graft fabric [32]. Type V endoleaks have unknown origin and are characterized by increased tension inside the aneurysmal sac (endotension). Although Type IV and V endoleaks are rare, they might lead to sac growth and if that is demonstrated during follow-up, open surgery for the removal of the endograft and substitution with a traditional prosthesis is necessary.

Case 3 (Figure 4): A 46-year-old male BD patient presents with pulsatile mass in the right groin, the site of a previous arterial access for positioning of an EVAR device for exclusion of abdominal aortic aneurism. DUS and contrast CT scan reveal the presence of a 41-mm pseudoaneurysm at the access site. The pseudoaneurysm is successfully treated with ultrasound-guided thrombin injection.

Pseudoaneurysm formation at the site of puncture may occur, but these are easier to correct compared to pseudoaneurysms at the anastomotic site in the aortoiliac region [8, 14, 25]. In order to prevent this complication, it is recommendable to perform high-pressure compression at the site of puncture for 8 h after the procedure [7]. The use of closure devices may be an effective strategy to prevent this complication, though little information is available comparing closure devices to surgical cutdown in these patients [15].

Other rare complications in EVAR include peripheral or visceral embolization, acute renal failure, and graft migration [26, 32].

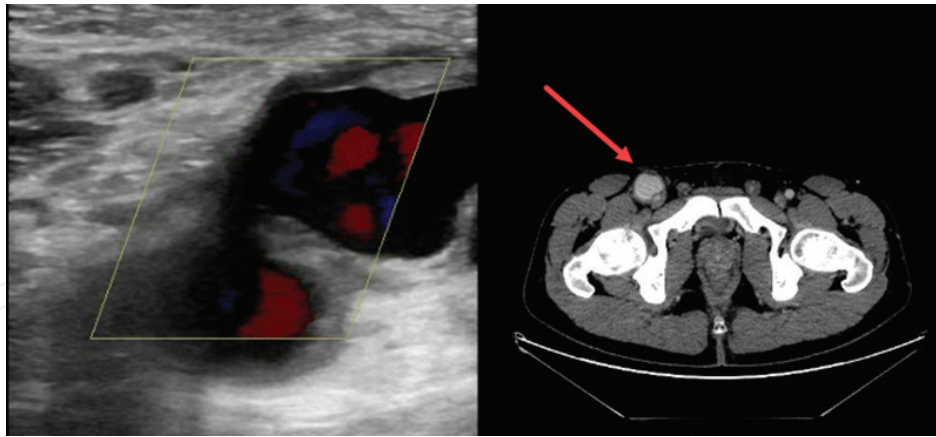


Figure 4. DUS and CT scan of a right common femoral artery pseudoaneurysm at a previous arterial access site in a BD patient.

2.6. Descending thoracic and thoracoabdominal aortic aneurysm

Descending thoracic aortic aneurysm (DTAA), defined as an aortic dilatation with at least a 50% increase in diameter located in any segment of the aorta between the left subclavian artery (LSA) origin and the diaphragm, is an uncommon finding in BD, though its rupture represents a catastrophic event and a major cause of death.

Crawford's classification, modified by Safi, of thoracic and thoracoabdominal aortic aneurysms (TAAAs) is based on the extension of the disease: type I extends from the origin of the left subclavian to the suprarenal abdominal aorta; type II TAA elongates from the left subclavian artery to the aortoiliac bifurcation; type III extends from the distal thoracic aorta to the aortoiliac bifurcation; type IV aneurysms are limited to the subdiaphragmatic aorta; type V, introduced by Safi, extends from the distal thoracic aorta to the abdominal aorta involving the celiac trunk and superior mesenteric artery origins, but not the renal arteries [33].

Chest and back pain are a common presentation of the disease, and physical examination can evidenciate signs of aortic regurgitation, cardiac tamponade, dyspnea, and dysphagia [33, 34].

Although several imaging techniques are available, such as MRI, positron emission tomography (PET), digital subtraction angiography, and intravascular ultrasonography, CTA scan is currently the gold standard for aortic imaging; it allows a conclusive study of thoracic aorta, showing an increased size of thoracic or thoracoabdominal aorta, and it can distinguish different aortic diseases like acute aortic syndromes (AASs) with a sensitivity up to 100% [18, 35].

AASs are defined as lesions involving disruption of the media of the aorta, with blood flow between the layers of the vessel or transmurally in the case of rupture [35].

According to Svensson, AASs are distinguished into five classes: class I is the classic aortic dissection, with a flap between true and false lumen; class II is the intramural hematoma;

class III is a limited intimal tear with an eccentric bulge at the tear site; class IV is a penetrating atherosclerotic ulcer with surrounding hematoma, usually subadventitial; and class V is represented by an iatrogenic or traumatic dissection [36].

The most dangerous complications of the invasive treatment of DTAAAs are spinal cord ischemia (SCI), resulting in paraparesis or paraplegia (2–6% of the cases), and stroke (up to 8%). SCI is due to reperfusion injury to the spinal cord caused by the sudden interruption of blood flow and its subsequent restoration. Methods like somatosensory-evoked potentials (SSEPs) and motor-evoked potentials (MEPs) are employed to monitor the spinal cord function; cerebrospinal fluid drainage, left heart bypass, and cardiopulmonary extracorporeal circulation with induced systemic hypothermia reduce the risk of SCI [35].

2.7. Open repair

Open surgical repair should be reserved to patients unsuitable for thoracic endovascular aortic repair (TEVAR) in patients affected from DTAA, while remaining the recommended treatment of choice for patients affected from TAAA [35].

The location and extension of the aneurysm determine the site of incision; common approaches are left thoracotomy at V, VI, VII, or VIII intercostal space (ICS), allowing the exposure of the descending thoracic aorta from the origin of the LSA to the suprarenal abdominal aorta; left thoracophrenotomy at VII, IX, or X ICS, with the section of diaphragm, grants access to the distal thoracic aorta and suprarenal abdominal aorta; midline, paramedian, or bilateral subcostal laparotomy are indicated to obtain a transperitoneal access to the suprarenal aorta, the celiac trunk, and the superior mesenteric artery, while left transverse lateral laparotomy allows extraperitoneal access to the same segment; thoracophrenolaparotomy permits complete exposure of the whole aorta, from the origin of the LSA to the iliac bifurcation [37].

After exposure and clamping of the aorta, the aneurysmatic sac is incised and, after reimplantation of intercostal arteries distal to T8–T9 and visceral vessels if involved, a Dacron graft is implanted using the same suturing technique described in the section about open repair of abdominal aortic aneurysms.

2.8. Thoracic endovascular aortic repair and hybrid surgery

Case 4 (Figure 5): A 26-year-old female BD patient presents with chest pain. After cardiac involvement is ruled out, a contrast CT scan reveals the presence of a pseudoaneurysm of the descending thoracic aorta. MRI and PET scans are also performed as evidence of aortitis is present (elevated ESR and CRP). The patient is successfully treated with a tubular endograft.

TEVAR has become the first-choice treatment for suitable patients affected by DTAAAs; when compared to open repair, TEVAR has lower mortality and morbidity rates and shorter length of hospital stay. In TAAAs, endovascular repair is reserved to those unfit for surgery.

Patients with a distal-landing zone of less than 15-mm length and a proximal neck diameter of >40 mm are unsuitable for treatment with currently available devices [35].

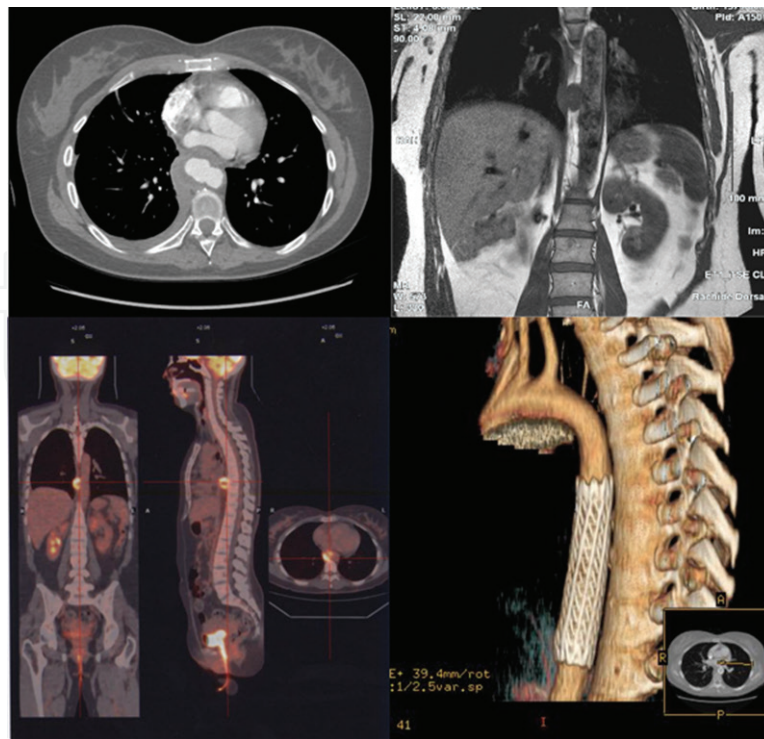


Figure 5. CT, MR, and PET scans in a 26-year-old female patient presenting with a descending thoracic aorta pseudoaneurysm. Lower-right image: exclusion of the pseudoaneurysm with a tubular thoracic endograft (3D reconstruction).

After gaining mono- or bilateral surgical or percutaneous access to the common femoral artery, the latter is punctured using Seldinger's technique after systemic heparinization.

Under fluoroscopic guidance, an introducer is placed and a Pig-Tail is progressed over a hydrophilic guidewire; a preliminary angiography and road mapping are performed; then the endoprosthesis' device is inserted over a super stiff guidewire, progressed to the aortic valve and retracted under fluoroscopic guidance. Angiography is performed to verify the correct positioning of the stent graft. Arterial blood pressure is lowered to 70–80 mmHg and momentary asystole is provoked in order to prevent the wind-shock effect, then the tube-shaped endoprosthesis is opened.

If one or more sovraortic trunks or visceral arteries are covered by the implantation of the stent graft, preliminary surgical debranching of these vessels is required. Debranching can be performed with a previous operation or during the same procedure, prior to the endovascular stage [12, 35].

Scallop designed, fenestrated, and branched custom-made endografts, with openings in the fabric or branches in correspondence to the origin of visceral arteries, are currently available [38].

Periscope and chimney/snorkel techniques, requiring antegrade catheterization from a trans-brachial access, consist in the placement of a stent graft into one or more branch vessels in

a parallel path alongside the aortic endograft; these techniques are promising, though supported by little clinical evidence [35].

2.9. Pulmonary artery aneurysms

Pulmonary artery aneurysms (PAAs), true or false, are the most lethal complication of BD; it has been reported that about 50% of these patients die within a year after the onset of hemoptysis although more recent data show survival rates of up to 80% at 5 years, mainly due to earlier diagnosis and treatment [39, 40]. Emergency surgery for aneurysm rupture carries high risk and uncertain results [8].

Hemoptysis, due to arterial-bronchial fistulization, is the most common presentation of these aneurysms, appearing as polinodular opacities and hilar or mediastinal enlargements on chest X-ray scan [41].

CTA scan, as stated before, is an important imaging method in BD, allowing detailed analysis of the aorta and other arterial and venous vessels; compared to MRI, it also shows lung parenchyma in greater detail [41]. PAA has strong association with DVT, caval, or intracardiac thrombus formation [11, 40].

Medical treatment with immunosuppressive therapy is the main treatment for PAAs [19]. Invasive treatment of PAA should be performed only in case of massive, life-threatening bleeding. Surgical techniques consisting in lobectomy or pneumonectomy of the involved structure have been reported, but aneurysmectomy with direct suturing of the wall defect has shown to have better long-term patency rates; additionally, endoaneurysmorrhaphy seems to be coherent with the morphology of the false and saccular aneurysms of BD [41, 42]. As in the other arterial districts, even PAA surgery is burdened with recurrency at the site of suture or anastomosis.

Endovascular embolization techniques have been described and endovascular treatment seems to be a safe option: Amplatzer duct occluder and coils have been successfully used to thrombose PAAs, though some limitations as aneurysmal sac size and complications like caval embolization have been reported.

Transhepatic embolization of PAA with N-butyl cyanoacrylate glue and coils has recently been successfully attempted [43].

2.10. Peripheral aneurysms

Case 5 (Figure 6): A 22-year-old female BD patient in corticosteroid and azathioprine treatment is referred to the vascular surgery department with an accidental finding on a CT scan of a 23-mm aneurysm at the origin of the right subclavian artery. Due to the location and characteristics of the lesion and the young age of the patient, a strict follow-up protocol with DUS every 6 months and annual CT scans is recommended. The aneurysm has maintained a stable diameter after 6 years of follow-up visits.

Peripheral aneurysmal degeneration is a common finding among patients with vasculo-Behçet.

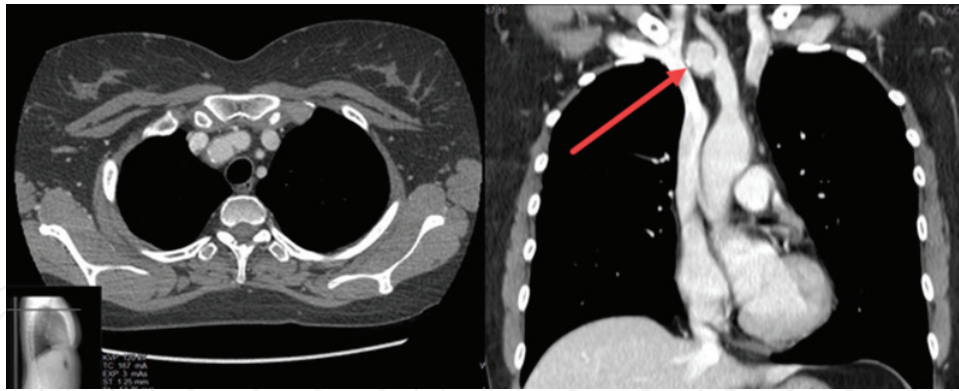


Figure 6. CT scan of a 22-year-old BD patient presenting with a right subclavian artery aneurysm.

Physical examination could reveal the presence of a pulsatile, hyperemic, and tender swelling in correspondence of a peripheral vessel, and all arterial segments should be explored and/or studied with CTA scan since multiple aneurysms in the same patient have been reported [10, 15].

Immunosuppressive therapy should be administered immediately, because early diagnosis and early administration of therapy will help in preventing the formation and progression of the arterial lesions [10, 20].

Case 6 (Figure 7): A 43-year-old male BD patient presents with pain in the right groin area. Physical examination reveals a large pulsatile mass. DUS confirms the presence of a 50-mm common femoral artery aneurysm. The patient undergoes aneurysmectomy with Dacron graft interposition.

Like the other arterial segments, peripheral arterial repair may be complicated by recurrency, anastomotic pseudoaneurysms, graft occlusion, and distal embolization [12, 44].

Surgical peripheral bypasses of affected arteries have been reported; the use of autologous saphenous vein is to be avoided, because the vein could be affected by vasculitis or previous superficial vein thrombosis, and synthetic grafts are to be preferred in these patients [44]. The choice of a disease-free segment for reconstruction is crucial.

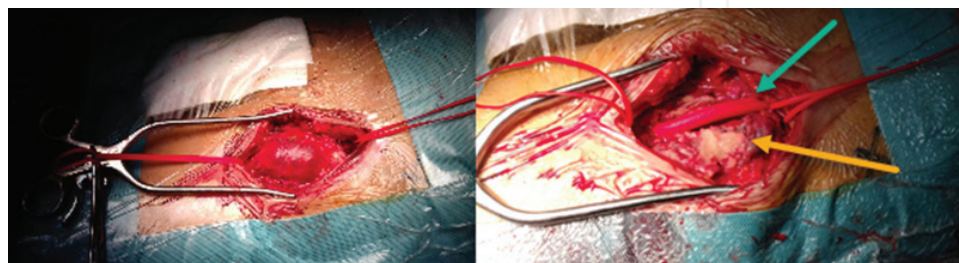


Figure 7. Open repair of a left common femoral artery aneurysm.

Case 7 (Figure 8): A 30-year-old male patient affected with BD was admitted at our division with a pulsatile, painful swelling in the right popliteal fossa. DUS showed partially thrombosed popliteal artery aneurysm. The patient underwent a femoral-popliteal bypass graft using a cryopreserved femoral superficial artery as an allograft. The procedure was uneventful, and short-term (6-month) follow-up showed graft patency, no detachment nor aneurysmatic degeneration at the anastomotic site.

The use of allografts has been reported in the case of aortic substitution to be an appropriate therapy in patients affected from noninfectious inflammatory diseases including BD with uneventful mid-term follow-up [45, 46]. Allografts, if available, could be a valid alternative for peripheral procedures in BD patients where due to the ongoing vasculitis it might be undesirable to employ venous segments.

In cases where surgical peripheral revascularization is not feasible for the absence of a disease-free arterial segment, ligation after stump pressure measurement has been reported to be an alternative treatment; successful ligation of carotid, subclavian, iliac, superficial femoral, popliteal, and posterior tibial artery have been reported [12, 47]. The presence of collateral circulation allows arterial ligation without disabling ischemia in a large number of patients; furthermore, peripheral graft occlusion often results in a mild claudication, requiring no additional revascularization procedure [8].

Endovascular treatment of peripheral aneurysms includes stent graft implantation, with patency rate of 89% at 2 years, and coil/plug embolization [4, 15, 48].

2.11. Carotid and vertebral artery aneurysm

Case 8 (Figure 9): A 40-year-old male BD patient in immunosuppressive therapy presents with a pulsatile mass in the neck and a recent transient ischemic episode characterized by a dyspraxia involving the right upper limb. DUS is performed showing high tortuosity of the left carotid artery with a 40-mm partially thrombosed aneurysm just distal to the bifurcation. The finding is confirmed by a contrast CT scan. The patient is referred to surgery. Extensive neck dissection was required for the repair. After the aneurysmectomy, direct anastomosis between the internal carotid and the common carotid and reconstruction of a neobifurcation was possible. Patient was discharged on the third postoperative day with no neurological deficits.

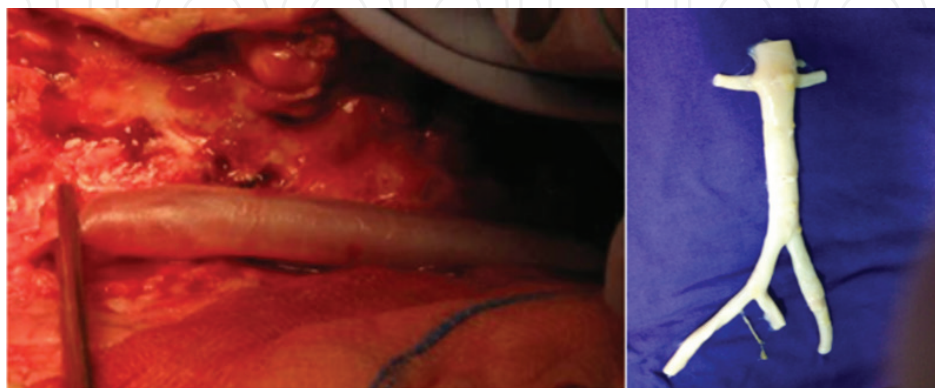


Figure 8. Femoropopliteal bypass grafting utilizing an allograft (left). Right image: aortobisiliac homograft prior to an implantation.

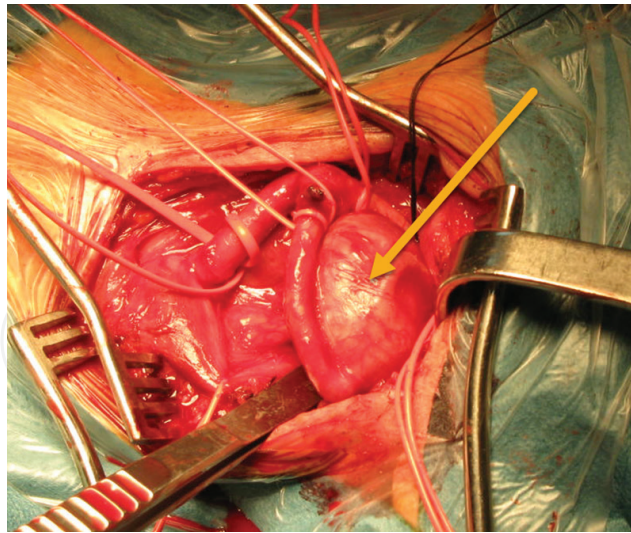


Figure 9. Open repair of a symptomatic left internal carotid aneurysm in a BD patient.

Few cases of extracranial carotid artery and vertebral artery aneurysms in BD have been reported [49–51]. Common carotid artery appears to be the most frequent location. Symptoms can derive from compression of nearby structures or from cerebral embolization from the aneurysmatic sac, resulting in neck pain, voice alterations, dyspnea, transient ischemic attacks, and ictus cerebri [47]. Rupture of these aneurysms is rare but has been reported [8].

Surgical treatment includes aneurysmectomy and synthetic graft bypass and, in case of emergency and impossibility to perform reconstruction, carotid or vertebral artery ligation [49, 51].

Endovascular treatment of carotid artery aneurysms is an option in cases where the aneurysm is surgically inaccessible, and it includes stent graft implantation and coil embolization. However, long-term results of endovascular treatment of carotid and vertebral arteries involvement in BD are still lacking.

3. Conclusion

Angio-Behçet's patients are challenging from a surgical standpoint. Both venous and arterial circulations are involved, even in the same patient, with a high rate of recurrence and postoperative complications. Though venous involvement is more frequent than arterial lesions, the latter account for the majority of deaths.

The need for a comprehensive vascular physical and radiological examination in BD patients presenting features of vascular involvement cannot be stressed enough.

Perioperative immunosuppressive and corticosteroid medications are the key to the success of any vascular surgical procedure in these patients.

New endovascular techniques are showing promising results for the treatment of arterial lesions with lower mortality rates and faster recovery time when compared to open repair. Technical success rate is close to 100%. Even though graft occlusions are not infrequent, they could be managed through endovascular-assisted patency procedures.

Open repair entails a high risk of pseudoaneurysm formation at the anastomotic site, and should therefore be reserved to cases unsuitable for endovascular procedures or where the latter have failed. Allografts could be a valid alternative to the use of autologous saphenous vein or prosthetic grafts for arterial substitution, though further studies are needed.

The management of venous lesions is mainly medical, and endovascular stents for the treatment of venous vessels are not yet available in a clinical setting.

The evolution of minimally invasive techniques is tracing new paths in the surgical management of Angio-Behçet's patients, broadening the array of tools available to the vascular surgeon and enabling him/her to tailor the treatment based on each patient's peculiar characteristics.

Author details

Genadi Georgiev Genadiev*, Lorenzo Mortola, Roberta Arzedi, Giuseppe Deiana, Francesco Spanu and Stefano Camparini

*Address all correspondence to: ggenadiev@gmail.com

AO "G. Brotzu", Cagliari, Italy

References

- [1] El-Ramahi KM, Al-Dalaan A, Al-Balaa S, et al. Vascular involvement in Behçet's disease. In: Wechsler B, Godeau P, editors. Behçet's Disease. Amsterdam: Excerpta Medica; 1993. p. 531
- [2] Melikoglu M, Kural-Seyahi E, Tascilar K, et al. The unique features of vasculitis in Behçet's syndrome. *Clinical Reviews in Allergy & Immunology*. 2008;**35**:40–46. DOI: 10.1007/s12016-007-8064-8
- [3] Calamia KT, Schirmer M, Melikoglu M. Major vessel involvement in Behçet's disease: An update. *Current Opinion in Rheumatology*. 2011;**23**(1):24–31. DOI: 10.1097/BOR.0b013e3283410088
- [4] Alpagut U, Ugurlucan M, Dayioglu E. Major arterial involvement and review of Behçet's disease. *Annals of Vascular Surgery*. 2007;**21**:232–239. DOI: 10.1016/j.avsg.2006.12.004
- [5] Duzgun N, Ates A. Characteristics of vascular involvement in Behçet's disease. *Scandinavian Journal of Rheumatology*, 2006;**35**(1):65–68 DOI: 10.1080/03009740500255761

- [6] Saadoun D, Wechsler B, Desseaux K, Le Thi Huong D, Amoura Z, Resche-Rigon M, Cacoub P. Mortality in Behçet's disease. *Arthritis & Rheumatism*. 2010;**62**:2806–2812. DOI: 10.1002/art.27568
- [7] Balcioglu O, Ertugay S, Bozkaya H, Parildar M, Posacioglu H. Endovascular repair and adjunctive immunosuppressive therapy of aortic involvement in Behçet's disease. *European Journal of Vascular and Endovascular Surgery*. 2015;**50**:593–598. DOI: 10.1016/j.ejvs.2015.07.011
- [8] Tüzün H, et al. Management of aneurysms in Behçet's syndrome: An analysis of 24 patients. *Surgery*. 1997;**121**:150–156. DOI: 10.1016/j.jvs.2011.07.049
- [9] Sherif A, Stewart P, Mendes DM. The repetitive vascular catastrophes of Behçet's disease: A case report with review of the literature. *Annals in Vascular Surgery*. 1992;**6**:85–89. DOI: 10.1007/BF02000674
- [10] Jayachandran NV, Rajasekhar L, Chandrasekhara PKS, Kanchinadham S, Narsimulu G. Multiple peripheral arterial and aortic aneurysms in Behçet's syndrome—A case report. *Clinical Rheumatology*. 2008;**27**:265–267. DOI: 10.1007/s10067-007-0713-z
- [11] Hamuryudan V, et al. Pulmonary arterial aneurysms in Behçet's syndrome: A report of 24 cases. *British Journal of Rheumatology*. 1994;**33**:48–51. DOI: 10.1093/rheumatology/33.1.48
- [12] Hosaka A, et al. Long-term outcome after surgical treatment of arterial lesions in Behçet disease. *Journal of Vascular Surgery*. 2005;**42**:116–121. DOI: 10.1016/j.jvs.2005.03.019
- [13] Kwon TW, et al. Surgical treatment result of abdominal aortic aneurysm in Behçet's disease. *European Journal of Vascular and Endovascular Surgery*. 2008 Feb;**35**(2):173–180. DOI: 10.1016/j.ejvs.2007.08.013[P3]
- [14] Liu CW, et al. Endovascular treatment of aortic pseudoaneurysm in Behçet disease. *Journal of Vascular Surgery*. 2009;**50**(5):1025–1030
- [15] Kim WH, et al. Effectiveness and safety of endovascular aneurysm treatment in patients with vasculo-Behçet disease. *Journal of Endovascular Therapy*. 2009;**16**:631–636. DOI: 10.1583/09-2812.1
- [16] Nitecki SS, et al. Abdominal aortic aneurysm in Behçet's disease: New treatment options for an old and challenging problem. *The Israel Medicine Association Journal*. 2004;**6**(3): 152-155. PMID: 15055270
- [17] Düzgün N, Ates A, Aydintug OT, Demir Ö, Ölmez Ü. Characteristics of vascular involvement in Behçet's disease. *Scandinavian Journal of Rheumatology*. 2006;**35**(1):65–68. DOI: 10.1080/03009740500255761
- [18] Ko GY, Byun JY, Choi BG, et al. The vascular manifestations of Behçet's disease: Angiographic and CT findings. *British Journal of Radiology*. 2000;**73**:1270–1274. DOI: 10.1259/bjr.73.876.11205670
- [19] Hatemi G, Silman A, Bang D, Bodaghi B, Chamberlain AM, Gul A, Houman MH, Kötter I, Olivieri I, Salvarani C, Sfikakis PP, Siva A, Stanford MR, Stübiger N, Yurdakul S, Yazici H.

- EULAR recommendations for the management of Behçet disease. *Annals of the Rheumatic Diseases*. 2008;**67**:12, 1656–1662. DOI: 10.1136/ard.2007.080432
- [20] Hendaoui L, et al. Imaging features of Behçet's disease. *Systemic Vasculitis. Medical Radiology*. 2012;**1**:137–173
- [21] Bayraktar Y, Balkanci F, Bayraktar M et al. Budd-Chiari syndrome: A common complication of Behçet's disease. *American Journal of Gastroenterology*. 1997;**92**:858–862. PMID: 9149201
- [22] Chae EJ, Do KH, Seo JB, et al. Radiologic and clinical findings of Behçet disease: Comprehensive review of multisystemic involvement. *Radio Graphics*. 2008 Sep-Oct;**28** (5):e31. DOI: 10.1148/rg.e31
- [23] Emmi L, editor. *Behçet Syndrome: From Pathogenesis to Treatment*. Italia: Springer-Verlag; 2014. pp. 217–225. DOI: 10.1007/978-88-470-5477-6_20
- [24] Wanhainen A, et al. Thoracic and abdominal aortic dimension in 70-year-old men and women – A population-based whole-body magnetic resonance imaging (MRI) study. *Journal of Vascular Surgery*. 2008;Mar;**47**(3):504–12. DOI: 10.1016/j.jvs.2007.10.043
- [25] Vasseur M. Endovascular treatment of abdominal aneurysmal aortitis in Behçet's disease. *Journal of Vascular Surgery*. 1998; May;**27**(5):974–6. DOI: 10.1016/S0741-5214(98)70281-2
- [26] Moll FL, et al. Management of abdominal aortic aneurysms clinical practice guidelines of the European society for vascular surgery. *European Journal of Vascular and Endovascular Surgery*. 2011;**41** Suppl 1:S1-S58. DOI: 10.1016/j.ejvs.2010.09.011
- [27] Park MC, Hong BK, Kwon HM, Hong YS. Surgical outcomes and risk factors for post-operative complications in patients with Behçet's disease. *Clinical Rheumatology*. 2007;**26**:1475–1480. DOI: 10.1007/s10067-006-0530-9
- [28] Robenshtok E. Arterial involvement in Behçet's disease—The search for new strategies. *The Israel Medicine Association Journal*. 2004 Mar;**6**(3):162–3. PMID: 15055273
- [29] AbuRahma AF, et al. Aortic neck anatomic features and predictors of outcomes in endovascular repair of abdominal aortic aneurysms following vs not following instructions for use. *Journal of the American College of Surgeons*. 2016;**222**:579–589. DOI: 10.1016/j.jamcollsurg.2015.12.037
- [30] Simons JP. Exploring EVAR instructions for use in 2016. *Endovascular Today*. 2016; **15**:48–52.
- [31] Clough RE. Low-profile EVAR. *Endovascular Today*. 2016;**15**:72–75.
- [32] Greenhalgh RM, Powell JT. Endovascular repair of abdominal aortic aneurysm the clinical problem. *New England Journal of Medicine*. 2008;**358**:494–501. DOI: 10.1056/NEJMc1513724
- [33] Safi HJ, Miller CC. Spinal cord protection in descending thoracic and dominal aortic repair. *Annals in Thoracic Surgery*. 1999;**67**:1937–9. DOI: 10.1016/ S1043-0679(98)70016-4

- [34] Ohira S, Masuda S, Matsushita T. Nine-year experience of recurrent anastomotic pseudoaneurysms after thoracoabdominal aneurysm graft replacement in a patient with Behçet disease. *Heart, Lung and Circulation*. 2014;**23**:210–213. DOI: 10.1016/j.hlc.2014.05.009
- [35] Riambau V, et al. Editor's choice—Management of descending thoracic aorta diseases. *European Journal of Vascular and Endovascular Surgery*. 2017;**53**:4–52. DOI: 10.1016/j.ejvs.2016.06.005
- [36] Svensson LG. Intimal tear without hematoma. *Circulation*. 1999;**99**:1331. DOI: 10.1161/01.CIR.99.10.1331
- [37] Rutherford RB. Atlas of vascular surgery: Basic techniques and exposures. Saunders. 1993;**1**:120–133. DOI: 10.1002/bjs.1800801151
- [38] Frederick JR, Woo YJ. Thoracoabdominal aortic aneurysm. *Annals in Cardiothoracic Surgery*. 2012;**1**:277–285. DOI: 10.3978/j.issn.2225-319X.2012.09.01
- [39] Kural-Seyahi E, et al. The long-term mortality and morbidity of Behçet syndrome. *Medicine (Baltimore)*. 2013;**82**:60–76. DOI: 10.1097/00005792-200301000-00006
- [40] Hamuryudan V, et al. Pulmonary artery aneurysms in Behçet syndrome. *American Journal of Medicine*. 2004;**117**:867–870. DOI: 10.1093/rheumatology/33.1.48
- [41] Ceylan N, Bayraktaroglu S, Erturk SM, Savas R, Alper H. Pulmonary and vascular manifestations of Behçet disease: Imaging findings. *American Journal of Roentgenology*. 2010;**194**:158–164. DOI: 10.2214/AJR.09.2763
- [42] Aroussi AA, Redai M, Ouardi FEI, Mehadji B-E, Casablanca M. Bilateral pulmonary artery aneurysm in Behçet syndrome: Report of two operative cases. 2005:1170–1171. DOI: 10.1016/j.jtcvs.2004.08.038
- [43] Seizem NG, et al. Transhepatic embolization of bilateral pulmonary artery aneurysm with N-butyl cyanoacrylate and coils in Behçet disease. *Journal of Vascular and Interventional Radiology*. 2016;**27**:293–295. DOI: 10.1016/j.jvir.2015.10.012
- [44] Iscan ZH, Vural KM, Bayazit M. Compelling nature of arterial manifestations in Behçet Disease. *Journal of Vascular Surgery*. 2005; **41**(1):53–8. DOI: 10.1016/j.jvs.2004.09.018
- [45] Umehara N, Saito S, Ishii H, Aomi S, Kurosawa H. Rupture of thoracoabdominal aortic aneurysm associated with Behçet's disease. *Annals in Thoracic Surgery*. 2007;**84**:1394–1396. DOI: 10.1016/j.athoracsur.2007.04.110
- [46] Sakuma K, Akimoto H, Yokoyama H, Iguchi A, Tabayashi, K. Cryopreserved aortic homograft replacement in 3 patients with noninfectious inflammatory vascular disease. *Japanese Journal of Thoracic and Cardiovascular Surgery*. 2001;**49**:652–655. DOI: 10.1007/BF02912473
- [47] Goz M, Cakir O. Huge popliteal arterial aneurysms in Behçet's syndrome: Is ligation an alternative treatment? *Vascular*. 2007;**15**:46–48. DOI: 10.2310/6670.2007.00010
- [48] Silistreli E, et al. Behçet's disease: Treatment of popliteal pseudoaneurysm by an endovascular stent graft implantation. *Annals in Vascular Surgery*. 2004;**18**:118–120. DOI: 10.1007/s10016-003-0107-x

- [49] Bouarhroum A, et al. Extracranial carotid aneurysm in Behçet disease: Report of two new cases. *Journal of Vascular Surgery*. 2006;**43**:627–630. DOI: 10.1016/j.jvs.2005.09.049
- [50] Posacioglu H, Apaydin AZ, Parildar M, Buket S. Large pseudoaneurysm of the carotid artery in Behçet's disease. *Texas Heart Institute Journal*. 2005;**32**:95–98. PMCID: PMC555835
- [51] Gürer O, Yapici F, Enç Y, Çınar B, Özler A. Spontaneous pseudoaneurysm of the vertebral artery in Behçet's disease. *Annals in Vascular Surgery*. 2005;**19**:280–283. DOI: 10.1007/s10016-004-0147-x