

We are IntechOpen, the world's leading publisher of Open Access books Built by scientists, for scientists

6,900

Open access books available

185,000

International authors and editors

200M

Downloads

Our authors are among the

154

Countries delivered to

TOP 1%

most cited scientists

12.2%

Contributors from top 500 universities



WEB OF SCIENCE™

Selection of our books indexed in the Book Citation Index
in Web of Science™ Core Collection (BKCI)

Interested in publishing with us?
Contact book.department@intechopen.com

Numbers displayed above are based on latest data collected.
For more information visit www.intechopen.com



Cone Beam Computed Tomography in Orthodontics

Emine Kaygısız and Tuba Tortop

Additional information is available at the end of the chapter

<http://dx.doi.org/10.5772/intechopen.68555>

Abstract

Cone beam computed tomography (CBCT) is an important source of three-dimensional volumetric data in clinical orthodontics. Due to the progress in the technology of CBCT, for orthodontic clinical diagnosis, treatment and follow-up, CBCT supply much more reliable information compared to conventional radiography. The most justified indications for the use of CBCT in orthodontics are the existence of impacted and transposed teeth. For the management of the impacted teeth, CBCT enhances the ability to localize these teeth accurately and to assess root resorption of adjacent teeth. Patients with cranio-facial anomalies like cleft palate cases, the abnormalities of the temporomandibular joint contributing malocclusion, evaluation of airway morphology in obstructive sleep apnea cases, patients needing maxillary expansion or planning orthognathic surgery in severe skeletal discrepancies are also listed among the indications of using CBCT in orthodontics. CBCT is useful in identifying optimal site location for temporary skeletal anchorage device. The use of CBCT for the assessment of treatment outcomes and evaluation of cervical vertebral maturation are still controversial issues. It should be kept in mind that before using CBCT, justification and evaluation of risks and benefits are needed. In order to minimize the radiation dose, the exam should include only the areas of interest.

Keywords: cone beam computed tomography, orthodontics, impacted canine, orthodontic treatment planning, root resorption

1. Introduction

The key of a successful orthodontic treatment is an accurate diagnosis, growth evaluation and treatment planning. Diagnostic records for an orthodontic treatment planning generally begin with history and intraoral and extraoral examination of the patient. Dental casts, intra-oral and extraoral photographs are also routine diagnostic materials. Imaging is a necessary diagnostic tool in the practice of orthodontics. For radiographic evaluation, panoramic

radiograph, periapical views, upper occlusal radiograph and lateral cephalometric radiograph are obtained if indicated. Imaging should answer the questions that cannot be solved clinically. By using radiographic examination, it is possible to confirm or rule out clinical findings [1].

In recent years, orthodontists have begun to use three-dimensional (3D) cone beam computed tomography (CBCT) images to overcome the inadequateness of two-dimensional (2D) radiographic records. When computed tomography was first introduced into the dental field, because of the high radiation dose, it is not preferred for orthodontic diagnosis. The technology has been evolving ever since, resulting in a reduction in radiation dose and relatively low cost of CBCT systems, so they become popular to visualize the craniofacial complex in three dimensions.

In some studies, it has been suggested that different options for orthodontic treatment plans in some specific cases may change due to use of CBCT [2–4]. Orthodontists should know how to use the radiographic records and what they offer, before deciding which tool they will use [1].

2. Advantages and disadvantages of using CBCT in orthodontics

Although there has been considerable interest in using CBCT as a part of routine orthodontic management, diverse results about the advantages, disadvantages and indications were noted in the literature.

The review of recent literature reveals some advantages [1, 5–15] and disadvantages [16–20] as following:

2.1. Advantages

- Accuracy of image geometry is increased, and real size 3D image is obtained by CBCT. Unlike lateral cephalometric radiographs, CBCT image is more similar to the patient, more accurate and distortion-free.
- It eliminates the magnification, overlapping and distortion of structures.
- It is possible to assess the image from the three planes.
- CBCT images allow to make localized and specific transversal cuts to assess areas of clinical interest.
- For a proper diagnosis and treatment planning, sometimes temporomandibular, postero-anterior cephalograms, periapical, occlusal and bite-wing radiographs are also required besides the routine panoramic and lateral cephalometric examination. But, by using CBCT technology, it is possible to produce several types of radiographic images and to construct study casts from a single scan.
- The reorientation of the images, on the contrary to the lateral cephalometric radiograph, is possible.

- The ease of landmark identification and high precision of superimposed images have been reported.
- By the use of CBCT, less variability and more reproducibility of transverse measurements were demonstrated compared to conventional 2D. CBCT images were reported to be more reliable than posteroanterior cephalograms and offer an unobstructed view for diagnosis of maxillary transverse discrepancies.
- The unerupted tooth sizes, bone dimensions and even soft tissue anthropometric measurements can be assessed precisely by CBCT.
- The fine adjustment of the head position is not essential for CBCT.
- The use of CBCT in orthodontics greatly enhances evaluation of impacted canines and offers comprehensive information.
- The detection of root resorption is reported to be highly accurate with CBCT scanners.
- An occlusal view of the maxilla from CBCT can be used for the customized transpalatal arch design. This might prevent interfering of the wire to the path of eruption of impacted tooth.

2.2. Disadvantages

- The amount of generated radiation is the biggest controversy about the use of CBCT in dental imaging. Although the radiation dose of the CBCT is lower than the medical spiral CT, it is still higher than that of a 2D cephalogram.
- Difficulty in differentiating various soft tissues in the image due to the poor low-contrast resolution compared to medical CT is one of the disadvantages.
- An adequate method to digitize and analyze 3D radiographic images is not still improved.
- The lack of 3D standard population norms has also restricted CBCT from routine orthodontic use.
- Landmark identification on coronal, sagittal and axial views of CBCT is more time consuming to carefully select the best slice.
- The diagnostic accuracy for caries detection with CBCT is less than with conventional periapical radiographs.

3. The usage of CBCT in orthodontics

Many orthodontists interested in using CBCT during their routine diagnosis and treatment planning because of the additional diagnostic information. This brings the risk of unnecessary ionizing radiation. So, it is mandatory to determine exact indications for the use of CBCT in orthodontics.

3.1. Impacted and transposed teeth

Tooth impaction is a commonly observed dental anomaly which needs orthodontic treatment. The most frequent impacted teeth were mandibular wisdom teeth, which were followed by maxillary and mandibular canines [21]. Radiographic examinations play a more critical role than clinical examination especially in the initial diagnosis and treatment planning of impacted teeth. For several years, radiographic evaluation of these teeth was done by using panoramic, periapical, occlusal or lateral cephalograms. These conventional two dimensional radiographs are inadequate in accurately visualizing the location, angulation, spatial position and relationships of the impacted tooth in three dimensions. So, the most justified indications for the use of CBCT in orthodontics are the existence of impacted and transposed teeth (**Figure 1a–c**).

For the management of the impacted teeth, CBCT enhances the ability to localize these teeth accurately, evaluate their proximity to other teeth and structures, determine the alveolar width and follicle size, the presence of pathology and assess root resorption of adjacent teeth, assist in planning surgical access and bond placement, besides determining optimal direction for the extrusion of these teeth into the oral cavity [22–25]. In particular, for impacted teeth, if exposure or forced eruption is planned, it would be possible to determine not only the position of tooth and dilacerated root but also the alveolar boundary conditions. Additionally, it would be much easier to prepare the space needed for the impacted tooth as it is possible to obtain a more accurate size from CBCT images.

Haney et al. [26] reported an approximate 20% lack of agreement among clinicians on the location (palatal versus labial) of the tooth tip between the routine 2D radiographs and 3D CBCT images. Also large differences in treatment approaches were demonstrated when the two imaging methods were compared [27]. On the other hand, in another study, it was reported that the determination of canine position was not significantly different when using panoramic and CBCT systems [3].

Using CBCT improves the clinician confidence in diagnosis and treatment plan as it is helpful in defining the surgical access site, bond position and in designing mechanics [25, 26]. The orthodontists have a different perception of localization and can determine the shortest way for the impacted tooth in three planes of space while avoiding damage to neighboring teeth.

In some studies, it was suggested that orthodontic treatment planning for impacted tooth showed no differences when using 2D- or 3D-based information. On the contrary, findings of some other studies showed that orthodontists changed their treatment planning derived from conventional radiographs for 25% of the impacted teeth when they viewed CBCT images [26, 28]. Alqerban et al. [4, 29] concluded that CBCT allows clinicians to obtain 3D images with visualization of cranio-facial structures and significantly increases the orthodontists' confidence level, with more information on canine localization and detection of possible root resorption on adjacent incisors [30].

When the impacted tooth did not move, CBCT is indicated. Becker et al. [31] reported that invasive cervical root resorption is a rare insidious and aggressive form of external

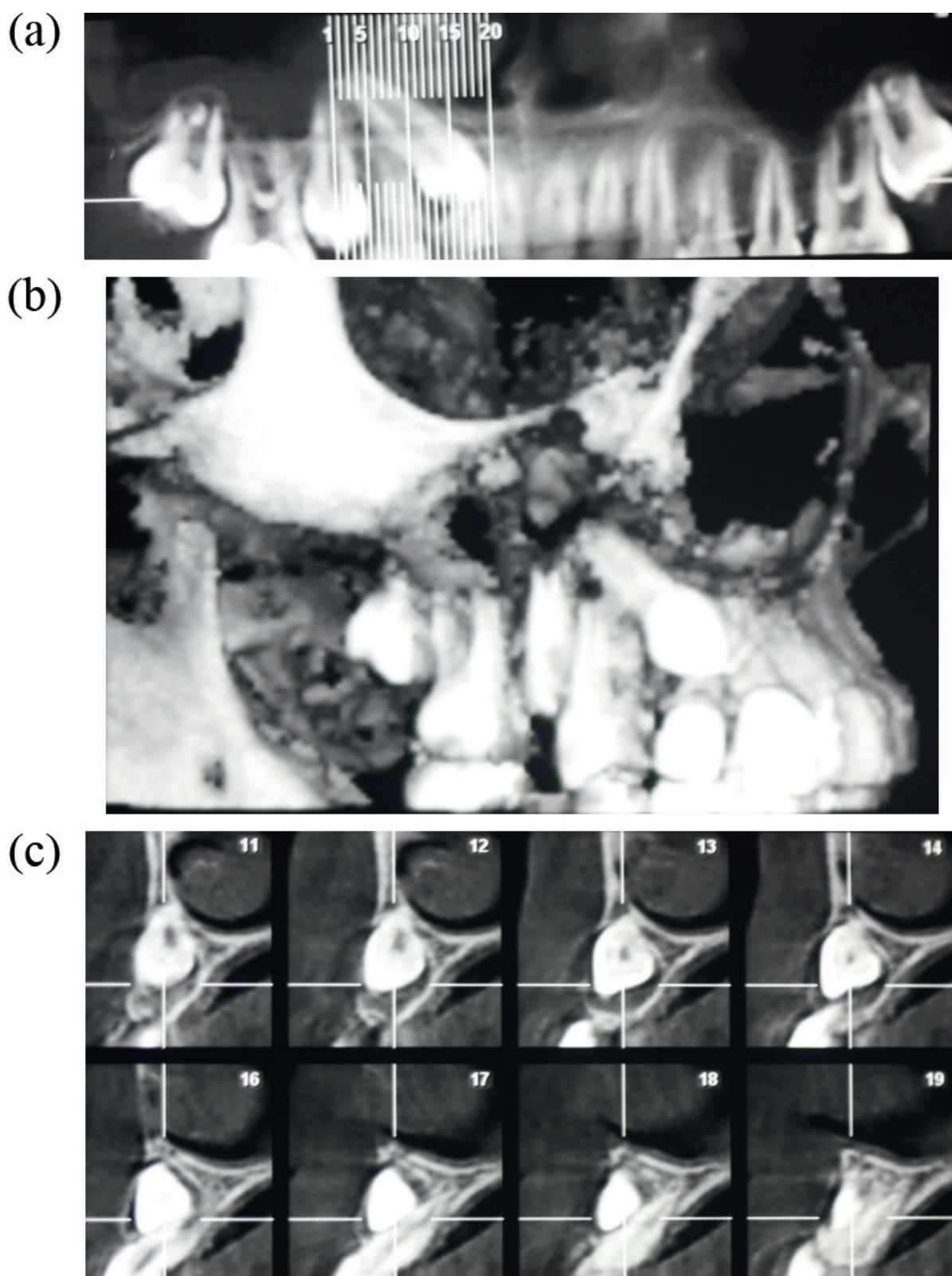


Figure 1. (a) Panoramic view of a maxillary impacted canine. Note that in this case, FOV was restricted only to maxilla. (b) Determination of vestibular location of a maxillary impacted canine. (c) Evaluation of proximity between impacted canine and root of lateral incisor by CBCT.

root resorption and an overlooked cause of failure of orthodontic resolution of impacted canines.

CBCT minimizes superimposition artifacts and provides superior visualization of roots [24, 32]. In extraction cases with an impacted tooth, it is a much more important to decide which tooth to extract, a tooth with a resorbed root or a healthy premolar? Using CBCT images will contribute to a logical clinical outcome, as it provides superior information on root resorption.

Overall, it could be considered to increase efficiency and enhance success rates for the treatment of impacted teeth when the treatment and biomechanics are customized by using CBCT [33].

Field of view (FOV) must be determined according to the needs of the case. If the only problem is an impacted tooth, it would be logical to localize the FOV as the impacted tooth, adjacent teeth and surrounding alveolar structure. In fact, in a recent study, Wriedt et al. [30] recommended small volume FOV CBCT for impacted maxillary canines if the canine inclination on a conventional 2D panoramic radiograph exceeds 30° relative to a perpendicular midline, when adjacent root resorption is suspected, and/or when canine root dilaceration is suspected on conventional panoramic radiographs. But if an orthognathic surgical treatment plan is predicted, cephalometric and panoramic radiograph need must be considered while determining FOV. It is advisable to refer the patient to an oral and maxillofacial radiologist with a note including clinically significant findings and request a report on the region of interest [27].

Maxillary lateral incisor root resorption is most commonly associated with canine impaction. It often remains asymptomatic, limiting early diagnosis. However, early diagnosis is important, because the presence or absence of root resorption will determine the treatment strategy. Furthermore, advanced root resorption can make treatment impossible [34]. Improvement in diagnostic measures for early detection and prevention is therefore essential for ensuring correct treatment, and it might also reduce treatment time, complexity, complications and costs. It has been suggested that by using 3D images, overlapping of structures can be avoided.

Dental transposition represents a multifactorial condition. In the etiology of transposition, both genetic and environmental factors play an important role [35]. For the diagnosis and treatment planning of transposed teeth, several significant variables can be derived from CBCT imaging, especially, critical when deciding whether patient requires extraction or not. So, it would be much easier to evaluate adequately the quality and shape of teeth, location of roots and limitations of the alveolar boundary conditions around the transposed teeth by using CBCT. Kapila et al. [28] recommended to be selective about which cases may benefit from CBCT scans for assessing boundary conditions. Cases with compromised periodontal or gingival conditions, patients with narrow alveolar bone in which it would be critical to manage buccolingual displacements or angulations of teeth, and cases who need shifting position of the teeth are listed as cases that will benefit from CBCT scans.

3.2. Supernumerary teeth

A supernumerary tooth may closely resemble the teeth of the group to which it belongs [36]. In supernumerary cases, radiographic examination aims to determine the localization and the morphology of the supernumerary teeth. As it is critical to decide which teeth to be

extracted and which teeth to be retained, CBCT helps to precisely evaluate the position and morphology of these teeth. It is also possible to detect any contact between the supernumerary teeth and adjacent teeth and to evaluate their relation with other anatomical structures. The information obtained from CBCT images also facilitates the determination of the optimal surgical access to these teeth in order to minimize harm to adjacent teeth and to surrounding tissue [37] (Figure 2).

3.3. Root resorption

Root resorption is a condition occurs in response to a variety of stimuli resulting in a loss of dentin, cementum or bone [36]. Panoramic radiographs have a weak diagnostic efficacy in determining external root resorption. So, root resorption has traditionally been evaluated by periapical radiographs. Nevertheless, in recent years, it is suggested that CBCT can detect precise images of small root defects with a greater sensitivity and specificity compared to 2D radiographs [3, 24]. In a meta-analysis, Yi et al. [38] reported that CBCT is superior to periapical radiographs in the accuracy of diagnosing external root resorption. They emphasized that periapical radiographs provide limited information of external root resorption in the buccal and lingual root surface.

External root resorption of maxillary lateral incisor is a common finding that associates with canine impaction. Early diagnosis is difficult as it is asymptomatic and advanced root resorption makes the treatment planning more complex. In a study evaluating efficacy of CBCT for the diagnosis of root resorption associated with impacted canines, improved detection rates of root resorption (63%) were reported [39]. By using CBCT, it is possible to visualize of root resorptions on buccal and lingual surfaces. This might be critical for the extraction decision during treatment planning. In another study, it was suggested that the combination of thin slices and high resolution caused overestimation of the cavities for moderate root resorption cases [3].

The main problem is to decide how and when a clinician justify taking CBCT scan when a patient has undergone root resorption. Yi et al. [38] suggested that patients with clinically suspected root resorption be first evaluated by periapical radiographs. If positive results are obtained, for further examination, CBCT should be considered.

Alqerban et al. [10] reported that all CBCT systems used in their study showed high accuracy in the detection of root resorption, and there was no significant difference among CBCT systems in the detection of the severity of root resorption. Limitations of using CBCT for external root

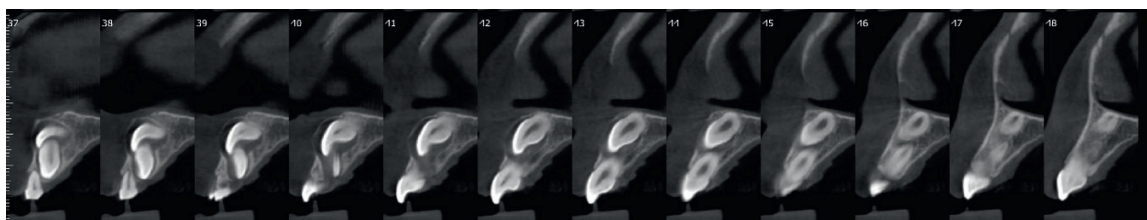


Figure 2. Evaluation of position of a supernumerary tooth and impacted incisor and their relation with neighboring structures.

resorption are the detection of small resorptions in the apical third and the high dose of radiation required [3].

3.4. Evaluation of root angulation and length

CBCT imaging becomes a preferred method for diagnosis by orthodontists because of its three dimensional rendering capability. Root position and morphology are critical issues for an orthodontist as it may affect the final occlusion. Root anatomy, such as short or dilacerated, is a determinant factor for the amount and direction of a tooth movement. Furthermore, because of the concerns about external root resorption, orthodontists need to get precise measurements of root angulation and length before treatment. Using CBCT images also provide detailed information about dysmorphic roots. Root positioning and morphology might be indicators of a disease. Of course, all root anomalies are not identical, but when supported with genetic testing, CBCT imaging will be helpful in interpreting anomalous root morphology in syndromic cases [40].

3.5. Tooth-bone relationship

In bimaxillary protrusion cases, Class 3 patients with an initial symphysis bone width, cases with preexisting periodontal disease, after maxillary expansion treatment, CBCT provides valuable information about tooth-bone relationships, and it might reduce the risk factor for dehiscence. While assessing deficiencies of buccolingual thickness in the alveolar ridge of patients subjected to critical tooth movement, high resolution and a limited FOV is recommended [41].

3.6. Cleft lip and palate (CLP) cases

Patients with CLP are treated by interdisciplinary teams from infancy until adulthood. Several types of surgical procedures are used to reconstruct the anatomy of the alveolar ridge, dentofacial region, lips and nose. The SEDENTEXCT Consortium stated, in regard to the radiation dose, that “the application of CBCT in cleft lip and palate patients was found to be the simplest to support” in dentistry [42]. However, in a recent systematic review, it was suggested that further investigation is necessary to determine the influence of this new 3D facial imaging modality on treatment planning, treatment outcome and treatment evaluation.

The preoperative CBCT may provide reliable estimates on how much expansion and graft material will be needed, aid in appropriate selection of an autogenous graft donor site before surgery and enable the visualization of the three-dimensional morphology of the bone bridge, the relationship between the bone bridge and roots of the neighboring teeth. For alveolar bone graft success, determination of the buccal-palatal width of the bone in CLP cases, the use of CBCT is recommended [43] (**Figure 3**). Pharyngeal space, the results of bone grafting, and the effect of nasoalveolar molding can be evaluated with a post-treatment CBCT.

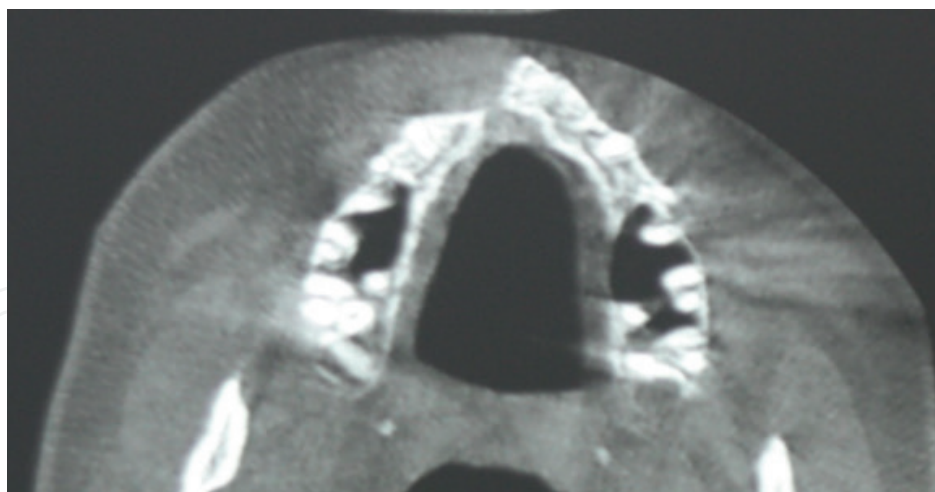


Figure 3. Preoperative CBCT view of a CLP case showing the graft site.

3.7. Temporomandibular joint (TMJ) morphology and pathology contributing to malocclusion

The changes in the size, form and special and functional relationships of the TMJ components might cause pathological TMJ conditions. TMJ disorders which occurred during active growth period might alter jaw, tooth positions and occlusion. Even though signs and symptoms of disturbances in the masticatory system are common, understanding the cause can be very complex. A proper diagnosis is possible, if only a thorough history and examination were achieved. Various types of imaging techniques can be used to gain additional information regarding the health and function of TMJs. CBCT is indicated for orthodontic cases that require analysis of TMJ bone components accompanied by signs and symptoms [44, 45]. One of the greatest advantages of CT scan is evaluating the condyle-disk relationship [46]. In comparison with panoramic radiograph and linear tomography, CBCT proves more accurate in diagnosing erosion of the condyle [47]. Soft tissue imaging is possible, but bony tissues are best imaged with CT scans [48]. As magnetic resonance imaging enables visualizing the non-mineralized soft tissues, it is preferable for the diagnosis of internal derangements of TMJ. However, it is not possible to observe dynamic joint movements.

Besides the evaluation of TMJ disorders, CBCT has been used to evaluate the condylar changes after orthodontic treatment. It allows volumetric evaluation of TMJ and provides better landmark identification on curved surfaces like condyle. Literature review showed that CBCT evaluation was preferred to determine respond of TMJ to mandibular advancement [49] or extraction treatment [50] and effects of the distraction splint therapy in mandibular asymmetry cases.

3.8. Airway morphology and obstructive sleep apnea (OSA)

Sleep-disordered breathing is a spectrum of conditions with abnormal respiratory pattern, and OSA is the severe end of that spectrum. Orthodontics takes place in the management of OSA by using mandibular advancement appliances and by planning orthognathic surgery in

these cases. It is also crucial to evaluate the dimensional changes in the nasopharyngeal area and airway obstruction in CLP [51]. Until recent years, lateral cephalometric radiography was used for the evaluation of the upper airway. But, changes which occur in the transverse dimension cannot be visualized. Three-dimensional analysis and evaluation of airway have got a significant attention in the literature. CBCT allows orthodontists to measure cross-sectional area, minimum cross section and total volume of the patient's airway accurately. Also, it has been used to investigate the effects of orthodontic treatments and orthognathic surgery on airway dimensions.

Studies of the upper airway based on CBCT scans are considered to be reliable in providing important information about the morphology of the pharyngeal airway; however, they have limitation in distinguishing different types of soft tissues [52]. Variations in airway dimensions and morphology due to patient's swallowing movement and head posture are also among the limitations of this technique [53].

3.9. Maxillary transverse dimension and maxillary expansion

In the treatment of transverse maxillary deficiencies, it is important to assess transverse dimension as early as possible and accurately diagnose the need for transverse maxillary expansion using proper diagnostic tools. Before CBCT, post-treatment skeletal changes on patients treated with RME were measured on dental casts, lateral and posterior-anterior cephalometric and occlusal radiographs. Researches to date on rapid maxillary expansion have focused on determining treatment outcomes like dental tipping, alveolar bone bending, skeletal expansion and soft tissue changes, rather than the benefits of CBCT in diagnosis and treatment planning. Nowadays, it is claimed that CBCT images appear to be more reliable than posteroanterior cephalograms, offer an unobstructed view for the assessment of transversal intermaxillary discrepancies and provide much greater resolution and minimal image distortion [15]. However, the radiation dosage and its effect on growing patients must be taken into account.

The mid-palatal suture becomes more fused after the completion of the adolescent growth spurt [54], as prediction of mid-palatal suture maturation is possible by using CBCT [55]. It is a reliable diagnostic tool, while planning surgically assisted rapid maxillary expansion (SARME) in skeletally mature patients or using bone-borne devices, which have recently gained popularity. It is possible to determine treatment outcomes of SARME and also permits the detection of the complications, such as tooth tilting of the anchoring teeth and bone fenestration due to periodontal stress [56].

3.10. Temporary anchorage device (TAD) placement

In recent years, TADs are considered as a prerequisite for the resistance of unwanted tooth movements during the treatment of various orthodontic problems without patient compliance. The most common indications for treatment with TADs are molar protraction followed by indirect skeletal anchorage for space closure, intrusion of supraerupted teeth, intrusion of anterior to manage anterior open bite, anterior en-masse retraction, molar uprighting,

intrusion of maxillary cant, molar distalization, traction on impacted canine, and attachment for protraction facemask. CBCT images can be helpful to anchor the miniscrew and mini-plate securely in the surrounding bone and to visualize neighboring structures for avoiding damage or complications during TAD placement and be useful in identifying optimal site location (**Figure 4**).

CBCT technology enables us to evaluate the interradicular distance and thickness, transverse bone thickness, bone density and thickness, cortical bone dimensions and quality. Even though anterior palate offers the greatest bone thickness, Holm et al. [57] recommended a CBCT evaluation for maximum screw length, as there is considerable variation of bone thickness between individuals. Before placing a miniscrew by using CBCT, it is also possible to define even cranial and caudal boundaries, besides alveolar boundary conditions, and eliminate the risk of bone and root perforations. Surgical guides fabricated using CBCT images will help to avoid possible root and maxillary sinuses damage. Finite element analysis constructed using CBCT will also guide the evaluation of mechanical advantages or disadvantages of the orthodontic appliances with TADs by simulating stress distribution.

There are several factors that affect the stability and success rate of TADs. If cortical bone thickness is less than 1 mm, primary stability may not be achieved, and the TAD may loosen during orthodontic treatment [58]. Evaluation of cortical bone quantity and quality is also critical for long-term stability. With finite element analysis, it has been shown that root contact is also one of the factors that can cause loss of miniscrew stability [59]. The information gathered from CBCT will be determinant for some of these factors, such as the dimension and insertion

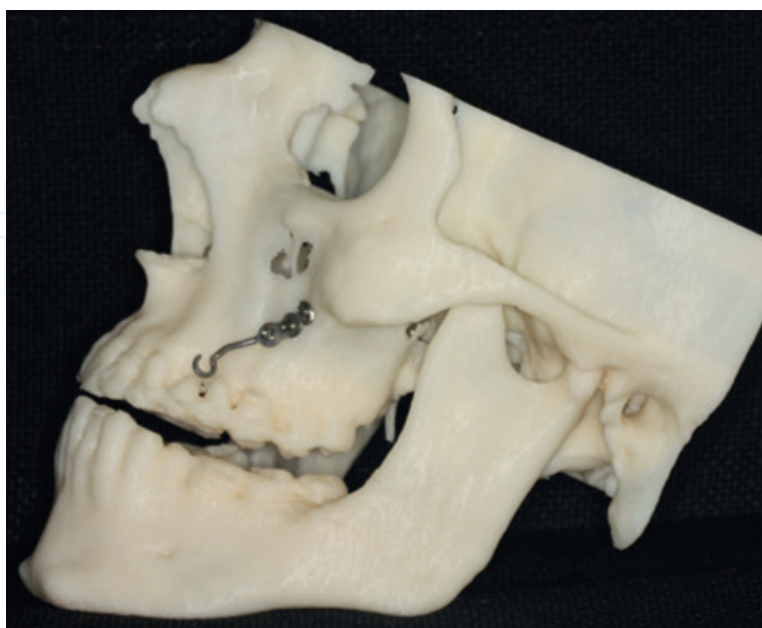

Figure 4. Planning and preparation of TAD (zygomatic skeletal anchorage) on a 3D model obtained from CBCT before surgery.

angle of the miniscrew, the insertion procedure, the depth of the screw insertion and insertion torque [38, 57, 60].

In some cases, routine panoramic, lateral and frontal cephalometric radiographs may not provide all information needed to optimize the location of a miniscrew placement. However, it should be kept in mind that in regions with a high bone quality, such as paramedian palate and palatal region, lateral cephalometric radiographs are usable to determine the location of TADs. Therefore, it is not necessary to take a CBCT in all cases [61].

It is recommended to use the smallest possible FOV unless the CBCT is needed for the diagnosis of another condition in which case a large FOV may be preferred [60].

3.11. Dentofacial deformities and craniofacial anomalies

Evaluation of changes in the craniofacial region during growth and with treatment using lateral cephalograms makes a great contribution to the science of orthodontics. However, in recent years, researches discussed the validity of evaluating a 3D craniofacial structure in a 2D plane. CBCT imaging can provide valuable information about dentofacial deformities and craniofacial anomalies, like facial asymmetry which affects three dimensions of the face, and it can be used to simulate virtual treatment plans for orthopedic corrections, orthognathic surgeries and distraction osteogenesis. By capturing images and analyzing the craniofacial hard and soft tissues and by generating virtual patient models, CBCT imaging permits the clinicians to reposition and reconstruct craniofacial structures (**Figure 5a, b**).

Several studies were conducted to determine reference planes, to develop cephalometric analysis, to evaluate the accuracy of these measurements, to establish the mean normality values and to assess the differences of gender and ethnic groups for 3D evaluations [62]. Besides morphological analysis, these images are used to evaluate the spatial relationship of the neighboring structures. CBCT technology enables carrying out the model surgery. So, computer assisted orthognathic surgery permits the design and fabrication of the occlusal surgical splints. By using virtual models, constructing anatomically grafts and correct replacement can be achieved (**Figure 6**). The data obtained from CBCT provide a better prediction of soft tissue response to the changes in the hard tissue after orthognathic surgery [63]. In the literature, CBCT is recommended for the assessment of preoperative orthodontic decompensation of maxillary and mandibular incisors [64]. This is an additional information from CBCT that is taken for orthognathic surgery planning, and it could not be one of the main purpose of using CBCT. Furthermore, CBCT proves a good method to assess TMJ after orthognathic surgery, particularly when there is considerable potential for resorption of the condyle [14].

3.12. Treatment outcomes

Taking CBCT at the end of orthodontic treatment is a controversial issue. However, it must be taken into consideration that studies on response to treatment can help elucidate clinical questions on variability of outcomes of treatment. There are studies assessing treatment

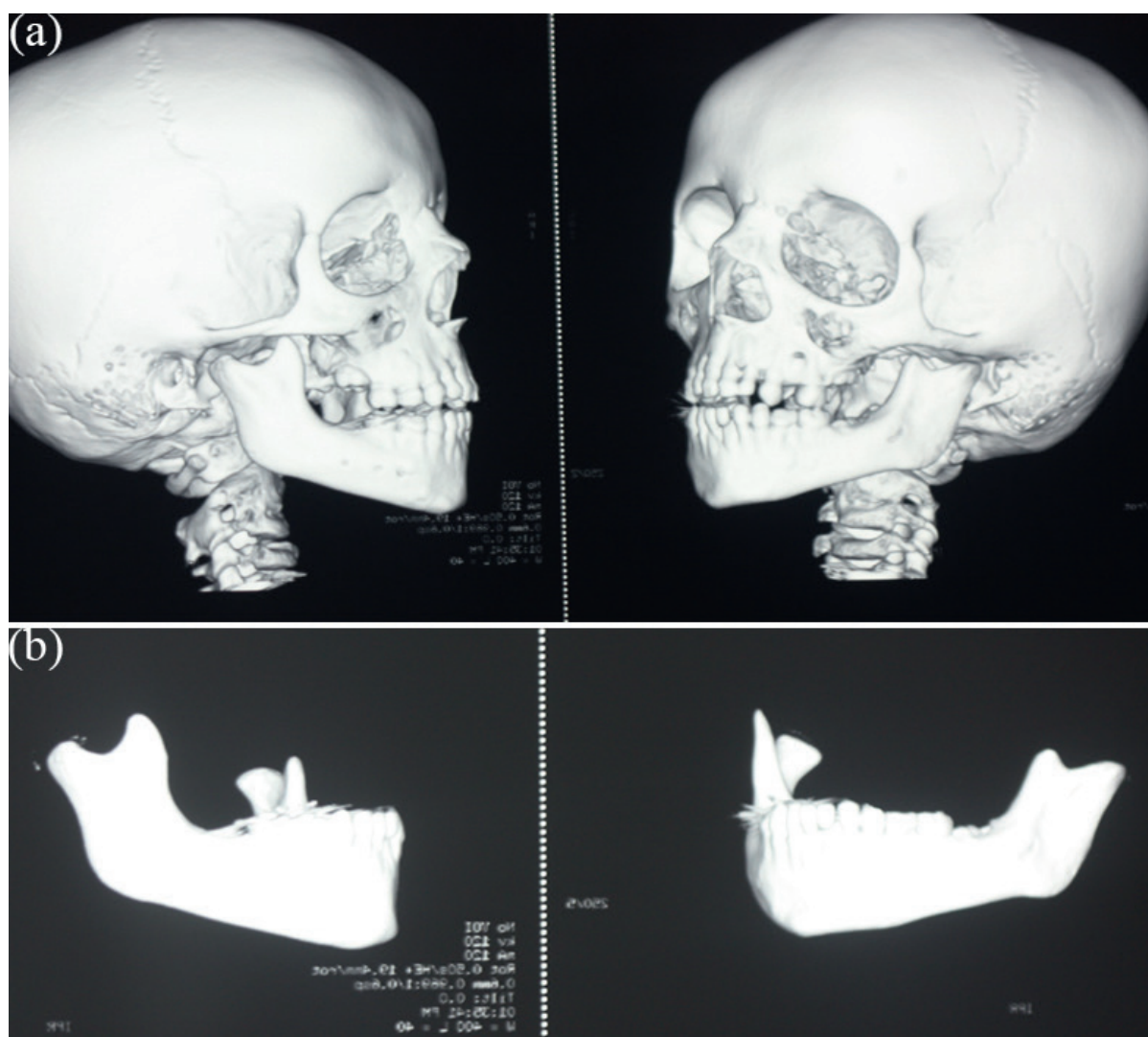


Figure 5. (a) 3D view of a case with Golden Haar syndrome. Note the asymmetric growth of left and right condyles. (b) 3D evaluation of mandible and condyles in this case.

outcomes of orthognathic surgery, maxillary expansion, bone grafting and several orthopedic appliances. A review of literature showed that jaw and teeth relationships, soft tissue, hyoid bone position, pharyngeal airway dimensions and morphology were evaluated after orthodontic and surgical treatments. To facilitate the evaluation of treatment outcomes, superimposition methods for CBCT images were also offered [28].

3.13. Evaluation of cervical vertebral maturation (CVM)

Skeletal maturation of patients is an important factor while planning orthodontic treatment. Hand-wrist and CVM methods were used for assessing the adolescent growth peak. It is suggested that the CBCT images may be useful for estimates of skeletal maturation, although they should not be used solely for that purpose [65]. Shim et al. [66] claimed that the esti-

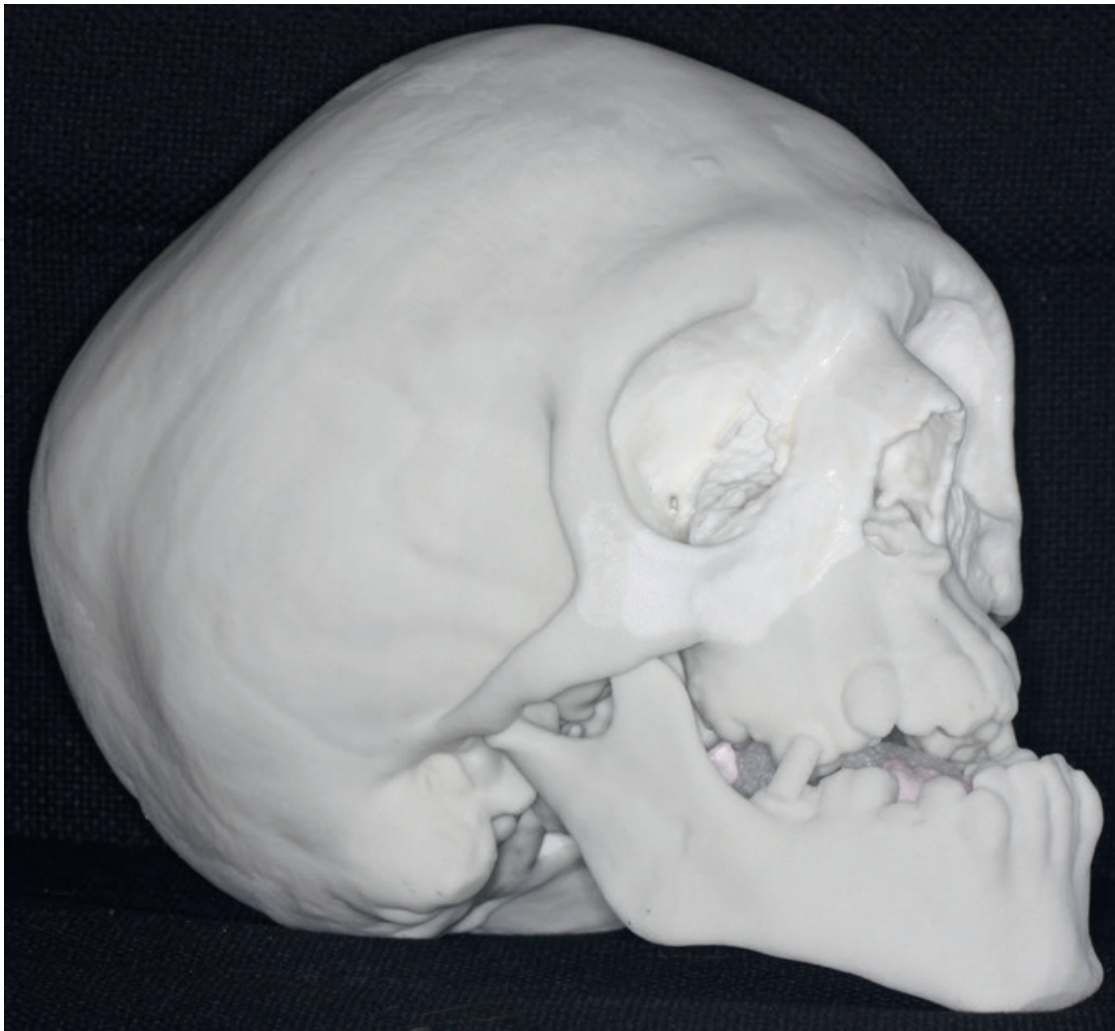

Figure 6. Presurgical 3D model of a case with Crouzon syndrome obtained from CBCT.

mate of maturation stages of the cervical vertebrae on CBCT provided a reliable evaluation of pubertal growth support and strongly positive correlations with lateral cephalograms and hand-wrist radiographs.

4. Radiation dose

Radiation dose depends on the CBCT scanner's specifications, milliamperage setting, peak kilovoltage (kVp), voxel size, sensor sensitivity and number of images obtained, the time of scanning, and FOV. It is recommended to apply the 3D evaluation when the use of CBCT can be justified. Clinicians should always keep in mind that the radiation exposure to a human being should be kept "As Low As Reasonably Achievable" (ALARA) principle.

SEDENTEXCT project guidelines include a variety of topics, like justification, referral criteria, optimization, training, quality assurance and staff protection aspects [67]. Justification

of using CBCT in dentistry can be considered if only a patient history and clinical information are available, if additional new information is expected, and if 2D radiographs are inadequate for diagnosis. The orthodontist should weigh the potential benefits of a CBCT against the chance of causing cancer for each patient. The chance may be small, but it is never negligible.

To reduce the patient dose, the smallest available volume size should be preferred. kVp and mAs of CBCT used in dental and maxillofacial region vary in a wide range and patients' doses varies considerably. It is recommended to standardize exposure parameters in dental and maxillofacial CBCT for each imaging task [68]. Gamache et al. [7] suggested that the total radiation exposure from CBCT scans can be reduced by while maintaining adequate image quality using low kV and moderate-to-high mA settings rather than the manufacturer-recommended settings.

Voxel size should be determined according to the purpose of the exam. When voxel dimension decreases, a better spatial resolution will be achieved, but the radiation dose will be increased [70]. Voxel sizes of 0.3–0.4 mm should be preferred if there is no need for a high level of detail [41].

Using child dose is offered because effective doses are higher compared with adults if exposure factors are not adapted. In a study on estimation of pediatric organ and effective doses from dental CBCT in 2012, it was reported that the average effective doses to the 10-year-old and adolescent phantoms were 116 and 79 mSv, respectively, which are similar to adult doses. So, the authors concluded that dental CBCT examinations on children should be fully justified over conventional X-ray imaging due to the higher radiosensitivity of children and that dose optimization by FOV collimation is particularly important in young children [69]. FOV should be restricted as much as possible [42]. So, the examination should include only the areas of interest in order to minimize radiation dose and ALARA principle must be followed. Repeated CBCT examinations should be avoided. The patient must be informed, and consent of the patient or parents must be obtained.

Technical properties of CBCT units were given inadequately in several studies. To make a comparison based on effective dose between studies, these properties must be reported and more evidence base studies on effective dose and image quality relation are still needed [70].

5. Future of CBCT in orthodontics

Further research-based technological developments are needed to achieve CBCT imaging, which is cost-effective, more precise on landmark identification and providing more accurate image quality with reduced radiation dose. By technological evolution and innovation of this technique, indications and the usage of CBCT in orthodontics will advance in the future. Future investigations are needed to investigate the dose levels for pediatric imaging protocols and to assess the use of a thyroid collar as a dose reduction technique.

6. Conclusions

In recent years, the use of CBCT in orthodontics has gained popularity and preferred as an imaging method by many clinicians for diagnosis and treatment planning. In this chapter, the indications and usage of CBCT in orthodontics are summarized. Clinicians should have comprehensive knowledge about advantages, disadvantages, limitations and potential risks due to increased radiation dose before deciding to use CBCT. Evidence-based studies are still needed whether using CBCT has any effect on clinical decision and lead to an improvement in treatment outcome.

Acknowledgements

We like to thank for their valuable contributions Dr. Sema Yuksel, Dr. Neslihan Ucuncu, Dr. Nilufer Darendeliler, Dr. Erdal Bozkaya, Dr. Secil Acar, Dr. Gülce Tosun who shared 3D views of their cases.

Author details

Emine Kaygısız* and Tuba Tortop

*Address all correspondence to: dt.emineulug@mynet.com

Faculty of Dentistry, Department of Orthodontics, Gazi University, Ankara, Turkey

References

- [1] Palomo JM, Valiathan M, Hans MG. Orthodontic Diagnosis and Treatment Planning. Available from: <http://pocketdentistry.com/11-3d-orthodontic-diagnosis-and-treatment-planning/3D>
- [2] Edwards R, Alsufyani N, Heo G, Flores-Mir C. Agreement among orthodontists experienced with cone-beam computed tomography on the need for follow-up and the clinical impact of craniofacial findings from multiplanar and 3-dimensional reconstructed views. *American Journal of Orthodontics and Dentofacial Orthopedics*. 2015;**148**(2):264-273
- [3] Alqerban A, Jacobs R, Souza PC, Willems G. In-vitro comparison of 2 cone-beam computed tomography systems and panoramic imaging for detecting simulated canine impaction-induced external root resorption in maxillary lateral incisors. *American Journal of Orthodontics and Dentofacial Orthopedics*. 2009;**136**(6):764.e1-e11; discussion 764-5
- [4] Alqerban A, Willems G, Bernaerts C, Vangastel J, Politis C, Jacobs R. Orthodontic treatment planning for impacted maxillary canines using conventional records versus 3D CBCT. *European Journal of Orthodontics*. 2014;**36**(6):698-707

- [5] Ludlow JB, Gubler M, Cevdanes L, Mol A. Precision of cephalometric landmark identification: Cone-beam computed tomography vs conventional cephalometric views. *American Journal of Orthodontics and Dentofacial Orthopedics*. 2009;**136**(3):312.e1-e10
- [6] Ludlow JB, Laster WS, See M, Bailey LJ, Hershey HG. Accuracy of measurements of mandibular anatomy in cone beam computed tomography images. *Oral Surgery, Oral Medicine, Oral Pathology, Oral Radiology, and Endodontology*. 2007;**103**(4):534-542
- [7] Gamache C, English JD, Salas-Lopez AM, Rong J, Akyalcin S. Assessment of image quality in maxillofacial cone-beam computed tomography imaging. *Seminars in Orthodontics*. 2015;**21**(4):248-253
- [8] Seet KY, Barghi A, Yartsev S, Van Dyk J. The effects of field-of-view and patient size on CT numbers from cone-beam computed tomography. *Physics in Medicine and Biology*. 2009;**54**(20):6251-6262
- [9] Varghese S, Kailasam V, Padmanabhan S, Vikraman B, Chithranjan A. Evaluation of the accuracy of linear measurements on spiral computed tomography-derived three-dimensional images and its comparison with digital cephalometric radiography. *Dentomaxillofacial Radiology*. 2010;**39**:216-223
- [10] Alqerban A, Jacobs R, Fieuws S, Nackaerts O, SEDENTEXCT Project Consortium, Willems G. Comparison of 6 cone-beam computed tomography systems for image quality and detection of simulated canine impaction-induced external root resorption in maxillary lateral incisors. *American Journal of Orthodontics and Dentofacial Orthopedics*. 2011;**140**(3):129-139
- [11] Larson BE. Cone-beam computed tomography is the imaging technique of choice for comprehensive orthodontic assessment. *American Journal of Orthodontics and Dentofacial Orthopedics*. 2012;**141**(4):402, 404, 406 passim
- [12] Kusnoto B, Kaur P, Salem A, Zhang Z, Galang-Boquiren MT, Viana G, Evans CA, Robert Manasse, Monahan R, BeGole E, Abood A, Han X, Sidky E, Pan X. Implementation of ultra-low-dose CBCT for routine 2D orthodontic diagnostic radiographs: Cephalometric landmark identification and image quality assessment. *Seminars in Orthodontics*. 2015;**21**(4):233-247
- [13] Cevdanes LH, Bailey LJ, Tucker GR Jr, Styner MA, Mol A, Phillips CL, Proffit WR, Turvey T. Superimposition of 3D cone-beam CT models of orthognathic surgery patients. *Dentomaxillofacial Radiology*. 2005;**34**(6):369-375
- [14] Cevdanes LH, Bailey LJ, Tucker SF, Styner MA, Mol A, Phillips CL, Proffit WR, Turvey T. Three-dimensional cone-beam computed tomography for assessment of mandibular changes after orthognathic surgery. *American Journal of Orthodontics and Dentofacial Orthopedics*. 2007;**131**(1):44-50
- [15] Sawchuk D, Currie K, Vich ML, Palomo JM, Flores-Mir C. Diagnostic methods for assessing maxillary skeletal and dental transverse deficiencies: A systematic review. *The Korean Journal of Orthodontics*. 2016;**46**(5):331-342

- [16] Baumrind S. The road to three-dimensional imaging in orthodontics. *Seminars in Orthodontics*. 2011;**17**(1):2-12
- [17] Scholz R. The radiology decision. *Seminars in Orthodontics*. 2011;**17**:15-19
- [18] Bayome M, Park JH, Kim Y, Kook Y. 3D analysis and clinical applications of CBCT images. *Seminars in Orthodontics*. 2015; **21**: 254-262
- [19] Valizadeh S, Tavakkoli MA, Karimi Vasigh H, Azizi Z, Zarrabian T. Evaluation of cone beam computed tomography (CBCT) system: Comparison with intraoral periapical radiography in proximal caries detection. *Journal of Dental Research, Dental Clinics, Dental Prospects*. 2012;**6**(1):1-5
- [20] Chang ZC, Hu FC, Lai E, Yao CC, Chen MH, Chen YJ. Landmark identification errors on cone-beam computed tomography-derived cephalograms and conventional digital cephalograms. *American Journal of Orthodontics and Dentofacial Orthopedics*. 2011;**140**(6):e289-e297
- [21] Alling CC, Helfrick JF, Alling RD. *Impacted Teeth*. Philadelphia, Pa: W.B. Saunders; 1993
- [22] Oberoi S, Knueppel S. Three-dimensional assessment of impacted canines and root resorption using cone beam computed tomography. *Oral Surgery, Oral Medicine, Oral Pathology, Oral Radiology*. 2012;**113**(2):260-267
- [23] Scarfe WC, Farman AG, Sukovic P. Clinical applications of cone beam computed tomography in dental practice. *Journal - Canadian Dental Association*. 2006;**72**(1):75-80
- [24] Alqerban A, Jacobs R, Lambrechts P, Loozen G, Willems G. Root resorption of the maxillary lateral incisor caused by impacted canine: A literature review. *Clinical Oral Investigations*. 2009;**13**(3):247-255
- [25] Walker L, Enciso R, Mah J. Three-dimensional localization of maxillary canines with cone-beam computed tomography. *American Journal of Orthodontics and Dentofacial Orthopedics* 2005;**128**(4):418-423
- [26] Haney E, Gansky SA, Lee JS, Johnson E, Maki K, Miller AJ, Huang JC. Comparative analysis of traditional radiographs and cone-beam computed tomography volumetric images in the diagnosis and treatment planning of maxillary impacted canines. *American Journal of Orthodontics and Dentofacial Orthopedics*. 2010;**137**(5):590-597
- [27] Kapila S, Nervina JM. 3D image-aided diagnosis and treatment of impacted and transposed teeth. In: Kapila S, editor. *Cone Beam Computed Tomography in Orthodontics*. John Wiley & Sons; 2014. pp. 349-382
- [28] Kapila S, Conley RS, Harrell WE Jr. The current status of cone beam computed tomography imaging in orthodontics. *Dentomaxillofacial Radiology*. 2011;**40**(1):24-34
- [29] Alqerban A, Hedesiu M, Baciut M, Nackaerts O, Jacobs R, Fieuws S; SedentexCT Consortium., Willems G. Pre-surgical treatment planning of maxillary canine impactions using panoramic vs cone beam CT imaging. *Dentomaxillofacial Radiology*. 2013;**42**(9):20130157

- [30] Wriedt S, Jaklin J, Al-Nawas B, Wehrbein H. Impacted upper canines: Examination and treatment proposal based on 3D versus 2D diagnosis. *Journal of Orofacial Orthopedics*. 2012;**73**(1):28-40
- [31] Becker A, Abramovitz I, Chaushu S. Failure of treatment of impacted canines associated with invasive cervical root resorption. *The Angle Orthodontist*. 2013;**83**(5):870-876
- [32] Alqerban A, Jacobs R, Fieuws S, Willems G. Comparison of two cone beam computed tomographic systems versus panoramic imaging for localization of impacted maxillary canines and detection of root resorption. *European Journal of Orthodontics*. 2011;**33**:93-102
- [33] Kapila SD, Nervina JM. CBCT in orthodontics: Assessment of treatment outcomes and indications for its use. *Dentomaxillofacial Radiology*. 2015;**44**(1):20140282
- [34] Westphalen VP, Gomes de Moraes I, Westphalen FH, Martins WD, Souza PH. Conventional and digital radiographic methods in the detection of simulated external root resorptions: A comparative study. *Dentomaxillofacial Radiology*. 2004;**33**(4):233-235
- [35] Ely NJ, Sherriff M, Cobourne MT. Dental transposition as a disorder of genetic origin. *European Journal of Orthodontics*. 2006;**28**(2):145-151
- [36] Shafer WG, Hine MK, Levy BM. *A Textbook of Oral Pathology*. Philadelphia: WB Saunders Co; 1985
- [37] Toureno L, Park JH, Cederberg RA, Hwang EH, Shin JW. Identification of supernumerary teeth in 2D and 3D: review of literature and a proposal. *Journal of Dental Education*. 2013;**77**(1):43-50
- [38] Yi J, Sun Y, Li Y, Li C, Li X, Zhao Z. Cone-beam computed tomography versus periapical radiograph for diagnosing external root resorption: A systematic review and meta-analysis. *The Angle Orthodontist*. 2017;**87**(2):328-337
- [39] Jawad Z, Carmichael F, Houghton N, Bates C. A review of cone beam computed tomography for the diagnosis of root resorption associated with impacted canines, introducing an innovative root resorption scale. *Oral Surgery, Oral Medicine, Oral Pathology, Oral Radiology, and Endodontology*. 2016;**122**(6):765-771
- [40] Nervina JM, Kapila SD. Assessment of root position and morphology by Cone Beam Computed Tomography. In: Kapila S, editor. *Cone Beam Computed Tomography in Orthodontics*. John Wiley & Sons; 2014. pp. 319-348.
- [41] Garib DG, Calil LR, Leal CR, Janson G. Is there a consensus for CBCT use in Orthodontics? *Dental Press Journal of Orthodontics*. 2014;**19**(5):136-149
- [42] European Commission. Radiation protection no 172. Cone beam CT for dental and maxillofacial radiology (evidence based guidelines). 2012. Available: http://www.sedentext.eu/files/radiation_protection_172.pdf. [Accessed 2014 Mar 16]
- [43] Hamada Y, Kondoh T, Noguchi K, Iino M, Isono H, Ishii H, et al. Application of limited cone beam computed tomography to clinical assessment of alveolar bone grafting: a preliminary report. *The Cleft Palate-Craniofacial Journal*. 2005;**42**(2):128-137

- [44] American Academy of Oral and Maxillofacial Radiology. Clinical recommendations regarding use of cone beam computed tomography in Orthodontics. Position statement by the American Academy of Oral and Maxillofacial Radiology. *Oral Surgery, Oral Medicine, Oral Pathology, Oral Radiology, and Endodontology*. 2013;**116**(2):238-257
- [45] Scarfe WC, Farman AG. What is cone-beam CT and how does it work? *Dental Clinics of North America*. 2008;**52**(4):707-730
- [46] Okeson JP. *Management of Temporomandibular Disorders and Occlusion*. Mosby Co.; 1998. pp. 281-303
- [47] Honey OB, Scarfe WC, Hilgers MJ, Klueber K, Silveira AM, Haskell BS, et al. Accuracy of cone-beam computed tomography imaging of the temporomandibular joint: comparisons with panoramic radiology and linear tomography. *American Journal of Orthodontics and Dentofacial Orthopedics*. 2007;**132**(4):429-438
- [48] Tuncer BB, Ataç MS, Yüksel S. A case report comparing 3-D evaluation in the diagnosis and treatment planning of hemimandibular hyperplasia with conventional radiography. *Journal of Cranio-Maxillo-Facial Surgery*. 2009;**37**(6):312-319
- [49] Knappe SW, Bakke M, Svanholt P, Petersson A, Sonnesen L. Long-term side effects on the temporomandibular joints and orofacial function in patients with obstructive sleep apnoea treated with a mandibular advancement device. *Journal of Oral Rehabilitation*. 2017;**44**(5):354-362
- [50] Alhammadi MS, Fayed MS, Labib A. Three-dimensional assessment of condylar position and joint spaces after maxillary first premolar extraction in skeletal Class II malocclusion. *Orthodontics & Craniofacial Research*. 2017. doi: 10.1111/ocr.12141
- [51] Massie JP, Runyan CM, Stern MJ, Alperovich M, Rickert SM, Shetye PR, Staffenberg DA, Flores RL. Nasal septal anatomy in skeletally mature patients with cleft lip and palate. *JAMA Facial Plastic Surgery*. 2016;**18**(5):347-353
- [52] Aboudara CA, Hatcher D, Neilsen IL, Miller A. A three-dimensional evaluation of the upper airway in adolescents. *Orthodontics & Craniofacial Research*. 2003;**6**(Suppl 1):173-175
- [53] Lenza MG, Lenza MM, Dalstra M, Melsen B, Cattaneo PM. An analysis of different approaches to the assessment of upper airway morphology: A CBCT study. *Orthodontics & Craniofacial Research*. 2010;**13**(2):96-105
- [54] Goldenberg DC, Alonso N, Goldenberg FC, Gebrin ES, Amaral TS, Scanavini MA, et al. Using computed tomography to evaluate maxillary changes after surgically assisted rapid palatal expansion. *Journal of Craniofacial Surgery* 2007;**18**:302-311
- [55] Jang HI, Kim SC, Chae JM, Kang KH, Cho JW, Chang NY, Lee KY, Cho JH. Relationship between maturation indices and morphology of the midpalatal suture obtained using cone-beam computed tomography images. *The Korean Journal of Orthodontics*. 2016;**46**(6):345-355

- [56] Koudstaal MJ, Wolvius EB, Schulten AJ, Hop WC, van der Wal KG. Stability, tipping and relapse of bone-borne versus tooth-borne surgically assisted rapid maxillary expansion: A prospective randomized patient trial. *International Journal of Oral and Maxillofacial Surgery*. 2009;**38**:308-315
- [57] Holm M, Jost-Brinkmann PG, Mah J, Bumann A. Bone thickness of the anterior palate for orthodontic miniscrews. *The Angle Orthodontist*. 2016;**86**(5):826-831
- [58] Motoyoshi M, Yoshida T, Ono A, Shimizu N. Effect of cortical bone thickness and implant placement torque on stability of orthodontic mini-implants. *The International Journal of Oral & Maxillofacial Implants*. 2007;**22**(5):779-784
- [59] Motoyoshi M, Ueno S, Okazaki K, Shimizu N. Bone stress for a mini-implant close to the roots of adjacent teeth-3D finite element analysis. *International Journal of Oral and Maxillofacial Surgery*. 2009;**38**(4):363-368
- [60] Baumgaertel S. Planning and placing temporary anchorage devices with the aid of cone beam computed tomography. In: Kapila S, editor. *Cone Beam Computed Tomography in Orthodontics*. John Wiley & Sons; 2014. pp. 411-426
- [61] Baumgaertel S, Hans MG. Buccal cortical bone thickness for mini-implant placement. *American Journal of Orthodontics and Dentofacial Orthopedics*. 2009;**36**(2):230-235
- [62] Porto OC, de Freitas JC, de Alencar AH, Estrela C. The use of three-dimensional cephalometric references in dentoskeletal symmetry diagnosis. *Dental Press Journal of Orthodontics*. 2014;**19**(6):78-85
- [63] Schendel SA, Lane C, Harrell WE Jr. 3D Orthognathic surgery simulation using image fusion. *Seminars in Orthodontics*. 2009;**15**:48-56
- [64] Sun B, Tang J, Xiao P, Ding Y. Presurgical orthodontic decompensation alters alveolar bone condition around mandibular incisors in adults with skeletal Class III malocclusion. *International Journal of Clinical and Experimental Medicine*. 2015;**8**(8):12866-12873
- [65] Bonfim MA, Costa AL, Fuziy A, Ximenez ME, Cotrim-Ferreira FA, Ferreira-Santos RI. Cervical vertebrae maturation index estimates on cone beam CT: 3D reconstructions vs sagittal sections. *Dentomaxillofacial Radiology*. 2016;**45**(1):20150162
- [66] Shim JJ, Heo G, Lagravère MO. Assessment of skeletal maturation based on cervical vertebrae in CBCT. *International Orthodontics*. 2012;**10**(4):351-362
- [67] Menezes CC, Janson G, Cambiaghi L, Massaro C, Garib DG. Reproducibility of bone plate thickness measurements with cone-beam computed tomography using different image acquisition protocols. *Dental Press Journal of Orthodontics*. 2010;**15**(5):143-149
- [68] ICRP. Radiological protection in Cone Beam Computed Tomography. ICRP Publication. 129. *Annals of the ICRP*. 2015;**44**(1)

- [69] Theodorakou C, Walker A, Horner K, Pauwels R, Bogaerts R, Jacobs R. SEDENTEXCT Project Consortium. Estimation of paediatric organ and effective doses from dental cone beam CT using anthropomorphic phantoms. *The British Journal of Radiology*. 2012;**85**(1010):153-160
- [70] Al-Okshi A, Lindh C, Sal'e H, Gunnarsson M, Rohlin M. Effective dose of cone beam CT (CBCT) of the facial skeleton: A systematic review. *The British Journal of Radiology*. 2015;**88**:20140658