

We are IntechOpen, the world's leading publisher of Open Access books Built by scientists, for scientists

6,900

Open access books available

186,000

International authors and editors

200M

Downloads

Our authors are among the

154

Countries delivered to

TOP 1%

most cited scientists

12.2%

Contributors from top 500 universities



WEB OF SCIENCE™

Selection of our books indexed in the Book Citation Index
in Web of Science™ Core Collection (BKCI)

Interested in publishing with us?
Contact book.department@intechopen.com

Numbers displayed above are based on latest data collected.
For more information visit www.intechopen.com



Percutaneous Treatment of Mitral and Tricuspid Regurgitation in Heart Failure

Tomás Benito-González, Rodrigo Estévez-Loureiro,
Javier Gualis Cardona, Armando Pérez de Prado,
Mario Castaño Ruiz and Felipe Fernández-Vázquez

Additional information is available at the end of the chapter

<http://dx.doi.org/10.5772/intechopen.68493>

Abstract

Heart failure has become a real epidemic condition related to poor outcomes despite advances in medical therapies. Prevalence of significant mitral and/or tricuspid regurgitation is high in patients with advanced heart failure. Novel transcatheter techniques have recently emerged as a minimally invasive alternative in patients deemed high-risk for surgery or inoperable. Among them, MitraClip® system is thus far the first device that received regulatory approval and gained widespread clinical application, especially in patients with functional mitral regurgitation. Furthermore, first experiences with new devices for percutaneous mitral and tricuspid valves repair, and transcatheter mitral valve prosthesis have been increasingly reported. Percutaneous therapies for valvular heart disease have therefore become one of the most promising fields in the present and future of interventional cardiology and heart failure.

Keywords: mitral valve, tricuspid valve, advanced heart failure, MitraClip®, percutaneous edge-to-edge mitral valve repair, Cardioband®, Mitralign®, Carillon®, percutaneous tricuspid valve repair, transcatheter mitral valve prosthesis

1. Introduction

Heart failure (HF) is one of the most important causes of morbidity and mortality in developed countries [1]. The improvement in care of cardiac diseases has significantly reduced acute mortality of this condition, in turn, increasing chronic HF prevalence [2]. Hospitalizations for

HF are similarly increasing, resulting in very high costs for national health systems [3]. Despite developments in drug therapies and the widespread use of implantable cardiac devices, outcomes remain poor [4]. Several transcatheter implantable devices have recently emerged in an attempt to improve the prognosis and quality of life of such patients. In this chapter, we will review the percutaneous treatment alternatives for mitral and tricuspid regurgitation (TR) associated with advanced HF.

2. Transcatheter mitral valve intervention in mitral regurgitation

2.1. Functional mitral regurgitation and heart failure. Why a percutaneous approach?

Mitral regurgitation (MR) is one of the most common valvular disease worldwide [5] and its frequency is increasing with the age of the population. Functional MR (FMR) is a consequence of left ventricular (LV) remodeling with structurally preserved mitral valve (MV) leaflets. Significant MR may be present in half of the patients with congestive HF [6] and the development of MR after an acute myocardial infarction or in patients with dilated cardiomyopathy is associated with an increased risk of developing cardiac adverse events [7–11].

Surgery is the treatment of choice for patients with severe MR who refer symptoms or present LV dysfunction (LVD) [12]. However, up to 50% of patients cannot undergo MV surgery due to prohibitive surgical risk, usually related to advanced age, LVD or comorbidities [13]. Moreover, the proportion of patients with FMR undergoing surgical treatment is even lower [14]. Interestingly, open-heart surgery has yielded conflicting results in this sort of patients, with a lack of clear survival benefit and high recurrence rates even with modern techniques [15–18]. On the other hand, conservatively managed unoperated patients have poor clinical outcomes, especially those with FMR, whose mortality can exceed 50% at 5-years follow-up [19]. Large series from Duke University has proved that isolated medical management in patients with ischemic MR is associated with the highest rates of death after 20 years [20]. Thus, patients with FMR managed medically represent a high-risk population with high rates of death and readmission for HF [21]. Percutaneous MV therapies are emerging as an alternative for this population in order to fill a large unmet need.

2.2. Percutaneous mitral valve repair

The MV has a complex structure and its competence depends on the preservation of the MV leaflets, the subvalvular apparatus, the mitral annulus (MA) and the LV normal shape. Dysfunction of any of these different components may lead to the development of MR [22]. In the last few years, several percutaneous devices have been under investigation, addressing different anatomical and pathophysiological targets involved in MR [23, 24]. Percutaneous ongoing therapies have somehow tried to reproduce any of the already contrasted open-surgery techniques, such as edge-to-edge MV repair (MitraClip®), undersized annuloplasty (Carillon®, Cardioband®, Mitralign®) or chordal implantation (Neochord®). Some of them have gained approval for human use and have been tested in small clinical trials (**Table 1**).


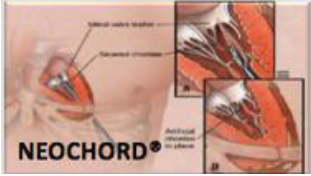



Device	Target of therapy	Year of CE mark	Current number of patients treated	Surgical background	Vascular access
	Leaflet coaptation	2008	>40,000	Edge-to-edge repair	Transfemoral
	Chordae implantation	2013	>300	Chordae implantation	Transapical
	Indirect annuloplasty	2009	>100	No	Transjugular
	Direct annuloplasty	2015	>100	Flexible ring	Transfemoral
	Direct annuloplasty	2016	>100	Commissuroplasty	Transarterial retrograde

Table 1. Summary of commercially available catheter-based therapies for PMVR.

2.2.1. Percutaneous edge-to-edge mitral valve repair (PMVR): MitraClip®

The MitraClip® system (Abbott Vascular, IL, USA) is thus far the first device that received regulatory approval and gained widespread clinical application. This device consists of two clip arms and opposing grippers, which can be opened and closed against each other in order to grasp and gain coaptation of MV leaflets at the origin of the regurgitant jet. The procedure is carried out under general anesthesia and using fluoroscopic and transesophageal echo guidance. Once the transseptal access is obtained, the system is advanced across the MV into the LV. Once the device is below the leaflets the two arms are opened and the device is retracted

to capture and subsequently closed to increase the coaptation surface of the MV leaflets. The clip can be reopened and repositioned if the obtained result is not acceptable. Further clips can be placed as needed for optimal MR reduction. The amount of remainder MV tissue and resulting increase in transmitral pressure gradient are the main procedural limitations for further clip deployment. A second-generation device with improved maneuverability is now available.

Transcatheter edge-to-edge MV repair has proven to be a safe and effective technique in selected patients with either functional or degenerative MR. Feasibility of the therapy with MitraClip® was first demonstrated in the Endovascular Valve Edge-to-Edge Repair Study (EVEREST) I trial [25] and subsequently compared with conventional surgery in the randomized controlled trial (RCT) EVEREST II [26]. In these studies, stringent echo criteria were used to guide the feasibility of device insertion and deployment. However, with increasing experience more complex valve pathologies can be treated with excellent results [27].

The vast majority of clinical evidence in PMVR is related to MitraClip® and it is currently the most advanced available technology for clinical use. In the EVEREST II trial, 184 patients were randomized (2:1) to receive MitraClip® therapy and 95 patients to undergo surgical MV repair or replacement. Included study population was older than reported surgical series of MV repair (mean age 67 years old) and presented higher rates of comorbidities. The device proved to be safer than surgery with a significant reduction of major adverse events (9.6% versus 57% with surgery, $p < 0.0001$), although this difference was mainly driven by a greater need for blood transfusion with surgery. Conversely, in the intent to treat analysis, survival free from the primary endpoint (death, MV surgery and MR > 2+) was lower with MitraClip® as compared with surgery (55% vs 73%, $p = 0.0007$) [26]. Results of this trial at 5 years follow-up confirmed the initial results of the study. In those patients with an initial successful repair, no differences in mortality or reoperation were found in the PMVR arm compared to surgery. The proportion of patients with MR grade 3+ or 4+ at 5-year follow-up was 19%, just the same observed at 1 year, reassuring the durability of the PMVR [28].

2.2.1.1. Real-world candidates for percutaneous edge-to-edge mitral repair

Although most patients included in the EVEREST II trial had degenerative MR, in the subgroup of patients with LVD and/or FMR, no differences in outcomes were observed between MV surgery and MitraClip®, opening a new niche for PMVR. In fact, subsequent observational studies, have mainly recruited patients with FMR, especially in Europe (**Table 2**) [29–36]. Beyond the learning curve, real-world reported results showed increasing rates of procedural success over 90–95%, compared to initial experience in the EVEREST I and II trials. Furthermore, observational published registries have reported very low short-term adverse events and consistent improvements in symptoms, quality of life and MR reduction. Cohorts included in the main European registries may draw the profile of the current prototype of patient candidate for PMVR: advanced age, high-surgical risk, FMR and frequent history of ischemic heart disease, LVD and implantable stimulation device therapies (**Table 3**).

Study	Type of study	Number of patients treated with MitraClip®	Location (number of sites)	Enrollment years	Functional MR (%)	Procedural success (MR ≤ 2+) (%)
EVEREST I [26]	Feasibility trial	24	USA (11)	2003–2005	21	74
EVEREST II [28]	RCT	184	USA (37)	2005–2008	49	77
EVEREST II HR [55]	Registry	351	USA (38)	2007–2014	70.1	85.8
ACCESS-EU [29]	Registry	567	Europe (11)	2009–2011	77	91.2
MitraSwiss [30]	Registry	100	Switzerland (4)	2009–2011	62	85
Armoiry et al. [31]	Registry	62	France (7)	2010–2012	74	88.2
SENTINEL [32]	Registry	628	Europe (25)	2011–2012	72	95.4
TRAMI [33, 34, 52]	Registry	1064	Germany (20)	2010–2013	71	95.2
MARS [35]	Registry	145	Asia (8)	2011–2013	54	94
STS/ACC TVT [36]	Registry	564	USA (61)	2013–2014	14	93

Table 2. Main multicenter trials and registries of PMVR.

2.2.1.2. Special subsets of patients candidates for MitraClip

2.2.1.2.1. Non-responders to cardiac resynchronization therapy

MitraClip® has also been proved to be a useful tool for those patients with HF not responding to cardiac resynchronization therapy (CRT) [37]. Auricchio et al. reported their experience with 51 patients who were severely symptomatic despite CRT therapy. In this cohort, PMVR was associated with a significant reduction in MR, clinical improvement and favorable remodeling echocardiographic parameters during a median follow-up of 14 months.

Appropriate candidates	Other potential candidates
Functional mitral regurgitation	Acute ischemic mitral regurgitation
Severe left ventricular dysfunction	Hemodynamically unstable
High-risk for conventional surgery or inoperable	Low probability of successful surgical repair
Prior cardiac surgery (CABG)	Falling surgical ring
Non-responders to cardiac resynchronization therapy	Advanced heart failure

Table 3. Profile of patients that should be considered for PMVR.

2.2.1.2.2. *End-stage heart failure*

The effect of MitraClip® in patients with end-stage HF was reported by Franzen et al., analyzing the treatment of 50 patients with LV ejection fraction (LVEF) $\leq 25\%$, MR $\geq 3+$ and severely symptomatic (NYHA III–IV) [38]. The acute procedural success was 94%, and 92% of patients were discharged with MR $\leq 2+$. One month mortality was 6% (predicted by EuroScore 34%). At 6-month follow-up, 72% patients were in functional class NYHA I or II; there was inverse remodeling on echo follow-up and a relevant reduction in BNP levels. Several reasons may account for these results: first, the positive hemodynamic changes observed after treatment with reductions in pulmonary pressure, capillary wedge pressure and increase in cardiac output (CO). Second, the avoidance of the low CO post MV surgery; and third, the favorable remodeling in LV [39–41]. However, patients with very poor LVEF are at high-risk of mortality even with this therapy. Careful selection of these candidates based on operators' experience, probability of success and expected benefits is strongly advisable [34].

2.2.1.2.3. *Acute ischemic mitral regurgitation*

Acute ischemic MR is a severe complication associated with high rates of morbimortality even when surgically corrected [42]. MitraClip® has proved to be a safe and effective alternative to surgical intervention in these unstable patients [43, 44]. Acute MR usually develops in a previously normal MV and therefore anatomical features are optimal for PMVR. Rapid improvement in patient's hemodynamics and the avoidance of the systemic inflammatory response associated with cardiopulmonary bypass are potential advantages of transcatheter approach [45]. MitraClip® implantation could be considered as an urgent therapy during admission in patients with recurrent pulmonary edema and/or cardiogenic shock in which MR is deemed to be the main cause of decompensation [46].

2.2.1.2.4. *Failing annuloplasty rings*

Undersized annuloplasty is currently the standard approach for MV surgical repair [47]. Even with the modern prosthetic mitral rings, long-term durability is a major concern in patients with FMR, in which the risk for recurrence can be over 50% at 2 years [48]. These patients are frequently symptomatic, with an increased number of hospitalizations, and present often significant LVD. Series from Italy and Spain have proved that the use of the device is safe and produces a persistent reduction in MR, hemodynamic improvement and symptom relief [49, 50]. Therefore, MitraClip® should be considered as an alternative therapy in this sort of patients, given the unacceptable high-risk that may carry reoperation.

2.2.1.3. *Expected benefits from percutaneous edge-to-edge repair*

2.2.1.3.1. *Persistent reduction in mitral regurgitation*

Persistent MR reduction is one of the main goals of PMVR. The target proposed since the EVEREST trials is to achieve a reduction of mitral insufficiency to a degree $\leq 2+$ and this has been considered as a definition for procedural success (PS) and an acceptable result during follow-up [25]. Interestingly, the EVEREST II trial was the one with the lower PS reported (77%)

[26]. The use of a single clip in almost all the patients and the fact that the trial was conducted in the beginning of the learning curve of most centers may explain the lower efficacy of the device compared to surgery. With increasing following experience, PS has raised to over 90% of cases in most series, highly impacting the prognosis of patients [29, 32–34, 51, 52]. A persistent MR reduction is linked to better outcomes and “the less MR possible” should be the target of all procedures [53]. Conversely, inability to reduce MR is an independent marker of adverse prognosis [32, 34]. The mechanisms supporting this observation are likely to be related to the hemodynamic changes observed after MR correction [39, 40]. Recurrence of significant MR is around 6–21.1% at 1 year [29, 32]; notably similar figures are reported with surgical repair for ischemic FMR [18].

2.2.1.3.2. *Symptoms improvement*

Symptomatic improvement is one of the most reported benefits of this therapy. Preprocedure patients are usually highly symptomatic with proportions of NYHA functional class III–IV over 85% in published series. After treatment with MitraClip®, there is a significant recovery in the functional capacity with patients presenting on NYHA functional class I–II in a range of 63.3–86% [29, 32, 34, 54, 55]. Furthermore, patients as well experience improvement in 6 minutes-walk test [29] and quality of life [54, 56], and a significant reduction in serum BNP levels [38]. Clinical improvement does also lead to a significant reduction in readmissions for HF, which reduces costs of patients’ health care and might probably turn into better prognosis [55].

2.2.1.3.3. *Survival advantage*

Survival of patients with FMR treated with MitraClip® is in the range of 15.3–20.3% within the first year [29, 32, 34]. The largest follow-up reported showed an actuarial survival at 3 years of 74.5% [55].

The available evidence to date regarding this issue relies mainly on retrospective studies. The first published was the EVEREST high-risk study [57], where 78 patients with high-surgical risk ($STS \geq 12\%$) were treated with MitraClip® and compared with a cohort of 36 patients managed medically. At 1 year, MitraClip® patients have significant higher survival rates (76% PMVR vs. 55% medical therapy, $p = 0.045$). In a study by Swaans et al. [58], 139 patients treated percutaneously were compared to 59 patients medically treated. After controlling by propensity score matching, MitraClip® was associated with a relative reduction in the risk of mortality of 59%. In another paper, Velazquez et al. [59] compared the outcomes of 351 patients included in the EVEREST high-risk registry with a historic comparator cohort. Two-hundred and thirty-nine propensity-matched patients in each group were analyzed and MitraClip® was associated with a 1 year improved survival (mortality 22.4% MitraClip® vs. 32% medical therapy, $p = 0.043$). The relative risk reduction in mortality associated with the device was 34%. Finally, Giannini et al. [60] included 60 patients treated with MitraClip® and propensity matched with 60 patients with OMT. After a median follow-up of 515 days, patients treated with PMVR showed less mortality, less cardiac mortality and less readmissions due to heart failure (log-rank test $p = 0.007$, $p = 0.002$ and $p = 0.04$, respectively). While we wait for the final confirmation of these results in currently ongoing RCTs, this information encourages the application of the therapy.

2.2.1.3.4. *Effect on heart remodeling: mitral annulus and left ventricle*

Reverse LV remodeling is the ‘holy grail’ of PMVR. Reported results from surgical series of primary MR have been linked to better prognosis [61]. Echo reports from EVEREST trial have demonstrated that there is an inverse remodeling after a successful MitraClip® procedure involving both the left chambers (ventricle and atrium) [62]. Interestingly, the magnitude of the reverse remodeling is greater with greater reduction in MR and this positive effect is maintained at 5 years follow-up [28]. Similar findings were reported in the EVEREST high-risk cohort [55, 57], although, in these series, patients with LVEF below 25% and severe LV dilation (LV end-systolic diameter > 55 mm) were excluded. By contrast, real-world FMR patients treated with MitraClip® tend to exhibit poor or no remodeling at all [32]. One possible explanation for these conflicting results is that real-world patients are treated too late in the natural history of the chronic HF disease, when the LV is largely dilated and LVEF is severely depressed. These patients are less likely to show reverse remodeling and this is a hint for the best timing for PMVR.

Although PMVR with MitraClip® reproduces somehow the Alfieri procedure, traction forces within MV may also favor MA remodeling. Recent studies have demonstrated that in FMR, the MA size (anteroposterior diameter), the MA area and the tenting area are significantly reduced after device implantation [63]. Furthermore, this reduction is associated with an improved functional status at 6 month after the procedure [64]. Conversely, in primary MR, MA parameters remain stable after clipping. Therefore, the potential association of an indirect annuloplasty-like effect may improve mid-term results of this therapy in patients with FMR.

2.2.2. *Percutaneous chordal replacement: Neochord®*

Neochord® (Neochord, Minnesota, MN) are the first ePTFE chordal loops conceived to be implanted on the MV leaflets to correct flail or prolapse [65]. Colli et al. reported the results of transapical off-pump mitral valve implantation of Neochord in 62 patients with MV prolapse [66]. Thirty-day major adverse events included one acute myocardial infarction (2%) and two cases of sepsis (3%). MR at 30 days was grade 1+ or 2+ in 55 patients (88.7%).

2.2.3. *Transcatheter mitral valve annuloplasty (TMVA): Carillon®, Cardioband®, Mitralign®*

Annuloplasty is the most common surgical repair performed to treat MR [47]. This technique is widely used as a stand-alone procedure to enhance MV coaptation in FMR or added to leaflet repair in degenerative MR in order to improve durability [67]. Based on prior large surgical experience, some percutaneous novel devices have tried to reproduce undersized MV annuloplasty to address dilatation of the MA. A reliable TMVA has the potential to improve outcomes in combination with edge-to-edge repair in selected patients and to increase therapeutic alternatives in patients with anatomic ineligibility for MitraClip®. As a further potential advantage, unlike the MitraClip®, this approach preserves the native valve anatomy, thus keeping the option for future valve implantation open. In fact, some of the annuloplasty rings may actually serve as a dock for the anchoring of available transcatheter aortic valves (“valve-in-ring” procedure).

2.2.3.1. *Carillon*[®]

The coronary sinus (CS) encircles approximately two-thirds of the MA, in close relation to the posterior and anterior MV leaflets. This was the rationale for the first catheter-based devices that aim to achieve an indirect annuloplasty through the cannulation of the CS. The *Carillon*[®] Mitral Contour System (Cardiac Dimension, Inc., Kirkland, WA, USA) obtained the CE mark in 2011. This deformable annular system is implanted in the CS and can reduce the septolateral diameter of the MA by postimplant cinching [68]. The procedure can be easily performed under fluoroscopic guidance through a jugular vein access and without general anesthesia. Nevertheless, some limitations have hampered the development of this technique. Advance imaging studies have demonstrated that the location of the CS is not coplanar to the MA, but basally displaced into the LA [69]. Moreover, potentially serious complications have also been reported, including compression of the circumflex artery or damage of the septal conduction system [70]. Finally, the lack of prior surgical background for the CS approach may be a concern as regards the long-term outcomes of this procedure.

To date, published evidence is limited to a couple observational studies. In the Titan trial, only 36 of 53 (67.9%) patients underwent permanent system implantation due to transient coronary compromise or reduction of MR < 1+ (recapture of the device was carried out in those cases) [71]. Rates of death at 1 and 12 months in this study were 1.9 and 22.6%. In the TITAN II trial, the system was successfully implanted in 30 of 36 (83.3%) patients, and 30-day and 1-year reported mortality were 2.8 and 23%, respectively. Both trials showed that device implantation was related to a significant reduction in MR, and to clinical improvement and reverse LV remodeling in patients with FMR and HF during up to 24-month follow-up. Ongoing REDUCE trial will compare the device to OMT in HF subjects with FMR, thus, providing further evidence of the potential benefits of this technology.

2.2.3.2. *Cardioband*[®]

Cardioband[®] (Valtech, Inc, Or Yehuda, Israel) is the transcatheter device that most closely resembles surgical direct annuloplasty technique. The system consists of a flexible annuloplasty band that is delivered from a transseptal approach and implanted onto the atrial side of the MA. This incomplete Dacron ring is attached in a supraannular position with multiple spiral anchors from commissure to commissure under transesophageal echo and fluoroscopic guidance. After implantation, the *Cardioband*[®] length can be shortened in order to improve leaflet coaptation and reduce MR.

Although flexible partial rings have failed in this sort of patients when implanted surgically [72], initial clinical experiences with *Cardioband*[®] are promising, confirming the feasibility and safety of the device implantation [73]. The CE Mark Trial has enrolled high-risk subjects with symptomatic FMR despite OMT. Early outcomes of this trial in 31 patients at 1 month showed a significant reduction in the septolateral dimension of the MA in all but two patients (36.8 ± 4.8 vs. 29 ± 5.5 mm, $p < 0.01$) and an increased leaflet coaptation surface [74]. Following *Cardioband*[®] adjustment (29 of 31 patients), MR was none or trace in 6 (21%), mild in 21 (72%) and moderate in 2 (7%) cases. Procedural mortality was zero and in-hospital mortality was 6.5%

(2 of 31 patients, neither procedure nor device-related). At 30 days, 22 of the 25 patients (88%) had MR grade $\leq 2+$. Following results of this trial showed persistent reduction in MR (92% MR $\leq 2+$) and improvement in functional class (77% NYHA I–II) at 24-month follow up. Reported procedural success rate (reduction in at least one grade in MR at discharge) was 86%. In 2017, an RCT comparing Cardioband® versus stand-alone OMT will start recruiting in the USA.

2.2.3.3. Mitralign®

The Mitralign® (Mitralign, Inc., Tewksbury, MA, USA) is a transcatheter direct annuloplasty system that mimics the Kay-Wooler commissuroplasty [75]. The device allows selective plication of the medial and lateral aspects of the MA by deploying pairs of transannular “pledgets”. The procedure is carried out from a transfemoral retrograde approach under live echo and fluoroscopic guidance. Each pledget pair can be pulled together resulting in a segmental posterior annuloplasty [76]. In the CE Mark Trial, the system was successfully implanted in 70.4% of 71 high-risk subjects with FMR [77]. No intraprocedural death occurred, but four (8.9%) patients experienced cardiac tamponade. 30-days and 6-month reported all-cause mortality were 4.4 and 12.2%, respectively. Significant improvements in MR and clinical functional class, reduction in MA dimensions and LV remodeling were demonstrated at 6 months.

2.2.4. Transcatheter multimodal approach for mitral regurgitation

One of the lessons learned from heart valve surgery is that a combination of diverse techniques addressing different mechanisms of MR may improve long-term outcomes [67]. Recently, first experiences of direct and indirect TMVA after failure of PMVR with MitraClip® have been published [78, 79]. MitraClip® is currently the most widespread technique that focus on MV leaflets, with contrasted effective results. Nevertheless, reported recurrence of significant MR can surpass 20% at 1 year [29]. Notably, transcatheter mitral rings may play a role as valuable adjunct catheter-based procedures to Mitraclip® (or percutaneous chordal replacement) in selected patients (such as very dilated LA and MA).

2.3. Transcatheter mitral valve replacement (TMVR)

The simpler structure of the aortic valve (AV) has probably facilitated the success of a stent-like transcatheter approach for the treatment of AV disease. On the contrary, the much more complex structure of the MV may explain the slower way to find a safe and effective alternative for TMVR. Many companies have completed first-in-human cases; however, no devices are currently approved beyond compassionate use, and several others remain in preclinical development. These percutaneous MV prostheses vary either in the access site, the design and the anchoring technology within the MA or the subvalvular apparatus [80] (**Figure 1**). Currently, eight different devices have been already implanted in-human since 2012 (CardiaQ®, Neovasc Tiara®, Edwards Fortis®, Tendyne®, Twelve®, Navigate®, Highlife®, Caisson®) [81–84]. These initial experiences showed heterogeneous rates of morbidity and mortality across different platforms and pointed out some important challenging issues that might be determinant in the development of this technique: the LV outflow obstruction, the delivery profile and the access route (transapical vs transeptal). Interestingly, patients with



Figure 1. Current mitral valve platforms under development.

poor ejection fraction presented the higher rates of adverse outcomes and might not benefit from this procedure.

Recently, promising results from the Tendyne® feasibility trial have been published [85]. In this study 30 high-risk patients (mean age 75.6 years) with predominantly FMR (76.6%) grade 3 or 4 underwent TMVR. Successful device implantation was achieved in 28 patients (93.3%). No acute major cardiovascular adverse events were reported. One patient died 13 days after TMVR from hospital-acquired pneumonia and prosthetic leaflet thrombosis was detected in one patient at follow-up. At 30 days, transthoracic echocardiography showed mild central MR in 1 patient, and no residual MR in the remaining 26 patients with valves *in situ*. A significant decrease in LV dimensions was documented. Seventy-five percent of the patients reported mild or no symptoms at follow-up. Successful device implantation free of cardiovascular mortality, stroke and device malfunction at 30 days was 86.6%.

3. Percutaneous therapies for tricuspid regurgitation in heart failure

3.1. Functional tricuspid regurgitation

Functional tricuspid regurgitation (TR) represents over 90% of cases of TR and it is typically due to tricuspid annular dilatation (mainly in anteroposterior diameter) and right ventricular (RV) enlargement (leading to leaflet tethering) secondary to progressive left heart disease (LHD) [86]. The tricuspid valve (TV) has been considered for years the “forgotten” valve. This

issue may be explained by the fact that TR was believed to be well tolerated and reduced after treating LHD. On the contrary, patients with significant TR and HF tend to be highly symptomatic due to decrease in CO and abdominal and peripheral congestion [87]. Furthermore, the presence of moderate or severe TR is independently associated with an increased mortality (over 25% at 1 year) regardless of biventricular function or pulmonary pressures [88, 89].

Despite surgical treatment of LHD, significant TR can be found in over two-thirds of patients in long-term follow-up, suggesting that a lower threshold for TV repair should be considered when MV surgery is carried out [87, 90–92]. Current data support that TV repair at the time of MV surgery is safe, whereas reoperation for persistent TR is related to high morbidity and mortality rates [93–95]. Notwithstanding, few patients undergo TR surgery and the vast majority are managed medically. Data from the STS database suggest that moderate to severe TR is present in almost 2 million of patients in the United States, but not even 10,000 undergo TV surgery each year. Progressive RV dysfunction may lead to an irreversible RV damage, which is thought to be the reason for the poor outcomes of late surgery in this scenario. Therefore, there is a large unmet clinical need for patients with significant TR who are not referred for conventional surgery, mainly due to expected high-surgical risk. Percutaneous therapies for functional TR are emerging as an alternative to surgery in this scenario. Patients with symptomatic severe TR and prior open-heart surgery and those with significant TR and progressive RV dysfunction and failure despite OMT may benefit from transcatheter TV interventions. Initial experiences include the off-label use MV devices and first-in-human cases of dedicated new technologies [96] (**Table 4**). Among different therapies that have been tested in preclinical setting, transcatheter TV annuloplasty, resembling different successful surgical techniques, might be one of the most promising approaches [97, 98].

3.2. Transcatheter tricuspid valve interventions

3.2.1. Percutaneous tricuspid valve repair with mitral valve dedicated devices

The acquired experience in catheter-based therapies for MV with satisfactory results has emerged the appealing concept of using some of these devices in tricuspid position. Recently, Braun et al. have reported first series of edge-to-edge TV repair in 18 patients with moderate to severe functional TR and right-sided heart failure [99]. Six patients were treated for isolated severe TR, whereas 12 patients were treated concomitantly to PMVR. A reduction of at least one TR grade was achieved in all patients and no in-hospital major events were reported. A significant improvement in TR was observed (TR \geq 3+ 94% vs. 33%, $p < 0.001$) and sixteen patients (89%) referred an improvement in NYHA functional class at 30-day follow-up. In 2015, the first-in-human transcatheter TV repair with Mitralign® system was published, reproducing Kay posterior annuloplasty [100]. Recently, acute results of Trialign® early human use were reported. A single pair of pledgets was successfully implanted in 14 of the 16 patients (87.5%), with an average postprocedural reduction of 37% in TA and 59% in TV regurgitant orifice area. No procedural mortality occurred. Potential advantage of additional pledgets will be assessed. Cardioband® has been also successfully implanted in TA in humans [101] and European CE mark study (TRI-REPAIR) is currently initiated.


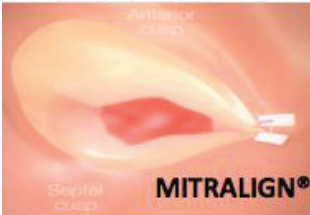
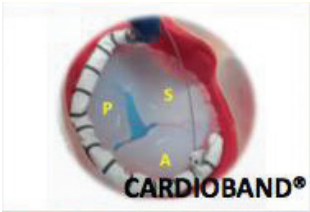

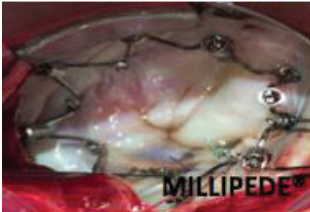
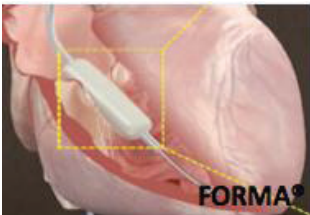
Device	Features	Strengths	Challenges
	Bicuspidization of the tricuspid valve First series reported	Large experience in mitral valve Friendly to operators	Vascular access route Modified clipping technique Three-leaflets configuration of the valve Annular dilatation not addressed
	Bicuspidization of the tricuspid valve (posterior commissure) First series reported Ongoing CE mark trial	Surgical background High safety profile	Risk of leaflet or right coronary artery injury Technically demanding Transesophageal echo guidance Valvular tissue properties
	Flexible-ring annuloplasty First in-human cases reported Ongoing CE mark trial	Surgical background	Little experience in mitral valve Risk of right coronary artery injury
	Simple indirect annuloplasty Ongoing CE mark trial	Surgical background High safety profile Fully retrievable before stenting	Risk of leaflet or right coronary artery injury Inferior vena cava dilatation
	Semi-rigid complete ring implanted in the atrial side of the tricuspid annulus First in-human cases reported	Surgical background Repositionable & retrievable	Risk of atrioventricular block
	Valve spacer to fulfil regurgitant orifice First in-human cases reported Ongoing CE mark trial	Good preliminary clinical results	Surgical pocket Large devices needed to fill coaptation gap No surgical background

Table 4. Catheter-based therapies for TR that have been already tested in humans.

3.2.2. *Transcatheter tricuspid valve repair therapies*

TriCinch® (4Tech Cardio, Galway, Ireland) consists of a steerable catheter with a corkscrew at the tip. Under echocardiographic and fluoroscopic guidance, supraannular fixation of the device is carried out in the mid part of the anterior TA. Afterwards, the catheter is tensioned in order to produce TA cinching, therefore reducing the anteroseptal dimension of the TA and improving leaflet coaptation. Finally, a self-expandable nitinol stent is positioned at the inferior vena cava in order to secure the system and maintain the tension applied. TriCinch® implantation preserves the native anatomy, allowing potential future treatment options. First in-human cases [102, 103] and early results from the PREVENT CE trial have been reported. The system was successfully implanted in 13 of 18 patients (72%). Two patients developed periprocedural hemopericardium and device TA detachment was observed in two patients. No mortality events occurred during up to 29 months follow-up. A significant improvement in 6-minute walk test and quality of life were documented, although only 37.5% remain in NYHA class I–II during this period.

3.2.3. *Other percutaneous approaches for tricuspid regurgitation*

The FORMA® Repair System (Edwards Lifescience, Irvine, USA) is a valve spacer created to increase coaptation surface by occupying space in the regurgitant orifice of the TV. The device is usually delivered through a transsubclavian venous route and anchored to the RV apex distally and proximally fixed within a small surgically prepared pocket. Preliminary results in seven high-risk patients with severe TR and advanced NYHA functional class III–IV were recently available [104]. The device was successfully implanted in all patients without major complications, obtaining at least one grade acute reduction in TR. 30-day results showed clinical improvements (100% NYHA class II) and stable TR reduction (100% moderate TR) without significant tricuspid stenosis.

Author details

Tomás Benito-González¹, Rodrigo Estévez-Loureiro^{1*}, Javier Gualis Cardona², Armando Pérez de Prado¹, Mario Castaño Ruiz² and Felipe Fernández-Vázquez¹

*Address all correspondence to: roiestevev@hotmail.com

1 Department of Cardiology, Interventional Cardiology Unit, University Hospital of León, León, Spain

2 Department of Cardiovascular Surgery, University Hospital of León, León, Spain

References

- [1] Go AS, Mozaffarian D, Roger VL, et al. Heart Disease and Stroke Statistics—2014 Update: A Report from the American Heart Association. 2014. Epub ahead of print 2014. DOI: 10.1161/01.cir.0000441139.02102.80

- [2] Roger VL. Epidemiology of heart failure. *Circulation Research*. 2013;**113**:646-659
- [3] Braunschweig F, Cowie MR, Auricchio A. What are the costs of heart failure? *Europace*. 2011;**13**:13-17
- [4] Metra M, Carubelli V, Ravera A, et al. Heart failure 2016: Still more questions than answers. *International Journal of Cardiology*. 2016;**227**:766-777
- [5] Nkomo VT, Gardin JM, Skelton TN, et al. Burden of valvular heart diseases: A population-based study. *Lancet*. 2006;**368**:1005-1011
- [6] Bursi F, Barbieri A, Grigioni F, et al. Prognostic implications of functional mitral regurgitation according to the severity of the underlying chronic heart failure: A long-term outcome study. *European Journal of Heart Failure*. 2010;**12**:382-388
- [7] Bursi F, Enriquez-Sarano M, Nkomo VT, et al. Heart failure and death after myocardial infarction in the community: The emerging role of mitral regurgitation. *Circulation*. 2005;**111**:295-301
- [8] Robbins JD, Maniar PB, Cotts W, et al. Prevalence and severity of mitral regurgitation in chronic systolic heart failure. *American Journal of Cardiology*. 2003;**91**:360-362
- [9] Trichon BH, Felker GM, Shaw LK, et al. Relation of frequency and severity of mitral regurgitation to survival among patients with left ventricular systolic dysfunction and heart failure. *American Journal of Cardiology*. 2003;**91**:538-543
- [10] Grigioni F, Enriquez-Sarano M, Zehr KJ, et al. Ischemic mitral regurgitation: Long-term outcome and prognostic implications with quantitative Doppler assessment. *Circulation*. 2001;**103**:1759-1764
- [11] López-Pérez M, Estévez-Loureiro R, López-Sainz A, et al. Long-term prognostic value of mitral regurgitation in patients with ST-segment elevation myocardial infarction treated by primary percutaneous coronary intervention. *American Journal of Cardiology*. 2014;**113**:907-912
- [12] Nishimura RA, Otto CM, Bonow RO, et al. 2014 AHA/ACC guideline for the management of patients with valvular heart disease: Executive summary: A report of the American college of cardiology/American heart association task force on practice guidelines. *Journal of the American College of Cardiology*. 2014;**63**:2438-2488
- [13] Mirabel M, Iung B, Baron G, et al. What are the characteristics of patients with severe, symptomatic, mitral regurgitation who are denied surgery? *European Heart Journal*. 2007;**28**:1358-1365
- [14] Borger MA, Alam A, Murphy PM, et al. Chronic ischemic mitral regurgitation: Repair, replace or rethink? *Annals of Thoracic Surgery*. 2006;**81**:1153-1161
- [15] Wu AH, Aaronson KD, Bolling SF, et al. Impact of mitral valve annuloplasty on mortality risk in patients with mitral regurgitation and left ventricular systolic dysfunction. *Journal of the American College of Cardiology*. 2005;**45**:381-387

- [16] Hung J, Papakostas L, Tahta SA, et al. Mechanism of recurrent ischemic mitral regurgitation after annuloplasty: Continued LV remodeling as a moving target. *Circulation*. 2004;**110**:II85-II90
- [17] McGee EC, Gillinov AM, Blackstone EH, et al. Recurrent mitral regurgitation after annuloplasty for functional ischemic mitral regurgitation. *Journal of Thoracic and Cardiovascular Surgery*. 2004;**128**:916-924
- [18] Acker MA, Parides MK, Perrault LP, et al. Mitral-Valve repair versus replacement for severe ischemic mitral regurgitation. *The New England Journal of Medicine*. 2014;**370**:23-32
- [19] Agricola E, Ielasi A, Oppizzi M, et al. Long-term prognosis of medically treated patients with functional mitral regurgitation and left ventricular dysfunction. *European Journal of Heart Failure*. 2009;**11**:581-587
- [20] Castleberry AW, Williams JB, Daneshmand MA, et al. Surgical revascularization is associated with maximal survival in patients with ischemic mitral regurgitation: A 20-year experience. *Circulation*. 2014;**129**:2547-2556
- [21] Goel SS, Bajaj N, Aggarwal B, et al. Prevalence and outcomes of unoperated patients with severe symptomatic mitral regurgitation and heart failure: Comprehensive analysis to determine the potential role of mitralclip for this unmet need. *Journal of the American College of Cardiology*. 2014;**63**:185-186
- [22] Dal-Bianco JP, Beaudoin J, Handschumacher MD, et al. Basic mechanisms of mitral regurgitation. *Canadian Journal of Cardiology*. 2014;**30**:971-981
- [23] Estevez-Loureiro R, Franzen O. Current state of percutaneous transcatheter mitral valve therapies. *Panminerva Medica*. 2013;**55**:327-337
- [24] Herrmann HC, Maisano F. Transcatheter therapy of mitral regurgitation. *Circulation*. 2014;**130**:1712-1722
- [25] Feldman T, Wasserman HS, Herrmann HC, et al. Percutaneous mitral valve repair using the edge-to-edge technique: Six-month results of the EVEREST phase I clinical trial. *Journal of The American College of Cardiology*. 2005;**46**:2134-2140
- [26] Feldman T, Foster E, Glower DD, Kar S, Rinaldi MJ, Fail PS, Smalling RW, Siegel R, Rose GA, Engeron E, Loghin C, Trento A, Skipper ER, Fudge T, Letsou GVL. Percutaneous repair or surgery for mitral regurgitation. *The New England Journal of Medicine*. 2011;**364**:1395-1406
- [27] Boekstegers P, Hausleiter J, Baldus S, et al. Percutaneous interventional mitral regurgitation treatment using the Mitra-Clip system. *Clinical Research in Cardiology*. 2014;**103**:85-96
- [28] Feldman T, Kar S, Elmariah S, et al. Randomized comparison of percutaneous repair and surgery for mitral regurgitation 5-Year results of EVEREST II. *Journal of the American College of Cardiology*. 2015;**66**:2844-2854

- [29] Maisano F, Franzen O, Baldus S, et al. Percutaneous mitral valve interventions in the real world: Early and 1-year results from the ACCESS-EU, A prospective, multicenter, nonrandomized post-approval study of the Mitraclip therapy in Europe. *Journal of the American College of Cardiology*. 2013;**62**:1052-1061
- [30] Sürder D, Pedrazzini G, Gaemperli O, et al. Predictors for efficacy of percutaneous mitral valve repair using the MitraClip system: The results of the MitraSwiss registry. *Heart*. 2013;**99**:1034-1040
- [31] Armoiry X, Brochet É, Lefevre T, et al. Initial French experience of percutaneous mitral valve repair with the MitraClip: A multicentre national registry. *Archives of Cardiovascular Diseases*. 2013;**106**:287-294
- [32] Nickenig G, Estevez-Loureiro R, Franzen O, et al. Percutaneous mitral valve edge-to-edge Repair: In-hospital results and 1-year follow-up of 628 patients of the 2011-2012 pilot European Sentinel Registry. *Journal of the American College of Cardiology*. 2014;**64**:875-884
- [33] Schillinger W, Hünlich M, Baldus S, et al. Acute outcomes after MitraClip® therapy in highly aged patients: Results from the German TRAns catheter Mitral valve Interventions (TRAMI) Registry. *EuroIntervention*. 2013;**9**:84-90
- [34] Puls M, Lubos E, Boekstegers P, et al. One-year outcomes and predictors of mortality after MitraClip therapy in contemporary clinical practice: Results from the German transcatheter mitral valve interventions registry. *European Heart Journal*. 2016;**37**:703-712
- [35] Yeo KK, Yap J, Yamen E, et al. Percutaneous mitral valve repair with the MitraClip: Early results from the MitraClip Asia-Pacific Registry (MARS). *EuroIntervention*. 2014;**10**:620-625
- [36] Sorajja P, Mack M, Vemulapalli S, et al. Initial experience with commercial transcatheter mitral valve repair in the United States. *Journal of the American College of Cardiology*. 2016;**67**:1129-1140
- [37] Auricchio A, Schillinger W, Meyer S, et al. Correction of mitral regurgitation in nonresponders to cardiac resynchronization therapy by MitraClip improves symptoms and promotes reverse remodeling. *Journal of the American College of Cardiology*. 2011;**58**:2283-2289
- [38] Franzen O, Van Der Heyden J, Baldus S, et al. MitraClip® therapy in patients with end-stage systolic heart failure. *European Journal of Heart Failure*. 2011;**13**:569-576
- [39] Siegel RJ, Biner S, Rafique AM, et al. The acute hemodynamic effects of mitralclip therapy. *Journal of the American College of Cardiology*. 2011;**57**:1658-1665
- [40] Biner S, Siegel RJ, Feldman T, et al. Acute effect of percutaneous MitraClip therapy in patients with haemodynamic decompensation. *European Journal of Heart Failure*. 2012;**14**:939-945
- [41] Gaemperli O, Biaggi P, Gugelmann R, et al. Real-time left ventricular pressure-volume loops during percutaneous mitral valve repair with the mitralclip system. *Circulation*. 2013;**127**:1018-1027

- [42] Chevalier P, Burri H, Fährat F, et al. Perioperative outcome and long-term survival of surgery for acute post-infarction mitral regurgitation. *European Journal of Cardio-Thoracic Surgery*. 2004;**26**:330-335
- [43] Bilge M, Alemdar R, Yasar AS. Successful percutaneous mitral valve repair with the mitralclip system of acute mitral regurgitation due to papillary muscle rupture as complication of acute myocardial infarction. *Catheterization and Cardiovascular Interventions*. 2014;**83**:E137-E140
- [44] Estévez-Loureiro R, Arzamendi D, Freixa X, et al. Percutaneous mitral valve repair for acute mitral regurgitation after an acute myocardial infarction. *Journal of the American College of Cardiology*. 2015;**66**:91-92
- [45] van Boven W-JP, Gerritsen WB, Driessen AH, et al. Myocardial oxidative stress, and cell injury comparing three different techniques for coronary artery bypass grafting. *European Journal of Cardio-Thoracic Surgery*. 2008;**34**:969-975
- [46] Leurent G, Corbineau H, Donal E. Uncontrolled daily pulmonary oedema due to severe mitral regurgitation emergently and effectively corrected by Mitraclip(R) implantation. *European Heart Journal: Acute Cardiovascular Care*. 2015;**5**:1-2
- [47] Maisano F, Skantharaja R, Denti P, et al. Mitral annuloplasty. *Multimedia Manual of Cardiothoracic Surgery MMCTS/European Association for Cardiothoracic Surgery* 2009; 2009: mmcts.2008.003640
- [48] Goldstein D, Moskowitz AJ, Gelijns AC, et al. Two-Year outcomes of surgical treatment of severe ischemic mitral regurgitation. *The New England Journal of Medicine* 2016;**374**:344-353
- [49] Grasso C, Ohno Y, Attizzani GF, et al. Percutaneous mitral valve repair with the MitraClip system for severe mitral regurgitation in patients with surgical mitral valve repair failure. *Journal of the American College of Cardiology*. 2014;**63**:836-838
- [50] Estévez-Loureiro R, Arzamendi D, Carrasco-Chinchilla F, et al. Usefulness of MitraClip for the treatment of mitral regurgitation secondary to failed surgical annuloplasty. *Revista Española de Cardiología (English Edition)* 2016;**69**:446-448
- [51] Grasso C, Capodanno D, Scandura S, et al. One- and twelve-month safety and efficacy outcomes of patients undergoing edge-to-edge percutaneous mitral valve repair (from the grasp registry). *American Journal of Cardiology*. 2013;**111**:1482-1487
- [52] Franzen O, Baldus S, Rudolph V, et al. Acute outcomes of MitraClip therapy for mitral regurgitation in high-surgical-risk patients: Emphasis on adverse valve morphology and severe left ventricular dysfunction. *European Heart Journal*. 2010;**31**:1373-1381
- [53] Paranskaya L, D'Ancona G, Bozdog-Turan I, et al. Residual mitral valve regurgitation after percutaneous mitral valve repair with the MitraClip system is a risk factor for adverse one-year outcome. *Catheterization and Cardiovascular Interventions*. 2013;**81**:609-617

- [54] Taramasso M, Maisano F, Latib A, et al. Clinical outcomes of MitraClip for the treatment of functional mitral regurgitation. *EuroIntervention*. 2014;**10**:746-752
- [55] Glower DD, Kar S, Trento A, et al. Percutaneous mitral valve repair for mitral regurgitation in high-risk patients: Results of the EVEREST II study. *Journal of the American College of Cardiology*. 2014;**64**:172-181
- [56] Ussia GP, Cammalleri V, Sarkar K, et al. Quality of life following percutaneous mitral valve repair with the MitraClip System. *International Journal of Cardiology*. 2012;**155**:194-200
- [57] Whitlow PL, Feldman T, Pedersen WR, et al. Acute and 12-month results with catheter-based mitral valve leaflet repair: The EVEREST II (Endovascular Valve Edge-to-Edge Repair) High Risk Study. *Journal of the American College of Cardiology*. 2012;**59**:130-139
- [58] Swaans MJ, Bakker ALM, Alipour A, et al. Survival of transcatheter mitral valve repair compared with surgical and conservative treatment in high-surgical-risk patients. *JACC: Cardiovascular Interventions*. 2014;**7**:875-881
- [59] Velazquez EJ, Samad Z, Al-Khalidi HR, et al. The MitraClip and survival in patients with mitral regurgitation at high risk for surgery: A propensity-matched comparison. *American Heart Journal*. 2015;**170**:1050-1059
- [60] Giannini C, Fiorelli F, De Carlo M, et al. Comparison of percutaneous mitral valve repair versus conservative treatment in severe functional mitral regurgitation. *American Journal of Cardiology*. 2016;**117**:271-277
- [61] Enriquez-Sarano M, Akins CW, Vahanian A. Mitral regurgitation. *Lancet*. 2009;**373**:1382-1394
- [62] Grayburn PA, Foster E, Sangli C, et al. Relationship between the magnitude of reduction in mitral regurgitation severity and left ventricular and left atrial reverse remodeling after mitraclip therapy. *Circulation*. 2013;**128**:1667-1674
- [63] Schmidt FP, Von Bardeleben RS, Nikolai P, et al. Immediate effect of the MitraClip® procedure on mitral ring geometry in primary and secondary mitral regurgitation. *European Heart Journal Cardiovascular Imaging*. 2013;**14**:851-857
- [64] Schueler R, Momcilovic D, Weber M, et al. Acute changes of mitral valve geometry during interventional edge-to-edge repair with the MitraClip system are associated with mid-term outcomes in patients with functional valve disease: Preliminary results from a prospective single-center study. *Circulation: Cardiovascular Interventions*. 2014;**7**:390-399
- [65] Seeburger J, Rinaldi M, Nielsen SL, et al. Off-pump transapical implantation of artificial neo-chordae to correct mitral regurgitation: The tact trial (transapical artificial chordae tendinae) proof of concept. *Journal of the American College of Cardiology*. 2014;**63**:914-919
- [66] Colli A, Manzan E, Rucinkas K, et al. Acute safety and efficacy of the NeoChord procedure. *Interactive CardioVascular and Thoracic Surgery*. 2015;**20**:575-581

- [67] De Bonis M, Lapenna E, Maisano F, et al. Long-Term results (≤ 18 years) of the edge-To-edge mitral valve repair without annuloplasty in degenerative mitral regurgitation implications for the percutaneous approach. *Circulation*. 2014;**130**:S19-S24
- [68] Schofer J, Siminiak T, Haude M, et al. Percutaneous mitral annuloplasty for functional mitral regurgitation: Results of the CARILLON mitral annuloplasty device european union study. *Circulation*. 2009;**120**:326-333
- [69] Maselli D, Guarracino F, Chiaramonti F, et al. Percutaneous mitral annuloplasty: An anatomic study of human coronary sinus and its relation with mitral valve annulus and coronary arteries. *Circulation*. 2006;**114**:377-380
- [70] Degen H, Schneider T, Wilke J, et al. Coronary sinus devices for treatment of functional mitral valve regurgitation. Solution or dead end? *Herz*. 2013;**38**:490-500
- [71] Siminiak T, Wu JC, Haude M, et al. Treatment of functional mitral regurgitation by percutaneous annuloplasty: Results of the TITAN Trial. *European Journal of Heart Failure*. 2012;**14**:931-938
- [72] Spoor MT, Geltz A, Bolling SF. Flexible versus nonflexible mitral valve rings for congestive heart failure: Differential durability of repair. *Circulation*. 2006;**114**:I67-71
- [73] Maisano F, La Canna G, Latib A, et al. First-in-man transseptal implantation of a surgical-like mitral valve annuloplasty device for functional mitral regurgitation. *JACC: Cardiovascular Interventions*. 2014;**7**:1326-1328
- [74] Maisano F, Taramasso M, Nickenig G, et al. Cardioband, a transcatheter surgical-like direct mitral valve annuloplasty system: Early results of the feasibility trial. *European Heart Journal*. 2016;**37**:817-825
- [75] Kay JH, Magidson O, Meihaus JE. The surgical treatment of mitral insufficiency and combined mitral stenosis and insufficiency using the heart-lung machine. *American Journal of Cardiology*. 1962;**9**:300-306
- [76] Siminiak T, Dankowski R, Baszko A, et al. Percutaneous direct mitral annuloplasty using the Mitralign Bident system: Description of the method and a case report. *Kardiologia Polska* 2013;**71**:1287-1292
- [77] Nickenig G, Schueler R, Dager A, et al. Treatment of chronic functional mitral valve regurgitation with a percutaneous annuloplasty system. *Journal of the American College of Cardiology*. 2016;**67**:2927-2936
- [78] Latib A, Ancona MB, Ferri L, et al. Percutaneous direct annuloplasty with cardioband to treat recurrent mitral regurgitation after MitraClip implantation. *JACC: Cardiovascular Interventions*. 2016;**9**:e191-e192
- [79] Abdelrahman N, Chowdhury MA, Al Nooryani A, et al. A case of dilated cardiomyopathy and severe mitral regurgitation treated using a combined percutaneous approach of MitraClip followed by CARILLON[®] mitral contour system. *Cardiovascular Revascularization Medicine*. 2016;**17**:578-581

- [80] Krishnaswamy A, Mick S, Navia J, et al. Transcatheter mitral valve replacement: A frontier in cardiac intervention. *Cleveland Clinic Journal of Medicine*. 2016;**83**:S10-S17
- [81] Ussia GP, Quadri A, Cammalleri V, et al. Percutaneous transfemoral-transseptal implantation of a second-generation CardiAQ™ mitral valve bioprosthesis: First procedure description and 30-day follow-up. *EuroIntervention*. 2016;**11**:1126-1131
- [82] Cheung A, Webb J, Verheye S, et al. Short-term results of transapical transcatheter mitral valve implantation for mitral regurgitation. *Journal of the American College of Cardiology*. 2014;**64**:1814-1819
- [83] Abdul-Jawad Altisent O, Dumont E, Dagenais F, et al. Initial Experience of transcatheter mitral valve replacement with a novel transcatheter mitral valve procedural and 6-Month Follow-Up results. *Journal of the American College of Cardiology*. 2015;**66**:1011-1019
- [84] Quarto C, Davies S, Duncan A, et al. Transcatheter mitral valve implantation. *Innovations: Technology & Techniques in Cardiothoracic & Vascular Surgery* 2016;**11**:174-178
- [85] Muller DWM, Farivar RS, Jansz P, et al. Transcatheter mitral valve replacement for patients with symptomatic mitral regurgitation. *Journal of the American College of Cardiology*. 2016;**69**:381-391
- [86] Dreyfus GD, Martin RP, Chan KMJ, et al. Functional tricuspid regurgitation: A need to revise our understanding. *Journal of the American College of Cardiology*. 2015;**65**:2331-2336
- [87] Taramasso M, Vanermen H, Maisano F, et al. The growing clinical importance of secondary tricuspid regurgitation. *Journal of the American College of Cardiology*. 2012;**59**:703-710
- [88] Nath J, Foster E, Heidenreich PA. Impact of tricuspid regurgitation on Long-Term survival. *Journal of the American College of Cardiology*. 2004;**43**:405-409
- [89] Topilsky Y, Nkomo VT, Vatury O, et al. Clinical outcome of isolated tricuspid regurgitation. *JACC: Cardiovascular Imaging* 2014;**7**:1185-1194
- [90] Porter A, Shapira Y, Wurzel M, et al. Tricuspid regurgitation late after mitral valve replacement: Clinical and echocardiographic evaluation. *Journal of Heart Valve Disease*. 1999;**8**:57-62
- [91] Kwak JJ, Kim YJ, Kim MK, et al. Development of tricuspid regurgitation late after left-sided valve surgery: A single-center experience with long-term echocardiographic examinations. *American Heart Journal*. 2008;**155**:732-737
- [92] Dreyfus GD, Corbi PJ, Chan KMJ, et al. Secondary tricuspid regurgitation or dilatation: Which should be the criteria for surgical repair? *Annals of Thoracic Surgery*. 2005;**79**:127-132
- [93] Rogers JH, Bolling SF. Surgical approach to functional tricuspid regurgitation: Should we be more aggressive? *Current Opinion in Cardiology*. 2014;**29**:1-7

- [94] Teman NR, Huffman LC, Krajacic M, et al. 'Prophylactic' tricuspid repair for functional tricuspid regurgitation. *Annals of Thoracic Surgery*. 2014;**97**:1520-1524
- [95] Kim Y-J, Kwon D-A, Kim H-K, et al. Determinants of surgical outcome in patients with isolated tricuspid regurgitation. *Circulation*. 2009;**120**:1672-1678
- [96] Taramasso M, Pozzoli A, Guidotti A, et al. Percutaneous tricuspid valve therapies: The new frontier. *European Heart Journal*. 2017; **38**:639-647
- [97] Rogers JH, Bolling SF. The tricuspid valve: Current perspective and evolving management of tricuspid regurgitation. *Circulation*. 2009;**119**:2718-2725
- [98] Navia JL, Nowicki ER, Blackstone EH, et al. Surgical management of secondary tricuspid valve regurgitation: Annulus, commissure, or leaflet procedure? *The Journal of Thoracic and Cardiovascular Surgery*. 2010;**139**:1473-1482.e5
- [99] Braun D, Nabauer M, Orban M, et al. Transcatheter treatment of severe tricuspid regurgitation using the edge-to-edge repair technique. *EuroIntervention*. 2017;**12**:e1837-e1844
- [100] Schofer J, Bijuklic K, Tiburtius C, et al. First-in-human transcatheter tricuspid valve repair in a patient with severely regurgitant tricuspid valve. *Journal of the American College of Cardiology*. 2015;**65**:1190-1195
- [101] Kuwata S, Taramasso M, Nietlispach F, et al. Transcatheter tricuspid valve repair toward a surgical standard: First-in-man report of direct annuloplasty with a cardio-band device to treat severe functional tricuspid regurgitation. *European Heart Journal*. 2017 Jan 10. pii: ehw660. doi: 10.1093/eurheartj/ehw660. [Epub ahead of print]
- [102] Schofer J. Transcatheter interventions for tricuspid regurgitation: Trialalign and Mitralign. *EuroIntervention*. 2016;**12**:Y119-Y120
- [103] Taramasso M, Nietlispach F, Zuber M, et al. Transcatheter repair of persistent tricuspid regurgitation after MitraClip with the TriCinch system: Interventional valve treatment toward the surgical standard. *European Heart Journal*. 2016 Dec 9. pii: ehw541. [Epub ahead of print]
- [104] Puri R, Rodés-cabau J, Heart Q, et al. Transcatheter interventions for tricuspid regurgitation: The FORMA Repair System. *Eurointervention* 2016;**12**:Y113-Y115