

We are IntechOpen, the world's leading publisher of Open Access books Built by scientists, for scientists

6,900

Open access books available

186,000

International authors and editors

200M

Downloads

Our authors are among the

154

Countries delivered to

TOP 1%

most cited scientists

12.2%

Contributors from top 500 universities



WEB OF SCIENCE™

Selection of our books indexed in the Book Citation Index
in Web of Science™ Core Collection (BKCI)

Interested in publishing with us?
Contact book.department@intechopen.com

Numbers displayed above are based on latest data collected.
For more information visit www.intechopen.com



Cardiogenic Shock Due to Coronary Artery Stent Thrombosis

Mustafa Yildiz, Dogac Oksen and Ibrahim Akin

Additional information is available at the end of the chapter

<http://dx.doi.org/10.5772/intechopen.68362>

Abstract

Stent thrombosis is an uncommon but serious complication that causes sudden death or myocardial infarction (MI). A large MI, especially with ST elevation, can cause cardiogenic shock and pose a significant incidence of morbidity and mortality. Largeness of ischemic territory is the main reason that causes cardiogenic shock. The fundamental treatment strategies are immediate coronary revascularization and perfusion support to avoid end organ damage with medically or mechanical in intensive care units. The prevention, incidences, mechanisms, management, and clinical impacts of cardiogenic shock discussed under this topic.

Keywords: cardiogenic shock, stent thrombosis, drug-eluting stent, bare-metal stent, bioabsorbable stent, treatment

1. Introduction

1.1. Stent thrombosis: incidence, pathophysiological mechanisms, technological developments

Percutaneous coronary interventions are the main treatment of coronary artery disease patients with target vessel stenting. In 1977, firstly, it was performed by Andreas Gruntzig; afterward in 1994, the Food and Drug Administration (FDA) approved the procedure. Nowadays, coronary stent use is more than 90% of the percutaneous coronary interventions. Since the start of revascularization of coronary arteries with percutaneous transluminal coronary angioplasty (PTCA), invasive cardiologists face with a fatal problem, stent thrombosis.

Today, invasive cardiologists have a lot of options between bare metal stents (BMSs), first and second generation of drug-eluting stents (DESs) and bioresorbable vascular stents (BVSs). The decision of which kind of stent is up to physicians and particular factors about patient and his/her clinics have an effect on the choice. Widespread use of stents for target vessel revascularization brings the problem of different rates of restenosis which has a percutaneous reintervention necessity [1]. The neo-endothelial coverage with proliferation and migration of vascular smooth muscle and proteoglycan deposition causes restenosis. Restenosis may occur mostly within the first 6–9 months after implantation, depending on type of strut and procedure. Drug released from DES inhibits the signal transduction pathways of proliferation of vascular smooth muscle cell and migration. DES delays reendothelialization and avoid from prothrombogenic events.

Bare metal stent implantation reduces the risk of restenosis more than 50% when compared to balloon angioplasty. However, BMS has still a risk of 20–30% restenosis in the following year after implantation. Restenosis mostly occurs in diabetic patients, small vessels, and long lesions. Currently, BMSs often used in shortening dual antiplatelet time after implantation. DES significantly reduces restenosis compared to BMS [2].

Stent thrombosis is the acute, completely thrombotic occlusion of the stented segment of coronary artery. The incidence has been reported in various studies about 0.5–2% for elective cases and up to 6% for the patients presented with acute coronary syndromes underwent PCI. Stent thrombosis causes ST elevation myocardial infarction (MI) in 70–80% cases. Major clinical impacts, high mortality rates, nearly 40%, make the issue nightmare of interventional cardiologists [3]. Stent thrombosis alters by the time event occurs with different mechanisms. Mostly, stent thrombosis occurs within 30 days after placement. Acute stent thrombosis becomes in 24 h, if any thrombosis occurs between 24 h and 30 days, defined as early stent thrombosis. These are arising from mechanical issues, failure of platelet adhesion aggregation suppression, persistence of slow coronary flow and prothrombotic constituents. Late stent thrombosis (up to 1 year) and very late stent thrombosis (after the first year) are results of delayed reendothelialization and neointimal coverage. Delay of neointimal restoration and ongoing vascular repair is particularly the effects of agents used in DES to prevent proliferation [4].

The first generation of DES, paclitaxel and sirolimus eluting stents, has an increased risk of late and very late stent thrombosis, as compared to BMS caused more delayed reendothelialization, impaired arterial healing and long lasting inflammation. However, in newer generation of DES, late stent thrombosis risks are similar with BMS, lower than first generation. Signalizations of inflammatory and thrombotic pathways are similar, and inflammation activates clotting cascade and enhances the platelet activation [5].

Binding of von Willebrand's factor with factor VIII, glycoproteins Ib and Ia/IIb and collagen assures platelet adhesion to stent struts. Platelets provide aggregation by glycoproteins Ib, IIb/IIIa, serotonin, and fibrinogen causes thrombosis. BMS thrombosis mostly occurs within the first 24 h after stent implantation, less often within 30 days. Similarly, DES thrombosis mostly occurs in 30 days, but in DES, stent thrombosis risk continues up to 5 years. Because of the delayed endothelialization and promoted inflammation, very late stent thrombosis more likely seen in DES rather than BMS. Despite all of these, the first generation of DES such as

paclitaxel—eluting stent, sirolimus—eluting stent is effective and reliable in use compared with BMS.

In the Swedish Coronary Angiography and Angioplasty Registry (SCAAR), 42,150 individuals underwent PCI with either BMS or DES. During 661-day follow-up, the rate of described stent thrombosis was 1.2%, and half of this was acute and subacute. The rates after the following year decrease to 0.3–0.4% per year constantly up to 3 years. First 6 months after stent implantation and onward, the risk for stent thrombosis was higher in DES compared with BMS (adjusted risk ratio, 2.02; 99% CI, 1.30–3.14). DES compared with BMS, initially, BMS demonstrated a higher risk of stent thrombosis, after the first months, stent thrombosis risk was higher with DES [6]. In the Bern-Rotterdam registry, the annual rate of stent thrombosis was 0.4–0.6% for up to 4 years in an 8146 patients who underwent percutaneous coronary interventions with either sirolimus-eluting stent or paclitaxel-eluting stent. Diabetes is an independent predictor of early stent thrombosis, whereas acute coronary syndrome, younger age, and paclitaxel-eluting stent implantation are associated with late stent thrombosis [7]. Use of new generation DES has significantly lower risk of restenosis and stent thrombosis though; triggers chronic vessel inflammation, fibrin deposition and cause medial cell loss, delay stent strut endothelialization therefore increase the risk of very late stent thrombosis [8].

Second-generation DES developed with more bioabsorbable and biocompatible polymers and thinner strut stent platforms, which reduce chronic inflammation similar with BMS but more effective than BMS also safer than first-generation DES with lower risk of late and very late stent thrombosis. The most recent innovation in stent technology was third generation bioabsorbable stents that after implantation polymers gradually degraded. Bioabsorbable stents are expensive in comparison with DES. In a meta-analysis of Palmerini et al. [9], data from 89 trials including 85,490 patients were analyzed. Bioabsorbable polymer-based stents were associated with superior clinical outcomes compared with BMS and first-generation DES and similar outcomes of cardiac death/MI, target vessel revascularization compared with second-generation DES. Real-world studies suggested an increased risk of mortality, MI and late stent thrombosis with first-generation DES compared to BMS, especially after discontinuation of dual antiplatelet therapy [10].

Bioresorbable stents with completely absorbable materials have some benefits over BMS and DES. These novel stents resolve the shortcoming of DES by enabling re-stent implantation to same region and restoration of vasomotor activity. Bioresorbable stents are associated with low revascularization rates which also have better short-term outcomes when compared with metallic stent technology. As there is a complete bioabsorption without any remnant material, late and very late stent thrombosis will be significantly less seen. Bioresorbable scaffolds liberate vessel walls from metallic stent material, therefore decrease late remodeling and luminal enlargement and save the vessels biomechanics property. Earlier complete resorption allows shortening dual antiplatelet treatment duration [11].

In a meta-analysis, 3738 patients in six trials underwent percutaneous coronary intervention with either everolimus-eluting bioresorbable vascular scaffold (n = 2337) or everolimus-eluting metallic stent (n = 1401) were included. Patients receiving bioresorbable vascular scaffolds

had a similar risk of target lesion revascularization (OR, 0.97 [95% CI, 0.66–1.43]; $p = 0.87$), target lesion failure (1.20 [0.90–1.60]; $p = 0.21$), MI (1.36 [0.98–1.89]; $p = 0.06$), and death (0.95 [0.45–2.00]; $p = 0.89$) when compared with metallic stent receivers. Bioresorbable vascular scaffold implanted group had a higher risk of stent thrombosis than metallic stent group (OR, 1.99 [95% CI, 1.00–3.98]; $p = 0.05$). The highest risk was between 1 and 30 days after implantation (3.11 [1.24–7.82]; $p = 0.02$). Bioresorbable scaffolds had similar rates necessity of revascularization; however, subacute stent thrombosis risk had increased [12].

Stent thrombosis is a main problem as a completely risk of MI and high fatality rates that has been stated almost 45%. After a stent implantation, dual antiplatelet therapy is prescribed as a routine in the following year. With the use of dual antiplatelet therapy, stent thrombosis declined approximately 1% but can be higher after stenting emergency cases or complex lesions [3]. Clinical, procedural, and lesion specific factors induce the development of stent thrombosis. Premature withdrawal of dual antiplatelet therapy still constitutes the majority [13]. Beside patients noncompliance, clopidogrel or acetylsalicylic acid resistance and hypercoagulation disorders predispose to its development. Further risk factors about clinical contain diabetes mellitus, congestive heart failure, renal failure, implantation during acute MI, previous brachytherapy. Lesion specific factors are long lesions, smaller vessels, multivessel disease, and bifurcation lesions. Persistent dissection, stent underexpansion, incomplete wall apposition, multiple stenting, overlapping stents, crush technique, residual flow defect, and sort of polymer materials are described as procedure-related risk factors [14].

1.2. Prevention of devastating effects of stent thrombosis

Aspirin and thienopyridines are anti-platelet agents and have different mechanism of action. They acquire extensive impact, and combination of both is essential to prevent stent thrombosis. Thienopyridine derivatives cause platelet inhibition through the P2Y₁₂ ADP receptor whose role is to activate the glycoprotein IIb/IIIa complex. Aspirin cause an irreversible cyclooxygenase inhibiting effect and restrains synthesis of thromboxane A₂.

In thrombus formation, platelets play critical role, and thus, an optimal dual antiplatelet therapy is essential preventing stent thrombosis [15]. Coating stents with cytotoxic material and polymers inhibit endothelialization, inflammation in vessel wall, and preliminary tissue factor activity. Nowadays, a pro-healing modality has been developed to achieve a natural cover of endothelium on stent surface by endothelial progenitor cells. A new approach is coating stents label with controlled releasing nitric oxide (NO) for the suppression or prevention of restenosis and thrombosis caused by implantation. NO containing liposomes control the releasing rate and prolong up to 5 days. In vitro cell studies, point NO enhances endothelial cell proliferation, while it significantly inhibits smooth muscle cell proliferation. NO-releasing stents with highly optimized release rate demonstrate improvement in arterial healing, inflammation, and neointimal thickening except thrombo-resistant effect [16].

CD133 and CD34 antibodies may be able to prevent thrombosis by promoting endothelial progenitor cells and accelerating endothelialization. The studies on novel coating strategy found that the stainless steel stents coated with vascular endothelial growth factor (VEGF) and anti-CD34 antibody less toxic on endothelial progenitor cells than single VEGF coating

or bare metals [17]. Anti-CD133 antibody-coated stents have superiority in capturing endothelial progenitor cells and accelerate re-endothelialization when compared with anti-CD34 [18]. Furthermore, usage of novel biodegradable stents might also contribute the effort given against the stent thrombosis [15].

In a multicenter retrospective observational study, among 2047 STEMI patients, 1123 (54.9%) of them were received post-procedural bivalirudin full dose infusion, while the other 924 (45.1%) received low doses (0.25 mg/kg/h) or null post-procedural infusion. Three acute stent thrombosis (0.3%) occurred in the group of none or low dose bivalirudin, while there was not any in the full-dose receiving group (0.3 vs 0.0%, $P = 0.092$). Full-dose bivalirudin infusion after PTCA procedure is safe and has protective effect against acute stent thrombosis [19].

1.3. Cardiogenic shock caused by stent thrombosis: definition, symptoms, predictors, and therapy

Cardiogenic shock is characterized by decreased end-organ perfusion due to cardiac dysfunction, and it is often caused by acute MI which may cause extensive damage of left ventricular myocardium or other mechanical complications such as free wall rupture, ventricular septal rupture, and papillary muscle rupture. It is a serious disorder with high mortality, aggressive and accurate approach increases the likelihood of treatment. The pathophysiological mechanism involves a vicious circle: ischemia causes myocardial dysfunction, which in turn aggravates myocardial ischemia (**Figure 1**). Cardiogenic shock contains three parameters: persistent hypotension (systolic blood pressure <80 – 90 mm Hg or mean arterial pressure <30 mm Hg) with severe reduction in cardiac index (<1.8 L min^{-1} m^{-2} without support or <2.0 – 2.2 L min^{-1} m^{-2} with support) and sufficient or elevated filling pressure (egg, left ventricular end-diastolic pressure >18 mm Hg, or right ventricular end-diastolic pressure >10 – 15 mm Hg) [20].

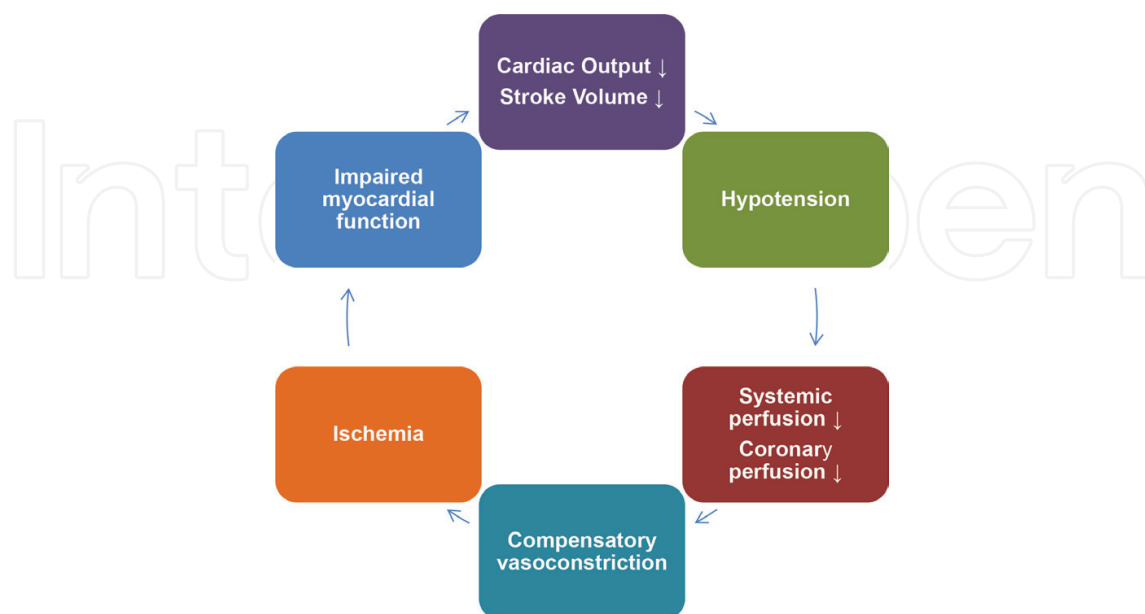


Figure 1. Vicious circle in cardiogenic shock.

Acute MI due to stent thrombosis may lead cardiogenic shock with severe ventricular dysfunction (**Figure 2**). Early revascularization such as thrombus aspiration with thrombectomy catheter and PTCA plays key role to improve the survival (**Figure 3** and **4A–F**).

1.4. Pathophysiology of cardiogenic shock due to stent thrombosis

Stent thrombosis occurs as a result of variety of factors inducing thrombogenesis, clinical, and anatomical variability. BMS complete endothelialization nearly 3–4 months, this returns with risk reduction of stent thrombosis. Antineoplastic stent material, hypersensitivity reaction, inflammatory response, and delayed endothelialization facilitate the risk of stent thrombosis in DES. Endothelial cells in the vessel lumen maintain vascular flow with providing a barrier to avoid aggregation and coagulation. The most frequent reason is early discontinuation of antiplatelet therapy. Mechanical factors, factors effecting coagulation cascade and response to medication, influence the risk of stent thrombosis. Evolution of intracoronary thrombus especially in acute coronary syndrome cases is related to high risk of stent thrombosis. Stent placement at injury sides increases the platelet deposition. At initial phase, the stent side covered with a thin highly platelet rich thrombus label. The neo-intimal structure mainly contains smooth muscle cells, and this occurs nearly in 6 weeks and may continue up to 12 weeks. In thrombus lesions, the elastic lamina layer is significantly thicker especially in plaque and stent area. Also, eosinophil density is apparently higher when compared to other lesions without stent [15]. Stent thrombus often ends off with ST elevation MI that can easily ruin the contraction of extensive myocardial tissue. This sudden power dissipation may break the hemodynamic stability and cause deep hypotension. As a vicious circle, hypotension reduces the coronary perfusion and enhances ischemia that result with hemodynamic collapse. Also, mechanical complications aggravate and facilitate clinical deterioration. Myocardial stunning and hibernating augment myocardial dysfunction. Increased ischemia leads the release of inflammatory mediators like interleukine-6 and cytokines thus brings barrier injuries and disrupts microcirculation. Low pressures of blood in vessels initiate multiple organ failure [20].

1.5. Cardiogenic shock caused by stent thrombosis: treatment and literature review

Thrombus aspiration has been associated with retrieving dense thrombus load away from coronary arterials to preserve myocardial performance by enhancing epicardial and microvascular

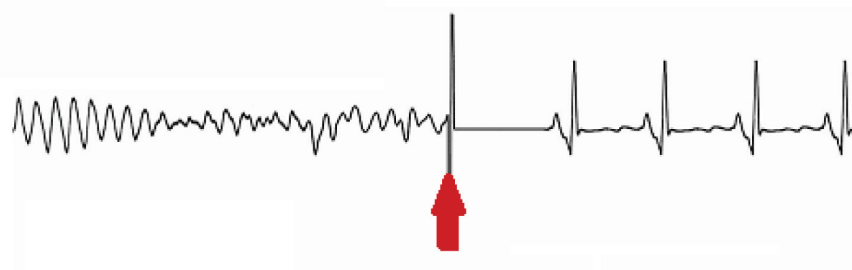


Figure 2. Ventricular fibrillation due to acute stent thrombosis. Successful defibrillation made in this patient (arrow).

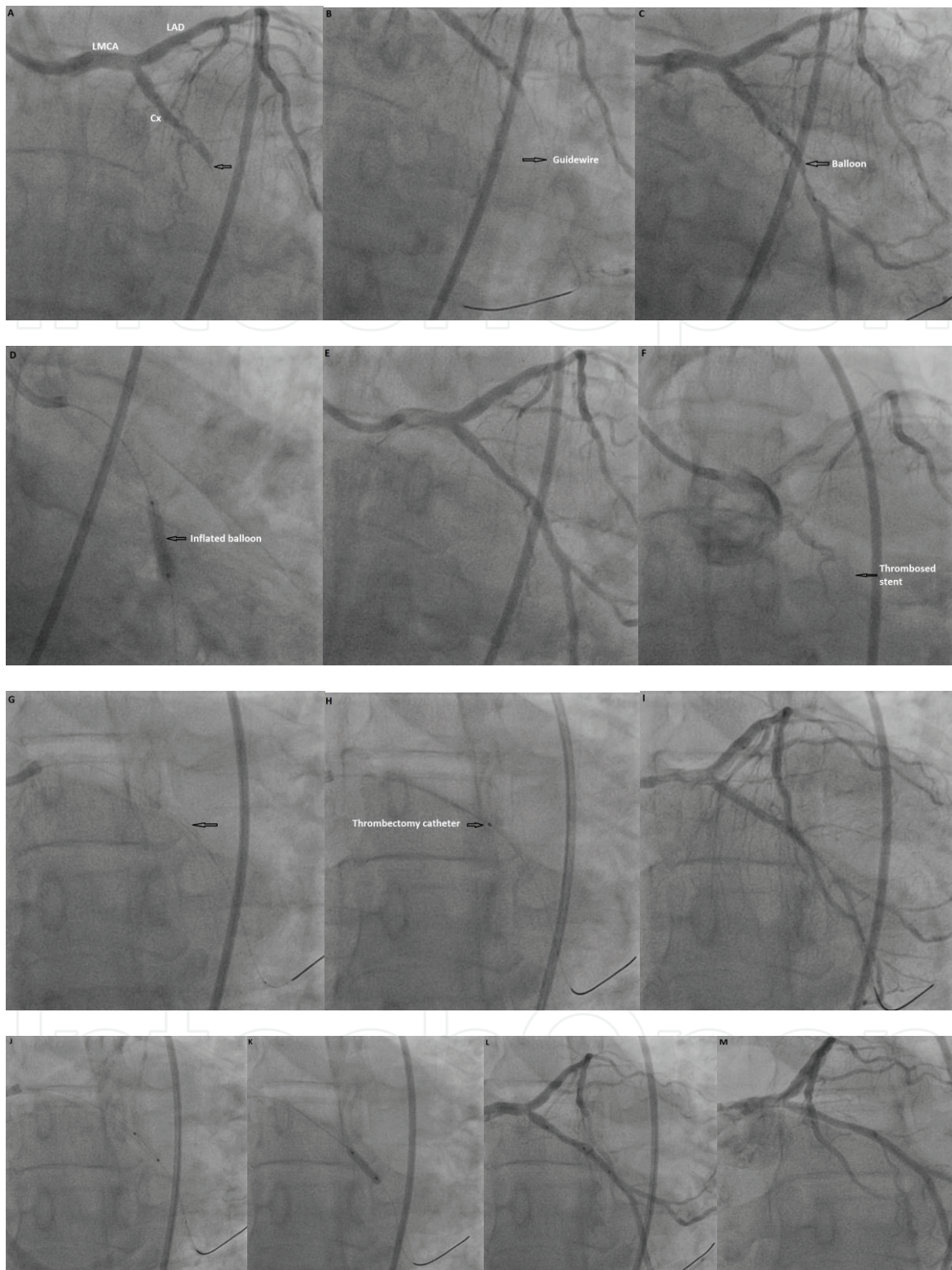


Figure 3. A. Total occlusion in Cx (arrow). B. Occlusion was passed with a guidewire (arrow). C. A coronary balloon was inflated in the occluded segment (arrow). D. The stent was implanted (arrow). E. The occluded segment was opened. F. Acute stent thrombosis of Cx stent (arrow). G. Occlusion was passed with a guidewire (arrow). H. Thrombus aspiration with thrombectomy catheter (arrow). I. Flow was reenabled. J, K. A coronary balloon was inflated in the stent. L, M. The stent was reopened. LMCA: left main coronary artery, LAD: left anterior descending coronary artery, Cx: circumflex artery.

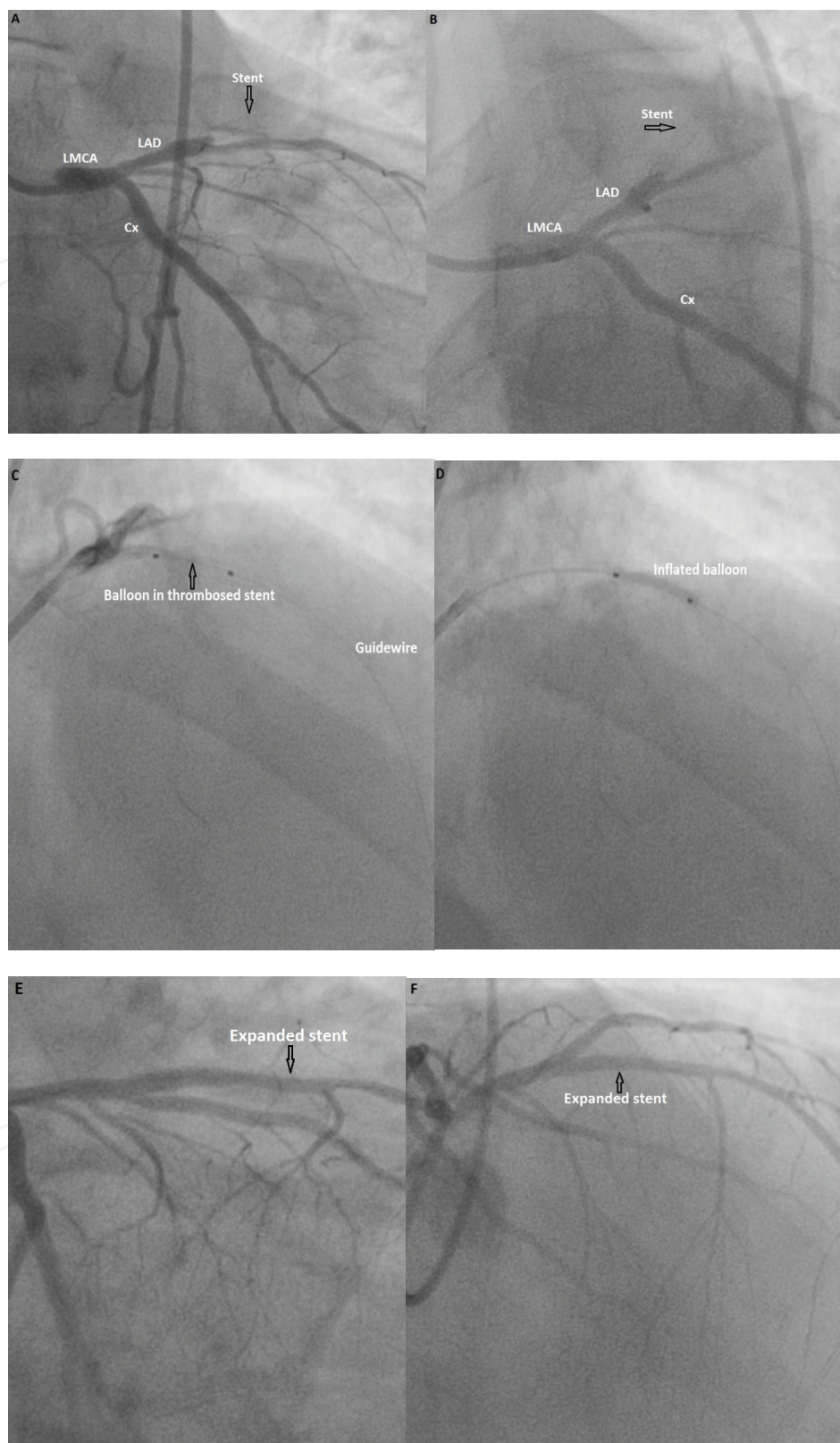


Figure 4. A, B. Total occlusion in stent (acute stent thrombosis) of mid-portion of left anterior descending coronary artery (arrow). LMCA: left main coronary artery, LAD: left anterior descending coronary artery, Cx: circumflex artery. C. Thrombosis was passed with a guidewire (arrow). D. A coronary balloon was inflated in the thrombosed stent (arrow). E, F. The stent was opened (arrows).

perfusion. A retrospective study systematically reviewed 13 stent thrombosis cases underwent angiography between January 2002 and May 2010. Thrombus aspiration performed 51 patients and 62 of them received conventional angiography. Distal embolization was significantly lower in thrombus aspiration group when compared with conventional PTCA. Mostly aspirated thrombus material included platelet and erythrocyte components at histopathologic analysis. Mortality rates in thrombus aspiration group lower but not statistically significant when compared with conventional angiography group (9.8 vs. 16% p : 0.351 at 30 days; 12 vs. 21% p : 0.220 at 1 year) [21].

Neurohormonal and cytokine systems contribute in the pathogenesis and clinical progress. As a result of hemodynamic abnormalities, hypoperfusion symptoms such as mental abnormalities, oliguria, anuria, and cool extremities can be seen. Mortality rates are between 10 and 80%, changes with demographic, initial clinical status, and hemodynamic factors. Early revascularization has a significant effect on survey [20, 22]. In the Arbeitsgemeinschaft Leitende Kardiologische Krankenhausärzte (ALKK) registry, in-hospital mortality of patients with acute myocardial infarction complicated by cardiogenic shock remained high, especially younger patient early invasive approach was the best strategy; however, in elderly patients are still a matter of debate [23].

National Cardiovascular Data Registry (NCDR) trial published data from 1,208,137 patients PCI procedures performed. In-hospital mortality was 1.4%, ranging from 0.2% within elective cases (45.1% of total PCI) to 65.9% among patients with shock and recent cardiac arrest (0.2% of total cases). Cardiogenic shock and emergent cases constitute the most predictive inpatient mortality. Intervention to chronic total occlusions, stent thrombosis, and left main lesions were the angiographic predictors of mortality [24].

Left ventricular ejection fraction (LVEF) is a prognostic indicator in cardiogenic shock. Picard et al. [25] performed echocardiography to 175 cardiogenic shock patients, 169 of them were suitable for analysis. Patients randomized into two arms: early revascularization or initial medical stabilization. In terms of echocardiography, two groups were similar. Mean LVEF was 31%, and moderate or greater mitral regurgitation was noted in 39.1%. Both short- and long-term mortality estimation according to echocardiographic indicators associated with initial left ventricular systolic function and mitral regurgitation.

Pulmonary arterial catheterization (PAC) is occasionally performed to confirm the diagnosis of cardiogenic shock. In hypotensive cases, clinical assessment of catheterization more reliable than echocardiography [26]. Performing pulmonary arterial catheterization was associated with lower short-term mortality [hazard ratio (HR) = 0.55, 95% confidence interval (CI), 0.35–0.86, p = 0.008] as well as lower mortality rates in the long-term follow-up (HR = 0.63, 95% CI 0.41–0.97, p = 0.035). However, according to subgroup analysis, the use of PAC has benefits in patients without acute coronary syndrome [26].

The main treatment to deal with cardiogenic shock is early revascularization. Patient's risk factors should be evaluated and closely followed up in case of any impending situation especially high heart rate and low blood pressure. Hypoperfusion induces catecholamine release but catecholamines increase myocardial oxygen demand so ischemia that causes

vicious circle. Using inotropic agents temporarily increase the cardiac output therewith peripheral perfusion but unfortunately cannot interrupt the vicious circle. Intra-aortic balloon pump is a temporary solution, improves circulation, peripheral perfusion, and relieve ischemia; however, this is not long-term complete solution. Calcium-sensitizing agents such as levosimendan have some beneficial effects including positive inotropy, increases in tissue perfusion, and anti-stunning and anti-inflammatory effects. In clinical trials, levosimendan improves symptoms, cardiac function, hemodynamics, and end-organ function [27].

The Should We Emergently Revascularize Occluded Coronaries for Cardiogenic Shock (SHOCK) trial enrolled 302 patients presented with cardiogenic shock due to left ventricular failure complicating MI. Patients were randomized in emergency revascularization (152 patients) or initial medical stabilization (150 patients) groups. Intra-aortic balloon counterpulsation was performed 86% patients. At 30 days, there was not any significant difference between revascularization and medical therapy groups (46.7 and 56%, respectively; $p = 0.11$). In revascularization group, the mortality rates were significantly lower than medication group at 6-month follow-ups (50.3 vs. 63.1%, respectively; $p = 0.027$). Interventional cardiologist should strongly considered early revascularization for the patients with MI complicated by cardiogenic shock [28].

Stent thrombosis is a rare disorder while depending on the extensity of ischemic surface, cardiogenic shock can be occur with ventricular dysfunction and become life-threatening. Cardiogenic shock mainly associated with the infarct-related territories. A study observed 92 ST segment elevated patients from January 2004 to March 2007 [29]. Of the total, 15.2% ($n = 14$) presented with cardiogenic shock and 85.7% ($n = 12$) were DES thrombosis. Coronary collateral growth is injured with DES which inhibits formation of cytokines, chemotactic proteins, and proliferation of vascular smooth muscle cells. Mean time passed from stent implantation procedure to stent thrombosis was 4.5 ± 7.6 months. 57% of the stent thrombosis occurred less than 30 days (early stent thrombosis). In 35.7% cases, MI related to left main or multivessel stent thrombosis. Before coronary angiography, all patients underwent intra-aortic balloon pump implantation [enlarges during diastole, prior to systole, and the balloon is deflated. Therefore, device augments diastolic pressure, reduces afterload, enhances coronary perfusion, and improves cardiac output [30]. In 80% of cases, revascularization was achieved, and 21% of cases, Impella LP 2.5 pump was used because of the low cardiac output persistence. In-hospital survival was 28.6%, and in the majority of cases, death occurred within the first 48 h. All the patients who survived in the acute phase were alive at 6 months visit and had significantly lower thrombus grade after wire passage ($p = 0.03$). However, they showed a higher rate of very late stent thrombosis, longer times from symptoms onset to revascularization, and higher TIMI flow grade both before and after percutaneous coronary intervention [29].

The IMPRESS trial compares the 30-day mortality rates of Impella CP and intra-aortic balloon pump devices in patients with severe shock complicating acute MI. Forty eight patients randomized to Impella CP ($n = 24$) or intra-aortic balloon pump ($n = 24$). At 30 days, mortality in patients treated with either intra-aortic balloon pump or Impella CP was similar (50 and 46%, respectively, $p = 0.92$). At 6 months, mortality rates for both Impella CP and intra-aortic balloon pump were 50% ($p = 0.923$) [31].

Mechanical circulatory support device implantation when in early cardiogenic shock manifestation, before inotropic and vasopressor agents or coronary intervention, is independently associated with decreased mortality rates. An immediate and adequate device assists cardiac support especially Impella or intra-aortic balloon pump and supplies reperfusion without any delay are the key points of improving survival of these patients under high risk [29].

Therapeutic hypothermia is beneficial of care after cardiac arrest. ISAR-SHOCK registry included 145 patients with acute MI, cardiogenic shock, and primary percutaneous coronary intervention, 64 (44%) patients received therapeutic hypothermia treatment. After 30-day follow-up, no significant differences were observed between both groups for mortality (42 vs. 44%, HR: 0.93, 95% CI [0.56–1.53], $p = 0.77$) and MI (6 vs. 6%, HR: 0.99 95% CI [0.27–3.7], $p = 0.99$). Three definite stent thrombosis were observed, and all of them belonged to therapeutic hypothermia group ($p = 0.09$). Therapeutic hypothermia does not have a negative effect in patients who receives clopidogrel or prasugrel [32].

2. Conclusion

Stent thrombosis is the nightmare of interventional cardiologists with fatal complications such as cardiogenic shock. It occurs rarely but has significantly high incidence of in-hospital mortality. Primary strategy should avoid all the predisposing factors. The main reason of cardiogenic shock due to stent thrombosis is extensiveness of infarct-related myocardial tissue. Early revascularization and intensive life support to supply cardiac output with inotropic agents and/or mechanical circulatory devices are the beneficial strategies.

3. In the future

Developments in stent technology and novel drugs inhibits platelet aggregation are decreasing the complications of stent implantation. By completely absorption of stent material in novel stents, dual anti-platelet therapy shortens and overall late stent thrombosis and revascularization rates decreases. Recently, endothelial progenitor cell-capturing stent technology contributes re-endothelialization. With the improvement in therapeutic modulations, incidences of cardiogenic shock due to stent thrombosis and mortality rates are in decreasing tendency.

4. Take home messages

- Choice of stent type depends on clinical properties, patient and angiographic features, and carries significant weight.
- Appropriate use of dual anti-platelet therapy is essential and should be explained to patient carefully.

- In case of any cardiogenic shock presentation, patient should promptly transport to catheterization laboratory for urgent revascularization.
- Revascularization is the keystone of cardiogenic shock management due to stent thrombosis.
- To maintain end organ perfusion, inotropic agents and mechanical circulatory support devices are the only bullets for surviving from cardiogenic shock.

Author details

Mustafa Yildiz^{1*}, Dogac Oksen¹ and Ibrahim Akin²

*Address all correspondence to: mustafayilldiz@yahoo.com

1 Department of Cardiology, Istanbul University Cardiology Institute, Istanbul, Turkey

2 First Department of Medicine, University Medical Center Mannheim, University of Heidelberg, Germany

References

- [1] Kastrati A, Mehilli J, Dirschinger J, Dotzer F, Schühlen H, Neumann FJ, Fleckenstein M, Pfafferoth C, Seyfarth M, Schömig A. Intracoronary stenting and angiographic results: strut thickness effect on restenosis outcome (ISAR-STEREO) trial. *Circulation*. 2001;**103**(23):2816-2821
- [2] Stolker JM, Cohen DJ, Kennedy KF, Pencina MJ, Arnold SV, Kleiman NS, Spertus JA; EVENT Investigators. Combining clinical and angiographic variables for estimating risk of target lesion revascularization after drug eluting stent placement. *Cardiovascular Revascularization Medicine*. 2016 Dec 18. pii: S1553-8389(16)30350-5
- [3] Iakovou I, Schmidt T, Bonizzoni E, Ge L, Sangiorgi GM, Stankovic G, Airolidi F, Chieffo A, Montorfano M, Carlino M, Michev I, Corvaja N, Briguori C, Gerckens U, Grube E, Colombo A. Incidence, predictors, and outcome of thrombosis after successful implantation of drug-eluting stents. *JAMA*. 2005;**293**(17):2126-2130
- [4] Nakazawa G, Finn AV, Joner M, Ladich E, Kutys R, Mont EK, Gold HK, Burke AP, Kolodgie FD, Virmani R. Delayed arterial healing and increased late stent thrombosis at culprit sites after drug-eluting stent placement for acute myocardial infarction patients: An autopsy study. *Circulation*. 2008;**118**(11):1138-1145
- [5] Croce K, Libby P. Intertwining of thrombosis and inflammation in atherosclerosis. *Current Opinion in Hematology*. 2007;**14**(1):55-61

- [6] Lagerqvist B, Carlsson J, Fröbert O, Lindbäck J, Scherstén F, Stenestrand U, James SK; Swedish Coronary Angiography and Angioplasty Registry Study Group. Stent thrombosis in Sweden: A report from the Swedish Coronary Angiography and Angioplasty Registry. *Circulation: Cardiovascular Interventions*. 2009;**2**(5):401-408
- [7] Wenaweser P, Daemen J, Zwahlen M, van Domburg R, Jüni P, Vaina S, Hellige G, Tsuchida K, Morger C, Boersma E, Kukreja N, Meier B, Serruys PW, Windecker S. Incidence and correlates of drug-eluting stent thrombosis in routine clinical practice. 4-year results from a large 2-institutional cohort study. *Journal of the American College of Cardiology*. 2008;**52**(14):1134-1140
- [8] Sarno G, Lagerqvist B, Fröbert O, Nilsson J, Olivecrona G, Omerovic E, Saleh N, Venetianos D, James S. Lower risk of stent thrombosis and restenosis with unrestricted use of 'new-generation' drug-eluting stents: A report from the nationwide Swedish Coronary Angiography and Angioplasty Registry (SCAAR). *European Heart Journal*. 2012;**33**(5):606-613
- [9] Palmerini T, Biondi-Zoccai G, Della Riva D, Mariani A, Sabaté M, Smits PC, Kaiser C, D'Ascenzo F, Frati G, Mancone M, Genereux P, Stone GW. Clinical outcomes with bio-absorbable polymer- versus durable polymer-based drug-eluting and bare-metal stents: Evidence from a comprehensive network meta-analysis. *Journal of the American College of Cardiology*. 2014;**63**(4):299-307
- [10] Eisenstein EL, Anstrom KJ, Kong DF, Shaw LK, Tuttle RH, Mark DB, Kramer JM, Harrington RA, Matchar DB, Kandzari DE, Peterson ED, Schulman KA, Califf RM. Clopidogrel use and long-term clinical outcomes after drug-eluting stent implantation. *JAMA*. 2007;**297**(2):159-168
- [11] Verheye S, Ormiston JA, Stewart J, Webster M, Sanidas E, Costa R, Costa JR Jr, Chamie D, Abizaid AS, Pinto I, Morrison L, Toyloy S, Bhat V, Yan J, Abizaid A. A next-generation bioresorbable coronary scaffold system: From bench to first clinical evaluation: 6- and 12-month clinical and multimodality imaging results. *JACC: Cardiovascular Interventions*. 2014;**7**(1):89-99
- [12] Cassese S, Byrne RA, Ndrepepa G, Kufner S, Wiebe J, Repp J, Schunkert H, Fusaro M, Kimura T, Kastrati. Everolimus-eluting bioresorbable vascular scaffolds versus everolimus-eluting metallic stents: A meta-analysis of randomised controlled trials. *Lancet*. 2016;**387**(10018):537-544
- [13] Schouten O, van Domburg RT, Bax JJ, de Jaegere PJ, Dunkelgrun M, Feringa HH, Hoeks SE, Poldermans D. Non cardiac surgery after coronary stenting: early surgery and interruption of antiplatelet therapy are associated with an increase in major adverse cardiac events. *Journal of the American College of Cardiology*. 2007;**49**:122-124
- [14] Cheneau E, Leborgne L, Mintz GS, Kotani J, Pichard AD, Satler LF, Canos D, Castagna M, Weissman NJ, Waksman R. Predictors of subacute stent thrombosis: Results of a systematic intravascular ultrasound study. *Circulation*. 2003;**108**:43-47

- [15] Yildiz M, Yildiz BS, Aydin E, Akin I. Stent thrombosis--myth and facts. *Cardiovascular & Hematological Disorders-Drug Targets*. 2014;**14**(3):231-234
- [16] Elnaggar MA, Seo SH, Gobaa S, Lim KS, Bae IH, Jeong MH, Han DK, Joung YK. Nitric oxide releasing coronary stent: A new approach using layer-by-layer coating and liposomal encapsulation. *Small*. 2016;**12**(43):6012-6023
- [17] Song C, Li Q, Zhang JC, Wang JP, Xue X, Wang G, Shi YF, Diao HY, Liu B. Study of a novel coating strategy for coronary stents: Evaluation of stainless metallic steel coated with VEGF and anti-CD34 antibody in vitro. *European Review for Medical and Pharmacological Sciences*. 2016;**20**(2):311-316
- [18] Wu X, Yin T, Tian J, Tang C, Huang J, Zhao Y, Zhang X, Deng X, Fan Y, Yu D, Wang G. Distinctive effects of CD34- and CD133-specific antibody-coated stents on re-endothelialization and in-stent restenosis at the early phase of vascular injury. *Regenerative Biomaterials*. 2015;**2**(2):87-96
- [19] Wang H, Liang Z, Li Y, Li B, Liu J, Hong X, Lu X, Wu J, Zhao W, Liu Q, An J, Li L, Pu F, Ming Q, Han Y. Effect of post-procedural full dose infusion of bivalirudin on acute stent thrombosis in patients with ST-elevation myocardial infarction undergoing primary percutaneous coronary intervention: Outcomes in a large real-world population. *Cardiovascular Therapeutics*. 2017 Jan 13. doi:10.1111/1755-5922.12251
- [20] Reynolds HR, Hochman JS. Cardiogenic shock: Current concepts and improving outcomes. *Circulation*. 2008;**117**:686-697
- [21] Mahmoud KD, Vlaar PJ, van den Heuvel AF, Hillege HL, Zijlstra F, de Smet BJ. Usefulness of thrombus aspiration for the treatment of coronary stent thrombosis. *American Journal of Cardiology*. 2011;**108**(12):1721-1727
- [22] Sleeper LA, Jacobs AK, LeJemtel TH, Webb JG, Hochman JS. A mortality model and severity scoring system for cardiogenic shock complicating acute myocardial infarction. *Circulation*. 2000;**102**(suppl II):II-795
- [23] Zeymer U, Vogt A, Zahn R, Weber MA, Tebbe U, Gottwik M, Bonzel T, Senges J, Neuhaus KL; Arbeitsgemeinschaft Leitende Kardiologische Krankenhausärzte (ALKK). Predictors of in-hospital mortality in 1333 patients with acute myocardial infarction complicated by cardiogenic shock treated with primary percutaneous coronary intervention (PCI); Results of the primary PCI registry of the Arbeitsgemeinschaft Leitende Kardiologische Krankenhausärzte (ALKK). *European Heart Journal*. 2004;**25**(4):322-328
- [24] Brennan JM, Curtis JP, Dai D, Fitzgerald S, Khandelwal AK, Spertus JA, Rao SV, Singh M, Shaw RE, Ho KK, Krone RJ, Weintraub WS, Weaver WD, Peterson ED; National Cardiovascular Data Registry. Enhanced mortality risk prediction with a focus on high-risk percutaneous coronary intervention: Results from 1,208,137 procedures in the NCDR (National Cardiovascular Data Registry). *JACC: Cardiovascular Interventions*. 2013;**6**(8):790-799

- [25] Picard MH, Davidoff R, Sleeper LA, Mendes LA, Thompson CR, Dzavik V, Steingart R, Gin K, White HD, Hochman JS; SHOCK Trial. Should we emergently revascularize Occluded Coronaries for cardiogenic shock. Echocardiographic predictors of survival and response to early revascularization in cardiogenic shock. *Circulation*. 2003;**107**(2): 279-284
- [26] Rossello X, Vila M, Rivas-Lasarte M, Ferrero-Gregori A, Sans-Roselló J, Duran-Cambra A, Sionis A. Impact of pulmonary artery catheter use on short- and long-term mortality in patients with cardiogenic shock. *Cardiology*. 2017;**136**(1):61-69
- [27] Nieminen MS, Buerke M, Cohen-Solál A, Costa S, Édes I, Erlikh A, Franco F, Gibson C, Gorjup V, Guarracino F, Gustafsson F, Harjola VP, Husebye T, Karason K, Katsytadze I, Kaul S, Kivikko M, Marenzi G, Masip J, Matskeplishvili S, Mebazaa A, Møller JE, Nessler J, Nessler B, Ntalianis A, Oliva F, Pichler-Cetin E, Pöder P, Recio-Mayoral A, Rex S, Rokyta R, Strasser RH, Zima E, Pollesello P. The role of levosimendan in acute heart failure complicating acute coronary syndrome: A review and expert consensus opinion. *International Journal of Cardiology*. 2016;**218**:150-157
- [28] Hochman JS, Sleeper LA, Webb JG, Sanborn TA, White HD, Talley JD, Buller CE, Jacobs AK, Slater JN, Col J, McKinlay SM, LeJemtel TH. Early revascularization in acute myocardial infarction complicated by cardiogenic shock. SHOCK Investigators. Should We Emergently Revascularize Occluded Coronaries for Cardiogenic Shock. *The New England Journal of Medicine*. 1999;**341**(9):625-634
- [29] Lilli A, Vecchio S, Chechi T, Vittori G, Giuliani G, Spaziani G, Consoli L, Giannotti F, Baldereschi G, Margheri M. Left ventricular support device for cardiogenic shock during myocardial infarction due to stent thrombosis: A single centre experience. *International Journal of Cardiology*. 2011;**148**(3):337-340
- [30] Cove ME, MacLaren G. Clinical review: Mechanical circulatory support for cardiogenic shock complicating acute myocardial infarction. *Critical Care*. 2010;**14**(5):235
- [31] Ouweneel DM, Eriksen E, Sjaauw KD, van Dongen IM, Hirsch A, Packer EJ, Vis MM, Wykrzykowska JJ, Koch KT1, Baan J, de Winter RJ, Piek JJ, Lagrand WK, de Mol BA, Tijssen JG, Henriques JP. Impella CP versus intra-aortic balloon pump in acute myocardial infarction complicated by cardiogenic shock: The IMPRESS trial. *Journal of the American College of Cardiology*. 2016 Oct 27. pii: S0735-1097(16)36767-5
- [32] Orban M, Mayer K, Morath T, Bernlochner I, Hadamitzky M, Braun S, Schulz S, Hoppmann P, Hausleiter J, Tiroch K, Mehilli J, Schunkert H, Massberg S, Laugwitz KL, Sibbing D, Kastrati A. The impact of therapeutic hypothermia on on-treatment platelet reactivity and clinical outcome in cardiogenic shock patients undergoing primary PCI for acute myocardial infarction: Results from the ISAR-SHOCK registry. *Thrombosis Research*. 2015;**136**(1):87-93

