

We are IntechOpen, the world's leading publisher of Open Access books Built by scientists, for scientists

6,900

Open access books available

186,000

International authors and editors

200M

Downloads

Our authors are among the

154

Countries delivered to

TOP 1%

most cited scientists

12.2%

Contributors from top 500 universities



WEB OF SCIENCE™

Selection of our books indexed in the Book Citation Index
in Web of Science™ Core Collection (BKCI)

Interested in publishing with us?
Contact book.department@intechopen.com

Numbers displayed above are based on latest data collected.
For more information visit www.intechopen.com



Neonatal Tumors

Kenneth W. Gow and Matthew Dellinger

Additional information is available at the end of the chapter

<http://dx.doi.org/10.5772/68070>

Abstract

Neonatal tumors encompass a group of heterogeneous neoplasms that demonstrate anatomic locations, behavior patterns, histologic features, and treatment responses that are distinct from neoplasms found in older children. The majority of neonatal tumors are benign, with malignant lesions accounting for only 2% of childhood cancers. However, histologically benign tumors can lead to detrimental effects on the fetus and newborn due to their size and location in relation to vital structures. An understanding of the incidence, appearance, and typical locations of neonatal tumors can provide important diagnostic information and guide treatment decisions. Although surgical intervention is the mainstay of therapy for many neonatal tumors, it is important to recognize that some lesions will regress spontaneously, whereas others may respond to noninvasive treatment modalities. In this chapter, we explore the epidemiology of neonatal tumors and provide a location-based classification schema to aid in diagnosis. A summary of the presentation, diagnosis, and management of the most common neonatal tumors is provided as well.

Keywords: neonatal tumors, sacrococcygeal teratoma, neuroblastoma, infantile hepatic hemangioma, mesenchymal hamartoma, ovarian cyst, cervical lymphatic malformation, rhabdomyosarcoma, congenital mesoblastic nephroma

1. Introduction

Neonatal tumors encompass a group of heterogeneous neoplasms that are diagnosed prenatally or within the first 30 days of life. Neonatal tumors demonstrate anatomic locations, behavior patterns, histologic features, and treatment responses that are distinct from neoplasms found in older children [1]. The preponderance of information regarding the epidemiology of neonatal tumors is provided through the experience of single institutions. The true incidence of these lesions is unknown, as studies do not always account for pregnancies with a prenatally diagnosed mass that end in stillbirth, miscarriage, or early termination of pregnancy.

Most solid neoplasms identified in neonates are benign [2]. The incidence of a malignant tumor is 1 in every 12,500–27,500 live births, accounting for 2% of all childhood cancers [1]. Distinguishing between benign and malignant neoplasms can prove to be challenging in this group of patients. The features of a tumor that denote malignancy in adults, such as high nuclear-cytoplasmic ratio, high mitotic rate, and anaplasia, may be present in benign lesions in children and neonates [3]. Neonatal tumors are also unique in that they arise from embryonic and immature tissue as a result of intrinsic dysfunction of cellular growth and proliferation [3, 4]. As opposed to adult tumors, environmental exposures are believed to play little to no role in tumorigenesis [4]. Some malignant lesions have minimal potential for invasion or metastasis, while histologically benign lesions can be lethal due to their size and location.

Although less than 10% of childhood cancers arise in the setting of a cancer predisposition syndrome, any neonatal tumor should raise concern for this possibility [5]. The presence of associated congenital anomalies, multifocal or bilateral disease, and cancer in close relatives is suggestive of an underlying cancer predisposition syndrome [6]. Several specific types of tumors, including retinoblastoma, adrenocortical carcinoma, pleuropulmonary blastoma, hepatoblastoma, and Wilms' tumor, show a strong association with a cancer predisposition syndrome [5]. Since the presence of genetically derived lesions can have implications for these children and their family members, genetic counseling and testing should be offered.

2. Diagnosis

A thorough history and physical examination are paramount in the evaluation of a newborn. However, many anomalies can be detected prior to birth. The ability to diagnose neoplasms in utero has evolved significantly with improvement in imaging modalities. Fetal ultrasonography, magnetic resonance imaging (MRI), and echocardiography offer physicians the opportunity to diagnose a variety of congenital diseases in the prenatal period [7–9]. Ultrasonography is a critical component of the prenatal obstetric evaluation and is currently the standard of care. Prenatal ultrasound provides vital information regarding gestational age, number of fetuses, fetal health, and the presence of congenital anomalies [9]. Ultrasound and MRI are preferred because they avoid the damaging effects of ionizing radiation.

For decades, ultrasonography has been the principal imaging modality for prenatal diagnosis of fetal anomalies [10]. The benefits of ultrasound are numerous, including wide availability, low cost, noninvasiveness, and the ability, to provide real-time evaluation of the fetus. One shortcoming of ultrasound is that results are operator dependent and can vary with the experience and expertise of the examiner [11]. In a systematic review of ultrasound for fetal assessment in early pregnancy, Bricker et al. [12] determined the overall sensitivity for detection of fetal anomalies to be 44.7%. However, the sensitivities of the included studies showed great variability, ranging from 15 to 85.3%. In addition to operator experience, gestational age, anomaly type, and equipment quality impact the accuracy of screening prenatal ultrasound [12].

In the past two decades, magnetic resonance imaging (MRI) has become increasingly utilized as an adjunct to ultrasound in the evaluation of fetal and neonatal anomalies [8, 10, 13].

One driving force behind this phenomenon is the development of ultrafast MRI, which limits fetal motion artifact and does not require maternal-fetal sedation [11]. The greatest utility of MRI appears to occur in cases where sonographic findings are equivocal or further diagnostic information is desired [11, 14, 15]. MRI is also particularly useful in illustrating anatomic relationships between neoplasms and adjacent structures, characterizing intracranial and soft tissue lesions, in cases of oligohydramnios and in cases of maternal obesity [11, 14, 15].

In the most recent Guidelines for Diagnostic Imaging in Pregnancy and Lactation, the American College of Obstetricians and Gynecologists states that there is no evidence of harm from tissue heating, acoustic damage, or teratogenesis when using MRI in pregnancy [16]. However, one issue that merits discussion is the use of gadolinium contrast dye to enhance fetal imaging. In practice, gadolinium is administered as a gadolinium-chelate molecule that is water-soluble and can cross the placenta into fetal circulation. Following filtration and excretion by the fetal kidneys, these molecules can accumulate in amniotic fluid with the ability to release potentially toxic gadolinium ions [17]. Although the effect of free gadolinium ions on the fetus is unknown, the current recommendation is to abstain from the routine use of MRI contrast agents unless the benefits can be shown to clearly outweigh this theoretical risk [17].

The diagnosis of a neonatal tumor has a profound emotional impact on a family and raises questions about accuracy of diagnosis, prognosis, treatment options, and long-term outcomes [18]. While technological improvements in imaging modalities have led to better sensitivity in diagnosing congenital anomalies, the false-positive rate is far from negligible [19]. Care should be taken in making definitive statements about diagnosis and prognosis on prenatal imaging as normal anatomic variants can have the appearance of a neoplastic process and some lesions will regress spontaneously. Conversely, sonographic findings of polyhydramnios, fetal hydrops, hepatosplenomegaly, and placentomegaly should raise suspicion for an undiagnosed tumor.

Finally, having diagnostic imaging that points to anomalies will allow the care team to have prenatal discussions and do important planning. Depending on all tests done, the parents should be offered possible diagnoses, complications, and outcomes. However, one needs to be guarded with prognostication, and consideration for termination of the pregnancy must be very carefully made including all knowns and unknowns. Assuming that the plans are for delivery, early diagnosis will allow for planning around the delivery; the location of the birthing center (closer to home vs. in a maternal-neonatal center), the means of birth (vaginal vs. Cesarean section vs. ex utero intrapartum treatment (EXIT)), the personnel required for the birth aside from those needed to care for the mother (neonatologist, pediatric anesthesiologist, pediatric otolaryngologist, pediatric general surgeon, pediatric cardiothoracic surgeon), and logistics with regard to coordination of the team including diagnostic and operative services.

3. Anatomic considerations/locations

Neonatal tumors represent a varied group of neoplasms that are discovered in multiple locations throughout the body (**Figure 1**). The diversity observed is not surprising since these lesions arise

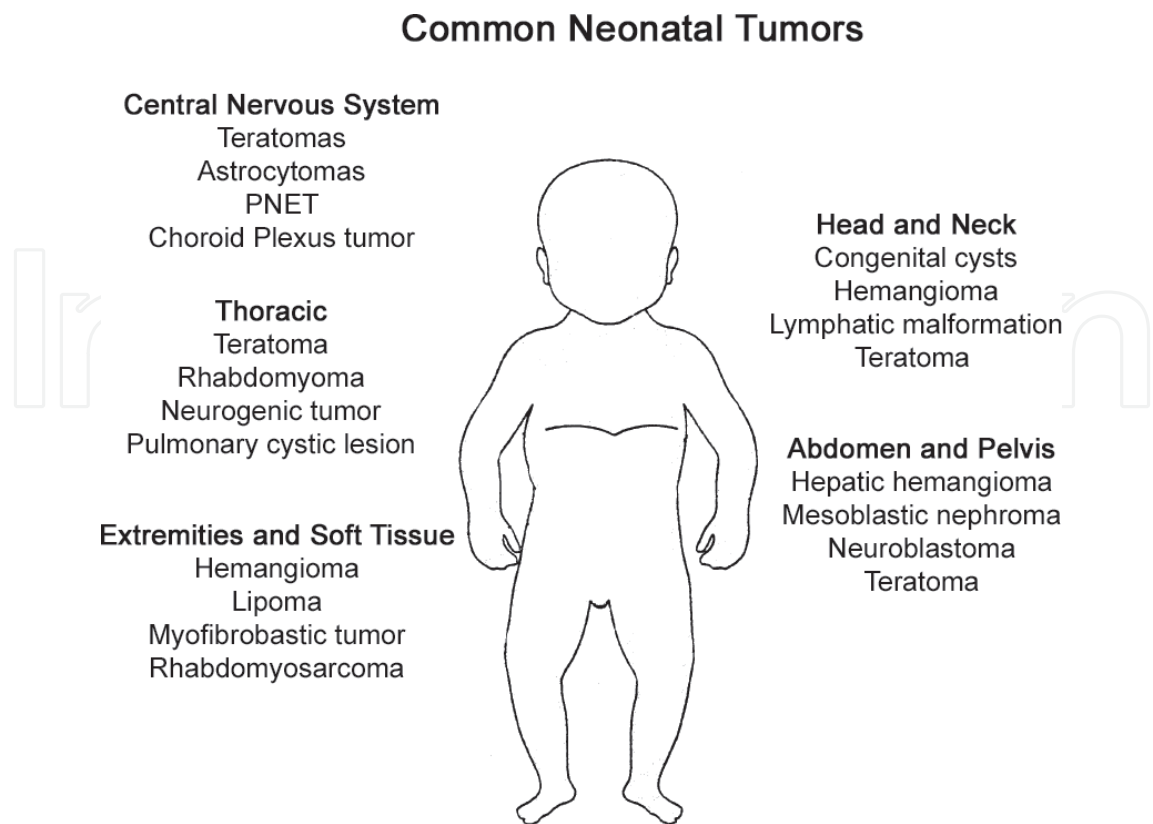


Figure 1. Common neonatal tumors based on location.

from abnormalities in fetal and neonatal development. Teratomas, particularly sacrococcygeal teratomas, are the most common neonatal tumor [1, 20, 21]. Neuroblastoma is the second most common neoplasm in neonates and the leading cause of malignancy in this group of patients. In order to decrease frequency, soft tissue tumors, central nervous system (CNS) tumors, leukemia, and renal tumors are the next most common tumor types recognized [1, 20, 21]. **Table 1** provides a brief summary of the most frequently encountered neonatal tumors. Knowledge of the incidence, appearance, and typical locations of these lesions can provide important diagnostic

Type	Percentage
Extracranial teratoma	24–30%
Neuroblastoma	23–30%
Soft tissue tumors	8–12%
Leukemia	6–12%
CNS tumors	6–10%
Renal tumors	5–7%
Hepatic tumors	5%
Cardiopulmonary tumors	<3%

Table 1. Distribution of commonly occurring neonatal tumors [1, 18, 20, 21].

information. In particular, the location of the lesion gives a wealth of information regarding the differential diagnosis. The following discussions provide a location-based review of common neonatal tumors, which is intended to provide the clinician a basis to create a differential diagnosis to plan for management. Later, specific histologic diseases will be presented to allow tailoring of therapy.

4. Central nervous system

Primary central nervous system (CNS) neoplasms are the most common solid tumor in childhood and the leading cause of cancer death in this group of patients [22]. Fortunately, this is a rare entity with an estimated incidence of 5.57 cases per 100,000 children between the ages of 0 and 19 [23]. In neonates, CNS tumors are the fifth most common solid malignancy, which occur less frequently than lesions found in older children. Brain tumors in fetuses and neonates are unique in that they are often supratentorial, while lesions in older children are typically infratentorial [24]. The rarity of neonatal brain tumors and the absence of a national pediatric CNS cancer registry make it difficult to ascertain a true incidence [25].

In a retrospective review of 250 cases of perinatal brain tumors, Isaacs [24] found that the most common tumors were teratomas (29.6%), astrocytomas (18.8%), primitive neuroectodermal tumors (13.2%), and choroid plexus tumors (13.2%). Those children presenting with choroid plexus tumors, low-grade astrocytomas, and gangliogliomas had the best survival, while intracranial teratomas and neuroectodermal tumors exhibited the worst prognosis [24]. The 5-year survival rate for neonatal brain tumors, regardless of treatment modality, is 23–36% [25]. The management of these patients includes surgical resection, chemotherapy, and irradiation, although any treatment decision should be coordinated through a multidisciplinary approach. Regardless of the histologic subtype and associated prognosis, the identification of a neonatal brain tumor is a devastating and life-altering experience for families.

5. Head and neck

Multiple conditions lead to the development of masses occurring in the head and neck of pediatric patients. The differential diagnosis is extensive and includes a variety of congenital, inflammatory, benign, and malignant lesions [26]. The vast majority of these lesions are benign. According to a comprehensive, 5-year review of 445 pediatric neck masses at Children's Hospital of Philadelphia, the most frequent lesions were congenital in origin (55%), followed by inflammatory masses (27%), malignant neoplasms (11%), and benign neoplasms (3%) [27]. Inflammatory lesions likely account for the most common pediatric neck masses but often resolve with conservative therapy, obviating the need for biopsy or excision [26]. The incidence and distribution of head and neck masses in the neonatal period are not as well defined.

The most common congenital head and neck lesions are branchial cleft, thyroglossal duct, and dermoid cysts. Although less common, vascular masses, lymphatic malformations, and

teratomas deserve special consideration secondary to the potential to cause detrimental effects on the developing fetus and newborn. Highly vascular lesions can lead to high-output cardiac failure and hydrops fetalis. Fluid accumulation in lymphatic malformations and the nearby tissues can also lead to fetal hydrops. Mass effect and extrinsic compression from certain lesions have the potential to cause life-threatening airway obstruction as well as atypical development of adjacent structures. Cervical lymphatic malformations and cervical teratomas, two lesions responsible for these physiologic disturbances, will be discussed in greater detail later in this chapter.

Cervical vascular masses include congenital and infantile hemangiomas. An important distinction to make is that vascular malformations and congenital hemangiomas are present at birth, grow concurrently with the child, and do not involute. Vascular tumors develop in the neonatal period and demonstrate a proliferative phase followed by involution [28]. Infantile hemangiomas occur in up to 4–5% of newborns [29]. Infantile hemangiomas arise following birth, proliferate for a variable amount of time, and ultimately involute. In contrast, congenital hemangiomas proliferate in utero and are fully developed at birth. These masses can be subdivided into rapidly involuting and noninvoluting types. Congenital hemangiomas are rare, accounting for only 3% of all hemangiomas [30].

Malignant head and neck lesions are rarely diagnosed in neonates. Lymphomas are the most common head and neck malignancy in children, with 60% of these tumors being classified as non-Hodgkin's lymphoma and the remaining 40% classified as Hodgkin's lymphoma [31]. Excisional biopsy is usually necessary to provide adequate tissue to confirm the diagnosis. Following diagnosis, a multidisciplinary approach is recommended for appropriate staging and treatment [31]. Neuroblastoma is another malignancy that can be found in the head and neck of neonates. Typically, these are metastatic lesions as primary cervical neuroblastoma accounts for only 5% of neonatal neuroblastoma [32]. Some children may have a concomitant Horner's syndrome secondary to compression of the cervical sympathetic chain. Treatment of neuroblastoma is also conducted via a multidisciplinary approach, with lesions diagnosed prenatally having a better prognosis than those identified following birth [32]. Other neonatal head and neck cancers include salivary gland malignancies, thyroid cancer, and nasopharyngeal carcinoma, each of which is exceedingly rare in this population.

6. Thoracic

The differential diagnosis of fetal and neonatal thoracic tumors can be narrowed significantly with an understanding of their incidence and common locations. One useful method for organizing these tumors is to differentiate between mediastinal, pleural, and pulmonary neoplasms.

The anterior mediastinum includes the region between the sternum and pericardium below the thoracic inlet. The thymus, portions of the thyroid gland, and nodal tissue serve as potential sites for tumorigenesis. In a retrospective review of 534 fetuses and neonates diagnosed with teratomas, Isaacs [33] found that 2.6% of these masses occurred in the mediastinum. Teratomas that do occur in this region are usually located in the anterior mediastinum [34]. Sonographic

identification of calcifications can help differentiate mediastinal teratomas from congenital pulmonary airway malformations and pulmonary sequestration [35]. Large mediastinal teratomas have the potential to cause lethal sequelae for the fetus and newborn. Polyhydramnios and preterm labor may develop from esophageal obstruction. High-output cardiac failure secondary to solid lesions with high vascularity can lead to fetal hydrops and intrauterine death. Perinatal decompensation and death are risks associated with intrathoracic airway obstruction. Although the thymus is included in the anterior mediastinum, thymomas are exceptionally rare in children, with most of the published cases being limited to case reports and retrospective reviews. Thyroid neoplasms and lymphoma are also extremely rare in this group of patients.

The middle mediastinum encompasses the heart and pericardium, great vessels, tracheal bifurcation, and phrenic nerves. Primary cardiac tumors are very uncommon in the fetus and neonate [36]. Of the primary cardiac tumors that occur in these patients, nearly all of them are histologically benign [37, 38]. Rhabdomyomas account for the majority of these lesions [36–38]. Fibromas, myxomas, and teratomas represent additional benign cardiac lesions with rare occurrence. Pericardial-based teratomas are also exceedingly rare. Based on their size and location, middle mediastinal tumors can have a number of detrimental physiologic effects. Dysrhythmias, impairment of cardiac function, and great vessel compression may result in fetal or neonatal demise without timely intervention.

The posterior mediastinum is bound by the pericardium and thoracic vertebrae and extends from the sternal notch inferiorly to the diaphragm. The esophagus, descending thoracic aorta, azygos veins, thoracic duct, and neural tissue are the key components of this region. Nearly all of the tumors arising in the posterior mediastinum in children are neurogenic in origin. Neurogenic tumors are named according to the type of neural tissue from which they originate. Neoplasms that arise from the sympathetic chain reflect a continuum of cellular differentiation and maturation [39]. Ganglioneuromas are benign, fully differentiated, and arise from mature Schwann and ganglion cells. These are the most common posterior mediastinal masses in children [39]. Ganglioneuroblastomas are malignant tumors of intermediate differentiation and contain both mature and immature elements of ganglion cells [39]. Neuroblastomas are also malignant tumors that are derived from immature, undifferentiated ganglion cells [39]. Neuroblastoma is the most common malignancy and second most common tumor in neonates, with approximately 5% arising in the posterior mediastinum [32]. Additional tumors include neurofibroma, neurilemoma, neurosarcoma, and paraganglioma, all of which are uncommon in neonates.

Pulmonary lesions diagnosed prenatally or in the newborn are rarely true neoplasms. The most commonly identified abnormalities are congenital pulmonary malformations, intra- and extralobar pulmonary sequestrations, and congenital lobar emphysema. Pleuropulmonary blastoma is a very rare, aggressive pulmonary malignancy. Although uncommon, it is the primary pulmonary malignancy presenting in childhood with up to 94% of cases being diagnosed in children 6 years of age and younger [40]. Type I and II pleuropulmonary blastomas possess cystic components, which can lead to misdiagnosis as benign lesions. Since pleuropulmonary blastoma is rare and over 90% of pulmonary cystic lesions in children are benign, surveillance may be an appropriate strategy with the knowledge that the emergence of solid components in the lesion warrants surgical resection [40].

7. Abdominal/retroperitoneal/pelvic

Masses discovered in the neonatal abdominal cavity, retroperitoneum, and pelvis represent a very diverse group of pathologies as would be expected based on the tissue types and organs in this region. These lesions range from small incidentally discovered masses to those occupying an entire body cavity, from benign to malignant and from purely cystic to solid neoplasms [41]. Hepatic lesions are the most common intra-abdominal neonatal tumors, while neuroblastoma and teratoma are the most common retroperitoneal and pelvic masses, respectively.

Hepatic tumors encompass a variety of benign and malignant lesions, representing only 5% of neonatal tumors. Most neonatal liver tumors are benign and discovered as an asymptomatic abdominal mass or identified on prenatal imaging [5]. In a retrospective review of 194 cases of fetal and neonatal hepatic tumors, Isaacs [42] identified hemangioma (60.3%), mesenchymal hamartoma (23.2%), and hepatoblastoma (16.5%) as the three primary tumor types. Hepatoblastoma represents the most common primary hepatic malignancy in this patient population. Serum alpha-fetoprotein is elevated in nearly half of neonates with hepatoblastoma; however, serum levels may remain elevated for several months following birth in children with benign hepatic masses or in the absence of hepatic masses [43]. Surgical resection is the primary treatment modality for hepatoblastoma with chemotherapy typically reserved for children with unresectable lesions or metastatic disease. Newborns presenting with congenital hepatoblastoma appear to have similar survival when compared to older children with similar stages of disease [43].

Renal tumors account for approximately 5–7% of neonatal tumors. Non-neoplastic pathologies, such as hydronephrosis and renal cystic disease, are far more prevalent than true neoplasms, accounting for up to 40% of neonatal abdominal masses [44]. The most common neonatal renal neoplasm is congenital mesoblastic nephroma (CMN), followed in frequency by Wilms' tumor, rhabdoid tumor, and clear cell sarcoma [44]. Juxtarenal masses are also part of the differential diagnosis with neuroblastoma being the most common of these lesions.

Although prenatal ultrasound is widely used, it is estimated that only 15% of renal masses are diagnosed prenatally [45]. Of those lesions not diagnosed via fetal ultrasound, nearly 50% are identified during routine physical examination [45]. Mesoblastic nephroma is rarely diagnosed following the first 3 months of life, while it is uncommon for Wilms' tumor to be diagnosed prior to 6 months of age [41]. Mesoblastic nephroma may be differentiated from other masses by the presence of a "ring sign" or anechoic circle surrounding the mass on sonography [46]. The optimal treatment for neonatal renal masses is surgical resection. Similar to hepatic lesions, chemotherapy is reserved for malignant lesions that are unresectable or metastatic at the time of diagnosis.

Teratomas are the most common neonatal tumors and the most prevalent pelvic neoplasms. In contrast, neonatal testicular tumors are rarely encountered in clinical practice. The tumors that do occur are usually testicular germ cell tumors such as teratomas and yolk sac tumors [47]. Diagnosis typically occurs after parents or clinicians palpate a testicular mass. Ultrasound examination distinguishes between intra- and extratesticular pathology. Yolk sac tumors are

the most common testicular malignancy in children, although most masses are benign. Serum alpha-fetoprotein (AFP) is a useful adjunct in the diagnosis of testicular tumors as it is elaborated by nearly 90% of yolk sac tumors in childhood [48]. However, measuring AFP levels is less reliable in newborns as they can physiologically remain elevated for up to 1 year after birth in the absence of underlying pathology. Since most of these lesions are benign, some tumors can be excised with a testicle-sparing approach [49]. In the event that a malignancy is identified on intraoperative frozen section, radical orchiectomy is required.

Ovarian enlargement can result from a variety of pathologies including ovarian cysts, ovarian torsion, and benign and malignant neoplasms [50]. Fortunately, true neonatal ovarian masses are infrequently seen in practice. Many lesions are identified on prenatal imaging, although some children present with palpable abdominal or groin masses, endocrine abnormalities, or ambiguous genitalia and congenital anomalies [50]. The majority of fetal and neonatal ovarian masses are cystic in nature. Management of ovarian cysts includes observation for simple lesions and surgical excision for larger, more complex lesions [41]. Preservation of functional ovarian parenchyma is the foundation of management.

8. Extremities and soft tissue

Soft tissue tumors comprise a heterogeneous group of benign and malignant neoplasms that represent 8–12% of neonatal tumors [1, 20, 21]. Soft tissue tumors are a rare entity in neonates, and the true incidence is unknown. There are a wide variety of benign tumors, including vascular malformations, lipomas, lipoblastomas, and fibroblastic tumors.

Head and neck hemangiomas are the most common benign soft tissue tumors in neonates. Lipomas consist of a group of widely distributed fatty tumors that are composed of mature adipocytes with a histologic appearance identical to normal fat [51]. Lipomas are classified based on their depth, with superficial lesions being much more common than deep lesions, which are located beneath the superficial fascia [51]. Lipoblastomas are rare, benign, rapidly growing tumors that arise from embryonic white fat and typically occur on the trunk and limbs [52]. The treatment of lipomas and lipoblastomas is usually complete excision, although the extent of resection should take functional and cosmetic outcomes into consideration. Fibroblastic and myofibroblastic tumors of intermediate prognosis represent benign lesions that display locally aggressive behavior with little to no propensity to metastasize [53]. Surgical resection remains the mainstay of treatment, yet a multidisciplinary approach is often necessary as radical resection of large, invasive lesions can lead to significant disfigurement and disability [53].

In infants, rhabdomyosarcoma (32.8%) is the most common malignant soft tissue tumor, followed in frequency by infantile fibrosarcoma (24.5%) and rhabdoid tumors (14.2%) [53]. Overall, malignant soft tissue tumors are rare in neonates. Rhabdoid tumors represent rare, aggressive malignancies that typically occur not only in the kidney and brain but can also be found in various soft tissue locations [54]. These tumors are relatively chemoresistant, demonstrate early tumor recurrence following surgical resection, and portend an overall poor prognosis [54].

9. Birth considerations

Certain neonatal tumors warrant special consideration regarding fetal delivery and perinatal management. Neoplasms that compromise the fetal airway represent an immediate threat to the neonatal airway, with the potential for hypoxia, ischemic brain injury, and death [55]. Cervical teratomas, cervical lymphatic malformations, and cervical hemangiomas are the most common neoplasms with the propensity to cause extrinsic airway compression in the neck. Mediastinal tumors that compress the great vessels or intrathoracic trachea also demand specialized pre- and postnatal care. Large tumors, particularly sacrococcygeal teratomas, merit consideration for Cesarean or early delivery as a method to avoid intrauterine or perinatal complications.

Prior to the development of the ex utero intrapartum treatment (EXIT) procedure, case reports described managing obstructing cervical masses with bronchoscopy and intubation prior to division of the umbilical cord [56]. The operation on placental support (OOPS) procedure involved Cesarean delivery of the head and thorax in order to perform endotracheal intubation [57]. Inhaled isoflurane anesthesia was administered in hopes of minimizing uterine contractions in an effort to preserve fetoplacental circulation and prevent placental abruption [57]. These early procedures were felt to provide inadequate tocolysis and/or reduce the uterine volume through fetal delivery, both of which result in uterine contraction and interruption of uteroplacental gas exchange [58].

Currently, the EXIT procedure offers a more comprehensive management approach to fetal and neonatal airway obstruction. The procedure also has application in the treatment of pulmonary and mediastinal masses leading to airway obstruction or other physiologic derangements. The EXIT procedure [59] entails intubating the mother and administering deep inhalational anesthesia with high-dose (2–3%) isoflurane. Anesthetic alone provides adequate uterine relaxation in many cases, but bolus doses of terbutaline or nitroglycerin can be given when necessary. Prior to performing hysterotomy, ultrasound is used to identify the location of the fetus and placenta. Following hysterotomy, the head and thorax of the fetus are delivered, allowing for multiple procedures to be performed, including bronchoscopy, orotracheal intubation, tracheostomy, mass excision, and ECMO cannulation. Fetoplacental circulation is preserved during the procedure and mitigates the possibility of hypoxia and brain ischemia. Once the airway is secured, the umbilical cord is divided, and Pitocin is administered, while the concentration of inhalational anesthetic is decreased to low levels or discontinued. The remainder of the procedure proceeds as would be expected from a routine Cesarean section.

Mediastinal tumors of appropriate size and location have the potential to cause fetal and neonatal demise through several mechanisms. One potential presentation is fetal airway and esophageal obstruction leading to polyhydramnios and preterm labor [60]. A second presentation is great vessel compression with resulting nonimmune fetal hydrops and fetal demise [60]. Several successful management strategies have been reported. One strategy involves aspiration of the cystic component of mediastinal teratomas for size reduction and alleviation of fetal hydrops until delivery and definitive management [61]. Serial amniocenteses to reduce uterine volume followed by neonatal resection have also been reported [60, 62–64].

The EXIT procedure also serves as a useful adjunct in transitioning these children from intra-uterine life to definitive airway control, ECMO cannulation, or surgical resection.

10. Common specific lesions

10.1. Teratomas

Teratomas are the most common neonatal tumors, accounting for up to 30% of these lesions in some series [1, 20, 21]. Teratomas typically occur in the midline, spanning a variety of locations from the pineal gland to the coccyx [34]. The distribution of these tumors is explained by the fact that they arise from pluripotent germ cells that arrest in abnormal locations during embryologic migration [30]. Persistent division by these aberrant nests of cells results in tumors of varying size in diverse locations.

These neoplasms include all three germ cell layers, endoderm, mesoderm, and ectoderm. Most tumors are benign and can be classified as mature or immature based on their histologic appearance. Elements of the ectoderm, particularly neural tissue, are a dominant feature of immature fetal and neonatal teratomas [65, 66]. Mature and immature teratomas also contain mesenchymal components, including smooth muscle, cartilage, fat, and bone. Endodermal features such as respiratory and gastrointestinal epithelium are much less common [33, 65, 66]. Sacrococcygeal teratomas are the most common type of these tumors, followed in frequency by intracranial, cervical, palatal and nasopharyngeal, cardiac, gastric, and mediastinal teratomas [33]. Survival rates vary considerably by location, with intracranial teratomas (11%) having the lowest survival and gastric teratomas (100%) demonstrating the best prognosis [33].

Sacrococcygeal teratomas represent 40–60% of teratomas and demonstrate a 3 to 1 female to male distribution [33, 67]. The estimated incidence is 1 in every 35,000 live births [68]. In countries where prenatal ultrasound is ubiquitous, many lesions are diagnosed in utero. In the absence of prenatal diagnosis, the classic presentation is that of a newborn with an evident mass on physical examination. Diagnosis of purely pelvic teratomas is frequently delayed [69]. Children in this category may develop urinary retention, constipation, a palpable abdominal mass, or failure to thrive. MRI serves as a useful adjunct to ultrasound in determining the degree of intrapelvic extension. In 1973, Altman et al. [69] developed a location-based classification system for sacrococcygeal teratoma. Type I tumors are mainly external (sacrococcygeal) with minimal presacral component. Type II tumors exhibit an external component on presentation but have a substantial intrapelvic component. Type III tumor indicates a tumor with minimal external component with the majority of the mass located intrapelvic and extending into the abdomen. Type IV tumors are found entirely in the presacral space without any external component. Accurate classification is critical to parental counseling and appropriate operative planning.

Large sacrococcygeal teratomas represent a challenging diagnosis due to their potential to cause perinatal complications as well as unpredictable growth patterns [70]. Potential complications associated with these tumors are numerous, consisting of premature labor from

polyhydramnios or increased intrauterine volume, tumor rupture, labor dystocia, hemorrhage, maternal mirror syndrome, and fetal hydrops secondary to high-output cardiac failure in highly vascular lesions [70]. Prenatally diagnosed sacrococcygeal teratomas should undergo frequent surveillance to monitor for rapidity of growth and development of the aforementioned complications [63]. For tumors that demonstrate a predominantly solid component with high vascularity, open fetal surgery may be necessary for tumor debulking to prevent high-output cardiac failure and fetal hydrops [71]. Similar to the management options for mediastinal teratomas, cyst aspiration and serial amniocenteses are beneficial interventions in appropriately selected patients [63, 64]. Cesarean delivery should be considered in larger lesions to prevent labor dystocia, tumor rupture, and hemorrhage.

En bloc resection of the tumor and coccyx is the primary treatment modality for sacrococcygeal teratoma. Failure to remove the coccyx and gross tumor spillage appear to have the highest association with recurrence [72]. The presence of microscopically positive margins necessitates routine surveillance in the absence of yolk sac tumor elements on final pathology, while histologic confirmation of yolk sac tumor components warrants adjuvant chemotherapy [72]. The age at diagnosis correlates with the presence of underlying malignancy and overall survival. Approximately 10% of neonatal sacrococcygeal teratomas contain a yolk sac tumor with the incidence of a concurrent malignancy increasing with age [33]. The outcome of fetuses diagnosed with sacrococcygeal teratoma is worse than those diagnosed in neonates. The estimated mortality for prenatally diagnosed lesions ranges from 33 to 50% and approaches 100% when fetal hydrops is present [33, 63, 73]. Conversely, the survival for a newborn diagnosed with this disease approaches 90% following complete surgical excision [33, 63, 73].

10.2. Neuroblastoma

Neuroblastoma represents the second most common neonatal tumor, accounting for 22.5–30% of these neoplasms, and the most common congenital malignancy [1, 20, 21]. Neuroblastomas are derived from primitive neural crest cells, or neuroblasts, and can be identified in any location where sympathetic tissue exists [74, 75]. Nearly 90% of fetal and neonatal cases of neuroblastoma occur in the adrenal gland compared to 35% in infants and older children [75, 76]. The next most common sites, in order to decrease frequency, are the retroperitoneum, posterior mediastinum, and neck [32]. The incidence of neuroblastoma is approximately 1 in 100,000 children, with a mean age of diagnosis of 18 months [77]. The incidence of neuroblastoma in neonates is not as well defined as tumors occur less commonly in this age group compared to older children.

Neuroblastoma is being diagnosed with increased frequency on prenatal ultrasound due to widespread use of fetal sonography and continued technological improvement [78]. In fact, there was once an interest in screening for neuroblastoma with prenatal ultrasound, but in general this practice has been abandoned as it only succeeded in identifying lesions that could otherwise be observed and did not identify the more aggressive lesions that most are interested in identifying early. The differential diagnosis of an adrenal lesion includes adrenal hemorrhage, adrenal abscess, adrenal cyst, and renal anomalies. Nearly all cases are diagnosed during the third trimester. Identification of a solid or cystic adrenal mass should

raise suspicion for the presence of an underlying neuroblastoma [78]. Postnatal MRI serves as useful to clarify the extent of disease and guide treatment options. Most mothers with a prenatal diagnosis of neuroblastoma are asymptomatic, although maternal hypertension and preeclampsia may occur due to elevated levels of catecholamines in maternal circulation [76]. In the absence of a prenatal diagnosis of neuroblastoma, presentation is variable and includes detection of a palpable abdominal mass, hepatomegaly, respiratory distress, and the presence of cutaneous nodules. Neuroblastomas are hormonally active tumors that secrete high levels of catecholamines and their by-products. The diagnosis can be further solidified by detection of these chemicals in a urine sample, although serum levels are not predictive of prognosis and do not dictate treatment.

Staging of neuroblastoma follows the International Neuroblastoma Staging System, which considers tumor location, nodal involvement, and the presence of metastases in assessing the burden of disease [79]. The majority of fetal and neonatal cases of neuroblastoma are stage I, stage II, and stage IV-S at the time of diagnosis [32, 76, 77]. Most tumors also demonstrate favorable histology including N-myc non-amplification, stroma-rich appearance, and aneuploid DNA content [32, 76, 77]. Surgical resection is the principal treatment for localized cases of neuroblastoma. In cases of unresectable disease, open or core needle biopsy provides valuable histologic information to help guide treatment decisions. Neonates with stage IV-S represent a particularly unique group of patients who have a localized tumor with metastases isolated to the liver, bone, and skin [79]. Despite the presence of metastatic disease, these children have a favorable prognosis, and many tumors undergo spontaneous regression without specific treatment. Treatment options for stage IV-S include observation, surgical resection, and chemotherapy. Chemotherapy is also employed in the neoadjuvant setting for tumors that are initially deemed to be unresectable. Overall, the prognosis for fetal and neonatal neuroblastoma is excellent, with survival ranging from 70 to 100% [32, 76, 77]. There have been favorable studies that have demonstrated success with observation with small lesions that likely represent neuroblastoma [80]. Moving forward, current staging is changing from a surgery-based staging toward image-defined risk categories with the majority of neonatal lesions falling into the low-risk categories. Therefore, we would recommend that these patients should be enrolled in current observation studies to document outcomes of this patient population.

10.3. Infantile hepatic hemangioma and mesenchymal hamartoma

Infantile hepatic hemangiomas are the most common primary liver tumors in newborns. Hemangiomas display a wide range of behavior, spanning from asymptomatic masses to those causing significant physiologic distress and potential demise [41]. Most lesions are diagnosed on prenatal imaging or found incidentally on physical examination. In some cases, the presence of cutaneous hemangiomas prompts evaluation for a concomitant hepatic mass [41]. Infantile hepatic hemangiomas are benign, vascular masses characterized by rapid postnatal growth followed by involution in childhood [42]. For this reason, asymptomatic and smaller lesions can be observed for involution through serial ultrasonography. Conversely, some lesions develop severe arteriovenous shunting, which can lead to high-output cardiac

failure, fetal hydrops, and death. Other masses lead to Kasabach-Merritt syndrome, which can cause consumptive coagulopathy, thrombocytopenia, and hemolytic anemia [81]. Surgical excision is an effective management for localized lesions in children without severe physiologic derangement. Selective hepatic arterial embolization can be used to induce preoperative tumor shrinkage and in cases of refractory coagulopathy [82].

Mesenchymal hamartomas are the second most common hepatic tumor in newborns. These lesions are congenital malformations that contain elements of normal hepatic parenchyma including mesenchyme, portal venous branches, bile ducts, hepatocytes, and cysts of varying size [41]. Hamartomas are benign masses that display several chromosomal abnormalities [83]. Similar to hemangiomas, hamartomas are typically identified on prenatal imaging or found as an asymptomatic mass on physical examination. Approximately 75% are found in the right hepatic lobe with the rest involving the left lobe or both lobes [84]. Although these are histologically benign tumors, some lesions demonstrate rapid growth and result in significant physiologic disturbance. Tumors abutting the diaphragm can cause significant respiratory compromise. Compression of intra-abdominal vascular structures may lead to nonimmune fetal hydrops and fetal demise. Complete surgical excision is the optimal management for children with hepatic mesenchymal hamartomas. In tumors with large cystic components, fetal aspiration has been reported to mitigate detrimental fetal and obstetric sequelae [85].

10.4. Ovarian cysts

Ovarian cysts are the most common masses identified in neonatal girls and are nearly always benign. The etiology of ovarian cysts is not completely understood, but hormonal stimulation is felt to be responsible for this disease process [86]. In 1975, Valenti et al. [87] reported the first case of a prenatally diagnosed ovarian cyst. With improvement in ultrasonography, ovarian cysts are being identified with increasing frequency on prenatal imaging. Ultrasound provides vital information about size, location, wall characteristics, and vascularity [41]. However, many lesions are asymptomatic and would not be identified if not for routine fetal ultrasound [88].

Treatment of ovarian cysts hinges upon the risk of complications and the ability to differentiate between truly benign cysts and other ovarian neoplasms [89]. The most common complication encountered is ovarian torsion with subsequent loss of the affected ovary [86, 89]. Many cases of ovarian torsion occur prenatally, precluding the ability to intervene in an effort for ovarian preservation. Doppler evaluation is an unreliable measure of torsion in this patient population secondary to vessel size and the fact that normal flow does not exclude the diagnosis [86]. Fetal cyst aspiration is one management strategy used to mitigate the risk of in utero torsion, but there is no agreed upon size cutoff to determine when this measure should be employed.

Simple cysts less than 4–5 cm in size can be observed for spontaneous regression with serial ultrasonography [41, 86, 88, 89]. Cysts larger than 4–5 cm are candidates for cyst aspiration or surgical intervention given a higher potential for ovarian torsion [41, 86, 88, 89]. Complex ovarian cysts, cysts that fail to regress spontaneously, cysts that recur following aspiration, and those that are symptomatic should be removed surgically [89]. Preservation of ovarian parenchyma is the hallmark of surgery for ovarian cysts. Options for surgical management include cyst unroofing, partial or total cystectomy, and oophorectomy. In cases of ovarian

torsion, the macroscopic appearance of the ovary does not necessarily correlate with the degree of parenchymal damage [88]. Pathologic evaluation of a portion of the cyst wall is recommended; however, the presence of an underlying malignancy is exceedingly rare.

10.5. Cervical lymphatic malformations

Lymphatic malformations are characterized by localized collections of malformed lymphatic channels that occur most commonly in the head and neck [90]. Lymphatic malformations typically occur in the posterior neck and are often associated with karyotypic abnormalities [91]. Other common locations are the trunk and extremities, the thoracic cavity, and the abdominal cavity. Traditionally, lymphatic malformations have been assigned to different categories based on histologic appearance: cavernous lymphangiomas, capillary lymphangiomas, and cystic hygroma [90]. However, the histologic classification does not seem to correlate with clinical behavior or response to therapy [90]. These masses follow a variable clinical course, with prenatally diagnosed lesions having a worse prognosis than those identified following birth [91].

Lymphatic malformations typically grow proportionally with the growth of the child, with rapid enlargement occurring as the result of trauma, hemorrhage, or infection [91]. Spontaneous infection occurs in approximately 7–30% of these masses [92]. The size and location of a given lymphatic malformation are predictive of potential adverse consequences to the developing child. Head and neck lesions can lead to fetal esophageal obstruction, resulting in polyhydramnios and preterm labor. A more serious complication is the potential for neonatal airway obstruction and rapid demise following birth. The EXIT procedure [56] offers a comprehensive management strategy to establish a definitive airway while maintaining fetoplacental circulation. However, if the lesion is soft and away from the midline, such fetuses may not require EXIT as obtaining an airway may not be difficult. Intrathoracic lymphatic malformations also have the potential to cause airway obstruction. Compression of the great vessels in the thorax and abdomen can cause high-output cardiac failure, hydrops fetalis, and fetal demise.

Many treatment modalities exist for the management of lymphatic malformations. In general, asymptomatic lesions can be observed for some time as many of these lesions will resolve without intervention. In those lesions that are large, growing, or symptomatic, therapeutic maneuvers include sclerotherapy and surgery. Prior to pursuing these therapies, the extent of the tumor and association with surrounding structures must be determined [91]. Nerves and major vessels should be preserved [90]. More complex and invasive lesions may require multiple, staged operations to achieve complete resection [90, 91]. Tumors that undergo complete macroscopic excision show the lowest recurrence rates but still return in 17% of cases [93]. Recurrences occur in up to 100% of cases following aspiration and in 40% of masses that are incompletely excised [93]. The estimated recurrence rate following injection of sclerosing agents, such as sodium tetradecanol, bleomycin, and OK-432, ranges from 50 to 100% [91, 93]. Aspiration does play a role in emergent cases to decrease the mass effect of the tumor and establish an airway [90]. In small, asymptomatic lesions, a period of surveillance to monitor for spontaneous regression may also be pursued [90].

10.6. Rhabdomyosarcoma

Soft tissue tumors account for 8–12% of neonatal tumors [1, 20, 21]. Rhabdomyosarcoma is the most common malignant soft tissue tumor in children, representing one third of these masses in infants and nearly half of soft tissue tumors found in older children [53]. Rhabdomyosarcoma is an aggressive, embryonal tumor of childhood marked by high-grade histology, local invasiveness, and a propensity to metastasize [53]. There are two main histologic subtypes: embryonal rhabdomyosarcoma accounts for nearly 70% of all cases and portends a better prognosis and alveolar rhabdomyosarcoma which is characterized by numerous chromosomal translocations and has a worse overall outcome [94]. As mesenchymal tumors that arise from skeletal muscle, rhabdomyosarcoma can occur in many locations throughout the body. The most common sites of occurrence are the head and neck followed by the genitourinary system and extremities [53]. Neonatal cases of rhabdomyosarcoma are rare. Male gender, Caucasian race, embryonal subtype, and undifferentiated histology are the predominant characteristics in neonates [95].

Rhabdomyosarcoma may be identified on prenatal imaging but more commonly presents as an identifiable mass following birth. The differential diagnosis is broad and includes many benign and malignant soft tissue tumors. Lymphatic involvement and metastatic disease are present in nearly 20% of cases at presentation [53]. The most common sites of metastasis are the lung, bone marrow, and bone. Neonatal cases of alveolar rhabdomyosarcoma may present with brain metastases and subcutaneous nodules [96]. Biopsy of the primary lesion is recommended for diagnostic purposes and to determine tumor biology to guide treatment. However, one should proceed with complete excision of smaller lesions (<5 cm) if this can be performed with clear margins and without injury to surrounding structures. Larger or difficult to excise lesions should have an incisional biopsy with a sufficient tissue sample to allow for all necessary studies (1 cm³). Following diagnosis, tumors require staging with CT or MRI of the primary lesion, imaging of the chest, bone marrow aspiration, and bone marrow biopsy.

Treatment of neonatal rhabdomyosarcomas should be undertaken in a multidisciplinary fashion. Therapy is multimodal and includes systemic chemotherapy for metastatic disease and surgical resection and radiation for local disease. Complete surgical resection may not always be feasible, and age at diagnosis dictates the ability to give chemotherapy and radiation. Age is an independent prognostic factor with children less than 1 year of age having a worse overall prognosis than children between the ages of 1 and 10 [97, 98]. In the Intergroup Rhabdomyosarcoma Study, Lobe et al. [95] found that only 49% of 14 newborns diagnosed with rhabdomyosarcoma were alive at 3 years.

10.7. Congenital mesoblastic nephroma

Congenital mesoblastic nephroma is the most common renal tumor occurring in neonates and during the first 3 months of life [45]. In a retrospective review of 210 renal tumors in fetuses and infants less than 2 months of age, Isaacs [44] found that the four most common renal neoplasms were congenital mesoblastic nephroma (66%), Wilms' tumor (20%), rhabdoid tumor of the kidney (11%), and clear cell sarcoma of the kidney (3%). Congenital mesoblastic

nephroma demonstrates a slight male predominance with a male to female ratio of 1.5 to 1 [45]. The most common presentations of mesoblastic nephroma are prenatal identification on fetal ultrasound, polyhydramnios, and palpation of an abdominal mass following birth. Sonographically, the presence of an anechoic circle or “ring sign” surrounding the mass may help differentiate congenital mesoblastic nephroma from other renal neoplasms [46]. These tumors typically demonstrate benign behavior; however, in addition to polyhydramnios, some masses may be complicated by hypertension; respiratory compromise; circulatory compromise from large, space-occupying lesions; and fetal hydrops [44].

Congenital mesoblastic nephroma (CMN) is a benign neoplasm that is characterized by leiomyomatous histology with bundles of spindle cells, rare mitoses, and lack of necrosis [99]. The tumor can be further subdivided into classic and cellular subtypes based on histological appearance. Patients with the cellular subtype of CMN tend to have larger tumor burdens and older age of presentation [99]. Additionally, many cellular mesoblastic nephromas are cystic in nature, which may lead to increased risk of rupture and higher rates of recurrence [99]. Radical nephrectomy is the mainstay of treatment for a neonate diagnosed with CMN. Patients with the classic subtype of CMN are typically cured with surgical excision alone, while aggressive tumors, which are often of the cellular subtype, may require adjuvant chemotherapy. Recurrence occurs in 5% of patients, while metastases are present in 2% of cases [44]. The overall survival for a patient diagnosed with congenital mesoblastic nephroma is 95–98% [99, 100].

11. Chemotherapy and irradiation

One of the greatest challenges in pediatric oncology is determining the appropriate dosing regimen for chemotherapeutic agents in young children [101]. Multiple factors influence the pharmacology of chemotherapeutic drugs in the newborn, including changes in blood flow, hepatic and renal development, and alterations in the amount of body composition attributed to fat and water [101]. Body surface area dosing is the most commonly employed dosing method in the pediatric setting, but there are inconsistencies in the cutoffs and magnitude for dose reductions [101]. Administration of chemotherapy in newborns should always take place under the guidance of a pediatric oncologist.

Radiation therapy is also very challenging in the pediatric patient population. Although radiation therapy has been successful in the treatment of many pediatric cancers, concerns remain about long-term side effects [102]. Growth and development failure is a primary concern for children who receive radiation therapy [102]. Other late sequelae include neurocognitive defects, infertility, cardiac and pulmonary abnormalities, gastrointestinal dysfunction, and secondary cancer development [102]. Over the last 35 years, the use of radiation therapy has declined in the treatment of many pediatric cancers, including Wilms’ tumor, neuroblastoma, ALL, and non-Hodgkin’s lymphoma [102]. The decision to use radiation therapy in the treatment of neonatal tumors should always include a discussion of the risks and benefits of therapy with a radiation oncologist. Of note for this patient population is the need to perform radiation under sedation as the drugs used in this treatment modality are under investigation as to potential long-term side effects.

12. Conclusion

Neonatal tumors encompass an extremely diverse, heterogeneous group of neoplasms. Neonatal tumors demonstrate a broad spectrum of behaviors and outcomes with some lesions spontaneously regressing without treatment, while others are resistant to aggressive, multi-modal therapy. The majority of lesions are benign, but histologic classification is not always predictive of clinical behavior or overall outcome. Treatment of neonatal tumors requires a clear understanding of the natural history of disease and the limitations of each treatment modality. The optimal management strategy incorporates the expertise of pediatricians, pediatric surgeons, pediatric medical oncologists, and pediatric radiation oncologists.

Author details

Kenneth W. Gow* and Matthew Dellinger

*Address all correspondence to: kenneth.gow@seattlechildrens.org

Seattle Children's Hospital and the University of Washington, USA

References

- [1] Moore SW, Satge D, Sasco AJ, et al. The epidemiology of neonatal tumours. Report of an international working group. *Pediatric Surgery International*. 2003;**19**:509–519
- [2] Weitzman S, Grant R. Neonatal oncology: Diagnostic and therapeutic dilemmas. *Seminars in Perinatology*. 1997;**21**(1):102–111
- [3] Batcup G. Cancer in the very young child—pitfalls and problems for the pathologist. *British Journal of Cancer. Supplement*. 1992;**18**:S5–S7
- [4] Halperin E. Neonatal neoplasms. *International Journal of Radiation Oncology Biology Physics*. 2000;**47**(1):171–178
- [5] Orbach D, Sarnacki S, Brisse HJ, et al. Neonatal cancer. *Lancet Oncology*. 2013;**14**:e609–e620
- [6] Merks JHM, Caron HN, Hennekam RCM. High incidence of malformation syndromes in a series of 1073 children with cancer. *American Journal of Medical Genetics*. 2005;**134**:132–143
- [7] Santos XM, Papanna R, Johnson A, et al. The use of combined ultrasound and magnetic resonance imaging in the detection of fetal anomalies. *Prenatal Diagnosis*. 2010;**30**:402–407
- [8] Nemec SF, Horcher E, Kasprian G, et al. Tumor disease and associated congenital abnormalities on prenatal MRI. *European Journal of Radiology*. 2012;**81**:e115–e122
- [9] Lee TC, Olutoye OO. Evaluation of the prenatally diagnosed mass. *Seminars in Fetal & Neonatal Medicine*. 2012;**17**:185–191

- [10] Pugash D, Brugger PC, Bettelheim D, et al. Prenatal ultrasound and fetal MRI: The comparative value of each modality in prenatal diagnosis. *European Journal of Radiology*. 2008;**68**:214–226
- [11] Chung R, Kasprian G, Brugger PC, et al. The current state and future of fetal imaging. *Clinics in Perinatology*. 2009;**36**:685–699
- [12] Bricker L, Garcia J, Henderson J, et al. Ultrasound screening in pregnancy: A systematic review of the clinical effectiveness, cost-effectiveness, and women's views. *Health Technology Assessment*. 2000;**4**(16):1–193
- [13] Chen MM, Coakley FV, Kaimal A, et al. Guideline for computed tomography and magnetic resonance imaging use during pregnancy and lactation. *Obstetrics & Gynecology*. 2008;**112**:333–340
- [14] Breyssem L, Bosmans H, Dymarkowski S, et al. The value of fast MR imaging as an adjunct to ultrasound in prenatal diagnosis. *European Radiology*. 2003;**13**:1538–1548
- [15] Wagenvoort AM, Bekker MN, Go ATJI, et al. Ultrafast scan magnetic resonance in prenatal diagnosis. *Fetal Diagnosis and Therapy*. 2000;**15**:364–372
- [16] American College of Obstetricians and Gynecologists' Committee on Obstetric Practice. Guidelines for diagnostic imaging during pregnancy and lactation. *Obstetrics & Gynecology*. 2016;**127**(2):e75–e80
- [17] Kanal E, Barkovich AJ, Bell C, et al. ACR guidance document on MR safe practices: 2013. Expert Panel on MR Safety. *Journal of Magnetic Resonance Imaging*. 2013;**37**:501–530
- [18] Alamo L, Beck-Popovic M, Gudinchet F, et al. Congenital tumors: Imaging when life just begins. *Insights into Imaging*. 2011;**2**:297–308
- [19] Borsellino A, Zaccara A, Nahom A, et al. False-positive rate in prenatal diagnosis of surgical anomalies. *Journal of Pediatric Surgery*. 2006;**41**:826–829
- [20] Isaacs H Jr. Congenital and neonatal malignant tumors. A 28-year experience at Children's Hospital of Los Angeles. *The American Journal of Pediatric Hematology/Oncology*. 1987;**9**(2):121–129
- [21] Parkes SE, Muir KR, Southern L, et al. Neonatal tumours: A thirty-year population-based study. *Medical and Pediatric Oncology*. 1994;**22**:309–317
- [22] Bauchet L, Rigau V, Mathieu-Daudé H, et al. Clinical epidemiology for childhood primary central nervous system tumors. *Journal of Neuro-Oncology*. 2009;**92**:87–98
- [23] Ostrom QT, Gittleman H, Fulop J, et al. CBTRUS statistical report: Primary brain and central nervous system tumors diagnosed in the United States in 2008–2012. *Neuro-Oncology*. 2015;**17**:iv1–iv62
- [24] Isaacs H Jr. Perinatal brain tumors: A review of 250 cases. *Pediatric Neurology*. 2002;**27**:333–342
- [25] Magdum SA. Neonatal brain tumours—a review. *Early Human Development*. 2010;**86**:627–631

- [26] Goins MR, Beasley MS. Pediatric neck masses. *Oral & Maxillofacial Surgery Clinics of North America*. 2012;**24**:457–468
- [27] Torsiglieri AJ Jr, Tom LWC, Ross AJ III, et al. Pediatric neck masses: Guidelines for evaluation. *International Journal of Pediatric Otorhinolaryngology*. 1988;**16**:199
- [28] Krol A, MacArthur CJ. Congenital hemangiomas: Rapidly involuting and noninvoluting congenital hemangiomas. *Archives of Facial Plastic Surgery*. 2005;**7**:307–311
- [29] Kanada KN, Merin MR, Munden A, et al. A prospective study of cutaneous findings in newborns in the United States: Correlation with race, ethnicity, and gestational status using updated classification and nomenclature. *Journal of Pediatrics*. 2012;**161**:240–245
- [30] Tranvinh E, Yeom KW, Iv M. Imaging neck masses in the neonate and young infant. *Seminars in Ultrasound, CT, and MRI*. 2015;**36**:120–137
- [31] Dickson PV, Davidoff AM. Malignant neoplasms of the head and neck. *Seminars in Pediatric Surgery*. 2006;**15**(2):92–98
- [32] Isaacs H Jr. Fetal and neonatal neuroblastoma: Retrospective review of 271 cases. *Fetal and Pediatric Pathology*. 2007;**26**:177–184
- [33] Isaacs H Jr. Perinatal (fetal and neonatal) germ cell tumors. *Journal of Pediatric Surgery*. 2004;**39**(7):1003–1013
- [34] Woodward PJ, Sohaey R, Kennedy A, Koeller KK. From the archives of the AFIP: A comprehensive review of fetal tumors with pathologic correlation. *Radiographics*. 2005;**25**(1):215–242
- [35] Wienk MA, Van Geijn HP, Copray FJ, Brons JT. Prenatal diagnosis of fetal tumors by ultrasonography. *Obstetrical & Gynecological Survey*. 1990;**45**:639–653
- [36] Isaacs H Jr. Fetal and neonatal cardiac tumors. *Pediatric Cardiology*. 2004;**25**:252–273
- [37] Chan HS, Sonley MJ, Moes CA, Daneman A, Smith CR, Martin DJ. Primary and secondary tumors of childhood involving the heart, pericardium, and great vessels. A report of 75 cases and review of the literature. *Cancer*. 1985;**56**:825–836
- [38] Van der Hauwaert LG. Cardiac tumours in infancy and childhood. *British Heart Journal*. 1971;**33**:125–132
- [39] Jaggars J, Balsara K. Mediastinal masses in children. *Seminars in Thoracic and Cardiovascular Surgery*. 2004;**16**:201–208
- [40] Priest JR, Williams MG, Hill DA, et al. Pulmonary cysts in early childhood and the risk of malignancy. *Pediatric Pulmonology*. 2009;**44**:14–30
- [41] Chandler JC, Gauderer MWL. The neonate with an abdominal mass. *Pediatric Clinics of North America*. 2004;**51**:979–997
- [42] Isaacs H Jr. Fetal and neonatal hepatic tumors. *Journal of Pediatric Surgery*. 2007;**42**:1797–1803

- [43] Trobaugh-Lotrario AD, Chaibachati BH, Meyers RL, et al. Outcomes for patients with congenital hepatoblastoma. *Pediatric Blood & Cancer*. 2013;**60**:1817–1825
- [44] Isaacs H Jr. Fetal and neonatal renal tumors. *Journal of Pediatric Surgery*. 2008;**43**:1587–1595
- [45] Powis M. Neonatal renal tumors. *Early Human Development*. 2010;**86**:607–612
- [46] Kelner M, Droullé P, Didier F, et al. The vascular “ring” sign in mesoblastic nephroma: Report of two cases. *Pediatric Radiology*. 2003;**33**:123–128
- [47] Manivel JC. Testicular germ cell tumors (TGCTs) in neonates and infants. *Seminars in Diagnostic Pathology*. 2016;**33**(6):410–148
- [48] Ross JH. Prepubertal testicular tumors. *Urology*. 2008;**74**:94–99
- [49] Ross J, Rybicki L, Kay R. Clinical behavior and a contemporary management algorithm for prepubertal testis tumors: A summary of the Prepubertal Testis Tumor Registry. *Journal of Urology*. 2002;**168**:1675–1679
- [50] Quint EH, Smith YR. Ovarian surgery in premenarchal girls. *Journal of Pediatric & Adolescent Gynecology*. 1999;**12**:27–30
- [51] Navarro OM, Laffan EE, Ngan BY. Pediatric soft-tissue tumors and pseudotumors: MRI imaging features with pathologic correlation. *Radiographics*. 2009;**29**:887–906
- [52] Bruyeer E, Lemmerling M, Poorten VV, et al. Paediatric lipoblastoma in the head and neck: Three cases and review of literature. *Cancer Imaging*. 2012;**12**:484–487
- [53] Ferrari A, Orbach D, Sultan I, et al. Neonatal soft tissue sarcomas. *Seminars in Fetal & Neonatal Medicine*. 2012;**17**:231–238
- [54] Bourdeaut F, Fréneaux P, Thuille B, et al. Extra-renal non-cerebral rhabdoid tumours. *Pediatric Blood & Cancer*. 2008;**51**:363–368
- [55] Marwan A, Crombleholme TM. The EXIT procedure: Principles, pitfalls, and progress. *Seminars in Pediatric Surgery*. 2006;**15**:107–115
- [56] Langer JC, Tabb T, Thompson P, et al. Management of prenatally diagnosed tracheal obstruction: Access to the airway in utero prior to delivery. *Fetal Diagnosis and Therapy*. 1992;**7**:12–16
- [57] Skarsgard ED, Chitkara U, Krane EJ, et al. The OOPS procedure (operation on placental support): In utero airway management of the fetus with prenatally diagnosed tracheal obstruction. *Journal of Pediatric Surgery*. 1996;**31**:826–828
- [58] McNamara H, Johnson N. The effect of uterine contractions on fetal oxygen saturation. *British Journal of Obstetrics and Gynaecology*. 1995;**102**:644–647
- [59] Mychaliska GB, Bealer JF, Graf JL, et al. Operating on placental support: The ex utero intrapartum treatment procedure. *Journal of Pediatric Surgery*. 1997;**32**:227–231
- [60] Merchant AM, Hedrick HL, Johnson MP, et al. Management of fetal mediastinal teratoma. *Journal of Pediatric Surgery*. 2005;**40**:228–231

- [61] Takayasu H, Kitano Y, Kuroda T, et al. Successful management of a large fetal mediastinal teratoma complicated by hydrops fetalis. *Journal of Pediatric Surgery*. 2010;**45**: e21-e24
- [62] Dumbell HR, Coleman AC, Pudifin JM, et al. Prenatal ultrasonographic diagnosis and successful management of mediastinal teratoma. A case report. *South African Medical Journal*. 1990;**20**:481–483
- [63] Hedrick HL, Flake AW, Crombleholme TM, et al. Sacrococcygeal teratoma; Prenatal assessment, fetal intervention, and outcome. *Journal of Pediatric Surgery*. 2004;**39**:430–438
- [64] Makin EC, Hyett J, Ade-Ajayi N, et al. Outcome of antenatally diagnosed sacrococcygeal teratomas: Single-center experience (1993–2004). *Journal of Pediatric Surgery*. 2006;**41**:388–393
- [65] Isaacs H Jr. Perinatal (congenital and neonatal) neoplasms: A report of 110 cases. *Pediatric Pathology*. 1985;**3**:165–216
- [66] Werb P, Scurry J, Ostor A, et al. Survey of congenital tumors in perinatal necropsies. *Pathology*. 1992;**24**:247–253
- [67] Billmire DF, Grosfeld JL. Teratomas of childhood: Analysis of 142 cases. *Journal of Pediatric Surgery*. 1986;**21**:548–551
- [68] Pantoja E, Liobet R, Gonsales-Flores B. Retroperitoneal teratoma: Historic review. *Journal of Urology*. 1976;**115**:520–523
- [69] Altmann RP, Randolph JG, Lilly JR. Sacrococcygeal teratoma: American Academy of Pediatrics Surgical Section Survey 1973. *Journal of Pediatric Surgery*. 1974;**9**:389–398
- [70] Roybal JL, Moldenhauer JS, Khalek N, et al. Early delivery as an alternative management strategy for selected high-risk fetal sacrococcygeal teratomas. *Journal of Pediatric Surgery*. 2011;**46**: 1325–1332
- [71] Adzick NS. Open fetal surgery for life-threatening fetal anomalies. *Seminars in Fetal & Neonatal Medicine*. 2010;**15**(1):1–8
- [72] De Backer A, Maderen GC, Hakvoort-Cammel FGAJ, et al. Study of the factors associated with recurrence in children with sacrococcygeal teratoma. *Journal of Pediatric Surgery*. 2006;**41**:173–181
- [73] Holterman AX, Filiatrault D, Lallier M, et al. The natural history of sacrococcygeal teratomas diagnosed through routine obstetric sonogram: A single institution experience. *Journal of Pediatric Surgery*. 1998;**33**:899–903
- [74] Fisher JPH, Tweddle DA. Neonatal neuroblastoma. *Seminars in Fetal & Neonatal Medicine*. 2012;**17**:207–215
- [75] Lonergan GJ, Schwab CM, Suarez ES, et al. Neuroblastoma, ganglioneuroblastoma, and ganglioneuroma: Radiologic-pathologic correlation. *Radiographics*. 2002;**22**:911–934
- [76] Acharya S, Jayabose S, Kogan SJ, et al. Prenatally diagnosed neuroblastoma. *Cancer*. 1997;**80**:304–310

- [77] Kostyrka B, Li J, Soundappan SV, et al. Features and outcomes of neonatal neuroblastoma. *Pediatric Surgery International*. 2011;**27**:937–941
- [78] Ho PTC, Estroff JA, Kozakewich M, et al. Prenatal detection of neuroblastoma. A ten year experience from the Dana Farber Cancer Institute and Children's Hospital. *Pediatrics*. 1993;**92**(3):358–364
- [79] Brodeur GM, Pritchard J, Berthold F, et al. Revisions of the international criteria for neuroblastoma diagnosis, staging, and response to treatment. *Journal of Clinical Oncology*. 1993;**11**:1466–1467
- [80] Nuchtern JG, London, WB, Barnewolt CE, et al. A prospective study of expectant observation as primary therapy for neuroblastoma in young infants: A Children's Oncology Group study. *Annals of Surgery*. 2012;**256**(4):573–580
- [81] Haisley-Royster C, Enjolras O, Frieden IJ, et al. Kasabach-Merritt phenomenon: A retrospective study of treatment with vincristine. *Journal of Pediatric Hematology/Oncology*. 2002;**24**(6):459–462
- [82] Kullendorff CM, Cwikiel W, Sandstrom S. Embolization of hepatic hemangiomas in infants. *European Journal of Pediatric Surgery*. 2002;**12**(5):348–352
- [83] Murthi GV, Paterson L, Azmy A. Chromosomal translocation in mesenchymal hamartoma of liver: What is its significance? *Journal of Pediatric Surgery*. 2003;**38**(10):1543–1545
- [84] Stringer MD, Alizai NK. Mesenchymal hamartoma of the liver: A systematic review. *Journal of Pediatric Surgery*. 2005;**40**:1681–1690
- [85] Tsao K, Hirose S, Sydorak R, et al. Fetal therapy for giant hepatic cysts. *Journal of Pediatric Surgery*. 2002;**37**(10):e31
- [86] Bagolan P, Giorlandino C, Nahom A, et al. The management of fetal ovarian cysts. *Journal of Pediatric Surgery*. 2002;**37**(1):25–30
- [87] Valenti C, Kassner EG, Yermakov V, et al. Antenatal diagnosis of a fetal ovarian cyst. *American Journal of Obstetrics and Gynecology*. 1975;**123**:216–219
- [88] Galinier P, Carfagna L, Juricic M, et al. Fetal ovarian cysts management and ovarian prognosis: A report of 82 cases. *Journal of Pediatric Surgery*. 2008;**43**:2004–2009
- [89] Brandt ML, Luks FI, Filiatrault D, et al. Surgical indications in antenatally diagnosed ovarian cysts. *Journal of Pediatric Surgery*. 1991;**26**(3):276–282
- [90] Bloom DC, Perkins JA, Manning SC. Management of lymphatic malformations. *Current Opinion in Otolaryngology & Head and Neck Surgery*. 2004;**12**:500–504
- [91] Gallagher PG, Mahoney MJ, Gosche JR. Cystic hygroma in the fetus and newborn. *Seminars in Perinatology*. 1999;**23**(4):341–356
- [92] Wiswell TE, Miller JA. Infections of congenital cervical neck masses associated with bacteremia. *Journal of Pediatric Surgery*. 1986;**21**:173–174

- [93] Alqahtani A, Nguyen LT, Flageole H, et al. 25 years' experience with lymphangiomas in children. *Journal of Pediatric Surgery*. 1999;**34**(7):1164–1168
- [94] De Giovanni C, Landuzzi L, Nicoletti G, et al. Molecular and cellular biology of rhabdomyosarcoma. *Future Oncology*. 2009;**5**:1449–1475
- [95] Lobe TE, Wiener ES, Hays DM, et al. Neonatal rhabdomyosarcoma: The IRS experience. *Journal of Pediatric Surgery*. 1994;**29**:1167–1170
- [96] Rodriguez-Galindo C, Hill DA, Onyekwere O, et al. Neonatal alveolar rhabdomyosarcoma with skin and brain metastases. *Cancer*. 2001;**92**:1613–1620
- [97] Sultan I, Casanova M, Al-Jumaily U, et al. Soft tissue sarcomas in the first year of life. *European Journal of Cancer*. 2010;**46**:2449–2456
- [98] Joshi D, Anderson JR, Paidas C, et al. Age is an independent prognostic factor in rhabdomyosarcoma: A report from the Soft Tissue Sarcoma Committee of the Children's Oncology Group. *Pediatric Blood & Cancer*. 2004;**42**(1):64–73
- [99] Furtwaengler R, Reinhard H, Leuschner I, et al. Mesoblastic nephroma—a report from the Gesellschaft für Pädiatrische Onkologie und Hämatologie (GPOH). *Cancer*. 2006;**106**:2275–2283
- [100] Howell CG, Othersen HB, Kiviat NE, et al. Therapy and outcome in 51 children with mesoblastic nephroma: A report of the National Wilms' Tumor Study. *Journal of Pediatric Surgery*. 1982;**17**:826–831
- [101] Veal GJ, Boddy AV. Chemotherapy in newborns and preterm babies. *Seminars in Fetal and Neonatal Medicine*. 2012;**17**(4):243–248
- [102] Jairam V, Roberts KB, Yu JB. Historical trends in the use of radiation therapy for pediatric cancers: 1973–2008. *International Journal of Radiation Oncology Biology Physics*. 2013;**85**(3):e151–e155