

We are IntechOpen, the world's leading publisher of Open Access books Built by scientists, for scientists

6,900

Open access books available

186,000

International authors and editors

200M

Downloads

Our authors are among the

154

Countries delivered to

TOP 1%

most cited scientists

12.2%

Contributors from top 500 universities



WEB OF SCIENCE™

Selection of our books indexed in the Book Citation Index
in Web of Science™ Core Collection (BKCI)

Interested in publishing with us?
Contact book.department@intechopen.com

Numbers displayed above are based on latest data collected.
For more information visit www.intechopen.com



Medication-Related Osteonecrosis of the Jaw

Kenji Yamagata, Fumihiko Uchida, Naomi Kanno,
Toru Yanagawa and Hiroki Bukawa

Additional information is available at the end of the chapter

<http://dx.doi.org/10.5772/67980>

Abstract

Osteonecrosis of the jaw (ONJ) is a common side effect of antiresorptive drugs that are administered to cancer patients for bone metastasis, multiple myeloma, and osteoporosis. Since both bisphosphonate (BP) and denosumab show anti-bone resorption effects with ONJ, antiresorptive agent-related ONJ (ARONJ) has been suggested as a comprehensive term encompassing both BP-related osteonecrosis of the jaw (BRONJ) and denosumab-related osteonecrosis of the jaw (DRONJ). The term medication-related osteonecrosis of the jaw (MRONJ) is proposed as ARONJ with the antiangiogenic inhibitors or molecularly targeted drugs-related ONJ. Suppression of bone remodeling may contribute to the development of osteonecrosis and results in inadequate osteoclast activity to allow healing of the extraction socket. Infection is a major factor in the development of MRONJ. The major treatment goals for patients at risk of developing or who have MRONJ are prioritization and support of continued oncologic treatment in patients receiving antiresorptive and antiangiogenic therapy. To minimize the development of MRONJ in patients at risk, regular dental examinations are encouraged. Oral hygiene should be improved and local infection is managed as early as possible. The use of antibiotics before and after oral surgical procedures has been demonstrated to lower the risk of MRONJ.

Keywords: medication-related osteonecrosis of the jaw (MRONJ), bisphosphonate (BP), receptor activator nuclear factor κ B ligand (RANKL) inhibitor, BP-related osteonecrosis of the jaw (BRONJ), denosumab-related osteonecrosis of the jaw (DRONJ), antiresorptive agent, antiresorptive agent-related osteonecrosis of the jaw (ARONJ), angiogenesis inhibitors

1. Introduction

Osteonecrosis of the jaw is a common side effect of antiresorptive drugs that are administered to cancer patients for bone metastasis, multiple myeloma, and osteoporosis. Antiresorptive

medications contain bisphosphonates and the receptor activator nuclear factor κ B ligand (RANKL) inhibitor [1].

On the other hand, denosumab, a human IGG2 monoclonal antibody against RANKL, is a therapeutic agent for bone metastasis and osteoporosis, with a half-life of approximately 1 month. Unlike bisphosphonates (BPs), which promotes apoptosis in osteoclasts, denosumab inhibits osteoclastic bone resorption without causing apoptosis. Furthermore, denosumab is not deposited in the bone and thus does not persist for long periods of time, as is the case with BPs, and so the effects of denosumab are reversible [2]. However, patients treated with denosumab also developed ONJ (denosumab-related ONJ [DRONJ]), which was clinically indistinguishable from BRONJ and occurred at almost the same rates [3].

Since both BP and denosumab which show anti-bone resorption effects through different molecular mechanisms of action are associated with ONJ, antiresorptive agent-related ONJ (ARONJ) has been suggested as a comprehensive term encompassing both BRONJ and DRONJ [4]. The American Association of Oral and Maxillofacial Surgeons (AAOMS) has proposed the term “medication-related osteonecrosis of the jaw” (MRONJ), based on observations that antiangiogenic inhibitors and molecularly targeted drugs such as tyrosine kinase inhibitors are also infrequently associated with ONJ or increase the incidence of BRONJ/DRONJ in cancer patients receiving BPs or denosumab, although global consensus has not yet been established [5].

The number of patients with MRONJ has grown recently. Medication-related osteonecrosis of the jaw (MRONJ) is defined as exposed bone in the oral cavity or extra-oral fistula in the maxillofacial region for more than 8 weeks with the treatment of antiresorptive or antiangiogenic agents for more than 8 weeks. These patients have no history of radiotherapy or metastatic disease in the jaw. We present about the details, pathophysiology, diagnosis, staging and treatment, risk factor, and prevention of MRONJ in below paragraphs in this chapter.

2. Antiresorptive and antiangiogenic medications

2.1. Bisphosphonates (BPs)

Intravenous BPs are antiresorptive agents and administered for cancer-related conditions; hypercalcemia of malignancy, skeletal-related events (SREs) associated with bone metastases in the context of solid tumors (for example breast, prostate and lung cancers), and lytic lesions of multiple myeloma. These medications have a significant positive effect for the quality of life of patients with bone metastatic cancer [5]. Oral BPs are approved for the treatment of osteoporosis and osteopenia. They have been used in less common conditions, such as paget disease of bone and osteogenesis imperfection. The most common use is for osteopenia and osteoporosis [6].

2.2. RANKL inhibitor (denosumab)

The receptor activator of RANKL inhibitor (denosumab) inhibits osteoclast function and bone resorption. There is a decrease in the risk of vertebral, nonvertebral, and hip fractures

in osteoporotic patients for administering denosumab subcutaneously every 6 months. Moreover, monthly administration of denosumab is effective for decreasing SREs-related metastatic bone disease from solid tumors [7, 8]. In contrast to BPs, denosumab do not bind to bone and their effects of bone remodeling continue within 6 months [5].

2.3. Antiangiogenic medications

Angiogenesis inhibitors interfere with the formation of new blood vessels by connecting to many signaling molecules and disrupting the angiogenesis-signaling cascade. These medications are administered for gastrointestinal tumors, renal cell carcinoma, neuroendocrine tumors, and other malignancies [5].

3. Pathophysiology

The pathophysiology of MRONJ is well unknown and considered to be multifactorial. Suppressed bone remodeling may contribute to the development of osteonecrosis, and in inadequate osteoclast activity disturbed cure the extraction socket. Infection is a major factor for the development of MRONJ. Bacteria stimulate bone resorption and contribute to bone necrosis [9].

3.1. Incidence of MRONJ

The reported incidence of MRONJ varies by study, and there are no reliable epidemiological data derived from evidenced-based medicine. This chapter follows the data cited by the International Task Force on ONJ [10].

3.1.1. *Patients with osteoporosis*

1. BRONJ

The incidence is 1.04–69/100,000 patients per year treated with orally administered BPs and 0–90/100,000 patients per year treated with intravenous administration. The incidence of ONJ in patients with osteoporosis treated with oral/intravenous nitrogen-containing BPs ranges from 0.001 to 0.01%, which is estimated to be almost the same or slightly higher than the incidence (0.01%) of ONJ in the general population [10].

2. DRONJ

The incidence is 0–30.2/100,000 patients per year [10].

3.1.2. *Cancer patients*

The incidence of ONJ in cancer patients is higher than that in patients with osteoporosis. Prospective studies on the incidence of ONJ were conducted in cancer patients treated with

zoledronic acid or denosumab. Among 5723 patients with breast, prostate, and other solid cancer and multiple myeloma, there were 89 ONJ cases in total, 52 in the denosumab, and 37 in the zoledronic acid-treated. The incidence in the denosumab-treated was 1.8% and 1.3% in the zoledronic acid [3, 11].

3.2. Uniqueness of the jaw bone [12]

There are several unique anatomical and microbiological characteristics of the jaw bone, which could be responsible for the specific occurrence of MRONJ. These characteristics are not found in bones or in other parts of the body.

The teeth erupt from the jawbone, breaking the oral epithelium, allowing infectious factors, agents, and microbes in the oral cavity to directly invade the jaw bone through the gap between the epithelium and the teeth or via root canal.

1. The oral mucosa covering the jawbone is thin, and infection caused by mucosal injury spreads to the jawbone beneath the mucosa.
2. More than 800 types of resident bacteria (10^{11} to 10^{12} cm⁻³) inhabit dental plaque and can serve as a source of infection in the oral cavity.
3. Inflammation due to tooth decay, pulpitis, periapical lesions, or periodontal disease extends to the jawbone.
4. The jawbone is exposed to the oral cavity following invasive dental treatments including tooth extraction, leading to infection.

3.3. Suppression of bone turnover

BPs and denosumab inhibit osteoclast differentiation and function, increased apoptosis, and decreased bone resorption and remodeling [2, 13, 14]. Osteoclast differentiation and function act as an effective role for bone remodeling for skeletal sites, but MRONJ occurs only primarily within the alveolar bone of jaw [15]. An increased remodeling rate in the jaw may be considered for the differential predisposition of MRONJ to occur in the jaws compared with other bones in the axial or appendicular skeleton [5].

The relation between excessive suppression of C-terminal telopeptides of type I collagen (CTX), a bone resorption marker, and MRONJ incidence has been reported in several studies. However, a correlation between CTX level and severity of MRONJ has not been observed. There is still much controversy on whether a relationship exists between CTX levels and MRONJ incidence [16–18].

3.4. Infection/inflammation

The risk factors have been implicated dental disease or bacterial infection in MRONJ. Although dental extraction was performed in most reported cases of MRONJ, these teeth commonly

contracted with periodontal or periapical diseases. Inflammation or infection has long been considered an important component of MRONJ [19, 20].

3.5. Angiogenesis inhibition

Angiogenesis is a process that involves growth, migration, and differentiation of endothelial cells to form new blood vessels. Angiogenesis favorably influences tumor growth and influences tumor invasion of vessels, resulting in tumor metastasis. Osteonecrosis is classically considered as an interruption in vascular supply or avascular necrosis; therefore, it is not surprising that inhibition of angiogenesis is a leading hypothesis in MRONJ pathophysiology [21, 22].

3.6. Soft tissue toxicity

Although BPs primarily targets the osteoclast and bind to hydroxyapatite in bone, soft tissue toxicity has been reported. In contrast to BPs, no soft tissue toxicity has been reported with denosumab [23].

4. Diagnosis of MRONJ [5, 12]

MRONJ is definitively diagnosed when the following three conditions are met:

1. Patients have a history of treatment with BP, denosumab, and antiangiogenic agents.
2. Patients have no history of radiation therapy to the jaw. Bone lesions of MRONJ must be differentiated from cancer metastasis to the jawbone by histological examination.
3. Exposure of alveolar bone in the oral cavity, jaw, and/or face is continuously observed for longer than 8 weeks after first detection by a medical or dental expert, or the bone is palpable in the intra- or extra-oral fistula for longer than 8 weeks.

5. Staging of MRONJ

The clinical manifestations and staging of MRONJ are summarized in **Table 1**. Paresthesia of the chin, including the lower lip (Vincent's symptom), in patients treated with BP is an early sign of MRONJ, before alveolar bone exposure is detected [5, 12].

1. At risk

There is no apparent necrotic bone in asymptomatic patients who have been treated with intravenous or oral antiresorptive or antiangiogenic therapy.

	Staging of MRONJ	Treatment strategies
At risk	No apparent necrotic bone in patients who have been treated with oral or intravenous bisphosphonates	No treatment indicated and patient education
Stage 0	No clinical evidence of necrotic bone but nonspecific clinical findings, radiographic changes, and symptoms	Systemic management, including use of pain medication and antibiotics
Stage 1	Exposed and necrotic bone or fistula that probes to bone in patients who are asymptomatic and have no evidence of infection	Antibiotic mouth rinse, clinical follow-up on a quarterly basis, patient education, and review of indications for continued bisphosphonate therapy
Stage 2	Exposed and necrotic bone or fistula that probes to bone associated with infection as evidenced by pain and erythema in the region of exposed bone with or without purulent drainage	Symptomatic treatment with oral antibiotics, oral bacterial mouth rinse, pain control, debridement to relieve soft tissue irritation, and infection control
Stage 3	Exposed and necrotic bone or a fistula that probes to bone in patients with pain, infection, and >1 of the following: exposed and necrotic bone extending beyond the region of alveolar bone (i.e., inferior border and ramus in mandible, maxillary sinus, and zygoma in maxilla) resulting in pathologic fracture, extra-oral fistula, oral antral or oral nasal communication, or osteolysis extending to inferior border of the mandible or sinus floor	Antibacterial mouth rinse, antibiotic therapy and pain control, surgical debridement or resection for longer-term palliation of infection and pain

Table 1. Staging and treatment strategies.

2. Stage 0 (unexposed bone variant)

These patients have no clinical evidence of necrotic bone, but nonspecific clinical findings, radiographic changes, and symptoms.

3. Stage 1

Stage 1 is defined as asymptomatic exposed and necrotic bone or a fistula that probes to bone. These patients have no evidence of infection and may present with radiographic findings localized to the alveolar bone region.

4. Stage 2 (Figures 1–4)

Stage 2 is defined as exposed and necrotic bone or a fistula that probes to bone with evidence of infection. These patients are typically symptomatic. These patients also may present with radiographic findings which are localized to the alveolar bone region.

5. Stage 3 (Figures 5–11)

Stage 3 is defined as exposed and necrotic bone or fistula that probes to bone with evidence of infection and at least one of the following:

- (i) Exposed necrotic bone extending beyond the region of alveolar bone to the inferior border and ramus in the mandible, maxillary sinus, and zygoma in the maxilla.
- (ii) Pathologic fracture.

- (iii) Extra-oral fistula.
- (iv) Oral antral or oral nasal communication.
- (v) Osteolysis extending to the inferior border of the mandible or sinus floor.

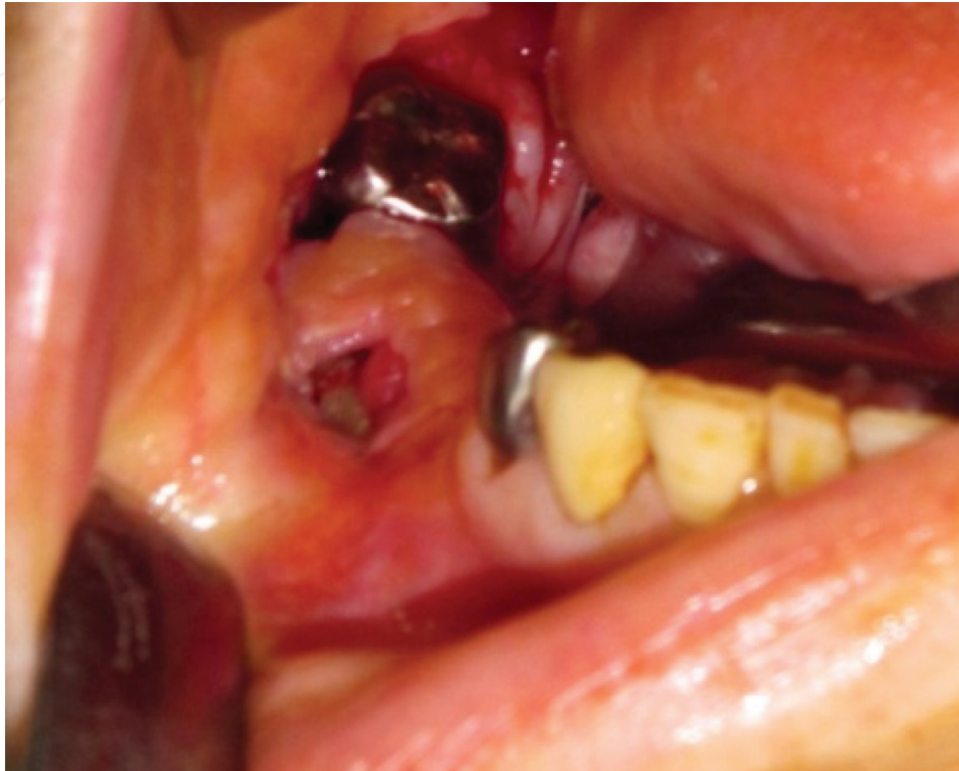

Figure 1. MRONJ (Stage 2). Intraoral examination. The necrotic bone with evidence of infection is exposed. The permission to use the picture of this figure from the Ishiyaku Publisher, Inc. in Japan.

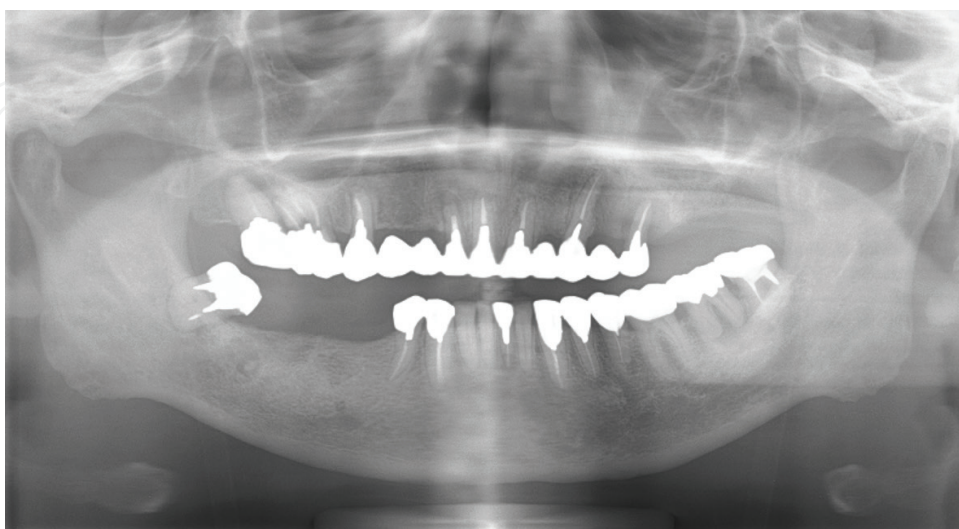


Figure 2. Panoramic X-ray. The permission to use the picture of this figure from the Ishiyaku Publisher, Inc. in Japan.

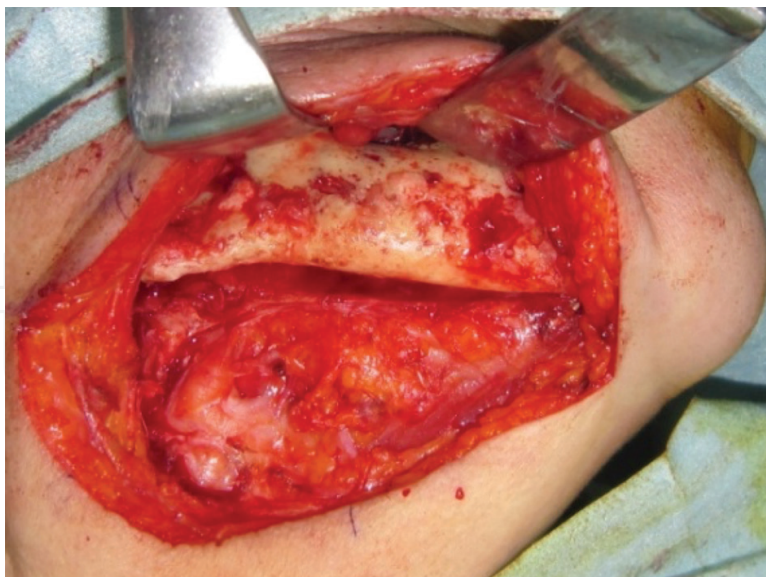


Figure 3. The segmental resection of the mandible is performed under general anesthesia. There is partial bone defect. The permission to use the picture of this figure from the Ishiyaku Publisher, Inc. in Japan.

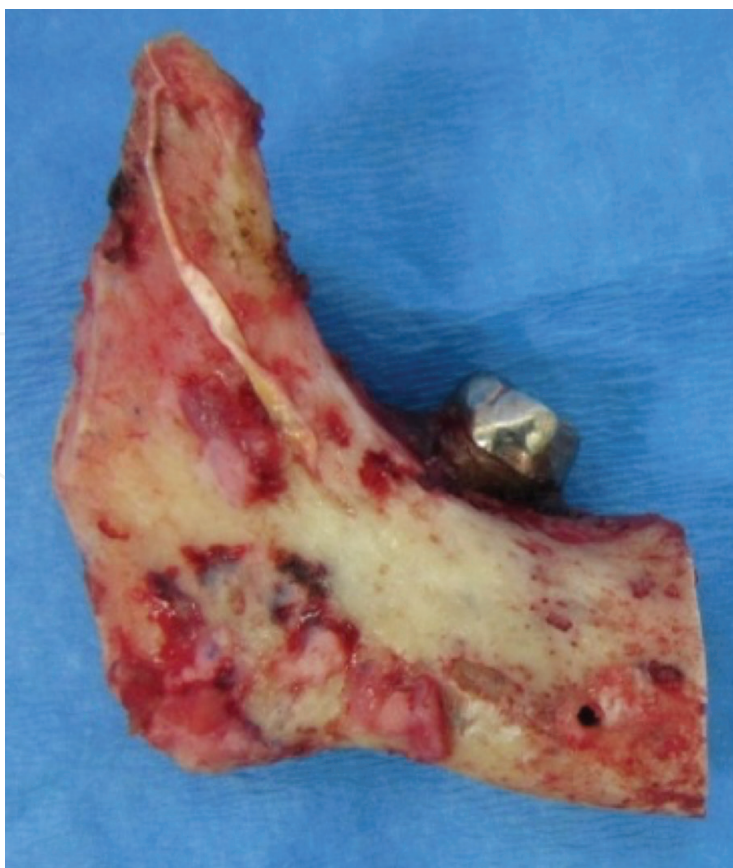


Figure 4. The resected specimen of the mandible. The permission to use the picture of this figure from the Ishiyaku Publisher, Inc. in Japan.

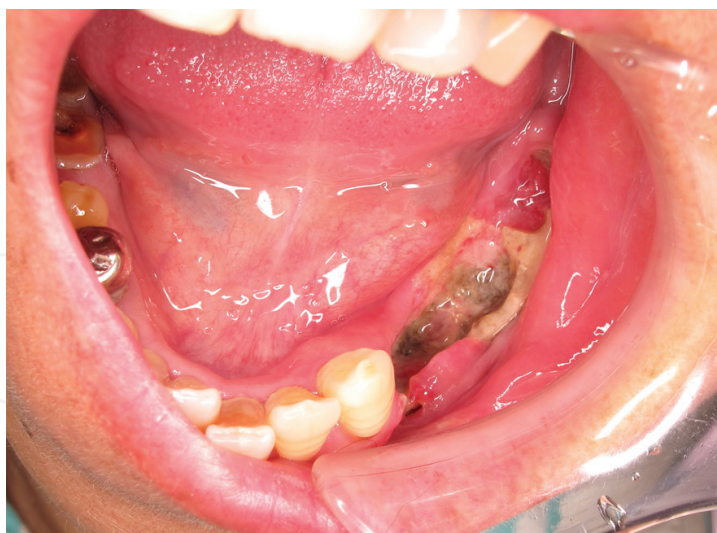

Figure 5. MRONJ (Stage 3). Intraoral examination. The necrotic bone with evidence of infection is exposed. The molar teeth are lost naturally. The permission to use the pictures of this figure from the Ishiyaku Publisher, Inc. in Japan.

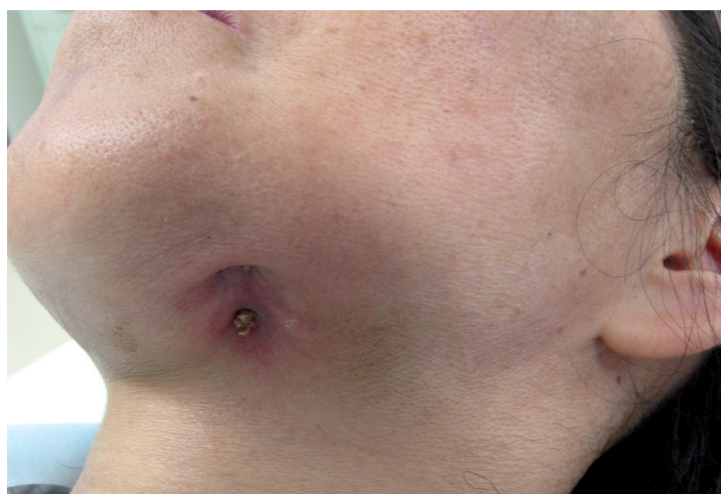

Figure 6. Necrotic bone extending beyond the region of alveolar bone is exposed, and extra-oral fistula is appeared. The permission to use the picture of this figure from the Ishiyaku Publisher, Inc. in Japan.

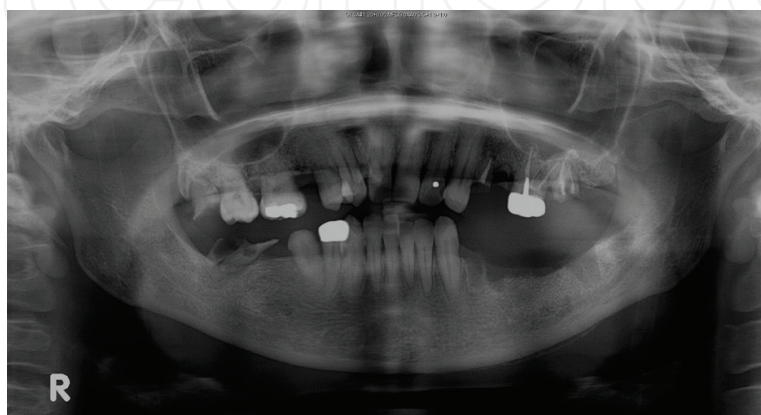

Figure 7. The panoramic X-ray. Regions of osteosclerosis involving the alveolar bone of lost molar teeth are depicted. The permission to use the picture of this figure from the Ishiyaku Publisher, Inc. in Japan.

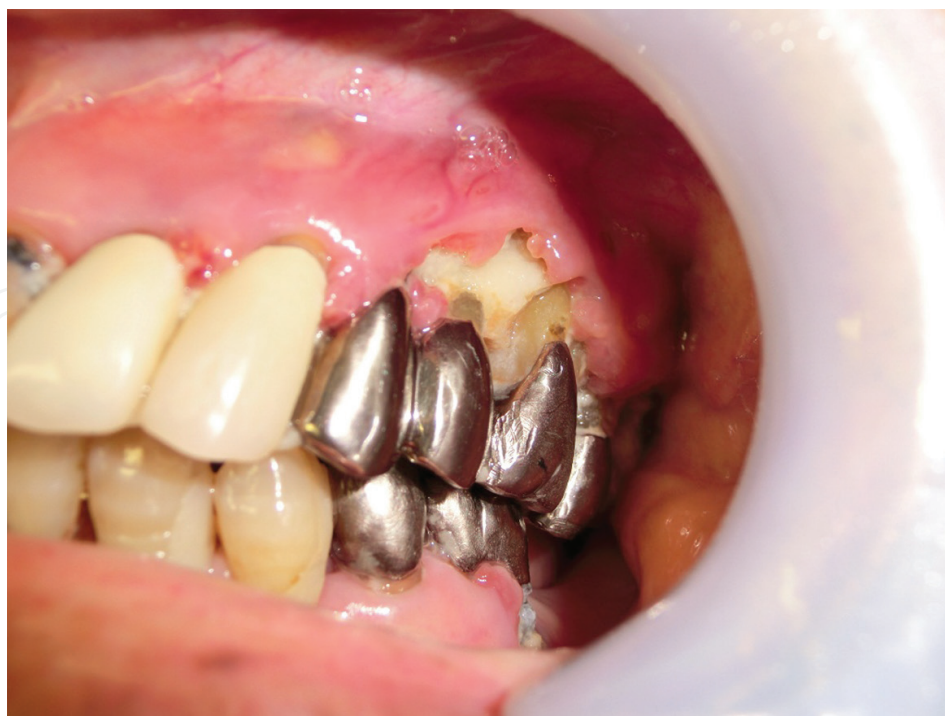

Figure 8. MRONJ (Stage 3). Sequester is extended to maxillary sinus. Oral antral communication is made. The permission to use the picture of this figure from the Ishiyaku Publisher, Inc. in Japan.

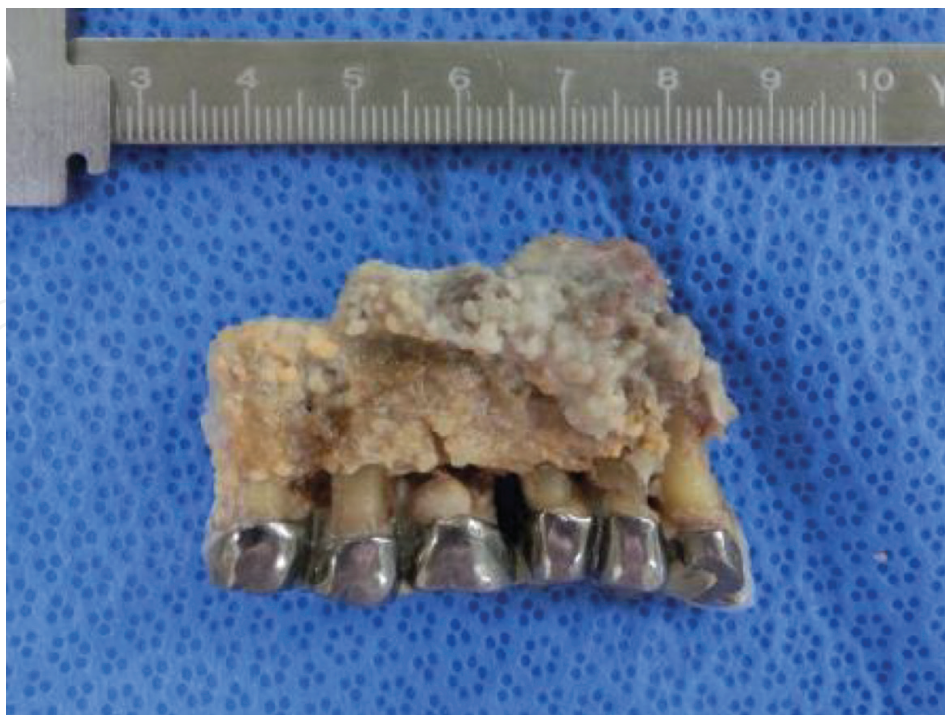

Figure 9. The sequester and six teeth are removed under local anesthesia. The oral antral communication is made at the anterior part of defect. The permission to use the picture of this figure from the Ishiyaku Publisher, Inc. in Japan.

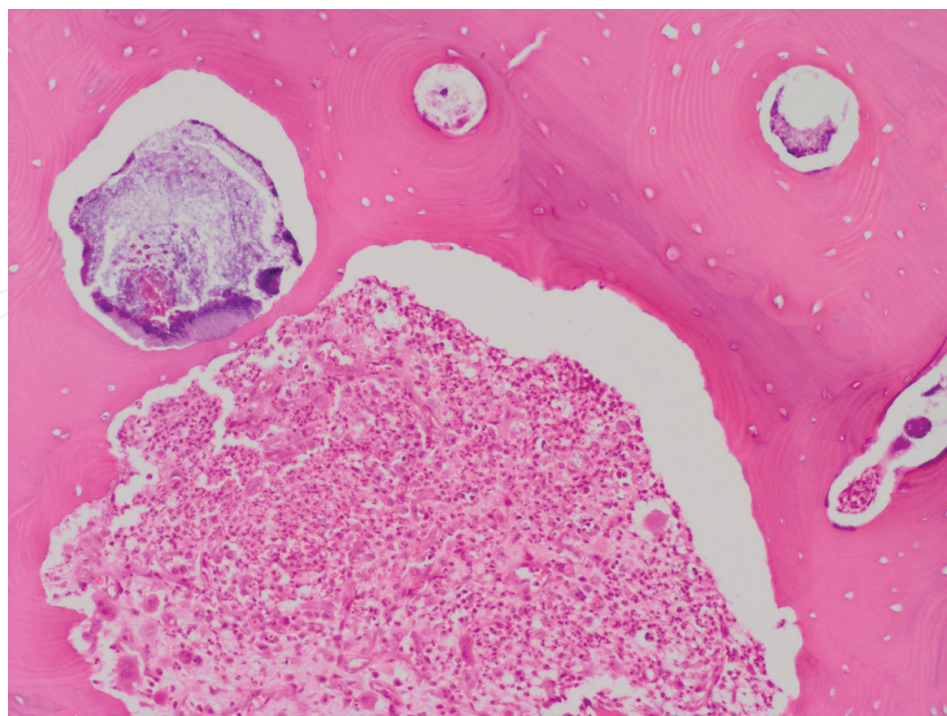


Figure 10. The necrotic bone and infiltrating inflammatory cells. The stimulating micrograms are observed (HE staining: 100×). The permission to use the picture of this figure from the Ishiyaku Publisher, Inc. in Japan.

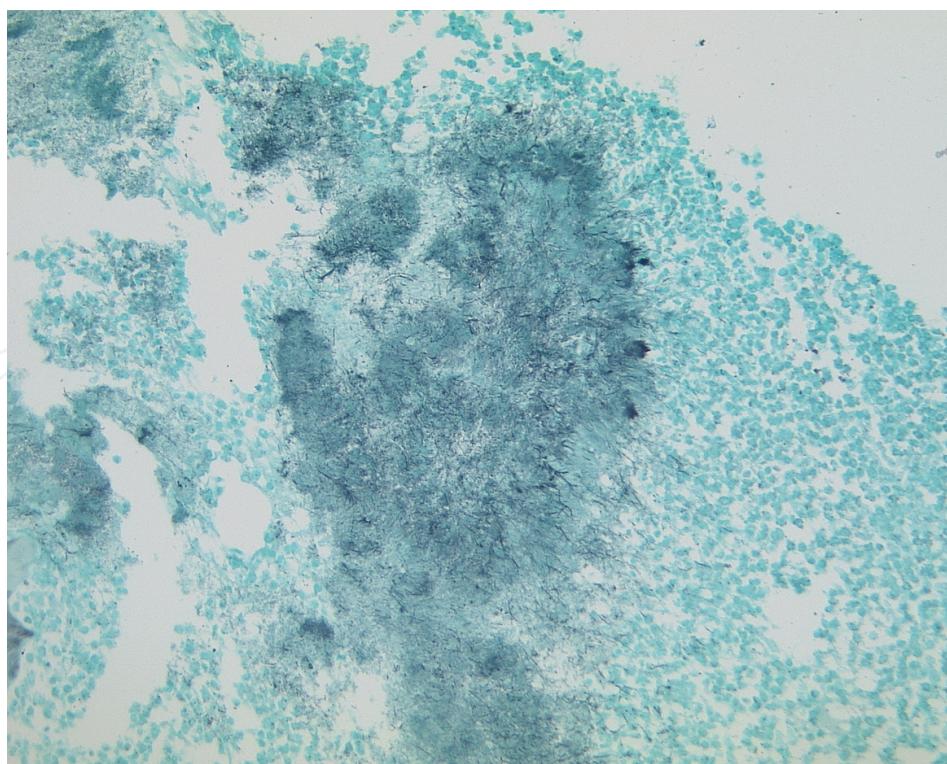


Figure 11. Actinomycetes stained with Grocott in the granulation tissue (Grocott staining). The permission to use the picture of this figure from the Ishiyaku Publisher, Inc. in Japan.

6. Treatment strategies for MRONJ

6.1. Treatment goals

The treatment goals for patients at risk of developing or who have MRONJ are prioritization and support of continued cancer treatment in patients receiving intra venous antiresorptive and antiangiogenic therapy [5, 12]. Cancer patients can benefit greatly from the therapeutic effect from antiresorptive agents by controlling SREs.

Maintenance of patient quality of life (QOL) is done by relieving symptoms, including pain, pus discharge, and paresthesia, and by control of infection. Moreover, patient education and routine follow-up for oral health care are needed by dental expert.

6.2. Stage-specific treatment strategies

Therapeutic strategies based on MRONJ stages are summarized in **Table 1** [5].

Treatment of MRONJ varies with the stages of the disease. However, regardless of the stage, the protocol must include treating dental and periodontal diseases, maintaining and improving oral health with antibacterial mouthwash, and systemically administering antibacterial agents. To ensure success with surgical treatment, the complete elimination of MRONJ lesions and closure of surgical wounds is critical, along with systemic administration of antibacterial agents. For patients with a history of malignant tumors, histopathological examination of all necrotic bones removed will be needed to exclude the possibility that excised MRONJ lesions are tumor metastases to the jaw [12].

1. At risk

These patients have no exposed bone and requirement of any treatment. They should be informed of the risks of developing to MRONJ.

2. Stage 0

These patients receive the treatment of symptomatic disease and conservative management of caries and periodontal disease. Systemic management, including use of pain medication and antibiotics are indicated. These patients should be prevented of progression to a higher stage.

3. Stage 1

These patients are indicated with medical management of the use for oral antimicrobial rinses, such as chlorhexidine 0.12%. No immediate surgery is required.

4. Stage 2

These patients are indicated with oral antimicrobial rinses in combination with administering antibiotic therapy. The debridement to relieve soft tissue irritation and infection control is needed.

5. Stage 3

These patients are benefit from debridement, including resection, in combination with antibiotic therapy. Symptomatic patients with stage 3 may require resection and immediate reconstruction with reconstruction plate or an obturator.

Regardless of the disease stage, mobile bony sequestra should be removed to facilitate soft tissue healing. The extraction of symptomatic teeth within exposed necrotic bone should be considered because it is unlikely that the extraction will exacerbate the established necrotic process.

6.3. Treatment with parathyroid hormone (teriparatide)

Systemic administration of low doses of recombinant parathyroid hormone (teriparatide) has been shown to resolve ONJ symptoms and promote a cure. Japanese studies have also shown improved bone regeneration and healing in ONJ lesions with the use of teriparatide [24, 25]. It should also be noted that administration of teriparatide is contraindicated in patients with metastatic bone tumors, and its total dose and period of administration are restricted as well.

7. Risk factors for MRONJ

Proposed risk factors for MRONJ are listed in **Table 2** [12]. Among these factors, invasive dental treatments, such as tooth extraction, dental implant, or apical/periodontal surgery, are definitive local risk factors for MRONJ.

7.1. Dental implants and MRONJ [12]

Recent reports suggested that dental implant procedures performed in patients with cancer or osteoporosis prior to treatment with BPs are not likely associated with subsequent occurrence of MRONJ, if oral health is appropriately managed. However, dental implant performed during or after BP treatment is a potential risk factor for MRONJ [26, 27].

It is unknown whether dental implant is a risk factor in patients receiving denosumab. Implants are not advised for cancer patients who are receiving antiresorptive treatment, and alternative dental measures are recommended. On the other hand, in patients with osteoporosis, dental implant may be performed in cases in which physicians and dentists agree that dental implants are essential for improving the systemic and oral health of patients [12].

7.2. Coadministered agents and MRONJ

Antiangiogenic agents and tyrosine kinase inhibitors, which are essentially administered as adjuvants in the treatment of cancer patients, have been shown to cause MRONJ, albeit very rarely, when used alone, or to increase the incidence of MRONJ when used concomitantly with BP or denosumab [28].

1. Local
Invasive dental treatments including bone (e.g., tooth extraction, dental implants, apical/periodontal surgery)
Ill-fitting dentures and excessive bite force
Poor sanitation in the oral cavity, periodontal disease, and gingival abscess inflammatory disease, including apical periodontitis
Common site: mandible > maxilla, mandibular torus, palatal torus, and mylohyoid line torus
Root canal and orthodontic treatments are not considered to be risk factors
2. Antiresorptive agents
Nitrogen-containing bisphosphonates (BPs) > nonnitrogen-containing BPs
Denosumab
Drugs for malignant tumor > drug for osteoporosis
Drug for malignant tumor (Zometa, Aredia, Teirot, Ranmark)
Drug for osteoporosis (Didronel, Fosamac, Bonalon, Actonel, Benet, Bonoteo, Recalbon, Bonbiba and Pralia)
Dose and administration period
3. Systemic
Cancer (breast, prostate, lung, renal and colon cancer, multiple myeloma, and other cancers)
Diabetes, rheumatoid arthritis, hypocalcemia, hypoparathyroidism, osteomalacia, vitamin D deficiency, renal dialysis, anemia, and Paget's disease of bone
4. Congenital
Single-nucleotide polymorphisms (SNPs) in MMP-2 and cytochrome P450-2C genes
5. Lifestyle
Smoking, drinking alcohol, and obesity
6. Coadministered agents
Anticancer agents, corticosteroid, and erythropoietin
Angiogenic inhibitors (e.g., thalidomide, sunitinib, and lenalidomide)
Tyrosine kinase inhibitors

Table 2. Risk factors for MRONJ.

8. Prevention of MRONJ

To minimize the development of ONJ in patients at risk, regular dental examinations are encouraged. Oral hygiene should be improved and local infection is managed as early as possible. The use of antibiotics before and after oral surgical procedures has been demonstrated to lower the risk of ONJ [29, 30]. Antimicrobial mouth rinses may also be useful in lowering the risk of ONJ [30, 31].

All necessary oral surgeries in oncology patients should ideally be completed before the initiation of high-dose antiresorptive therapy. For oncology patient requiring high-dose intravenous BPs

or high-dose denosumab, dental radiographs should be completed before medication begins. Any invasive dental procedure including dental extractions or implants should ideally be completed before the initiation of antiresorptive therapy. Nonurgent procedures should be delayed if necessary. If ONJ develops, it is recommended that the antiresorptive drug therapy should be withheld until soft tissue closure with a well-epithelialized mucosa is achieved [32].

There is currently no evidence that interruption of drug therapy in patients requiring dental procedures reduces the risk of ONJ or the progression of the disease [29]. (BPs) that have long-term skeletal retention and cessation for weeks or months may not impact remodeling significantly. However, BPs do have increased skeletal uptake at the sites of local bone injury, and withholding BP therapy following oral surgery may be of use in reducing the local deposition in the mandible and maxilla after oral surgery. In individuals with significant risk factors for ONJ, including oncology patients on high-dose antiresorptive therapy as well as those individuals with multiple risk factors for ONJ, it may be of benefit to withhold BP or denosumab therapy following oral surgery until soft tissue healing occurs [32].

In determining the suitability of drug interruption, it is necessary to weigh the risks of ONJ with the risk of skeletal-related events in oncology patients and the risk of fracture in those with osteoporosis. The decision to hold therapy should be jointly made between the oral surgeon and the physician treating the underlying osteoporosis. Patients with osteoporosis receiving BP or denosumab may continue with therapy if a dental procedure including extraction and implant surgery is required [4]. The decision to continue or hold antiresorptive therapy should be made by the dental health provider in consultation with the patient's physician [32].

8.1. Dental treatments and discontinuation of antiresorptive therapy

8.1.1. Dental treatments in patients who are to receive antiresorptive therapy

Before initiation of antiresorptive therapy, it is wise to request that patients visit a dentist for control of oral health to prevent the occurrence of ONJ. Ideally, all dental treatments should be completed 2 weeks before starting antiresorptive treatment. However, in the event that antiresorptive treatment cannot be delayed due to progression of bone metastases or high risk of fracture, administration of antiresorptive agents in parallel with dental treatments may be acceptable. During antiresorptive treatment, patients should be instructed by physicians to adhere to routine dental visits for oral examination [12].

8.1.2. Dental treatments in patients receiving antiresorptive agents

1. Discontinuation of BPs before starting dental treatment

There is a considerable controversy around the question of whether discontinuation (drug holiday) of BPs for a certain period of time before invasive dental treatment is effective in preventing or reducing occurrence of BRONJ. A BP drug holiday before starting invasive dental treatment is not logically supported from background information [12]. The American Association of Oral and Maxillofacial (AAOMS) and

other groups have described an increased incidence of BRONJ who were treated with BPs for longer than 4 years. From these results, AAOMS recommended that, for patients receiving antiresorptive therapy for longer than 4 years and who have low fracture risk but potentially high risk for BRONJ, discontinuation of antiresorptive treatment for approximately 2 months before invasive dental treatment should be considered, in consultation with the physician [5]. Thus, no consensus has yet been reached regarding whether a BP drug holiday before invasive dental treatment is appropriate and necessary for prevention of BRONJ [12].

2. Suggested dental treatment in patients with cancer and osteoporosis who are receiving BPs

Dental experts will need to educate patients on the importance of daily oral sanitation, including how to clean the oral cavity after each meal and rinse their mouths with antibacterial mouthwash. Subsequently, dentists begin conservative dental treatment without discontinuation of BPs. In the case that invasive dental treatment such as removal of the teeth responsible for BRONJ is inevitable, however, antibacterial agents will be administered to the patients in advance, and invasive dental treatments should be restricted to the minimum extent and area possible to avoid discontinuation of BP treatment [12].

3. Suggested dental treatment in patients with cancer and osteoporosis who are receiving denosumab

For cancer patients with bone metastases, studies have found that the benefits of denosumab are highly superior to those of zoledronic acid [11]. The incidence of DRONJ and BRONJ, however, was found to be similar in patients with cancer [3]. Similar to case of patients treated with BPs, dentists perform conservative dental treatment without drug holiday. Invasive dental treatments, if inevitable, can be conducted without a drug holiday following appropriate infection control. Given that denosumab is administered to osteoporotic patients once every 6 months and the half-life of denosumab is approximately 1 month, there is an ample window of time within the 6-month interval to plan for dental treatments [12].

4. Discontinuation of antiresorptive therapy after invasive dental treatment

Antiresorptive agents may interfere with the healing of surgical wounds, especially epithelialization [33]. The decision to continue or discontinue antiresorptive treatment must be made jointly by the physician and dentist based on fracture risk, and the status of healing of surgical wounds in the oral cavity.

5. Timing of resumption of antiresorptive therapy

The time at which to resume antiresorptive administration after a drug holiday is dependent on the balance between the healing of surgical wounds and control of the primary disease. If fracture risk or bone metastasis is well-controlled, resumption of antiresorptive treatment is recommended approximately 2 months after invasive dental procedure, when the damaged alveolar bones are expected to have healed. However, if fracture risk is high or bone metastasis progresses during the drug holiday and resumption of antiresorptive therapy is urgent, it may resume antiresorptive drug with no sign of infection around surgical wounds and epithelialization of the surgical site at 2 weeks after invasive dental treatment, when epithelialization of the surgical site is almost complete, may be the earliest possibility [12].

9. Case report of the patient of brain abscesses caused by MRONJ [34]

Reports of brain abscesses caused by MRONJ are very rare. The case of a 76-year-old man with terminal-stage prostatic carcinoma and a brain abscess caused by MRONJ at the maxilla with conscious loss is presented here. The zoledronic acid and denosumab were administered for bone metastasis. In the case of maxillary, MRONJ spreads beyond the maxillary sinus into the ethmoid sinus and into the brain. For the brain abscess, an antibiotic regimen based on ceftriaxone and metronidazole and a sequestrectomy contributed to a successful outcome (Figures 12–15).

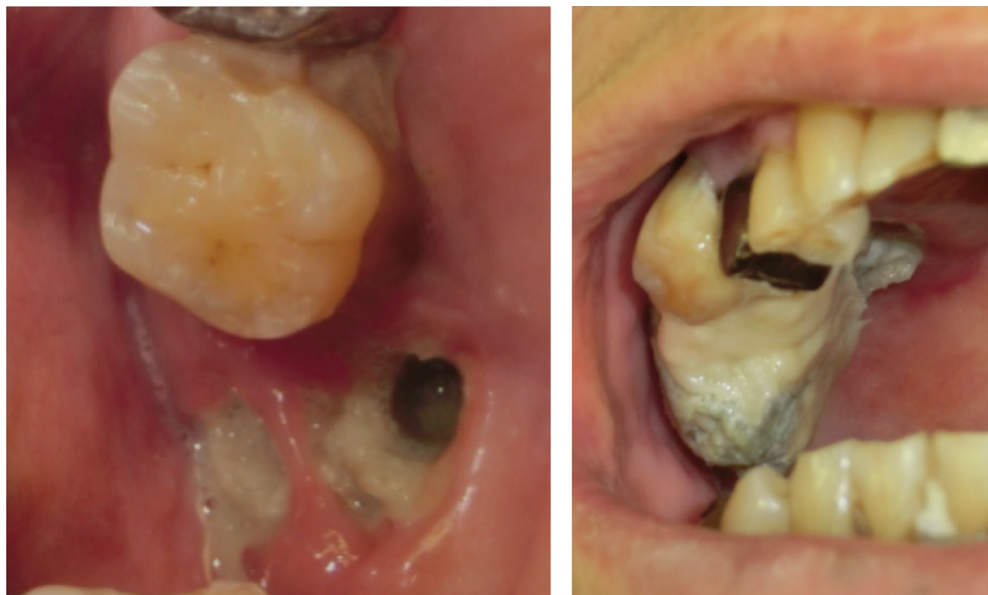

Figure 12. Intra-oral examination. The 17 was lost naturally 2 months from the first visit and sequester was revealed. The sequester expanded in 8 months from socket.

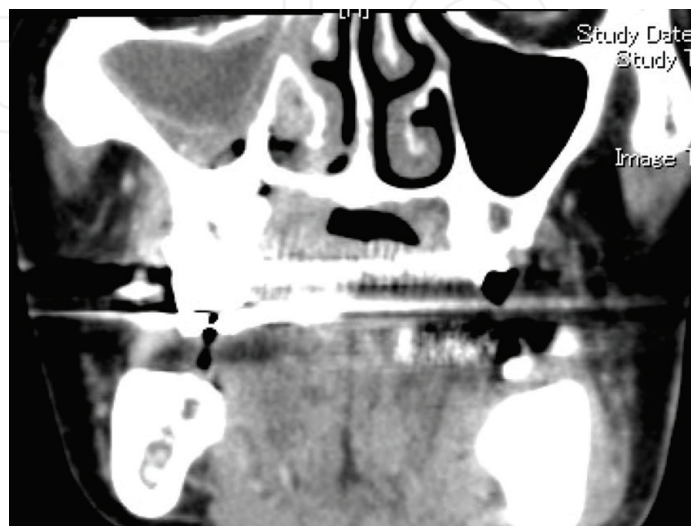


Figure 13. Preoperative CT. Abscess formation is revealed in right maxillary sinus.

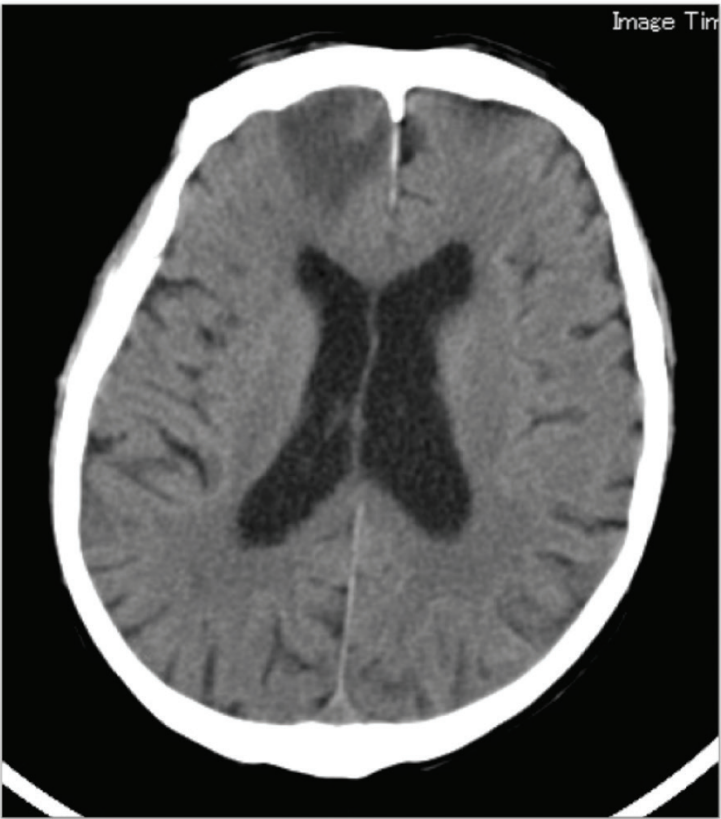


Figure 14. CT after conscious lost in ER. The absorption image in right frontal lobe is revealed.

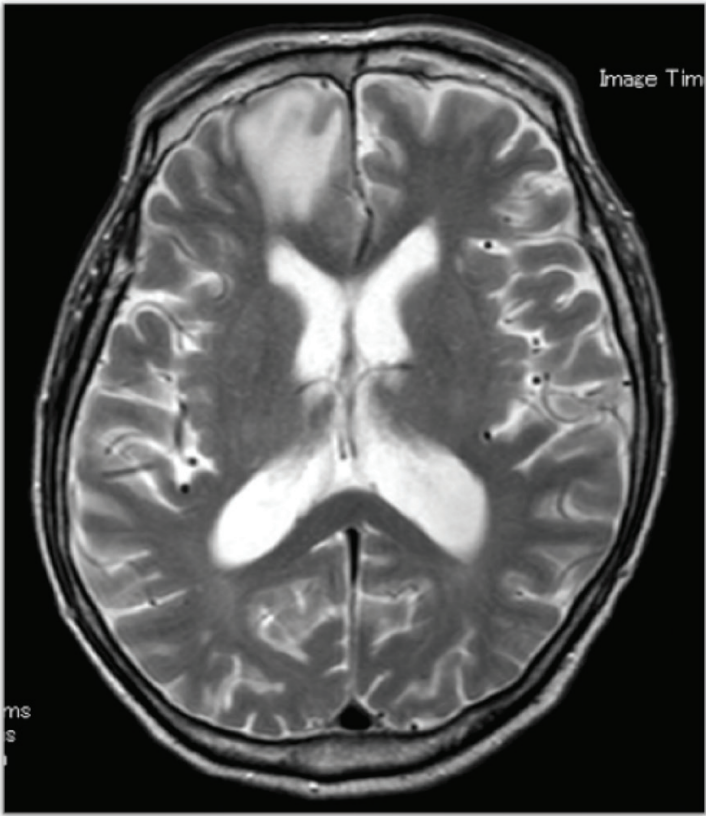


Figure 15. MRI (T2WI) after conscious lost in ER. Right frontal lobe abscess is depicted.

10. Conclusion

Medication-related osteonecrosis of the jaw (MRONJ) is a common side effect of antiresorptive drugs, which are administered to cancer patients for bone metastasis, multiple myeloma, and osteoporosis. All necessary oral surgeries in oncology patients should ideally be completed before the initiation of high-dose antiresorptive therapy, and to minimize the development of ONJ in patients at risk, regular dental examinations are encouraged. Oral hygiene should be improved and local infection should be managed as early as possible.

Author details

Kenji Yamagata*, Fumihiko Uchida, Naomi Kanno, Toru Yanagawa and Hiroki Bukawa

*Address all correspondence to: y-kenji@md.tsukuba.ac.jp

Department of Oral and Maxillofacial Surgery, Faculty of Medicine, University of Tsukuba, Tsukuba, Japan

References

- [1] Marx RE. Pamidronate (Aredia) and zoledronate (Zometa) induced avascular necrosis of the jaws: a growing epidemic. *J Oral Maxillofac Surg.* 2003;**61**(9):1115-7.
- [2] Baron R, Ferrari S, Russell RGG. Denosumab and bisphosphonates: different mechanisms of action and effects. *Bone.* 2011;**48**(4):677-92.
- [3] Saad F, Brown JE, Van Poznak C, Ibrahim T, Stemmer SM, Stopeck AT, et al. Incidence, risk factors, and outcomes of osteonecrosis of the jaw: integrated analysis from three blinded active-controlled phase III trials in cancer patients with bone metastases. *Ann Oncol.* 2012;**23**(5):1341-7.
- [4] Hellstein JW, Adler RA, Edwards B, Jacobsen PL, Kalmar JR, Koka S, et al. Managing the care of patients receiving antiresorptive therapy for prevention and treatment of osteoporosis: executive summary of recommendations from the American dental association council on scientific affairs. *J Am Dent Assoc.* 2011;**142**(11):1243-51.
- [5] Ruggiero SL, Dodson TB, Fantasia J, Goodday R, Aghaloo T, Mehrotra B, et al. American association of oral and maxillofacial surgeons position paper on medication-related osteonecrosis of the jaw—2014 update. *J Oral Maxillofac Surg.* 2014;**72**(10):1938-56.
- [6] Delmas PD. The use of bisphosphonates in the treatment of osteoporosis. *Curr Opin Rheumatol.* 2005;**17**(4):462-6.
- [7] Cummings SR, San Martin J, McClung MR, Siris ES, Eastell R, Reid IR, et al. Denosumab for prevention of fractures in postmenopausal women with osteoporosis. *N Engl J Med.* 2009;**361**(8):756-65.

- [8] Papapoulos S, Chapurlat R, Libanati C, Brandi ML, Brown JP, Czerwiński E, et al. Five years of denosumab exposure in women with postmenopausal osteoporosis: results from the first two years of the FREEDOM extension. *J Bone Miner Res.* 2012;**27**(3):694-701.
- [9] Hinson AM, Smith CW, Siegel ER, Stack BC. Is bisphosphonate-related osteonecrosis of the jaw an infection? A histological and microbiological ten-year summary. *Int J Dent.* 2014;**2014**:452-737.
- [10] Khan AA, Morrison A, Hanley DA, Felsenberg D, McCauley LK, O’Ryan F, et al. Diagnosis and management of osteonecrosis of the jaw: a systematic review and international consensus. *J Bone Miner Res.* 2015;**30**(1):3-23.
- [11] Lipton A, Fizazi K, Stopeck AT, Henry DH, Brown JE, Yardley DA, et al. Superiority of denosumab to zoledronic acid for prevention of skeletal-related events: a combined analysis of 3 pivotal, randomised, phase 3 trials. *Eur J Cancer.* 2012;**48**(16):3082-92.
- [12] Japanese Allied Committee on Osteonecrosis of the Jaw T, Yoneda T, Hagino H, Sugimoto T, Ohta H, Takahashi S, et al. Antiresorptive agent-related osteonecrosis of the jaw: position paper 2017 of the Japanese allied committee on osteonecrosis of the jaw. *J Bone Miner Metab.* 2017; **35**(1): 6-19.
- [13] Russell RGG, Watts NB, Ebetino FH, Rogers MJ. Mechanisms of action of bisphosphonates: similarities and differences and their potential influence on clinical efficacy. *Osteoporos Int.* 2008;**19**(6):733-59.
- [14] Lacey DL, Boyle WJ, Simonet WS, Kostenuik PJ, Dougall WC, Sullivan JK, et al. Bench to bedside: elucidation of the OPG-RANK-RANKL pathway and the development of denosumab. *Nat Rev Drug Discov.* 2012;**11**(5):401-19.
- [15] Aghaloo TL, Kang B, Sung EC, Shoff M, Ronconi M, Gotcher JE, et al. Periodontal disease and bisphosphonates induce osteonecrosis of the jaws in the rat. *J Bone Miner Res.* 2011;**26**(8):1871-82.
- [16] Kwon Y-D, Ohe J-Y, Kim D-Y, Chung D-J, Park Y-D. Retrospective study of two biochemical markers for the risk assessment of oral bisphosphonate-related osteonecrosis of the jaws: can they be utilized as risk markers? *Clin Oral Implants Res.* 2011;**22**(1):100-5.
- [17] Kwon Y-D, Kim D-Y, Ohe J-Y, Yoo J-Y, Walter C. Correlation between serum C-terminal cross-linking telopeptide of type I collagen and staging of oral bisphosphonate-related osteonecrosis of the jaws. *J Oral Maxillofac Surg.* 2009;**67**(12):2644-8.
- [18] Bagan J V., Jiménez Y, Gómez D, Sirera R, Poveda R, Scully C. Collagen telopeptide (serum CTX) and its relationship with the size and number of lesions in osteonecrosis of the jaws in cancer patients on intravenous bisphosphonates. *Oral Oncol.* 2008;**44**(11):1088-9.
- [19] Ripamonti CI, Maniezzo M, Campa T, Fagnoni E, Brunelli C, Saibene G, et al. Decreased occurrence of osteonecrosis of the jaw after implementation of dental preventive measures

in solid tumour patients with bone metastases treated with bisphosphonates. The experience of the National Cancer Institute of Milan. *Ann Oncol Off J Eur Soc Med Oncol*. 2009;**20**(1):137-45.

- [20] Dimopoulos MA, Kastritis E, Bamia C, Melakopoulos I, Gika D, Roussou M, et al. Reduction of osteonecrosis of the jaw (ONJ) after implementation of preventive measures in patients with multiple myeloma treated with zoledronic acid. *Ann Oncol*. 2008;**20**(1):117-20.
- [21] Yamashita J, McCauley LK. Antiresorptives and osteonecrosis of the jaw. *J Evid Based Dent Pract*. 2012;**12**(3 Suppl):233-47.
- [22] Landesberg R, Woo V, Cremers S, Cozin M, Marolt D, Vunjak-Novakovic G, et al. Potential pathophysiological mechanisms in osteonecrosis of the jaw. *Ann N Y Acad Sci*. 2011;**1218**(1):62-79.
- [23] Reid IR, Bolland MJ, Grey AB. Is bisphosphonate-associated osteonecrosis of the jaw caused by soft tissue toxicity? *Bone*. 2007;**41**(3):318-20.
- [24] Ohbayashi Y, Miyake M, Sawai F, Minami Y, Iwasaki A, Matsui Y. Adjunct teriparatide therapy with monitoring of bone turnover markers and bone scintigraphy for bisphosphonate-related osteonecrosis of the jaw. *Oral Surg Oral Med Oral Pathol Oral Radiol*. 2013;**115**(4):e31-7.
- [25] Kakehashi H, Ando T, Minamizato T, Nakatani Y, Kawasaki T, Ikeda H, et al. Administration of teriparatide improves the symptoms of advanced bisphosphonate-related osteonecrosis of the jaw: preliminary findings. *Int J Oral Maxillofac Surg*. 2015;**44**(12):1558-64.
- [26] Matsuo A, Hamada H, Takahashi H, Okamoto A, Kaise H, Chikazu D. Evaluation of dental implants as a risk factor for the development of bisphosphonate-related osteonecrosis of the jaw in breast cancer patients. *Odontology*. 2016;**104**(3):363-71.
- [27] Holzinger D, Seemann R, Matoni N, Ewers R, Millesi W, Wutzl A. Effect of dental implants on bisphosphonate-related osteonecrosis of the jaws. *J Oral Maxillofac Surg*. 2014;**72**(10):1937.e1-8.
- [28] Ramírez L, López-Pintor RM, Casañas E, Arriba L de, Hernández G. New non-bisphosphonate drugs that produce osteonecrosis of the jaws. *Oral Health Prev Dent*. 2015;**13**(5):385-93.
- [29] Montefusco V, Gay F, Spina F, Miceli R, Maniezzo M, Teresa Ambrosini M, et al. Antibiotic prophylaxis before dental procedures may reduce the incidence of osteonecrosis of the jaw in patients with multiple myeloma treated with bisphosphonates. *Leuk Lymphoma*. 2008;**49**(11):2156-62.
- [30] Kunchur R, Goss A. The oral health status of patients on oral bisphosphonates for osteoporosis. *Aust Dent J*. 2008;**53**(4):354-7.

- [31] Ferlito S, Puzzo S, Liardo C. Preventive protocol for tooth extractions in patients treated with zoledronate: a case series. *J Oral Maxillofac Surg*. 2011;**69**(6):e1-4.
- [32] Khan AA, Morrison A, Kendler DL, Rizzoli R, Hanley DA, Felsenberg D, et al. Case-based review of osteonecrosis of the jaw (ONJ) and application of the international recommendations for management from the international task force on ONJ. *J Clin Densitom*. 2016;**20**(1):8-24(Article in press).
- [33] Allen MR. Medication-related osteonecrosis of the jaw. *Oral Maxillofac Surg Clin North Am*. 2015;**27**(4):497-508.
- [34] Yamagata K, Nagai H, Baba O, Uchida F, Kanno N, Hasegawa S, et al. A Case of brain abscess caused by medication-related osteonecrosis of the jaw. *Case Rep Dent*. 2016;**2016**:1-4.