

We are IntechOpen, the world's leading publisher of Open Access books Built by scientists, for scientists

6,900

Open access books available

186,000

International authors and editors

200M

Downloads

Our authors are among the

154

Countries delivered to

TOP 1%

most cited scientists

12.2%

Contributors from top 500 universities



WEB OF SCIENCE™

Selection of our books indexed in the Book Citation Index
in Web of Science™ Core Collection (BKCI)

Interested in publishing with us?
Contact book.department@intechopen.com

Numbers displayed above are based on latest data collected.
For more information visit www.intechopen.com



Peripheral Nerve Entrapment and their Surgical Treatment

Vicente Vanaclocha-Vanaclocha,

Nieves Sáiz-Sapena, Jose María Ortiz-Criado and

Nieves Vanaclocha

Additional information is available at the end of the chapter

<http://dx.doi.org/10.5772/67946>

Abstract

Nerves pass from one body area to another through channels made of connective tissue and/or bone. In these narrow passages, they can get trapped due to anatomic abnormalities, ganglion cysts, muscle or connective tissue hypertrophy, tumours, trauma or iatrogenic mishaps. Nearly all nerves can be affected. The clinical presentation is pain, paraesthesia, sensory and motor power loss. The specific clinical features will depend on the affected nerve and on the chronicity, severity, speed and mechanism of compression. Its incidence is higher under some occupations and in some systemic conditions: diabetes mellitus, hypothyroidism, acromegaly, alcoholism, oedema and inflammatory diseases. The diagnosis is suspected with the clinical presentation and provocative clinical test, being confirmed with electrodiagnostic and/or ultrasonographic studies. Magnetic Resonance Studies (MRI) rule out ganglion cysts or tumours. Conservative medical treatment is often sufficient. In refractory ones, surgical decompression should be performed before nerve damage and muscle atrophy are irreversible. The 'double crush' syndrome happens when a peripheral nerve is compressed at more than one point along its trajectory. In cases with marked muscle atrophy, a 'supercharge end-to-side' nerve transfer can be added to the decompression. After decompression in those few cases with refractory pain, a nerve neurostimulator can be applied.

Keywords: entrapment neuropathy, compression neuropathy, carpal tunnel syndrome, cubital tunnel syndrome, meralgia paraesthetica, cheiralgia paraesthetica, peroneal nerve entrapment, ulnar tunnel syndrome, radial tunnel syndrome, tarsal tunnel syndrome

1. Introduction

Nerves pass from one body area or cavity to another through holes and channels made of connective tissue and/or a bone channel, be it total (mental nerve) or partial (carpal tunnel). In these narrow passages, they can get trapped and/or injured due to congenital anatomical abnormalities, muscle or connective tissue hypertrophy, ganglion cysts, tumours, trauma or iatrogenic mishaps. Nearly all nerves can suffer an entrapment syndrome. Not all have the same incidence, some being very common (i.e. carpal tunnel) [1] and some exceedingly rare (i.e. tarsal tunnel) [2].

Entrapment neuropathies results in pain, paraesthesia and muscle power loss in the distribution of a peripheral nerve. With time muscle atrophy and skin trophic changes will appear. The clinical presentation will depend on the specific affected nerve, the chronicity, severity, speed and mechanism of compression [3, 4].

Nerve entrapment incidence is higher under some systemic conditions: diabetes mellitus, hypothyroidism, acromegaly, chronic alcoholism, extensive oedema and systemic inflammatory diseases [4]. Some occupations are associated with specific peripheral nerve entrapment syndromes. For example, occupations requiring repetitive wrist or finger movements or handling of vibrating tools have a higher incidence of carpal tunnel syndrome (CTS) [5–7].

Clinical presentation and provocative tests will suggest a diagnosis [3] confirmed or not with electrodiagnostic or ultrasonographic studies [4, 8]. Moreover, electrodiagnostic studies are also helpful to stage the severity and to rule out other confounding conditions (i.e. carpal tunnel and C₇ radiculopathy, peroneal nerve compression vs. L₅ radiculopathy) [3, 9] or generalized diseases (i.e. diabetic peripheral neuropathy) [9, 10]. MRI studies often show changes, ganglion cysts or tumours [11, 12] but the ultrasonography is less costly and more easily available [13].

Conservative treatment is sufficient in many cases (i.e. Saturday night palsy) but otherwise surgical decompression should be considered before irreversible peripheral nerve damage and muscle atrophy are established [3, 4, 8].

A nerve can be compressed at more than one single point, exacerbating the effects [14, 15]. This is called the '*double crash*' syndrome and is common in some systemic diseases, particularly in diabetes mellitus [16].

In cases with advanced muscle atrophy, a '*supercharge end-to-side*' nerve transfer is an option. After thorough decompression, a nearby healthy nerve is sectioned and sutured to the side of the previously compressed nerve, ideally distal to the entrapment point. The motor axons of the healthy nerve will grow inside of the damaged one much faster than the damaged axons of the damaged nerve. So, the healthy axons of the healthy nerve will keep the muscle alive while the axons of the damaged nerve recover [4]. This has been performed between the *pronator quadratus* (PQ) nerve branch and the motor fascicle

of the ulnar nerve (UN) at the forearm, between the flexor *digitorum superficialis* (FDS) and the anterior *interosseous* syndrome (AIN), between the triceps long head branch of the radial nerve (RN) and the axillary nerve, between the medial pectoral nerve and the axillary or the musculocutaneous nerve and between the spinal accessory nerve and the suprascapular nerve [4].

CTS is the most frequent entrapment syndrome, followed by meralgia paraesthetica and UN in the elbow. Decompression is always the treatment, removing the fibrous band, muscle or benign lesion causing the entrapment. After decompression, cases with refractory pain can undergo a nerve neurostimulator to block the pain transmission.

2. Upper extremity entrapment syndromes

2.1. Carpal tunnel syndrome (CTS)

This tunnel is formed by the 'U' of the carpal bones closed by the transverse carpal ligament. It is the most frequent entrapment neuropathy and one of the most common surgical conditions [17, 18]. Its estimated prevalence is 2% in men and 3% in women [17, 18], affecting a 3.72% of the USA population [1].

Idiopathic forms are due to a connective tissue proliferation of the flexor tendons synovium [19]. Some medical conditions predispose to its development: diabetes mellitus [20, 21], acromegaly [22], obesity [23], pregnancy [24], amyloidosis [25], hypothyroidism [22], rheumatoid arthritis [26], chronic kidney disease [27] and haemodialysis [28]. Its incidence is higher in occupations requiring repetitive finger and wrist movements [29], handling of vibrating tools [5–7] or repetitive blows with the palm of the hand (carpenters, sculptors) [29], but not with keyboard use [30]. It affects 30% of diabetics with polyneuropathy and 14% without it [31]. In pregnancy, it is most common in the third trimester [32].

Patients notice pain, numbness and tingling in the first three fingers of the hand. Initially symptoms are intermittent but become permanent with time, worsening with activity and at night [3]. Symptoms wake patients up at dawn, making them shake the affected hand to get rid of the symptoms (the so called *flick sign*). Paraesthesia may affect the whole hand. The pain may be an early symptom and radiate to the forearm or even to the whole arm up to the shoulder [33].

Sensory deficits affect the thumb, index and middle fingers and spare the thenar eminence [34], but 20% of clear-cut CTS show no sensory abnormalities [35]. Because the palmar cutaneous branch for the thenar eminence branches off the MN a few centimetres before the carpal tunnel the sensation of this area is normal in CTS. If this sensation is impaired pre-operatively it indicates proximal MN compression [3] while if damaged is only seen post-operatively it indicates iatrogenic injury.

Entrapment of this branch is possible but exceedingly rare [36].

Atrophy of the thenar muscles is a very late event in the progression of the disease [3] (**Figure 1C**), as are motor symptoms (**Figure 1D**) such as hand clumsiness, rigidity and loss of dexterity.

Symptoms are usually bilateral but predominate in one hand.

The diagnosis is suspected by the symptoms and provocative manoeuvres (Phalen test (**Figure 1A**) and the Tinel and the carpal compression signs) [37]. The Phalen test indicates advanced disease [38], having a 75% sensitivity and a 47% specificity [39]. Electrodiagnostic studies confirm the diagnosis, rule out confounding conditions and stage the disease [40], with an 85% sensitivity and a 95% specificity [41]. Symptoms do not always correlate with electrodiagnostic findings. Ultrasonography is also useful [42]. Due to its higher costs, MRI is not used regularly [43].

Up to 20% of CTS cases improve with conservative treatments [44, 45]. Night-time wrist splints help 60% of patients but many eventually need an operation [46, 47]. Local corticosteroid injections can provide relief but often temporary [48]. Surgical decompression is the only proven long-term lasting relief [40, 49]. Any concomitant systemic disease predisposing to CTS should be treated at once although decompression is usually needed nonetheless [27]. The surgical procedure entails complete transverse carpal ligament section to decompress the MN. Local, regional or general anaesthesia are options, but local is faster and more cost effective [50, 51]. Open field (**Figures 1F and G**) or endoscopy has a similar time out of work, but the latter MN damage is more frequent [52–54]. Retinaculotome decompression is similar to endoscopy but with less time and cost requirements [55] (**Figures 1H and I**). Re-operation is indicated in failure or recurrence. Incomplete decompression either at the distal carpal ligament or at the proximal antebrachial fascia is a frequent finding [56], but sometimes there is a thick scar tissue recreating the transverse carpal ligament and fixing the MN [4].

2.2. Pronator *teres* syndrome (PTS)

It is the MN compression as it passes through the pronator *teres* muscle (PTM) [57], the proximal arch of the FDS, the bicipital aponeurosis, the ligament of Struthers or an accessory head of the flexor *pollicis* longus muscle (FPL) (Gantzer's muscle) [58]. There is proximal forearm deep pain with sensory and/or motor deficits in the distribution of distal MN [33, 57]. Repetitive pronation aggravates symptoms, and contrary to CTS, they appear at daytime and disappear during the night. Another difference is that in PTS there can be sensory loss in the thenar eminence [58]. The pronator compression test is a steady digital pressure on the proximal edge of the PTM 6 cm distal to the elbow crease and 4 cm lateral to the medial epicondyle for 30 s [57]. If positive, it should reproduce the symptoms. Forearm pain and hand MN paraesthesias can be induced by resistive pronation or by elbow extension with the forearm in pronation [57], elbow flexion with the arm supinated or flexion of the middle finger interphalangeal joint [58]. Electrodiagnostic studies can confirm the diagnosis [59]. Conservative treatment should be attempted, encouraging patients to avoid pronation, particularly against resistance. If symptoms persist, surgical decompression is recommended [60]. It is usually performed open field but some have reported an endoscopic approach [57]. The number of cases is limited, so no definitive conclusions on the best technique can be drawn yet.

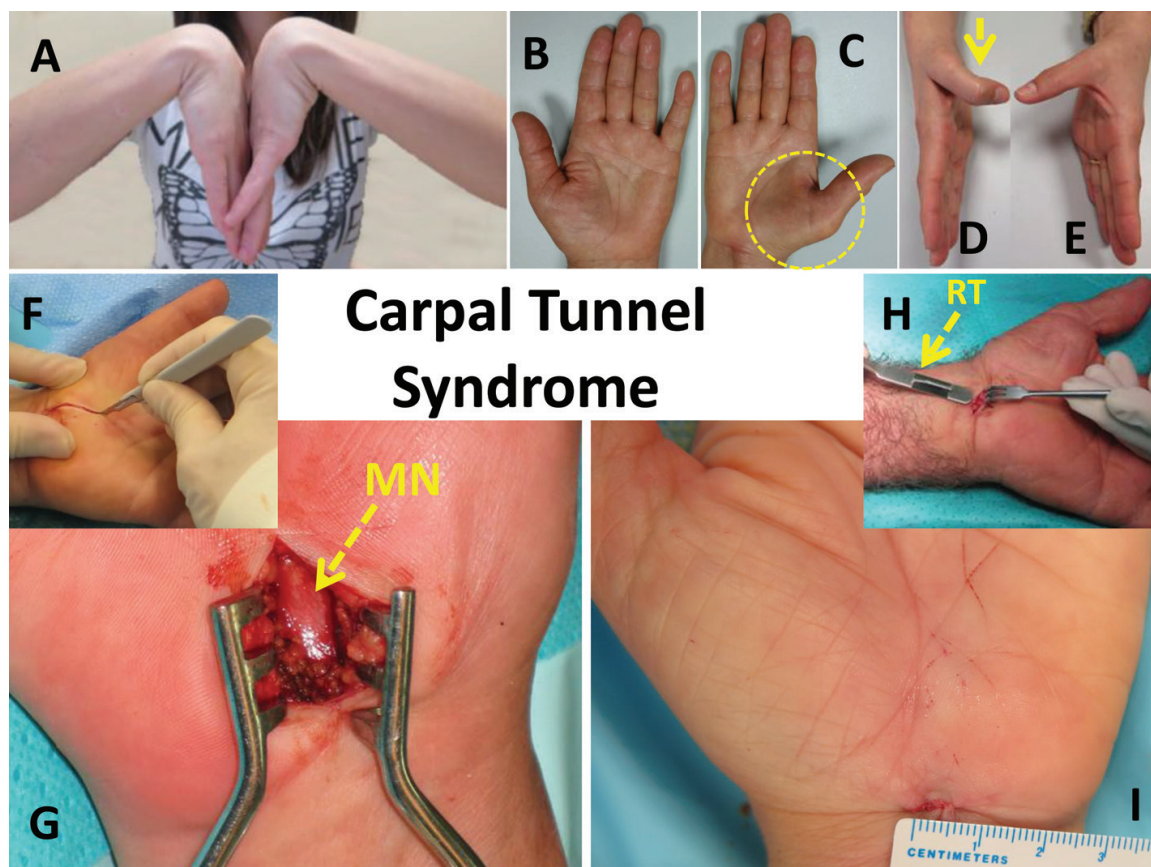


Figure 1. Carpal tunnel syndrome. (A) Phalen sign; (B) normal hand; (C) atrophy thenar eminence; (D) testing for weakness in motor thenar branch of median nerve; (E) normal hand; (F) and (G) open carpal tunnel release, median nerve (MN); (H) and (I) carpal tunnel decompression with retinaculotome (RT) or with endoscope.

2.3. Anterior interosseous syndrome

It is due to compression of this purely motor branch of the MN [61]. It induces a mild vague forearm pain accompanied by paresis or complete paralysis of the FPL and flexor *digitorum profundus* (FDP) of the second and at times part of the third finger [33]. The PQ is also affected but as the PTM remains intact the pronation is preserved. Patients notice lack of muscle power in the pinch between the thumb and index finger [62]. This induces difficulties on the writing hand [62], and the patient cannot make the OK sign [58]. There is no sensory deficit [61]. The causes are a tendinous origin of the PTM deep head or the third finger FDS, collateral ulnar vessel thrombosis, an accessory head of the FPL (Gantzer's muscle), aberrant radial arteries or an enlarged bicipital bursa encroaching on the MN near the AIN site of origin [63]. Electrodiagnostic studies can confirm the diagnosis. If conservative treatment fails, surgical decompression is indicated [64]. The results are usually satisfactory provided that the nerve is freed on time.

2.4. Ulnar nerve compression at the elbow

Cubital tunnel syndrome (CubTS) is the entrapment of the UN at the elbow [65]. It is the most common site of UN entrapment and the second most common in the upper extremity nerve

[66]. Its estimated incidence is 25 new cases/100,000 inhabitants/year [67, 68], affecting males more often than females [68–72]. It is more common in jobs with constant leaning on the elbow (i.e. book keepers, drivers resting the elbow on the window frame) [73], gripping tools (gardeners, farmers, builders) [74], professional motorbike runners, cyclist [75, 76], repetitive elbow flexoextension [73, 74] and in floor cleaners [73, 77]. It is also more frequent in some systemic disorders like diabetes mellitus [16], acromegaly [78], rheumatoid arthritis [79] or amyloidosis [80]. CTS and CubTS in the same arm is not a rare finding [81–83].

Its clinical presentation consists of pain, sensory loss, paraesthesias, motor weakness and muscle atrophy at the forearm ulnar side and fourth and fifth fingers [33]. If untreated, it can lead to lack of sensation and muscle power, as well as pain and clumsiness in the affected hand [70]. Patients often complain of a dull pain at the elbow with shock-like sensations with any mild pressure or blow on this area. Some patients notice no sensory symptoms because of progressive weakness in the fourth and fifth fingers accompanied by muscle atrophy of the hand intrinsic muscles (**Figures 2E and F**) [84]. Symptoms get worse with activity and on flexing the elbow.

On clinical examination, the fifth finger remains in abduction due to weakness of the fourth palmar interosseous muscle (*Wartenberg sign*) (**Figure 2A**). This finger stays behind and out when the patient is attempting to put his/her hand inside the pocket [33]. The *Froment sign* is the flexion of the distal phalanx of the thumb when attempting to hold a piece of paper (**Figure 2C**). It is due to weakness of adductor *pollicis*, flexor *pollicis brevis* and first dorsal interosseous muscle, being substituted by the action of the FPL [33]. The weakness of the *interossei* and lumbrical muscles induces metacarpophalangeal joint hyperextension with flexion of the interphalangeal joint of the fourth and fifth fingers, creating the ‘*claw hand*’, ‘*main en griffe*’ or *Duchenne sign* (**Figure 2B**) [33]. Contrariwise to the hand of benediction seen with medial nerve damage at the forearm, the ulnar claw hand is due to the impossibility of the fourth and fifth fingers to extend. Meanwhile in the hand of benediction it is impossible to flex the thumb, index and middle digits when attempting to make a fist. In CubTS the weakness and atrophy of the first dorsal interosseous muscle (**Figure 2D**) is much more severe and earlier than the weakness and atrophy of the abductor *digiti minimi* (ADM) [33].

The most common site of UN entrapment is the retroepicondylar groove followed by the cubital tunnel 1.5–3 cm distal to the epicondyle [3]. About 40% of the cases are idiopathic [33]. The causes of compression are a bulky triceps muscle [85], the *anconeus epitrochlearis* muscle [86], fibrous bands bridging between the medial epicondyle and the olecranon [87], Osborne’s fascia [88] or the point where the UN crosses under the two heads of the flexor *carpi ulnaris* muscle [89]. It can occur after trauma or a protracted wrong position of the arm. It is the most common entrapment syndrome after anaesthesia for surgical procedures, particularly if they are long [90].

The diagnosis is based on the symptoms. Electrodiagnostic studies confirm the diagnosis and rule out other medical conditions (i.e. C₈ radiculopathy) [3].

Some patients may improve with conservative measures like avoiding external elbow pressure, using a night time splint to keep the elbow extended or stopping any occupational activity that might be causing the disease. If that is not enough or the patient presents with muscle weakness and atrophy, a surgical decompression is indicated.

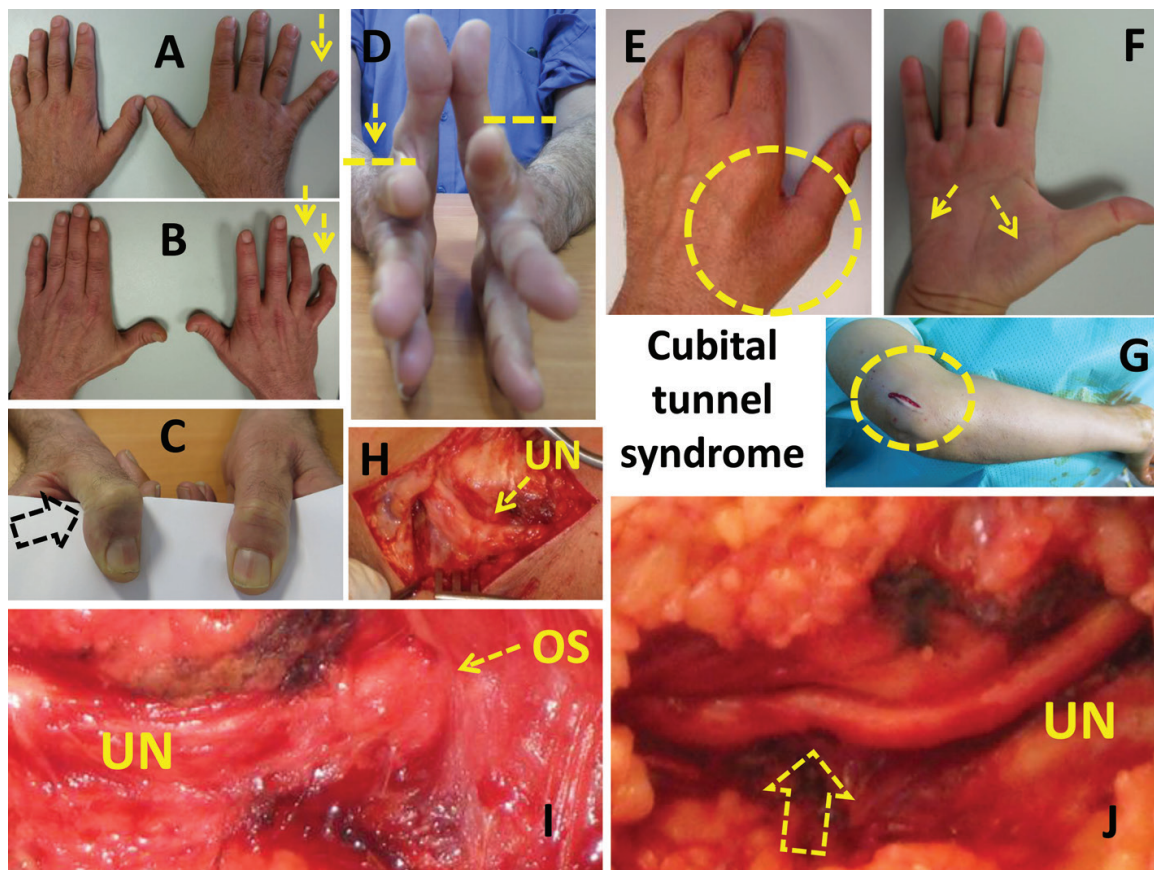


Figure 2. Cubital tunnel syndrome. (A) Wartenberg sign; (B) claw hand; (C) Froment sign; (D) weakness of the first interosseous muscle; (E) atrophy thenar eminence; (F) atrophy thenar and hypothenar eminences; (G) surgical incision; (H) ulnar nerve (UN) compression by the (I) Osborne's arcade (OS); (J) ulnar nerve fully decompressed with a compression mark at the retroepicondylar tunnel (depicted by the arrow).

The techniques for UN decompression at the elbow are medial epicondylectomy, *in situ* decompression and transposition. The epicondylectomy is not popular anymore. Several clinical comparative studies [91–94], meta-analyses [95–97] and prospective randomized trials [98, 99] have shown that *in situ* CubTS decompression (**Figures 3A–D**) is just as effective as transpositions (**Figures 4A–D**) provided there is no UN subluxation on elbow flexoextension [97, 99]. Advantages of *in situ* decompression are smaller surgical incisions, less risk of medial antebrachial cutaneous nerve damage [100], no UN devascularisation [97], shorter operating time [101], smaller costs [99] and a faster recovery [102]. Transpositions need more surgical time, are more expensive and have more complications than *in situ* decompression [99], but can be used in the case of failure [102, 103]. It is imperative to avoid damaging the medial antebrachial cutaneous nerve or its branches regardless of the technique, as injury will induce post-operative neuropathic pain in the elbow area [104–106]. The *in situ* decompression can be performed open field or endoscopic. The latter shows a higher rate of post-operative surgical field haematoma [107]. The clinical results are equivalent for both procedures [100, 107, 108]. In recurrent cases, the most frequent finding is incomplete decompression either at the distal flexor-pronator muscle group or proximally at the intermuscular septum [109, 110].

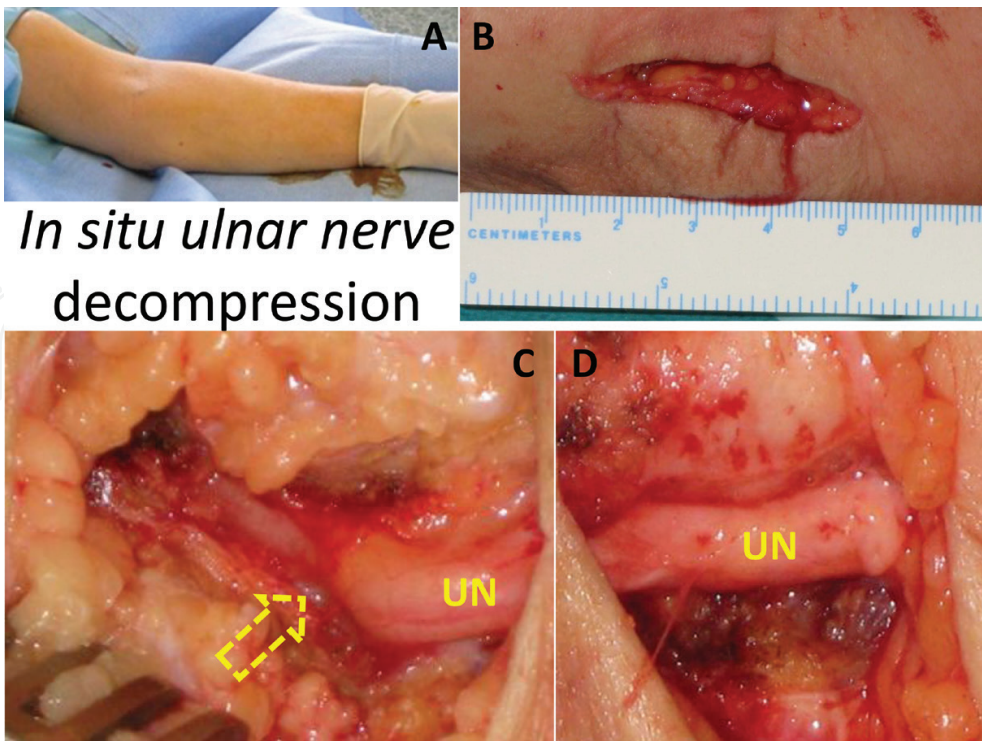


Figure 3. *In situ*, ulnar nerve decompression. (A) patient position; (B) skin incision; (C) ulnar nerve (UN) decompression, the arrow points to the entrapment point at the retroepicondylar tunnel; (D) ulnar nerve fully decompressed.

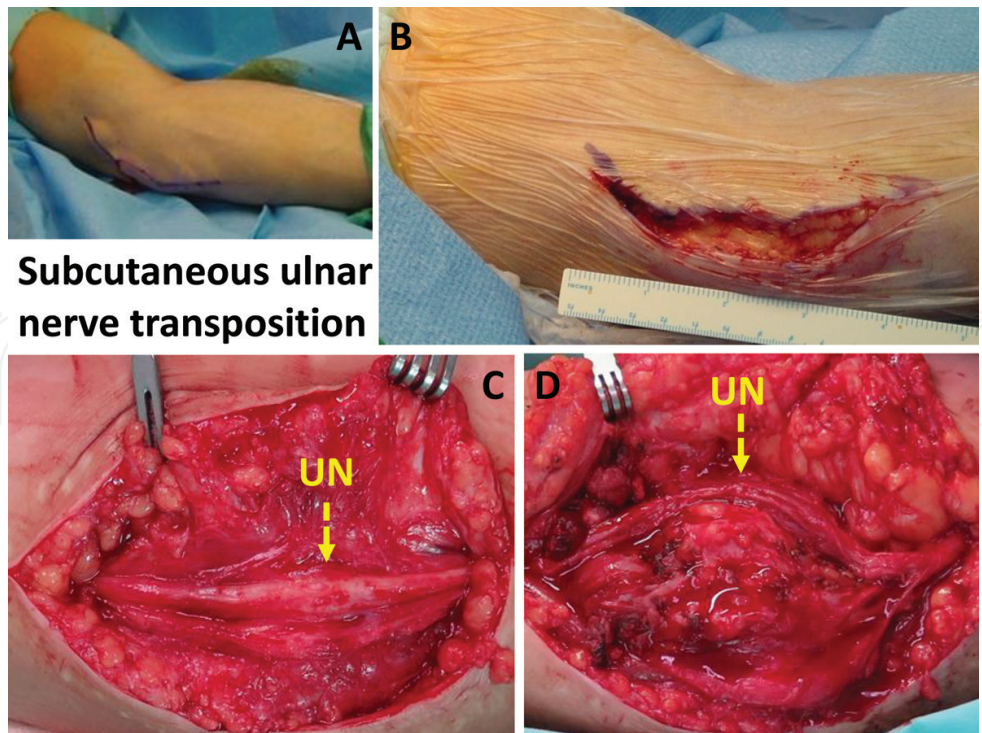


Figure 4. Cubital tunnel syndrome. Subcutaneous ulnar nerve transposition. (A) patient position; (B) skin incision; (C) ulnar nerve (UN) decompressed; (D) ulnar nerve transposed subcutaneously.

Pre-operative and intra-operative electrophysiological inching studies have found that the compression point is at or immediately proximal to the cubital tunnel [87, 111–113], less often at the Osborne's arcade but not proximally at the intermuscular septum [82]. Others with endoscopic assistance have reported no nerve constriction beyond 4 cm distally or proximally to the retroepicondylar tunnel [100]. So, extensive proximal decompression seems futile [100, 114]. Unsatisfactory results have been related to concomitant undiagnosed CTS or to weight gain [107].

2.5. Ulnar nerve compression at the hand

It is an uncommon site for UN entrapment (**Figure 5A**). Depending on the exact point of compression, it can be classified into five types [88, 115, 116]. In type I, the compression is proximal to Guyon's canal with involvement of the superficial sensory, hypothenar motor, as well as deep motor branch. In type II, the compression is inside the canal and only the superficial sensory branch is affected. In type III, the compression is distal to the sensory branch with involvement of the hypothenar and deep motor branch proximal to the branch for the ADM. In type IV, the compression is distal to the superficial sensory and the hypothenar branch, so only the deep motor branch is affected. In type V, there is compression to the deep motor branch just proximal to the adductor *pollicis* and first dorsal interosseous muscles.

Usually there is the antecedent of an acute trauma [58] or chronic compression (cyclists) [76]. In other cases, there is a structural lesion in the area compressing the nerve, most commonly a ganglion cyst [116]. In cases of repetitive compression (i.e. cyclists), removal of the offending activity can be tried. If there is a lesion it has to be removed before irreversible UN damage develops (**Figures 5B–E**) [116].

2.6. Radial nerve (RN) entrapment syndromes

Its entrapment points are [3] at the spiral groove by the intermuscular septum between the triceps and brachialis (BaM) muscles, at the proximal forearm by the ligament of Frohse (posterior *interosseous* nerve or PIN), between the two heads of the *supinator* muscle (PIN) and by edge of the *brachioradialis* muscle (BRM) in the distal forearm (superficial cutaneous branch of the RN). It is the third most common upper limb entrapment [3].

The *Saturday Night palsy* or *Honeymoon palsy* is the most common compression of the RA occurring at the spiral groove [117]. It is usually due to local pressure on the posterior aspect of the arm under anaesthesia, drug intoxication (i.e. alcohol) or profound sleep with the arm over a hard surface or under the body of somebody else (Honeymoon palsy) [118]. In most cases, it improves spontaneously [117].

The *radial tunnel syndrome* is the entrapment of the deep branch of the RA [119]. This tunnel begins where the deep branch of the RN crosses over the radiohumeral joint, ending where this nerve becomes the PIN below the supinator muscle (SM) [33]. It has an average length of 5 cm. Its lateral wall is formed by the muscles BRM, extensor *carpi radialis brevis* (ECRB), BaM and extensor *carpi radialis longus* (ECRL). Its medial wall is created by the biceps tendon and the BaM. The floor of this tunnel is created by the radiocapitellar joint [120]. The compression can be due to the arcade of Frohse (tendinous border of the superficial layer of the SM),

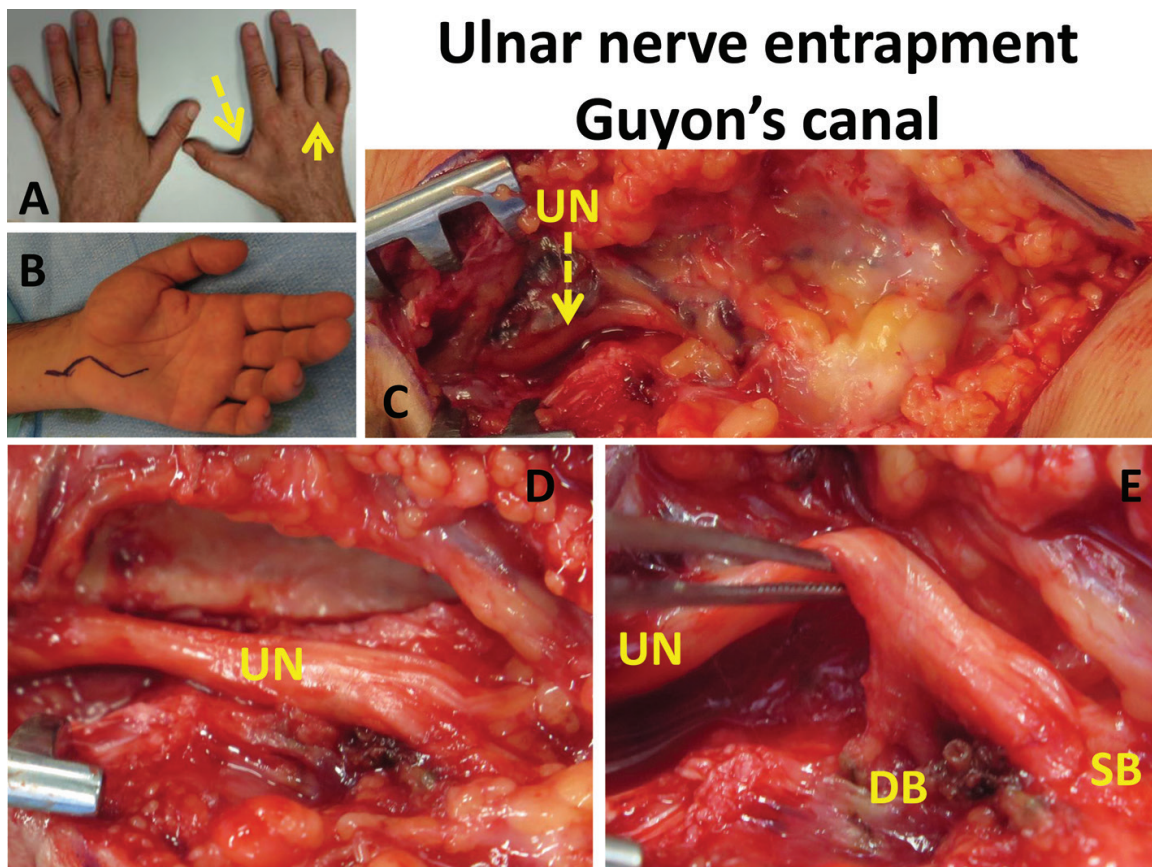


Figure 5. Ulnar nerve entrapment at wrist. (A) Atrophy thenar eminence and claw hand; (B) skin incision; (C) ulnar nerve (UN) exposed in the distal third of the forearm; (D) ulnar nerve exposed in the wrist; (E) ulnar nerve deep (DB) and superficial branch (SB) liberated.

the superomedial border of the ECRB, the inferior border of the superficial layer of the SM, fibrous bands at the radio-humeral joint and some radial vessels with a recurrent direction and a fibrous septum between the BRM and BaM muscles [119, 121, 122]. The treatment is conservative [123] avoiding the movements that induce pain but if it persists surgical exploration may be justified [124].

The *PIN entrapment* induces pain in the lateral aspect of the arm and forearm [125] and weakness in extension in all fingers (thumb included) and in thumb abduction (**Figure 6A**). There is no wrist drop because the ECRB is spared but on wrist extension the extensor *carpi ulnaris* weakness induces radial deviation [33]. There is no sensory deficit as the superficial RN is not involved. Symptoms exacerbate on hand or forearm repetitive movements [126]. Symptoms can be reproduced by direct pressure on the radial aspect of the forearm at 6 cm distal to the epicondyle. The provocative test consists in forceful hand supination with the shoulder in adduction and the elbow at 90° flexion or with extension of the middle finger [58]. It can be due to entrapment by the arcade of Frohse or on its way between both heads of the SM [126] (**Figure 6C**), ganglion cysts [125] or benign tumours (lipoma the most frequent) [127]. When symptomatic its treatment is surgical decompression [128] (**Figures 6B–E**).

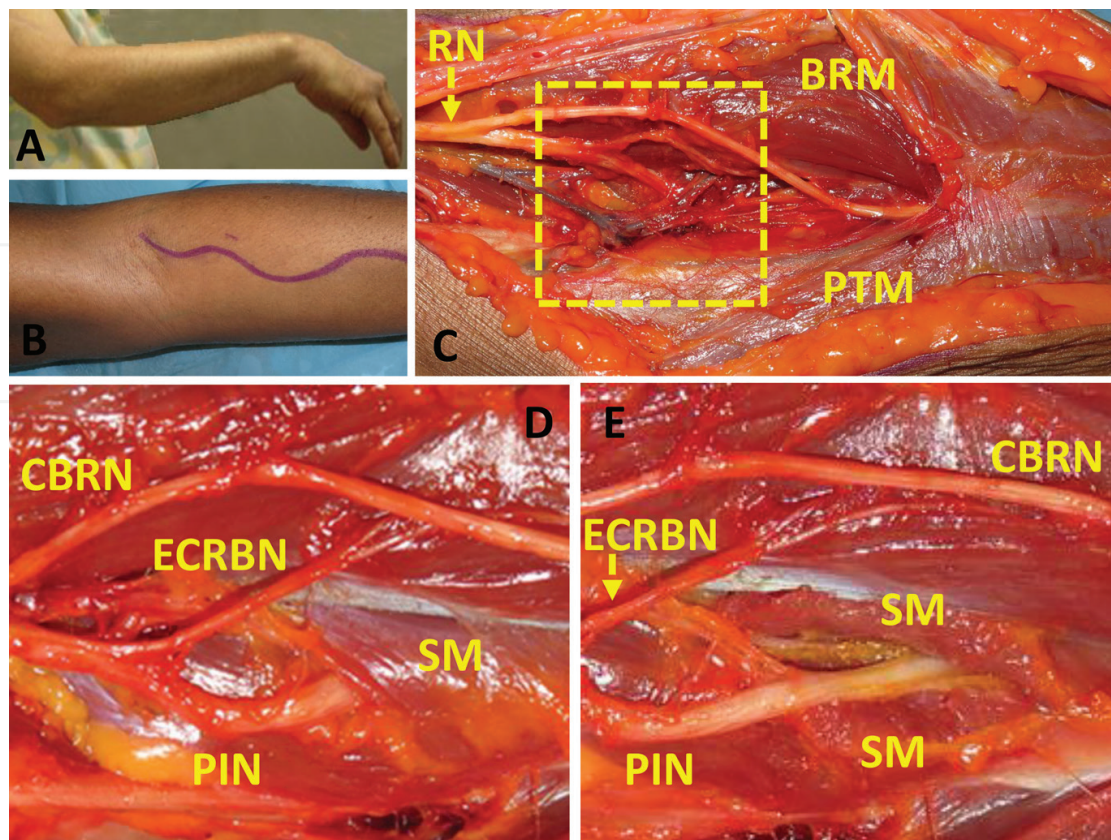


Figure 6. Posterior interosseous nerve entrapment. (A) paralysis of finger extension; (B) skin incision; (C) the radial nerve (RN) is found between the *Brachioradialis* (BRM) and *Pronator Teres* (PTM) muscles; (D) the posterior interosseous nerve (PIN) is compressed between both heads of the *Supinator* muscle (SM), cutaneous branch radial nerve (CBRN), extensor carpi radialis brevis nerve (ECRBN); (E) the supinator muscle has been sectioned, freeing the posterior interosseous nerve.

Cheiralgia paraesthetica or *Wartenberg syndrome* is the entrapment of the superficial cutaneous branch of the RN. There is numbness and pain in the dorsum of the hand, the thumb, index and middle fingers, accompanied by dysaesthesia, burning sensation and hyperesthesia [58]. The entrapment points are at the forearm between the tendons of the BRM and ECRB or at the wrist at its exit from beneath the fascia to the subcutaneous layer in the site where the fascia joins the tendons of the BRM and ECRL [129]. In the first case, it can be due to repetitive pronation and supination [58]. In this second case, it is usually due to external compression by hand-cuffs [130] or a wristwatch [131]. The best provocative test is to ask the patient to place their arm under maximum pronation with the wrist flexed to the ulnar side [132]. The Finkelstein test is positive, inducing confusion with a De Quervain syndrome [58]. The treatment is the removal of the cause. In case of persistence, surgical decompression of this nerve, particularly as it crosses the edge of the tendon of the BRM muscle, is indicated [131, 133] (Figures 7A–D).

2.7. Suprascapular nerve entrapment

It can be trapped at the suprascapular and spinoglenoid notches where the nerve is fixed by ligaments in a bony canal [134]. The first symptom is pain localized in the posterior aspect of the shoulder that gets worse with activity, when lying on the affected area, or by

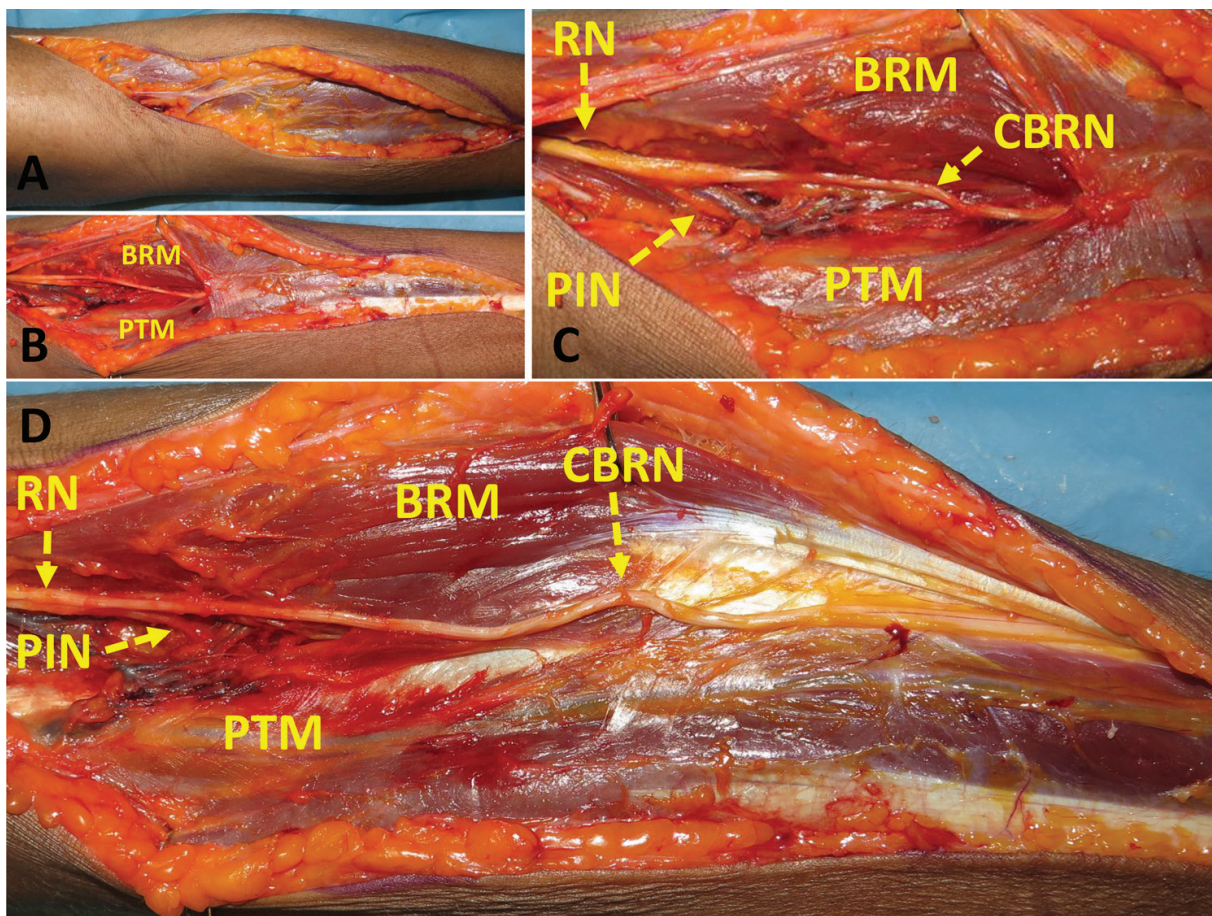


Figure 7. Superficial cutaneous nerve branch radial nerve entrapment. (A) skin incision; (B) approach between the brachioradialis (BRM) and pronator teres (PTM) muscles; (C) and (D) exposure and liberation of the superficial cutaneous radial nerve branch (CRNB), radial nerve (RN), posterior interosseous nerve (PIN).

shoulder adduction crossing the midline with the extended arm [33]. The weakness and atrophy of the supra and infraspinatus muscles induce paresis of shoulder abduction and external rotation.

On clinical examination, the affected shoulder is lower than the healthy one and the scapular muscles are atrophied (**Figure 8A**). The patient has difficulty raising the outstretched arm above the horizontal (**Figures 8B and C**).

Its treatment is surgical with section of the ligament that closes the suprascapular notch at the superior aspect of the scapula. It can be done open field [135] (**Figures 8D and E**) or endoscopically [136] with similar outcomes.

2.8. Thoracic outlet syndrome

There is pain in the inner aspect of the arm and forearm, sometimes reaching the fourth and fifth fingers [137]. This pain gets worse when lifting the arm above the horizontal [138]. Sometimes there is associated hand muscle atrophy [139]. Claw hand deformity can be

Suprascapular nerve entrapment

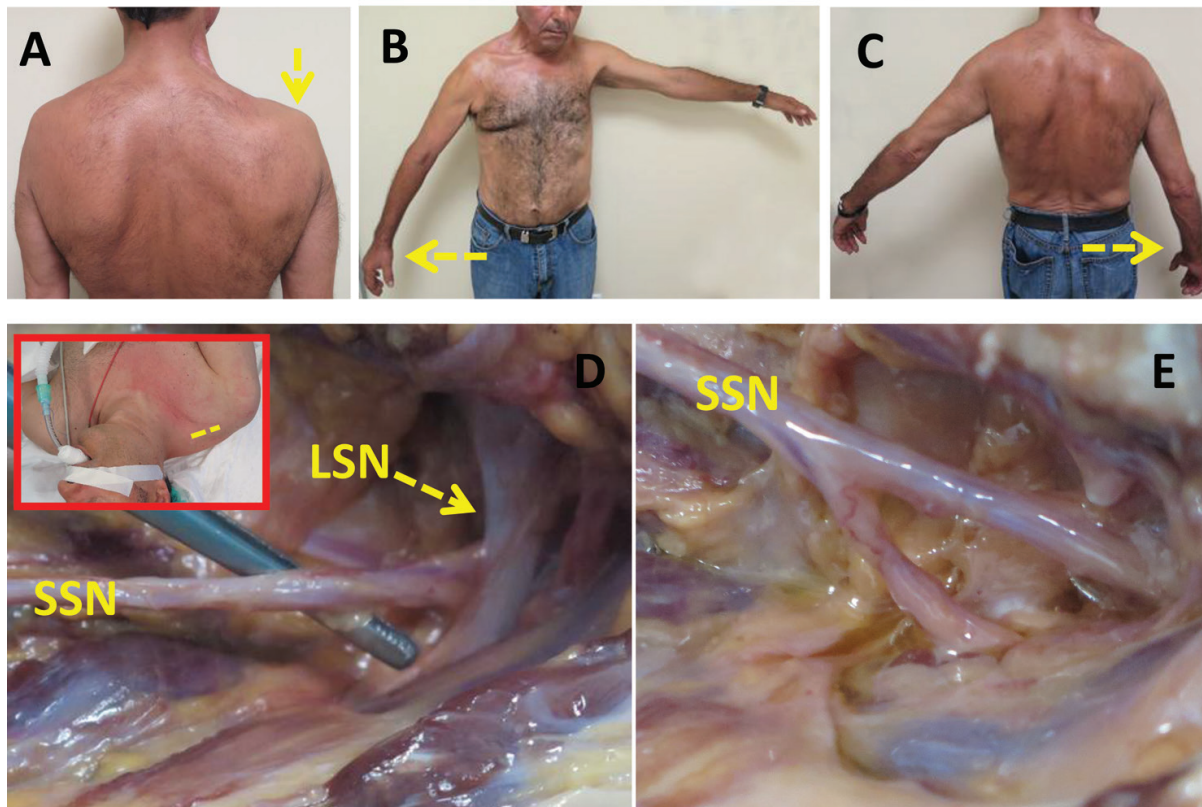


Figure 8. Suprascapular nerve entrapment. (A) Atrophy supra and infraspinatus muscles; (B) and (C) weakness of shoulder abduction; (D) suprascapular nerve (SSN) exposed with the ligament for the suprascapular notch (LSN) intact; (E) suprascapular nerve after removal of the ligament for the suprascapular notch.

present in the long protracted cases [138]. The neurogenic type has an incidence of one case per million inhabitants [137]. It can be due to hypertrophy of some muscles at the root of the arm (typical of ceiling painters or swimmers) or to the existence of a cervical rib or fibrous ligament at the same point [137].

The clinical presentation is pins and needles with overhead activities (like painting a ceiling) [140], carrying heavy objects with the arms hanging down [138], combing hair and applying makeup [4].

In the *Roos' elevated arm stress test*, the shoulder is abducted 90° and kept in external rotation with the elbow in 30° flexion. This provocative test is positive if opening and closing the hand for 1 min reproduces the symptoms [141].

In case of poor response to conservative treatment, surgical decompression is in order. The two possibilities are the transaxillary removal of the first rib [142] or supraclavicular scalenectomy [143] (**Figures 9A–D**). This depends on the causative mechanism and the surgeon's preferences but the supraclavicular approach offers a better chance of solving any causative abnormality [143].

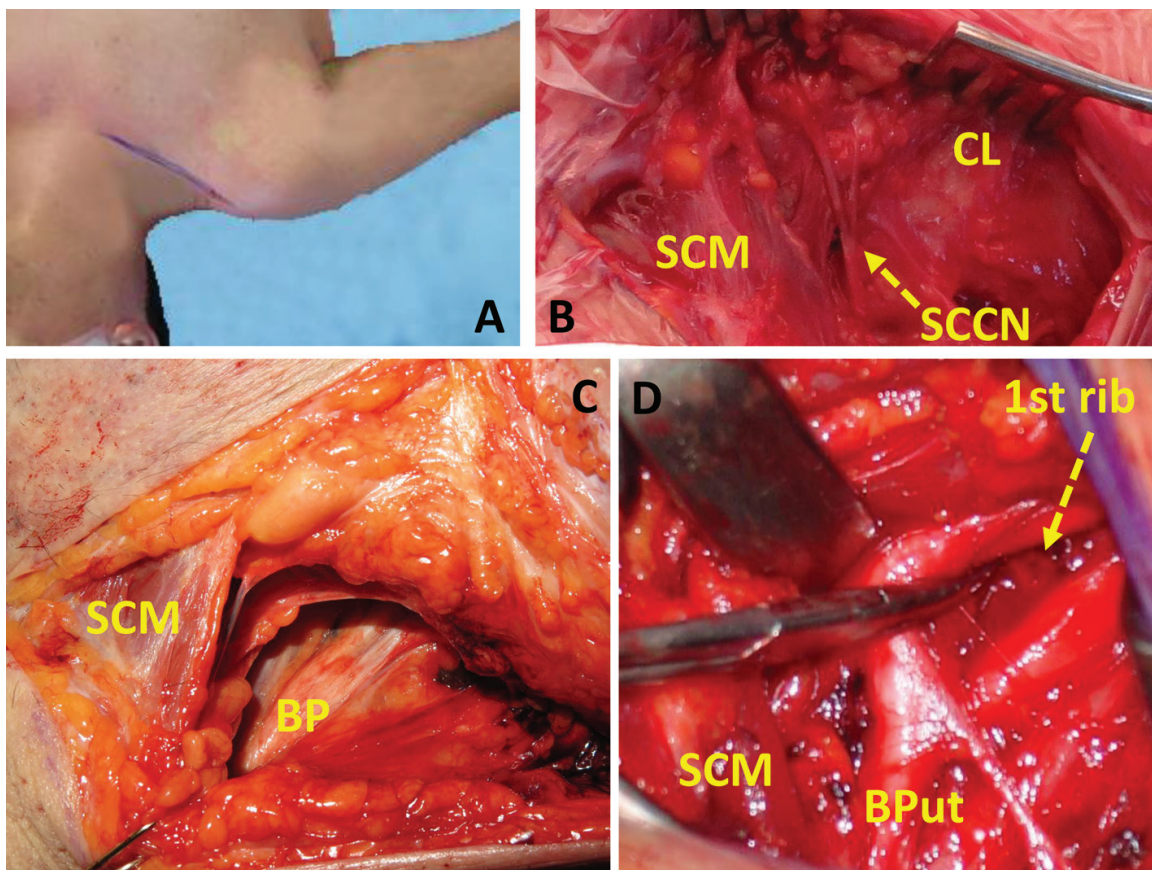


Figure 9. Thoracic outlet syndrome. (A) skin incision; (B) supraclavicular cutaneous nerve (SCCN), sternocleidomastoid muscle (SCM), clavicle (CL); (C) brachial plexus (BP) exposed; (D) first rib exposed, brachial plexus upper trunk (BPut).

3. Lower limb entrapment syndromes

3.1. Meralgia paraesthetica

The femoral cutaneous nerve is a purely sensory nerve which runs usually medial to the ASIS. The name meralgia paraesthetica comes from the Greek, *meros* meaning thigh and *algos* meaning pain. The clinical presentation is pain, paraesthesia, numbness and hypersensitivity in the anterolateral side of the thigh down to the knee (**Figures 10A and B**) [144]. There are no motor signs and if present a different medical condition should be suspected [145]. The pain worsens when standing or walking and improves on sitting [146]: it is aggravated on leg extension and improved on knee flexion [146]. Its estimated incidence is 36.2 cases/100,000 habitants/year in the USA [147] and 43 cases/100,000 persons/year in Europe [145]. Meralgia paraesthetica is more frequent in obese people, in the fourth–six decades of life [145, 147, 148] and in diabetics (seven times more than in the general population) [147, 148]. Although many cases are idiopathic oftentimes its cause is an external compression of the nerve as it passes underneath or through the anterior inguinal ligament at its origin on the ASIS [149]. This can be due to either internal causes like a bulging abdomen [150], obesity [147], pregnancy [151], ascites [152], external agents like tight clothes [153] or belts resting on the outer aspect of the thigh

repeatedly while standing (typical of hairdressers) or due to a prolonged position (lithotomy posture, cycling) [144]. It can also be induced by a pelvic fracture with psoas haematoma or by surgical procedures such as hip [154] or knee replacements [155] or an aortofemoral bypass [144, 147]. It has also been related to acute seat belt compression in car accidents [144].

The clinical presentation in the absence of motor signs helps to make the diagnosis. Electrodiagnostic studies can rule out confounding conditions [144, 156], but ultrasonography is very useful, particularly in obese patients [156, 157].

Initially, the treatment is to remove the compressing agent and/or lose weight. If insufficient, the area can be infiltrated with a local anaesthetic agent and corticosteroids [158]. The rebel cases require surgical treatment with nerve decompression (**Figures 10C–E**) or neurectomy [159].

3.2. Peroneal nerve entrapment

It is the most common lower limb entrapment neuropathy [162]. It is a mixed nerve that runs at the fibular head, reaching the anterior compartment of the leg distal to the knee [160]. At that level, it lies between the skin and bone. This makes it very sensitive to trauma or pressure,

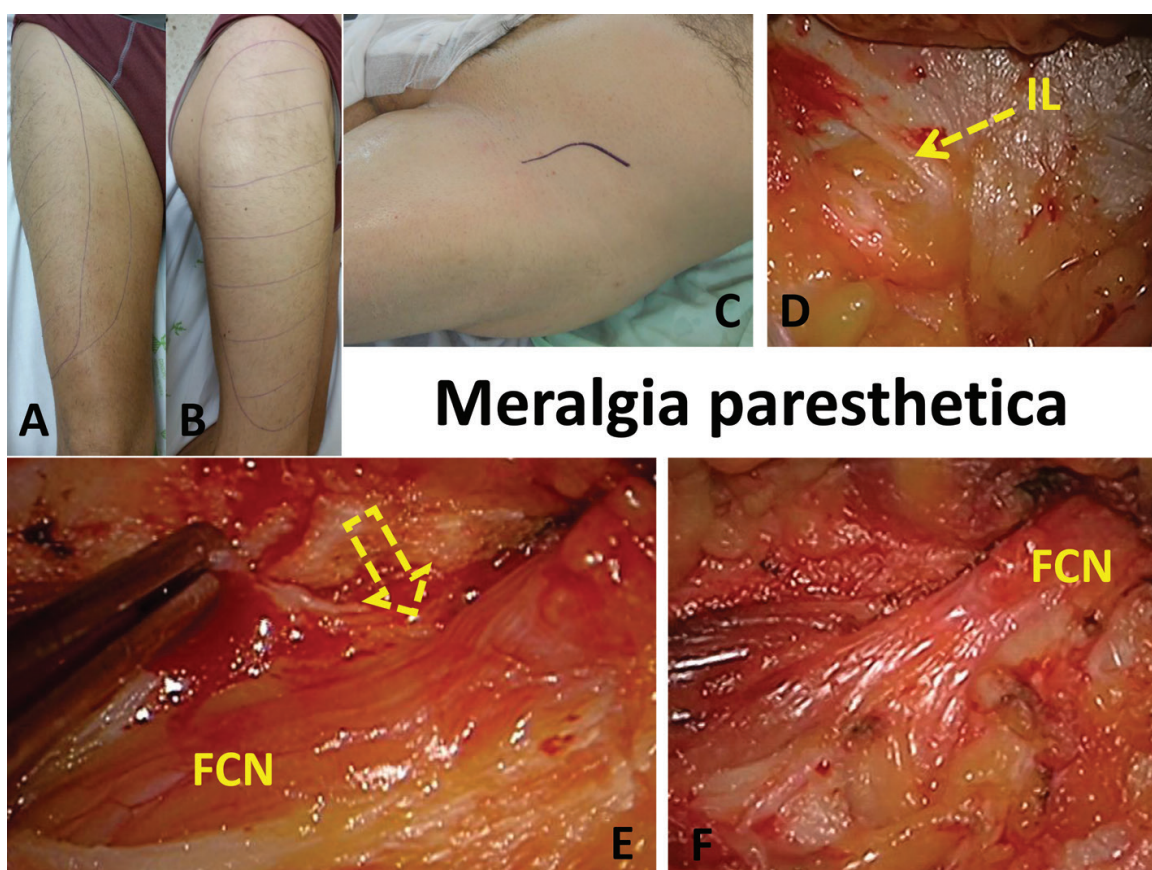


Figure 10. Femoral cutaneous nerve entrapment (meralgia paraesthetica). (A) and (B) area of sensory disturbance; (C) skin incision; (D) subcutaneous tissues with inguinal ligament (IL); (E) femoral cutaneous nerve (FCN) with the arrow pointing at the entrapment point under the inguinal ligament; (F) femoral cutaneous nerve fully decompressed.

particularly in bedridden lean patients [161]. It can also be due to mass lesions (i.e. ganglion cyst of the tibiofibular joint) or associated with systemic diseases (diabetes and vasculitis) [162]. It is more frequent in occupations requiring people to squat for long periods of time (strawberry pickers, farm workers and carpet layers) [163] or that sit crossing their legs [164].

The clinical presentation is pain at the fibular head and loss of strength in dorsiflexion (**Figure 11A**), which causes the foot to drag when walking. The patient notices foot slap with stepage gait and wearing the tip of the shoe as well as a sensory loss on the dorsal aspect of the foot between the first and second toe [165].

The treatment is surgical decompression (**Figures 11B–G**) [161, 166].

3.3. Anterior tarsal tunnel

It is the entrapment of the deep peroneal nerve. The clinical presentation is pain in the dorsum of the foot associated with sensory loss in the first foot web space [167]. The treatment is initially conservative, but surgical decompression with extensive fascial opening might be needed [168].

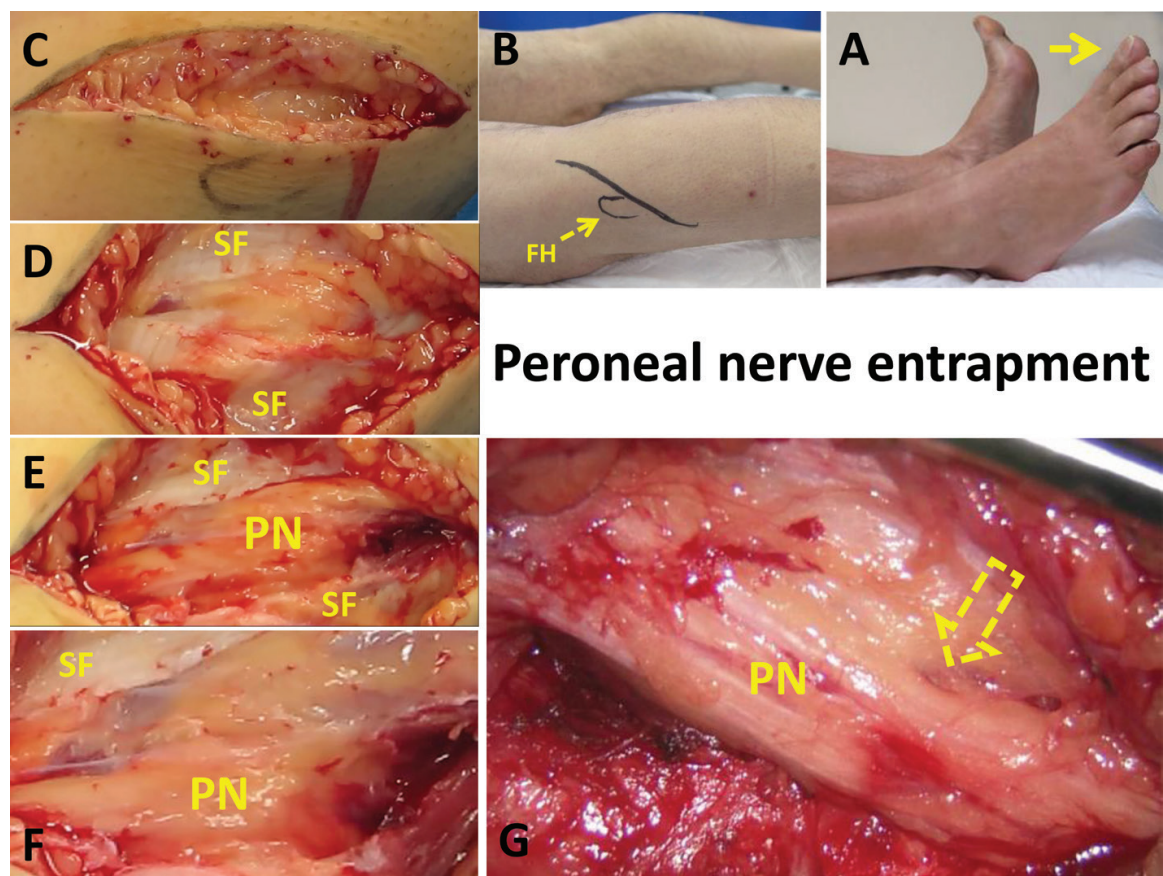


Figure 11. Peroneal nerve entrapment at the level of the fibular head. (A) foot dorsiflexion weakness; (B) skin incision and fibular head (FH) depicted; (C)–(G) steps in peroneal nerve (PN) decompression, subcutaneous fascia (SB). The arrow points at the marked impinging on the nerve by the compressing fascial band.

3.4. Tarsal tunnel syndrome

It is due to compression of the posterior tibial nerve at the tarsal tunnel behind the foot medial malleolus. It is very uncommon. Many cases are idiopathic (20–46%) [169]. Contributing factors are ankle sprain and fracture, tight-fitting foot wear and space occupying lesions [170]. The clinical presentation is pain, paraesthesia and numbness in the sole of the foot. This symptoms get worse on standing, walking and at night time [2]. The sensory loss affects the sole of the foot sparing the heel, supplied by the calcaneal branch [171]. The diagnosis is identified with the clinical presentation. Electrodiagnostic studies can be useful to rule out confounding medical conditions [172]. Ultrasonography [173] and MRI [174] can rule out associated space occupying lesions.

Its initial treatment is rest and anti-inflammatories, but if there is no improvement or relapse after an initial response, surgical decompression may be necessary. This can be done endoscopically [175], but for a good decompression, especially in the distal part, an open approach gives better results [176] (Figures 12A–D).

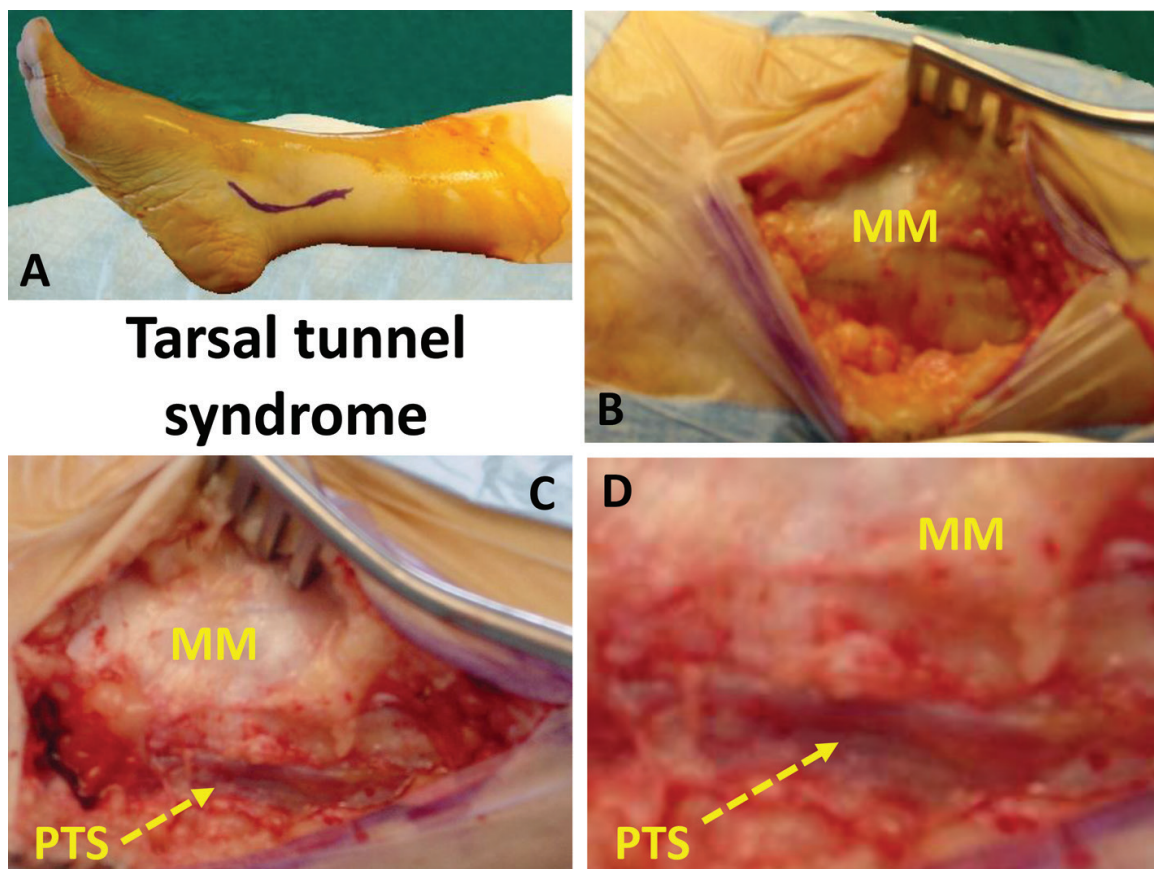


Figure 12. Tarsal tunnel syndrome. (A) skin incision; (B) exposure medial malleolus (MM); (C) section of roof tarsal tunnel, posterior tibial structures (PTS); (D) exposure posterior tibial structures.

3.5. Piriformis syndrome

It is a very rare disorder in which *the sciatic nerve is compressed by the piriformis muscle*. This is a flat, pyramid-shaped *muscle located deep in the gluteal region*, running between the femur and the iliac bone. It helps in hip external rotation [177]. Common sciatic nerve pain (i.e. lumbar disc hernia) is much more prevalent than this syndrome.

The conditions associated with this syndrome are sitting for extended periods of time, sitting with a large wallet in the rear pocket, repeated forward movements, running, bicycling, stiff sacroiliac joints, foot overpronation, Morton's toe (the second toe is longer than the first one) and after a fall on the buttocks [177–179]. Approximately 50% of the cases are caused by trauma and the rest are spontaneous [178].

The symptoms are sciatica-like pain. Pain starts in the gluteal area and may travel through the back of the thigh and calf up to sole the foot. Patients might experience tingling, numbness, burning sensation and weakness. The sciatic pain aggravates with sitting or with activities that press the piriformis against the sciatica nerve, such as running, cycling or horse riding [178].

The diagnosis is usually made through physical examination. Certain tests may elicit sciatica nerve pain indicating the presence of the syndrome, especially internal rotation of the hip with the knee in full extension.

On MRI examination, it is possible to see the sciatic nerve with oedema when crossing under the piriformis muscle.

Conservative treatment is initially recommended. Alternate ice and heat treatment may provide relief. Ultrasound penetrates deep into the muscle alleviating the sciatica nerve pain. Stretching exercises to target the piriformis, hamstrings and hip muscles, will help increase the range of motion and decrease the sciatic nerve pain.

If all these treatments prove unsuccessful, injection of botulinum toxin in the piriformis muscle [180] under CT or MRI guidance can be attempted. In the case of failure, surgical decompression removing the piriformis muscle or the offending fibrous band could be indicated [179, 181] (**Figures 13A–E**). The results are inconsistent.

3.6. Pudendal nerve entrapment

It induces pain in the genital and sometimes gluteal areas [182]. The pain worsens with local pressure, sitting, defecating, and urinating and with sexual intercourse [183]. It is constant, intense and burning. The cause can be local pressure induced by repeated cycling [184] or by horse riding. The problem is that most patients are diagnosed late. Once suspected, it can be confirmed with electrodiagnostic studies [185]. When conservative treatments [186] fail, surgical decompression should be considered [187] (**Figures 14A–E**). The results are often poor, at times because patients are diagnosed much too late due to lack of awareness in the medical world.

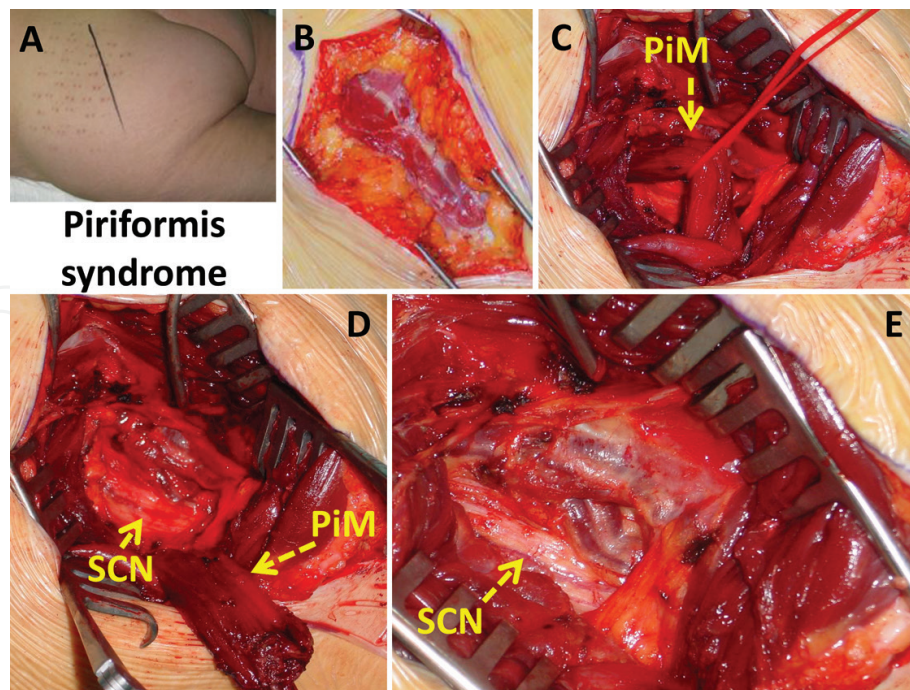


Figure 13. Piriformis syndrome with sciatic nerve (SCN) entrapment. (A) Skin incision; (B) gluteus *maximus* muscle exposed; (C) piriformis muscle (PiM) isolated; (D) piriformis muscle sectioned exposing the sciatic nerve (SCN); (E) sciatic nerve free.

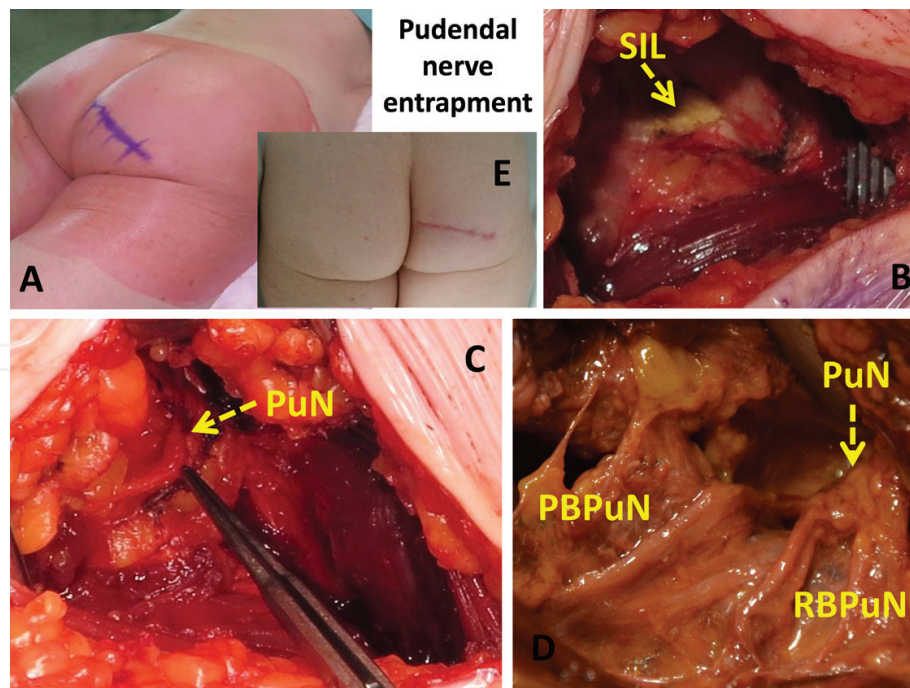


Figure 14. Pudendal nerve entrapment. (A) skin incision; (B) gluteus maximus muscle dissection exposing the sacroischiatic ligament (SIL); (C) the pudendal nerve (PuN) is exposed after sectioning the sacroischiatic ligament; (D) the pudendal and its branches are freed (RBPuB, rectal branch pudendal nerve; PBPuN, perineal branch pudendal nerve); (E) post-operative scar.

4. Conclusion

Nerve entrapments syndromes are more frequent than currently thought. Their awareness is essential to diagnose and treat the patient on time. Although almost any nerve can suffer an entrapment syndrome, some are more common than others. The most frequent is CTS, followed by meralgia paraesthetica and ulnar nerve entrapment at the elbow. The clinical presentation is pain, paraesthesia and muscle power loss in the distribution of the affected nerve. Many cases are idiopathic, but others are induced by internal or external compressing mechanisms. Some systemic conditions are associated with an increased incidence of these syndromes. The clinical presentation together with the electrodiagnostic studies help in the diagnosis. The ultrasonography and the MRI are also helpful but not used so regularly.

In many cases, conservative medical treatment is sufficient. When it is not, surgical decompression has to be performed.

Open and endoscopic approaches are available. In each case, we will have to see which shows better outcomes. A few cases with persistent pain after surgical decompression might benefit from peripheral nerve neurostimulation.

Acknowledgements

We thank the Department of Human Anatomy and Embryology of the Faculty of Medicine of the University of Valencia, particularly to the laboratory curators Lucia and Carmina and to Dr. Tomás Hernández Gil de Tejada, and to all personnel of the *Instituto de Medicina Legal de Valencia*, for their assistance in this study.

Appendices and nomenclatures

AIN	Anterior <i>interosseous</i> syndrome
ASIS	Anterior superior iliac spine
BaM	<i>Brachialis</i> muscle
BRM	<i>Brachioradialis</i> muscle
CubTS	Cubital tunnel syndrome
CTS	Carpal tunnel syndrome
ECRB	Extensor <i>carpi radialis brevis</i>
ECRL	Extensor <i>carpi radialis longus</i>
FDS	Flexor <i>digitorum superficialis</i>
FDP	Flexor <i>digitorum profundus</i>
FPL	Flexor <i>pollicis longus</i>

MN	Median nerve
PIN	Posterior interosseous nerve (PIN)
PQ	Pronator <i>quadratus</i> muscle
PTM	Pronator <i>teres</i> muscle
RN	Radial nerve
SM	<i>Supinator</i> muscle
UN	Ulnar nerve

Author details

Vicente Vanaclocha-Vanaclocha^{1*}, Nieves Sáiz-Sapena², Jose María Ortiz-Criado³ and Nieves Vanaclocha⁴

*Address all correspondence to: vvanaclo@hotmail.com

1 Department of Neurosurgery, Hospital General Universitario, Valencia, Spain

2 Hospital 9 de Octubre, Valencia, Spain

3 Universidad Católica San Vicente Mártir, Valencia, Spain

4 Hospital General Universitario Valencia, Spain

References

- [1] Papanicolaou GD, McCabe SJ, Firrell J. The prevalence and characteristics of nerve compression symptoms in the general population. *J Hand Surg.* 2001 May;26(3):460–6.
- [2] McSweeney SC, Cichero M. Tarsal tunnel syndrome—a narrative literature review. *Foot (Edinb Scotland).* 2015 Dec;25(4):244–50.
- [3] Arnold WD, Elsheikh BH. Entrapment neuropathies. *Neurol Clin.* 2013 May;31(2):405–24.
- [4] Tang DT, Barbour JR, Davidge KM, Yee A, Mackinnon SE. Nerve entrapment: update. *Plast Reconstr Surg.* 2015 Jan;135(1):199e–215e.
- [5] Ettema AM, Amadio PC, Zhao C, Wold LE, O’Byrne MM, Moran SL, An K-N. Changes in the functional structure of the tenosynovium in idiopathic carpal tunnel syndrome: a scanning electron microscope study. *Plast Reconstr Surg.* 2006 Nov;118(6):1413–22.
- [6] Latko WA, Armstrong TJ, Franzblau A, Ulin SS, Werner RA, Albers JW. Cross-sectional study of the relationship between repetitive work and the prevalence of upper limb musculoskeletal disorders. *Am J Ind Med.* 1999 Aug;36(2):248–59.

- [7] Wieslander G, Norbäck D, Göthe CJ, Juhlin L. Carpal tunnel syndrome (CTS) and exposure to vibration, repetitive wrist movements, and heavy manual work: a case-referent study. *Br J Ind Med*. 1989 Jan;46(1):43–7.
- [8] Fox IK, Mackinnon SE. Adult peripheral nerve disorders: nerve entrapment, repair, transfer, and brachial plexus disorders. *Plast Reconstr Surg*. 2011 May;127(5):105e–118e.
- [9] Mills KR. The basics of electromyography. *J Neurol Neurosurg Psychiatry*. 2005 Jun;76 Suppl 2:ii32–35.
- [10] Rempel DM, Diao E. Entrapment neuropathies: pathophysiology and pathogenesis. *J Electromyogr Kinesiol Off J Int Soc Electrophysiol Kinesiol*. 2004 Feb;14(1):71–5.
- [11] Kim S, Choi J-Y, Huh Y-M, Song H-T, Lee S-A, Kim SM, Suh J-S. Role of magnetic resonance imaging in entrapment and compressive neuropathy—what, where, and how to see the peripheral nerves on the musculoskeletal magnetic resonance image: part 1. Overview and lower extremity. *Eur Radiol*. 2007 Jan;17(1):139–49.
- [12] Kim S, Choi J-Y, Huh Y-M, Song H-T, Lee S-A, Kim SM, Suh J-S. Role of magnetic resonance imaging in entrapment and compressive neuropathy—what, where, and how to see the peripheral nerves on the musculoskeletal magnetic resonance image: part 2. Upper extremity. *Eur Radiol*. 2007 Feb;17(2):509–22.
- [13] Koenig RW, Pedro MT, Heinen CPG, Schmidt T, Richter H-P, Antoniadis G, Kretschmer T. High-resolution ultrasonography in evaluating peripheral nerve entrapment and trauma. *Neurosurg Focus*. 2009 Feb;26(2):E13.
- [14] Mackinnon SE. Double and multiple “crush” syndromes. Double and multiple entrapment neuropathies. *Hand Clin*. 1992 May;8(2):369–90.
- [15] Upton AR, McComas AJ. The double crush in nerve entrapment syndromes. *Lancet Lond Engl*. 1973 Aug 18;2(7825):359–62.
- [16] Rota E, Morelli N. Entrapment neuropathies in diabetes mellitus. *World J Diabetes*. 2016 Sep 15;7(17):342–53.
- [17] Atroshi I, Gummesson C, Johnsson R, Ornstein E, Ranstam J, Rosén I. Prevalence of carpal tunnel syndrome in a general population. *JAMA*. 1999 Jul 14;282(2):153–8.
- [18] de Krom MC, Knipschild PG, Kester AD, Thijs CT, Boekkooi PF, Spaans F. Carpal tunnel syndrome: prevalence in the general population. *J Clin Epidemiol*. 1992 Apr;45(4):373–6.
- [19] Schmid AB, Bland JDP, Bhat MA, Bennett DLH. The relationship of nerve fibre pathology to sensory function in entrapment neuropathy. *Brain J Neurol*. 2014 Dec;137(Pt 12):3186–99.
- [20] Han HY, Kim HM, Park SY, Kim M-W, Kim JM, Jang D-H. Clinical findings of asymptomatic carpal tunnel syndrome in patients with diabetes mellitus. *Ann Rehabil Med*. 2016 Jun;40(3):489–95.
- [21] Gulliford MC, Latinovic R, Charlton J, Hughes RAC. Increased incidence of carpal tunnel syndrome up to 10 years before diagnosis of diabetes. *Diabetes Care*. 2006 Aug;29(8):1929–30.

- [22] Oktayoglu P, Nas K, Kiliç F, Tasdemir N, Bozkurt M, Yildiz I. Assessment of the presence of carpal tunnel syndrome in patients with diabetes mellitus, hypothyroidism and acromegaly. *J Clin Diagn Res*. 2015 Jun;9(6):OC14–18.
- [23] Shiri R, Pourmemari MH, Falah-Hassani K, Viikari-Juntura E. The effect of excess body mass on the risk of carpal tunnel syndrome: a meta-analysis of 58 studies. *Obes Rev Off J Int Assoc Study Obes*. 2015 Dec;16(12):1094–104.
- [24] Meems M, Truijens S, Spek V, Visser LH, Pop VJM. Prevalence, course and determinants of carpal tunnel syndrome symptoms during pregnancy: a prospective study. *BJOG Int J Obstet Gynaecol*. 2015 Jul;122(8):1112–8.
- [25] Nakagawa M, Sekijima Y, Yazaki M, Tojo K, Yoshinaga T, Doden T, Koyama J, Yanagisawa S, Ikeda S-I. Carpal tunnel syndrome: a common initial symptom of systemic wild-type ATTR (ATTRwt) amyloidosis. *Amyloid Int J Exp Clin Investig Off J Int Soc Amyloid*. 2016;23(1):58–63.
- [26] Shiri R. Arthritis as a risk factor for carpal tunnel syndrome: a meta-analysis. *Scand J Rheumatol*. 2016 Oct;45(5):339–46.
- [27] Atcheson SG, Ward JR, Lowe W. Concurrent medical disease in work-related carpal tunnel syndrome. *Arch Intern Med*. 1998 Jul 27;158(14):1506–12.
- [28] Yamazaki T, Kawahara N, Arai K, Oyoshi K, Oshima M, Koike S, Miyauchi A, Hayasaka T, Saito T, Tsuruoka S. Utility of ultrasonography of the median nerve with a high-frequency probe for the diagnosis of dialysis-related carpal tunnel syndrome. *Ther Apher Dial Off Peer-Rev J Int Soc Apher Jpn Soc Apher Jpn Soc Dial Ther*. 2016 Oct;20(5):483–91.
- [29] Derebery J. Work-related carpal tunnel syndrome: the facts and the myths. *Clin Occup Environ Med*. 2006;5(2):353–367, viii.
- [30] Palmer KT, Harris EC, Coggon D. Carpal tunnel syndrome and its relation to occupation: a systematic literature review. *Occup Med Oxf Engl*. 2007 Jan;57(1):57–66.
- [31] Perkins BA, Olaleye D, Bril V. Carpal tunnel syndrome in patients with diabetic polyneuropathy. *Diabetes Care*. 2002 Mar;25(3):565–9.
- [32] Sax TW, Rosenbaum RB. Neuromuscular disorders in pregnancy. *Muscle Nerve*. 2006 Nov;34(5):559–71.
- [33] Bouche P. Compression and entrapment neuropathies. *Handb Clin Neurol*. 2013;115:311–66.
- [34] Bland JDP. Carpal tunnel syndrome. *BMJ*. 2007 Aug 18;335(7615):343–6.
- [35] Borg K, Lindblom U. Diagnostic value of quantitative sensory testing (QST) in carpal tunnel syndrome. *Acta Neurol Scand*. 1988 Dec;78(6):537–41.
- [36] Imai T, Wada T, Matsumoto H. Entrapment neuropathy of the palmar cutaneous branch of the median nerve in carpal tunnel syndrome. *Clin Neurophysiol Off J Int Fed Clin Neurophysiol*. 2004 Nov;115(11):2514–7.

- [37] Buch N, Foucher G. Validity of clinical signs and provocative tests in carpal tunnel syndrome. *Rev Chir Orthop Reparatrice Appar Mot.* 1995;80(1):14–21.
- [38] Padua L, Padua R, Aprile I, Pasqualetti P, Tonali P, Italian CTS Study Group. Carpal tunnel syndrome. Multiperspective follow-up of untreated carpal tunnel syndrome: a multicenter study. *Neurology.* 2001 Jun 12;56(11):1459–66.
- [39] Katz JN, Larson MG, Sabra A, Krarup C, Stirrat CR, Sethi R, Eaton HM, Fossel AH, Liang MH. The carpal tunnel syndrome: diagnostic utility of the history and physical examination findings. *Ann Intern Med.* 1990 Mar 1;112(5):321–7.
- [40] Wipperfman J, Goerl K. Carpal tunnel syndrome: diagnosis and management. *Am Fam Physician.* 2016 Dec 15;94(12):993–9.
- [41] Jablecki CK, Andary MT, Floeter MK, Miller RG, Quartly CA, Vennix MJ, Wilson JR, American Association of Electrodiagnostic Medicine, American Academy of Neurology, American Academy of Physical Medicine and Rehabilitation. Practice parameter: Electrodiagnostic studies in carpal tunnel syndrome. Report of the American Association of Electrodiagnostic Medicine, American Academy of Neurology, and the American Academy of Physical Medicine and Rehabilitation. *Neurology.* 2002 Jun 11;58(11):1589–92.
- [42] Kutlar N, Bayrak AO, Bayrak İK, Canbaz S, Türker H. Diagnosing carpal tunnel syndrome with Doppler ultrasonography: a comparison of ultrasonographic measurements and electrophysiological severity. *Neurol Res.* 2017 Feb;39(2):126–32.
- [43] Razek AAKA, Shabana AAE, El Saied TO, Alrefey N. Diffusion tensor imaging of mild-moderate carpal tunnel syndrome: correlation with nerve conduction study and clinical tests. *Clin Rheumatol.* 2016 Nov 3, 1–6, 10.1007/s10067-016-3463-y.
- [44] Padua L, Coraci D, Erra C, Pazzaglia C, Paolasso I, Loreti C, Caliandro P, Hobson-Webb LD. Carpal tunnel syndrome: clinical features, diagnosis, and management. *Lancet Neurol.* 2016 Nov;15(12):1273–84.
- [45] Ballester-Pérez R, Plaza-Manzano G, Urraca-Gesto A, Romo-Romo F, Atín-Arratibel M de LÁ, Pecos-Martín D, Gallego-Izquierdo T, Romero-Franco N. Effectiveness of nerve gliding exercises on carpal tunnel syndrome: a systematic review. *J Manipul Physiol Ther.* 2017 Jan;40(1):50–9.
- [46] Gerritsen AAM, de Vet HCW, Scholten RJPM, Bertelsmann FW, de Krom MCTFM, Bouter LM. Splinting vs. surgery in the treatment of carpal tunnel syndrome: a randomized controlled trial. *JAMA.* 2002 Sep 11;288(10):1245–51.
- [47] Povlsen B, Bashir M, Wong F. Long-term result and patient reported outcome of wrist splint treatment for carpal tunnel syndrome. *J Plast Surg Hand Surg.* 2014 Jun;48(3):175–8.
- [48] Mezian K, Bruthans J. Why do local corticosteroid injections work in carpal tunnel syndrome, but not in ulnar neuropathy at the elbow? *Muscle Nerve.* 2016 Aug;54(2):344.
- [49] Huisstede BM, Randsdorp MS, Coert JH, Glerum S, van Middelkoop M, Koes BW. Carpal tunnel syndrome. Part II: effectiveness of surgical treatments—a systematic review. *Arch Phys Med Rehabil.* 2010 Jul;91(7):1005–24.

- [50] Leblanc MR, Lalonde J, Lalonde DH. A detailed cost and efficiency analysis of performing carpal tunnel surgery in the main operating room versus the ambulatory setting in Canada. *Hand N Y N*. 2007 Dec;2(4):173–8.
- [51] Chatterjee A, McCarthy JE, Montagne SA, Leong K, Kerrigan CL. A cost, profit, and efficiency analysis of performing carpal tunnel surgery in the operating room versus the clinic setting in the United States. *Ann Plast Surg*. 2011 Mar;66(3):245–8.
- [52] Scholten RJPM, Mink van der Molen A, Uitdehaag BMJ, Bouter LM, de Vet HCW. Surgical treatment options for carpal tunnel syndrome. *Cochrane Database Syst Rev*. 2007 Oct 17;(4):CD003905.
- [53] Thoma A, Veltri K, Haines T, Duku E. A meta-analysis of randomized controlled trials comparing endoscopic and open carpal tunnel decompression. *Plast Reconstr Surg*. 2004 Oct;114(5):1137–46.
- [54] Zuo D, Zhou Z, Wang H, Liao Y, Zheng L, Hua Y, Cai Z. Endoscopic versus open carpal tunnel release for idiopathic carpal tunnel syndrome: a meta-analysis of randomized controlled trials. *J Orthop Surg*. 2015 Jan 28;10:12.
- [55] Fernandes CH, Nakachima LR, Hirakawa CK, Gomes Dos Santos JB, Faloppa F. Carpal tunnel release using the paine retinaculotome inserted through a palmar incision. *Hand N Y N*. 2014 Mar;9(1):48–51.
- [56] Jones NF, Ahn HC, Eo S. Revision surgery for persistent and recurrent carpal tunnel syndrome and for failed carpal tunnel release. *Plast Reconstr Surg*. 2012 Mar;129(3):683–92.
- [57] Rasmussen MB, Deutch SR. Pronator teres syndrome is a rare but important cause of pain in the forearm. *Ugeskr Laeger*. 2016 Nov 14;178(46).
- [58] Xing SG, Tang JB. Entrapment neuropathy of the wrist, forearm, and elbow. *Clin Plast Surg*. 2014 Jul;41(3):561–88.
- [59] Olehnik WK, Manske PR, Szerzinski J. Median nerve compression in the proximal forearm. *J Hand Surg*. 1994 Jan;19(1):121–6.
- [60] Lee HJ, Kim I, Hong JT, Kim MS. Early surgical treatment of pronator teres syndrome. *J Korean Neurosurg Soc*. 2014 May;55(5):296–9.
- [61] Komaru Y, Inokuchi R. Anterior interosseous nerve syndrome. *QJM Mon J Assoc Physicians*. 2017 Jan 10;
- [62] Ulrich D, Piatkowski A, Pallua N. Anterior interosseous nerve syndrome: retrospective analysis of 14 patients. *Arch Orthop Trauma Surg*. 2011 Nov;131(11):1561–5.
- [63] Spinner M. The anterior interosseous-nerve syndrome, with special attention to its variations. *J Bone Joint Surg Am*. 1970 Jan;52(1):84–94.
- [64] Damert H-G, Hoffmann R, Kraus A, Stowell RL, Lubahn J. Minimally invasive endoscopic decompression for anterior interosseous nerve syndrome: technical notes. *J Hand Surg*. 2013 Oct;38(10):2016–24.

- [65] Feindel W, Stratford J. Cubital tunnel compression in tardy ulnar palsy. *Can Med Assoc J*. 1958 Mar 1;78(5):351–3.
- [66] Bradshaw DY, Shefner JM. Ulnar neuropathy at the elbow. *Neurol Clin*. 1999 Aug;17(3):447–461, v–vi.
- [67] Apfelberg DB, Larson SJ. Dynamic anatomy of the ulnar nerve at the elbow. *Plast Reconstr Surg*. 1973 Jan;51(1):79–81.
- [68] Mondelli M, Giannini F, Ballerini M, Ginanneschi F, Martorelli E. Incidence of ulnar neuropathy at the elbow in the province of Siena (Italy). *J Neurol Sci*. 2005 Jul 15;234(1–2):5–10.
- [69] Contreras MG, Warner MA, Charboneau WJ, Cahill DR. Anatomy of the ulnar nerve at the elbow: potential relationship of acute ulnar neuropathy to gender differences. *Clin Anat N Y N*. 1998;11(6):372–8.
- [70] Cutts S. Cubital tunnel syndrome. *Postgrad Med J*. 2007 Jan;83(975):28–31.
- [71] Latinovic R, Gulliford MC, Hughes R A. Incidence of common compressive neuropathies in primary care. *J Neurol Neurosurg Psychiatry*. 2006 Feb;77(2):263–5.
- [72] Richardson JK, Green DF, Jamieson SC, Valentin FC. Gender, body mass and age as risk factors for ulnar mononeuropathy at the elbow. *Muscle Nerve*. 2001 Apr;24(4):551–4.
- [73] Descatha A, Leclerc A, Chastang J-F, Roquelaure Y. Incidence of ulnar nerve entrapment at the elbow in repetitive work. *Scand J Work Environ Health*. 2004;30:234–6.
- [74] van Rijn RM, Huisstede BMA, Koes BW, Burdorf A. Associations between work-related factors and specific disorders at the elbow: a systematic literature review. *Rheumatol Oxf Engl*. 2009 May;48(5):528–36.
- [75] Patterson JMM, Jaggars MM, Boyer MI. Ulnar and median nerve palsy in long-distance cyclists. A prospective study. *Am J Sports Med*. 2003 Aug;31(4):585–9.
- [76] Akuthota V, Plastaras C, Lindberg K, Tobey J, Press J, Garvan C. The effect of long-distance bicycling on ulnar and median nerves: an electrophysiologic evaluation of cyclist palsy. *Am J Sports Med*. 2005 Aug;33(8):1224–30.
- [77] Mondelli M, Grippo A, Mariani M, Baldasseroni A, Ansuini R, Ballerini M, Bandinelli C, Graziani M, Luongo F, Mancini R, Manescalchi P, Pellegrini S, Sgarrella C, Giannini F. Carpal tunnel syndrome and ulnar neuropathy at the elbow in floor cleaners. *Neurophysiol Clin Clin Neurophysiol*. 2006 Aug;36(4):245–53.
- [78] Tagliafico A, Resmini E, Nizzo R, Derchi LE, Minuto F, Giusti M, Martinoli C, Ferone D. The pathology of the ulnar nerve in acromegaly. *Eur J Endocrinol*. 2008 Oct;159(4):369–73.
- [79] Balagtas-Balmaseda OM, Grabois M, Balmaseda PF, Lidsky MD. Cubital tunnel syndrome in rheumatoid arthritis. *Arch Phys Med Rehabil*. 1983 Apr;64(4):163–6.
- [80] Shinohara T, Tatebe M, Okui N, Yamamoto M, Kurimoto S, Hirata H. Cubital tunnel syndrome caused by amyloid elbow arthropathy in long-term hemodialysis patients: report of 4 cases. *J Hand Surg*. 2011 Oct;36(10):1640–3.

- [81] Harder K, Lukschu S, Dunda SE, Krapohl BD. Results after simple decompression of the ulnar nerve in cubital tunnel syndrome. *GMS Interdiscip Plast Reconstr Surg DGPW*. 2015;4:Doc19.
- [82] Nathan PA, Istvan JA, Meadows KD. Intermediate and long-term outcomes following simple decompression of the ulnar nerve at the elbow. *Chir Main*. 2005 Feb;24(1):29–34.
- [83] Seror P, Nathan PA. Relative frequency of nerve conduction abnormalities at carpal tunnel and cubital tunnel in France and the United States: importance of silent neuropathies and role of ulnar neuropathy after unsuccessful carpal tunnel syndrome release. *Ann Chir Main Memb Supérieur Organe Off Soc Chir Main Ann Hand Up Limb Surg*. 1993;12(4):281–5.
- [84] Mallette P, Zhao M, Zurakowski D, Ring D. Muscle atrophy at diagnosis of carpal and cubital tunnel syndrome. *J Hand Surg*. 2007 Aug;32(6):855–8.
- [85] Hayashi Y, Kojima T, Kohno T. A case of cubital tunnel syndrome caused by the snapping of the medial head of the triceps brachii muscle. *J Hand Surg*. 1984 Jan;9A(1):96–9.
- [86] Morgenstein A, Lourie G, Miller B. Anconeus epitrochlearis muscle causing dynamic cubital tunnel syndrome: a case series. *J Hand Surg Eur Vol*. 2016 Feb;41(2):227–9.
- [87] Nagle DJ, Patel RM, Paisley S. Endoscopic detection of compressing fascial bands around the ulnar nerve within the FCU. *Hand N Y N*. 2012 Mar;7(1):103–7.
- [88] Earp BE, Floyd WE, Louie D, Koris M, Protomastro P. Ulnar nerve entrapment at the wrist. *J Am Acad Orthop Surg*. 2014 Nov;22(11):699–706.
- [89] Trehan SK, Parziale JR, Akelman E. Cubital tunnel syndrome: diagnosis and management. *Med Health R I*. 2012 Nov;95(11):349–52.
- [90] Prielipp RC, Morell RC, Butterworth J. Ulnar nerve injury and perioperative arm positioning. *Anesthesiol Clin N Am*. 2002 Sep;20(3):589–603.
- [91] Asamoto S, Böker D-K, Jödicke A. Surgical treatment for ulnar nerve entrapment at the elbow. *Neurol Med Chir (Tokyo)*. 2005 May;45(5):240–245.
- [92] Bacle G, Marteau E, Freslon M, Desmoineaux P, Saint-Cast Y, Lancigu R, Kerjean Y, Vernet E, Fournier J, Corcia P, Le Nen D, Rabarin F, Laulan J. Cubital tunnel syndrome: comparative results of a multicenter study of 4 surgical techniques with a mean follow-up of 92 months. *Orthop Traumatol Surg Res*. 2014 Jun;100(4 Suppl):S205–208.
- [93] Keiner D, Gaab MR, Schroeder HWS, Oertel J. Comparison of the long-term results of anterior transposition of the ulnar nerve or simple decompression in the treatment of cubital tunnel syndrome—a prospective study. *Acta Neurochir (Wien)*. 2009 Apr;151(4):311–315; discussion 316.
- [94] Sousa M, Aido R, Trigueiros M, Lemos R, Silva C. Cubital compressive neuropathy in the elbow: in situ neurolysis versus anterior transposition - comparative study. *Rev Bras Ortop*. 2014 Dec;49(6):647–52.

- [95] Chen H, Ou S, Liu G, Fei J, Zhao G, Wu L, Pan J. Clinical efficacy of simple decompression versus anterior transposition of the ulnar nerve for the treatment of cubital tunnel syndrome: a meta-analysis. *Clin Neurol Neurosurg.* 2014 Nov;126:150–5.
- [96] Macadam SA, Gandhi R, Bezuhly M, Lefaivre KA. Simple decompression versus anterior subcutaneous and submuscular transposition of the ulnar nerve for cubital tunnel syndrome: a meta-analysis. *J Hand Surg.* 2008 Oct;33(8):1314.e1–12.
- [97] Zlowodzki M, Chan S, Bhandari M, Kallianen L, Schubert W. Anterior transposition compared with simple decompression for treatment of cubital tunnel syndrome. A meta-analysis of randomized, controlled trials. *J Bone Joint Surg Am.* 2007 Dec;89(12):2591–8.
- [98] Biggs M, Curtis JA. Randomized, prospective study comparing ulnar neurolysis in situ with submuscular transposition. *Neurosurgery.* 2006 Feb;58(2):296–304–304.
- [99] Bartels RHMA, Verhagen WIM, van der Wilt GJ, Meulstee J, van Rossum LGM, Grotenhuis JA. Prospective randomized controlled study comparing simple decompression versus anterior subcutaneous transposition for idiopathic neuropathy of the ulnar nerve at the elbow: Part 1. *Neurosurgery.* 2005 Mar;56(3):522–530–530.
- [100] Schmidt S, Kleist Welch-Guerra W, Matthes M, Baldauf J, Schminke U, Schroeder HWS. Endoscopic vs open decompression of the ulnar nerve in cubital tunnel syndrome: a prospective randomized double-blind study. *Neurosurgery.* 2015 Dec;77(6):960–971.
- [101] Sener S, Menovsky T, Kloet A. Open ulnar nerve decompression using small incision and alternate positioning. *Neurosurgery.* 2014 Feb;74(2):E230–232.
- [102] Manske PR, Johnston R, Pruitt DL, Strecker WB. Ulnar nerve decompression at the cubital tunnel. *Clin Orthop.* 1992 Jan;(274):231–7.
- [103] Bartels RHMA, Termeer EH, van der Wilt GJ, van Rossum LGM, Meulstee J, Verhagen WIM, Grotenhuis JA. Simple decompression or anterior subcutaneous transposition for ulnar neuropathy at the elbow: a cost-minimization analysis—Part 2. *Neurosurgery.* 2005 Mar;56(3):531–536–536.
- [104] Dellon AL, MacKinnon SE. Injury to the medial antebrachial cutaneous nerve during cubital tunnel surgery. *J Hand Surg Edinb Scotl.* 1985 Feb;10(1):33–6.
- [105] Lowe JB, Maggi SP, Mackinnon SE. The position of crossing branches of the medial antebrachial cutaneous nerve during cubital tunnel surgery in humans. *Plast Reconstr Surg.* 2004 Sep 1;114(3):692–6.
- [106] Ruchelsman DE, Lee SK, Posner MA. Failed surgery for ulnar nerve compression at the elbow. *Hand Clin.* 2007 Aug;23(3):359–371, vi–vii.
- [107] Yoshida A, Okutsu I, Hamanaka I. Endoscopic anatomical nerve observation and minimally invasive management of cubital tunnel syndrome. *J Hand Surg Eur Vol.* 2009 Feb;34(1):115–20.
- [108] Dützmann S, Martin KD, Sobottka S, Marquardt G, Schackert G, Seifert V, Krishnan KG. Open vs retractor-endoscopic in situ decompression of the ulnar nerve in cubital tunnel syndrome: a retrospective cohort study. *Neurosurgery.* 2013 Apr;72(4):605–616–616.

- [109] Tang P, Hoellwarth JS, Chauhan A. Recurrent cubital tunnel syndrome: a critical analysis review. *JBJS Rev.* 2016 Mar 8;4(3).
- [110] Ehsan A, Hanel DP. Recurrent or persistent cubital tunnel syndrome. *J Hand Surg.* 2012 Sep;37(9):1910–2.
- [111] Campbell WW, Pridgeon RM, Sahni KS. Short segment incremental studies in the evaluation of ulnar neuropathy at the elbow. *Muscle Nerve.* 1992 Sep;15(9):1050–4.
- [112] Kanakamedala RV, Simons DG, Porter RW, Zucker RS. Ulnar nerve entrapment at the elbow localized by short segment stimulation. *Arch Phys Med Rehabil.* 1988 Nov;69(11):959–63.
- [113] Raynor EM, Shefner JM, Preston DC, Logigian EL. Sensory and mixed nerve conduction studies in the evaluation of ulnar neuropathy at the elbow. *Muscle Nerve.* 1994 Jul;17(7):785–92.
- [114] Cho Y-J, Cho S-M, Sheen S-H, Choi J-H, Huh D-H, Song J-H. Simple decompression of the ulnar nerve for cubital tunnel syndrome. *J Korean Neurosurg Soc.* 2007 Nov;42(5):382–7.
- [115] Kothari MJ. Ulnar neuropathy at the wrist. *Neurol Clin.* 1999 Aug;17(3):463–476, vi.
- [116] Bouche P, Séror R, Psimaras D, Séror P, Ebelin M. Entrapment neuropathies involving the ulnar nerve at the wrist (and into the hand) and the peroneal nerve. *Rev Neurol (Paris).* 2008 Dec;164(12):1073–6.
- [117] Kerasnoudis A, Ntasiou P, Ntasiou E. Prognostic value of nerve ultrasound and electrophysiological findings in Saturday night palsy. *J Neuroimaging Off J Am Soc Neuroimaging.* 2016 Dec 5;
- [118] Reichert P, Wnukiewicz W, Witkowski J, Bocheńska A, Mizia S, Gosk J, Zimmer K. Causes of secondary radial nerve palsy and results of treatment. *Med Sci Monit Int Med J Exp Clin Res.* 2016 Feb 19;22:554–62.
- [119] Naam NH, Nemani S. Radial tunnel syndrome. *Orthop Clin North Am.* 2012 Oct;43(4):529–36.
- [120] Urch EY, Model Z, Wolfe SW, Lee SK. Anatomical study of the surgical approaches to the radial tunnel. *J Hand Surg.* 2015 Jul;40(7):1416–20.
- [121] Konjengbam M, Elangbam J. Radial nerve in the radial tunnel: anatomic sites of entrapment neuropathy. *Clin Anat N Y N.* 2004 Jan;17(1):21–5.
- [122] Stanley J. Radial tunnel syndrome: a surgeon's perspective. *J Hand Ther Off J Am Soc Hand Ther.* 2006 Jun;19(2):180–4.
- [123] Ke M-J, Chen L-C, Chou Y-C, Li T-Y, Chu H-Y, Tsai C-K, Wu Y-T. The dose-dependent efficiency of radial shock wave therapy for patients with carpal tunnel syndrome: a prospective, randomized, single-blind, placebo-controlled trial. *Sci Rep.* 2016 Dec 2;6:38344.

- [124] Moradi A, Ebrahimzadeh MH, Jupiter JB. Radial tunnel syndrome, diagnostic and treatment dilemma. *Arch Bone J Surg*. 2015 Jul;3(3):156–62.
- [125] Sun Y, Tong P-J, Li X-J. Entrapment syndrome of posterior interosseous nerve caused by elbow cyst: 5 cases reports. *Zhongguo Gu Shang China J Orthop Traumatol*. 2013 Nov;26(11):949–52.
- [126] Quignon R, Marteau E, Penaud A, Corcia P, Laulan J. Posterior interosseous nerve palsy. A series of 18 cases and literature review. *Chir Main*. 2012 Feb;31(1):18–23.
- [127] Borman P, Tuncay F, Ulusoy G, Koçer U. Posterior interosseous nerve syndrome due to lipoma. *Neurophysiol Clin Clin Neurophysiol*. 2010 Jun;40(3):189–91.
- [128] Wu P, Yang JY, Yu C. Surgical treatment of spontaneous posterior interosseous nerve palsy with hourglass-like constriction. *J Hand Surg Eur Vol*. 2015 Jul;40(6):646–7.
- [129] Ehrlich W, Dellon AL, Mackinnon SE. Classical article: Cheiralgia paresthetica (entrapment of the radial nerve). A translation in condensed form of Robert Wartenberg's original article published in 1932. *J Hand Surg*. 1986 Mar;11(2):196–9.
- [130] Dorfman LJ, Jayaram AR. Handcuff-related cheiralgia paresthetica. *Neurology*. 1979 Jun;29(6):908–9.
- [131] Stahl S, Kaufman T. Cheiralgia paresthetica—entrapment of the superficial branch of the radial nerve: a report of 15 cases. *Eur J Plast Surg*. 1997;20(2):57–9.
- [132] Dellon AL, Mackinnon SE. Radial sensory nerve entrapment. *Arch Neurol*. 1986 Aug;43(8):833–5.
- [133] Spies CK, Müller LP, Oppermann J, Neiss WF, Hahn P, Unglaub F. Surgical decompression of the superficial radial nerve: Wartenberg syndrome. *Oper Orthopädie Traumatol*. 2016 Apr;28(2):145–52.
- [134] Kumar A, Sharma A, Singh P. Anatomical study of the suprascapular notch: quantitative analysis and clinical considerations for suprascapular nerve entrapment. *Singapore Med J*. 2014 Jan;55(1):41–4.
- [135] Hill LJN, Jelsing EJ, Terry MJ, Strommen JA. Evaluation, treatment, and outcomes of suprascapular neuropathy: a 5-year review. *PM R*. 2014 Sep;6(9):774–80.
- [136] Yamakado K. Quantification of the learning curve for arthroscopic suprascapular nerve decompression: an evaluation of 300 cases. *Arthrosc J Arthrosc Relat Surg Off Publ Arthrosc Assoc N Am Int Arthrosc Assoc*. 2015 Feb;31(2):191–6.
- [137] Ferrante MA, Ferrante ND. The thoracic outlet syndromes: part 1. Overview of the thoracic outlet syndromes and review of true neurogenic thoracic outlet syndrome. *Muscle Nerve*. 2016 Dec 22;
- [138] Laulan J. Thoracic outlet syndromes. The so-called “neurogenic types.” *Hand Surg Rehabil*. 2016 Jun;35(3):155–64.

- [139] Marty F-L, Corcia P, Alexandre J, Laulan J. True neurological thoracic outlet syndrome. Retrospective study of 30 consecutive cases. *Chir Main*. 2012 Oct;31(5):244–9.
- [140] Mackinnon SE, Novak CB. Thoracic outlet syndrome. *Curr Probl Surg*. 2002 Nov; 39(11):1070–145.
- [141] Hooper TL, Denton J, McGalliard MK, Brismée J-M, Sizer PS. Thoracic outlet syndrome: a controversial clinical condition. Part 1: anatomy, and clinical examination/diagnosis. *J Man Manip Ther*. 2010 Jun;18(2):74–83.
- [142] Machleder HI. The treatment of thoracic outlet syndrome: a comparison of different operations. *J Vasc Surg*. 1990 Aug;12(2):220–1.
- [143] Abdel Ghany W, Nada MA, Toubar AF, Desoky AE, Ibrahim H, Nassef MA, Mahran MG. Modified interscalene approach for resection of symptomatic cervical rib: anatomical review and clinical study. *World Neurosurg*. 2016 Oct 27;
- [144] Seror P, Seror R. Meralgia paresthetica: clinical and electrophysiological diagnosis in 120 cases. *Muscle Nerve*. 2006 May;33(5):650–4.
- [145] van Slobbe AM, Bohnen AM, Bernsen RMD, Koes BW, Bierma-Zeinstra SMA. Incidence rates and determinants in meralgia paresthetica in general practice. *J Neurol*. 2004 Mar;251(3):294–7.
- [146] Craig A. Entrapment neuropathies of the lower extremity. *P M R*. 2013 May;5(5 Suppl): S31–40.
- [147] Parisi TJ, Mandrekar J, Dyck PJB, Klein CJ. Meralgia paresthetica: relation to obesity, advanced age, and diabetes mellitus. *Neurology*. 2011 Oct 18;77(16):1538–42.
- [148] Cheatham SW, Kolber MJ, Salamh PA. Meralgia paresthetica: a review of the literature. *Int J Sports Phys Ther*. 2013 Dec;8(6):883–93.
- [149] Lee S-H, Shin K-J, Gil Y-C, Ha T-J, Koh K-S, Song W-C. Anatomy of the lateral femoral cutaneous nerve relevant to clinical findings in meralgia paresthetica. *Muscle Nerve*. 2016 Aug 20;
- [150] Mondelli M, Rossi S, Romano C. Body mass index in meralgia paresthetica: a case-control study. *Acta Neurol Scand*. 2007 Aug;116(2):118–23.
- [151] Van Diver T, Camann W. Meralgia paresthetica in the parturient. *Int J Obstet Anesth*. 1995 Apr;4(2):109–12.
- [152] Pauwels A, Amarenco P, Chazouillères O, Pigot F, Calmus Y, Lévy VG. Unusual and unknown complication of ascites: meralgia paresthetica. *Gastroenterol Clin Biol*. 1990;14(3):295.
- [153] Moucharafieh R, Wehbe J, Maalouf G. Meralgia paresthetica: a result of tight new trendy low cut trousers ('taille basse'). *Int J Surg Lond Engl*. 2008 Apr;6(2):164–8.
- [154] Chauhan G, Gupta K, Nayar P. Meralgia paresthetica after total hip arthroplasty in supine position. *Saudi J Anaesth*. 2013 Jan;7(1):105–6.

- [155] Shin HJ, Kim YH, Lee HW. Meralgia paresthetica-like symptoms following epidural analgesia after total knee arthroplasty. *Acta Anaesthesiol Scand*. 2014 Nov;58(10):1276–9.
- [156] Suh DH, Kim DH, Park JW, Park BK. Sonographic and electrophysiologic findings in patients with meralgia paresthetica. *Clin Neurophysiol Off J Int Fed Clin Neurophysiol*. 2013 Jul;124(7):1460–4.
- [157] Aravindakannan T, Wilder-Smith EP. High-resolution ultrasonography in the assessment of meralgia paresthetica. *Muscle Nerve*. 2012 Mar;45(3):434–5.
- [158] Klauser AS, Abd Ellah MMH, Halpern EJ, Sporer I, Martinoli C, Tagliafico A, Sojer M, Taljanovic MS, Jaschke WR. Meralgia paraesthetica: ultrasound-guided injection at multiple levels with 12-month follow-up. *Eur Radiol*. 2016 Mar;26(3):764–70.
- [159] de Ruitter GCW, Wurzer JAL, Kloet A. Decision making in the surgical treatment of meralgia paresthetica: neurolysis versus neurectomy. *Acta Neurochir (Wien)*. 2012 Oct;154(10):1765–72.
- [160] Tzika M, Paraskevas G, Natsis K. Entrapment of the superficial peroneal nerve: an anatomical insight. *J Am Podiatr Med Assoc*. 2015 Mar;105(2):150–9.
- [161] Bregman PJ, Schuenke M. Current diagnosis and treatment of superficial fibular nerve injuries and entrapment. *Clin Podiatr Med Surg*. 2016 Apr;33(2):243–54.
- [162] Poage C, Roth C, Scott B. Peroneal nerve palsy: evaluation and management. *J Am Acad Orthop Surg*. 2016 Jan;24(1):1–10.
- [163] Koller RL, Blank NK. Strawberry pickers' palsy. *Arch Neurol*. 1980 May;37(5):320.
- [164] Stewart JD. Foot drop: where, why and what to do? *Pract Neurol*. 2008 Jun;8(3):158–69.
- [165] Iwamoto N, Isu T, Chiba Y, Kim K, Morimoto D, Yamazaki K, Isobe M. Clinical features and treatment of peroneal nerve entrapment neuropathy. *No Shinkei Geka*. 2015 Apr;43(4):309–16.
- [166] Morimoto D, Isu T, Kim K, Imai T, Yamazaki K, Matsumoto R, Isobe M. Surgical treatment of superior cluneal nerve entrapment neuropathy. *J Neurosurg Spine*. 2013 Jul;19(1):71–5.
- [167] Logullo F, Ganino C, Lupidi F, Perozzi C, Di Bella P, Provinciali L. Anterior tarsal tunnel syndrome: a misunderstood and a misleading entrapment neuropathy. *Neurol Sci Off J Ital Neurol Soc Ital Soc Clin Neurophysiol*. 2014 May;35(5):773–5.
- [168] DiDomenico LA, Masternick EB. Anterior tarsal tunnel syndrome. *Clin Podiatr Med Surg*. 2006 Jul;23(3):611–20.
- [169] Pfeiffer WH, Cracchiolo A. Clinical results after tarsal tunnel decompression. *J Bone Joint Surg Am*. 1994 Aug;76(8):1222–30.

- [170] Kawakatsu M, Ishiko T, Sumiya M. Tarsal tunnel syndrome due to three different types of ganglion during a 12-year period: a case report. *J Foot Ankle Surg Off Publ Am Coll Foot Ankle Surg*. 2017 Jan 7;
- [171] Pomeroy G, Wilton J, Anthony S. Entrapment neuropathy about the foot and ankle: an update. *J Am Acad Orthop Surg*. 2015 Jan;23(1):58–66.
- [172] Pardal-Fernández JM. Bilateral tarsal tunnel syndrome due to synovitis. Combined diagnostic contribution made by ultrasound and electrophysiology. *Rev Neurol*. 2013 Jan 16;56(2):124–5.
- [173] Coraci D, Ioppolo F, Di Sante L, Santilli V, Padua L. Ultrasound in tarsal tunnel syndrome: correct diagnosis for appropriate treatment. *Muscle Nerve*. 2016 Dec;54(6):1148–9.
- [174] Wong GNL, Tan TJ. MR imaging as a problem solving tool in posterior ankle pain: a review. *Eur J Radiol*. 2016 Dec;85(12):2238–56.
- [175] Yassin M, Garti A, Weissbrot M, Heller E, Robinson D. Treatment of anterior tarsal tunnel syndrome through an endoscopic or open technique. *Foot Edinb Scotl*. 2015 Sep;25(3):148–51.
- [176] Reichert P, Zimmer K, Wnukiewicz W, Kuliński S, Mazurek P, Gosk J. Results of surgical treatment of tarsal tunnel syndrome. *Foot Ankle Surg Off J Eur Soc Foot Ankle Surg*. 2015 Mar;21(1):26–9.
- [177] Cass S. Upper extremity nerve entrapment syndromes in sports: an update. *Curr Sports Med Rep*. 2014 Feb;13(1):16–21.
- [178] Siddiq MAB, Hossain MS, Uddin MM, Jahan I, Khasru MR, Haider NM, Rasker JJ. Piriformis syndrome: a case series of 31 Bangladeshi people with literature review. *Eur J Orthop Surg Traumatol Orthop Traumatol*. 2016 Sep 19;
- [179] Carro LP, Hernando MF, Cerezal L, Navarro IS, Fernandez AA, Castillo AO. Deep gluteal space problems: piriformis syndrome, ischiofemoral impingement and sciatic nerve release. *Muscles Ligaments Tendons J*. 2016 Sep;6(3):384–96.
- [180] Fishman LM, Wilkins AN, Rosner B. Electrophysiologically identified piriformis syndrome is successfully treated with incobotulinum toxin A and physical therapy. *Muscle Nerve*. 2016 Dec 9;
- [181] Park M-S, Yoon S-J, Jung S-Y, Kim S-H. Clinical results of endoscopic sciatic nerve decompression for deep gluteal syndrome: mean 2-year follow-up. *BMC Musculoskelet Disord*. 2016 May 20;17:218.
- [182] Khoder W, Hale D. Pudendal neuralgia. *Obstet Gynecol Clin North Am*. 2014 Sep;41(3):443–52.
- [183] Ploteau S, Cardaillac C, Perrouin-Verbe M-A, Riant T, Labat J-J. Pudendal neuralgia due to pudendal nerve entrapment: warning signs observed in two cases and review of the literature. *Pain Physician*. 2016 Mar;19(3):E449–454.

- [184] Andersen KV, Bovim G. Impotence and nerve entrapment in long distance amateur cyclists. *Acta Neurol Scand*. 1997 Apr;95(4):233–40.
- [185] Örmeci B, Avcı E, Kaspar Ç, Terim ÖE, Erdoğan T, Öge AE. A novel electrophysiological method in the diagnosis of pudendal neuropathy: position-related changes in pudendal sensory evoked potentials. *Urology*. 2017 Jan;99:288.e1–288.e7.
- [186] Labat JJ, Riant T, Lassaux A, Rioult B, Rabischong B, Khalfallah M, Volteau C, Leroi A-M, Ploteau S. Adding corticosteroids to the pudendal nerve block for pudendal neuralgia: a randomised, double-blind, controlled trial. *BJOG Int J Obstet Gynaecol*. 2017 Jan;124(2):251–60.
- [187] Pérez-López FR, Hita-Contreras F. Management of pudendal neuralgia. *Climacteric J Int Menopause Soc*. 2014 Dec;17(6):654–6.