

We are IntechOpen, the world's leading publisher of Open Access books Built by scientists, for scientists

6,900

Open access books available

185,000

International authors and editors

200M

Downloads

Our authors are among the

154

Countries delivered to

TOP 1%

most cited scientists

12.2%

Contributors from top 500 universities



WEB OF SCIENCE™

Selection of our books indexed in the Book Citation Index
in Web of Science™ Core Collection (BKCI)

Interested in publishing with us?
Contact book.department@intechopen.com

Numbers displayed above are based on latest data collected.
For more information visit www.intechopen.com



Caustic Ingestion

Abdulkerim Temiz

Additional information is available at the end of the chapter

<http://dx.doi.org/10.5772/67526>

Abstract

Caustic ingestion with resultant esophagitis and gastritis is still an important social and medical problem due to early and long-term complications. This injury is seen frequently as an accidental event and may also lead to psychosocial impacts, including antisocial behavior, suicide attempts, criminal incarceration, and educational delinquency. It often occurs as a result of uncontrolled and unsafe storage of materials used in household cleaning. Despite the various treatment proposals, optimal management of the patients remains controversial. The presentation of the depth and extent of injury with endoscopy plays a key role in treatment planning. In the absence of life-threatening complications, the general approach is conservative management in the acute period. The most common complications are esophageal stricture and gastric outlet obstruction. Different treatment methods such as bougienage, stent application, balloon dilation, or esophageal replacement are used in the treatment of the caustic esophageal strictures. The decision of the least invasive method for the treatment of complications will reduce the potential hazardous results.

Keywords: caustic, esophagitis, esophageal stenosis, pyloric stenosis

1. Introduction

Caustic ingestion, which can cause severe morbidity and mortality, is still an important problem worldwide, especially in developing countries, which have an uncontrolled market selling cheap cleaning solutions of unknown composition. Despite several educational and public health initiatives to prevent caustic ingestion in children, in the United States (US), an estimated 5000–15,000 cases of caustic ingestion (incidence 1.08 per 100,000) occur each year [1]. Caustic ingestion also imposes a severe economic burden in terms of medical costs, as children with caustic injuries incurred hospital charges greater than \$22 million US dollars in 2009. It is thought that the total costs exceed these amounts when indirect costs such as parental lost

income or lodging for parents during hospitalization of children are factored in. These injuries may also lead to psychosocial impacts, including antisocial behavior, suicide attempts, criminal incarceration, and educational delinquency, as well as domestic problems such as family break-up, relocation, or loss of employment. De Jong et al. reported that 50% of children who ingested a caustic substance developed behavioral or educational problems [2]. Moreover, 25% of the families of severely affected children developed domestic problems [2]. Caustic injury may occur via accidental ingestion or as a suicide attempt. Caustic injury is usually more serious in patients who attempted suicide as compared with accidental ingestion [3]. These cases usually occur in low income and poorly educated families [4]. The age distribution of caustic injury shows a bimodal pattern [1]. The first peak is seen in children between 1 and 5 years of age. In this period, injuries always occur due to accidental ingestion. De Jong et al. reported caustic injured patients aged as young as 1 month [2]. This usually occurs due to incorrect preparation of baby food with a liquid caustic substance accidentally in infancy or the neonatal period [2, 5]. The second peak of distribution is seen during and after the pubertal period; the majority of the cases are suicide attempts [6]. The type of ingested substances varies by geography. While alkaline ingestion is usually seen in more developed countries, acidic ingestion is seen usually in developing countries.

2. Etiology and pathophysiology

Caustic ingestion often occurs as a result of uncontrolled and unsafe storage of materials used in household cleaning. The extent and outcome of caustic ingestion depends on the identity of the caustic substance, as well as the concentration, the pH, the duration of contact between the substance and tissue, and the physical form of the substance. Increased free oxygen radical production, which arises due to ischemia and direct injury, leads to excessive tissue damage in addition to direct injury from the substance. Increased tissue or blood levels of free oxygen radicals have been demonstrated in different experimental studies [7–9]. Ischemic injury occurs during the first 1–4 days, which is defined as the acute necrotic phase. Severe inflammation, necrosis, edema, and hemorrhage are observed during this period. The second period is the subacute phase, usually observed between 4 and 15 days of injury. Mucosal sloughing, bacterial invasion, mucosal ulcer with fibrin crusts and increased granulation tissue due to fibroplasia and increased collagen deposition are the main findings in the second period. Because the aforementioned healing tissue is quite fragile, esophageal perforation or complications of endoscopy may occur during this period. Thus, endoscopy is only recommended in the first 24–48 hours or 2 weeks after the injury. The chronic or cicatrization phase begins at the end of the second week and may continue for several months.

The majority of reported cases are alkaline ingestions. Alkaline ingestion causes liquefaction necrosis, saponification of fats, penetration into the deeper layers, denaturation of proteins, emulsification of cellular membranes, and thrombosis of blood vessels [10]. Because of the greater viscosity of alkaline substances compared to acidic substances, prolonged contact with the substance often occurs in alkaline ingestion. Traditionally, alkaline substances cause tissue damage at pH levels higher than 11.5. It has been reported that a 30% solution of sodium

hydroxide is able to induce a full thickness injury in 1 second. Additionally, caustic injury may occur with a lower concentration but a longer contact time. Mattos et al. demonstrated that the level of macroscopic and microscopic injury mainly depends on the concentration used as the aggressiveness of injuries gradually increases. Even a caustic soda solution at a concentration of 1.83% is able to induce epithelial necrosis in 1 hour [11]. However, they concluded that solution concentration revealed to be most important determinant in injury. Acidic injury causes coagulation necrosis; this results in the formation of an eschar, which limits the depth of penetration and injury. Injury related to acidic ingestion usually occurs with substances with a pH <2. Because of protective effects of eschar formation and rapid transit to the stomach due to low viscosity, acidic ingestion results in more gastric injury than alkaline ingestion. Commonly, gastric injury and complications occur in patients who have ingested an acidic substance, while alkaline ingestion is associated with esophageal injury and complications. Although Temiz et al. diagnosed severe gastric injury in 40.27% of acid-ingesting patients and in 10.71% of alkaline-ingesting patients, there was no difference in the rate of esophageal stricture development between these patients [5]. However, Ciftci et al. reported that the gastric outlet obstruction rate is higher with alkaline ingestion than acidic ingestion [12].

Caustic ingestion may also cause airway injury, resulting in laryngeal and lower airway edema and respiratory distress [5, 6]. Additionally, fibroblast proliferation occurs as a result of caustic injury due to alkaline or acid ingestion, resulting in circular and longitudinal contraction in the submucosal and muscular layers. The clinical manifestations are esophageal stricture, gastric outlet obstruction, gastroesophageal reflux, and hiatal hernia [10].

3. Clinical presentation

Caustic ingestion is seen frequently as an accidental event in children, especially in low income families. It usually occurs between 1 and 3 years of age [2]. The male/female ratio shows a male predominance. Clinical presentations of caustic ingestion vary from no injury to fatal complications. The outcomes and clinical findings depend on the properties of the caustic substance such as type, amount, physical form and depth, and extent of injury. Solid substances may adhere to the mucosa and be difficult to swallow. Therefore, solid substances commonly cause upper level damage, such as upper respiratory, oral cavity, or pharynx injury. Liquid substances may be swallowed easily. Thus, injury to the lower levels such as the esophagus or the stomach occurs more frequently with liquid substances. In the early stage, patients may refer with vomiting, excessive salivation, refusal to drink, apparent oral mucosal findings that vary from mild hyperemia to severe edema and diffuse fibrin sheets on lips, oral, or oropharyngeal mucosa [5, 13, 14]. Respiratory distress, stridor, hoarseness, aphonia, and dyspnea indicate respiratory tract injury. Drooling, dysphagia, odynophagia, and chest or abdominal pain usually observed in severely injured patients. Nausea or hematemesis also may occur. Gaudreault et al. reported severe esophageal burns in only 18–33% of patients with specific clinical signs and symptoms of caustic injury [13]. They concluded that positive clinical signs or symptoms cannot predict esophageal injury. Although they recommended endoscopic evaluation in symptomatic patients, they did not suggest endoscopy for asymptomatic patients, especially

those with a questionable history [13]. Temiz et al. reported severe esophageal injury in 19.3% of patients with no symptoms whereas nearly 60% of their patients with significant physical findings had no or mild esophageal injury [5]. Boskovic and Stankovic reported that 6.03% of patients with normal clinical findings had severe esophageal injuries, whereas 66.6% of patients with positive clinical findings had no or mild esophageal findings [15]. Additionally, severe gastric injury was seen in 6.8% of caustic ingestion patients; 1.7% of them had no clinical signs whereas 5.1% of them had positive clinical findings. These results show that the sensitivity and specificity of clinical findings regarding esophageal injury are 74 and 73%, respectively, with a positive predictive value of 0.33 and a negative predictive value of 0.66. They calculated these values as sensitivity 75%, specificity 68%, positive predictive value 0.15, and negative predictive value 0.97 for gastric injury [15]. Temiz et al. observed severe gastric injury in 18.5% of all caustic ingestion patients; 3.9% of these patients had normal physical findings whereas 14.6% of them had positive clinical findings [5]. Fifty percent of patients who developed gastric outlet obstruction did not have physical findings [5]. They calculated the sensitivity and specificity of clinical findings regarding severe esophageal injury as 80.6 and 32.8%, respectively. Also, they reported the sensitivity and specificity of clinical findings regarding severe gastric injury as 75.7 and 29%, respectively. Severe complications, including severe esophageal or gastric injury (especially transmural necrosis or perforation), should be considered in patients with abdominal/chest pain and hematemesis. More serious and fatal presentations secondary to caustic ingestion, such as disseminate intravascular coagulation, tracheoesophageal fistula, brachiocephalic fistula, paralyzed vocal cords, and acute pancreatitis have been reported [16, 17].

Button battery ingestion seems to cause the most severe injuries. Button battery tends to become lodged at areas of physiological narrowing in the gastrointestinal tract, such as the pharyngoesophageal junction, gastroesophageal junction, pylorus, ligament of Treitz, Meckel diverticulum or ileocecal valve (**Figure 1a** and **b**). Larger batteries usually tend to be affixed in the esophagus, whereas smaller batteries pass into the stomach and intestine [18]. Especially, button batteries with a diameter of 20 mm or larger can become lodged in the esophagus in children [19]. The complications associated with button battery ingestion are the result of a combination of four mechanisms, including leakage of the alkaline substance, absorption of the toxic substance, and necrosis secondary to either direct pressure from the battery or electrical discharge [18]. Votteler et al. demonstrated that mucosal necrosis occurred within 1 hour and ulceration within 2 hours of battery placement in an experimental study [20]. Litovitz et al. reported that batteries become lodged within 4 hours of ingestion, and esophageal perforation occurs 6 hours after ingestion [21]. These results are related to the site at which the battery is lodged, the contact time and the possibility of heavy metal absorption [18, 20, 22]. The complications of esophageal impactions are more severe than those of lower gastrointestinal impactions. The most dangerous complications, such as esophageal or aortic perforation, trachea-esophageal fistula, hemorrhagic shock, severe esophageal bleeding, and vocal cord paralysis, have been observed in patients with esophageal button battery impactions [19]. Fatal aorto esophageal fistula and perforation of the brachiocephalic artery secondary to button battery ingestion have been reported in children [23, 24].

The clinical complaints of late presenting patients are slightly different. Generally, after 3 weeks, the patients may admit with dysphagia, vomiting, or respiratory problems [25]. These complaints

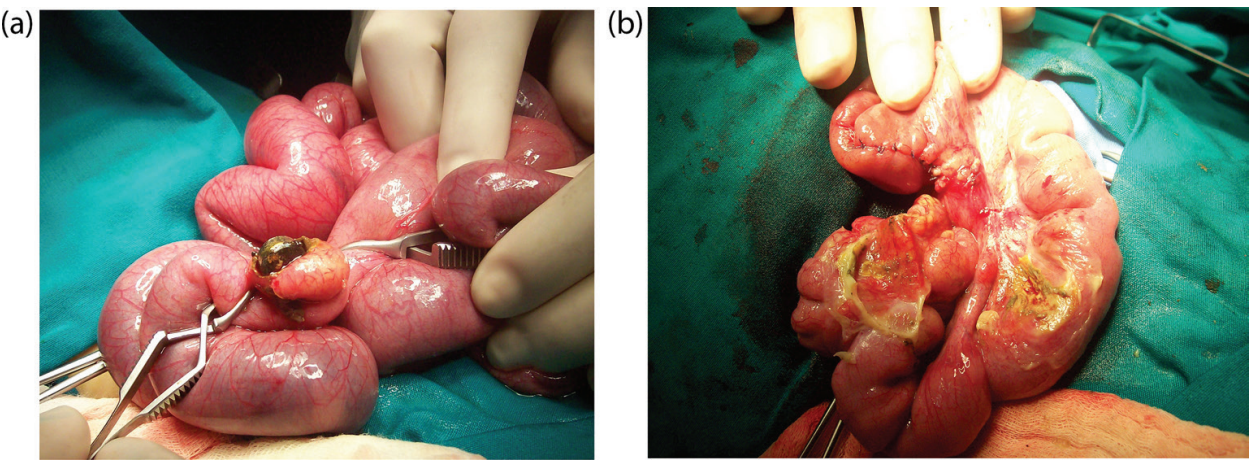


Figure 1. Perforation of Meckel’s diverticulum by button battery (a) and caustic injury of adjacent intestinal segments (b).

indicate late complications such as esophageal stricture, gastric outlet obstruction, or gastroesophageal reflux. Late complications especially esophageal strictures or gastric outlet obstructions cause dysphagia, insufficient oral intake or vomiting. Malnutrition, growth retardation, feeding intolerance, dehydration or liquid and electrolyte imbalance may develop secondary to these symptoms and complications. Obstructive complications usually occur at the level of physiological narrowing of the gastrointestinal tract, especially at three esophageal narrowing and the pylorus.

3.1. Staging

Staging is important to separate severely injured patients from mildly injured or healthy children. The classification of patients allows for the identification of patients at risk of developing early or late complications. Several different grading systems have been described and suggested in previous studies [26, 27]. The modification of the method of Di Costanzo grading system is summarized in **Table 1** [5, 28]. All classifications based on endoscopic findings have been prepared on the basis of mucosal findings, mucosal involvement, and the depth of injury.

Grade	Findings
0	Normal
1	Mucosal edema Hyperemia
2a	Hemorrhagic mucosa Bullous mucosa Exudates Fibrinous membranes Superficial ulceration
2b	Circumferential ulceration (addition to the grade 2a)
3	Scattered small necrotic area Hemorrhagic black or brown mucosa

Table 1. Modify Di Costanzo classification [5, 28].

Most researchers make modifications to previously described grading systems [3, 28]. The most preferred staging systems were Di Costanzo and Zargar grading system or their modifications [3, 10, 26–29]. Additionally, Ryu et al. have described a classification according to computed tomography findings. Computed tomography has been suggested to be more effective for the evaluation of transmural injuries to esophagus and stomach as well as necrosis [30, 31]. In our opinion, this type of imaging is advantageous in selected cases, especially in patients with necrosis or perforation, although the radiation effects of computed tomography must be considered.

3.2. Complications

The complications that develop secondary to caustic ingestion are divided into early and long-term complications. Early complications are usually related to the acute effects of the caustic substance, which generally manifest as tissue necrosis. Chemical pneumonitis, atelectasis, aspiration pneumonia, and dysphagia are some of early complications due to the acute effects of ingestion [2]. Tracheoesophageal fistula is another early stage complication. Poley et al. detected severe systemic complications more frequently among patients who ingested acidic substances than those who drank alkaline substances in their report on adolescent and adult patients [28]. They reported renal insufficiency, hepatic dysfunction, diffuse intravascular coagulation, and hemolysis as systemic complications [28]. These authors reported 16% overall mortality. They showed a worse death rate with the ingestion of acidic substances compared with alkaline substances (14 vs. 2%); 11% of overall mortality was related to systemic complications [28]. Early complications may also have catastrophic consequences, and some complications can result in death [23]. Ulceration, edema, gastrointestinal hemorrhage, total loss of the vocal cord, vocal cord paresis, denuded epiglottis, aorta esophageal fistula, esophageal perforation, perforation of Meckel's diverticulum, and perforation of the brachiocephalic artery are early stage complications that have been reported previously [18, 19, 24, 32–37]. Acute pancreatitis has been reported as an early complication secondary to accidental caustic ingestion in a young adult [16]. Skin injuries are seen in some cases (**Figure 2a** and **b**).

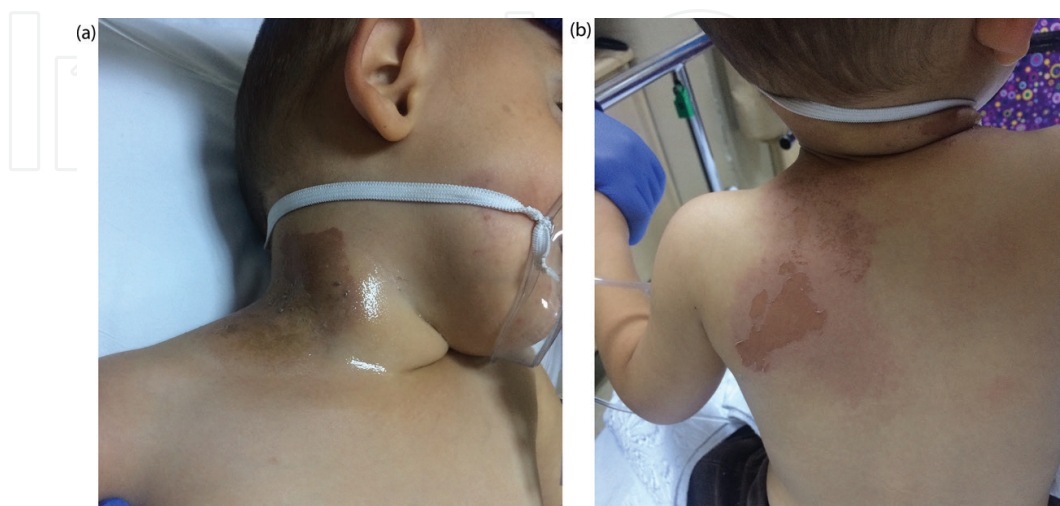

Figure 2. Injury of the neck (a) and back (b) resulting from casting onto the skin during caustic ingestion.

Long-term complications usually develop 3 weeks after the injury. Most commonly, strictures occur due to increased fibrosis in the injured area. The esophagus is the most severely affected gastrointestinal segment in most caustic ingestion patients. Therefore, the majority of upper gastrointestinal strictures secondary to caustic ingestion develop in the esophagus. Esophageal strictures may involve a short segment (usually accepted as shorter than two vertebral bodies in length) or a long segment (described as more than two vertebral bodies in length), or even the whole esophagus [38, 39] (**Figure 3a–d**). The rate of esophageal stricture has been reported to be between 2 and 63% in different series [2, 13, 29, 40–42]. Baskin et al. reported that 4.7% of grade-2a injured patients and 26% of grade 2b injured patients

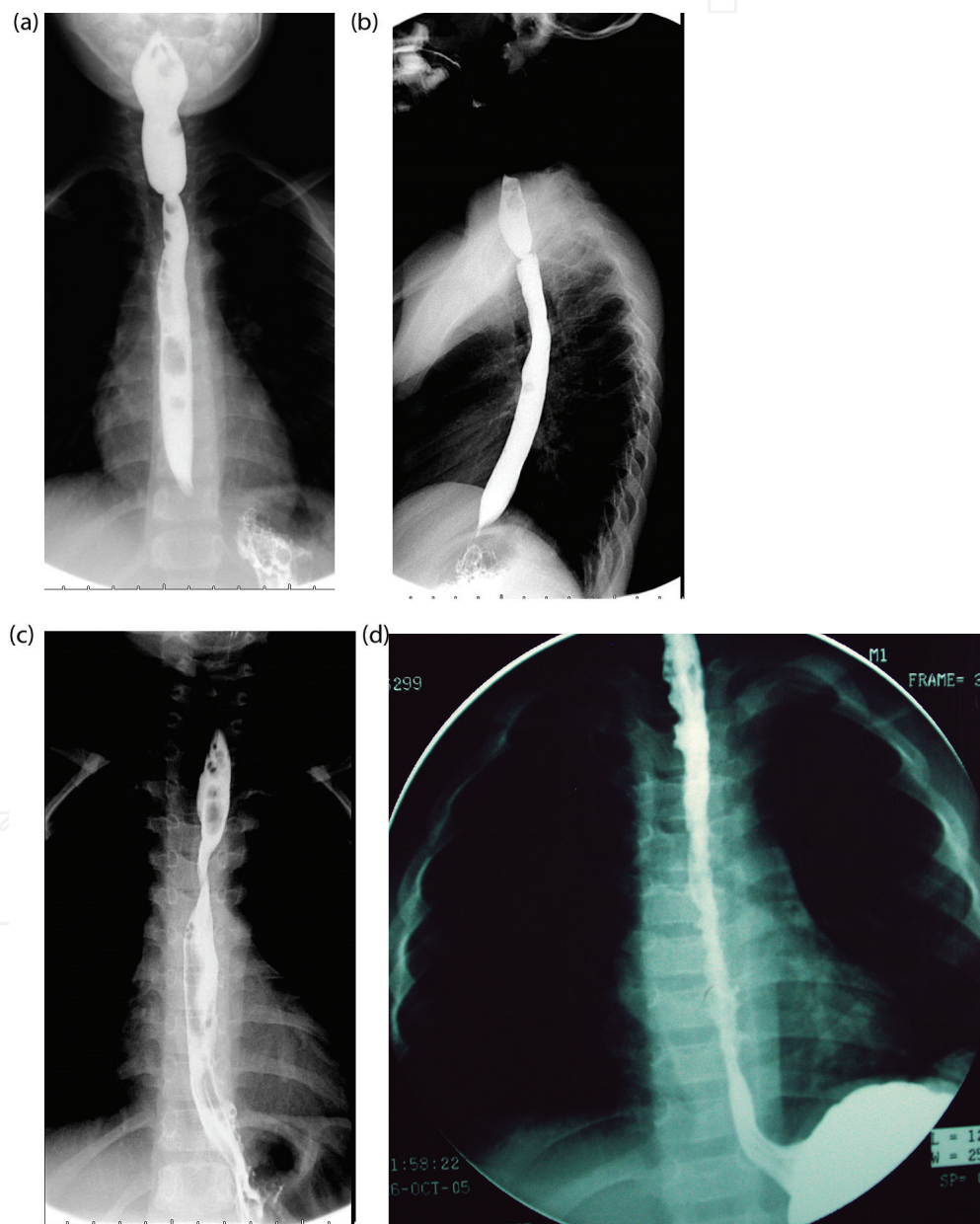


Figure 3. Barium meal studies reveal short segment (a and b) and long segment (c and d) stricture of esophagus in 7 years old boy and 15 years old girl respectively.

develop esophageal strictures [29]. Huang et al. reported that all grade 2 and 3 injured patients develop esophageal strictures [40]. Temiz et al. showed an esophageal stricture rate of 32.1 and 100%, respectively, in patients with grade 2b and 3 injuries [5]. The second most common level of upper gastrointestinal stricture due to caustic ingestion is the pylorus (**Figure 4**). This usually occurs due to accumulation of the ingested substance at the antrum or pylorus level. Several studies have reported that the overall incidence of gastric outlet obstruction is between 5 and 10% [12, 43–45]. Temiz et al. showed a pyloric obstruction rate of 15.7% in patients with severe gastric injury [5]. Gastric outlet obstruction may present with gastroesophageal reflux symptoms. The third long-term complication of caustic ingestion is gastroesophageal reflux and hiatal hernia (**Figure 5**). It occurs as a result of esophageal shortening and retraction due to the inflammation and fibrosis that develop secondary to the ingestion injury. Progressive inflammation and fibrosis may cause disruption of His' angle and even a hiatal hernia. This clinical presentation may cause growth retardation or the inability to eat. Also, gastroesophageal reflux may increase the rate of esophageal stricture and influence the response to the treatment of esophageal stricture.

Esophageal carcinoma is another long-term complication [46–48]. This is usually squamous cell carcinoma. Appelqvist and Salmo showed in patients that had ingested lye (the mean age of patients at the time of lye ingestion was 6.2) that the mean latent period between ingestion and esophageal carcinoma was 41 years [46]. Moreover, 84% of these patients had squamous cell carcinoma at the middle part of esophagus. Kochhar et al. reported two patients with esophageal carcinoma after acidic agent ingestion [49]. Patients with esophageal strictures secondary to caustic ingestion have more than a 1000-fold risk of

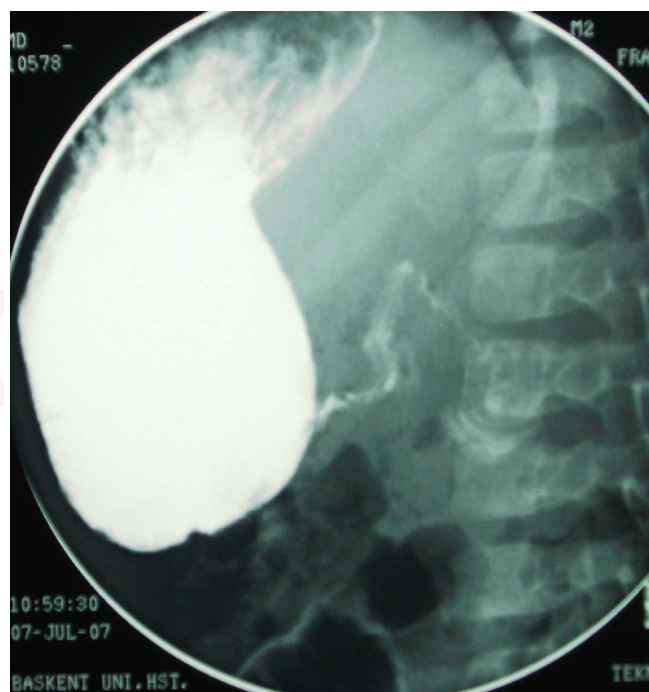


Figure 4. Barium meal study reveals pyloric stenosis secondary to the acidic substance ingestion.

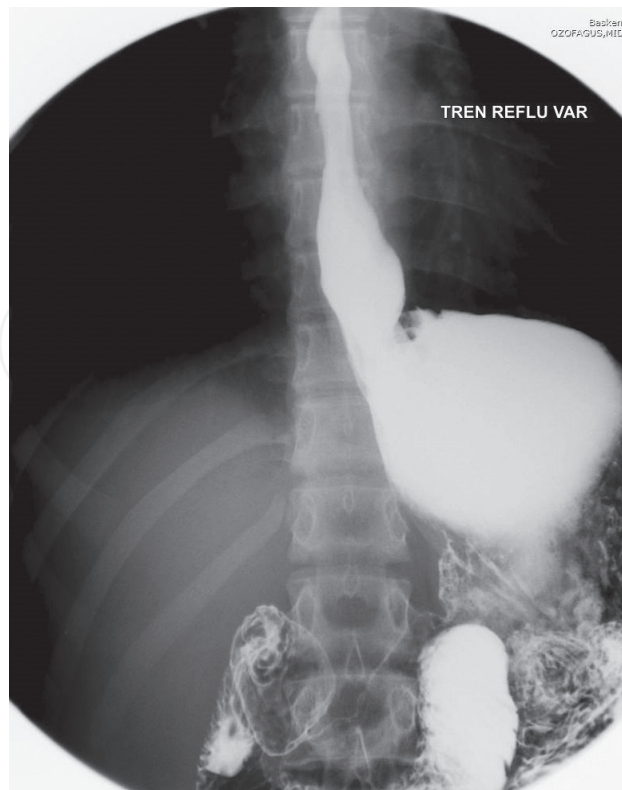


Figure 5. Gastroesophageal reflux and sliding type of hiatal hernia is presented by contrast study.

developing esophageal carcinoma [49]. Appelqvist et al. reviewed a total of 2414 patients with esophageal carcinoma and found that 2.6% of them had a history of caustic injury of the esophagus [46].

4. Diagnostic methods

Several techniques and methods, including laboratory tests, radiological studies, scintigraphy, and endoscopy, are used to determine the severity and depth of injury.

4.1. Laboratory

White blood cell count, C-reactive protein, plasma creatinine level, aspartate aminotransferase (AST), alanine aminotransferase (ALT), and blood gases are usually assessed in serious cases. These tests can be used both in diagnosis and in management to define whether the patient has developed complications. High white blood cell counts ($>20,000$ cells/mm³), low arterial pH (<7.22), and low base excess (<-12) are considered signs of serious esophageal injury in adults [50, 51]. However there is no clinical study that examined the relation of laboratory findings and caustic injury level. Laboratory tests are also used for the detection and monitoring of systemic and metabolic complications such as liver damage or renal insufficiency [28].

4.2. Endoscopy

Several studies have indicated that clinical signs are not helpful in predicting the degree of injury and late complications. However, the necessity for endoscopy has been discussed in the literature previously; esophagogastroduodenoscopy is still the most preferred and effective diagnostic practice and approach [4, 5, 28, 53]. It is based on direct visualization and staging of injury according to the grading system previously described. It can be performed using a rigid or flexible endoscope. While only the esophagus can be seen by rigid endoscopes, both the esophagus and the stomach can be seen with a flexible endoscope. It is recommended within the first 24–48 hours after injury. The burned area of the esophagus is weakest between days 7 and 21 after injury [2]. Due to the high frequency of complications related with endoscopy, such as fistulas, perforation or bleeding, it is not recommended in patients with high grade injuries [2]. Moreover, it is usually recommended to stop endoscopy at the first severe circumferential burn because of the risk of complications [2, 52]. Poley et al. reported that the esophagus was the most severely affected segment of the upper gastrointestinal tract in 79% of their patients [28]. Injury to the stomach, especially the fundus and body, was relatively common. They observed damage to the duodenum only in 6% of their patients [28]. Doğan et al. observed gastric injury in 17.1% of patients [53]. Urgancı et al. reported normal or mild injury (57%), severe esophagitis (19.1%), erosive gastritis (4.3%), gastric necrosis (0.3%), esophagogastritis (3.7%), and esophagogastroduodenitis (4%) in their series [4]. Temiz et al. reported that 18.4% of patients with severe esophageal injury likewise had severe gastric injury (**Figure 6a–d**). Also, 3.4% of their patients had more severe damage to the stomach than to the esophagus [5]. They performed complete upper gastrointestinal endoscopy to avoid overlooking a gastric injury, even in patients with severe esophageal damage. They reported that there were no complications due to late or complete endoscopy, even in severely damaged patients [5]. There are many articles about esophageal endoscopic findings, but there are limited studies providing gastric findings after caustic ingestion in children [5, 28]. Poley reported that normal findings or mild esophageal injury was found in 40% of patients, while this value was 80% in a study by Boskovic [15, 28]. Doğan et al. reported normal or mild injury in 47.5% of patients [53]. Temiz et al. reported that 43.2% of their patients had normal or mild esophagitis demonstrated by endoscopy, while they all presented with positive clinical findings [5]. In this way, unnecessary hospitalization was prevented by endoscopy [5, 15, 28]. Also, endoscopy can be used for planning the treatment of possible complications such as early dilation of the esophagus in severely injured patients [5, 54]. Radiologically suspected or proven gastrointestinal perforations, severe respiratory injury with distress, poor general condition or metabolic imbalance are accepted as contraindications of endoscopy. However, endoscopy can be performed under sedation within a short period of time. The rate of complications related to endoscopy is very low. Bleeding, perforation, and mucosal tears are complications of endoscopy. Iqbal et al. reported a 0.06% rate of complications in all endoscopy procedures, regardless of the indication [55]. Although Doğan et al. reported that esophageal perforation occurred after endoscopy in one patient (0.21%), most of the articles which examined the results of endoscopy in caustic ingestion patients reported no complications [5, 15, 28, 53]. Although many articles have emphasized the importance of early endoscopy in planning the treatment strategy, some centers do not offer early endoscopic examination, claiming that

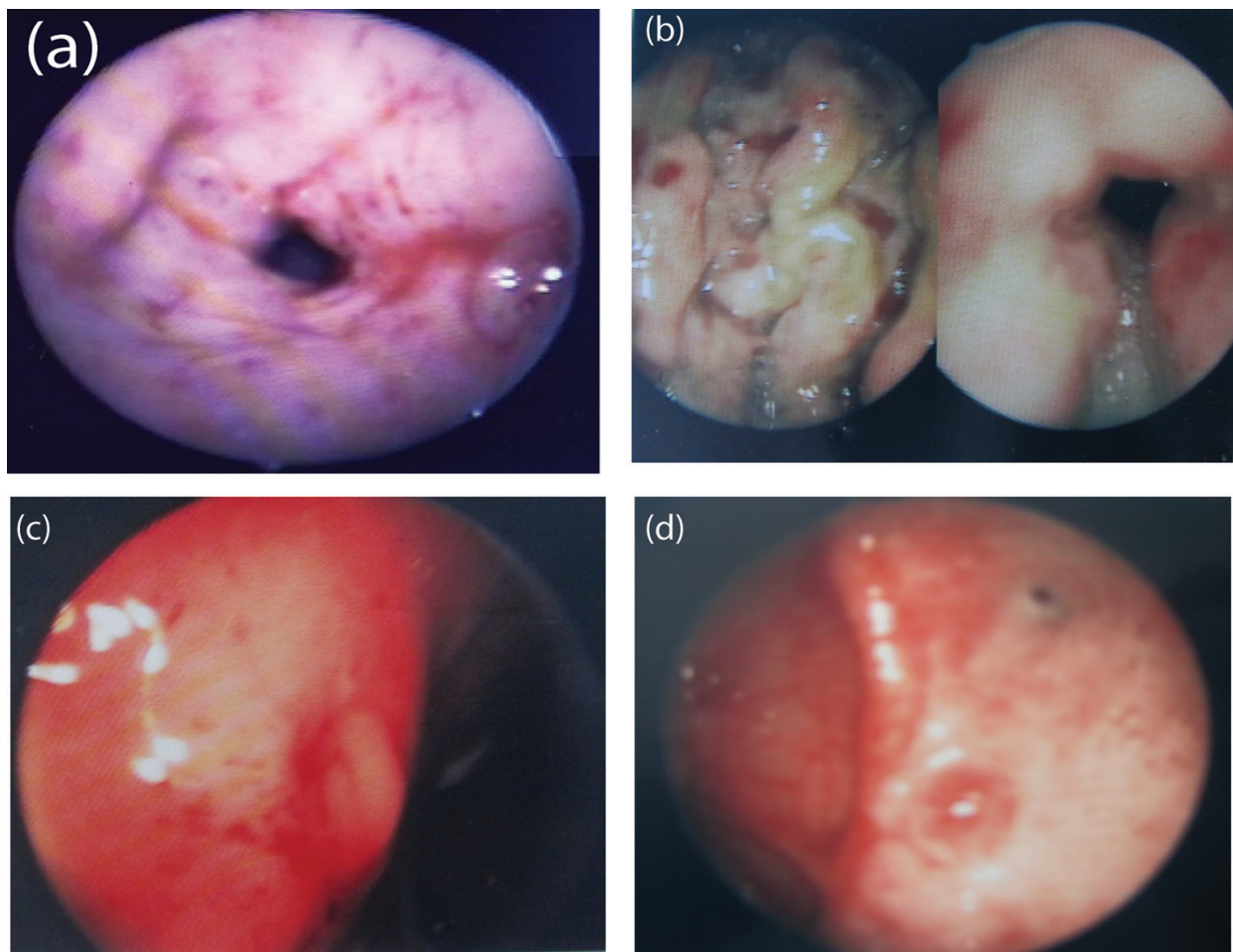


Figure 6. Endoscopy demonstrated the severe caustic injury in the esophagus (a) antrum and pylorus (b). Pylorus narrowing was observed in the control endoscopy (c). A pint point appearance of pylorus in a patient admitted during the past period (d).

endoscopic findings do not change treatment strategies [14, 42, 56]. Additionally, the risk of general anesthesia and the complications of endoscopy are avoided using these protocols [42]. Lamireau et al. reported that the absence of symptoms was always associated with no or minimal lesions in their patients. Therefore, they did not recommend endoscopy in asymptomatic patients, especially in developed countries [14]. In the same way, Gupta et al. reported that all patients with clinically significant injuries were symptomatic. Also, all asymptomatic patients had normal findings on endoscopic examinations [56].

4.3. Scintigraphy

In the last two decades, clinical and experimental studies have been performed assessing the value of scintigraphic evaluation and detection of caustic injury of the esophagus [57, 58]. Millar et al. performed a prospective clinical study to assess whether sucralfate has an affinity for the chemically injured esophagus and to assess the accuracy of radiolabeled sucralfate as an indicator of the presence and extent of esophageal injury [57]. They

found that technetium-99m scintigraphy is an accurate diagnostic method to assess caustic esophageal injury [57]. Technetium-99m pyrophosphate scintigraphy has been used in diagnostic studies on the detection of caustic esophageal injury [58, 59].

In the late period, scintigraphic studies may be used to evaluate esophageal transit time, gastric emptying and gastroesophageal reflux, which are common complications [60]. Technetium-99m sulfur colloid in milk or formula is often used for gastrointestinal scintigraphic studies [61]. Kochhar et al. performed a study to assess esophageal motor dysfunction in patients with corrosive esophageal stricture. They used segmental and total esophagus transit time. They found that esophageal transit time is prolonged in one-third of patients with corrosive injury-induced esophageal strictures despite adequate esophageal dilatation. They also reported that these findings were correlated with the length of the stricture and the severity of dysphagia [62].

4.4. Radiology

Several radiological modalities are used to define early and late complications. These studies vary from simple plain chest or abdominal X-ray to complex contrast studies such as cine esophagography or computerized tomography.

4.4.1. Chest X-ray, erect abdominal X-ray

Pneumothorax, pneumomediastinum, or pneumoperitoneum, which are signs of esophageal or gastric perforation, can be observed. These methods are often used in patients with hematemesis.

4.4.2. Esophagogastrography

This is useful for the demonstration of early or late complications. Esophageal stenosis, hiatal hernia, gastroesophageal reflux, pyloric stenosis, esophageal perforation, gastric perforation or tracheoesophageal fistula can be demonstrated with contrast studies. Traditional esophagography may not show pathology in some cases. In these situations, cine esophagography may be helpful (**Figure 7**). In suspected patients, the uses of water-soluble substances, which are less irritant than barium, are preferred for the demonstration of esophageal or gastric perforation (**Figure 8**). However, more radiologic details with better images are obtained with barium meal studies. Contrast studies are also used to determine the location and length of the esophageal stricture (**Figure 9a and b**).

4.4.3. Ultrasonography (US)

There have been some studies that focused on the utility of endoscopic esophageal or gastric miniprobe US to predict of outcomes of caustic injury [63–66]. The basis for this method is to evaluate the integrity of the mucosa and deeper muscle layers or to assess gastric wall thickness. Endoscopic ultrasonographic findings are classified as grade-1 when involving only the mucosal edema and grade-2 and grade-3 with destruction of the muscular layers. Grades 2

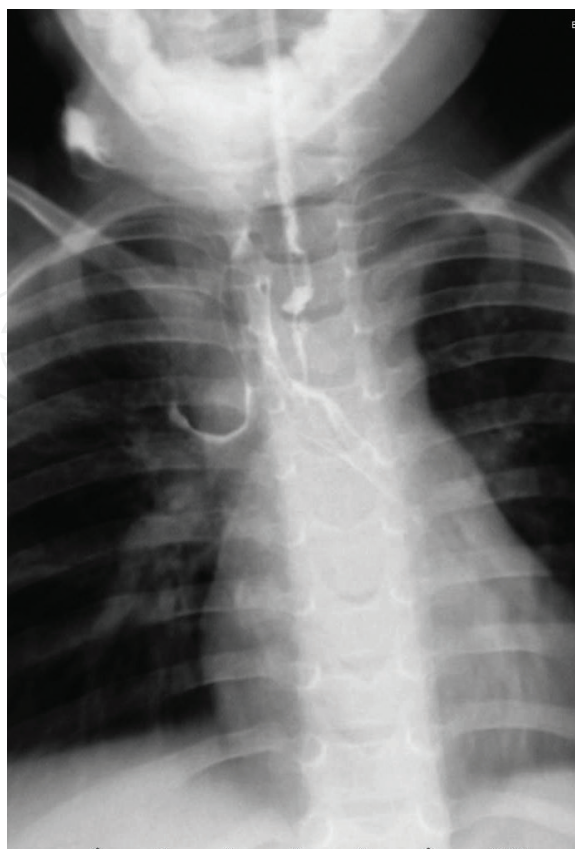


Figure 7. Tracheoesophageal fistula was described by cine esophagography.

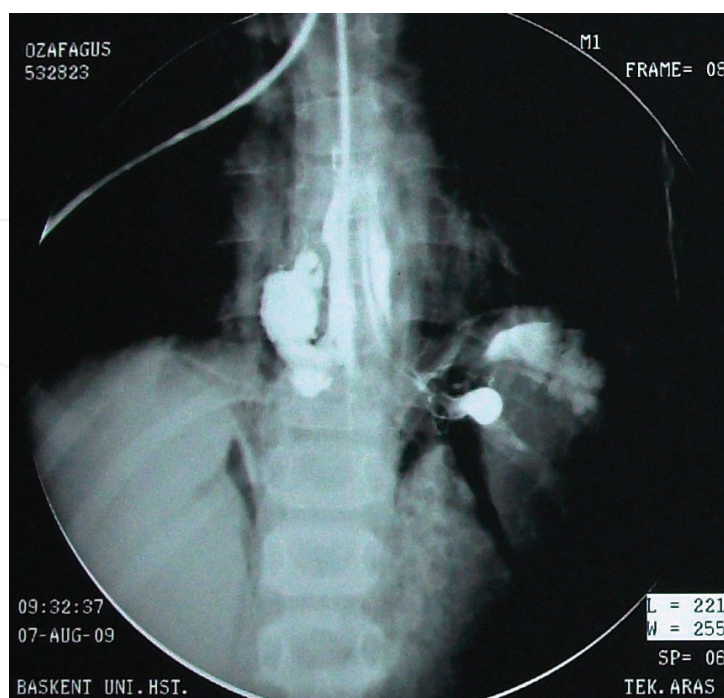


Figure 8. Contrast meal study revealed esophageal perforation after dilatation session.

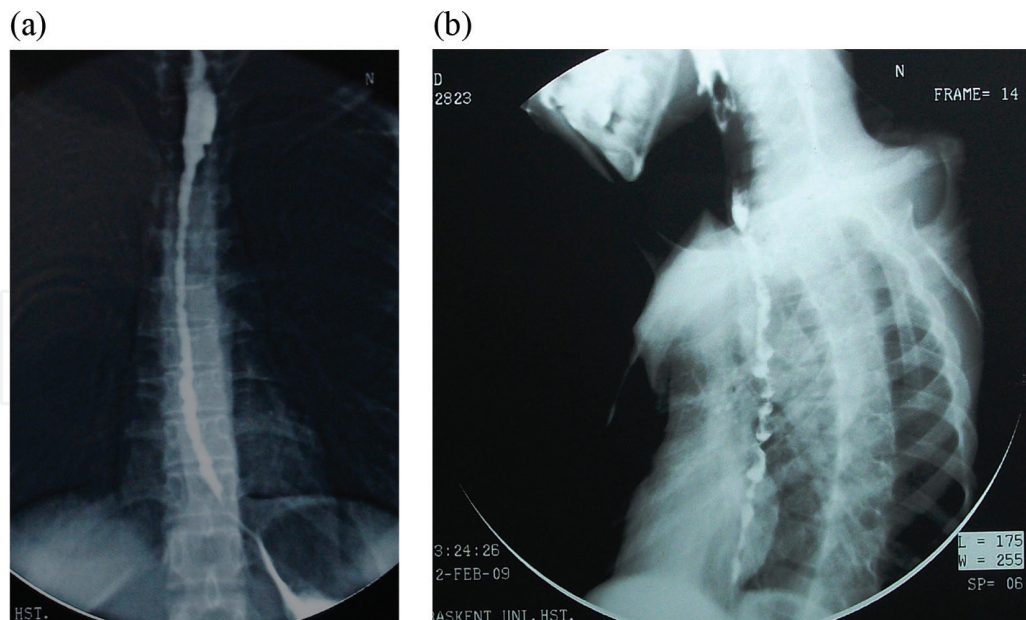


Figure 9. (a) and (b) Multiple and long segment strictures of esophagus were showed by esophagography.

and 3 are associated with the development of future esophageal or gastric strictures [63–66]. However, Chiu et al. reported that US does not increase the accuracy of predicting early or late complications when used in conjunction with conventional endoscopic observation [66].

4.4.4. Computerized tomography (CT)

CT is usually used to define transmural injury and the extent of necrosis in patients with complications such as esophageal or gastric perforations due to caustic ingestion. Ryu et al. recently described a grading system to predict late complications after caustic ingestion [30].

5. Treatment

The treatment approach to caustic ingestion can be divided into two stages: acute management and the treatment of complications.

5.1. Acute management

The acute management of caustic ingestion is based on the general principles of acute trauma life support guidelines. The aim of this approach is the stabilization of vital functions. This includes continuity of the airway and respiratory function and controlling the circulation. Hemodynamic and respiratory stabilization should be priority aims. Endotracheal intubation may be necessary in patients with severe airway caustic injury. Intubation can be difficult in patients with a severely affected airway. Fiber optic laryngoscopy may provide direct

visualization and safe intubation. Thus, the complications that occur secondary to blind intubation may be prevented [6, 10]. Oral feeding is discontinued and adequate intravenous fluid replacement should be provided [10, 31]. A detailed history and identification and measurement of the pH level of the ingested caustic substance will provide information about the severity of the injury. Chest and erect abdominal X-ray should be performed to look for pneumomediastinum, pneumothorax, and pneumoperitoneum, which indicate esophageal or gastric perforation. pH neutralization is not recommended, because it can increase damage by direct effects on the mucosa. This may also cause emesis and vomiting, which may cause recurrent injury to the esophagus [10]. Nasogastric decompression is recommended to prevent vomiting and to provide gastric decompression. However, the benefits have not been conclusively shown. It may be used as a stent in severe circumferential injury. The placement of nasogastric tubes is recommended under endoscopic visualization to prevent esophageal perforation. Oral feeding is still controversial. The authors who believe in the necessity of endoscopy recommend feeding after endoscopy if the findings are normal or mild [5, 53]. In patients with severe esophagitis, enteral nutrition may be applied via a nasogastric tube. However, some authors prefer enteral nutrition without endoscopy for patients who are able to swallow their saliva easily [42]. They perform barium contrast esophagography after 3 weeks. In cases of esophageal or gastric stricture, endoscopy and dilatation are performed [42]. Total parenteral nutrition is preferred in patients with severe gastric injury or who are intolerant to enteral nutrition with normal gastroscopic findings [5, 42]. Proton pump inhibitors or H₂ antagonists are usually recommended to prevent possible gastroesophageal injury or stress ulcers [25, 29, 31]. However, the beneficial effects of agents that reduce gastric pH levels remain unclear. Broad spectrum antibiotics are preferred by many authors, especially in patients with airway injury [5, 6, 25]. However, there is no evidence that antibiotics reduce infections of the injured area or the rate of stricture formation. The benefits of corticosteroids are still controversial. Two different studies that presented a meta-analysis of the literature regarding the use of corticosteroids in caustic injury showed that steroids do not have beneficial effects [67, 68]. Anderson et al. found that there is no benefit from the use of steroids in caustic injured patients regarding the rate of stricture formation [69]. However, there are also studies presenting the opposite opinion. Mamede et al. found that antibiotics combined with corticosteroids reduced the incidence of stenosis [70]. These authors reported infection and gastrointestinal bleeding as side effects of corticosteroids, especially in patients who had ingested large amounts of a caustic substance. Bautista et al. also reported that dexamethasone had better effects than prednisone [71]. Usta et al. investigated the effects of a high dose methylprednisolone (1 g/1.73 m²) on caustic esophageal burns [72]. They found that the stricture development rate and the duration of total parenteral nutrition were statistically significantly low in the methylprednisolone group [72]. Boukthir et al. reported that high dose methylprednisolone seems to improve the prognosis and prevent stricture formation in grade-2b injured patients [73]. Another situation is the treatment of metabolic complications of caustic injury including renal insufficiency, hepatic dysfunction, diffuse intravascular coagulation, and hemolysis or acute pancreatitis. Supportive care and medication are important [28]. Blood and blood product replacement, hemodialysis and other medications are arranged depending on the clinical and laboratory findings of the patient.

5.2. Treatment of complications

5.2.1. Acute complications

The most severe acute complications are esophageal and gastric perforations. These complications are diagnosed by regular chest or abdominal X-ray. Esophageal perforation is commonly described in adult patients. Aggressive surgical interventions such as esophagectomy or esophagostomy are recommended in adults with esophageal perforation [74, 75]. It is known that more conservative treatment modalities are preferred in several diseases in children. Tube thoracostomy into the pleural space or mediastinum may be performed. However, gastric perforation due to caustic ingestion is more often reported than esophageal perforation in children [76–78]. It is diagnosed by a pneumoperitoneum under the diaphragm and requires immediate surgery. Partial or total gastrectomy with roux-n-y gastrojejunostomy or esophagojejunostomy or different gastrointestinal reconstruction procedures may be required.

5.2.2. Esophageal stricture

Esophageal stricture is most serious complication of caustic ingestion. It usually occurs in patients with grade 2a and more severe injury. Various treatment approaches ranging from minimally invasive methods such as balloon dilatation to aggressive surgery such as colonic transposition have been described.

5.2.2.1. Dilatation

Bougienage has traditionally been used as a first step in the treatment of esophageal stricture. Bougienage can be performed both antegradely by using Savary-Gilliard dilators over a guide wire and retrogradely via gastrostomy. Balloon dilatation has recently become the most common and preferred method of dilatation [38, 79–81]. The dilatation force is applied equally and radially at the esophageal wall with balloon dilatation; rigid dilators induce axial, radial, and shearing force [80, 82]. Balloon dilation can be performed easily with low complication rates in experienced hands. Esophageal perforation is the most serious complication of esophageal balloon dilatation and has been reported to occur in 0.33–45% of balloon dilatation sessions in previous studies [38, 80, 83, 84]. Esophageal perforations usually occur in patients with delayed treatment or with long segment strictures that have become fibrotic. Esophageal perforations that occur secondary to dilatation are almost always treated with a conservative approach [38, 76, 79]. Respiratory distress, fever, or severe chest pain could cause a perforation after dilatation. Chest X-ray may reveal pneumothorax or pneumomediastinum. Treatment with broad spectrum antibiotics and the interruption of feeding are the initial treatment steps. Chest tube insertion may be required in respiratory distress or in the presence of pleural effusion. However, complication rates can be reduced by using a staged dilatation, i.e., gradually increasing the diameter over consecutive sessions to the required balloon diameter with experienced hands [38, 79]. It is known as remodeling time; stabilization of the esophageal stricture requires between 6 months and 3 years. In light of this information, long-term dilatation may be required in severe cases [38, 85]. Gündoğdu et al. reported that the success rate of conservative approach was higher in patients younger

than 8 years of age, and in strictures due to caustics other than lye involving upper third portion and less than 5 cm of length [85]. Repeated hospitalization and general anesthesia are accepted as disadvantages of long-term dilatation. Doo et al. reported a 91% technical success rate and a 64% clinical success rate [84]. Kim et al. obtained a 100% technical success rate and a 46% clinical success rate in their patients [39]. However, Alshammari et al. reported a 33% failure rates for balloon dilatation of caustic esophageal strictures [86]. Temiz et al. reported the results of long-term dilatation up to 4 years; full recovery occurred with long-term dilatation [38]. The author suggested that balloon dilatation is a safe and effective method and that the dilatation program should be carried out for at least 2 years before deciding that dilatation has failed [38]. Tiryaki et al. reported their experience with early prophylactic bougienage methods. They found that the strictures had resolved after 6 months of dilatation in patients initially treated prophylactically with early bougienage, whereas stricture resolution did not occur for more than 1 year in patients in whom dilatation began after stricture development [54]. Uygun et al. evaluated their early and late dilatation results in patients with short and long segments caustic esophageal strictures [79]. They reported a 100% success rate. Also, they reported that treatment with early balloon dilatation was significantly faster and shorter than that in the late dilatation group, and short stricture treatment was also of significantly shorter duration than long stricture treatment [79]. However, there are no controlled data to support the use of early dilatation, which could increase the risk of perforation [87].

Balloon dilatation is usually performed as one dilatation every 3 weeks for the first 3 months with subsequent modifications as required thereafter [88]. However, the patient's complaints and clinical condition are the most influential factor on the frequency of sessions. Temiz et al. reported that dilatations were performed weekly initially [38]. Eventually, balloon dilatation will be accepted as a safe and effective treatment modality with a low rate of complications for caustic esophageal strictures [38, 42, 79, 89].

5.2.2.1.1. *Balloon dilatation technique*

This operation is performed under general anesthesia. The radiopaque guide wire is introduced fluoroscopically or endoscopically to the stomach. The balloon catheter is pushed over the wire and placed in the stricture. Then, the balloon is inflated with radiocontrast solution. The balloon is inflated until a flattening of the hourglass deformity of the stricture observed for 2–4 minutes [38, 42] (**Figure 10a–c**). The same procedure is applied at each location for multiple or long segment strictures. The first dilatation starts with the smallest balloon even 4 or 6 mm diameter. The balloon sizes are increased to the appropriate diameter equal to the patient's esophageal diameter, defined by the thumb rule, i.e., the esophageal diameter is equal to the diameter of the patient's own thumb [42, 90].

5.2.2.2. *Stenting*

Intraluminal esophageal stenting is an option in cases of intractable strictures. It should be mentioned that stenting should be continued until complete esophageal healing. Therefore, stenting is a long-term treatment strategy. Mutaf reported outcomes with polytetrafluorethylene stents

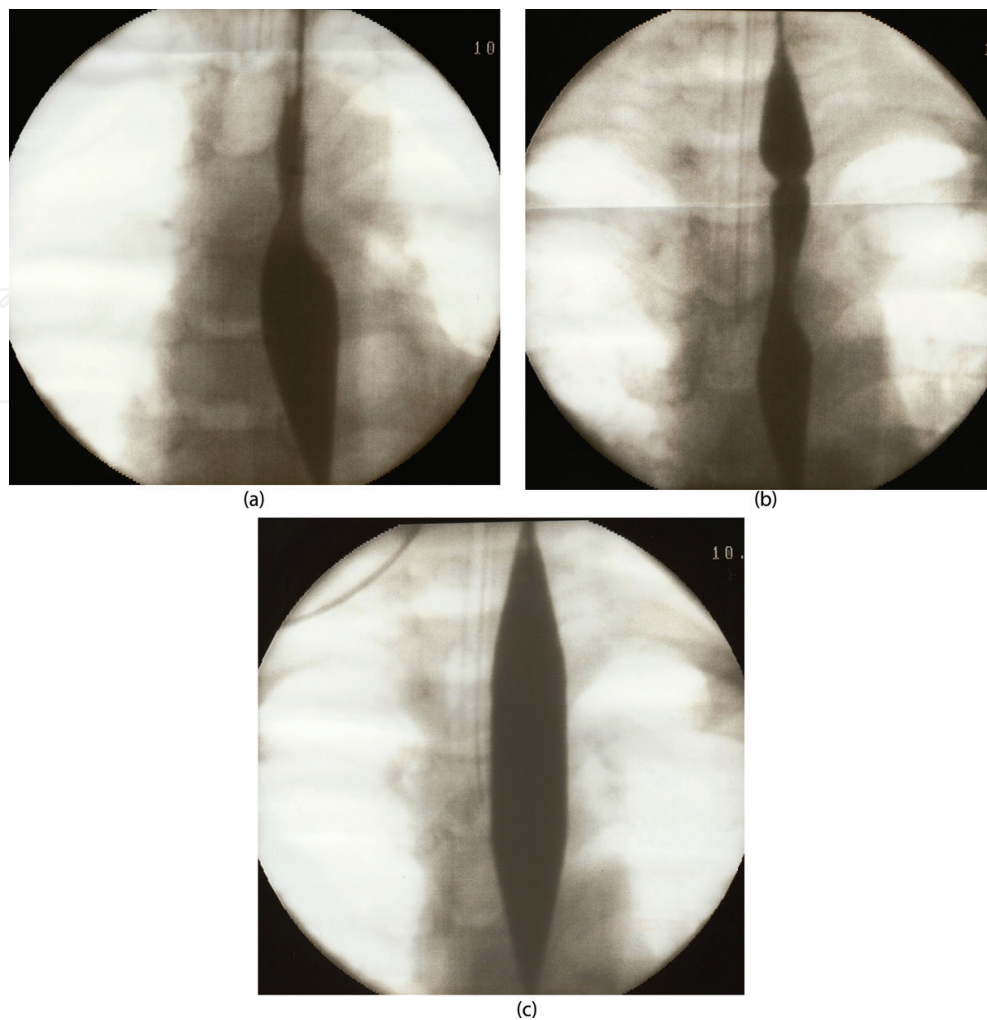


Figure 10. (a)–(c) The balloon catheter is pushed over the wire and placed in the stricture. Then, the balloon is inflated with radiocontrast solution until a flattening of the hourglass deformity.

5 mm in diameter or larger [88]. The stent was replaced with a 1 mm larger stent every third week, and was left in place for 1 year after a stent diameter of 10 mm was reached. However, stent placement is usually applied after dilatation session in different series [91–93]. Using this method, a success rate of 68% was reported. Atabek et al. also reported that 72.7% of their patients resumed normal feeding after 9–14 months of stenting. So, long-term stenting is an effective method to reduce the necessity for major surgical intervention for recalcitrant esophageal strictures [91]. Foschia et al. reported an 86.6% success rate with dynamic stents. They claimed that stenting reduces the necessity of dilatation sessions [92]. Gastroesophageal reflux and poor patient compliance are the most commonly encountered causes of stenting failure [88]. However, stents can worsen esophagitis by increasing reflux. The migration of stents, sialorrhea, retching, esophageal subclavian fistula, stent dislocation and perforation, soft plate injury, swallowing difficulties, chest pain, and vomiting are the reported complications [88, 91, 93]. Zhang et al. reported complete improvement in all their limited number of patients with self-expanding stents without serious complications [94]. Recently, self-expandable, biodegradable stents have become available and usable for the treatment of esophageal strictures. Stent integ-

rity and a radial force that continues for 6–8 weeks are seen as the advantages of the approach [87]. However, there have been no controlled trials yet on these stents.

5.2.2.3. Topical mitomycin C and steroid treatment

These options are based on their antifibroblastic properties, with a preventive effect on collagen synthesis and chronic scarring [42, 95–97]. El-Asmar et al. performed a double-blinded, randomized, placebo-controlled trial on the effects of topical mitomycin C application in patients with caustic esophageal strictures [98]. They found that topical mitomycin C application statistically significantly reduced the number of dilatation sessions. Mitomycin C is usually recommended at a dose of 0.4 mg/ml, which is applied with cotton or a pledget via a rigid endoscope [98, 99]. Additionally, submucosal application of triamcinolone acetonide, a member of the steroid family, has been used in patients with refractory caustic strictures. It can be applied together with endoscopic dilation [42, 97]. In the treatment approach, 2 ml (40 mg/ml) of triamcinolone acetonide is injected into quadrant 3 or 4 of the esophageal stricture at intervals of 2 or 3 weeks until full recovery [42].

5.2.2.4. Surgery

It is well established that the child's own esophagus is the ideal option and the esophagus should be preserved without any replacement for native esophagus [100–103]. The ideal organ to be used for replacement is expected to deliver food efficiently from the mouth to the intestinal system, to be resistant to stomach acid, grow parallel to the child, preserving cardiac and respiratory functions [101, 102]. The indication of esophageal replacement in patients with caustic stricture is failure of normal swallowing [100] (**Figure 11a and b**). Although multiple strictures, longer than 5-cm stricture and tortuous strictures, which do not allow to passage of the guidewire are the contraindications of esophageal dilatation, it is still controversial

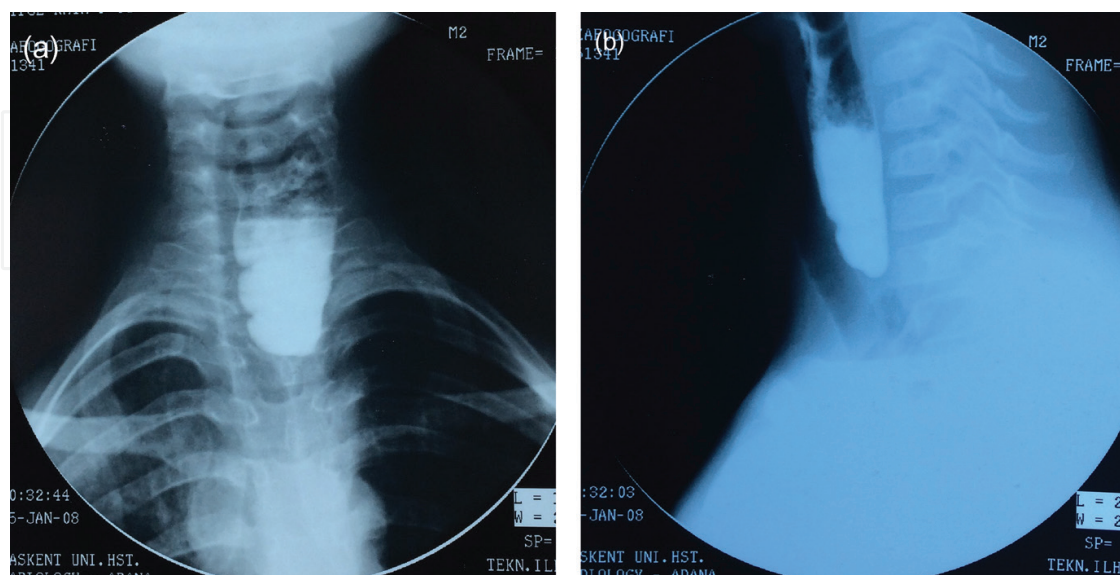


Figure 11. Complete obstruction of the cervical esophagus prevents oral feeding. Posterior-anterior (a) and lateral (b) frame of obstruction.

[38, 100]. Psychological problems may also occur secondary to prolonged dilatation, which required repeated anesthesia are other indications for esophageal replacement [100]. Spitz reported that necessity of regular dilatation for 6–12 months following the ingestion constituted an indication for esophageal replacement in caustic esophageal injury [104]. Gundoğdu et al. suggested that difficulty to swallow saliva, total or nearly total obliteration of the lumen involving more than 3 cm of an esophagus at admittance, difficulty in swallowing within one-month period following the recent dilation after completion of one-year dilation program were the main indications of esophageal replacement [105]. Social and psychological problems due to the lack of normal feeding or swallow, interrupted schooling and domestic family problems secondary to prolonged and multiple hospital admissions may be also considered other reasons of esophageal substations [102].

Surgical techniques include resection and end-to-end anastomosis, colonic or jejunal interposition, reversed gastric tube, or gastric transposition have been described for esophageal replacement in patients with resistant strictures [100, 104, 106]. Although the colon is the most commonly used intestinal component, progressively increased gastric transposition has been reported in recent years. Colonic interposition can be performed in the posterior mediastinum with transhiatal esophagectomy. It can be also done retrosternally by leaving the native esophagus.

Various segments of the colon can be used depending on the discretion of the surgeon [107, 108]. Ergün et al. used the left colon in 75% of their patients, while Bothereau et al. performed right colonic interposition in 87% of their patients [107, 108]. However, the latter authors reported no statistically significant difference in the complication rates [108]. Complications of colonic transposition are also frequently seen. Hamza et al. reported 1% mortality due to postoperative respiratory problems or sepsis [100]. Bothereau et al. reported 4% mortality secondary to complications [108]. Complications are classified under three main titles as early, late, and long-term complications. Early complications are defined as those occurred within the first month of surgery, while late complications are those occurred between 1 month and 1 year after surgery. Complications are described as long-term, while occurring more than 1 year after operation [109]. Complications of colonic interposition are summarized in **Table 2** [100, 107–112]. Cervical anastomotic leakage, adhesive intestinal obstructions, colo-esophageal stricture, redundancy, gastrocolic reflux, and graft necrosis are the most common complications (**Figures 12 and 13a and b**). Furthermore, several suggestions have been made to reduce the rate of complications. Ergün et al. reported that the incidence of cervical anastomotic stricture was significantly lower by two-stage procedure. Bothereau et al. showed the upper thoracic inlet enlargement by resection of manubrium and tip of left clavicle to reduce the rate of complications in colonic interposition [108]. Also, Chirica et al. reported that the absence of thoracic inlet enlargement, delayed reconstruction were associated with an increased risk of early and late complications in adults [113].

Gastric transposition is another choice of surgical treatment. The method popularized by Spitz et al. which is the largest-scale study, has been increasingly utilized in recent years [103]. It is based on the good blood supply of the stomach. The right gastric and gastroepiploic vessels are preserved, and the left gastric and left gastroepiploic vessels are ligated. After the stomach is fully mobilized and passed transhiatal, posterior mediastinally, fundus

Intraoperative complication	Pneumothorax
	Tracheal injury
	Major bleeding
	Recurrent laryngeal injury
Early complications	Death
	Graft necrosis
	Respiratory failure
	Gastrocolic reflux
	Sepsis
	Fistula
	Cervical anastomotic stricture
	Cologastric anastomosis stricture
	Dehiscence of colocolic anastomosis
	Dehiscence of cologastric anastomosis
	Dumping syndrome
	Intussusception
	Enterocutaneous fistula
	Biliary reflux
Late complications	Anastomotic stricture
	Reflux
	Redundancy
	Ulceration
	Graft hernia into the pleura
	Intestinal obstruction
	Aspiration pneumonia
	Incisional hernia
	Postprandial neck bulge
Long-term complication	Relux
	Dysphagia
	Pain
	Nocturnal regurgitation
	Redundancy
	Anastomotic stricture
	Ulceration
	Scoliosis
	Malnutrition

Table 2. Complications of colonic interposition [100, 107–112].

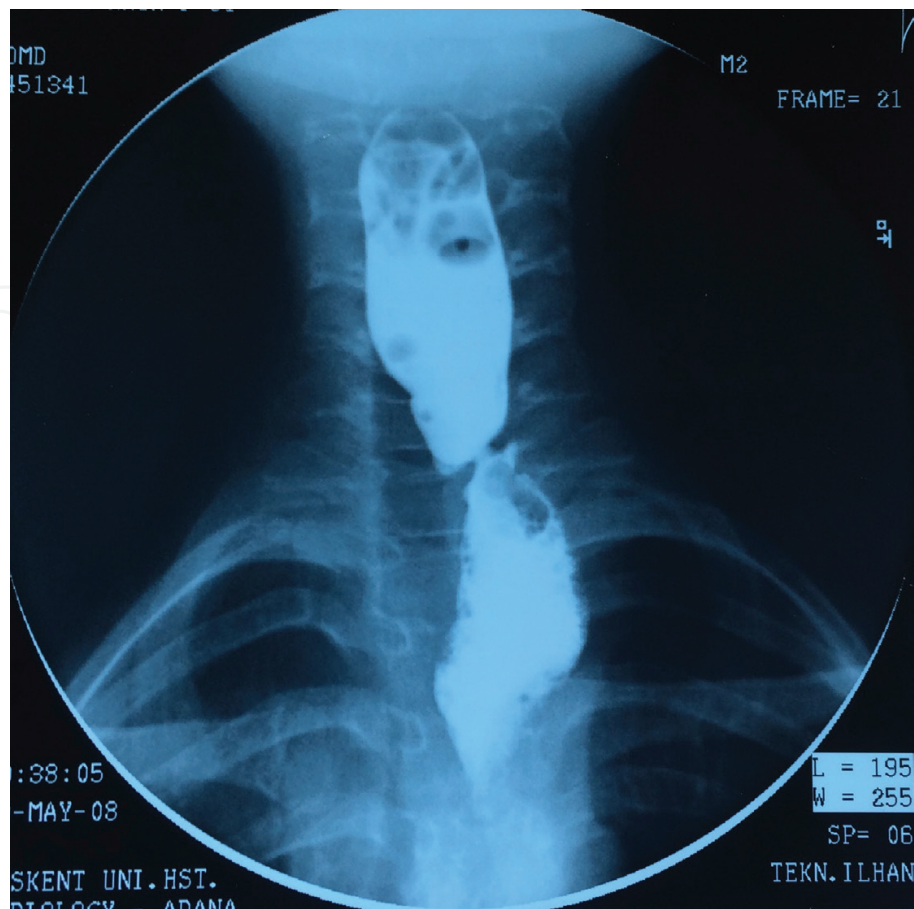

Figure 12. Coloesophageal stricture in a 14 years old girl underwent colonic interposition.

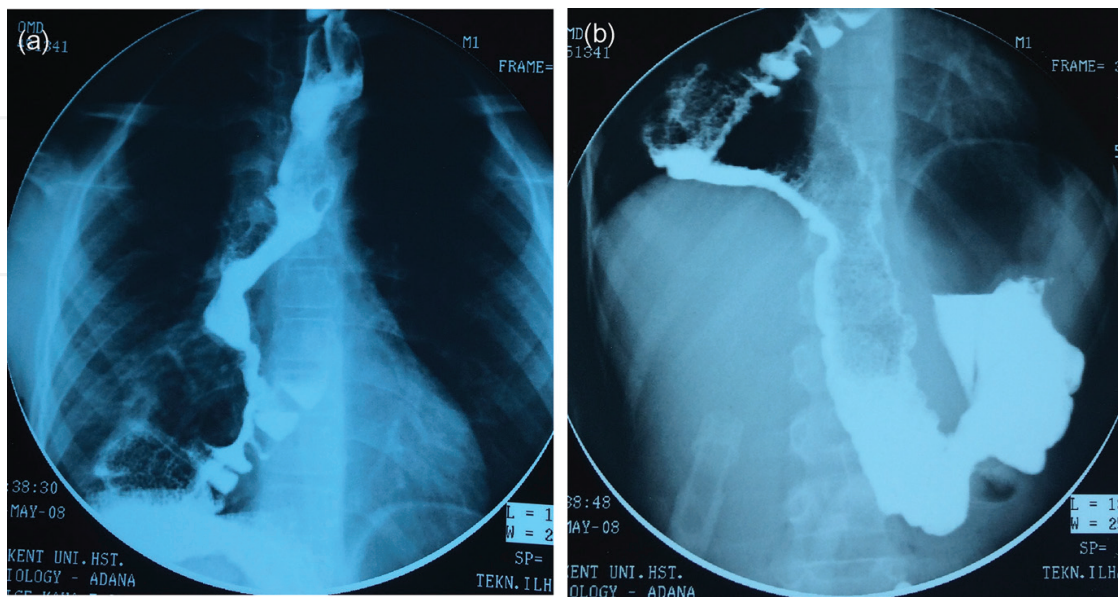


Figure 13. Colonic redundancy after coloesophagoplasty. Thoracic (a) and abdominal (b) appearance.

is pulled up from the cervical incision. Anastomosis between the stomach and esophagus is performed between the gastric fundus, which is easily mobilized and has a good blood supply and the cervical esophagus. Pyloroplasty or pyloromyotomy is carried out with the aim of facilitating gastric emptying [101, 102, 104]. Gastric transposition can usually be performed without thoracotomy. Spitz et al. performed thoracotomy in selected patients, due to dense fibrous tissues [114]. The most common complications of total gastric transposition up are the anastomotic leakage, stenosis, swallowing disorders, delayed gastric emptying, and mortality [101, 103, 114, 115]. Anastomotic leakage usually resolves spontaneously, while it requires surgical correction in a few cases [114, 115]. Stenosis usually improves with a number of dilatation sessions [114, 115]. Spitz reported that 94% of patients with swallowing difficulties experienced major swallowing problems before the gastric transposition. Severe gastric emptying problem may require converting to the pyloroplasty or Roux-en-Y gastrojejunostomy [103]. Spitz found the result of gastric transpositions to be good to excellent in terms of absence of swallowing difficulties or other gastrointestinal symptoms in 90% of their patients [114]. In another study, Marujo reported excellent and good results in 85 and 15% of patients, respectively [115]. In addition, Angotti et al. reported that all patients had gain weight and height postoperatively [101]. Davenport et al. also reported the long-term results of gastric transposition and showed that gastric transposition allowed satisfactory growth and nutrition for the majority of children [116]. The authors also observed respiratory symptoms in a number of patients and suggested that respiratory symptoms were related to small lung volume, rather than an increased airway resistance. In another study, Tannuri et al. compared esophagocoloplasty and gastric transposition in terms of early complications and mortality [117]. The authors reported that minor complications were statistically significantly higher in colonic transposition, while the rate of major complications was statistically significantly higher in gastric transposition. However, they found no significant difference in the mortality rates between the groups. Hence, they recommended esophagocoloplasty based on their experiences.

5.2.3. Gastric outlet obstruction

Gastric injury is less encountered than esophageal injury in caustic ingestion. Gastric outlet obstruction may develop as early as 3 weeks or as late as 10 weeks [118]. Endoscopy is recommended to diagnose the gastric injury and to tailor the treatment modality. There are two different approaches including minimal invasive technique, endoscopic balloon dilatation of the obstruction, and surgical intervention to resolve the obstructions [43, 45, 119, 120].

5.2.3.1. Endoscopic dilatation

On the other hand, there is limited experience on endoscopic treatment of gastric outlet obstruction secondary to the caustic ingestion in children. Treem et al. reported successful treatment outcomes of pyloric obstruction secondary to caustic ingestion with endoscopy-guided balloon dilatation before three decades. Nasr et al. also reported two patients who underwent endoscopic dilatation; one of them improved only with dilatation. Dehghani et al. reported a patient with pyloric stenosis treated with balloon dilatation [118]. The authors achieved normal pyloric

canal after four dilatation sessions. In another study, Temiz et al. attempted endoscopic dilatation in seven patients with corrosive stricture, and performed successful dilatation in five of them [119]. However, symptoms of pyloric obstruction recurred in three patients. Due to the inability to pass the guidewire through the pylorus, they were unable to reperform dilatation. Despite low successful rates, the authors recommended endoscopic balloon dilatation before a surgical intervention.

5.2.3.2. Technique of balloon dilatation

Endoscopy is performed under general anesthesia. After focusing on the pylorus, a radiopaque guidewire is inserted through the pylorus under the guidance of endoscopy. A balloon catheter is passed over the guidewire and through the pylorus. The location of the balloon is monitored endoscopically. Then, the balloon is inflated with a radiopaque solution under fluoroscopic guidance. Inflation is performed for at least 2 minutes after the expansion of hourglass deformity of the obstruction [119] (**Figure 14a–c**).

5.2.3.3. Surgical options

To date, several surgical techniques including Heicke-Mikulicz pyloroplasty, Finney pyloroplasty, Jabulay pyloroplasty, gastrojejunostomy, and Billroth-I procedure have been described for the treatment of acquired gastric outlet obstructions [12, 119, 120]. The preference may vary depending on the discretion of the surgeon. Ozcan et al. performed retrocolic gastrojejunostomy in all patients, while Ozokutan et al. performed gastroduodenostomy and Billroth-I procedure [45, 120]. However, the timing of surgery is of utmost importance for the method to be selected. Surgical intervention is recommended at the end of cicatrization period of caustic injury [44, 119, 121]. Due to anastomotic stricture, secondary to the progressive inflammatory process may develop in early operated patients. Temiz et al. reported anastomotic stricture in a case that underwent gastrojejunostomy after 6 weeks of injury. Endoscopic dilatation may help to solve this problem [119] (**Figure 15a and b**). Dumping syndrome is another postoperative clinical condition. Ozcan suggested an anastomosis not exceeding 2 cm to prevent postoperative dumping syndrome [45].

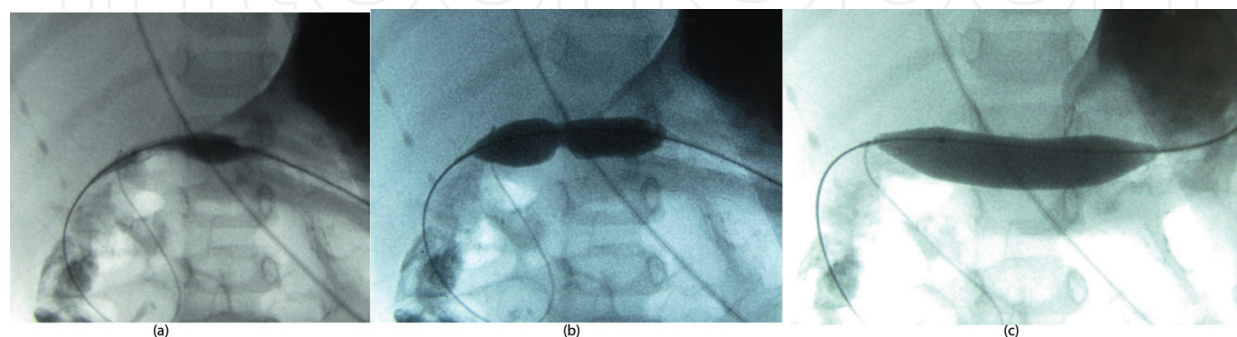


Figure 14. (a)–(c) After placement of guide wire under endoscopic guidance through the pyloric stenosis, a balloon catheter is passed over the guidewire and inflated with radiocontrast solution until a flattening of the hourglass deformity.

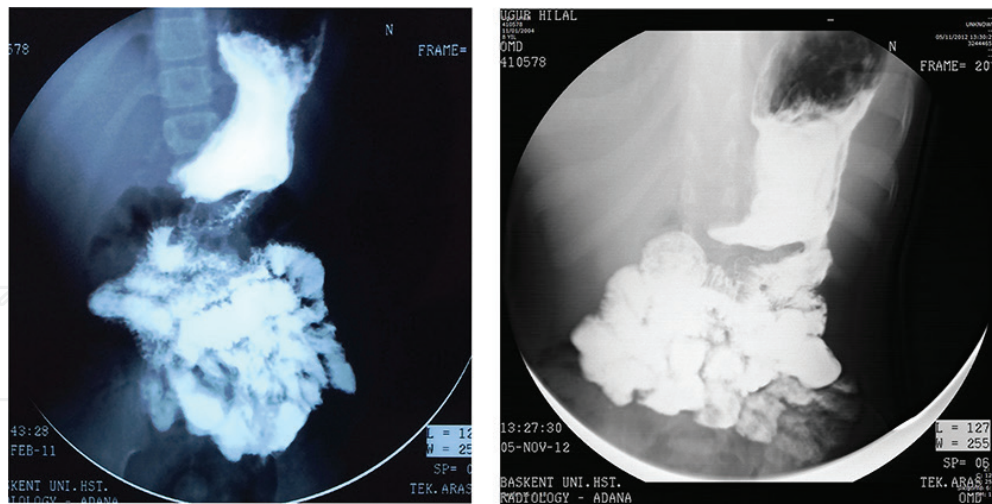


Figure 15. Anastomotic stricture was revealed by gastroscopy (a), after balloon dilatation easy flow from gastrojejunostomy is seen (b).

5.2.4. Gastroesophageal reflux

Caustic esophageal injury results with narrowed and also shortened esophagus [122]. This process alters the lower esophageal sphincter function, which leads to gastroesophageal reflux. As a consequence, reflux can adversely affect the development of stenosis and response to treatment of the stenosis. Mutaf et al. recommended that patients with caustic esophageal burn should be screened for gastroesophageal reflux during the treatment period [122]. The most preferred surgical procedures for gastroesophageal reflux disease include the Nissen, Thal, and BoixOchoa procedures. However, all these procedures have a significant recurrence rate in the patients, particularly with a shortened esophagus. In addition, Collis gastroplasty with partial or complete fundoplication can be used as alternative surgical techniques in the treatment of a shortened esophagus (**Figure 16a and b**).

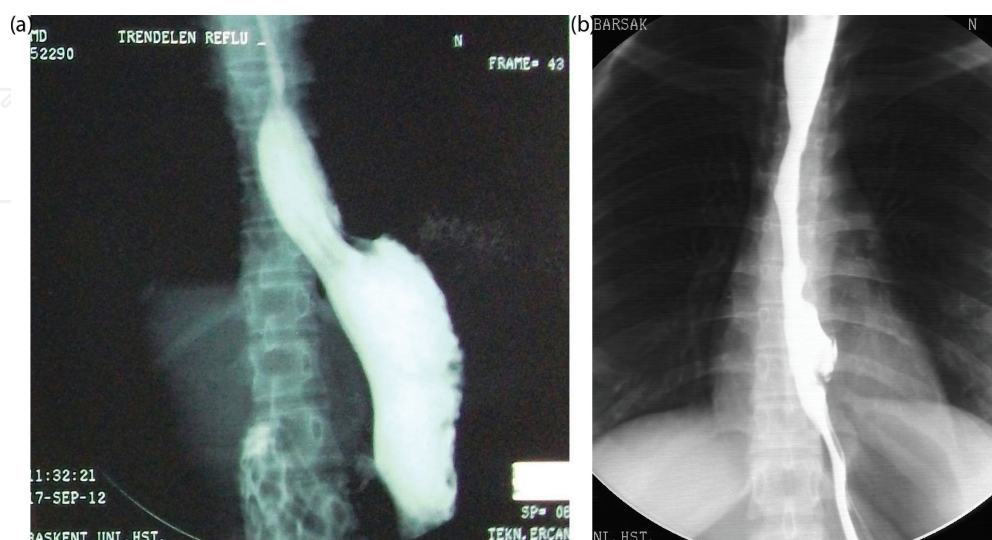


Figure 16. The sliding type of hiatal hernia (a) was ameliorated with Collis gastroplasty (b).

Author details

Abdulkerim Temiz

Address all correspondence to: aktemiz@yahoo.com

Başkent University, Faculty of Medicine, Department of Pediatric Surgery, Turkey

References

- [1] Johnson CM, Brigger MT: The public health impact of pediatric caustic ingestion injuries. *Arch Otolaryngol Head Neck Surg.* 2012;138:1111–5. doi: 10.1001/jamaoto.2013.672.
- [2] de Jong AL, Macdonald R, Ein S, Forte V, Turner A: Corrosive esophagitis in children: a 30-year review. *Int J Pediatr Otorhinolaryngol.* 2001;57:203–11.
- [3] Arévalo-Silva C, Eliashar R, Wohlgeleirnter J, Elidan J, Gross M: Ingestion of caustic substances: a 15-year experience. *Laryngoscope.* 2006;116:1422–6.
- [4] Urgancı N, Usta M, Kalyoncu D, Demirel E: Corrosive substance ingestion in children. *Indian J Pediatr.* 2014;81:675–9. doi: 10.1007/s12098-013-1170-0.
- [5] Temiz A, Oguzkurt P, Ezer SS, Ince E, Hicsonmez A: Predictability of outcome of caustic ingestion by esophagogastroduodenoscopy in children. *World J Gastroenterol.* 2012;18:1098–103. doi: 10.3748/wjg.v18.i10.1098.
- [6] Lupa M, Magne J, Guarisco JL, Amedee R: Update on the diagnosis and treatment of caustic ingestion. *Ochsner J.* 2009;9:54–9.
- [7] Somuncu S, Cakmak M, Erdogan S, Caglayan O, Akman H, Kaya M: Trapidil, an inhibitor for phosphodiesterase and platelet-derived-growth factor, ameliorates corrosive esophageal burn in rats. *Tohoku J Exp Med.* 2005;207:203–8.
- [8] Ozel SK, Dagli TE, Yuksel M, Kiyan G, Kotiloglu E: The roles of free oxygen radicals, nitric oxide, and endothelin in caustic injury of rat esophagus. *J Pediatr Surg.* 2004;39:1381–5.
- [9] Temiz A, Ünal B, Koçer NE, Oğuzkurt P, Ezer SS, İnce E, Yalçın HS, Hiçsönmez A: Late complications of corrosive esophagitis may be predicted using biochemical methods: preliminary report. *Türkiye Klinikleri J Med Sci.* 2012;32:193–200. doi:10.5336/medsci.2011-25229.
- [10] Contini S, Scarpignato C: Caustic injury of the upper gastrointestinal tract: a comprehensive review. *World J Gastroenterol.* 2013;19:3918–30. doi:10.3748/wjg.v19.i25.3918.
- [11] Mattos GM, Lopes DD, Mamede RC, Ricz H, Mello-Filho FV, Neto JB: Effects of time of contact and concentration of caustic agent on generation of injuries. *Laryngoscope.* 2006;116:456–60.

- [12] Ciftci AO, Senocak ME, Büyükpamukçu N, Hiçsönmez A: Gastric outlet obstruction due to corrosive ingestion: incidence and outcome. *Pediatr Surg Int.* 1999;15:88–91.
- [13] Gaudreault P, Parent M, McGuigan MA, Chicoine L, Lovejoy FH: Predictability of esophageal injury from signs and symptoms: a study of caustic ingestion in 378 children. *Pediatrics.* 1983;71: 767–70.
- [14] Lamireau T, Rebouissoux L, Denis D, Lancelin F, Vergnes P, Fayon M: Accidental caustic ingestion in children: is endoscopy always mandatory? *J Pediatr Gastroenterol Nutr.* 2001;33:81–4.
- [15] Boskovic A, Stankovic I: Predictability of gastroesophageal caustic injury from clinical findings: is endoscopy mandatory in children? *Eur J Gastroenterol Hepatol.* 2014;26:499–503. doi: 10.1097/MEG.000000000000060.
- [16] Nijhawan S, Jain P: Acute pancreatitis as an unusual complication of corrosive ingestion. *J Gastrointest Liver Dis.* 2007;16:345–6.
- [17] Gupta V, Kurdia KC, Sharma A, Mishra AK, Yadav TD, Kochhar R: Tracheoesophageal fistula in adults due to corrosive ingestion: challenges in management. *Updates Surg.* 2015;67:75–81. doi: 10.1007/s13304-015-0292-5.
- [18] Samad L, Ali M, Ramzi H: Button battery ingestion: hazards of esophageal impaction. *J Pediatr Surg.* 1999;34:1527–31.
- [19] Marom T, Goldfarb A, Russo E, Roth Y: Battery ingestion in children. *Int J Pediatr Otorhinolaryngol.* 2010;74:849–54. doi: 10.1016/j.ijporl.2010.05.019.
- [20] Votteler TP, Nash JC, Rutledge JC: The hazard of ingested alkaline disk batteries in children. *JAMA.* 1983;249:2504–6.
- [21] Litovitz T, Schmitz BF: Ingestion of cylindrical and button batteries: an analysis of 2382 cases. *Pediatrics.* 1992;89:747–57.
- [22] Bass DH, Millar AJ: Mercury absorption following button battery ingestion. *J Pediatr Surg.* 1992;27:1541–2.
- [23] Hamilton JM, Schraff SA, Notrica DM: Severe injuries from coin cell battery ingestions: 2 case reports. *J Pediatr Surg.* 2009;44:644–7. doi: 10.1016/j.jpedsurg.2008.10.110.
- [24] Loots DP, du Toit-Prinsloo L, Saayman G: Disk battery ingestion: a rare cause of perforation of the brachiocephalic artery. *Forensic Sci Med Pathol.* 2015;11:614–7. doi: 10.1007/s12024-015-9706-4.
- [25] Stiff G, Alwafi A, Rees BI, Lari J: Corrosive injuries of the oesophagus and stomach: experience in management at a regional paediatric centre. *Ann R Coll Surg Engl.* 1996;78:119–23.
- [26] Di Costanzo J, Noirclerc M, Jouglaard J, Escoffier JM, Cano N, Martin J, Gauthier A: New therapeutic approach to corrosive burns of the upper gastrointestinal tract. *Gut.* 1980;21:370–75.

- [27] Zargar SA, Kochhar R, Mehta S, Mehta SK: The role of fiberoptic endoscopy in the management of corrosive ingestion and modified endoscopic classification of burns. *Gastrointest Endosc.* 1991;37:165–9.
- [28] Poley JW, Steyerberg EW, Kuipers EJ, Dees J, Hartmans R, Tilanus HW, Siersema PD: Ingestion of acid and alkaline agents: outcome and prognostic value of early upper endoscopy. *Gastrointest Endosc.* 2004;60:372–7.
- [29] Baskin D, Urganci N, Abbasoğlu L, Alkim C, Yalçın M, Karadağ C, Sever N: A standardised protocol for the acute management of corrosive ingestion in children. *Pediatr Surg Int.* 2004;20:824–8.
- [30] Ryu HH, Jeung KW, Lee BK, Uhm JH, Park YH, Shin MH, Kim HL, Heo T, Min YI: Caustic injury: can CT grading system enable prediction of esophageal stricture? *Clin Toxicol (Phila).* 2010;48:137–42. doi: 10.3109/15563650903585929.
- [31] Keh SM, Onyekwelu N, McManus K, McGuigan J: Corrosive injury to upper gastrointestinal tract: still a major surgical dilemma. *World J Gastroenterol.* 2006;12:5223–8.
- [32] Kua K, Jonas N, O'Donnell R: The larynx and caustic soda ingestion. *Arch Dis Child.* 2015;100:570. doi: 10.1136/archdischild-2014-307588.
- [33] Shabino CL, Feinberg A: Esophageal perforation secondary to alkaline battery ingestion. *JACEP.* 1979;8:360–3.
- [34] Chiang MC, Chen YS: Tracheoesophageal fistula secondary to disc battery ingestion. *Am J Otolaryngol.* 2000;21:333–6.
- [35] Anand TS, Kumar S, Wadhwa V, Dhawan R: Rare case of spontaneous closure of tracheoesophageal fistula secondary to disc battery ingestion. *Int J Pediatr Otorhinolaryngol.* 2002;63:57–9.
- [36] Grisel JJ, Richter GT, Casper KA, Thompson DM: Acquired tracheoesophageal fistula following disc-battery ingestion: can we watch and wait? *Int J Pediatr Otorhinolaryngol.* 2008;72:699–706. doi: 10.1016/j.ijporl.2008.01.015.
- [37] Okuyama H, Kubota A, Oue T, Kuroda S, Nara K, Takahashi T: Primary repair of tracheoesophageal fistula secondary to disc battery ingestion: a case report. *J Pediatr Surg.* 2004;39:243–4.
- [38] Temiz A, Oguzkurt P, Ezer SS, Ince E, Hicsonmez A: Long-term management of corrosive esophageal stricture with balloon dilation in children. *Surg Endosc.* 2010;24:2287–92. doi: 10.1007/s00464-010-0953-x.
- [39] Kim JH, Song HY, Kim HC, Shin JH, Kim KR, Park SW, Jung HY, Lee GH, Park SI: Corrosive esophageal strictures: Long-term effectiveness of balloon dilation in 117 patients. *J Vasc Interv Radiol.* 2008;19:736–41.
- [40] Huang YC, Ni YH, Lai HS, Chang MH: Corrosive esophagitis in children: *Pediatr Surg Int.* 2004;20:207–10.

- [41] Broto J, Asensio M, Jorro CS, Marhuenda C, Vernet JM, Acosta D, Ochoa JB: Conservative treatment of caustic esophageal injuries in children: 20 years of experience. *Pediatr Surg Int.* 1999;15:323–5.
- [42] Bicakci U, Tander B, Deveci G, Rizalar R, Ariturk E, Bernay F: Minimally invasive management of children with caustic ingestion: less pain for patients. *Pediatr Surg Int.* 2010;26:251–5. doi: 10.1007/s00383-009-2525-5.
- [43] Tekant G, Eroğlu E, Erdoğan E, Yeşildağ E, Emir H, Büyükcinal C, Yeker D: Corrosive injury-induced gastric outlet obstruction: a changing spectrum of agents and treatment. *J Pediatr Surg.* 2001;36:1004–7.
- [44] Kaushik R, Singh R, Sharma R, Attri AK, Bawa AS: Corrosive-induced gastric outlet obstruction. *Yonsei Med J.* 2003;44:991–4.
- [45] Ozcan C, Ergün O, Sen T, Mutaf O: Gastric outlet obstruction secondary to acid ingestion in children. *J Pediatr Surg.* 2004;39:1651–3.
- [46] Appelqvist P, Salmo M: Lye corrosion carcinoma of the esophagus: a review of 63 cases. *Cancer.* 1980;45:2655–8.
- [47] Kozarek RA, Sanowski RA: Caustic cicatrization of the pharynx associated with dysphagia and premalignant mucosal changes. *Am J Gastroenterol.* 1982;77:5–8.
- [48] Zhang X, Wang M, Han H, Xu Y, Shi Z, Ma G: Corrosive induced carcinoma of esophagus after 58 years. *Ann Thorac Surg.* 2012;94:2103–5. doi: 10.1016/j.athoracsur.2012.03.110.
- [49] Kochhar R, Sethy PK, Kochhar S, Nagi B, Gupta NM: Corrosive induced carcinoma of esophagus: report of three patients and review of literature. *J Gastroenterol Hepatol.* 2006;21:777–80. doi: 10.1111/j.1440-1746.2006.03211.x.
- [50] Rigo GP, Camellini L, Azzolini F, Guazzetti S, Bedogni G, Merighi A, Bellis L, Scarcelli A, Manenti F: What is the utility of selected clinical and endoscopic parameters in predicting the risk of death after caustic ingestion? *Endoscopy.* 2002;34:304–10.
- [51] Cheng YJ, Kao EL: Arterial blood gas analysis in acute caustic ingestion injuries. *Surg Today.* 2003;33:483–5.
- [52] Thompson JN: Corrosive esophageal injuries. I. A study of nine cases of concurrent accidental caustic ingestion. *Laryngoscope.* 1987;97:1060–8.
- [53] Doğan Y, Erkan T, Cokuğraş FC, Kutlu T: Caustic gastroesophageal lesions in childhood: an analysis of 473 cases. *Clin Pediatr (Phila).* 2006;45:435–8.
- [54] Tiryaki T, Livanelioğlu Z, Atayurt H: Early bougienage for relief of stricture formation following caustic esophageal burns. *Pediatr Surg Int.* 2005;21:78–80.
- [55] Iqbal CW, Askegard-Giesmann JR, Pham TH, Ishitani MB, Moir CR: Pediatric endoscopic injuries: incidence, management, and outcomes. *J Pediatr Surg.* 2008;43:911–5. doi: 10.1016/j.jpedsurg.2007.12.036.

- [56] Gupta SK, Croffie JM, Fitzgerald JF: Is esophagogastroduodenoscopy necessary in all caustic ingestions? *J Pediatr Gastroenterol Nutr.* 2001;32:50–3.
- [57] Millar AJ, Numanoglu A, Mann M, Marven S, Rode H: Detection of caustic oesophageal injury with technetium 99m-labelled sucalfate. *J Pediatr Surg.* 2001;36:262–5.
- [58] Çiftçi ÖD, Gül SS, Açıkşarı K, Maman A, Çavuşoğlu T, Bademci R, Taskiran D, Erbaş O: The diagnostic utility of scintigraphy in esophageal burn: a rat model. *J Surg Res.* 2016;200:495–500. doi: 10.1016/j.jss.2015.09.006.
- [59] Aksu B, Durmus-Altun G, Ustun F, Torun N, Kanter M, Umit H, Sut N: A new imaging modality in detection of caustic oesophageal injury: technetium-99m pyrophosphate scintigraphy. *Int J Pediatr Otorhinolaryngol.* 2009;73:409–15. doi:10.1016/j.ijporl.2008.11.008.
- [60] Maurer AH, Parkman HP: Update on gastrointestinal scintigraphy. *Semin Nucl Med.* 2006;36:110–8.
- [61] Warrington JC, Charron M: Pediatric gastrointestinal nuclear medicine. *Semin Nucl Med.* 2007;37:269–85.
- [62] Kochhar R, Mittal BR, Kumar S, Bhattacharya A, Sethy PK, Dutta U: Segmental and total oesophageal transit time in patients with corrosive-induced oesophageal stricture. *Nucl Med Commun.* 2007;28:920–3.
- [63] Kamijo Y, Kondo I, Soma K, Imaizumi H, Ohwada T: Alkaline esophagitis evaluated by endoscopic ultrasound. *J Toxicol Clin Toxicol.* 2001;39:623–5.
- [64] Kamijo Y, Kondo I, Kokuto M, Kataoka Y, Soma K: Miniprobe ultrasonography for determining prognosis in corrosive esophagitis. *Am J Gastroenterol.* 2004;99:851–4.
- [65] Kamijo Y, Kondo I, Watanabe M, Kan'o T, Ide A, Soma K: Gastric stenosis in severe corrosive gastritis: prognostic evaluation by endoscopic ultrasonography. *Clin Toxicol (Phila).* 2007;45:284–6.
- [66] Chiu HM, Lin JT, Huang SP, Chen CH, Yang CS, Wang HP: Prediction of bleeding and stricture formation after corrosive ingestion by EUS concurrent with upper endoscopy. *Gastrointest Endosc.* 2004;60:827–33.
- [67] Pelclová D, Navrátil T: Do corticosteroids prevent oesophageal stricture after corrosive ingestion? *Toxicol Rev.* 2005;24:125–9.
- [68] Fulton JA, Hoffman RS: Steroids in second degree caustic burns of the esophagus: a systematic pooled analysis of fifty years of human data: 1956–2006. *Clin Toxicol (Phila).* 2007;45:402–8.
- [69] Anderson KD, Rouse TM, Randolph JG: A controlled trial of corticosteroids in children with corrosive injury of the esophagus. *N Engl J Med.* 1990;323:637–40.
- [70] Mamede RC, De Mello Filho FV: Treatment of caustic ingestion: an analysis of 239 cases. *Dis Esophagus.* 2002;15:210–3.

- [71] Bautista A, Varela R, Villanueva A, Estevez E, Tojo R, Cadranel S: Effects of prednisolone and dexamethasone in children with alkali burns of the oesophagus. *Eur J Pediatr Surg.* 1996;6:198–203.
- [72] Usta M, Erkan T, Cokugras FC, Urganci N, Onal Z, Gulcan M, Kutlu T: High doses of methylprednisolone in the management of caustic esophageal burns. *Pediatrics.* 2014;133:E1518–24.
- [73] Boukthir S, Fetni I, Mrad SM, Mongalgi MA, Debbabi A, Barsaoui S: High doses of steroids in the management of caustic esophageal burns in children. *Arch Pediatr.* 2004;11:13–7.
- [74] Andreoni B, Farina ML, Biffi R, Crosta C: Esophageal perforation and caustic injury: emergency management of caustic ingestion. *Dis Esophagus.* 1997;10:95–100.
- [75] Cattani P, Munoz-Bongrand N, Berney T, Halimi B, Sarfati E, Celerier M: Extensive abdominal surgery after caustic ingestion. *Ann Surg.* 2000;231:519–23.
- [76] Gün F, Abbasoğlu L, Celik A: Acute gastric perforation after acid ingestion. *J Pediatr Gastroenterol Nutr.* 2002;35:360–2.
- [77] Ceylan H, Ozokutan BH, Gündüz F, Gözen A: Gastric perforation after corrosive ingestion. *Pediatr Surg Int.* 2011;27:649–53. doi:10.1007/s00383-010-2739-6.
- [78] Boybeyi O, Karnak I, Tanyel FC, Senocak ME: Management of unusually extensive esophagogastric corrosive injuries: emergency measures and gastric reconstruction. *J Pediatr Surg.* 2009;44:1022–6. doi:10.1016/j.jpedsurg.2009.02.001.
- [79] Uygun I, Arslan MS, Aydogdu B, Okur MH, Otcu S: Fluoroscopic balloon dilatation for caustic esophageal stricture in children: an 8-year experience. *J Pediatr Surg.* 2013;48:2230–4. doi:10.1016/j.jpedsurg.2013.04.005.
- [80] Lan LC, Wong KK, Lin SC, Sprigg A, Clarke S, Johnson PR, Tam PK: Endoscopic balloon dilatation of esophageal strictures in infants and children: 17 years' experience and a literature review. *J Pediatr Surg.* 2003;38:1712–5.
- [81] Pyrtle J, Obando J: Endoscopic management of difficult benign esophageal stricture. *Tech Gastrointest Endosc.* 2007;9:74–83.
- [82] Poddar U, Thapa BR: Benign esophageal strictures in infants and children: results of Savary-Gilliard bougie dilation in 107 Indian children. *Gastrointest Endosc.* 2001;54:480–4.
- [83] Kukkady A, Pease PW: Long-term dilatation of caustic strictures of the oesophagus. *Pediatr Surg Int.* 2002;18:486–90.
- [84] Doo E-Y, Shin JH, Kim JH, Song H-Y: Oesophageal strictures caused by the ingestion of corrosive agents: effectiveness of balloon dilation in children. *Clin Radiol.* 2009; 64:265–71.
- [85] Gündoğdu HZ, Tanyel FC, Büyükpamukçu N, Hiçsönmez A: Conservative treatment of caustic esophageal strictures in children. *J Pediatr Surg.* 1992;27:767–70.

- [86] Alshammari J, Quesnel S, Pierrot S, Couloigner V: Endoscopic balloon dilatation of esophageal strictures in children. *Int J Pediatr Otorhinolaryngol.* 2011;75:1376–9. doi:10.1016/j.ijporl.2011.07.031.
- [87] Vandenplas Y, Hauser B, Devreker T, Urbain D, Reynaert H: A biodegradable esophageal stent in the treatment of a corrosive esophageal stenosis in a child. *J Pediatr Gastroenterol Nutr.* 2009;49:254–7. doi: 10.1097/MPG.0b013e31819de871.
- [88] Mutaf O: Treatment of corrosive esophageal strictures by long-term stenting. *J Pediatr Surg.* 1996;31:681–5.
- [89] Chang CF, Kuo SP, Lin HC, Chuang CC, Tsai TK, Wu SF, Chen AC, Chen W, Peng CT: Endoscopic balloon dilatation for esophageal strictures in children younger than 6 years: experience in a medical center. *Pediatr Neonatol.* 2011;52:196–202. doi: 10.1016/j.pedneo.2011.05.005.
- [90] Tam PKH, Sprigg A, Cudmore RE, Cook RC, Carty H: Endoscopy-guided balloon dilatation of esophageal strictures and anastomotic strictures after esophageal replacement in children. *J Pediatr Surg.* 1991;26:1101–3.
- [91] Atabek C, Surer I, Demirbag S, Caliskan B, Ozturk H, Cetinkursun S: Increasing tendency in caustic esophageal burns and long-term polytetrafluorethylene stenting in severe cases: 10 years' experience. *J Pediatr Surg.* 2007;42:636–40.
- [92] Foschia F, De Angelis P, Torroni F, Romeo E, Caldaro T, di Abriola GF, Pane A, Fiorenza MS, De Peppo F, Dall'Oglio L: Custom dynamic stent for esophageal strictures in children. *J Pediatr Surg.* 2011;46:848–53. doi: 10.1016/j.jpedsurg.2011.02.014.
- [93] Zhang C, Zhou X, Yu L, Ding J, Shi R: Endoscopic therapy in the treatment of caustic esophageal stricture: a retrospective case series study. *Dig Endosc.* 2013;25:490–5. doi:10.1111/den.12023.
- [94] Zhang C, Yu JM, Fan GP, Shi CR, Yu SY, Wang HP, Ge L, Zhong WX: The use of a retrievable self-expanding stent in treating childhood benign esophageal strictures. *J Pediatr Surg.* 2005;40:501–4.
- [95] Heran MK, Baird R, Blair GK, Skarsgard ED: Topical mitomycin-C for recalcitrant esophageal strictures: a novel endoscopic/fluoroscopic technique for safe endoluminal delivery. *J Pediatr Surg.* 2008;43:815–8. doi: 10.1016/j.jpedsurg.2007.12.017.
- [96] El-Asmar KM, Hassan MA, Abdelkader HM, Hamza AF: Topical mitomycin C can effectively alleviate dysphagia in children with long-segment caustic esophageal strictures. *Dis Esophagus.* 2015;28:422–7. doi: 10.1111/dote.12218.
- [97] Kochhar R, Ray JD, Sriram PV, Kumar S, Singh K: Intralesional steroids augment the effects of endoscopic dilation in corrosive esophageal strictures. *Gastrointest Endosc.* 1999;49:509–13.
- [98] El-Asmar KM, Hassan MA, Abdelkader HM, Hamza AF: Topical mitomycin C application is effective in management of localized caustic esophageal stricture: a double-blinded, randomized, placebo-controlled trial. *J Pediatr Surg.* 2013;48:1621–7. doi: 10.1016/j.jpedsurg.2013.04.014.

- [99] Heran MK, Pham TH, Butterworth S, Robinson A: Use of a microporous polytetrafluoroethylene catheter balloon to treat refractory esophageal stricture: a novel technique for delivery of mitomycin C. *J Pediatr Surg*. 2011;46:776–9. doi: 10.1016/j.jpedsurg.2010.11.030.
- [100] Hamza AF, Abdelhay S, Sherif H, Hasan T, Soliman H, Kabesh A, Bassiouny I, Bahnassy AF: Caustic esophageal strictures in children: 30 years' experience. *J Pediatr Surg*. 2003;38:828–33.
- [101] Angotti R, Molinaro F, Noviello C, Cobellis G, Martino A, Del Rossi C, Bianchi A, Messina M: Gastric transposition as a valid surgical option for esophageal replacement in pediatric patients: experience from three Italian medical centers. *Gastroenterol Rep (Oxf)*. 2016;pii: gow012:1–5. doi:10.1093/gastro/gow012.
- [102] Arul GS, Parikh D: Oesophageal replacement in children. *Ann R Coll Surg Engl*. 2008;90:7–12. doi: 10.1308/003588408X242222.
- [103] Spitz L, Kiely E, Pierro A: Gastric transposition in children—a 21-year experience. *J Pediatr Surg*. 2004;39:276–81; discussion 276–81.
- [104] Spitz L: Esophageal replacement: overcoming the need. *J Pediatr Surg*. 2014;49:849–52. doi: 10.1016/j.jpedsurg.2014.01.011.
- [105] Gündoğdu HZ, Tanyel FC, Büyükpamukçu N, Hiçsönmez A: Colonic replacement for the treatment of caustic esophageal strictures in children. *J Pediatr Surg*. 1992;27:771–4.
- [106] Ezemba N, Eze JC, Nwafor IA, Etukokwu KC, Orakwe OI: Colon interposition graft for corrosive esophageal stricture: midterm functional outcome. *World J Surg*. 2014;38:2352–7. doi: 10.1007/s00268-014-2574-3.
- [107] Ergün O, Celik A, Mutaf O: Two-stage coloesophagoplasty in children with caustic burns of the esophagus: hemodynamic basis of delayed cervical anastomosis—theory and fact. *J Pediatr Surg*. 2004;39:545–8.
- [108] Bothereau H, Munoz-Bongrand N, Lambert B, Montemagno S, Cattan P, Sarfati E: Esophageal reconstruction after caustic injury: is there still a place for right coloplasty? *Am J Surg*. 2007;193:660–4.
- [109] Coopman S, Michaud L, Halna-Tamine M, Bonneville M, Bourgois B, Turck D, Gottrand F: Long-term outcome of colon interposition after esophagectomy in children. *J Pediatr Gastroenterol Nutr*. 2008;47:458–62. doi: 10.1097/MPG.0b013e31815ce55c.
- [110] Boukerrouche A: Left colonic graft in esophageal reconstruction for caustic stricture: mortality and morbidity. *Dis Esophagus*. 2013;26:788–93. doi: 10.1111/j.1442-2050.2012.01383.x.
- [111] Boukerrouche A: Isoperistaltic left colic graft interposition via a retrosternal approach for esophageal reconstruction in patients with a caustic stricture: mortality, morbidity, and functional results. *Surg Today*. 2014;44:827–33. doi: 10.1007/s00595-013-0758-3.

- [112] Raffensperger JG, Luck SR, Reynolds M, Schwartz D: Intestinal bypass of the esophagus. *J Pediatr Surg.* 1996;31:38–46; discussion 46–7.
- [113] Chirica M, Veyrie N, Munoz-Bongrand N, Zohar S, Halimi B, Celerier M, Cattani P, Sarfati E: Late morbidity after colon interposition for corrosive esophageal injury: risk factors, management, and outcome. A 20-years' experience. *Ann Surg.* 2010;252:271–80. doi: 10.1097/SLA.0b013e3181e8fd40.
- [114] Spitz L: Gastric transposition in children. *Semin Pediatr Surg.* 2009;18:30–3. doi: 10.1053/j.sempedsurg.2008.10.006.
- [115] Marujo WC, Tannuri U, Maksoud JG: Total gastric transposition: an alternative to esophageal replacement in children. *J Pediatr Surg.* 1991;26:676–81.
- [116] Davenport M, Hosie GP, Tasker RC, Gordon I, Kiely EM, Spitz L: Long-term effects of gastric transposition in children: a physiological study. *J Pediatr Surg.* 1996;31:588–93.
- [117] Tannuri U, Maksoud-Filho JG, Tannuri AC, Andrade W, Maksoud JG: Which is better for esophageal substitution in children, esophagocoloplasty or gastric transposition? A 27-year experience of a single center. *J Pediatr Surg.* 2007;42:500–4.
- [118] Dehghani SM, Aldaghi M, Javaherizadeh H: Endoscopic pyloroplasty for severe gastric outlet obstruction due to alkali ingestion in a child. *Gastroenterol Hepatol Bed Bench.* 2016;9:64–7.
- [119] Temiz A, Oguzkurt P, Ezer SS, Ince E, Gezer HO, Hicsonmez A: Management of pyloric stricture in children: endoscopic balloon dilatation and surgery. *Surg Endosc.* 2012;26:1903–8. doi: 10.1007/s00464-011-2124-0.
- [120] Ozokutan BH, Ceylan H, Ertaşkin I, Yapici S: Pediatric gastric outlet obstruction following corrosive ingestion. *Pediatr Surg Int.* 2010;26:615–8. doi: 10.1007/s00383-010-2613-6.
- [121] Chaudhary A, Puri AS, Dhar P, Reddy P, Sachdev A, Lahoti D, Kumar N, Broor SL: Elective surgery for corrosive induced gastric injury. *World J Surg.* 1996;20:703–6.
- [122] Mutaf O, Genç A, Herek O, Demircan M, Ozcan C, Arikan A: Gastroesophageal reflux: a determinant in the outcome of caustic esophageal burns. *J Pediatr Surg.* 1996;31:1494–5.