

We are IntechOpen, the world's leading publisher of Open Access books Built by scientists, for scientists

6,900

Open access books available

185,000

International authors and editors

200M

Downloads

Our authors are among the

154

Countries delivered to

TOP 1%

most cited scientists

12.2%

Contributors from top 500 universities



WEB OF SCIENCE™

Selection of our books indexed in the Book Citation Index
in Web of Science™ Core Collection (BKCI)

Interested in publishing with us?
Contact book.department@intechopen.com

Numbers displayed above are based on latest data collected.
For more information visit www.intechopen.com



Human Brain Anatomy: Prospective, Microgravity, Hemispheric Brain Specialisation and Death of a Person

Zamzuri Idris, Faruque Reza and
Jafri Malin Abdullah

Additional information is available at the end of the chapter

<http://dx.doi.org/10.5772/67897>

Abstract

Central nervous system seems to float inside a craniospinal space despite having miniscule amount of CSF. This buoyancy environment seems to have been existing since embryogenesis. This indicates central nervous system always need microgravity environment to function optimally. Presence of buoyancy also causes major flexure to occur at midbrain level and this deep bending area of the brain, better known as greater limbic system seems to regulate brain functions and site for cortical brainwave origin. These special features have made it as a possible site for seat of human soul and form a crucial part in discussion related to death. Besides exploring deep anatomical areas of the brain, superficial cortical areas were also studied. The brainwaves of thirteen clinical patients were analysed. Topographical, equivalent current dipoles and spectral analysis for somatosensory, motor, auditory, visual and language evoked magnetic fields were performed. Data were further analysed using matrix laboratory method for bilateral hemispheric activity and specialization. The results disclosed silent word and picture naming were bilaterally represented, but stronger responses were in the left frontal lobe and in the right parietotemporal lobes respectively. The sensorimotor responses also showed bilateral hemispheric responses, but stronger in the contralateral hemisphere to the induced sensation or movements. For auditory-visual brainwave responses, bilateral activities were again observed, but their lateralization was mild and could be in any hemisphere. The conclusions drawn from this study are brainwaves associated with cognitive-language, sensorimotor and auditory-visual functions are represented in both hemispheres; and they are efficiently integrated via commissure systems, resulting in one hemispheric specialization. Therefore, this chapter covers superficial, integrative and deep parts of human brain anatomy with emphasis on brainwaves, brain functions, seat of human soul and death.

Keywords: microgravity, hemispheric specialization, brainwaves, soul, magnetoencephalography

1. Introduction

The average weight of the brain is 50 g in cerebrospinal fluid (CSF) and 1400 g without CSF (the actual brain weight) [1, 2]. The reduction in brain weight is believed to have resulted from the effect of CSF buoyancy or a microgravity environment created by CSF [3–5]. In principle, the force of gravity can be defied in three ways: (a) by acceleration or aerodynamic force, (b) by buoyant force that follows the Archimedes principle in 212 BC, which stated ‘any object wholly or partially immersed in fluid, is buoyed up by a force equal to the weight of the fluid displaced by the object’; it is a weightlessness concept (**Figure 1A**) and (c) by an object with no (or negative) mass (? dark matter) or time (? soul). CSF buoyancy results in a reduction of actual brain weight, leading to a state of microgravity or weightlessness. An extension of this postulation is the pregnant uterus, which can exert similar effects (buoyancy resulting in microgravity). During early gestation, the ratio of foetus size to the volume of amniotic fluid is greater than the ratio at late gestation. During this period, the foetus is in a flexed position or an antigravity (microgravity) position. Therefore, it can be postulated that antigravity or microgravity environment is essential for normal development of CNS (**Figure 1B**). This stage of development leads to a flexed position of the foetus at early gestation (microgravity body position: just like the astronaut in space, curved or a horizontal position, whilst the gravity position assumes a vertical position). The microgravity position of the foetus changes at later gestation to assume a vertical gravity position, which is essential for muscles and bone development and for preparation of childbirth (with gravity force: 1g or 9.81 m/s^2) [6–8].

Regarding hemispheric specialization, the cerebrum consists of two hemispheres that are interconnected via commissures, the largest of which is the corpus callosum. Integration of information from each side appears crucial in a normal functional brain. This chapter illustrates

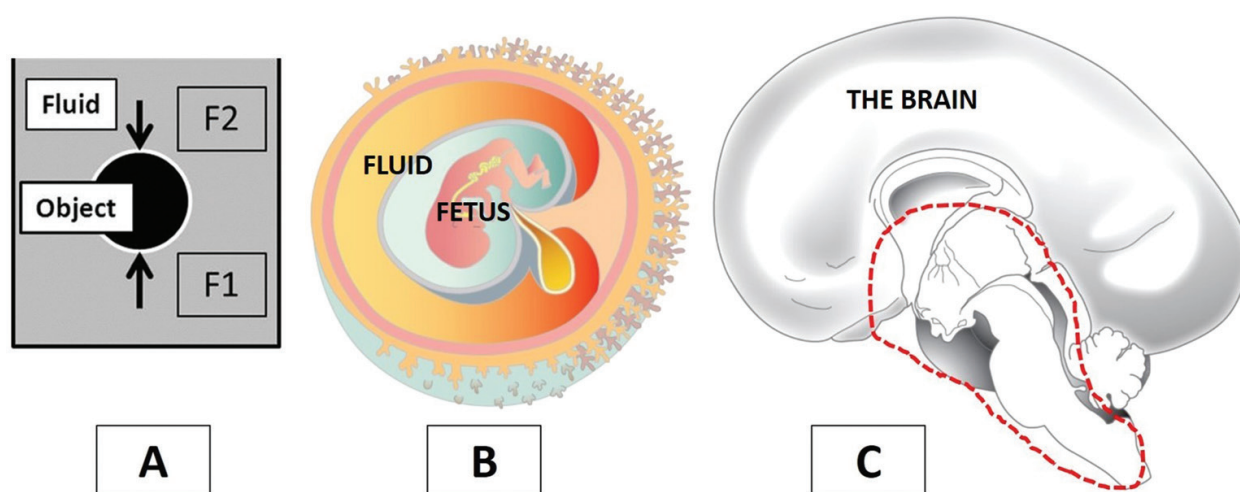


Figure 1. (A) The Archimedes principle: The sunken object will not move if the F1 force equals the F2 force. (B) Early embryogenesis which occurs in buoyant environment. The system is at its best when no influence from the gravity force is present. (C) Microgravity posture and the greater limbic area (covered by a dashed line).

the usage of magnetoencephalography (MEG) and electroencephalography (EEG) to analyse brainwaves and to map the functional anatomy of both hemispheres. Mapping and studying the functional and anatomical aspects of language, sensorimotor and auditory-visual functions have commonly been performed in other studies with positron emission tomography (PET) or functional MRI (fMRI) [9–14]. In this particular chapter, we used brainwave detection technology (MEG and EEG) to visualize the cortical brainwaves for the aforementioned tasks and study their hemispheric activity and specialization. We also performed a literature review on the anatomical structures involved in the fast and efficient transfer of information between the two cerebral hemispheres, the corpus callosum and other commissures as well as a brief review on callosal surgery.

After discussing the whole brain as an organ in microgravity environment and cortical brain anatomy and function (the superficial part of the brain), finally, in this chapter, we also discuss on the major issue related to the death of a person, which has a close anatomical link with structures at the ‘deep and central part of the brain’. This deep anatomical area seems to play a crucial role in either cardiac or brain death and was labelled as ‘the seat of human soul’ by many ancient philosophers including Plato and Leonardo Da Vinci [15, 16]. This deep periventricular area covers anatomical structures of the brainstem, reticular system, hypothalamus, thalamus, basal forebrain or septal area, amygdala, hippocampus and pineal and pituitary glands, and it is better known as the ‘greater limbic system’, which was introduced by Nieuwenhuys et al. in 1988 [17, 18].

2. Microgravity inside the central nervous system

The concept of microgravity within the CNS relates to the Archimedes buoyancy effect of CSF. Despite miniscule amount of CSF, buoyancy is maintained by: (a) the Windkessel phenomenon (vascular pulsations) that causes brain pulsation and hence well-distributed intraventricular and extraventricular cerebrospinal fluid which sandwich the brain parenchyma, (b) the anchoring effect provided by the nerve roots, filum terminale, denticulate ligament at the bottom and cranial nerves as well as blood vessels at the skull base, and importantly (c) the brain itself consists of 70% of water and 30% of dry matter, and 60% of dry matter actually consists of fat. In relation to this, the proofs for the central nervous system lie in the microgravity environment and are provided by: (a) weightlessness of the brain, (b) microgravity or bending posture at the mid-brain level for the brain (therefore, terms such as ventral and dorsal, rostral and caudal for the brainstem and spinal cord and cerebrum are different: e.g., the term ventral for the brainstem is anterior whilst ventral for the cerebrum is inferior and the term rostral for the brainstem is the superior end whilst for the cerebrum, it means the anterior end) (**Figure 1C**), (c) the central nervous system development always requires buoyant environment, and this is provided by the chorionic and later by an amniotic fluid during pregnancy, (d) sinking skin flap syndrome with alteration in cerebral blood flow in a chronic craniectomy patient [19], (e) the brain seems to easily float when saline

flushing is made during open brain surgery, (f) brainshift whenever CSF buoyancy is eliminated: this may suggest that the brain could indeed be in 'neutral buoyancy' by which 'CSF density' is nearly the same with 'brain density' [20, 21] and (g) studies indicating simulated microgravity enhance the differentiation of mesenchymal stem cells into neurons [8, 22]. These arguments point that the CNS could possibly lie within a microgravity environment (between 0 and 1g or 9.81 m/s^2).

In reference to aforementioned notes, this concept could explain the occurrence of flexures at the base of the brain (transitional region at the anchoring base and floating part of the telen-cephalon) and indicates that the thalamus and hypothalamus are possible rostral extensions of the brainstem. Furthermore, this new perspective on the CNS has several important points that should be emphasized:

- a. the early development of the CNS requires microgravity environment.
- b. a study of the CNS such as CNS stem cells should be done in the microgravity environment (between 0 and 1g).
- c. the 'greater limbic system', as suggested by Nieuwenhuys and colleagues in 1988, is possibly a valid notion, which should include (i) the classical limbic system—amygdala, hippocampus, fornix, habenular complex, mamillary body, cingulate and parahippocampal cortices, nucleus accumbens and hypothalamus, (ii) thalamus, (iii) basal forebrain or septal nuclei, (iv) pineal and pituitary glands and (v) classical reticular-brainstem system (17, 18). This set of 'periventricular' anatomical structures should be viewed as one system, and brain networks would possibly cover at least one of its structures. This hypothesis is made based on the fact that the origin for the cortical brainwaves is from this deep anatomical area, as shown by a study done by Moruzzi and Magoun in 1949 [23].

The concepts of microgravity inside the brain, and the greater limbic system as an origin for the brainwaves that are much emphasized here, lead us to examine more on their anatomical and functional relationships.

2.1. Anatomical relationship: reticular formation network anatomy, microgravity inside the central nervous system and origin for the brainwaves

Classical reticular formation occupies the central portion of the brainstem, surrounded by the cranial nerve, sensory relay nuclei and the ascending and descending fibre systems. It is connected to all parts of the brain neocortex (six layers of cerebral hemispheric cortex), archicortex (three to four cortical layers of hippocampus and olfactory cortex) and paleocortex (four to five cortical layers of rostral insular, parahippocampus, olfactory bulb, olfactory tubercle, piriform cortex, periamygdalar area, anterior olfactory nucleus, anterior perforated substance and prepyriform area), either directly or indirectly via the basal forebrain nuclei,

thalamus or hypothalamus and to the spinal cord. It is extraordinarily rich in neuromediators: noradrenalin, serotonin, choline, histamine, gamma-aminobutyric acid (GABA) and hypocretin. Generally, it can be divided into two systems: (a) ascending reticular activating system (ARAS) and (b) ascending reticular inhibitory system (ARIS) [24]. These two divisions are important in mediating consciousness, integration of autonomic (visceromotor), behavioural and somatomotor responses, the endocrine and regulation of sleep-wake cycle. The classical view of the reticular formation identifies its components only in the brainstem, with connections primarily to the thalamus, hypothalamus and basal forebrain nuclei (septal nuclei, etc.). Nieuwenhuys and colleagues provide an alternative view of the reticular system highlighting its significant involvement with the limbic, hypothalamic and parhypothalamic structures. They named this new circuit as the 'greater limbic system' and identified the hypothalamus, which resides rostrally outside the classical reticular formation as a vital component of it [17, 18].

The classical reticular formation forms diffused mosaic-like structures with many functional nuclei inside the brainstem, which includes anatomically the medulla oblongata (myelencephalon), pons (part of metencephalon) and mid-brain (mesencephalon). It forms the core of the neuroaxis, which is anatomically orientated in a vertical or gravity posture. In contrast to the brainstem, the diencephalon that consists of thalamus, epithalamus, subthalamus, hypothalamus, basal forebrain area, amygdala, hippocampus and some other periventricular structures is positioned horizontally, in an antigravity or microgravity posture. A combination of these two postures forms the 'T'-like shape of CNS cores and paracores. This is mainly resultant from the presence of mesencephalic or primary cephalic flexure during early brain development. If without this flexure, the brainstem and reticular formation shall assume a single vertical configuration with the hypothalamus-thalamus forming its rostral end. This early embryological bending occurs because of the buoyant environment provided by the chorionic and amniotic fluid during gestation and maintained throughout life by the CSF. Interestingly, a study by Moruzzi and Magoun in 1949 disclosed that the origin for the brainwaves is from this deep reticular system and influences the cortical brainwave rhythms through two pathways: (a) dorsal pathway via the thalamus (thalamocortical network) and (b) ventral pathway through the hypothalamus, basal forebrain region, amygdala and hippocampus (extra-thalamic network) [23]. This extra-thalamic network could be the reason why in refractory epilepsy, peripheral stimulation of the vagus nerve can reduce seizure rates (vagus nerve-extrathalamic pathway-hippocampus-cortex) [25–27]. These two circuits run deep inside the brain and form important circuits (core and paracore of the CNS) which deal with at least two important aspects of neurocognition: (a) consciousness and (b) memory.

2.2. Functional relationship: consciousness, memory and origin for the brainwaves

Consciousness and memory are seen as two essential aspects in human cognition. This mental process of acquiring knowledge and understanding through thought, experience and senses is special for human beings. This cognitive capability also allows some humans who are believers to appreciate creations and God (creator). One may find difficulty in praying to God if he

or she had an alteration in conscious or memory level. Therefore, one may view that these cores and paracores of the CNS which give rise to consciousness and memory are essentially a seat of human soul. The debates on the seat of human soul had been going on since ancient times. Plato (424–348 BC) and Galen (circa 200/216 BC) had labelled the brain (encephalocentric theory) as an important organ for the soul whilst Aristotle (circa 384–383 BC) who learnt from Plato disagreed on Plato's idea and preferred the heart as the seat of human soul. Later, during the renaissance period, which began roughly at fourteenth century in Italy, Leonardo da Vinci (1452–1519) had located the soul inside the brain and more specifically in the middle ventricle close to anterior portion of the third ventricle near the hypothalamus after drawing the intersecting infinity lines (golden ratio) of the human cranium [5, 15, 16]. The area identified by Leonardo da Vinci is in fact part of the greater limbic system [interesting to note that most structures in this deep anatomical area are infinity in shapes—such as Solomon's knot (mosaic-like reticular system), Pascal's spiral, Archimedean and Durer spirals (hippocampus, caudate nucleus), cycles of Lemniscate (thalamus) and pyramid (insular)]. Therefore, it seems that the greater limbic system is an attractive notion for the seat of human soul because of several reasons:

- a. It is an area for 'brainwave origin'.
- b. It controls 'consciousness and memory' (two main aspects of human cognition and closely related to remembering God); alteration or loss of consciousness (or memory) happens if someone injured this deep area and therefore have difficulty to remember or appreciate God.
- c. A person's death would involve this anatomical area—refer to the last section in this chapter.
- d. It may be viewed as the centre of 'all brain networks' (at least one node which arises from this deep brain region may be present in any brain network, and this node could appear larger than the rest).
- e. 'Infinity' lines of the skull intercepting at this area, and most anatomical structures in this deep area, are likely 'infinite' in their shapes.

We have discussed the whole brain and viewed it as one in microgravity environment and touched on the curving region of the brain (periventricular region or deep region of the brain), which forms a core and a paracore of the CNS that regulates brainwave rhythms, controls consciousness and memory and determines death of a person. Before discussing further on matters pertaining to death of a person and deep brain area, next we present our study on neurocognition, which commonly involves the superficial brain area or two cortical brain hemispheres, which is also known as 'bilateral hemispheric involvement and hemispheric specialization'.

3. A study on hemispheric human brain specialization

Cortical brainwaves mainly result from pyramidal postsynaptic potentials, which have synchronized oscillations with the following: (a) the thalamus, otherwise known as thalamocortical

networks, which are modulated by the reticulo-thalamo-cortical circuits, (b) the extrathalamic-cortical circuits, which mainly involve the reticular system, hypothalamus, hippocampus, amygdala, basal forebrain and septal nuclei and (c) other cortices, known as cortical-cortical networks [5, 17]. In 1952, Magoun reported that the reticular system in the brainstem has a crucial role in generating the pattern of brainwaves [23]. This classical reticular system in the brainstem has vast networks with other structures in the diencephalon, such as the thalamus, hypothalamus, basal forebrain and septal nuclei, parhypothalamic nuclei, pineal and pituitary glands, the limbic system as well as the insula, basal ganglia and neocortex. The vast interconnecting networks, via the thalamic and extrathalamic circuits, create optimal brain-wave oscillations in the cortex, which can be studied using MEG and EEG [4, 28].

Generally, it is complicated to map the actual areas responsible for brain cognition, sensorimotor and auditory-visual functions. Many believe that these brain functions could have originated deep within the centre of the brain, involving anatomical areas that have vast networks with the cortices [28–32]. These areas are the thalamus, hypothalamus, amygdala, hippocampus, basal forebrain and septal nuclei, reticular system and pituitary-pineal system which form the core and paracore for the central nervous system. Mapping the areas involved in the aforementioned functions should ideally have covered these deep areas. However, our study focused only on superficial brain mapping and cortical brainwave analysis as the availability of MEG testing allows relatively reliable, superficial and non-invasive methods compared to deep brain mapping [33].

3.1. Studied subjects

This chapter included 13 clinical, adult, right-handed patients with various pathologies as follows: cortical dysplasia, meningioma, low- and high-grade gliomas, glioblastomas (GBM), basal ganglia arteriovenous malformation, temporal arteriovenous malformation, cavernomas and peritrial lesions (**Table 1**). All patients underwent routine MEG recordings before the neurosurgical interventions. MEG recordings were made for standard evoked somatosensory, motor, auditory and visual responses. For patients with lesions near the assumed speech area, further language MEG recordings and mappings were performed. The MEG data were registered, processed and fused with anatomical MRI images. These images were then used with the neuronavigation system for surgery. Two patients underwent contralateral hemispheric scalp EEG recordings during awake brain surgery (cases 1 and 2 in **Table 1**).

3.2. MEG recording, procedure, post-processing and overdetermined anatomical analysis for somatosensory-, motor-, auditory- and visual-evoked fields

Magnetic-evoked fields were recorded whilst patients were seated in a magnetically shielded room (MaxShieldTM, ElektaOy, Helsinki, Finland) using a 306-channel (102 magnetometers and 204 gradiometers) whole-head MEG system (ElektaNeuromag®, ElektaOy, Helsinki, Finland) (**Figure 2A**). Online band-pass filtering was performed between 0.01 and 330 Hz to discard the noise. Further filtering was performed for offline data analysis using a high-pass filter of 60 Hz with a width of 0.6 Hz and a low-pass filter of 3 Hz with a width of 0.3 Hz. The epoch duration was up to 300 ms. The sampling frequency was 1 kHz. With respect to the procedure, the head position relative to the MEG sensors of the helmet was localized using

Types of analysis	Diagnosis	MEG/EEG analysis	MEG/EEG findings	Summary of the responses
Motor responses	1. Motor cortex metastases	a. Topographical non-superimposed MEG motor-evoked fields and	a. MEG: Bilateral-evoked fields with stronger fields noted contralateral to the movements	Bilateral hemispheric motor responses with stronger fields in the contralateral side to the movements and inversed polarity in the hemisphere that was ipsilateral to the movements
		b. Contralateral to the stimulated motor gyrus EEG analysis (during awake surgery)	b. EEG: Contralateral responses were recorded when the motor gyrus was stimulated	
	2. Right peritrial lesion	a. Topographical non-superimposed MEG motor-evoked fields and	a. MEG: Bilateral-evoked fields with stronger fields noted contralateral to the movements	
		b. Contralateral to the stimulated motor gyrus EEG analysis (during awake surgery)	b. EEG: Contralateral responses were recorded when the motor gyrus was stimulated	
	3. Basal ganglia vascular lesion (AVM)	a. Topographical superimposed MEG motor-evoked fields	a. MEG: Bilateral hemispheric motor-evoked fields responses with stronger fields in the hemisphere contralateral to the movements	
	4. Motor cortical dysplasia	a. Topographical non-superimposed bilateral MEG motor-evoked fields	a. MEG: Bilateral hemispheric motor-evoked field responses with stronger fields in the hemisphere contralateral to the movements	
Sensory responses	1. Left lower frontal low-grade gliomas	a. Brain lobes MEG analysis for sensory-evoked fields	a. Bilateral hemispheric sensory-evoked field responses that were stronger in the hemisphere that was contralateral to the sensory median nerve stimulation	Bilateral hemispheric sensory responses were stronger in the hemisphere that was contralateral to the sensory stimulation
	2. Right frontal-temporal glioblastomas (GBM)	a. MEG source analysis for sensory-evoked fields	a. Bilateral hemispheric sensory-evoked field responses that were stronger in the hemisphere that was contralateral to the sensory median nerve stimulation	

Types of analysis	Diagnosis	MEG/EEG analysis	MEG/EEG findings	Summary of the responses
Auditory responses	3. Right temporal meningioma	a. MEG source analysis for sensory-evoked fields	a. Bilateral hemispheric sensory-evoked field responses that were stronger in the hemisphere that was contralateral to the sensory median nerve stimulation	
	1. Cribiform plate meningioma	a. Brain lobes and topographical MEG analysis for auditory-evoked fields	a. Bilateral hemispheric auditory-evoked field responses with mild dominance in the ipsilateral hemisphere to ear clicks for hearing	Bilateral hemispheric auditory responses with mild dominance in either hemisphere
	2. Small basal ganglia vascular lesion (AVM)	a. Brain lobes and topographical MEG analysis for auditory-evoked fields	a. Bilateral hemispheric auditory-evoked field responses with mild dominance in the contralateral hemisphere to ear clicks for hearing	
Visual responses	3. Left frontal-temporal meningioma	a. MEG source analysis for auditory-evoked fields	a. Bilateral hemispheric sensory-evoked field responses. Source localization and brain activity of the auditory area are matched. Stronger activation on the left hemisphere	
	1. Right peritrial lesion	a. Topographical non-superimposed MEG visual-evoked fields and Matlab analysis	a. Bilateral visual-evoked field responses with mild left dominance	Bilateral hemispheric visual responses with mild dominance in either hemisphere
	2. Right parietal cavernoma	a. Topographical non-superimposed MEG visual-evoked fields	a. Bilateral visual-evoked field responses with mild right dominance	
Language responses—silent word naming	3. Right temporal arteriovenous malformation	a. MEG source analysis for visual evoked fields	a. Bilateral hemispheric visual-evoked fields responses. Source localization and brain activity are matched. Brain activation of both hemispheres is recruited equally	
	1. Left lower frontal low-grade gliomas	a. Brain lobes MEG and Matlab analysis for silent word naming	a. Bilateral frontal, parietal, temporal and occipital lobe responses with marked differences (stronger) in the left frontal lobe (dominant hemisphere)	Bilateral hemispheric responses with dominance in the left hemisphere

Types of analysis	Diagnosis	MEG/EEG analysis	MEG/EEG findings	Summary of the responses
Language responses—silent picture naming	2. Left upper frontal low-grade tumour	a. MEG source analysis for silent word naming of language-evoked field	a. Source analysis indicated that there is bilateral source localization in the temporal area. Source localization and brain activity are matched. Stronger activation on the left hemisphere	
	1. Left lower frontal low-grade gliomas	a. Brain lobe MEG analysis for silent picture naming	a. Bilateral parietal, temporal and occipital lobe responses with stronger responses noted in the right temporal lobe	Bilateral hemispheric responses with stronger responses noted in the non-dominant (right) temporal and parietal lobes
	2. Left temporal high-grade gliomas	a. Brain lobe MEG and Matlab analysis for silent picture naming	a. Bilateral responses with stronger responses noted in the right temporal lobe	

Table 1. Summary of clinical cases that were studied using MEG and EEG for hemispheric specialization.

the following: (a) three fiducial localization coils attached to the right and left pre-auricular points and to the nasion of the patient, (b) 100–150 points digitized around the head using a 3D position monitoring system (Pholemus, Colchester, VT) and (c) four electromagnetic head position indicator (HPI) coils to assess the head position at the beginning of the measurement process. During the recording, head position changes of up to 1.5 cm were accepted. MEG source localization for somatosensory- (stimulation of the median nerve in the hand), motor- (active movement of the index finger), auditory- (emission of clicking sounds in each ear separately) and visual (each eye tested with a checkerboard separately)-evoked magnetic fields were performed using the overdetermined equivalent current dipole (ECD) technique, which was already installed inside the Neuromag computer working station (**Figure 2B**). The somatosensory-, motor-, auditory- and visual-evoked magnetic fields for a person without intracranial pathology is expected to be at around N20 (20 ms), P5 (–5 ms) (left-hand motor), P50 (–50 ms) (right-hand motor), N100 (100 ms) and N75–120 (75–120 ms), respectively (N: negativity and P: positivity). The anatomical magnetic resonance imaging (MRI) of T1, T2, FLAIR and 3D sequences were obtained using Philips MRI (Philips Intera 3.0T MRI scanner). Fusion between the anatomical MRI images and topographic reconstruction of the head-model brainwave data was completed prior to source localization.

3.3. MEG recording, procedure, post-processing and overdetermined anatomical analysis for language

The MEG equipment, software and sampling rates were the same as the one described above using an Elekta MEG-Neuromag Ltd, with 306 channels consisting of 204 planar gradiometers and 102 magnetometers, which were set at a minimum sampling rate of 1 kHz. The band-pass

filter was between 0.01 and 330 Hz, with a high-pass filter of 60 Hz and width of 0.6 Hz and a low-pass filter of 3 Hz, with a width 0.3 Hz. The epoch duration for the language study was longer (850 ms), including a -150 ms pre-stimulus interval. Silent reading tasks were performed during MEG recordings, where subjects sat on a comfortable chair with their heads fixed into the MEG machine. After the presentation of an eye fixation point for 3 s, four-character semantic words for the word-naming task were shown for 3 s on an 80-inch rear projection screen that was located 1.5 m away from the subject in the same room. Visual stimuli were generated using a visual presentation system which was projected by a projector located outside the room. Subjects were tasked to read immediately after the presentation of the word only once, without phonation. One session consisted of 100 different word presentations. The words were selected from an elementary school dictionary so that the subjects would quickly and easily understand them. The word stimuli subtended a horizontal visual angle of 3° and a vertical angle of 1°; as a result, no eye movements were necessary to visualize the presented word. Each recording session took at least 1 h to complete; however, the subjects were able to pause the task if they were starting to feel uncomfortable. The same procedure was repeated for picture naming, whereby common pictures were shown and patients silently named the pictures. The analysed brainwave language-related field (LRF) components included N100 (100 ms), N200 (200 ms), N400 (400 ms) and N600 (600 ms). The components were taken from the highest peak of each evoked LRF signal. The evoked LRF data were analysed in topographical brain lobes, then were fused with the anatomical MRI images and further subjected to the underdetermined modelling analysis using Matlab-statistical parametric mapping (SPM) and brain electrical source analysis (BESA) software.

3.4. Underdetermined anatomical analysis for MEG data

An in-house Matlab-SPM-based MEG-pipeline programme was used to analyse the MEG data. This was accomplished with SPM-based Matlab 7.4-R2008a (MathWorks Inc., Natick, MA, USA) to diffusely localize eloquent areas based on Montreal Neurological Institute (MNI) template. Standard neuroscience spectral data analysis, such as analysis on the region of interest (ROI) with the concomitant detection of significant active regions ($p < 0.05$) that respond to external stimuli and inverse solutions for EEG or MEG data, was utilized (**Figure 2C–E**). Besides an in-house SPM-based Matlab, BESA (Version 6.0, GmbH, Graefelfing, Germany) was also used to process the source localization of the waveforms for the sensory, visual, auditory and language processing area. MEG data were co-registered to the template of structural MRI implemented in BESA Research 6.0. Two source dipoles were fitted with the constraint of having symmetrical sources in each hemisphere. Using different start locations, these symmetric dipoles were allocated consistently to the region of interest. Dipoles were fitted sequentially; a single dipole was placed on the right hemisphere and fitted over 50–150 ms for auditory-, visual- and language-evoked responses and 0–50 ms for somatosensory-evoked responses. These steps were subsequently repeated in the opposite hemisphere.

3.5. Results on data analysis

MEG data of 13 clinical patients were analysed. This included two patients who had scalp electrodes on the opposite hemisphere and direct motor cortex stimulation during awake

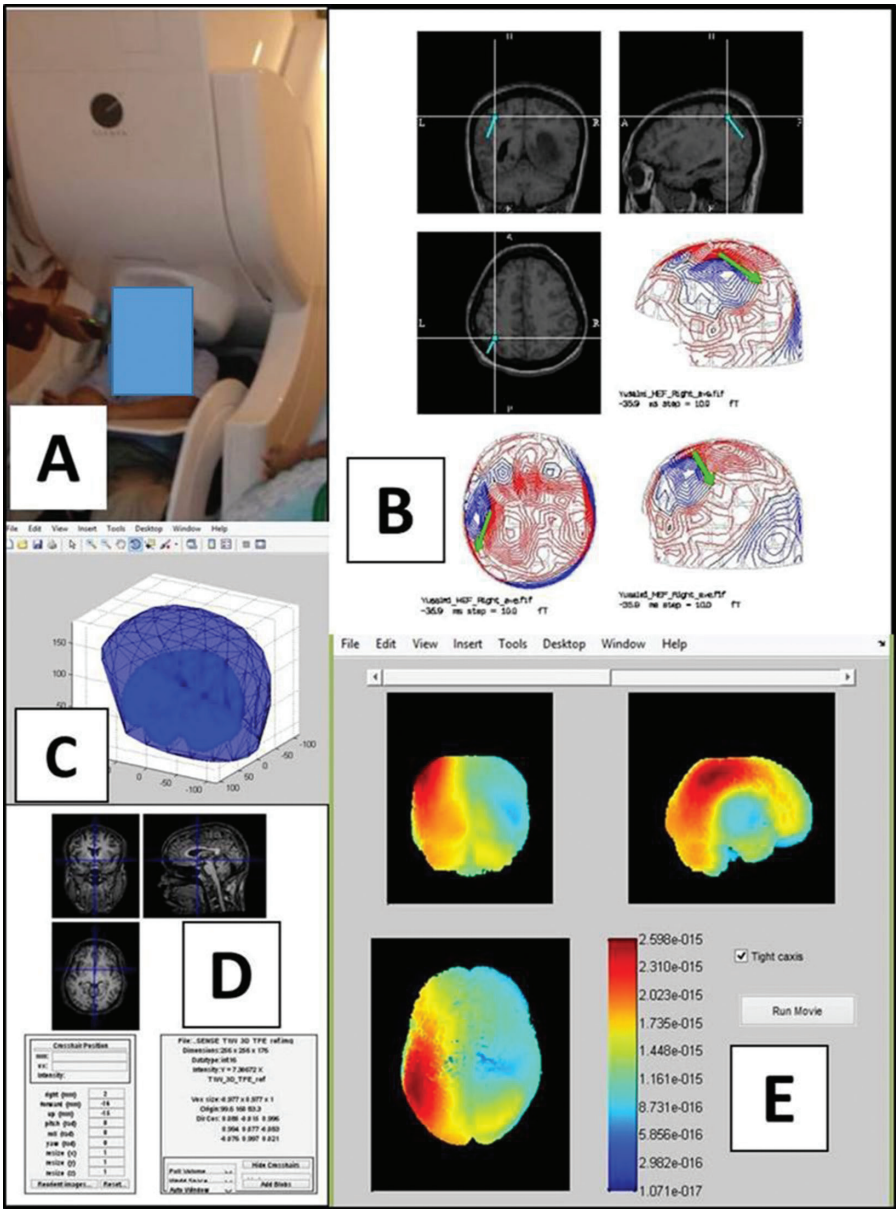


Figure 2. (A) MEG recording procedure. (B) An overdetermined equivalent current dipoles analysis using the vector of magnetic fields to localize the source of various evoked fields. (C) Spherical modelling for the brain using Matlab. (D) Image fusion between MEG-brainwave and MRI brain. (E) Underdetermined inverse solutions using Matlab for MEG data that have a significant response to the evoked magnetic field (in this example, it is the somatosensory-evoked field).

brain surgery. All patients underwent MEG prior to any surgical intervention for the purpose of mapping the eloquent anatomical areas of the brain. The MEG data were analysed for motor-, sensory-, auditory-, visual- and language-evoked fields. The summary of the analysis is presented in **Table 1** (17 analyses from 13 patients).

3.5.1. Hemispheric responses for motor-, sensory-, auditory- and visual-evoked fields

Unilateral motor-, sensory-, auditory- and visual-evoked fields were present in both cerebral hemispheres. There were some peculiar differences amongst them. For motor-evoked fields, there were bilateral hemispheric responses with stronger responses from the hemisphere

contralateral to the finger movement (**Figure 3A and B**). Two of the four patients analysed for motor responses underwent awake surgery with direct motor cortex stimulation and contralateral scalp EEG monitoring. The scalp EEG recordings demonstrated inverse polarities produced by unilateral hand movements where upgoing waveforms were seen in the contralateral hemisphere and downgoing waveforms were seen in the ipsilateral hemisphere (**Figure 3C–E**). These inversed polarities were further confirmed with topographical MEG brainwave analysis for motor functions as shown in **Figure 3A and B**. Similarly, sensory-evoked fields were studied using MEG, and responses were noted in both hemispheres with markedly stronger responses observed in the hemisphere contralateral to the sensory stimulation (**Figure 4**). Results from source localization and brain activation analysis of the other two patients also showed a similar pattern of responses, bilateral activities and a stronger activation on the contralateral sensory areas (**Figure 4C and D**).

For auditory-evoked fields, three patients were included in the analysis. Source localization and brain activation results were matched and demonstrated with bilateral activation of the

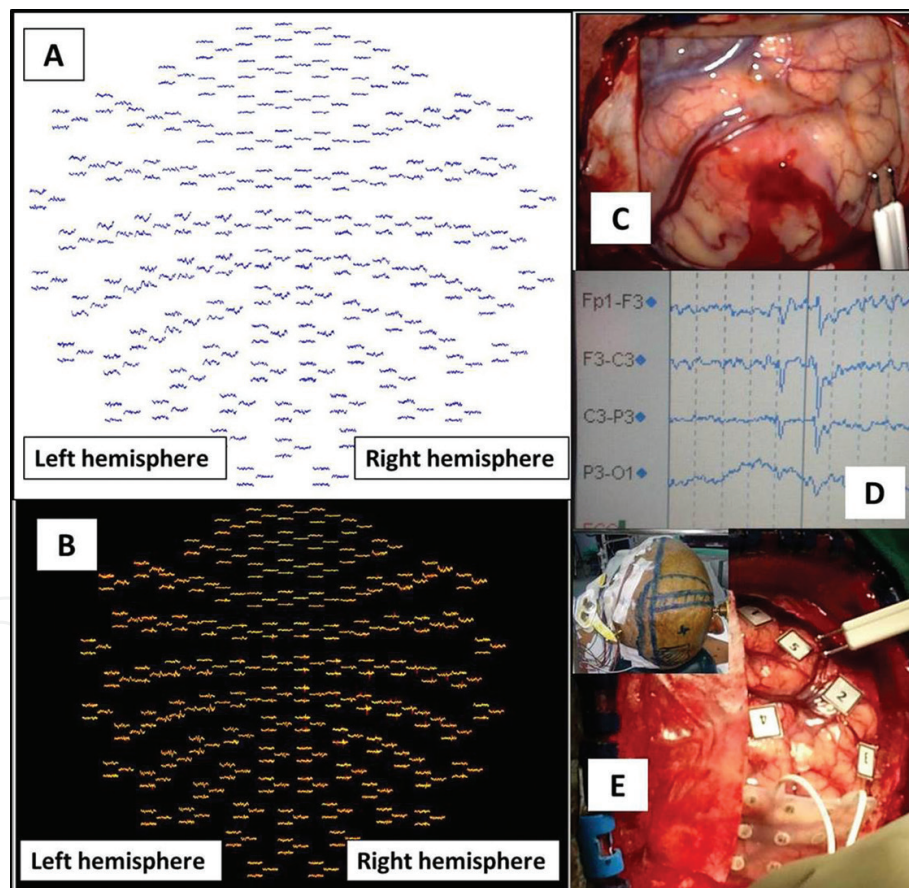


Figure 3. (A) Topographical non-superimposed motor-evoked fields for a right-finger tap. Bilateral hemispheric motor-evoked fields responses but stronger in the hemisphere contralateral to the movements (left hemisphere). (B) Topographical superimposed motor-evoked fields for the right-finger tap (red-evoked fields) and left-finger tap (yellow-evoked fields). Bilateral hemispheric motor-evoked fields responses are again noted here but a stronger response is seen in the hemisphere contralateral to the movements. (C and D) Direct motor cortex stimulation induces inversed-spike waves polarity in the contralateral hemisphere detected by scalp EEG. (E) A similar procedure in another patient showing similar findings (inset shows the scalp EEG in a contralateral hemisphere).

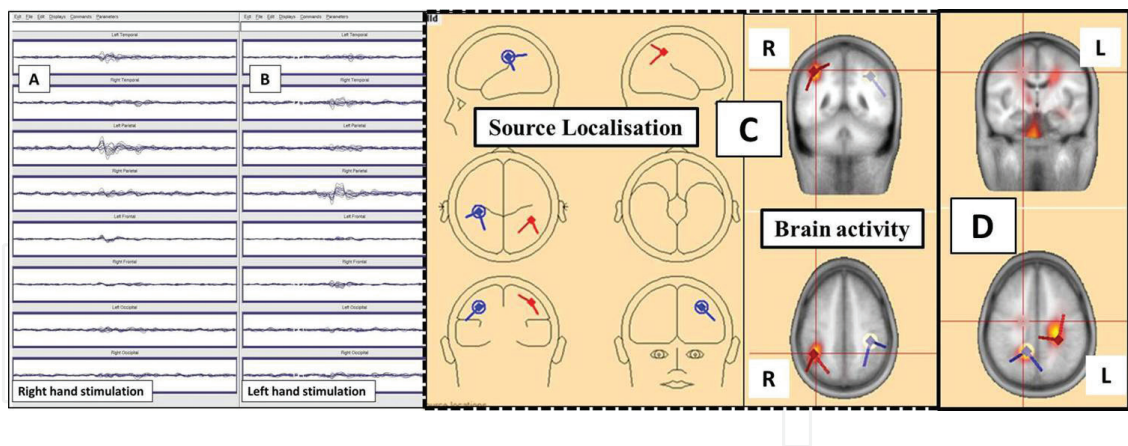


Figure 4. (A) Topographical brain lobe analysis: Right median nerve stimulation-induced bilateral hemispheric responses but a stronger response is noted in the contralateral hemisphere. (B) Similar findings were noted when the left median nerve was stimulated. (C and D) BESA-based source and brain activity analysis of another two patients during sensory-evoked field responses. Results indicate bilateral activations in the sensory areas but with a stronger activation in the contralateral hemisphere to the sensory stimulation (C: left-hand sensory stimulation and D: right-hand sensory stimulation).

auditory areas with mild hemispheric specialization. Moreover, the hemispheric dominance for auditory responses was noted as non-specific; it can either be in the right or left hemisphere (**Figure 5A–E**). This was because the waveforms produced by auditory stimulation were nearly similar in both hemispheres and indicated that auditory dominancy was indeed mild. For visual-evoked fields, there were again nearly similar bilateral brainwave representations and, therefore, unclear hemispheric specialization was observed on topographical images. As before, advanced source analysis and brain activation results again confirmed bilateral activations in the visual areas with mild hemispheric specialization. **Figure 6A** and **B** shows bilateral activations with mild hemispheric specialization in the left whilst in **Figure 6C**, the right side is the dominant hemisphere for visual-evoked fields.

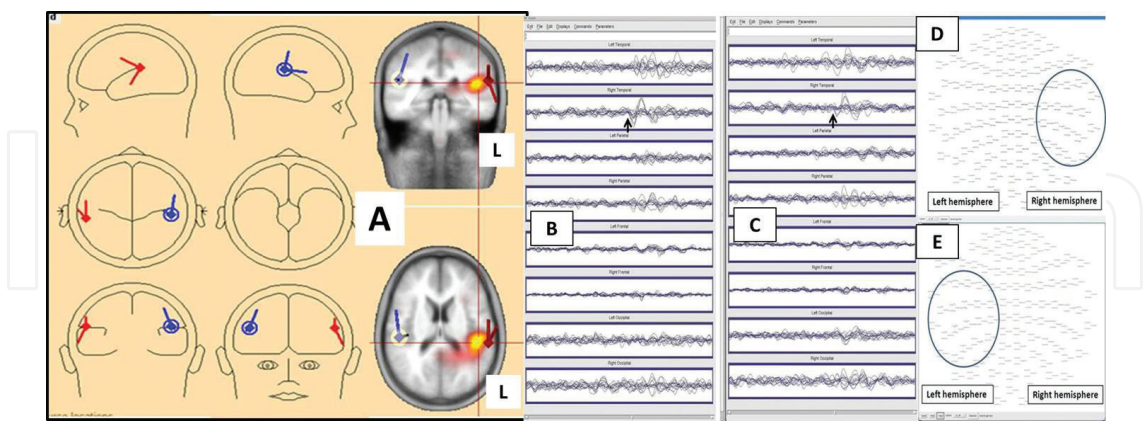


Figure 5. (A) Source localization and brain activity in the bilateral temporal areas during auditory-evoked field responses analysed using BESA. Results show stronger responses in the left hemisphere. (B and C) Topographical brain lobe analysis. (B) Right ear clicks resulting in auditory-evoked magnetic fields in ipsilateral ear (arrow head shows earlier responses in right temporal with smoother and well-formed waveforms). (C) A similar patient with left ear clicks, resulting in auditory-evoked magnetic field responses in the contralateral ear (arrow head shows earlier responses also in a right temporal with smoother and well-formed waveforms). Therefore, the right hemisphere is mildly dominant for hearing in this patient. (D) A similar patient in B and C with its data portrayed in topographical brainwave analysis for hearing—left ear clicks induced right hemispheric responses (circle). (E) Another patient who had left ear clicks but main responses were seen in the left hemisphere (circle); the subject has mild ipsilateral or the left hemisphere is dominant for hearing.

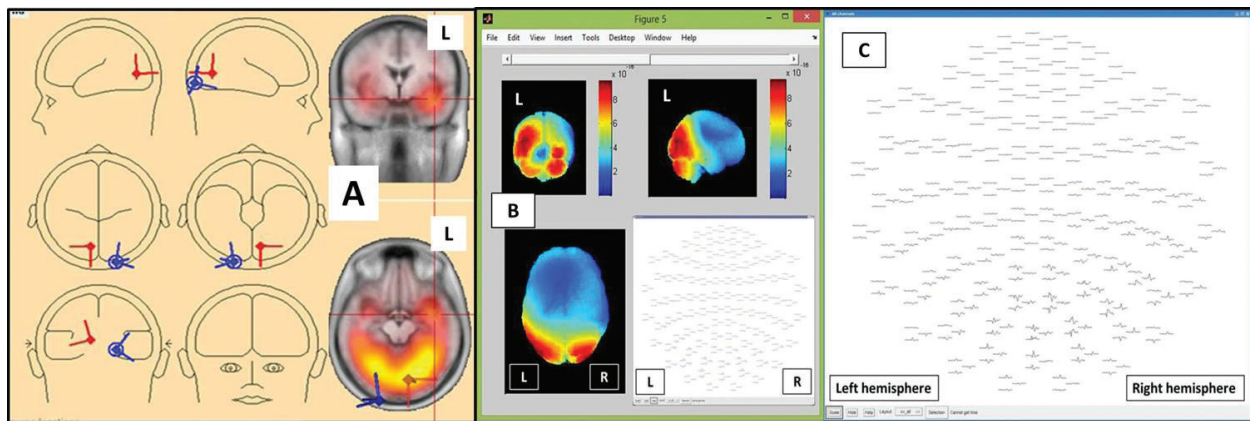


Figure 6. Source localization and brain activity for vision. (A) BESA-based analysis shows activation of the bilateral occipital areas during visual-evoked fields with mild hemispheric dominance in the left. (B) Topographical visual-evoked fields and Matlab-SPM-based analysis show bilateral visual-evoked field responses with mild left dominance. (C) Topographical visual-evoked fields of another patient depicting bilateral visual-evoked field responses but with mild right dominance.

3.5.2. Hemispheric responses for language—silent word and picture naming

Brainwave analysis for language study also showed bilateral hemispheric responses. For silent word naming, brainwave activities were more markedly noted in the left than in the right frontal lobe, which could reflect the Broca's speech area (**Figure 7A**). This magnetic-evoked field, which was localized over the left frontotemporal area, was subsequently confirmed during awake brain surgery (**Figure 7B and C**). The Matlab-SPM-based analysis for silent word naming also revealed bilateral hemispheric responses that were more pronounced in the left hemisphere (**Figure 7D**). Nonetheless, one must be reminded that the right frontal lobe may also be involved in speech. Similarly, for silent picture naming, the activities were also bilateral but more was noted in the right temporal and parietal lobes as depicted on brainwave topographical brain lobe images, magnetic-evoked fields and Matlab-SPM-based diffused underdetermined methods (**Figure 8**).

3.6. Discussion: bilateral hemispheric responses and hemispheric specialization for motor, sensory, auditory, visual and language

Cutting-edge clinical neuroimaging of MEG and EEG enables the study of brain activity as images (brainwaves) and depicts functional networks of the brain. This study showed that not only does language have a feature of hemispheric dominance, as shown by Pierre Paul Broca in 1861 [34] but also hemispheric dominance for motor, sensory, auditory and visual cortical functions. Hemispheric specialization or dominance is defined as a hemisphere-dependent relationship between a specific function and a set of brain structures, which includes both hemispheric interaction by a given hemisphere of specialized networks that have unique functional properties and its mechanisms, enabling efficient interhemispheric coordination [35]. This functional lateralization or dominance is related to the grey and white matter asymmetries, which are established early in life, and directly suggests a strong relationship with the underlying genetic factors, as noted in various studies on functional MRI and diffusion tensor imaging [36–39]. Our study is different from previously published studies as

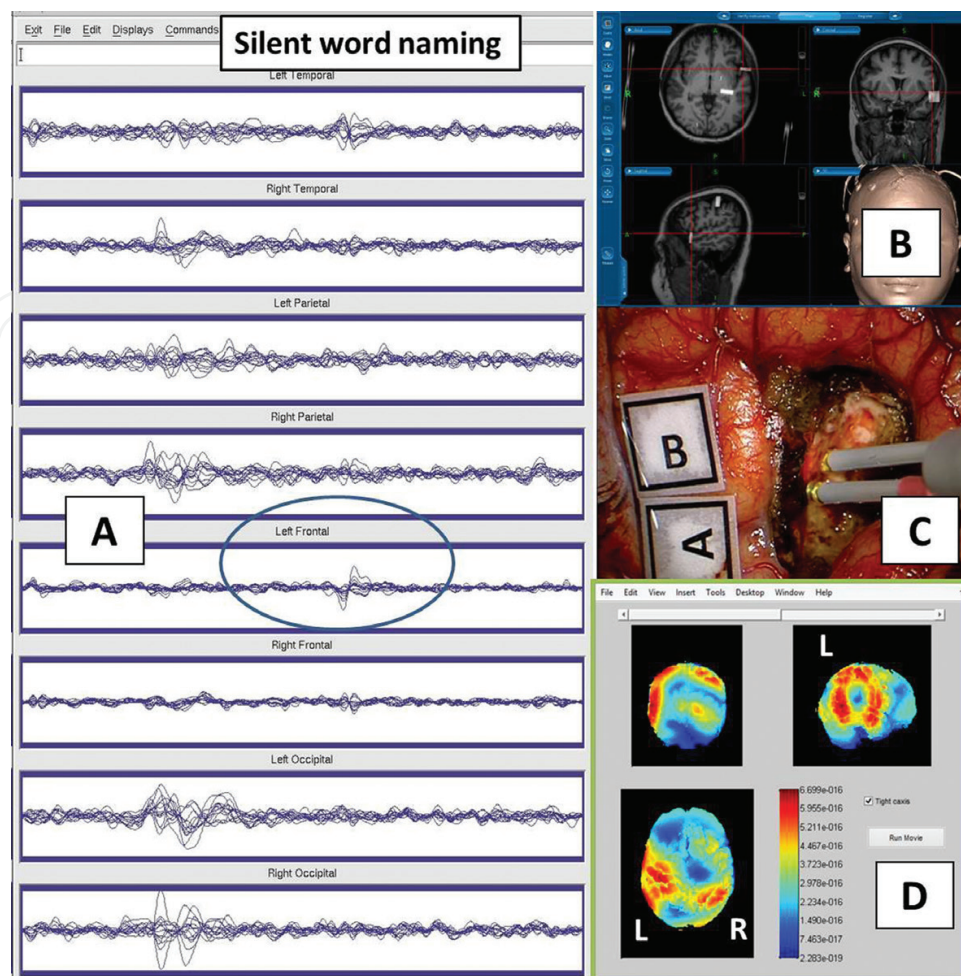


Figure 7. (A) Brainwaves analysis for silent word naming shows bilateral hemispheric responses; the activities were more marked in the left frontal lobe (circle) as compared to the right frontal which could reflect the Broca's speech area. (B and C) This magnetic-evoked field for silent word naming which was localized over the left frontotemporal area was subsequently confirmed during awake brain surgery. B image shows the navigation system during surgery which localized the speech area and was confirmed with direct brain stimulation as shown in image C. (D) The Matlab analysis for silent word naming also revealed bilateral hemispheric responses but more pronounced responses in the left hemisphere.

we used brainwaves (MEG and EEG) as the main parameter to study hemispheric activity and hemispheric specialization (dominance) for various tasks. Our brainwave study supports the findings of previous studies on hemispheric specialization using various other modalities [9, 10, 40–45]. Our chapter highlights that for sensorimotor activity, marked brainwave responses were noted in both hemispheres with a preference (lateralization or dominance or specialization) for one hemisphere. The motor brainwave responses were bilateral, and stronger wave responses were definitely noted in the hemisphere that was contralateral to the movements. The hemisphere that was ipsilateral to the movements was also activated, but it had inversed brainwave polarities. This suggests that integration of information from both hemispheres plays an essential role in carrying out efficient sensorimotor functions. By contrast, the results for hemispheric specialization for auditory and visual functions were unpredictable, and either hemisphere could be dominant (non-fixed). This could possibly be because lesions were present or because of a genetic factor that determines which hemisphere

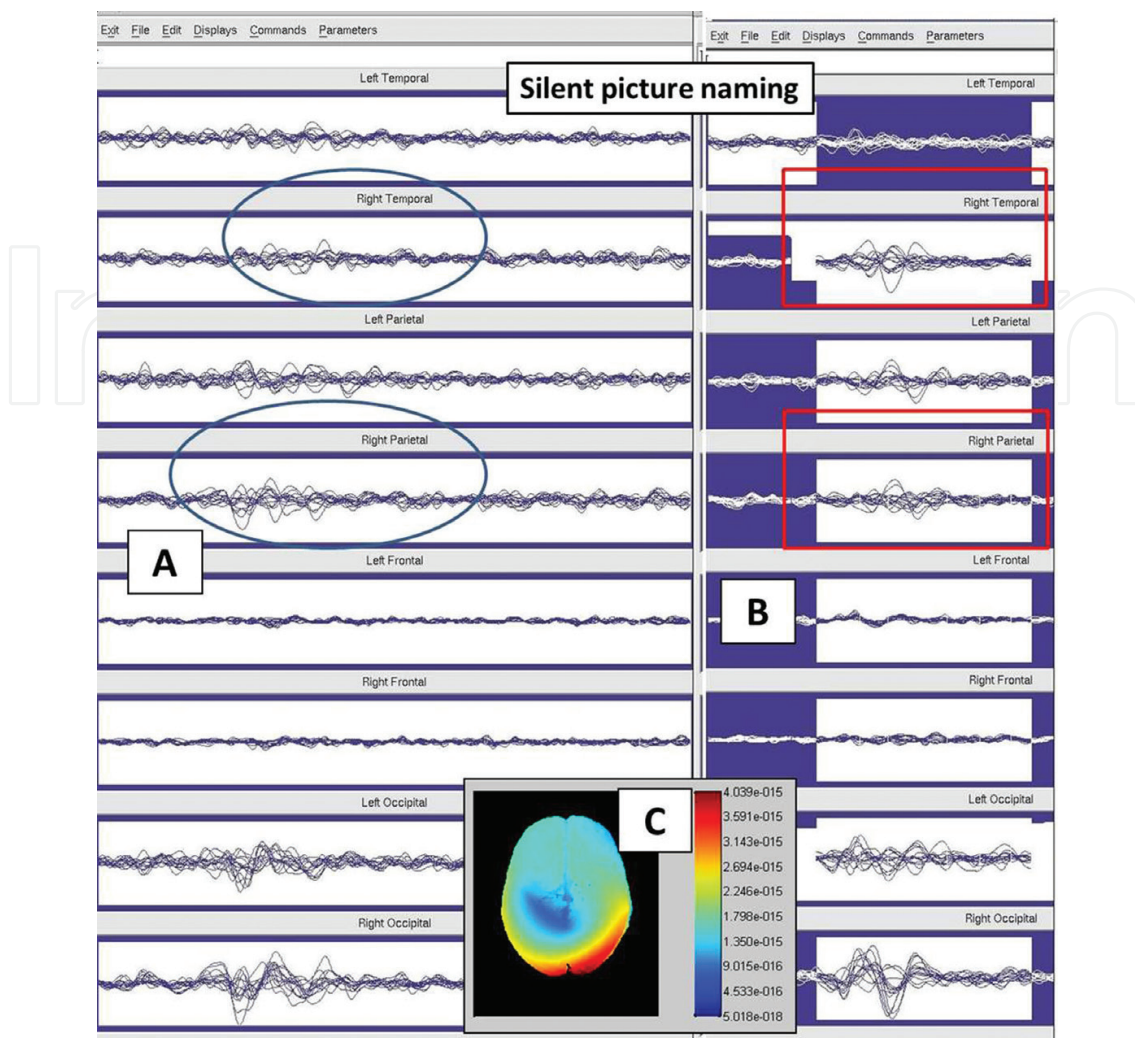


Figure 8. (A and B) Topographical brain lobe analysis for silent picture naming in two separate patients. The activities were also bilateral, but stronger activities were noted in the right temporal and parietal lobes (circles and rectangles). (C) Matlab-diffused underdetermined analysis confirmed the right shift.

is the dominant hemisphere for both auditory and visual functions. The genetic factor is the more likely explanation here as we had one patient with a mid-line lesion who underwent a hearing assessment and two patients with a right-sided lesion who had a visual assessment, and analysis of their data showed that either hemisphere could be a dominant hemisphere for auditory and visual functions. In addition, it is worth noting that there was only mild hemispheric specialization for both auditory and visual responses. In this respect, one cannot simply label auditory dominance based on the side of the ear that is commonly used for the telephone. This particular feature may arise because of the handedness of the person rather than the dominant character of auditory cortex. For cognitive-language brainwave responses, bilateral hemispheric responses were also noted. However, for silent word naming, there were more marked responses arising from the left frontal lobe in right-handed patients which suggest that silent word naming lateralizes to the dominant or left hemisphere. On the other hand, the brainwave study for silent picture naming in two right-handed subjects lateralized to the right hemisphere as there were more marked responses in the right parietal and temporal lobes. This indicates that hemispheric lateralization for visuospatial attention is in the right

hemisphere, which is in agreement with findings from other studies [46–48]. Although there has been progress in elucidating the neural basis of right hemispheric dominance for this function, there is little evidence supporting its origin. One theory considers right hemispheric specialization for certain tasks as a side-effect or overload of left hemisphere dominance for language, whereas another theory considers that this division of hemispheric specialization is a reflection of the genetic, biological or environmental conditions or a combination of these [35, 49]. In conclusion, both brain hemispheres are necessary to integrate information for cognition, sensorimotor and auditory-visual functions, but there is stronger lateralization or specialization (dominance) for sensorimotor and language functions and mild for auditory and visual specialization in one hemisphere. The need for information integration by bilateral hemispheres results in specialization (dominance or lateralization) of the hemisphere. This information-integration process in the form of brainwaves is accomplished by axonal connections between the two cerebral hemispheres which are well known as commissures. The largest of these is the corpus callosum (noteworthy that significant contribution can be made further by mathematicians in elucidating this integration process).

4. A review on corpus callosum, callosal surgery and commissures

The corpus callosum is a broad, transverse bundle of myelinated nerve fibres connecting the right and left cerebral hemispheres (**Figure 9A**). Anatomically, it is divided into the following five regions: rostrum, genu, body, isthmus and splenium. It has been suggested that such a connection and anatomical division are modality-specific; the anterior callosal fibres interconnecting the frontal lobes transfer motor information and the posterior fibres connecting the parietal, temporal and occipital lobes bilaterally are responsible for the integration of somatosensory (posterior mid-body), auditory (isthmus) and visual (splenium) information [50, 51]. Embryologically, the corpus callosum forms in an anterior to posterior direction with the genu forming first, followed by the body, isthmus (marked with a slight narrowing at the level where the fornix abuts the callosum), splenium and rostrum [51–54]. It develops from the upper segment of the telencephalic alar plate via the following four stages: (a) prosencephalic cleavage (28–35 days of gestation), (b) commissural plate formation (36–73 days of gestation), (c) corpus callosum formation (74–115 days of gestation) and (d) corpus callosum growth (after 115 days of gestation). During the prosencephalic cleavage period, the prosencephalon splits into the telencephalon and diencephalon. Subsequently, the single telencephalon leads to the formation of two telencephalic vesicles and a floor between them, which is called the lamina terminalis. During the commissural plate formation period, the lamina terminalis thickens and is called the lamina reuniens or commissural plate. The commissural plate continues to thicken, and by 73 days, the following four structures can be appreciated within it: (a) the site of the future corpus callosum, (b) area of the future anterior commissure, (c) hippocampal commissure and (d) septum cavum pellucidum. From 74 days onwards, the corpus callosum is formed from the crossed cortical axons through the area of the commissural plate. The axons from different regions of the brain cross at ‘different times’, resulting in different regions and functions of the corpus callosum (**Figure 9B**). In contrast to corpus callosum formation, the maturation and myelination process starts from the posterior to anterior [55, 56]. It begins to appear postnatally

in the splenium by approximately 4 months and in the genu by approximately 6 months. The corpus callosum has an adult appearance by approximately 8 months of age and continues to develop through the first two decades of life by a progressive increase in its size [57, 58]. These myelinated axons permit the fast propagation of neural impulses or waves that are considered prerequisites for normal cognitive, sensorimotor and auditory-visual functions. Indeed, abnormalities in the corpus callosum, especially those with associated brain anomalies and syndromic types of agenesis, are correlated with impairment in neurocognition, neurobehavioural, sensorimotor and auditory-visual functions [59–62]. These lines of suggestion indicate that the corpus callosum is a vital structure for cortical-cortical and interhemispheric connectivity, reflecting a computational requirement of interhemispheric coordination for normal behaviour, cognition, sensorimotor and auditory-visual functions.

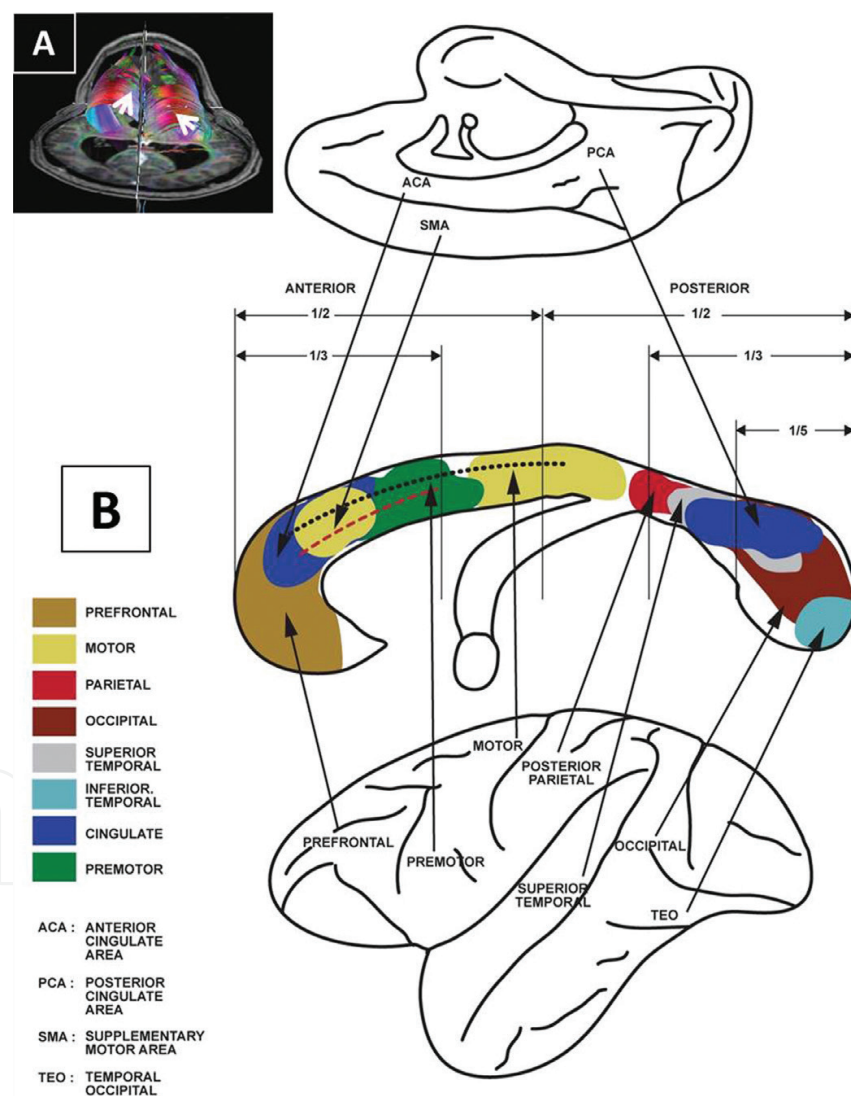


Figure 9. (A) Corpus callosum is a broad transverse bundle of myelinated nerve fibres, connecting the two cerebral hemispheres as shown here on the fibre tracking image (two white arrow heads). (B) Depicting crossing fibres from different regions of the brain passing through the corpus callosum and sites for surgical intervention: black dots—callosotomy site for refractory epileptic akinetic seizures—and red dashes—callosotomy for the surgical approach to lateral and third ventricles.

With respect to callosal surgery, it should be performed carefully, with adequate background knowledge on its anatomy and connectivity. The anterior interhemispheric transcallosal approach to the lateral and/or third ventricles should resect the anterior part alone, the rostral body and part of the genu, sparing the crossing motor fibres from the primary motor cortices in the anterior mid-body and, hence, avoiding motor complications [63] (**Figure 9B**). The posterior interhemispheric transcallosal approach is rarely used to reach the pineal region and posterior part of the third ventricle. This approach involves resection of the splenium, which may cause somatosensory, auditory, visual or emotional disturbances. Some patients may appear grossly intact and unchanged when observed by family and friends, but when specific neuropsychological tests are administered after the surgery, the deficits can be significant. Some examples of these deficits are verbal anosmia, double hemianopsia, poor processing of verbal information, apraxia or agraphia of the left hand. By contrast, resective callosotomy for intractable epilepsy due to severe, medically intractable seizures, where akinetic seizures or drop attacks are a predominant feature, will respond favourably to corpus callosum resection [64, 65]. Callosal division should be performed as described above. Resection can be extended further anteriorly until the rostrum, where the anterior commissure is an anterior limit and is best appreciated when seeing the two fornices converge together (**Figure 9B**). The resection should ideally be extended posteriorly to cover the anterior, two-thirds of the corpus callosum, especially in cases where the seizure outcome is unsatisfactory. This means that resection should include the motor fibres that run in the anterior and, possibly, part of the posterior mid-body, which carry the risk of permanent motor deficits. Hence, the posterior limit is more difficult to estimate and is commonly guided by the expected clinical outcomes (objective of the surgery), navigation system, thinning of the body (isthmus) and appearances of the fornices (the isthmus is the area where the fornix abuts the corpus callosum).

Other known commissures that cross the mid-line, connecting the two cerebral hemispheres, are the anterior, hippocampal or forniceal, habenular, posterior or epithalamic and supraoptic commissures [53, 54]. The anterior commissure can be found on either side, beneath the corpus striatum and in the substance of the temporal lobe. It connects the two amygdala and temporal lobes and contains decussating fibres from the olfactory tracts. It is part of the neospinothalamic tract for pain. The hippocampal or forniceal commissure is the second largest of the commissural connecting bundles that join the two crura of the fornix and connect the two hippocampi. Next is the habenular commissure, which is situated in front of the pineal gland and connects the habenular nuclei on both sides of the diencephalon. It has connections with the pineal and interpeduncular nuclei in the mid-brain. The second to last is the posterior commissure, which is a rounded band of white fibres crossing the mid-line on the dorsal aspect of the upper end of the cerebral aqueduct. It interconnects the pretectal nuclei and mediates the bilateral pupillary light reflex. Finally, the supraoptic commissure or decussation is the crossover within the optic pathway system, which interconnects the two eyes with the two visual cortices. Anatomical knowledge of these commissures, especially the anterior and posterior commissures, is commonly used in image fusion for deep brain stimulation surgery or radiosurgery. Currently, they are hardly implicated in resective surgery; however,

in future, they may be appropriate white matter targets for brain stimulation to modulate functions arising from certain part of both hemispheres.

5. Concept of death related to brainwaves

Once knowing the origin for the brainwaves (deep brain area), cortical functions and its fast hemispheric transfer of information (superficial brain area), perhaps then, the concept of death would easily be understood. If someone cut off his 'leg or hand or mouth or face, he shall not die', but if someone injured the core or deep area of the brain (the seat of soul area), or the cardiopulmonary system, death is likely. Therefore, death seems to be associated with two main human organs—the brain and the heart. Based on this, there are two types of deaths: (a) cardiac or circulatory death and (b) brain death. It seems that in both types of deaths, the anatomical region that concerns the brainwave origin or the greater limbic system is notably involved [66–68].

Brain death is associated with cessation of all brain functions. All points related to brain death are essentially documenting dysfunction in the greater limbic system (or the seat of soul area), such as: (a) conscious level, (b) autonomic disturbances, (c) absent brainstem reflexes, (d) flattened cortical brainwaves (bihemispheric dysfunction) and (e) disturbance in vital signs (noteworthy that these vital signs such as respiration, heart rate and blood pressure can be preserved by ventilatory support and medications in brain death). A dysfunction in anatomical region that controls brainwave rhythm would finally cause flattened cortical brainwaves. This may indirectly signify that cortical brainwaves have originated from deep structures inside the brain (the greater limbic system), and brain functions have indeed originated deep within the centre of the brain, involving anatomical areas that have vast networks with the cortices. On the other hand, for cardiac death, the cardiopulmonary system stops functioning and hence after few minutes (3–5 min), the brain also starts to stop functioning. This type of death is what most lay people think of when they think about the definition of death. Therefore, in documenting cardiac death, the person's pupils are commonly noted as fixed and dilated, and the vital signs (wavy items such as heart rate, blood pressure, respiration) are absent. Therefore, what seems initially as cardiac death is in fact related to the death of the brain too. All these indirectly denote that the brain is superior than the heart, and the seat (centre) of human soul likely resides in the brain at the greater limbic area; it may not be the observable anatomical structures in this area per se but instead is an 'unseen' element at this particular deep-centred anatomical area (noteworthy that the initial historical discussions on humans' seat of the soul and the greater limbic system are mainly meant for death status and unique human behaviour). In conclusion, five points are worth being emphasized and they are: (a) the brain seems superior than the heart because of the following reasons: (i) the status of the brain function is the most important in determining death of a person, (ii) vital signs of the cardiopulmonary system such as heart rate, blood pressure and respiration (wavy items) can be supported by a machine and medications, (iii) in contrast to point (ii) above, the flattened brainwaves seem unlikely reversible to wavy brainwaves in a dead person, and,

perhaps, no machine might be able to cause reappearance of 'persistent wavy' brainwaves in a dead person, (b) waves (ups and downs, downs and ups, right-left, left-right oscillations) may be 'indirect' manifestations of the soul; once dead, all waves are flattened and finally all atoms stop oscillating (non-wavy), and physical dimension starts to disappear. Remember that atoms can behave either as particles or waves. The phenomenon is known as wave-particle duality for an atom [69, 70], (c) brainwaves can be regarded as a way to 'visualize thought' as 'images'; therefore, more studies are needed to correlate brainwaves with brain anatomy, and, indeed, advanced technology is obviously needed to enable scientists examining the deep brainwaves non-invasively and correlating them with cortical (superficial) brainwaves, brain anatomy and functions, (d) all are waves (ups and downs, energy, life, the will to live, an indirect manifestation of soul or all is the soul) and finally (e) studies on waves, oscillations, frequency and physiology (even anatomy, simply because atoms can also behave as waves) could in fact be studies related to the soul.

6. Conclusions

This chapter stresses that the central nervous system could indeed lie in the microgravity environment. The importance of this notion includes studying the brain, brain cells or tissues or, specifically, the neural stem cells in a buoyant environment. The microgravity environment of CNS has also caused bending to occur at the mid-brain level involving a set of deep anatomical structures that lie 'close to the ventricles' and link to various brain functions, including control of consciousness and memory, and even are related to death. Noteworthy that this deep brain area also seems to regulate cortical brainwave rhythms and has close connectivity with two brain hemispheres. This bilateral hemispheric connectivity was studied on 13 clinical patients' brainwaves. Bilateral hemispheric brainwave responses were observed in tasks that were related to cognition for language, sensorimotor and auditory-visual functions. Topographical or brain lobe MEG wave representations and Matlab-SPM and BESA-based brainwave spectral analysis revealed that each task has a hemispheric specialization or lateralization, which suggests that there is fast brainwave information transfer between the two brain hemispheres via the commissural system as well as an efficient information integration system in each brain hemisphere. Therefore, one may view that cortical brain functions could have originated deep and within the centre of the brain. With advancement in neurotechnology, we hope that our hypotheses, clinical findings and conclusions drawn from this chapter may form the basis to study further the deep anatomical brain structures in relation to brain functions, neurocognitions and the seat of human soul.

Acknowledgements

The content of this chapter is partially obtained from study data using short-term grant (ref: 304/PPSP/61312142 from Universiti Sains Malaysia (USM)) and is approved by Human Research Ethics Committee, School of Medical Sciences, USM, Kubang Kerian, Kelantan, Malaysia.

Author details

Zamzuri Idris^{1,2*}, Faruque Reza² and Jafri Malin Abdullah^{1,2}

*Address all correspondence to: neuroscienceszamzuri@yahoo.com

1 Center for Neuroscience Service and Research, School of Medical Sciences, Universiti Sains Malaysia, Kelantan, Malaysia

2 Department of Neurosciences, School of Medical Sciences, Universiti Sains Malaysia, Kelantan, Malaysia

References

- [1] Hartmann P, Ramseier A, Gudat F, Mihatsch MJ, Polasek W. Normal weight of the brain in adults in relation to age, sex, body height and weight. *Der Pathologe*. 1994;**15**(3):165-170.
- [2] Noback CNL, Robert JD, David AR. The human nervous system: structure and function. Humana Press, New Jersey: ISBN-13: 978-1588290403.
- [3] Idris Z, Mustapha M, Abdullah JM. Microgravity environment and compensatory: decompensatory phases for intracranial hypertension form new perspectives to explain mechanism underlying communicating hydrocephalus and its related disorders. *Asian J Neurosurg*. 2014;**9**(1):7-13.
- [4] Idris Z, Muzaimi M, Ghani RI, Idris B, Kandasamy R, Abdullah JM. Principles, anatomical origin and applications of brainwaves: a review, our experience and hypothesis related to microgravity and the question on soul. *J Biomed Sci Eng*. 2014;**7**(8):11.
- [5] Idris Z. Searching for the origin through central nervous system: areview and thought which related to microgravity, evolution, big bang theory and universes, soul and brain-waves, greater limbic system and seat of the soul. *Malays J Med Sci*. 2014;**21**(4):4-11.
- [6] Liu PC, Liu K, Liu JF, Xia K, Chen LY, Wu X. Transfection of the IHH gene into rabbit BMSCs in a simulated microgravity environment promotes chondrogenic differentiation and inhibits cartilage aging. *Oncotarget*. 2016;**7**(39):62873-85.
- [7] Meigal AY. Synergistic action of gravity and temperature on the motor system within the lifespan: a "baby astronaut" hypothesis. *Med Hypotheses*. 2013;**80**(3):275-283.
- [8] Chen J, Liu R, Yang Y, Li J, Zhang X, Wang Z, et al. The simulated microgravity enhances the differentiation of mesenchymal stem cells into neurons. *Neurosci Lett*. 2011;**505**(2):171-175.
- [9] Coghill RC, Gilron I, Iadarola MJ. Hemispheric lateralization of somatosensory processing. *J Neurophysiol*. 2001;**85**(6):2602-2612.
- [10] Gandour J, Tong Y, Wong D, Talavage T, Dziedzic M, Xu Y, et al. Hemispheric roles in the perception of speech prosody. *NeuroImage*. 2004;**23**(1):344-357.

- [11] Guidotti R, Del Gratta C, Baldassarre A, Romani GL, Corbetta M. Visual learning induces changes in resting-state fMRI multivariate pattern of information. *J Neurosci*. 2015;**35**(27): 9786-9798.
- [12] Mehta JP, Verber MD, Wieser JA, Schmit BD, Schindler-Ivens SM. The effect of movement rate and complexity on functional magnetic resonance signal change during pedaling. *Motor Control*. 2012;**16**(2):158-175.
- [13] Mohades SG, Struys E, Van Schuerbeek P, Baeken C, Van De Craen P, Luypaert R. Age of second language acquisition affects nonverbal conflict processing in children: an fMRI study. *Brain Behav*. 2014;**4**(5):626-642.
- [14] Zhang Y, Wang T, Huang P, Li D, Qiu J, Shen T, et al. Free language selection in the bilingual brain: an event-related fMRI study. *Sci Rep*. 2015;**5**:11704.
- [15] Santoro G, Wood MD, Merlo L, Anastasi GP, Tomasello F, Germano A. The anatomic location of the soul from the heart, through the brain, to the whole body, and beyond: a journey through Western history, science, and philosophy. *Neurosurgery*. 2009;**65**(4):633-643; discussion 43.
- [16] Dolan B. Soul searching: a brief history of the mind/body debate in the neurosciences. *Neurosurg Focus*. 2007;**23**(1):E2.
- [17] Nieuwenhuys R, Veening JG, van Domburg P. Core and paracores; some new che-moarchitectural entities in the mammalian neuraxis. *Acta Morphol Neerlando-Scand*. 1988;**26**(2-3):131-163.
- [18] Nieuwenhuys R, Voogd J, Van Huijzen C. Greater limbic system. In *The human central nervous system* (4th ed.). Wurzberg, Berlin and Heidelberg: Springer-Verlag; 2008. pp. 917-946.
- [19] Gadde J, Dross P, Spina M. Syndrome of the trephined (sinking skin flap syndrome) with and without paradoxical herniation: a series of case reports and review. *Delaware Med J*. 2012;**84**(7):213-218.
- [20] Mohammadi A, Ahmadian A, Azar AD, Sheykh AD, Amiri F, Alirezaie J. Estimation of intraoperative brain shift by combination of stereovision and doppler ultrasound: phantom and animal model study. *Int J Comput Assist Radiol Surg*. 2015;**10**(11):1753-1764.
- [21] Ji S, Fan X, Roberts DW, Hartov A, Paulsen KD. Cortical surface shift estimation using stereovision and optical flow motion tracking via projection image registration. *Med Image Anal*. 2014;**18**(7):1169-1183.
- [22] Wang N, Wang H, Chen J, Zhang X, Xie J, Li Z, et al. The simulated microgravity enhances multipotential differentiation capacity of bone marrow mesenchymal stem cells. *Cytotechnology*. 2014;**66**(1):119-131.
- [23] Magoun HW. An ascending reticular activating system in the brain stem. *AMA Arch Neurol Psychol*. 1952;**67**(2):145-154; discussion 67-71.

- [24] Leon Dănilă and Mihail Lucian Pascu (2013). Contributions to the Understanding of the Neural Bases of the Consciousness, Clinical Management and Evolving Novel Therapeutic Strategies for Patients with Brain Tumors, Dr. Terry Lichtor (Ed.), Rijeka Croatia: InTech, doi: 10.5772/52688. Available from: <http://www.intechopen.com/books/clinical-management-and-evolving-novel-therapeutic-strategies-for-patients-with-brain-tumors/contributions-to-the-understanding-of-the-neural-bases-of-the-consciousness>
- [25] Englot DJ, Hassnain KH, Rolston JD, Harward SC, Sinha SR, Haglund MM. Quality-of-life metrics with vagus nerve stimulation for epilepsy from provider survey data. *Epilepsy Behav.* 2016;**66**:4-9.
- [26] Hulsey DR, Riley JR, Loerwald KW, Rennaker RL, Kilgard MP, Hays SA. Parametric characterization of neural activity in the locus coeruleus in response to vagus nerve stimulation. *Exp Neurol.* 2016;**289**:21-30.
- [27] Bartolomei F, Bonini F, Vidal E, Trebuchon A, Lagarde S, Lambert I, et al. How does vagal nerve stimulation (VNS) change EEG brain functional connectivity? *Epilepsy Res.* 2016;**126**:141-146.
- [28] Idris Z, Kandasamy R, Reza F, Abdullah JM. Neural oscillation, network, eloquent cortex and epileptogenic zone revealed by magnetoencephalography and awake craniotomy. *Asian J Neurosurg.* 2014;**9**(3):144-152.
- [29] Allen P, Modinos G, Hubl D, Shields G, Cachia A, Jardri R, et al. Neuroimaging auditory hallucinations in schizophrenia: from neuroanatomy to neurochemistry and beyond. *Schizophrenia Bull.* 2012;**38**(4):695-703.
- [30] Bingel U, Quante M, Knab R, Bromm B, Weiller C, Buchel C. Single trial fMRI reveals significant contralateral bias in responses to laser pain within thalamus and somatosensory cortices. *NeuroImage.* 2003;**18**(3):740-748.
- [31] Shergill SS, Brammer MJ, Williams SC, Murray RM, McGuire PK. Mapping auditory hallucinations in schizophrenia using functional magnetic resonance imaging. *Arch Gen Psychol.* 2000;**57**(11):1033-1038.
- [32] Silbersweig DA, Stern E, Frith C, Cahill C, Holmes A, Grooten S, et al. A functional neuroanatomy of hallucinations in schizophrenia. *Nature.* 1995;**378**(6553):176-179.
- [33] Okada YC, Wu J, Kyuhou S. Genesis of MEG signals in a mammalian CNS structure. *Electroencephalogr Clin Neurophysiol.* 1997;**103**(4):474-485.
- [34] Dronkers NF, Plaisant O, Iba-Zizen MT, Cabanis EA. Paul Broca's historic cases: high resolution MR imaging of the brains of Leborgne and Lelong. *Brain.* 2007;**130**(Pt 5):1432-1441.
- [35] Herve PY, Zago L, Petit L, Mazoyer B, Tzourio-Mazoyer N. Revisiting human hemispheric specialization with neuroimaging. *Trends Cogn Sci.* 2013;**17**(2):69-80.
- [36] Buchel C, Raedler T, Sommer M, Sach M, Weiller C, Koch MA. White matter asymmetry in the human brain: a diffusion tensor MRI study. *Cereb Cortex.* 2004;**14**(9):945-951.

- [37] James JS, Kumari SR, Sreedharan RM, Thomas B, Radhkrishnan A, Kesavadas C. Analyzing functional, structural, and anatomical correlation of hemispheric language lateralization in healthy subjects using functional MRI, diffusion tensor imaging, and voxel-based morphometry. *Neurol India*. 2015;**63**(1):49-57.
- [38] Takao H, Abe O, Yamasue H, Aoki S, Sasaki H, Kasai K, et al. Gray and white matter asymmetries in healthy individuals aged 21-29 years: a voxel-based morphometry and diffusion tensor imaging study. *Human Brain Map*. 2011;**32**(10):1762-1773.
- [39] Vernooij MW, Smits M, Wielopolski PA, Houston GC, Krestin GP, van der Lugt A. Fiber density asymmetry of the arcuate fasciculus in relation to functional hemispheric language lateralization in both right- and left-handed healthy subjects: a combined fMRI and DTI study. *NeuroImage*. 2007;**35**(3):1064-1076.
- [40] Fiori S, Staudt M, Pannek K, Borghetti D, Biagi L, Scelfo D, et al. Is one motor cortex enough for two hands? *Dev Med Child Neurol*. 2015. Oct;**57**(10):977-80. doi: 10.1111/dmcn.12817. Epub 2015 Jun 22.
- [41] Geven LI, de Kleine E, Willemsen AT, van Dijk P. Asymmetry in primary auditory cortex activity in tinnitus patients and controls. *Neuroscience*. 2014;**256**:117-125.
- [42] Kam JW, Nagamatsu LS, Handy TC. Visual asymmetry revisited: mind wandering preferentially disrupts processing in the left visual field. *Brain Cogn*. 2014;**92C**:32-38.
- [43] Kim YH, Jang SH, Han BS, Kwon YH, You SH, Byun WM, et al. Ipsilateral motor pathway confirmed by diffusion tensor tractography in a patient with schizencephaly. *Neuroreport*. 2004;**15**(12):1899-1902.
- [44] Mutha PK, Haaland KY, Sainburg RL. Rethinking motor lateralization: specialized but complementary mechanisms for motor control of each arm. *PLoS One*. 2013;**8**(3):e58582.
- [45] Rangarajan V, Hermes D, Foster BL, Weiner KS, Jacques C, Grill-Spector K, et al. Electrical stimulation of the left and right human fusiform gyrus causes different effects in conscious face perception. *J Neurosci*. 2014;**34**(38):12828-12836.
- [46] Asanowicz D, Smigasiewicz K, Verleger R. Differences between visual hemifields in identifying rapidly presented target stimuli: letters and digits, faces, and shapes. *Front Psychol*. 2013;**4**:452.
- [47] Hori T, Kawamata T, Amano K, Aihara Y, Ono M, Miki N. Anterior interhemispheric approach for 100 tumors in and around the anterior third ventricle. *Neurosurgery*. 2010;**66**(3 Suppl Operative):65-74.
- [48] Verleger R, Sprenger A, Gebauer S, Fritzmannova M, Friedrich M, Kraft S, et al. On why left events are the right ones: neural mechanisms underlying the left-hemifield advantage in rapid serial visual presentation. *J Cogn Neurosci*. 2009;**21**(3):474-488.
- [49] Jung-Beeman M. Bilateral brain processes for comprehending natural language. *Trends Cogn Sci*. 2005;**9**(11):512-518.

- [50] Fabri M, Pierpaoli C, Barbaresi P, Polonara G. Functional topography of the corpus callosum investigated by DTI and fMRI. *World J Radiol.* 2014;**6**(12):895-906.
- [51] Fabri M, Polonara G. Functional topography of human corpus callosum: an FMRI mapping study. *Neural Plast.* 2013;**2013**:251308.
- [52] Rakic P, Yakovlev PI. Development of the corpus callosum and cavum septi in man. *J Comp Neurol.* 1968;**132**(1):45-72.
- [53] Raybaud C. The corpus callosum, the other great forebrain commissures, and the septum pellucidum: anatomy, development, and malformation. *Neuroradiology.* 2010;**52**(6):447-477.
- [54] Suarez R, Gobius I, Richards LJ. Evolution and development of interhemispheric connections in the vertebrate forebrain. *Front Human Neurosci.* 2014;**8**:497.
- [55] Deoni SC, Mercure E, Blasi A, Gasston D, Thomson A, Johnson M, et al. Mapping infant brain myelination with magnetic resonance imaging. *J Neurosci.* 2011;**31**(2):784-791.
- [56] Provenzale JM, Isaacson J, Chen S. Progression of corpus callosum diffusion-tensor imaging values during a period of signal changes consistent with myelination. *Am J Roentgenol.* 2012;**198**(6):1403-1408.
- [57] Rauch RA, Jenkins JR. Analysis of cross-sectional area measurements of the corpus callosum adjusted for brain size in male and female subjects from childhood to adulthood. *Behav Brain Res.* 1994;**64**(1-2):65-78.
- [58] Barkovich AJ, Kjos BO. Normal postnatal development of the corpus callosum as demonstrated by MR imaging. *Am J Neuroradiol.* 1988;**9**(3):487-491.
- [59] Genc E, Ocklenburg S, Singer W, Gunturkun O. Abnormal interhemispheric motor interactions in patients with callosal agenesis. *Behav Brain Res.* 2015. Oct 15;**293**:1-9. doi: 10.1016/j.bbr.2015.07.016. Epub 2015 Jul 14.
- [60] Hasegawa T, Yamada K, Morimoto M, Morioka S, Tozawa T, Isoda K, et al. Development of corpus callosum in preterm infants is affected by the prematurity: in vivo assessment of diffusion tensor imaging at term-equivalent age. *Pediatr Res.* 2011;**69**(3):249-254.
- [61] Mathew P, Pannek K, Snow P, D'Acunto MG, Guzzetta A, Rose SE, et al. Maturation of corpus callosum anterior midbody is associated with neonatal motor function in eight preterm-born infants. *Neural Plast.* 2013;**2013**:359532.
- [62] Sztriha L. Spectrum of corpus callosum agenesis. *Pediatr Neurol.* 2005;**32**(2):94-101.
- [63] Shiramizu H, Hori T, Matsuo S, Niimura K, Yoshimoto H, Ishida A, et al. Anterior callosal section is useful for the removal of large tumors invading the dorsal part of the anterior third ventricle: operative technique and results. *Neurosurg Rev.* 2013;**36**(3):467-475.
- [64] Jenssen S, Sperling MR, Tracy JJ, Nei M, Joyce L, David G, et al. Corpus callosotomy in refractory idiopathic generalized epilepsy. *Seizure.* 2006;**15**(8):621-629.

- [65] Kasasbeh AS, Smyth MD, Steger-May K, Jalilian L, Bertrand M, Limbrick DD. Outcomes after anterior or complete corpus callosotomy in children. *Neurosurgery*. 2014;**74**(1):17-28; discussion.
- [66] Goila AK, Pawar M. The diagnosis of brain death. *Indian J Crit Care Med*. 2009;**13**(1):7-11.
- [67] De Georgia MA. History of brain death as death: 1968 to the present. *J Crit Care*. 2014;**29**(4):673-678.
- [68] Fishman GI, Chugh SS, Dimarco JP, Albert CM, Anderson ME, Bonow RO, et al. Sudden cardiac death prediction and prevention: report from a National Heart, Lung, and Blood Institute and Heart Rhythm Society Workshop. *Circulation*. 2010;**122**(22):2335-2348.
- [69] Arndt M, Nairz O, Vos-Andreae J, Keller C, van der Zouw G, Zeilinger A. Wave-particle duality of C(60) molecules. *Nature*. 1999;**401**(6754):680-682.
- [70] Gerlich S, Eibenberger S, Tomandl M, Nimmrichter S, Hornberger K, Fagan PJ, et al. Quantum interference of large organic molecules. *Nat Commun*. 2011;**2**:263.