

# We are IntechOpen, the world's leading publisher of Open Access books Built by scientists, for scientists

6,900

Open access books available

186,000

International authors and editors

200M

Downloads

Our authors are among the

154

Countries delivered to

TOP 1%

most cited scientists

12.2%

Contributors from top 500 universities



WEB OF SCIENCE™

Selection of our books indexed in the Book Citation Index  
in Web of Science™ Core Collection (BKCI)

Interested in publishing with us?  
Contact [book.department@intechopen.com](mailto:book.department@intechopen.com)

Numbers displayed above are based on latest data collected.  
For more information visit [www.intechopen.com](http://www.intechopen.com)



---

# Collaboration between Interventional Cardiologists and Cardiac Surgeons in the Era of Heart Team

## Approach

---

Takashi Murashita

Additional information is available at the end of the chapter

<http://dx.doi.org/10.5772/67788>

---

### Abstract

Along with the rapid evolution of transcatheter interventions, interventional cardiologists are playing more and more important role in the care of cardiovascular disease. The consequence of rapid change in the landscape has been fostering new and improved relationships between interventional cardiologists and cardiac surgeons and the formulation of Heart Team to facilitate patient management. A hybrid strategy is a combination of tools available only in the catheterization laboratory with those available only in the operative room in order to gain maximum profit from both of them. In the current era, the continuous development in transcatheter procedures along with the adoption of minimally invasive surgical approaches makes hybrid strategy an attractive alternative to conventional surgical or transcatheter techniques for any given set of cardiovascular diseases. In the areas of coronary revascularization, valve repair or replacement, and ablation for atrial fibrillation, hybrid approaches have shown great benefit especially in high-risk cases. With the technological evolutions in the treatment of cardiovascular disease, the Heart Team approach utilizing the expertise of all relevant specialties will be more and more invaluable in facilitating optimal patient selection, procedural planning, complication management, postprocedural care, and patient outcomes.

**Keywords:** interventional cardiologist, cardiac surgeon, hybrid, heart team

---

## 1. Introduction

A hybrid approach combines the treatments traditionally available only in the catheterization laboratory with those traditionally available only in the operative room in order to obtain maximum benefit from both procedures. The continuous evolution of transcatheter technology

along with the adoption of minimally invasive surgical approaches make hybrid procedures an attractive alternative to conventional surgical or interventional techniques for a wide variety of cardiovascular diseases [1–3]. Angelini et al. reported the first case series of hybrid coronary artery revascularization in 1996 [4]. Since then, along with technological advancement, hybrid procedures are currently applied not only for coronary artery disease, but also for valvular heart disease, arrhythmia, congenital heart disease, aortic diseases, and peripheral vascular disease.

As a result of rapid evolution of transcatheter techniques, interventional cardiologists are playing a central role in the management of cardiovascular diseases. For a success of hybrid approach, a formulation of Heart Team combined with good collaboration between interventional cardiologists and cardiac surgeons is encouraged to facilitate patient management. The indications and patient selection for hybrid procedures need to be well discussed in Heart Team.

## **2. Hybrid coronary revascularization (HCR)**

### **2.1. Rationale of HCR**

Despite the increasing use of percutaneous coronary intervention (PCI) for coronary artery disease during the past decade [5], coronary artery bypass grafting (CABG) remains the gold standard for multivessel coronary artery disease or left main disease [6]. A number of major trials such as SYNTAX [7], ASCERT [8], and FREEDOM [9] reported superior long-term survival rates of CABG compared with PCI.

The main factor of the superiority of CABG over PCI is the use of left internal mammary artery (LIMA) to left anterior descending (LAD) artery [10, 11]. The excellent long-term patency of LIMA to LAD graft has been established [12–14], whereas the long-term outcomes of other conduits such as saphenous vein graft and radial artery have been reported to be poorer than those of LIMA. The patency rates of saphenous vein grafts were 71–87% at 1-year after surgery in previous studies [15–17], and up to 50% at 10-years [15–19].

On the other hand, newer generation of drug-eluted stents are associated with fewer restenosis and repeat revascularization compared to conventional bare metal stents [20], and are associated with similar or even better long-term patency rates than saphenous vein grafts [11, 17, 21–23]. Thus, the combination of LIMA-LAD bypass and PCI using new generation of drug-eluting stents to non-LAD lesions takes the advantage of both procedures. The rationale of HCR is to combine the survival benefit and high patency rates of LIMA graft with the lower restenosis rates of new generation drug-eluting stents for non-LAD lesions [11, 24, 25].

### **2.2. Indications of HCR**

HCR is applicable in patients having multivessel coronary artery disease with CABG-suitable LAD disease and PCI-suitable non-LAD disease [1, 11, 26–28]. HCR takes the most advantage in patients with comorbidities such as diabetes mellitus, obesity, chronic kidney disease, chronic occlusive pulmonary disease, and advanced age [11, 28], because these comorbidities are known to increase the risk of conventional CABG.

On the other hand, there is a couple of situations where HCR is not suitable, such as left subclavian artery stenosis, nonusable LIMA graft due to prior radiation to the left chest, intramyocardial LAD, previous stent to the target lesions, and extensive calcification on LAD [27, 29].

American guidelines for HCR demonstrate that HCR is reasonable in patients with one or more of the following: limitations to traditional CABG, such as heavily calcified proximal aorta or poor target vessels for CABG but amenable to PCI; lack of suitable graft conduits; unfavorable LAD for PCI such as excessive vessel tortuosity or chronic total occlusion with Class IIa recommendation with level of evidence of B. Also, HCR may be reasonable as an alternative to multivessel PCI or CABG in an attempt to improve the overall risk-benefit ratio of the procedures with Class IIb recommendation with level of evidence of C [3].

### 2.3. Techniques of HCR

Several techniques have been reported for achieving minimally invasive CABG [1]. Thoracoscopic endoscopic CABG; LIMA graft is harvested with the use of thoracoscopy through a port-access approach. The LIMA-to-LAD anastomosis is then performed by hand on the beating heart using specially designed stabilizers and retractors [2]. Robotically assisted CABG; LIMA graft is harvested with an assistance of robot followed by a hand-sewn LIMA-to-LAD anastomosis on the beating heart [3]. Totally endoscopic CABG, LIMA harvest and the anastomosis are performed endoscopically with the robot. The anastomosis can be performed on the beating heart or on cardiopulmonary bypass on an arrested heart.

HCR can be performed either as a one-staged or a two-staged procedure. A two-staged procedure is defined as a PCI and CABG performed separately by hours or days. A one-staged HCR is defined as PCI and CABG performed in a hybrid-operating room in one operative setting. The advantages of one-staged HCR include complete revascularization with minimal patient discomfort, intraoperative confirmation of LIMA-to-LAD anastomosis, and easy conversion to conventional CABG if needed [29]. However, bleeding concerns due to dual antiplatelet therapy and incomplete heparin reversal, as well as acute stent thrombosis possibility are disadvantages of one-staged HCR [11].

In a two-staged approach, there is a concern of adverse coronary events between the procedures because patients are incompletely revascularized. When PCI is preceded, CABG needs to be performed under the effect of dual antiplatelet therapy, which leads to significant bleeding risk. On the other hand, when CABG is preceded, PCI can be performed under the protection of the LIMA-to-LAD graft and the ability to verify the patency of the LIMA-to-LAD graft while avoiding the risk of bleeding due to dual antiplatelet therapy. Therefore, CABG-first strategy for two-staged HCR is preferable.

### 2.4. Outcomes of HCR

The surgical outcomes of previous studies regarding HCR are summarized in **Table 1**. The 30-day mortality after HCR ranged from 0 to 2.4%. LIMA patency is reported to be over 90%. The event-free survival rate ranged from 83 to 100%, whereas the incidence of major adverse cardiac and cerebrovascular events (MACCEs) ranged from 0 to 12.2%. However, the sample size of each study was relatively small.

Study	Year	Number of pts	Follow-up (months)	30-day mortality (%)	MACCE (%)	Event-free survival (%)
Angelini et al. [4]	1996	6	–	0	–	89
Leacche et al. [25]	2013	80	1	–	2.5	91
Rab et al. [53]	2012	22	38.8 ± 22	0	0	95
Lewis et al. [54]	1999	14	1.44	0	–	93
Isomura et al. [55]	2000	37	24	1.4	–	92
Presbitero et al. [56]	2001	42	18	2.4	12.2	83
Lee et al. [57]	2004	6	12	0	0	–
Repossini et al. [58]	2013	166	64.6 ± 12.0	1.2	12	83 (at 5 years)
Gilard et al. [59]	2007	70	33	1.4	–	97
Kon et al. [60]	2008	15	12	0	–	93
Vassiliades et al. [61]	2006	47	7	0	–	90
Bonatti et al. [62]	2008	5	6	0	–	100

*Note:* MACCE; major adverse cardiac and cerebrovascular events.

**Table 1.** Outcomes of hybrid coronary revascularization.

Zhu et al. performed a meta-analysis to compare the short-term outcomes of HCR with those of CABG for multivessel coronary artery disease. They found that HCR was noninferior to CABG in terms of the incidence of death, myocardial infarction, stroke, and renal failure, whereas HCR was associated with less blood transfusion and shorter length of stay in hospital [30]. Halkos et al. compared the outcomes of 147 HCR cases with matched off-pump CABG cases. They reported 5-year survival rate and the incidence of MACCE were similar between HCR and off-pump CABG, whereas the need for repeated revascularization was higher in HCR group [31].

3. Transcatheter treatment for aortic valve disease

For the treatment of severe symptomatic aortic stenosis, surgical aortic valve replacement has been the gold standard. The advent and rapidly widespread adoption of transcatheter aortic valve replacement (TAVR) has now resulted in it becoming the option for patients who would have been considered inoperable or prohibitively high surgical risk [32]. Excellent mid-term

and long-term outcomes after TAVR have been reported [33, 34], and indications of TAVR are expanding to severe aortic valve regurgitation associated with moderate aortic valve stenosis and valve-in-valve procedures for surgical bioprosthetic valve failure.

TAVR procedures are now shifting to percutaneous approach and even general anesthesia is not mandatory. The percutaneous transfemoral route is the preferred approach in the majority of the cases due to its associated advantages [35]. Although some centers reported that transapical and transfemoral approach resulted in the similar outcomes [36], transapical approach is usually associated with poorer outcomes than transfemoral approach [37]. Interventional cardiologists possess the required skills for transfemoral TAVR including the handling of guidewires, catheters, and image selection. They can even take care of technical complications associated with TAVR, such as coronary obstruction and conduction disturbance by performing PCI or implanting pacemaker. Although interventional cardiologists can take a lead in TAVR procedures, surgeons still play an important role in managing life-threatening complications such as aortic root rupture, cardiac tamponade, and vascular complications. Those complications cannot be managed percutaneously and surgical interventions are the only viable rescue option. Furthermore, surgeons have the skill to ensure procedural success in patients whom transfemoral approach is not applicable. For the success of transapical and transaortic TAVR procedures, surgeons play a crucial role and they should be familiar with individual cases and technical aspects.

Postprocedural care and rehabilitation are undoubtedly important in optimizing functional status and clinical outcomes [38]. Cardiologists can take the leading role in this area by virtue of familiarity with all aspects of general cardiology issues such as heart failure and arrhythmia in the management of these complex patients.

In conclusion, a good collaboration between interventional cardiologists and cardiac surgeons and formulation of a Heart Team is essential for the success of TAVR. The decision making for patients selection and surgical approach, the actual performance of procedure in the operating room, and postoperative care should be performed by a Heart Team approach [39].

## **4. Transcatheter treatment for mitral valve disease**

### **4.1. Transcatheter mitral valve repair**

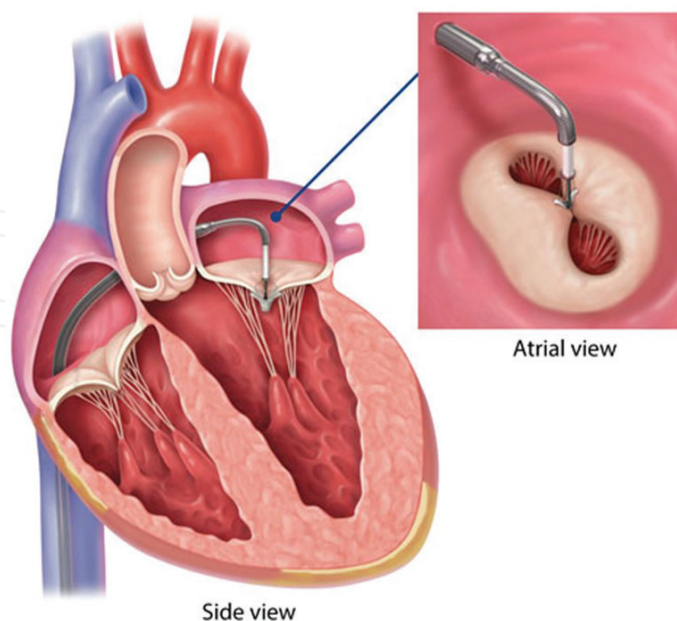
The prevalence of mitral regurgitation is higher than other valvular heart diseases [40, 41]. Surgical mitral repair remains the gold standard for patients with primary mitral regurgitation. However, there are a growing number of patients with mitral regurgitation underserved by surgical therapy due to prohibitive surgical risks. The recent development of transcatheter mitral valve technique provides an additional therapeutic option for some high-risk and inoperable patients [42, 43]. The optimal way to adjudicate innovative surgical and interventional mitral therapies is through a robust collaboration within a well-functioning Heart Team which includes not only cardiac surgeons and interventional cardiologists but also imaging specialists.



The current leader in the field of transcatheter mitral repair device is the MitraClip (Abbott Vascular, Santa Clara, CA). This device is delivered in an antegrade transseptal approach across the atrial septum from the femoral vein to achieve an edge-to-edge direct leaflet approximation (**Figure 1**). More than 30,000 patients worldwide have been treated with this procedure to date. In the United States, a Society of Thoracic Surgeons (STS)/American College of Cardiology database analysis of the first 564 cases performed through August 2014 showed the average patient age was 83 years, with a median STS predicted risk of mortality for mitral valve repair and replacement of 7.9 and 10.0%, respectively. The majority of the patients had prohibitive surgical risks such as severe frailty, prior cardiac surgery, and end-stage heart failure. The procedural success rate was 91.8% with a 30-day operative mortality of 5.8% [43].

The randomized EVEREST II trial showed that the need for surgery for residual mitral regurgitation was significantly higher in patients who received MitraClip compared with those who underwent surgery at 1 year and 5 years; however, the MitraClip procedure was associated with superior safety and similar improvements in clinical outcomes [44, 45]. Currently, guidelines state that MitraClip can be considered in patients with severe primary mitral regurgitation who meet the echocardiographic criteria of eligibility, and are judged inoperable or at prohibitive surgical risk by a Heart Team [32, 46]. Further studies are needed to apply this technique to intermediate- or low-risk patients.

In conclusion, the MitraClip procedure has proven reasonable safety and efficacy in high-risk patients and is already considered as an established part of the mitral valve program in high-volume centers. A multidisciplinary Heart Team approach will play a crucial role for careful patient selection and clinical application of the transcatheter interventions as a part of a successful and multimodal mitral valve program [47].



**Figure 1.** MitraClip (Abbott Vascular, Santa Clara, CA) is a percutaneous mitral valve repair using anterior-posterior edge-to-edge direct leaflet approximation.

#### 4.2. Transcatheter mitral valve replacement

Unlike transcatheter mitral valve repair, the challenges of deploying and anchoring a functional prosthetic device into the mitral valve annulus amid the intact subvalvular apparatus is more complex. As of January 2016, the total human experience with transcatheter mitral valve replacement implantation surpassed 50 cases, with half of those performed in the United States [43]. The preliminary outcomes have been promising so far.

The Tendyne device (Abbott Vascular, Santa Clara, CA) is a potentially fully retrievable trileaflet porcine pericardial valve with an impermeable nitinol skirt which has a prominent cuff positioned to rest on the intertrigonal aortomitral curtain [48] (**Figure 2**). The Tendyne is an intraannular valve that does not specifically capture the leaflets, and thus the primary clinical target is patients with functional mitral regurgitation. The first US use of Tendyne device was in April 2015. Currently, multiple experienced centers have been chosen for the Food and Drug Administration (FDA) clinical trial for high risk patients inoperable for conventional mitral valve replacement. Several other devices for transcatheter mitral valve replacement are also in the stage of clinical investigation.

Despite continuing innovation, current transcatheter mitral valve replacement delivery systems remain large and the majority require a transapical retrograde approach to the mitral valve. Therefore, the collaboration between interventional cardiologists and surgeons is needed as with the transapical TAVR procedure.



**Figure 2.** Tendyne (Abbott Vascular, Santa Clara, CA) is a transapically delivered porcine pericardial valve for transcatheter mitral valve replacement.

#### 5. Hybrid approach for atrial fibrillation

Nowadays the majority of ablations for symptomatic atrial fibrillation are catheter-cased. In the United States from 2000 to 2010, over 93,000 catheter ablations were performed for atrial



fibrillation [49]. However, the outcomes of catheter ablation for patients with significant valve disease and long-standing persistent atrial fibrillation remain poor [50]. For patients who have valvular heart disease or patients who are refractory to antiarrhythmic drugs or catheter ablation, surgical ablation called Cox-Maze procedure is recommended [51].

The hybrid approach for atrial fibrillation represents a collaborative between cardiac surgeons and cardiologists utilizing the strengths of both techniques in order to achieve outcomes that maximize the success rates and minimize the procedural complications. There are several potential advantages to a hybrid approach [50]. From a surgical standpoint, direct visualization allows surgeons to perform aggressive ablation at sites which may be challenging for catheter ablation due to risk of injuring esophagus or phrenic nerves, and also allows surgeons to confirm of transmuralty of ablation. Moreover, the ability to exclude the left atrial appendage serves to potentially eliminate need for anticoagulation. On the other hand, catheter ablation allows more complex mapping of the left atrium for either complex fractionated atrial electrograms or rotors.

Hybrid procedures incorporate both an epicardial surgical ablation and endocardial catheter ablation [52]. The procedure can be done in either one-staged or two-staged fashion. The outcomes of hybrid approach for atrial fibrillation in previous studies are shown in **Table 2**. While all procedures were done through minimally invasive approach, the approach varied with right,

Study	Year	Number of pts	Follow-up (months)	Mortality (%)	Success rate off AA drugs (%)	Success rate on AA drugs (%)
Mahapatra et al. [63]	2011	15	20.7 ± 4.5	0	86.7	93.3
Krul et al. [64]	2011	31	12	0	86	–
Pison et al. [65]	2012	26	12	0	92	–
Muneretto et al. [66]	2012	36	30	0	77.7	91.6
Gersak et al. [67]	2012	50	24	4	87	–
La Meir et al. [68]	2013	35	12	0	91.4	–
Gehi et al. [69]	2013	101	12	2	60.7	73.3
Bisleri et al. [70]	2013	45	28 ± 1.7	0	88.9	–
Gersak et al. [71]	2014	73	12	0	52	80
Bulava et al. [72]	2015	50	12	0	84	94

*Note:* AA, antiarrhythmic.

**Table 2.** Outcomes of hybrid approach for atrial fibrillation.

and bilateral thoracoscopic approaches as well as subxiphoid and laparoscopic access. Overall, hybrid ablation procedures are associated with low mortality which is up to 4%. High success rates are reported noting sinus rhythm off antiarrhythmic drugs in about 87% of cases and in about 92% when antiarrhythmic drugs are added.

In conclusion, for the success of the hybrid ablation for atrial fibrillation, a creation of a collaborative team between cardiac surgeons and electrophysiologists is crucial. This collaboration will permit important advances in improving the outcomes of procedure especially in challenging patients.

## 6. Conclusions

Nowadays, the cases of patients who suffer from cardiovascular disease are more and more complex. Along with the technological advancement, patients who used to be thought inoperable can be treated by a new technology with a reasonable risk. Interventional cardiologists tend to be more invasive in their field, whereas cardiac surgeons tend to seek for minimally invasive approach. There are advantages and disadvantages in both surgery and interventions. The rational for hybrid procedures is to achieve the best outcome by combining the strengths of both surgery and interventional procedures. The key point for the success of hybrid procedures is the collaboration between interventional cardiologists and cardiac surgeons. In the current era, patient selection and indications for each procedure must be well discussed in a well-functioning Heart Team.

## Author details

Takashi Murashita

Address all correspondence to: [tmurashita@gmail.com](mailto:tmurashita@gmail.com)

Heart and Vascular Institute, West Virginia University, Morgantown, WV, USA

## References

- [1] Byrne JG, Leacche M, Vaughan DE, Zhao DX. Hybrid cardiovascular procedures. *JACC Cardiovasc Interv.* 2008;1(5):459-68.
- [2] Leacche M, Umakanthan R, Zhao DX, Byrne JG. Surgical update: hybrid procedures, do they have a role? *Circ Cardiovasc Interv.* 2010;3(5):511-8.
- [3] Papakonstantinou NA, Baikoussis NG, Dedeilias P, Argiriou M, Charitos C. Cardiac surgery or interventional cardiology? Why not both? Let's go hybrid. *J Cardiol.* 2017; 69(1):46-56.

- [4] Angelini GD, Wilde P, Salerno TA, Bosco G, Calafiore AM. Integrated left small thoracotomy and angioplasty for multivessel coronary artery revascularisation. *Lancet* 1996; 347(9003):787-8.
- [5] Epstein AJ, Polsky D, Yang F, Yang L, Groeneveld PW. Coronary revascularization trends in the United States, 2001-2008. *JAMA*. 2011;305(17):1769-76.
- [6] Serruys PW, Morice MC, Kappetein AP, Colombo A, Holmes DR, Mack MJ, et al. Percutaneous coronary intervention versus coronary-artery bypass grafting for severe coronary artery disease. *N Engl J Med* 2009;360(10):961-72.
- [7] Mohr FW, Morice MC, Kappetein AP, Feldman TE, Stähle E, Colombo A, et al. Coronary artery bypass graft surgery versus percutaneous coronary intervention in patients with three-vessel disease and left main coronary disease: 5-year follow-up of the randomised, clinical SYNTAX trial. *Lancet*. 2013;381(9867):629-38.
- [8] Weintraub WS, Grau-Sepulveda MV, Weiss JM, O'Brien SM, Peterson ED, Kolm P, et al. Comparative effectiveness of revascularization strategies. *N Engl J Med* 2012;366(16): 1467-76.
- [9] Farkouh ME, Domanski M, Sleeper LA, Siami FS, Dangas G, Mack M, et al. Strategies for multivessel revascularization in patients with diabetes. *N Engl J Med*. 2012; 367(25):2375-84.
- [10] Wrigley BJ, Dubey G, Spyt T, Gershlick AH. Hybrid revascularisation in multivessel coronary artery disease: could a combination of CABG and PCI be the best option in selected patients? *EuroIntervention*. 2013;8(11):1335-41.
- [11] Harskamp RE, Zheng Z, Alexander JH, Williams JB, Xian Y, Halkos ME, et al. Status quo of hybrid coronary revascularization for multi-vessel coronary artery disease. *Ann Thorac Surg*. 2013;96(6):2268-77.
- [12] Shah PJ, Durairaj M, Gordon I, Fuller J, Rosalion A, Seevanayagam S, et al. Factors affecting patency of internal thoracic artery graft: clinical and angiographic study in 1434 symptomatic patients operated between 1982 and 2002. *Eur J Cardiothorac Surg*. 2004; 26(1):118-24.
- [13] Cameron A, Davis KB, Green G, Schaff HV. Coronary bypass surgery with internal-thoracic-artery grafts—effects on survival over a 15-year period. *N Engl J Med*. 1996; 334 (4):216-9.
- [14] Loop FD, Lytle BW, Cosgrove DM, Stewart RW, Goormastic M, Williams GW, et al. Influence of the internal-mammary-artery graft on 10-year survival and other cardiac events. *N Engl J Med*. 1986;314(1):1-6.
- [15] Alexander JH, Hafley G, Harrington RA, Peterson ED, Ferguson TB, Jr., Lorenz TJ, et al. Efficacy and safety of edifoligide, an E2F transcription factor decoy, for prevention of vein graft failure following coronary artery bypass graft surgery: PREVENT IV: a randomized controlled trial. *JAMA* 2005;294(19):2446-54.

- [16] Harskamp RE, Lopes RD, Baisden CE, de Winter RJ, Alexander JH. Saphenous vein graft failure after coronary artery bypass surgery: pathophysiology, management, and future directions. *Ann Surg.* 2013;257(5):824-33.
- [17] Puskas JD, Williams WH, Mahoney EM, Huber PR, Block PC, Duke PG, et al. Off-pump vs conventional coronary artery bypass grafting: early and 1-year graft patency, cost, and quality-of-life outcomes: a randomized trial. *JAMA.* 2004;291(15):1841-49.
- [18] Tatoulis J, Buxton BF, Fuller JA. Patencies of 2127 arterial to coronary conduits over 15 years. *Ann Thorac Surg.* 2004;77(1):93-101.
- [19] Goldman S, Zadina K, Moritz T, Ovitt T, Sethi G, Copeland JG, et al. Long-term patency of saphenous vein and left internal mammary artery grafts after coronary artery bypass surgery: results from a Department of Veterans Affairs Cooperative Study. *J Am Coll Cardiol.* 2004;44(11):2149-56.
- [20] Stettler C, Wandel S, Allemann S, Kastrati A, Morice MC, Schömig A, et al. Outcomes associated with drug-eluting and bare-metal stents: a collaborative network meta-analysis. *Lancet* 2007;370(9591):937-48.
- [21] Yeung AC, Leon MB, Jain A, Tolleson TR, Spriggs DJ, Mc Laurin BT, et al. Clinical evaluation of the resolute zotarolimus-eluting coronary stent system in the treatment of de novo lesions in native coronary arteries: the Resolute US clinical trial. *J Am Coll Cardiol.* 2011;57(17):1778-83.
- [22] Weisz G, Leon MB, Holmes DR, Jr., Kereiakes DJ, Popma JJ, Teirstein PS, et al. Five-year follow-up after sirolimus-eluting stent implantation results of the SIRIUS (Sirolimus-Eluting Stent in De-Novo Native Coronary Lesions) Trial. *J Am Coll Cardiol.* 2009; 53(17):1488-97.
- [23] Alfonso F, Pérez-Vizcayno MJ, Hernandez R, Fernandez C, Escaned J, Bañuelos C, et al. Sirolimus-eluting stents versus bare-metal stents in patients with in-stent restenosis: results of a pooled analysis of two randomized studies. *Catheter Cardiovasc Interv.* 2008;72(4):459-67.
- [24] Mauri L, Orav EJ, Kuntz RE. Late loss in lumen diameter and binary restenosis for drug-eluting stent comparison. *Circulation.* 2005;111(25):3435-42.
- [25] Leacche M, Byrne JG, Solenkova NS, Reagan B, Mohamed TI, Fredi JL, et al. Comparison of 30-day outcomes of coronary artery bypass grafting surgery versus hybrid coronary revascularization stratified by SYNTAX and euroSCORE. *J Thorac Cardiovasc Surg.* 2013; 145(4):1004-12.
- [26] Harskamp RE, Brennan JM, Xian Y, Halkos ME, Puskas JD, Thourani VH, et al. Practice patterns and clinical outcomes after hybrid coronary revascularization in the United States: an analysis from the society of thoracic surgeons adult cardiac database. *Circulation.* 2014;130(11):872-79.
- [27] Green KD, Lynch DR, Jr., Chen TP, Zhao D. Combining PCI and CABG: the role of hybrid revascularization. *Curr Cardiol Rep.* 2013;15(4):351.

- [28] Kappetein AP, Head SJ. CABG, stents, or hybrid procedures for left main disease? *EuroIntervention*. 2015;11:Suppl V:V111-4.
- [29] Verhaegh AJ, Accord RE, van Garsse L, Maessen JG. Hybrid coronary revascularization as a safe, feasible, and viable alternative to conventional coronary artery bypass grafting: what is the current evidence? *Minim Invasive Surg*. 2013;14:2616.
- [30] Zhu P, Zhou P, Sun Y, Guo Y, Mai M, Zheng S. Hybrid coronary revascularization versus coronary artery bypass grafting for multivessel coronary artery disease: systematic review and meta-analysis. *J Cardiothorac Surg*. 2015;10:63.
- [31] Halkos ME, Vassiliades TA, Douglas JS, Morris DC, Rab ST, Liberman HA, et al. Hybrid coronary revascularization versus off-pump coronary artery bypass grafting for the treatment of multivessel coronary artery disease. *Ann Thorac Surg*. 2011;92(5):1695-701.
- [32] Joint Task Force on the Management of Valvular Heart Disease of the European Society of Cardiology (ESC), European Association for Cardio-Thoracic Surgery (EACTS), Vahanian A, Alfieri O, Andreotti F, Antunes MJ, et al. Guidelines on the management of valvular heart disease (version 2012). *Eur Heart J*. 2012;33(19):2451-96.
- [33] Mack MJ, Leon MB, Smith CR, Miller DC, Moses JW, Tuzcu EM, et al. 5-year outcomes of transcatheter aortic valve replacement or surgical aortic valve replacement for high surgical risk patients with aortic stenosis (PARTNER 1): a randomised controlled trial. *Lancet*. 2015;385(9986):2477-84.
- [34] Kapadia SR, Leon MB, Makkar RR, Tuzcu EM, Svensson LG, Kodali S, et al. 5-year outcomes of transcatheter aortic valve replacement compared with standard treatment for patients with inoperable aortic stenosis (PARTNER 1): a randomised controlled trial. *Lancet*. 2015;385(9986):2485-91.
- [35] Stortecky S, O'Sullivan CJ, Buellesfeld L, Windecker S, Wenaweser P. Transcatheter aortic valve implantation: the transfemoral access route is the default access. *EuroIntervention*. 2013;9 Suppl:S14-8.
- [36] Murashita T, Greason KL, Pochettino A, Sandhu GS, Nkomo VT, Bresnahan JF, et al. Clinical outcomes after transapical and transfemoral transcatheter aortic valve insertion: an evolving experience. *Ann Thorac Surg*. 2016;102(1):56-61.
- [37] Blackstone EH, Suri RM, Rajeswaran J, Babaliaros V, Douglas PS, Fearon WF, et al. Propensity-matched comparisons of clinical outcomes after transapical or transfemoral transcatheter aortic valve replacement: a placement of aortic transcatheter valves (PARTNER)-I trial substudy. *Circulation*. 2015;131(22):1989-2000.
- [38] Zanettini R, Gatto G, Mori I, Pozzoni MB, Pelenghi S, Martinelli L, et al. Cardiac rehabilitation and mid-term follow-up after transcatheter aortic valve implantation. *J Geriatr Cardiol*. 2014;11(4):279-85.
- [39] Colombo A RN. Transcatheter valve interventions: playground for cardiologists or cardiac surgeons? The cardiologist's view. *EuroIntervention*. 2015;11(SupplW):W20-2.



- [40] Nkomo VT, Gardin JM, Skelton TN, Gottdiener JS, Scott CG, Enriquez-Sarano M. Burden of valvular heart diseases: a population-based study. *Lancet*. 2006;368(9540):1005-11.
- [41] Lloyd-Jones D, Adams RJ, Brown TM, Carnethon M, Dai S, De Simone G, et al. Heart disease and stroke statistics-2010 update: a report from the American Heart Association. *Circulation*. 2010;121(7):e46-215.
- [42] Maisano F, Alfieri O, Banai S, Buchbinder M, Colombo A, Falk V, et al. The future of transcatheter mitral valve interventions: competitive or complementary role of repair vs. replacement? *Eur Heart J*. 2015;36(26):1651-9.
- [43] Badhwar V, Thourani VH, Ailawadi G, Mack M. Transcatheter mitral valve therapy: the event horizon. *J Thorac Cardiovasc Surg*. 2016;152(2):330-6.
- [44] Feldman T, Foster E, Glower DD, Kar S, Rinaldi MJ, Fail PS, et al. Percutaneous repair or surgery for mitral regurgitation. *N Engl J Med*. 2011;364(15):1395-406.
- [45] Feldman T, Kar S, Elmariah S, Smart SC, Trento A, Siegel RJ, et al. Randomized comparison of percutaneous repair and surgery for mitral regurgitation: 5-Year Results of EVEREST II. *J Am Coll Cardiol*. 2015;66(25):2844-54.
- [46] Nishimura RA, Otto CM, Bonow RO, A. CB, Erwin JP, 3rd., Guyton RA, et al. 2014 AHA/ACC Guideline for the management of patients with valvular heart disease: a report of the American College of Cardiology/American Heart Association Task Force on Practice Guidelines. *Circulation*. 2014;129(23):e521-643.
- [47] Nielsen SL. Current status of transcatheter mitral valve repair therapies—From surgical concepts towards future directions. *Scand Cardiovasc J*. 2016;50(5-6):367-76.
- [48] Perpetua EM, Reisman M. The tendyne transcatheter mitral valve implantation system. *EuroIntervention*. 2015;11(Suppl W):W78-9.
- [49] Deshmukh A, Patel NJ, Pant S, Shah N, Chothani A, Mehta K, et al. In-hospital complications associated with catheter ablation of atrial fibrillation in the United States between 2000 and 2010: analysis of 93 801 procedures. *Circulation* 2013;128(19):2104-12.
- [50] Driver K, Mangrum JM. Hybrid approaches in atrial fibrillation ablation: why, where and who? *J Thorac Dis*. 2015;7(2):159-64.
- [51] Badhwar V, Rankin JS, Damiano RJ, Jr., Gillinov AM, Bakaeen FG, Edgerton JR, et al. The society of thoracic surgeons 2017 clinical practice guidelines for the surgical treatment of atrial fibrillation. *Ann Thorac Surg*. 2017;103(1):239-41.
- [52] Wang PJ. Hybrid epicardial and endocardial ablation of atrial fibrillation: is ablation on two sides of the atrial wall better than one? *J Am Heart Assoc*. 2015;4(3):e001893.
- [53] Rab ST, Douglas JS, Jr., Lyons E, Puskas JD, Bansal D, Halkos ME, et al. Hybrid coronary revascularization for the treatment of left main coronary stenosis: a feasibility study. *Catheter Cardiovasc Interv*. 2012;80(2):238-44.

- [54] Lewis BS, Porat E, Halon DA, Ammar R, Flugelman MY, Khader N, et al. Same-day combined coronary angioplasty and minimally invasive coronary surgery. *Am J Cardiol.* 1999;84(10):1246-47.
- [55] Isomura T, Suma H, Horii T, Sato T, Kobashi T, Kanemitsu H. Minimally invasive coronary artery revascularization: off-pump bypass grafting and the hybrid procedure. *Ann Thorac Surg.* 2000;70(6):2017-22.
- [56] Presbitero P, Nicolini F, Maiello L, Franciosi G, Carcagni A, Milone F, et al. "Hybrid" percutaneous and surgical coronary revascularization: selection criteria from a single-center experience. *Ital Heart J.* 2001;2(5):363-8.
- [57] Lee MS, Wilentz JR, Makkar RR, Singh V, Nero T, Swistel D, et al. Hybrid revascularization using percutaneous coronary intervention and robotically assisted minimally invasive direct coronary artery bypass surgery. *J Invasive Cardiol.* 2004;16(8):419-25.
- [58] Repossini A, Tespili M, Saino A, Kotelnikov I, Moggi A, Di Bacco L, et al. Hybrid revascularization in multivessel coronary artery disease. *Eur J Cardiothorac Surg.* 2013;44(2):288-93.
- [59] Gilard M, Bizon E, Cornily JC, Mansourati J, Mondine P, Barra JA, et al. Same-day combined percutaneous coronary intervention and coronary artery surgery. *Cardiology* 2007;108(4):363-7.
- [60] Kon ZN, Brown EN, Tran R, Joshi A, Reicher B, Grant MC, et al. Simultaneous hybrid coronary revascularization reduces postoperative morbidity compared with results from conventional off-pump coronary artery bypass. *J Thorac Cardiovasc Surg.* 2008;135(2):367-75.
- [61] Vassiliades TA, Jr., Douglas JS, Morris DC, Block PC, Ghazzal Z, Rab ST, et al. Integrated coronary revascularization with drug-eluting stents: immediate and seven-month outcome. *J Thorac Cardiovasc Surg.* 2006;131(5):956-62.
- [62] Bonatti J, Schachner T, Bonaros N, Jonetzko P, Ohlinger A, Ruetzler E, et al. Simultaneous hybrid coronary revascularization using totally endoscopic left internal mammary artery bypass grafting and placement of rapamycin eluting stents in the same interventional session. The COMBINATION pilot study. *Cardiology.* 2008;110(2):92-95.
- [63] Mahapatra S, LaPar DJ, Kamath S, Payne J, Bilchick KC, Mangrum JM, et al. Initial experience of sequential surgical epicardial-catheter endocardial ablation for persistent and long-standing persistent atrial fibrillation with long-term follow-up. *Ann Thorac Surg.* 2011;91(6):1890-98.
- [64] Krul SP, Driessen AH, van Boven WJ, Linnenbank AC, Geuzebroek GS, Jackman WM, et al. Thoracoscopic video-assisted pulmonary vein antrum isolation, ganglionated plexus ablation, and periprocedural confirmation of ablation lesions: first results of a hybrid surgical-electrophysiological approach for atrial fibrillation. *Circ Arrhythm Electrophysiol.* 2011;4(3):262-70.

- [65] Pison L, La Meir M, van Opstal J, Blaauw Y, Maessen J, Crijns HJ. Hybrid thoracoscopic surgical and transvenous catheter ablation of atrial fibrillation. *J Am Coll Cardiol*. 2012;60(1):54-61.
- [66] Muneretto C, Bisleri G, Bontempi L, Curnis A. Durable staged hybrid ablation with thoracoscopic and percutaneous approach for treatment of long-standing atrial fibrillation: a 30-month assessment with continuous monitoring. *J Thorac Cardiovasc Surg* 2012;144(6):1460-65.
- [67] Gersak B, Pernat A, Robic B, Sinkovec M. Low rate of atrial fibrillation recurrence verified by implantable loop recorder monitoring following a convergent epicardial and endocardial ablation of atrial fibrillation. *J Cardiovasc Electrophysiol* 2012;23(10):1059-66.
- [68] La Meir M, Gelsomino S, Lucà F, Pison L, Parise O, Colella A, et al. Minimally invasive surgical treatment of lone atrial fibrillation: early results of hybrid versus standard minimally invasive approach employing radiofrequency sources. *Int J Cardiol*. 2013;167(4):1469-75.
- [69] Gehi AK, Mounsey JP, Pursell I, Landers M, Boyce K, Chung EH, et al. Hybrid epicardial-endocardial ablation using a pericardioscopic technique for the treatment of atrial fibrillation. *Heart Rhythm*. 2013;10(1):22-8.
- [70] Bisleri G, Rosati F, Bontempi L, Curnis A, Muneretto C. Hybrid approach for the treatment of long-standing persistent atrial fibrillation: electrophysiological findings and clinical results. *Eur J Cardiothorac Surg*. 2013;44(5):919-23.
- [71] Geršak B, Zembala MO, Müller D, Folliguet T, Jan M, Kowalski O, et al. European experience of the convergent atrial fibrillation procedure: multicenter outcomes in consecutive patients. *J Thorac Cardiovasc Surg*. 2014;147(4):1411-6.
- [72] Bulava A, Mokrcek A, Hanis J, Kurfirst V, Eisenberger M, Pesl L. Sequential hybrid procedure for persistent atrial fibrillation. *J Am Heart Assoc*. 2015;4(3):e001754.

IntechOpen

