

# We are IntechOpen, the world's leading publisher of Open Access books Built by scientists, for scientists

6,900

Open access books available

185,000

International authors and editors

200M

Downloads

Our authors are among the

154

Countries delivered to

TOP 1%

most cited scientists

12.2%

Contributors from top 500 universities



WEB OF SCIENCE™

Selection of our books indexed in the Book Citation Index  
in Web of Science™ Core Collection (BKCI)

Interested in publishing with us?  
Contact [book.department@intechopen.com](mailto:book.department@intechopen.com)

Numbers displayed above are based on latest data collected.  
For more information visit [www.intechopen.com](http://www.intechopen.com)



---

# Photodynamic Therapy

---

Wei Liu and Hong Cai

Additional information is available at the end of the chapter

<http://dx.doi.org/10.5772/66420>

---

## Abstract

Photodynamic therapy (PDT) employs light activation of tissue-localized photosensitizer in an oxygen-dependent process which initiates oxidative stress, inflammation, and cell death. Photodynamic therapy (PDT) involves the activation of a previously administered photosensitizing agent by visible light to induce tumor necrosis. Photosensitizers are topically applied in the treatment of skin tumors to avoid systemic side effects. The main dermatology indications for topical PDT are superficial nonmelanoma skin cancer and dysplasia, notably superficial basal carcinoma (BCC), Bowen's disease (BD), and actinic keratosis (AK). In this chapter, we evaluated the feasibility and efficacy of aminolevulinic acid (ALA) as a photosensitizer (ALA-PDT) in combination with CO<sub>2</sub> laser in the treatment of dermatological disease from basics to clinic research.

**Keywords:** photodynamic therapy, photosensitizer, Bowen's disease, actinic keratosis, aminolevulinic acid

---

## 1. Photodynamic therapy for actinic keratoses

Skin aging is often divided into natural aging and photoaging. Photoaging is caused by excessive exposure to the ultraviolet (UV) irradiation. The skin becomes thick and rough, with coarse wrinkles, mottled pigmentation, and precancerous lesions, including actinic keratoses (AK). Actinic keratosis (AK) is a growth of dysplastic cells within the epidermis that presents clinically with a scaly localized macule or papule on chronically sun-exposed skin [1]. Over the last few years, the relationship between AK and SCC has been a topic for much debate in the literature, as AK is believed not to be a separate entity but an SCC *in situ*.

Some researchers also consider actinic keratoses equivalent to squamous cell carcinoma (SCC). Yet, SCC is capable of metastasis [2, 3]. So it can be life threatening. AK is a precancerous lesion, therefore should be treated early. There are a lot of methods for AK, while not all

treatments are appropriate for all patients or lesions, especially cosmetic outcome may be generally less than optimal [4, 5]. The ideal treatment for AKs should be effective, well tolerated, and have an excellent cosmetic outcome, particularly in cosmetic-sensitive areas such as the face.

Photodynamic therapy (PDT) has been under development for the treatment of various tumors by the end of the 1970s. Topical ALA-PDT was originally used for superficial non-melanoma skin cancers and their precursors. However, other benign diseases, such as acne vulgaris, sebaceous gland hyperplasia, and hidradenitis suppurativa, have been shown to improve with this treatment. Photodynamic therapy (PDT) is an alternative, minimally invasive treatment. Oxygen, photosensitizer, and light are the three principal elements of PDT. When illuminated by a light source with an appropriate wavelength, the photosensitizer is activated and will react with oxygen to produce singlet oxygen and reactive oxygen species (ROS) to cause the selective destruction of target tissues [6]. As a metabolic precursor of endogenous porphyrins in heme biosynthesis, the absorption of 5-ALA induces the production and accumulation of protoporphyrin IX (Pp IX), a fluorescent substance that is as effective as a light sensitive agent (408, 506, 532, 580, and 635 nm).

An ideal treatment for AK would only affect lesional skin, leaving normal surrounding skin unharmed. In the 1990s, Kennedy et al. using topic 5-aminolaevulinic acid (5-ALA) that has restricted the phototoxicity at the application site. Since AK lesions are capable of selectively accumulating PPIX, they are excellent targets for PDT.

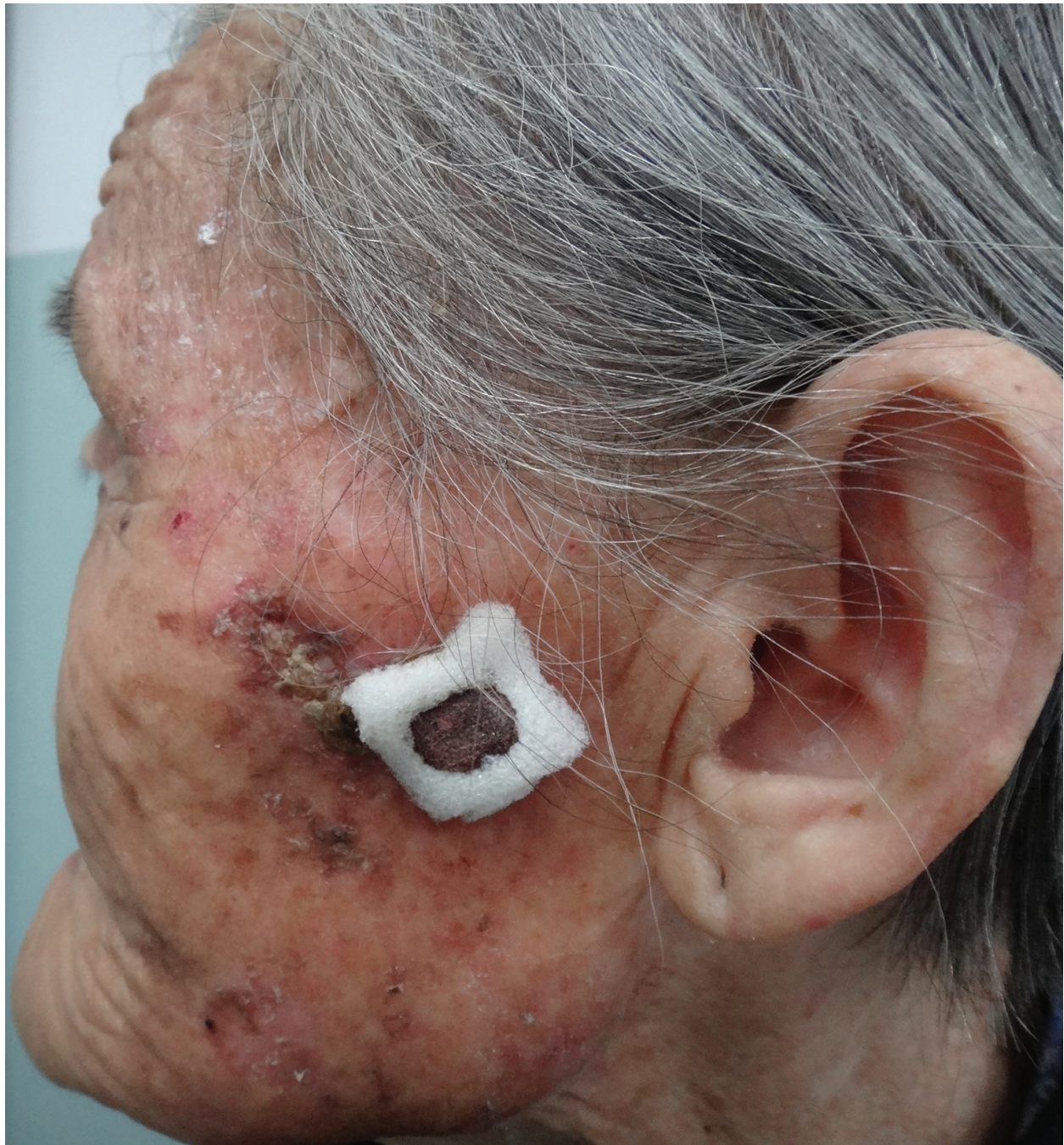Forty-two patients with a total of 56 AK lesions on the face were enrolled in our study. The 5-ALA (Zhangjiang, China) was prepared at a concentration of 20% in physiological saline. A thick layer of the formulation was applied to cover the AK lesions for 5 h. Then the lesions were illuminated by laser ( $\lambda = 630$  nm, light dose  $100 \text{ mW/cm}^2$ ) for 30 minutes. All patients were reviewed in at least 2-week intervals. The response to the PDT was evaluated 1 month after the therapy, and treatment is repeated if necessary [7].

Initially, AKs lesions were detected among the patients (**Figure 1**). The treated skin lesions were evaluated macroscopically at several time points following the treatment. Immediately after ALA-PDT, it showed limited edema and erythema in the treated area. Conversely, the lesions were covered with necrotic tissue after 1 day. A red granulation tissue developed after 4–7 days and gradually atrophic flatten (**Figure 2**). Afterwards, a pink-red contracted atrophic scar could be observed that progressively healed after 3 weeks. All the 56 lesions from 42 patients showed a complete response by histologic examination (remission rate, 85.71%) 1 month after PDT treatment. The epidermis of the photodamaged skin became thinner and more even. Clinically, there was no significant scarring or pigmentary changes after treatment (**Figure 3**).

There were six patients with persistent lesions, the six patients with eight lesions received one or two additional PDT treatments; the AKs in the follow-up biopsy resolved, and the lesions were all cleared in the end.

Before treatment, histopathological analysis of the lesions showed the presence of atypical keratinocytes characteristic for AK (**Figure 4**). After treatment, the epidermis of the



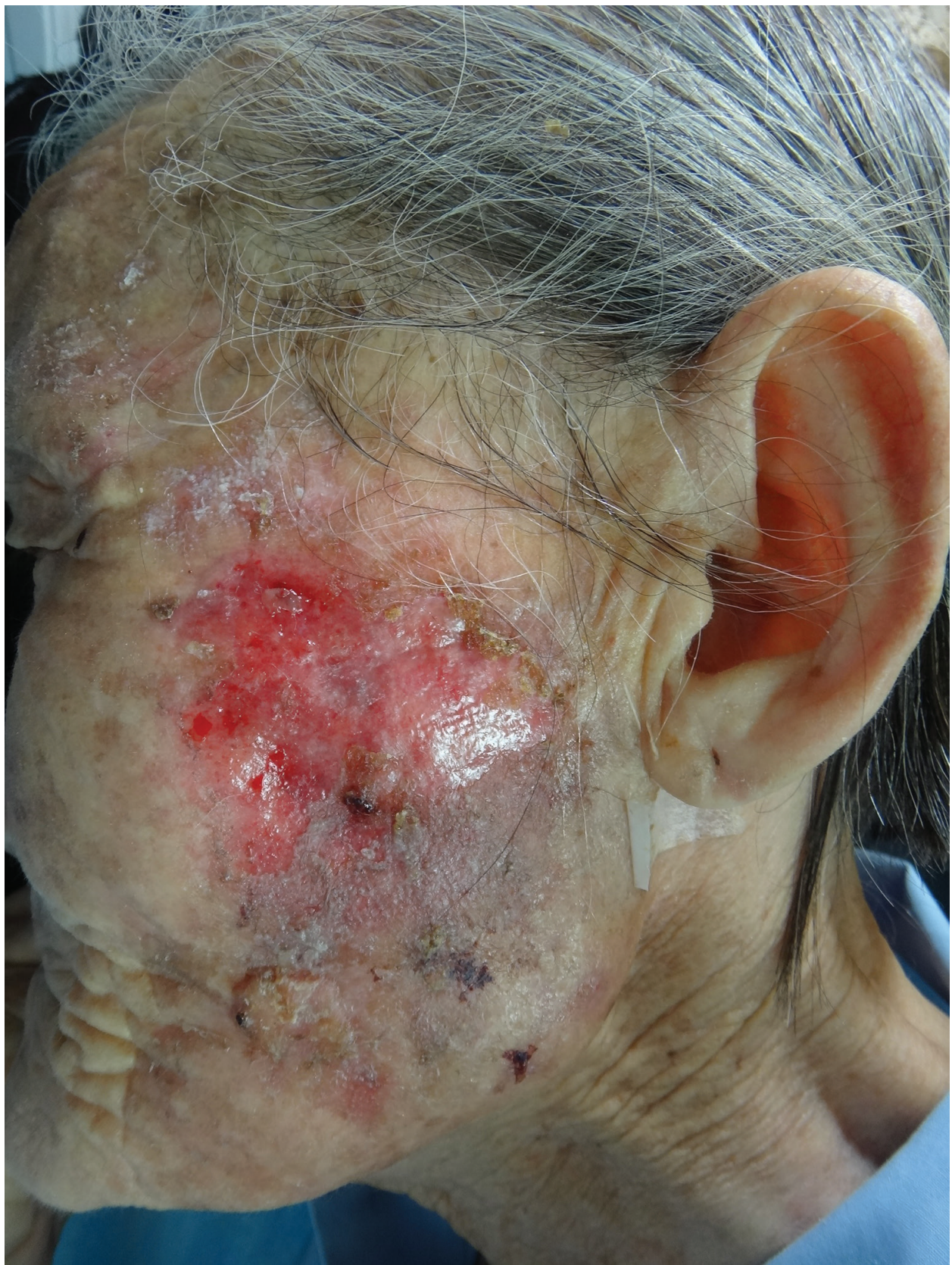

**Figure 1.** After biopsy.

photodamaged skin became thinner and more even, and the skin structure in responsive lesions had returned to normal and the atypical cells of AK were replaced by normal keratinocytes (**Figure 5**). The epidermis was fully regenerated by day 30 following PDT.

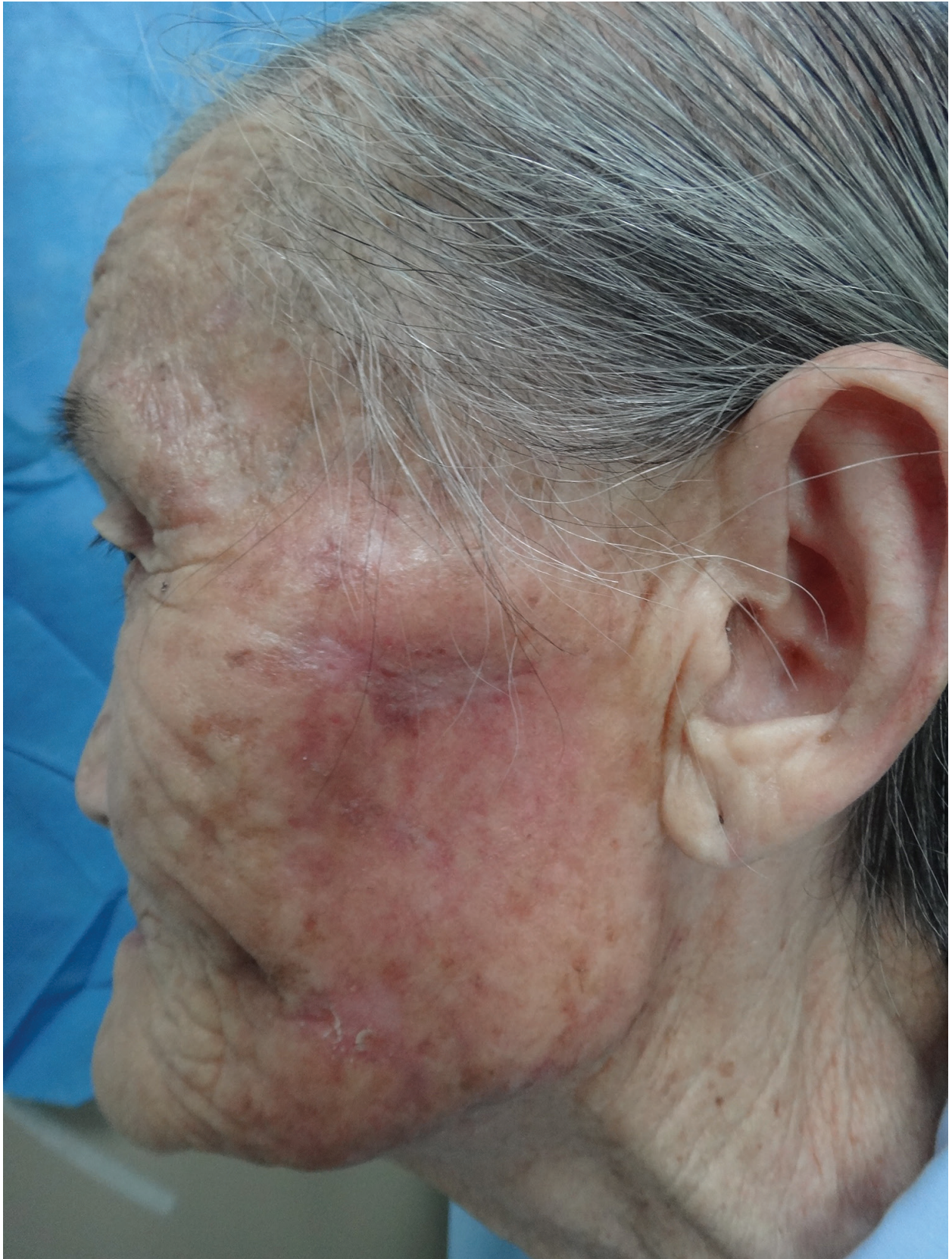The facial lesions' mean epidermal thickness significantly decreased from  $155.22 \pm 70.45$  to  $74.35 \pm 18.65$   $\mu\text{m}$  after treatment ( $P < 0.05$ ) (**Figure 6**). We can observe a large number of infiltrating cells in the dermis before the treatment, and those were significantly reduced after treatment. In 5 h of 5-ALA occlusive treatment, there were no reports of irritation, local or





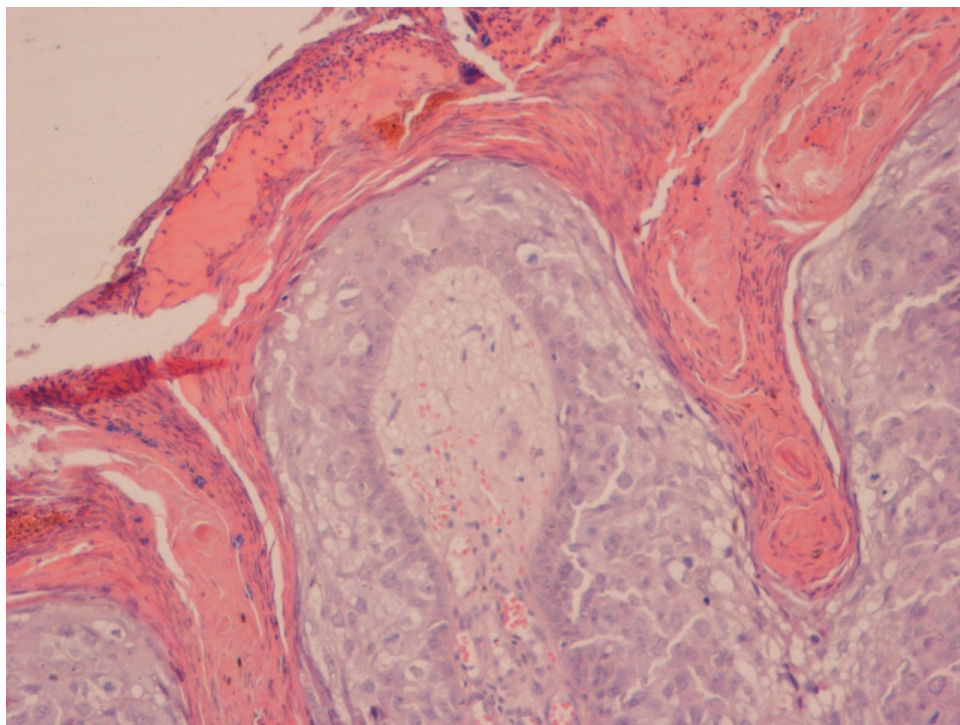
**Figure 2.** 1 week after PDT.



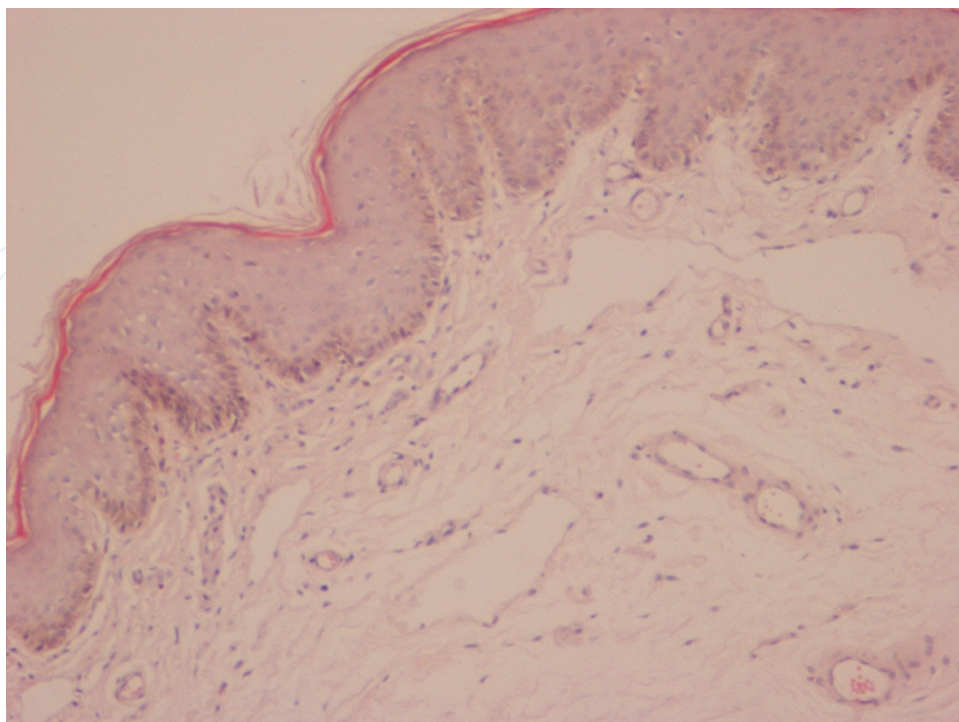


**Figure 3.** 1 month after PDT.

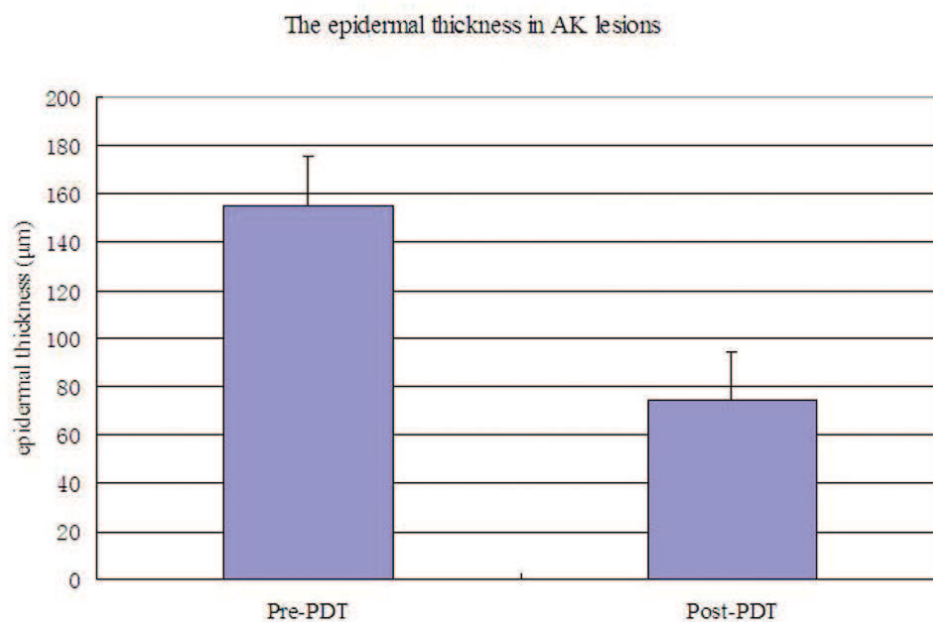




**Figure 4.** Before PDT.



**Figure 5.** After PDT.



**Figure 6.** Epidermal thickness.

systemic light sensitization reaction. During the exposure to the light source all patients complained about a burning sensation, ranging from light to intense. During the treatment, variable degrees of erythema, blistering and edema occurred, all of these events were of short duration and completely reversible. During the treatment, it was possible to see progressive and evident edema and erythema on the application site. Despite the pain, none of the patients asked or interrupted the light exposition treatment.

The cosmetic outcome in all cured AKs was excellent, except for one patient; after additional sun exposure, postinflammatory hyperpigmentation developed. The method of topical application of ALA is a minimally invasive treatment. Photosensitizer's metabolic cycle is very quick, the period of photosensitization is short, and can give good cosmetic effect.

The investigations of the action of light on living organisms began in the nineteenth century. Since Dougherty [8] in the 1970s began clinical trials for photodynamic destruction of cutaneous and subcutaneous malignancies, PDT has been used to treat esophageal [9], laryngeal, endobronchial, gastrointestinal, genitourinary, nervous, head and neck [10], oral leucoplakia, and skin malignancies [11].

Photodynamic therapy (PDT) is an oxygen-dependent process involving the use of a photosensitizing drug which accumulates in diseased tissue. The main topical agents used in dermatology are 20% 5-aminolaevulinic acid (ALA). It produced porphyrins via the heme biosynthetic pathway. It is an endogenous chemical, which participates in heme biosynthesis in the body. As a precursor of the hemoglobin content, its production has strong photosensitive function after the activation of ALA anhydrase and a series of enzymes. Porphyrin IX (protoporphyrin IX, Pp IX) is the last step of heme biosynthesis intermediate [12]. Under normal circumstances, heme biosynthesis pathway by regulating the body negative feedback mechanism, the synthesis of ALA is regulated by the hemoglobin content in the cell, so there will not be too much ALA accumulation in the body. When given overdoses of exogenous ALA, it



can increase the intracellular concentration of Pp IX to therapeutically useful concentrations. Photoactivation by visible light results in cell damage of targeted abnormal cells while preserving normal structures. This effect of PDT is connected with direct photochemical reactions mediated by singlet oxygen and other reactive species. The cooperation of photosensitizing substances with light leads to the release of cytotoxic substances. It has been described that tumor destruction of PDT is connected with indirect effects of PDT: blood vessel occlusion within vascularized tumors. These effects demonstrated [9] that PDT induces apoptosis and vascular endothelial damage [13, 14]. It has also been mediated by the release of prostaglandin E2 (PGE2) and cytokines (IL-2, IL-1, TNF).

In this study, we observed pre- and post- ALA-PDT specimens for AK and determined whether ALA-PDT induced histologic changes reversing the destructive connective tissue events. Normally, we selected 1 month after the PDT as the point time to evaluate the histologic changes for lots of results showing this time point of the assessment might be an important consideration. The fact that 1–20% of AKs progress to squamous cell carcinoma and approximately 60% of all squamous cell carcinomas develop from AKs underscores the importance of early treatment of AKs [3]. Our findings showed approximately 85% of AKs are already cured after a single PDT exposure. As a result, the majority of patients need only one treatment, and we only performed one PDT session followed by clinical examinations at 1 and 3 months after PDT. Only those lesions that showed an incomplete response need further treatment.

- The results of this study provide histologic evidence supporting the beneficial effects of ALA-PDT for photodamaged skin. PDT appears to be a more feasible alternative to conventional therapy of skin malignancies. Our results showed that the thickness of epidermis decreased significantly after ALA-PDT. We could see hyperkeratosis, stratum spinosum hypertrophy before the treatment. And the acanthocyte arranged in disorder. There are atypical keratinocytes in the central of the epidermis. We evaluated the histologic changes 1 month after the PDT, suggesting that the point in time of the assessment might be an important consideration. The epidermis was fully regenerated by day 30 following PDT. After treatment, the epidermis of the photodamaged skin became thinner and more even, and the skin structure in responsive lesions had returned to normal and the atypical cells of epidermis were replaced by normal keratinocyte [7]. Although the light source itself might affect the histologic changes in AKs, we still consider that ALA-PDT is the most important reason leading to the histologic changes in the present study where the light energy is very low.

Topically applied photosensitizers are preferred for dermatological PDT because of the reduced risk for prolonged skin photosensitivity. As we all know, topical application of ALA is a minimally invasive treatment. It has a short photosensitization period, can treat multiple lesions at the same time, and can give good cosmetic effect. Studies have shown that the depth of penetration for most tissues using 630 nm light is about 1 cm [15, 16]. This percutaneous penetration is the most important factor influencing response rates for topical ALA PDT. Photodynamic therapy is associated with epidermal necrosis and dermal inflammation, which in turn gives a series of side effects in dermatology, including pain, ecchymosis, ulceration, and blistering [17].

Selective photodynamic destruction of treated premalignant and malignant areas without injury of normal tissue, ability to repeat PDT without loss of normal tissue proves PDT to be a more acceptable option than surgical resection. At the same time, laser-induced PDT almost left no obvious scar in our study. Patients treated with PDT may also benefit from minimal invasiveness, low recurrence, as well as excellent cosmetic effects in premalignant and malignant lesions of the skin.

The present study is limited by the follow-up time. In our study at 1 and 3 months after PDT, previous reports are in good agreement with the overall CR rates of 85.71 and 100% that were found, respectively. However, there are still existed residual malignant cells in the epidermis but not apparent by visual inspection. It will lead to clinical recurrence of the AKs at a later examination if the malignant cells continue to proliferate. That is the important reason why we need to observe the clearance rate after PDT for a long follow-up time.

In conclusion, the results of this study provide histologic evidence supporting the beneficial effects of PDT for AK. PDT using topical ALA was a safe and effective treatment for actinic keratoses with an excellent cosmetic outcome. It is a promising treatment that could benefit from further study. Topical PDT for AKs is now a well-established treatment modality that showed easy handling of 5-ALA administration with excellent efficacy and safety results.

## 2. Photodynamic therapy for the treatment of Bowen's disease

Bowen's disease (BD), or squamous cell carcinoma *in situ*, usually presents as a well-defined erythematous plaque on photoexposed sites [18]. Although any body part can be involved, BD lesions are common on the head and neck and lower limbs. The diagnosis is often delayed because of the symptoms are often untypical. The early skin changes may often appear to be eczema, tinea corporis, and psoriasis. Therefore, pathological diagnosis might be necessary when clinical differentiation between these diseases is difficult [3].

BD is a more aggressive form of intraepidermal (*in situ*) squamous cell carcinoma. Risk factors for BD include fair skin, protracted sunlight damage, radiation exposure, immune compromise and human papillomavirus infection [19]. Most BD lesions are found in the elderly patients commonly at high risk for surgery.

Several equally efficacious treatment options are available for the treatment of BD including conventional surgery, Mohs' surgery, cryosurgery, and CO<sub>2</sub> laser. However, it is not indicated for patients with numerous or large lesions such as those located in face. Alternative treatments are needed to treat superficial malignancies on nose, ear, and other sites. CO<sub>2</sub> laser vaporizes lesional tissues by thermal effects and causes minimal injuries, but it often fails to entirely remove lesions, especially those invisible or infiltrating into adjacent tissues, resulting in disease persistence and recurrence.

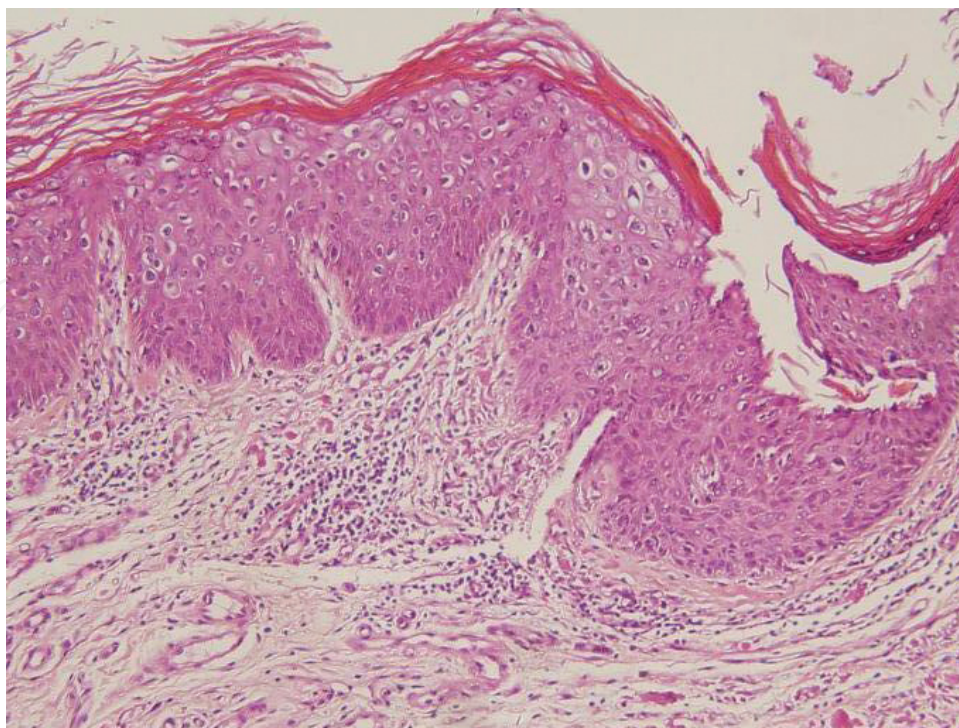
Topical 5-aminolevulinic acid-mediated photodynamic therapy (ALA-PDT) is a minimally invasive procedure, represents a relatively new treatment modality, and, with some unique features, it is especially suitable for the local treatment of superficial epithelial disorders. It



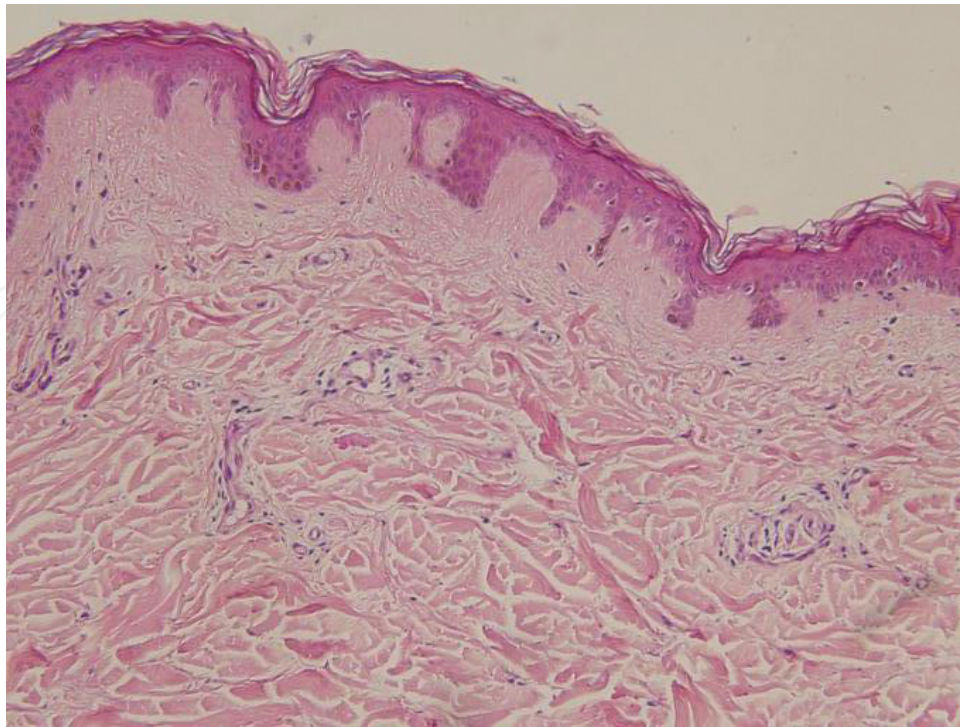
causes less damage to normal tissues than surgical treatment, radiation therapy, or chemotherapy. In addition, since PDT does not produce cumulative effect and systemic phototoxicity, it allows repetitive treatments for new, partially responding or recurrent lesions. In this study, ALA-PDT treatment was performed following local pretreatment with CO<sub>2</sub> laser. By the pretreatment, we could enhance photosensitizer absorption, reduce the thickness of the BD lesion, and even increase the penetration depth of the irradiation, to achieve a multiplier effect [20].

Twenty-two lesions from 18 patients were randomized into two groups [21]; 11 lesions were treated with CO<sub>2</sub> laser alone, serving as control group. The remaining 11 lesions were treated with topical ALA-PDT (180 J/cm<sup>2</sup> at 100 mW/cm<sup>2</sup>) + CO<sub>2</sub> laser for 1–3 sessions.

Biopsies were taken from BD lesions prior to treatment. BD is histopathologically characterized by the presence of atypical keratinocytes (**Figure 7**). Skin biopsies from the erythematous plaque exhibited proliferation of atypical squamous cells across the entire thickness of the epidermis and the BD diagnosis was based on the finding. The initial evaluation was undertaken 1 month after treatment and biopsies were harvested for histological evaluation. The epidermis fully regenerated in the point of 30 days after ALA-PDT + CO<sub>2</sub> laser treatment. The epidermis of the BD lesion became thinner and more even following the treatment. Moreover, the atypical BD cells were replaced by normal keratinocytes and the skin structure in responsive lesions returned to normal (**Figure 8**). All patients were reviewed at ≤1-week intervals. Patients who did not respond to the three sessions of treatment were referred to surgical treatment [21].



**Figure 7.** Before PDT (×20).



**Figure 8.** After PDT ( $\times 20$ ).

In the CO<sub>2</sub> laser group, eight patients who underwent 1–3 sessions of laser treatment alone showed response to the therapy. Seven lesions (63.63%) achieved complete recovery, three (27.27%) showed partial response but another five lesions (45.45%) relapsed within 6 months during follow-up. Five out of eight (62.5%) patients were satisfied with the therapeutic results of CO<sub>2</sub> laser therapy.

In the ALA-PDT + CO<sub>2</sub> laser group, complete response was achieved in 72.73% of the lesions after 1–3 treatment sessions. Three lesions (27.27%) showed partial response during the treatment. ALA-PDT + CO<sub>2</sub> laser was repeated in the cases of partial response after a single session. Out of eight lesions that initially responded completely, 1 month later one relapsed. The recurrence rate was 9.1% (1/11) and the overall clearance was 90.9% (10/11). Eight out of 10 (80%) patients were satisfied with their therapeutic outcome after ALA-PDT + CO<sub>2</sub> laser treatment, which is much higher than control group [21].

BD lesions are commonly seen on the head, neck, and lower limbs, although any site can be involved. The combination treatment of ALA-PDT and CO<sub>2</sub> laser could achieve a much better cosmetic outcome. Compared with CO<sub>2</sub> laser alone, histopathological examination of the BD lesions confirmed that the response to the combination therapy was more uniform after ALA-PDT + CO<sub>2</sub> laser. PDT appears to be a more feasible alternative to conventional therapy for skin malignancies. BD lesions predominantly consisted of atypical keratinocytes before the treatment. We can see the large number of atypical cells in the epidermis and superficial layers of the dermis, a few lymphocytes and dilated capillaries. Following ALA-PDT + CO<sub>2</sub> laser treatment, the epidermis was found to have fully regenerated 30 days. Furthermore, the stratum spinosum become thinner after treatment, the atypical BD cells were replaced by



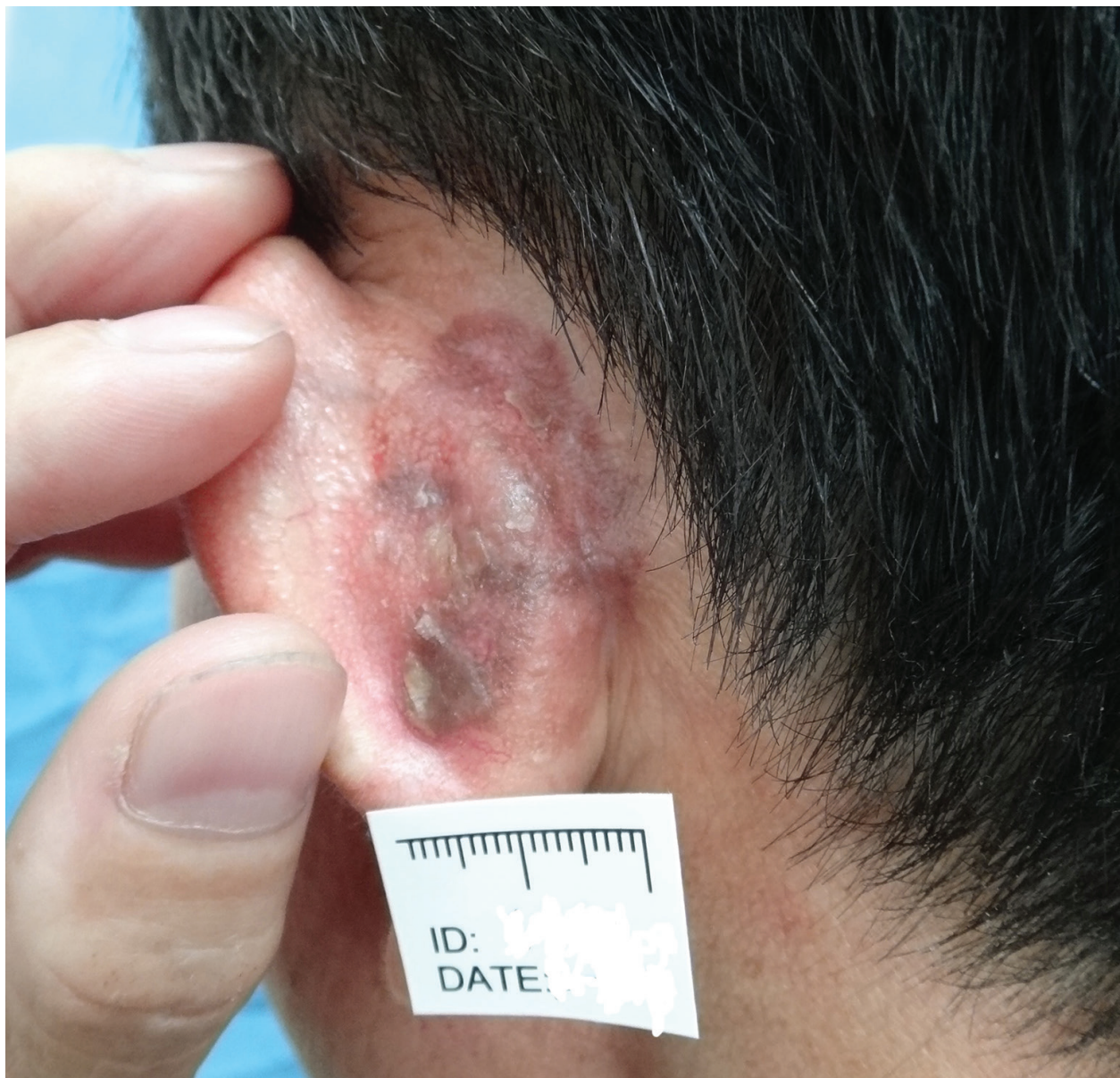normal keratinocytes and the photodamaged skin architecture in responsive lesions returned to normal.

Our study also showed that local ALA-PDT after CO<sub>2</sub> laser was highly effective for BD lesions and could be used as an ideal alternative for large and multiple BD lesions, or for other modalities of treatment (surgical or nonsurgical) are inappropriate or have failed. There was no difference in the complete remission rate between the two groups ( $P > 0.05$ ). However, recurrence of BD at the treated site is common. The recurrence rate was substantially higher in the control group than in the ALA-PDT + CO<sub>2</sub> laser group ( $P < 0.05$ ). While the overall clearance was higher in the ALA-PDT + CO<sub>2</sub> laser group than in the control group ( $P < 0.05$ ). A complete response was seen in 72.73% of lesions after 1–3 treatment sessions. Only one lesion developed recurrence 6 month after ALA-PDT + CO<sub>2</sub> laser treatment. The post-treatment recurrence rate was 45.45% (5/11) in CO<sub>2</sub> laser alone group, and five lesions relapsed within 6 months during follow-up. In general, we consider incomplete clearance after four or more times of PDT treatments to be a PDT failure. In terms of our experience, the vast majority of patients were cured within two or three treatment cycles. We would advise patients select alternative treatments in this failure situation. Recurrent disease can be retreated by PDT. This is another advantage of PDT and particularly applied for large or multiple areas and field change. **Figure 9** showed a 55-year-old male hepatitis B patient who has 6-month history of genital BD lesions. He underwent three sessions of ALA-PDT + CO<sub>2</sub> laser treatments, and he completely recovered from BD. He revealed no recurrence during the 6-month follow-up after treatment (**Figure 10**).

In most cases, PDT plus superficial laser vaporization was usually given as a single outpatient treatment that gave good therapeutic results. Most treatments are not suitable for BD lesions involving large and multiple lesions, but we used PDT for BD lesions in some sites such as peri-genital areas, and succeed in the end. The efficacy of local ALA-PDT after CO<sub>2</sub> laser for Bowen's disease lesions reaches almost 80–90%. Compared with the efficacy of PDT with laser in the treatment of Bowen's disease demonstrated that PDT was better than laser alone [14, 22]. Compared with other treatments, PDT causes the low incidences of ulceration and absence of infections.

BD may be a prototype of a non-melanoma skin cancer, and clinically PDT should be seen as a first-line therapy, especially for elderly patients who find the need for hospital attendance limiting [23]. Many BD lesions require immediate surgical intervention in order to avoid the risk of malignant change. With local ALA and light illumination combined with CO<sub>2</sub> laser, good results can be accomplished usually with a single outpatient treatment session without causing serious side effects except a few patients had transient pain, erythema, and scabby.

The most common side effect experienced with PDT is pain, with up to 20% of patients describing pain as being "severe". This can sometimes persist for a few hours after treatment, and it tends to be severest during the early period of irradiation. Postinflammatory hyper or hypopigmentation can also occur. Persistent erythema is often seen at 3 months but does not necessarily indicate residual disease [24, 25].



**Figure 9.** Before PDT.

This study explored the feasibility of using topical ALA-PDT combined with CO<sub>2</sub> laser for BD. Our preliminary results proved that the ALA-PDT after CO<sub>2</sub> laser is safe and effective and is associated with a low recurrence rate. The main limiting factors for PDT at the moment are pain and the inconvenience of hospital attendance. However, this study provided histological evidence that supports the beneficial effects of ALA-PDT + CO<sub>2</sub> laser for the treatment of BD. PDT is quite promising and could be the potential alternative, especially for large and multiple lesions; or for patients where other modalities of treatment (surgical or non-surgical) are inappropriate or have failed.



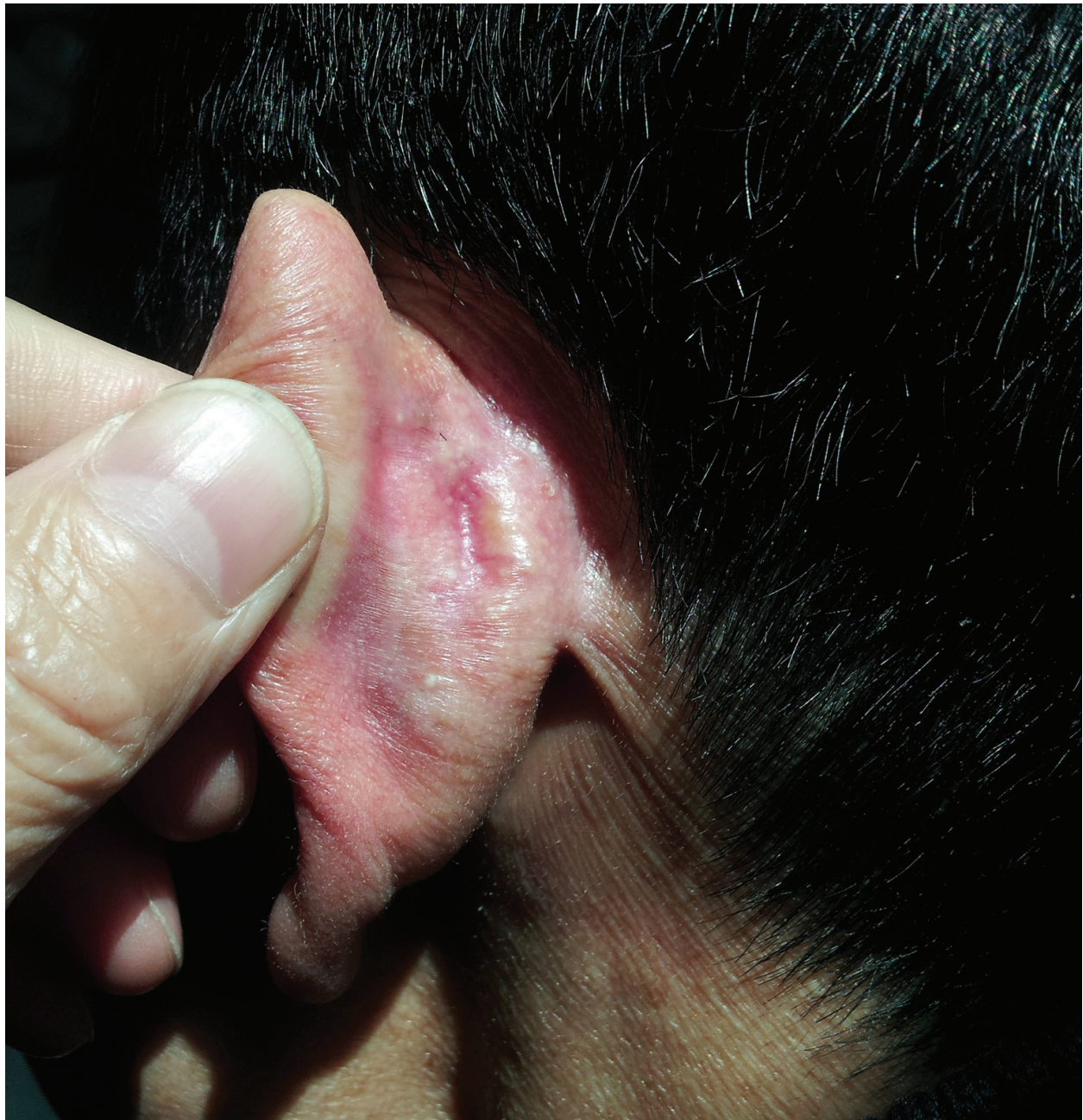

Figure 10. After PDT.

### 3. Photodynamic therapy for the treatment of port wine stains

Port-wine stain (PWS) is congenital vascular malformation characterized by ectatic capillaries in the papillary layer of the dermis. PWS occurs in an estimated 0.3% of births, affecting males and females and all racial groups equally. It may be located anywhere on the body, but more often on the face. PWS are permanent, do not disappear spontaneously. They usually appear at birth and tend to become darker and thicker with age [26, 27], deepening in color from faint pink to deep red or purple or developing nodularity. It is usually isolated but may be associated with other vascular malformations or occurs as a component of a variety of congenital syndromes.

Because persistent PWS lesions can cause serious psychological problems, therapy for PWS is considered a medical necessity. Many therapeutic methods have been used to treat PWS, including surgical excision, cryosurgery, dermabrasion, tattooing, and cosmetic camouflage makeup [28]. These methods are no longer used because of ineffectiveness and scarring.

PDT is a relatively new therapeutic modality for skin disease. The vascular effects of PDT on tumors leads to endothelial injury, vasoconstriction, thrombus formation, and blood flow stasis. These results suggest that PDT is a potential treatment for certain vascular diseases, including PWS. The advantage of PDT is its dual selectivity: precise direction of laser light to the specific target area and selective uptake of photosensitizer to target tissues. PWS have a histologic characteristic of dilated capillary vessels, the target of PDT. *In vivo* 23–26 and *in vitro* 25 studies have shown that photosensitizer accumulation occurs rapidly in vascular endothelial cells after intravenous administration.

Recently, the General Hospital of the Peoples' Liberation Army in China reported their decade-long experience of PWS with PDT. Gu et al. [29, 30] reported that among 1942 PWS lesions in 1385 patients treated by either PSD-007 or HMME from April 1991 to May 2003 showed that, after one PDT treatment session, total clearance was achieved in 128 lesions (6.6%), achieved excellent results, 746 (38.3%) good results, 923 (47.4%) fair results, 145 (7.4%) results, and seven (0.3%) with no visible change. Their data showed that PDT was an effective treatment in all patients with PWS, especially for dark-skinned patients or patients with papules or nodules.

## Acknowledgements

The authors are grateful to Ying Gu academician (Department of Laser Medicine, Chinese PLA General Hospital) for constructive suggestions and the members of the department of dermatology of the Air Force General Hospital for their technical support. This work was supported by the National Natural Science Foundation of China (No. 81301386) and the China Postdoctoral Science Foundation (no. 2013M532225 and no. 2014T71009).

## Author details

Wei Liu\* and Hong Cai

\*Address all correspondence to: lwei5811@126.com

Department of Dermatology, Air Force General Hospital, PLA, Beijing, P. R. China

## References

- [1] Zalaudek I, Giacomel J, Schmid K, et al. Dermatoscopy of facial actinic keratosis, intraepidermal carcinoma, and invasive squamous cell carcinoma: a progression model. *J Am Acad Dermatol.* 2012; 66(4):589–597.



- [2] Feldman SR, Fleischer AB Jr. Progression of actinic keratosis to squamous cell carcinoma revisited: clinical and treatment implications. *Cutis*. 2011; 87(4):201–207.
- [3] Butani AK, Arbesfeld DM, Schwartz RA. Premalignant and early squamous cell carcinoma. *Clin Plast Surg*. 2005; 32(2):223–235.
- [4] Borgonjen RJ, van Everdingen JJ, Bik CM, et al. Prospective comparison of three guideline development methods for treatment of actinic keratosis. *BMJ Qual Saf*. 2011; 20(10):832–841.
- [5] Demetriou C. Reversing precancerous actinic damage by mixing wavelengths (1064 nm, 532 nm). *J Cosmet Laser Ther*. 2011; 13(3):113–119.
- [6] Inada NM, Costa MM, Guimarães OC, et al. Photodiagnosis and treatment of condyloma acuminatum using 5-aminolevulinic acid and homemade devices. *Photodiagnosis Photodyn Ther*. 2012; 9(1):60–68.
- [7] Cai H, Wang YX, Sun P, et al. Photodynamic therapy for facial actinic keratosis: a clinical and histological study in Chinese patients. *Photodiagnosis Photodyn Ther*. 2013; 10(3):260–265.
- [8] Dougherty TJ. Introduction. *Methods Mol Biol*. 2010; 635:1–6.
- [9] Nava HR, Allamaneni SS, Dougherty TJ, et al. Photodynamic therapy (PDT) using HPPH for the treatment of precancerous lesions associated with barrett's esophagus. *Lasers Surg Med*. 2011; 43(7):705–712.
- [10] Biel MA. Photodynamic therapy of head and neck cancers. *Methods Mol Biol*. 2010; 635:281–293.
- [11] Guyon L, Ascencio M, Collinet P, et al. Photodiagnosis and photodynamic therapy of peritoneal metastasis of ovarian cancer. *Photodiagnosis Photodyn Ther*. 2012; 9(1):16–31.
- [12] Mitra S, Cassar SE, Niles DJ, et al. Photodynamic therapy mediates the oxygen-independent activation of hypoxia-inducible factor 1 alpha. *Mol Cancer Ther*. 2006; 5(12):3268–3274.
- [13] Ferrario A, Gomer CJ. Targeting the tumor microenvironment using photodynamic therapy combined with inhibitors of cyclooxygenase-2 or vascular endothelial growth factor. *Methods Mol Biol*. 2010; 635:121–132.
- [14] Sailer R, Strauss WS, Wagner M, et al. Relation between intracellular location and photodynamic efficacy of 5-aminolevulinic acid-induced protoporphyrin IX in vitro. Comparison between human glioblastoma cells and other cancer cell lines. *Photochem Photobiol Sci*. 2007; 6(2):145–151.
- [15] Camp WL, Turnham JW, Athar M, et al. New agents for prevention of ultraviolet-induced nonmelanoma skin cancer. *Semin Cutan Med Surg*. 2011; 30(1):6–13.
- [16] Lee Y, Baron ED. Photodynamic therapy: current evidence and applications in dermatology. *Semin Cutan Med Surg*. 2011; 30(4):199–209.

- [17] Apalla Z, Sotiriou E, Panagiotidou D, et al. The impact of different fluence rates on pain and clinical outcome in patients with actinic keratoses treated with photodynamic therapy. *Photodermatol Photoimmunol Photomed*. 2011; 27(4):181–185.
- [18] Wang X-L, Wang H-W, Yuan K-H, Li F-L, and Huang Z. Combination of photodynamic therapy and immunomodulation for skin diseases—update of clinical aspects. *Photochem. Photobiol. Sci*. 2011; 10(2):704–711.
- [19] Kaushal S, Merideth M, Kopparthy P, Pulanic TK, Stratton P. Treatment of multifocal Bowen's disease in immunocompromised women with surgery and topical imiquimod. *Obstet Gynecol*. 2012; 119(2):442–444.
- [20] Young LC, Tuxen AJ, Goodman G. Mohs' micrographic surgery as treatment for squamous dysplasia of the nail unit. *Australas J Dermatol*. 2012; 53(2):123–127.
- [21] Cai H, Wang YX, Zheng JC, et al. Photodynamic therapy in combination with CO<sub>2</sub> laser for the treatment of Bowen's disease. *Lasers Med Sci*. 2015; 30(5):1505–1510.
- [22] Hasegawa T, Suga Y, Mizuno Y, Haruna K, Ogawa H, Ikeda S. Efficacy of photodynamic therapy with topical 5-aminolevulinic acid using intense pulsed light for Bowen's disease. *J Dermatol*. 2010; 37(7):623–628.
- [23] Sidoroff A, Thaler P. Taking treatment decisions in non-melanoma skin cancer – the place for topical photodynamic therapy (PDT). *Photodiagnosis Photodyn Ther*. 2010; 7(1):24–32.
- [24] Steinbauer JM, Schreml S, Babilas P, Zeman F, Karrer S, Landthaler M, Szeimies R-M. Topical photodynamic therapy with porphyrin precursors—assessment of treatment-associated pain in a retrospective study. *Photochem Photobiol Sci*. 2009; 8(8):1111–1116.
- [25] Arits AH, van de Weert MM, Nelemans PJ, Kelleners-Smeets NW. Pain during topical photodynamic therapy: uncomfortable and unpredictable. *J Eur Acad Dermatol Venereol*. 2010; 24(12):1452–1457.
- [26] Zhao Y, Tu P, Zhou G, et al. Hemoporphin photodynamic therapy for port-wine stain: a randomized controlled trial. *PLoS One*. 2016; 11(5):e0156219.
- [27] Huang Z. Photodynamic therapy in China: 25 years of unique history – Part one: history and domestic photosensitizers. *Photodiagnosis Photodyn Ther*. 2006; 3(2):3–10.
- [28] Huang NY. What is the optimal PDT protocol for treating port wine stains (PWS)? *Photodiagnosis Photodyn Ther*. 2007; 4(2):145–146.
- [29] Gu Y, Huang NY, Liang J, Pan YM, Liu FG. Clinical study of 1949 cases of port wine stains treated with vascular photodynamic therapy (Gu's PDT). *Ann Dermatol Venereol*. 2007; 134(3):241–244.
- [30] Qiu H, Gu Y, Wang Y, et al. Twenty years of clinical experience with a new modality of vascular-targeted photodynamic therapy for port wine stains. *Dermatol Surg*. 2011; 37(11):1603–1610.



