

# We are IntechOpen, the world's leading publisher of Open Access books Built by scientists, for scientists

6,900

Open access books available

186,000

International authors and editors

200M

Downloads

Our authors are among the

154

Countries delivered to

TOP 1%

most cited scientists

12.2%

Contributors from top 500 universities



WEB OF SCIENCE™

Selection of our books indexed in the Book Citation Index  
in Web of Science™ Core Collection (BKCI)

Interested in publishing with us?  
Contact [book.department@intechopen.com](mailto:book.department@intechopen.com)

Numbers displayed above are based on latest data collected.  
For more information visit [www.intechopen.com](http://www.intechopen.com)



---

## Role of Endoscopic Ultrasound in Subepithelial Lesions (SELs)

---

Abed Al-Lehibi and Khaled Bamakhrama

Additional information is available at the end of the chapter

<http://dx.doi.org/10.5772/67102>

---

### Abstract

A subepithelial lesion (SET) is defined as a lesion, bulge or impression visible within the lumen of the gastrointestinal tract that is covered by normally appearing mucosa and usually found incidentally during routine endoscopy. Such a lesion could be either an intramural mass or an impression caused by extramural structures. The old terminology has recently been replaced by the term “subepithelial lesion” because intramural lesions may arise and can be located in any layer of the GI wall underneath the epithelium. The most common SELs are gastrointestinal stromal tumors (GISTs), leiomyomas, lipomas, granular cell tumors (GCTs), pancreatic rests and carcinoid tumors. The prognosis varies from benign to potentially malignant. While the majority of the lesions are considered benign, some tumors such as GISTs and carcinoids have a strong propensity for malignant transformation. Endoscopic ultrasonography (EUS) is the most accurate diagnostic method for distinguishing between extraluminal compressions and intramural lesions and plays a critical role in the detection and management of SELs. This is because EUS can reveal the precise sonographic nature of the lesion even though sometimes there are complex cases, which are difficult to diagnose by EUS alone. Performing routine biopsies and obtaining tissue samples for diagnosis can be difficult because SELs are located beneath the normal epithelial layer. Mostly, EUS allows the practitioner to extract an optimal tissue sample since it allows fine-needle aspiration (FNA) and fine-needle biopsy (FNB) both of which provide good results. With immunocytochemical staining, all these techniques increase the accuracy of the diagnosis. Evaluation of subepithelial lesions by means of EUS imaging will provide further characterization of the lesion to help guide us in appropriate differential diagnosis and further management. In this chapter, we provide a systematic EUS-guided approach to the diagnosis, management and later surveillance for SELs, as well as presenting updated diagnostic techniques that may help physicians to appropriately manage these subepithelial lesions.

**Keywords:** endoscopy, endoscopic ultrasound (EUS), subepithelial lesion (SET), fine-needle aspiration (FNA), fine-needle biopsy (FNB), multidetector computed tomography (MDCT)

---

1. Introduction

The prevalence of subepithelial lesions (SELs) detected on routine endoscopy is unknown; however, these are frequently encountered with 0.36% of EGD procedures. During the last 10 years, the detection rate has increased, with advances in endoscopic technology with the more widespread use of EUS and close attention paid during routine endoscopy exams and reported with 1%, with an incidence of 1 in 300 patients [1]. The malignant lesions are reported with 13% accuracy [2]. Men and women are equally affected. Most of the patients are more than 50-year old. Usually US, CT and MRI are not sensitive enough to detect and characterize the majority of SELs since they can be smaller than 1 cm in size. SELs have a wide and diverse spectrum of etiologies (normal structures; benign lesions and malignant tumor), clinical course, radiological, and understanding the endoscopic, EUS and underlying pathologic features of SELs is essential for their detection, differential diagnosis, staging and management. They are most commonly found in the stomach, esophagus and duodenum. The lower GI, rectum, and cecum are the commonest sites. Lipomas can be seen any part of the colon. They mostly occur in the rectum and cecum, but familial lesions such as lipomas may be seen in any part of the colon. In SELs, the order was as follows: Gastrointestinal stromal tumor (GIST), leiomyoma, hemangioma, external compression, pancreatic rest and granular cell tumor (**Table 1**). Most benign SELs can be diagnosed according to their endoscopic appearance, but findings on routine biopsy are not usually that helpful. Benign SELs tumors have a lower detection rate due to the fact that they are often small and most patients are asymptomatic. A minority of cases present with abdominal pain, vomiting, anemia, dysphagia, or gastrointestinal (GI) bleeding and obstruction, most of which are likely to result from complications and depending on the site and size of the lesion. [3] Among SETs, the malignant potential of GISTs is related to size; however, malignancy can be detected in smaller lesions [4]. However, SETs can have malignant potential, and it is therefore critical to be able to exclude malignant or premalignant lesions [5], the prognoses varying from benign to very aggressive with malignant potential.

Common benign lesions	
1	Lipomas
2	Ectopic pancreas
3	Schwannomas
4	Duplication cysts
Common malignant lesions	
1	GIST
2	Lymphoma
3	Metastasis

Table 1. Differential diagnosis of SELs.

Therefore, proper diagnostic and therapeutic plans are needed for GI SETs. For this purpose, endoscopic ultrasonography (EUS) is the most accurate diagnostic method [6]. The lesion can be evaluated based on its size, layer of origin and echotexture, echogenic homogeneity, and the presence of echogenic and anechoic foci. Border, extension to adjacent layers, irregular margins and invasion into adjacent organs or structures can all be used to help identify intramural lesions or direct further management (surgical resection, endoscopic submucosal resection/dissection) or studies (special stains and immunohistochemical evaluation of tissue samples) [7, 8]. There are some typical findings for some GI SETs such as lipoma, duplication cysts, and ectopic pancreas [7, 9]. However, most hypoechoic SELs make it difficult to come to a final diagnosis using EUS images alone. Biopsy is necessary for the definite diagnosis of GI SETs. Despite obtaining appropriate biopsy specimens, using an endoscopic biopsy procedure is often difficult and inconclusive [10]. To overcome the limitations of conventional endoscopic biopsy methods, using the bite-on-bite biopsy technique [11], EUS-guided cytology or biopsy methods, such as EUS-guided fine-needle aspiration (EUS-FNA), EUS-guided fine-needle biopsy (EUS-FNB) technique, have now been introduced to obtain sufficient tissue. EUS-tissue sampling is a safe procedure for the diagnosis of GI SETs and is used for cytological studies. Immunohistochemical staining (IHS) methods are used, resulting in good diagnostic yields. Recently, EUS-FNB has been introduced and reportedly provides good results for the diagnosis of GI SETs [8]. Although biopsy, including FNA and FNB or excision, is required for a definitive diagnosis. Management is generally based upon the confidence of diagnosis and whether the lesion causes symptoms. With advanced endoscopy technology and the more common use of EUS, the diagnosis and management of SETs has been changed.

## 2. Endoscopic ultrasound

Radial EUS and mini-probe EUS can reveal the precise nature and provide accurate diagnosis of GI SETs. SETs such as lipoma, duplication cysts, and ectopic pancreas exhibit some typical findings. Forward-viewing linear EUS has been introduced and has been shown to provide good image quality and shorter observation times in SETs than oblique-viewing linear EUS [12, 42]. EUS is the gold standard for evaluation of SELs with high precision. EUS is able to differentiate external compression from intramural lesion and to determine the layer of origin [13, 14]. The echogenicity of lesions is different. We can thus differentiate GISTs, leiomyomas, and schwannomas. The echogenicity of a leiomyoma is equal to the echogenicity of proper muscle, while a GIST shows slightly higher echogenicity than that of the proper muscle, and a schwannoma shows extremely low echogenicity [2]. In addition, EUS is better at providing a more accurate indication of the size of lesion than other modalities. EUS can evaluate for regional lymphadenopathy. Tissue biopsy can be obtained. Finally, EUS helps to determine appropriate management of the case. Some noninvasive imaging methods, such as transabdominal ultrasonography (US), computed tomography (CT), and magnetic resonance imaging (MRI), have been used, but they are often insufficient. With these methods, the transition zone (the area where the tumor arises from normal gut wall layers) needs to

be examined carefully to determine the layer of origin. The reported accuracy of EUS in predicting the pathologic diagnosis of subepithelial lesions showed a wide range, from 45.5 to 82.9% [14–19]. The sensitivity and specificity of EUS malignant finding is 64 and 80%, respectively [6]. However, EUS findings are not sufficient to accurately predict malignancy [10]. If tissue was obtained from EUS-guided fine-needle aspiration (EUS-FNA), the diagnostic accuracy increased markedly, ranging from 63 to 98% [1, 26–28]. EUS-FNA for SETs using a forward-viewing linear EUS has provided good results: full histologic assessment rate of 93.4%, sensitivity of 92.8%, specificity of 100% [20, 42]. Tumor size and location are important factors for good sampling in EUS-FNA for GI SETs. The diagnostic rate for tumors  $\geq 4$  cm was 100%, but for tumors of 2–4 and  $< 2$  cm, the diagnostic rates were only 86% and 71%, respectively [21, 22]. Using cytology alone, differentially diagnosing GISTs from other mesenchymal tumors is not easy. Findings of mitosis in EUS-FNA specimens are known to be associated with malignant GISTs [29, 30], Ki-67 staining is helpful in evaluating the aggressiveness of GISTs [7, 23, 24]. Many studies have reported the use of various EUS-FNA needles to improve diagnostic accuracy. Tissue sampling and diagnostic rates for SETs were similar when comparing the use of 22 and 25 G EUS-FNA needles (sampling rate, sensitivity, positive predictive value, negative predictive value: 100, 55, 100, and 0% for 22 G needles; 100, 64, 100, and 0% for 25 G needles) [25]. Furthermore, 25 G needles were superior to 22 G needles for diagnosing mobile small lesions. A histologic yield of 95% using this needle was similar to the 90% achieved in EUS-FNB using 19 G Pro-Core (Cook Endoscopy, Wilson-Salem, NC, USA) needles [26]. EUS-FNA with an on-site cytopathologist (rapid on-site cytopathological examination) resulted in a 10–29% increase in the adequacy rates of EUS-FNA specimens and a 10–15% increase in the diagnostic rate [27, 28]. Recently, EUS-FNB using reverse bevel cheese slicer technology has been introduced [29]. A study compared 22 G EUS-FNA and 22 G EUS-FNB in EUS-guided GI SET sampling. The EUS-FNB group required a significantly lower number of needle passes than the EUS-FNA group. The EUS-FNB group had higher yields of optimal macroscopic (30% vs. 92%,) and histological (20% vs. 75%,) core samples with three needle passes, which resulted in a high diagnostic rate (20% vs. 75%) [8]. The EUS helps in deciding whether a lesion should be removed or followed in situ [30]. Lesions confined to the mucosal or submucosal layers can be safely removed endoscopically. Surgical resection, if needed, is generally recommended for lesions located in muscularis propria, although these lesions need to be removed by experienced clinicians. There is minimal risk when using advances in endoscopic techniques such as endoscopic submucosal dissection (ESD) [5, 31, 32]. Follow-up EUS is often used in SETs smaller than 2 cm. For small GI SETs, follow-up after a 1-year interval is recommended. If the size of the mass is unchanged during two serial EUS follow-ups, extended follow-up is suggested [33]. The American Gastroenterological Association Institute Technical Review recommended follow-up by EUS or endoscopy at regular intervals for gastric SETs smaller than 3 cm [34]. However, in 2010, the National Comprehensive Cancer Network has recommended surgical resection of GISTs larger than 2 cm because of their malignant potential [35]. Lesions involving the muscularis propria are usually removed surgically because the complete endoscopic resection of these lesions is associated with the risk of perforation [36]. Endoscopic resection of gastric SETs from the muscularis propria (well-margined, endoluminal growth, 2–5 cm in size), results in complete endoscopic resection in 64% of cases [37].



3. EUS compared to other imaging modalities

Usually US, CT, and MRI are not sensitive enough to detect and characterize smaller SELs. Often it is impossible to differentiate them by endoscopy alone. EUS provides diagnostic information only for very large SELs. Like CT and MRI, it can also provide useful information on perigastric structures and when malignancy and metastasis is suspected. The diagnostic accuracy of MDCT is expected to be improved to even higher levels. Overall accuracy of MDCT in detection of SELs from a recent study was 78.8–85.3% [38], EUS has a history of higher accuracy in detecting and assessing the size and location of SELs comparison to other radiological imaging modalities. The narrow differential diagnosis of SELs afforded by the use of EUS is more effective than when the decision between observations with surveillance in patients with suspected benign lesions or resection when the lesion is likely to be malignant is taken (**Table 2**). In the differentiation between SELs and extraluminal compression, EUS also demonstrates a higher accuracy than endoscopy, ultrasonography, and CT. It has been reported that US and CT established the diagnosis in only 16% of cases, compared with 100% for EUS. In another comparison study of US, CT and EUS reported an accuracy of 22, 28, and 100%, respectively, in differentiating subepithelial tumors from extraluminal compression [39].

1	Endoscopy
2	Imaging (US, CT, MRI)
3	EUS with or without tissue acquisition
4	Further observation and surveillance for benign lesions
5	Endoscopic vs. surgical resection for premalignant and malignant lesions

**Table 2.** The practical approach.

4. Extramural lesions

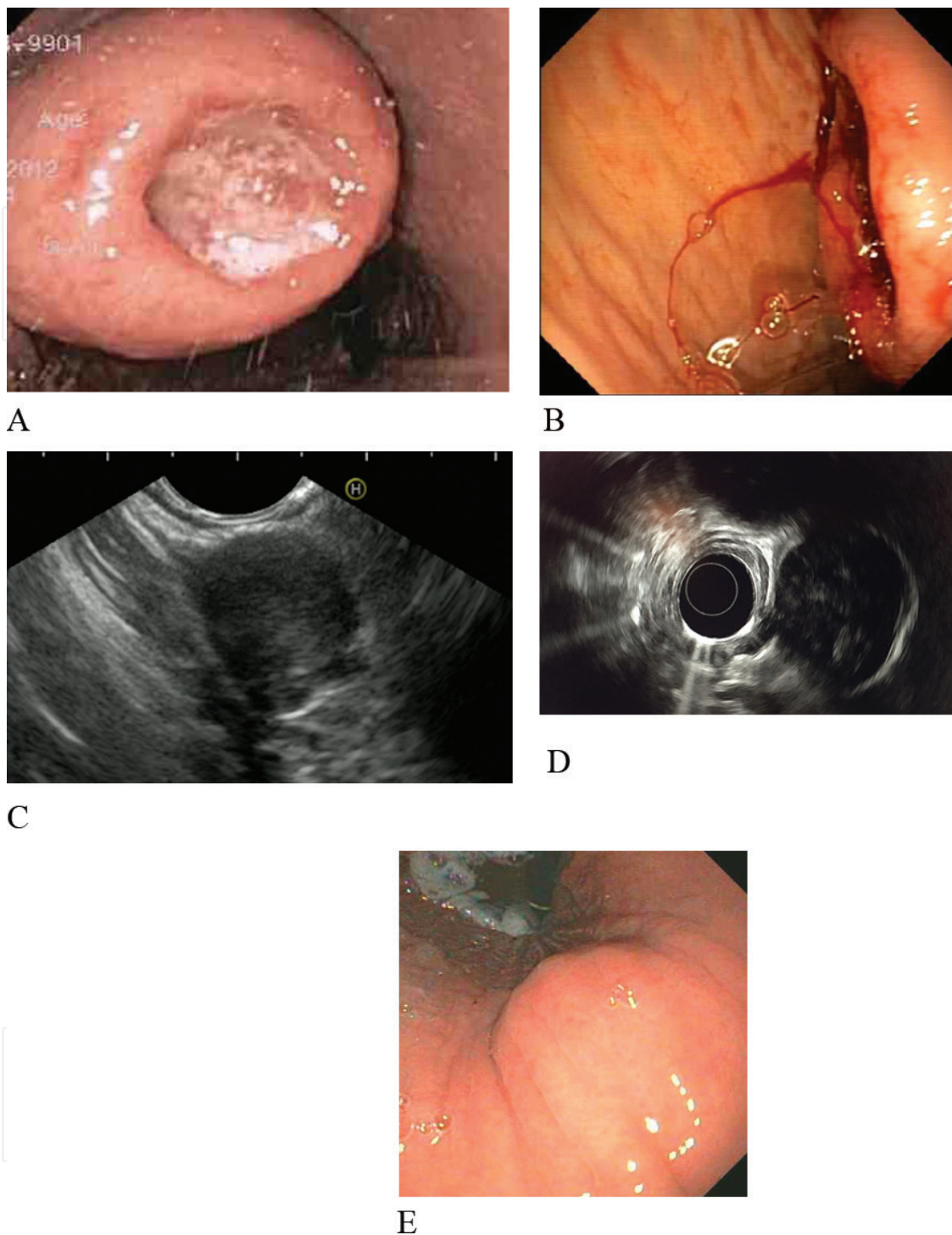
When EUS demonstrates the integrity of all gut wall layers between the gut lumen and the lesion, it is safe to say that the lesion is an impression caused by an extramural structure. A normal spleen or splenic hilum is the most common etiology for SELs found to be of extramural origin [40]. Other normal anatomic variants such as the left lobe of the liver, the gallbladder, the pancreas tail, and enlarged lymph nodes can also sometimes be interpreted as SELs [41]. Adjacent structures, such as the aortic arch and vertebrae and enlarged lymph nodes can also press on the esophagus. Abnormal structures such as pancreatic pseudocysts, splenic artery aneurysm, aortic aneurysm, cystic tumor of the pancreas or liver, colonic tumors, and lymphoma [42] may also be interpreted as SELs. When using EUS, at a low frequency of 7.5 MHz, the examiner should survey the gross relationship between the extramural structure and the gut wall. Then, at a higher frequency of 12 MHz, the outer hyper-echoic serosal layer should be observed carefully to determine whether it is intact or disrupted. EUS is very sensitive to the identification of these extramural lesions. It has been reported that 11% of these were due to pathologic lesions, while others were related to adjacent normal organs or vessels [43].

## 5. Intramural lesions

### 5.1. Gastrointestinal stromal tumors (GIST)

GIST lesions originate from the muscular propria, which is the fourth layer, and specifically from the interstitial cell of Cajal. The pathophysiology of GIST as result of mutation in the KIT gene which codes for the c-Kit protein, a tyrosine kinase receptor and in nearly immunohistochemical 95% positive of CD117 (corresponds to c-kit activation, epitope of kit protein), and, sometimes, CD34 but negative for desmin. Leiomyomas express smooth muscle actin and desmin, and schwannomas produce S-100 protein [42, 44]. Approximately 80% of GI mesenchymal tumors are GISTs, and approximately 10–30% of GISTs are malignant. GIST lesions have the potential for malignant transformation and distant metastases. GIST appeared on endoscopy as submucosal lesions (**Figure 1A, B, E**). On EUS (**Figure 1C, D**), a GIST is typically a well-circumscribed, hypoechoic, relatively homogeneous mass that can arise from either the second hypoechoic layer (muscularis mucosa) or more frequently the fourth hypoechoic layer (muscularis propria). In addition to size and mucosal ulcer, other EUS characteristics have been considered as possible predictive factors, but size is the only consistently definitive predictive factor [45–48]. One study suggested that GISTs have a marginal hypoechoic halo and relatively higher echogenicity compared with the adjacent muscular layer [49]. Another study reported that the internal hypoechoic feature could be suggested as a predictive marker of tumor progression [47]. The presence of two of these three features had a positive predictive value of 100% for malignant or borderline-malignant tumors [50]. A multicenter study reported that malignancy or indeterminate GIST status correlated with the presence of ulceration, tumor size larger than 3 cm, irregular margins, and gastric location, but not with hyperechoic or hypoechoic internal foci [51]. With hyper-enhanced GIST after infusion of ultrasound contrast, in consequence, the contrast-enhanced harmonic EUS (CEH-EUS) signal intensity of GIST is higher than other benign lesions [52]. In addition, another study reported that prediction of malignant GIST was possible with CEH-EUS by identifying intratumoral irregular vessels with 83% accuracy [63]. EUS-guided fine-needle aspiration (EUS-FNA) and EUS-guided biopsy (EUS) can be performed for immunohistochemical examination to achieve better diagnostic accuracy of GIST [53–62]. Risk of malignancy depends on the size, the number of cells at pathological evaluation and location (**Table 3**) If the lesion <2 cm and the mitotic count less than 5/50 HPF, the risk of malignancy is very low. A GIST larger 5 cm, 10/50 HPF and small bowel have a much higher risk [3, 40, 72, 73]. Pathologists classify GISTs as “very low risk,” “low risk,” “intermediate risk,” and “high risk” according to the size of the mass and the mitotic count of the resected specimen [50, 63, 64]. Management of the case depends on the size and present symptoms. A lesion of more than 1 cm needs more evaluation, EUS, FNA, and FNB or additional surgical specimens. Because small (<1 cm), asymptomatic mesenchymal tumors are rarely malignant, a close follow-up with EUS may be justified. Referral to a medical oncologist is preferable before surgical resection to consider adjuvant therapy with Imatinib (Gleevec) for high risk lesions.

Excision is advised when growth of the lesion, a change in the echo pattern, or necrosis is noted during yearly follow-up with EUS. Surgical treatment is indicated for lesions >3 cm in diameter, with features suggestive of malignancy (**Table 4**). For lesions between 1 and 3 cm,



**Figure 1.** GIST: (A, B) Endoscopy shows an ulcerated submucosal lesion in the stomach. (C) EUS image showing homogeneous hypoechoic lesion. The lesion is located with the fourth layer, corresponding to the muscularis propria. (D) Malignant gastrointestinal stromal tumor (GIST) of the stomach. (E) Endoscopy view of small smooth submucosal mass noted in the rectum.

EUS-FNA can be recommended, or ESD can be chosen as a definite diagnostic and therapeutic tool with some risk of bleeding and perforation (2 to 3% in specialized centers). When the lesion is confirmed to be a GIST, the risk of malignant transformation needs to be discussed with the patient; more careful follow-up or early resection should then be considered.



History of iron–deficiency anemia
Ulcerated GIST
Stigmata of recent bleeding
Small bowel (jejunum or ileum)
Lesion larger than 2 cm
If the lesion is noted to be growing during the surveillance period

**Table 3.** GIST, indication of surgery.

Pathology	Muscularis mucosa	Submucosa	Muscularis propria	Serosa
GIST	X		XXX	
Leiomyoma	X		XX	
Pancreatic rest		XXX		
Carcinoid tumor	X	XXX		
Duplication cyst		XXX	X	
Granular cell tumor		XX		
Varices		XXX		

**Table 4.** Lists of the most common types of subepithelial lesions.

**5.2. Leiomyoma**

A leiomyoma is a benign tumor originating from the muscular layers (muscularis propria and muscularis mucosa) composed of well-differentiated smooth muscle cells with positive immunihistochemical findings for desmin and a smooth muscle action protein and negative CD117, CD34, and s100. Leiomyomas arise from muscularis mucosa more frequently than do GISTs. True leiomyomas are more commonly found in the esophagus and the small intestine but have been found throughout the GI tract. They rarely occur in the stomach or small bowel. In contrast, GISTs are rare in the esophagus and are more common in the stomach [65]. The risk of malignant transformation is very rare [3]. They appear by EUS as hypoechoic well-circumscribed masses in the muscularis propria or the muscularis mucosae (the fourth and second EUS layers, respectively). The approach and management of these depends on the size of the lesion. A lesion more than 1 cm in size should be referred to EUS for further evaluation. With a lesion <1 cm, annual surveillance with EGD or EUS every 1–2 years should take place if the patient is asymptomatic [66]. Leiomyomas appearing similar to GIST on EUS require tissue sampling with both histologic and immunohistochemical analysis for better diagnosis. The indication of surgical resection symptomatic (bleeding) and if the lesion is noted to be growing and enlarged with structural changes during the surveillance period (Table 5).

Risk of malignancy	Size	Mitotic count
Very low	<2 cm	<5/50 HPF
Low	2–5 cm	<5/50 HPF
Moderate	<5 cm	6–10/50 HPF
	>5 cm	<5/50 HPF
High	>5 cm	6–10/50 HPF
	Any size	>10/50 HPF

**Table 5.** Association between risk of malignancy and size and mitotic count.

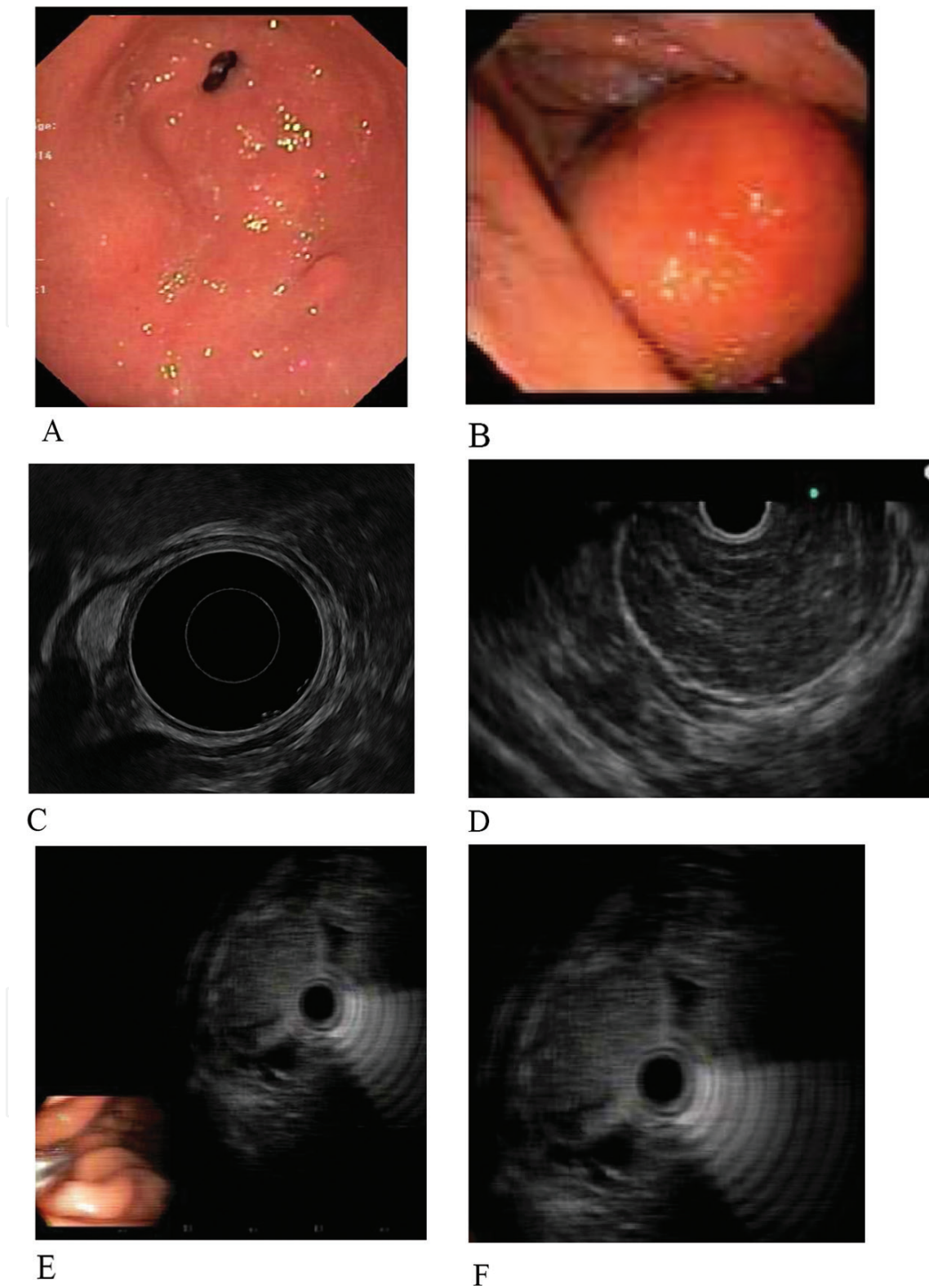
### 5.3. Lipoma

Lipomas are common benign tumors composed of mature lipocytes, slow growing fatty tumors SELs that originate from the submucosal layer (third layer). They are found incidentally in any part of the GI tract, but more often in the gastric antrum than in the small bowel and can be seen more frequently in the lower tract [67, 68]. Endoscopically, most lipomas are soft solitary, with a smooth bulge and a yellow hue appearance (**Figure 2A, B**). They are indented when pressed with closed biopsy forceps (pillow or cushion sign) an indication highly specific for lipoma with specificity of 98% and low sensitivity of 40% were reported. On EUS (**Figure 2C, D, E**), lipomas characteristically appear as intensely hyperechoic, well circumscribed homogeneous lesions with clean regular margins arising from the third layer of the GI tract, which corresponds to the submucosa. The characteristic appearance on EUS is diagnostic and no further evaluation, including biopsy, is indicated [69, 70]. The endoscopic and EUS characteristics make it possible to diagnose lipoma in most cases.

Since there is no malignant potential, those lesions, they do not require biopsy or surgical resection or even regular endoscopic surveillance. Jumbo biopsy when performed often reveals nothing more than yellowish adipose tissue [71]. Once a lipoma has been confirmed, follow-up EUS is not recommended. Extremely rare lipomas can become ulcerated [40, 72]. Local excision is then advised for these symptomatic lipomas when associated with bleeding or obstruction. Resection is also recommended when it is impossible to distinguish between a lipoma and a malignant neoplasm, such as a liposarcoma, even though this lesion is rare in the GI tract [73].

### 5.4. Granular cell tumor

Granular cell tumors (GCT) are rare benign lesions of neural derivation thought to arise from Schwann cells as supported by immunophenotypic and ultrastructural evidence. Granular cell tumors are SELs usually originated from submucosal layer of GI tract and arise from Schwann cell. There are reports of malignant transformation in 2–3% of cases. De Ceglie et al. [74] the tumor grows towards the mucosal layer. Approximately 2.7–8.1% of GCTs involve the digestive tract, and these tumors are multiple in 5–12% of patients, they are usually found incidentally during endoscopy or colonoscopy and are located mostly in the esophagus; other locations

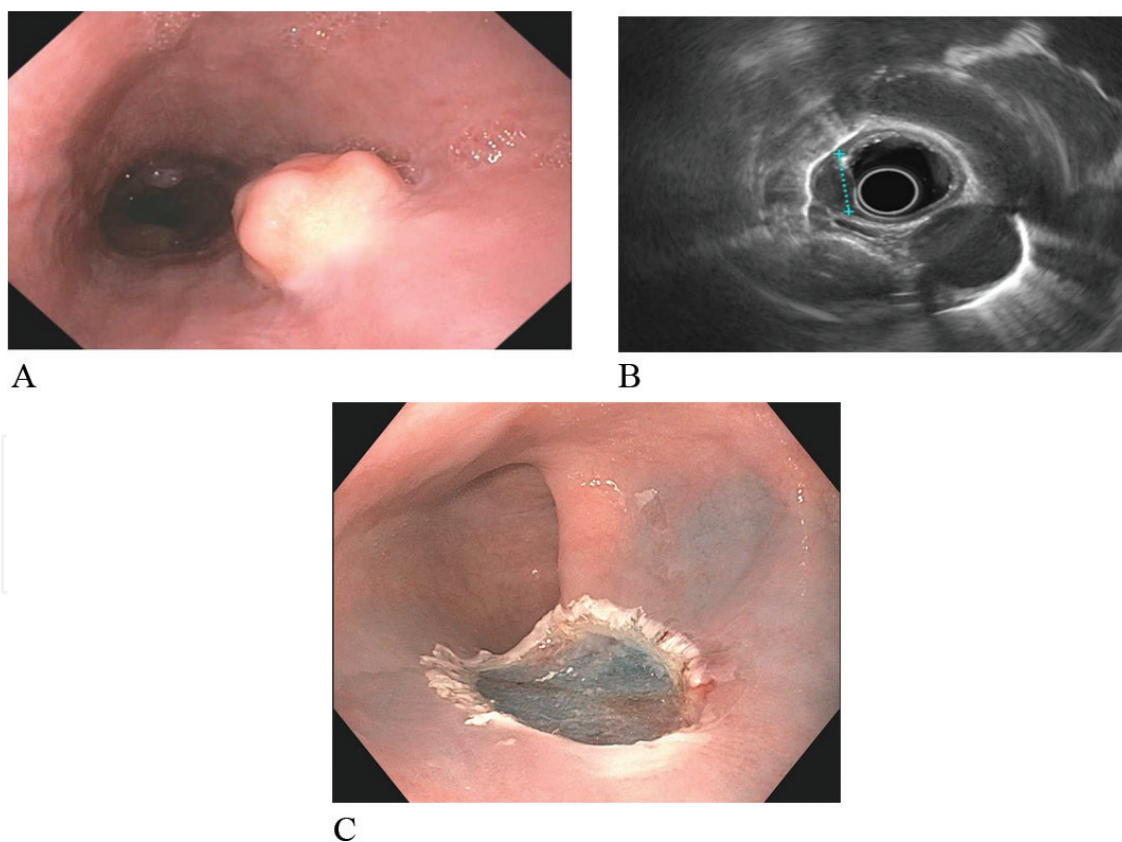


**Figure 2.** Lipoma. (A) Endoscopic view of a small elevated lesion covered with normal mucosa in the stomach. (B) Endoscopic view of a large elevated lesion covered with normal mucosa in the duodenum. (C) EUS reveals a homogeneous, hyperechoic lesion with smooth borders within the third gastric wall layer. (D) EUS image showed a heterogeneous, hyperchoic lesion within the third layer of the duodenal wall layer. (E) EUS reveals a large hyperechoic raised from the third colonic wall layer. (F) EUS image showing a large, well-defined, hyperechoic lesion within the third layer of the colonic wall.

include the stomach (10%) and rarely the colon or rectum. Endoscopically, they appear as small firm, isolated nodules or polyps resembling molar teeth, with normal overlying mucosa having a yellow hue (**Figure 3A**). On EUS (**Figure 3B**), GCTs appear as hypoechoic, homogeneous lesions with smooth margins originating from the second or third layer of the GI tract, which corresponds to deep mucosa or submucosa. Mucosal biopsy using a regular forceps is usually helpful. The risk of malignancy is low, but the size of the tumor is an important factor. Lesions >4 cm increase the risk to around 2–4% [2]. Cytologic or histopathologic evaluation staining for S-100 can be helpful in differentiating this tumor [75]. For asymptomatic GCTs that are not excised, surveillance with EUS every 1–2 years is recommended to monitor changes in size. Local endoscopic snare excision can be performed for small tumors limited to the mucosa (**Figure 3C**).

### 5.5. Ectopic pancreas

Heterotopic pancreas tissue (aberrant pancreas or ectopic pancreatic tissue)—these terms are used to describe ectopic pancreatic tissue lying outside its normal location with no anatomic or vascular connection to the pancreas proper. They are typically discovered incidentally during endoscopy, surgery, or autopsy, in approximately 1 of every 500 operations performed in the

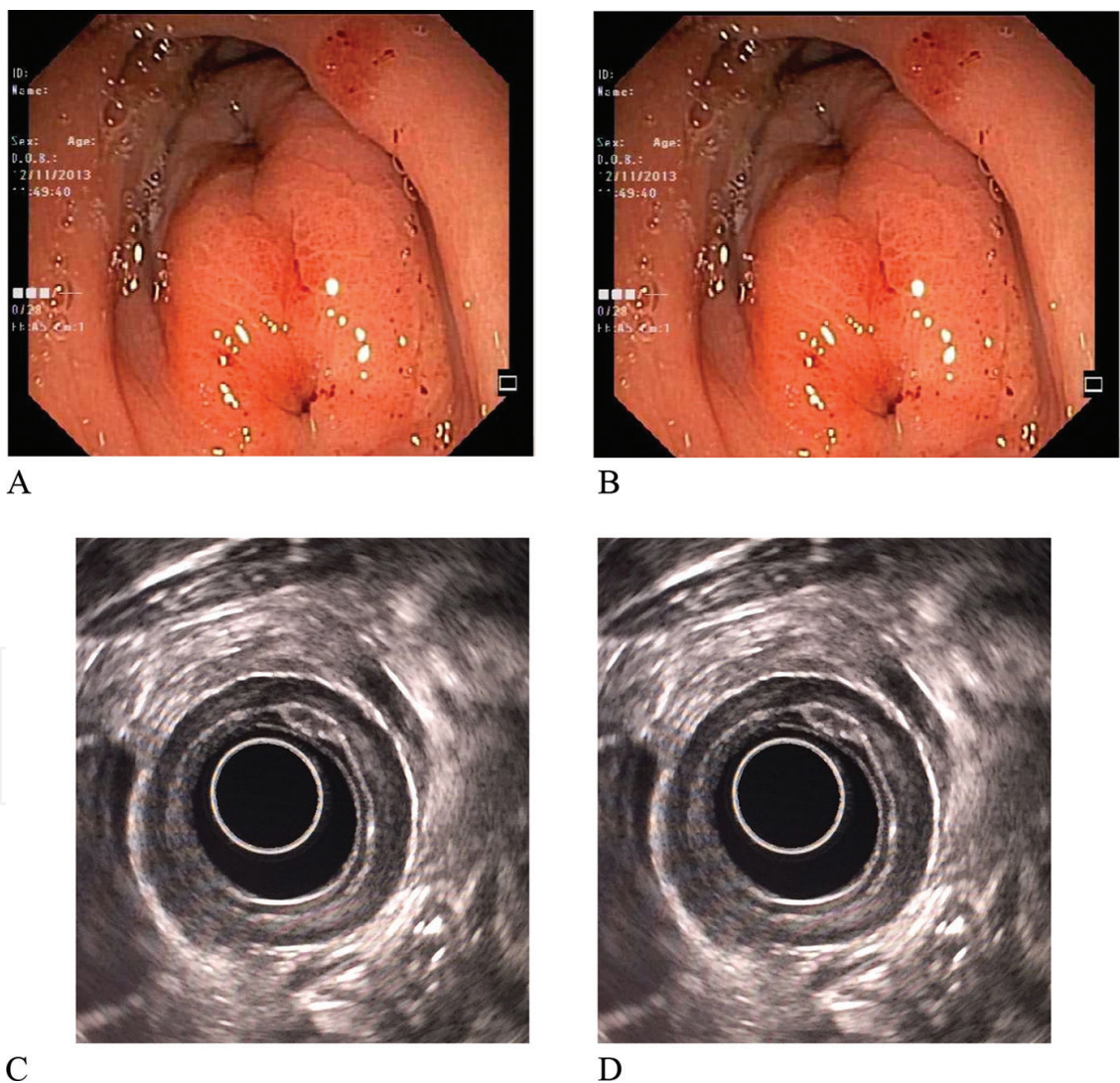


**Figure 3.** Granular cell tumor (GCT) of the esophagus. (A) Small, round, molar tooth-like, polypoid lesion in the esophagus. (B) Endosonographic image revealed a homogeneous, hypoechoic lesion with smooth margins is noted within the fourth layer. (C) Endoscopic image showed a EMR defect of GCT.



upper abdomen. The incidence in autopsy series has been estimated to be between 1 and 2% and in some reported autopsy series up to 13.7%. About 90% of the lesions are located within the stomach, and mainly in the gastric antrum, the duodenum, the small intestine, or anywhere in the GI tract. Most often asymptomatic incidental findings on endoscopy, they have been reported to present with nausea, epigastric pain, weight loss, hematemesis, ulceration, bleeding, acute pancreatitis and, rarely, gastric cyst formation, outlet obstruction, obstructive jaundice, dysphagia, and malignancy [76, 77]. These lesions have essentially no malignant potential, but there are rare case reports of adenocarcinoma arising from ectopic tissue [78].

Endoscopically (**Figure 4A, B**), this will typically be a small nodule with a central area of umbilication at the center of the lesion that corresponds to a draining duct. On deep biopsy sampling histologically, the presence of pancreatic acinar tissue will confirm the diagnosis. On EUS (**Figure 4C, D**) evaluation, it will have a heterogeneous hypoechoic. EUS features are heterogeneous



**Figure 4.** Pancreatic rest: (A and B) Endoscopic image of atypical raised submucosal lesion in the gastric antrum. A large umbilicated lesion, resembling diffused mucosal lesion (C and D), EUS image (different patient) showing a well defined, hypoechoic lesion involving the third gastric layers.

lesions, mainly hypoechoic or intermediate echogenic lesions located within the submucosal layer (the third EUS layer) accompanied by scattered small hyperechoic areas. Generally, an anechoic area and fourth layer thickening will accompany the lesions. Anechoic cystic or tubular structures within the lesion correlate with ductal structures. However, these lesions may develop in any location from the deep mucosal to the serosal layer. The management of aberrant pancreas tissue remains controversial. It should be guided by the symptoms and the possibility of malignancy. Asymptomatic lesions do not necessarily require resection and can simply be followed up. If there are severe symptoms removal is advised. Endoscopic removal is useful both for accurate diagnosis and treatment, although surgical resection is preferred to endoscopic resection when the muscularis propria is involved [79]. Cap-assisted endoscopic mucosal resection is an effective manner of obtaining adequate tissue for histologic diagnosis and management [80].

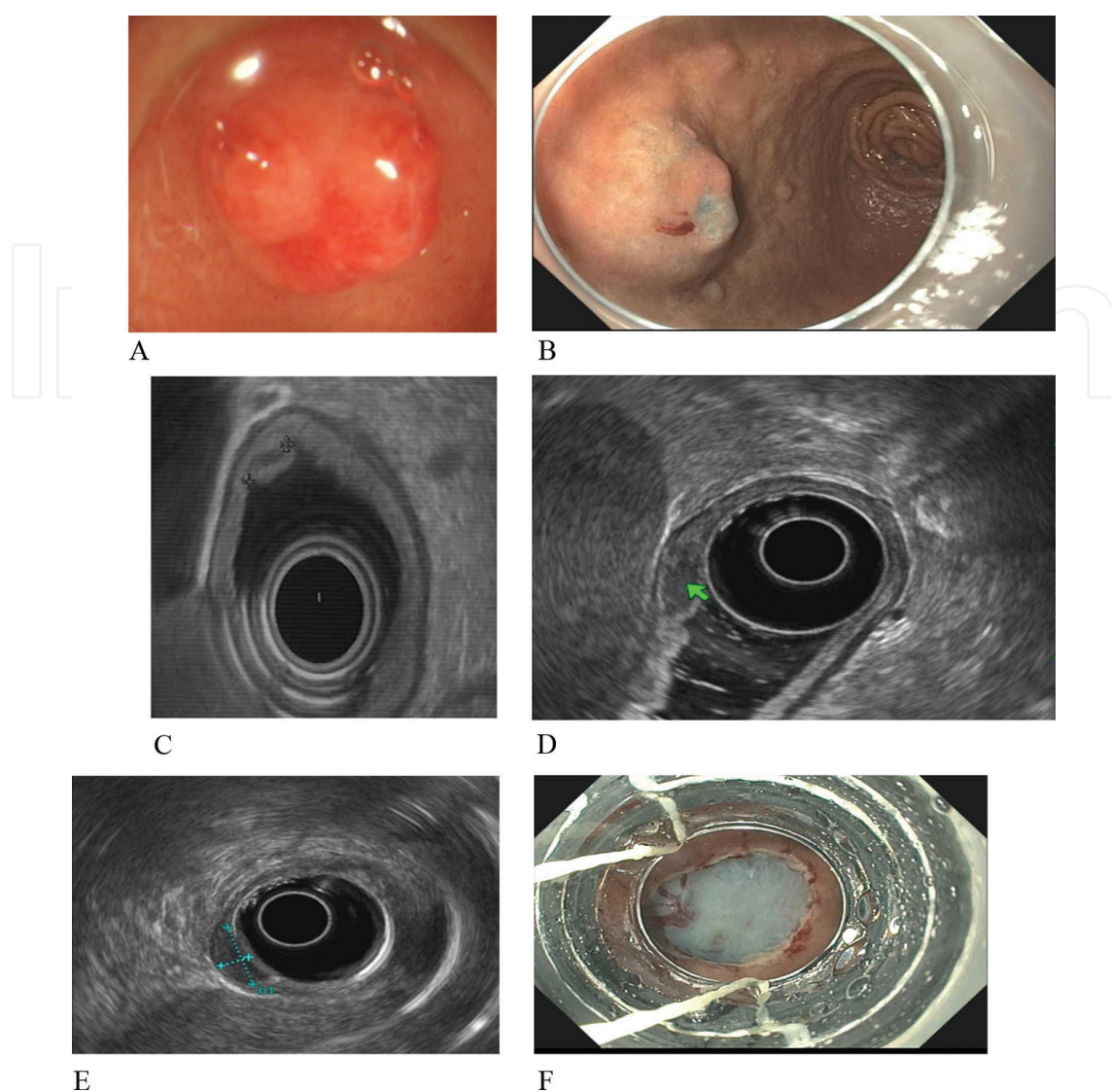
### 5.6. Carcinoid tumor

Carcinoid tumors are slow-growing neuroendocrine tumors arising from entero-chromaffin-like (ECL) cells with malignant potential. They may arise at various sites anywhere in the GI tract, most commonly the GI tract and lung. GI carcinoid tumors are generally discovered incidentally during endoscopy, surgery, or autopsy from the appendix, rectum, stomach, and small intestine, and at least 25% of all carcinoid tumors occur within the small bowel (ileum, followed by the jejunum, and then the duodenum). The gastric carcinoid tumors account for 9% of all carcinoid tumors [81, 82]. Rectal carcinoids are common and represent approximately 20% of all GI carcinoid lesions. Female patients predominate. Carcinoid tumors from different areas of the GI tract will have potentially varying presentation and symptoms. Carcinoid tumors are usually asymptomatic, but rare complications include hemorrhage, abdominal pain, intestinal obstruction, and the endocrine carcinoid syndrome that results from the secretion of functionally active substances. Endoscopically (**Figure 5A, B**), carcinoid tumors appear as small, round, sessile, or polypoid lesions with a smooth surface and a yellow hue. They usually have normal overlying mucosa and seldom ulcerate. Gastric and ileal carcinoids are commonly multiple, whereas those arising elsewhere are typically solitary. Deep mucosal biopsy is normally diagnostic. EUS (**Figure 5C, D, E**) appearance of carcinoids is usually that of a homogeneous, well demarcated, and mildly hypoechoic or isoechoic mass. These lesions arise from the second layer of the GI tract and may invade beyond the third submucosal layer. Usually originating from the deep mucosal layer and penetrating into the submucosal layer, they may have the classic “salt and pepper” pattern. EUS accurately defines the size and extent of these masses and can guide management. When the lesion is smaller than 2 cm, does not invade further than the third layer, and no adenopathy is noted, endoscopic resection is possible [83, 84] (**Figure 5F, Table 6**).

### 5.7. Rectal carcinoid tumors

Rectal carcinoid tumors are frequently discovered during routine screening by colonoscopy. The size of the lesion is a key factor in risk for metastasis. Lesions <1 cm have rarely metastasized, and endoscopic resection is potentially curative [85, 86]. Small lesions of <1 cm in size that are confined to the submucosa should be removed endoscopically. Larger lesions (>2 cm), or lesions with penetration into the muscularis propria layer on EUS, or lesions with enlarged regional lymphadenopathy should be referred for surgical resection [87, 88].





**Figure 5.** Carcinoid tumor. (A and B) Endoscopic images of a round submucosal lesion in the stomach and duodenal, respectively. (C-E) Endosonographic views of a homogeneous, hypoechoic lesions were located in the gastric and duodenum within the third layer, corresponding to the submucoal layer. (F) Endoscopy image of post-EMR of duodenal carcinoid.

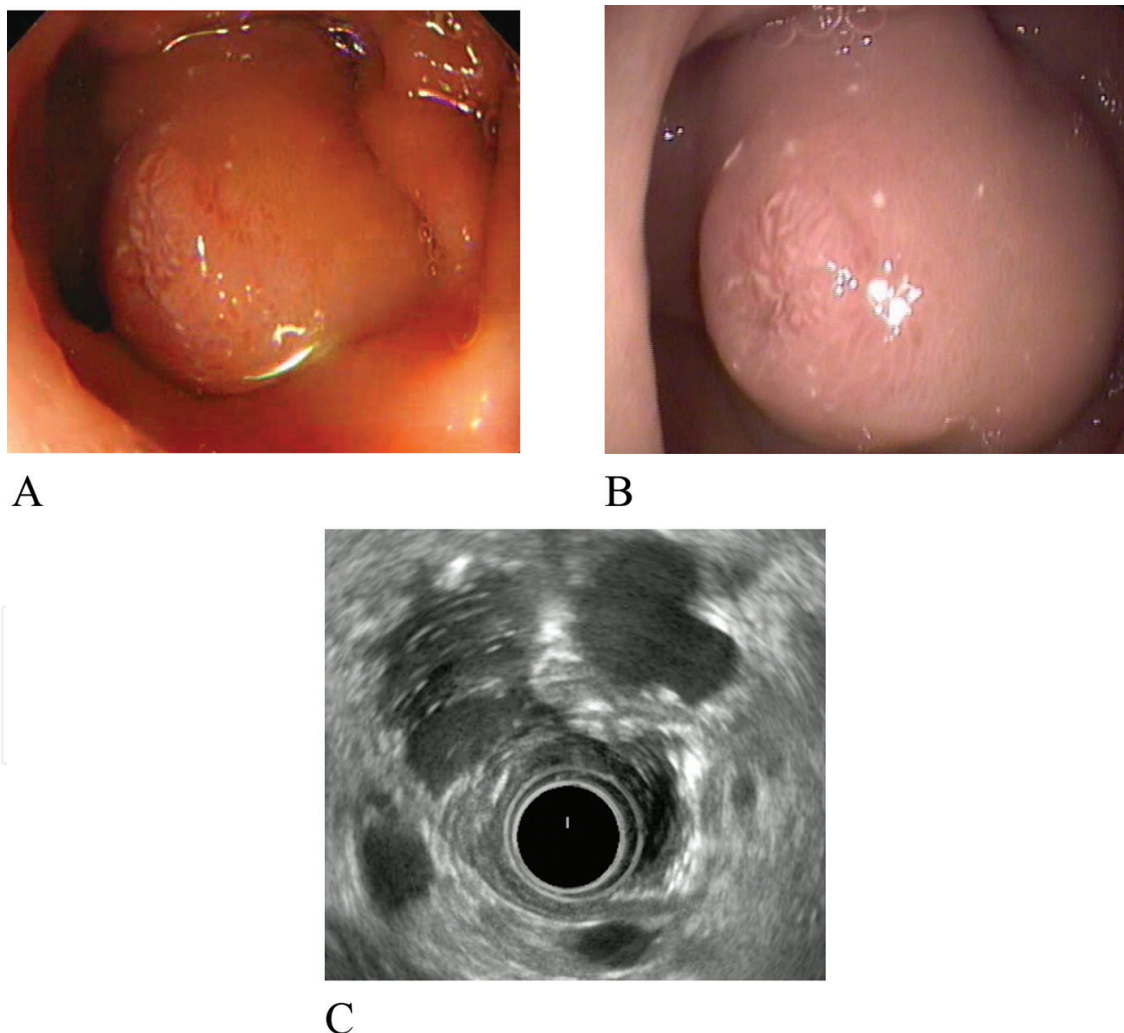
Symptomatic (bleeding)
If the lesion is noted to be growing and enlarged with structural changes during the surveillance period

**Table 6.** Indication of surgical resection.

5.8. Varices

Here, we are talking mainly about gastric varices or those in other areas of the small bowel requiring EUS evaluation (**Figure 6A, B**), compared to esophageal varices, which are obvious by routine endoscopy [89]. Patient history and portal hypertensive gastropathy will usually support diagnoses of varices versus other etiologies of SELs. Gastric varices can be

misdiagnosed endoscopically as submucosal tumors or thickened gastric folds. EUS (**Figure 6C**) will reveal varices as small, round to oval, and anechoic structures or tubular hypoechoic or anechoic structure within the submucosa (the third EUS layer) that demonstrates venous flow when evaluated with Doppler. When gastric varices grow larger, they appear as anechoic, serpentine, tubular structures with smooth margins, accompanied by perigastric collateral vessels. In comparative studies, EUS was shown to be inferior to endoscopy for detecting and grading esophageal varices, but it permitted detection of fundic varices earlier and more often than endoscopy in patients with portal hypertension. EUS can be one of the interventional modalities of bleeding varices. EUS was used in the treatment of varices by making it possible to inject a sclerosing agent into perforating veins. EUS is used to guide cyanoacrylate injection and case reports of EUS-guided coiling of refractory bleeding varices. [90] Also, there is a report about transesophageal EUS-guided treatment of gastric fundic varices. This procedure was shown to be safe and successful in 96% of cases [91].

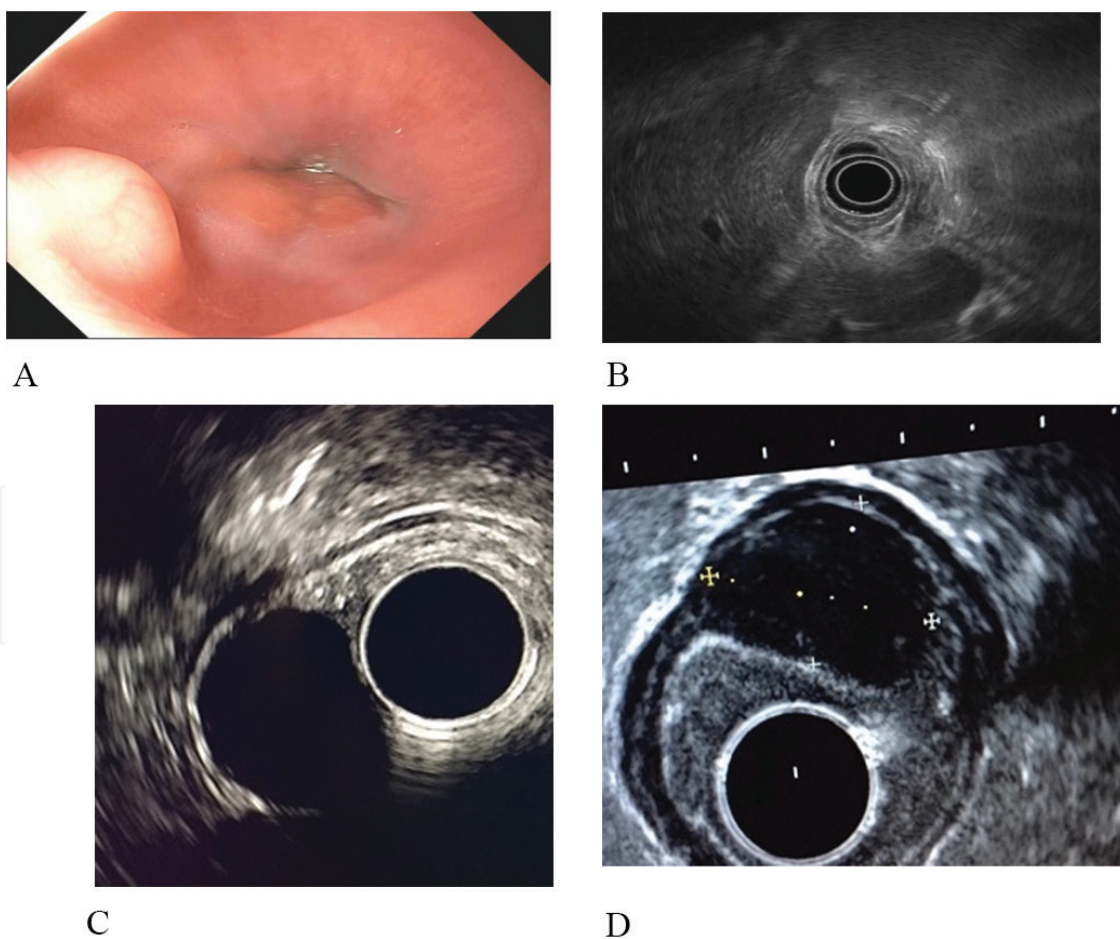


**Figure 6.** Ectopic duodenal varices. (A and B) Endoscopic views of a large bulging mass lesion at the duodenum. (C) EUS confirmed large, anechoic, tubular, submucosal vessels with multiple extramural collateral vascular structures.



### 5.9. Cyst and duplication cysts

Gastrointestinal duplication cysts are also identified throughout adulthood [92]. The cysts are benign lesions resulting from an error in the embryonic development of the foregut and can be found either within or adjacent to the wall of the gastrointestinal tract. The cysts can enlarge with secretions resulting in mass effect, infection, rupture, or bleeding [92]. The stomach is the least common site for GI duplication cysts but they can be anywhere in GI tract. On endoscopy appeared as small and smooth subepithelial lesion (**Figure 7A**) and EUS (**Figure 7B–D**), cysts in the GI tract appear as anechoic sharply demarcated structures, rounded, or ovoid structures with dorsal acoustic accentuation originating from the second and third layers. However, some may be seen as hypoechoic lesions containing echogenic foci. Cystic submucosal tumors can be classified into three EUS types (simple cystic, multicystic, and solid cystic tumors). Duplication cysts on EUS appear as anechoic, homogeneous lesions with regular margins arising from the third layer or extrinsic to the GI wall. The walls of duplication cysts may be seen as three or five layer structures because of the presence of the submucosa and the muscle layer [93]. Duplication cysts are believed to have a low malignant potential, but some case reports have described malignant transformation. Complications are rare and may include dysphagia,



**Figure 7.** Esophageal and gastric cysts: (A) Endoscopic view of a small bulge at the mid-esophagus. (B) EUS revealed a well-demarcated, round, anechoic, within the third layer of esophageal wall. (C and D) EUS images revealed a sharply demarcated, anechoic, ovoid structure within the third gastric wall layer.

abdominal pain, bleeding, and pancreatitis when the cyst is located near the ampulla of Vater. Bronchogenic cysts represent 50–60% of all mediastinal cysts, and they can be diagnosed easily with EUS as anechoic mass without wall layers. EUS-FNA would cause serious complications, including cyst infection and mediastinitis. Antibiotic prophylaxis is therefore needed and close attention should be paid to avoid accidental instrumentation (**Tables 7–9**).

Lesion <1 cm	Annual EGD surveillance
Lesion 1–2 cm	Annual EGD surveillance vs. endoscopic resection if there is no deeper penetration to submucosal layer
Lesion >2 cm	Surgical resection

**Table 7.** Management approach [95].

Type I gastric carcinoid tumors are associated with atrophic gastritis, pernicious anemia and hypergastrinemia	Low malignant potential
Type II gastric carcinoid tumors are also associated with hypergastrinemia, but the high gastrin levels are due to Zollinger-Ellison syndrome or MEN-1 (multiple endocrine neoplasia syndrome, type 1)	Intermediate malignant potential
Type III gastric carcinoid tumors (normal gastrin levels) are the sporadic form	High malignant potential

**Table 8.** Gastric carcinoid tumors [115].

Type I and II	Endoscopic resection for small lesion, <1–2 cm
Type I and II	Surgical resection for large lesions >2 cm or Multiple lesions (>5) Antrectomy or fundectomy (removal of G-cell or ECL) Surveillance every 6–12 months
Type III lesion (normal gastrin level)	Surgical resection with lymph node dissection

**Table 9.** Management of gastric carcinoid tumors.

**5.10. Glomus tumors**

A glomus tumor originates from smooth muscle cells of the glomus body and originates from modified vascular smooth muscle cells, and peripheral soft tissue, [94]. A glomus tumor of the gastrointestinal tract is a rare disease, and most of them are found in the stomach. The majority of gastric glomus tumors are benign and found incidentally as a SEL during routine endoscopy. However, some malignant gastric glomus tumors and cases of ulcerative bleeding have been reported. Contrast-enhanced CT reveals a homogeneous hyperdense enhancement on early and delayed phase. On evaluation by EUS, glomus tumors are shown as a circumscribed and hypoechoic mass internal heterogeneous echo mixed with hyperechogenic in the third or fourth layer [95]. Doppler signals suggest the hypervascularity of these lesions located in the submucosa and muscularis propria—also rarely in the serosa (third, fourth, and fifth EUS layers, respectively). Fine-needle aspiration with cytologic and immunohistochemical staining positive for smooth muscle actin and vimentin and negative for CD117 help to differentiate this lesion [96].

### 5.11. Inflammatory fibroid polyps

Inflammatory fibroid polyp is a rare benign polypoid lesion that is usually found in the stomach, occasionally in the small bowel, and rarely in the esophagus or large bowel [97]. The lesion is located in the second or third layer of the gastric wall, with an intact fourth layer. Sometimes the internal echo pattern is heterogeneous or hyperechoic [98].

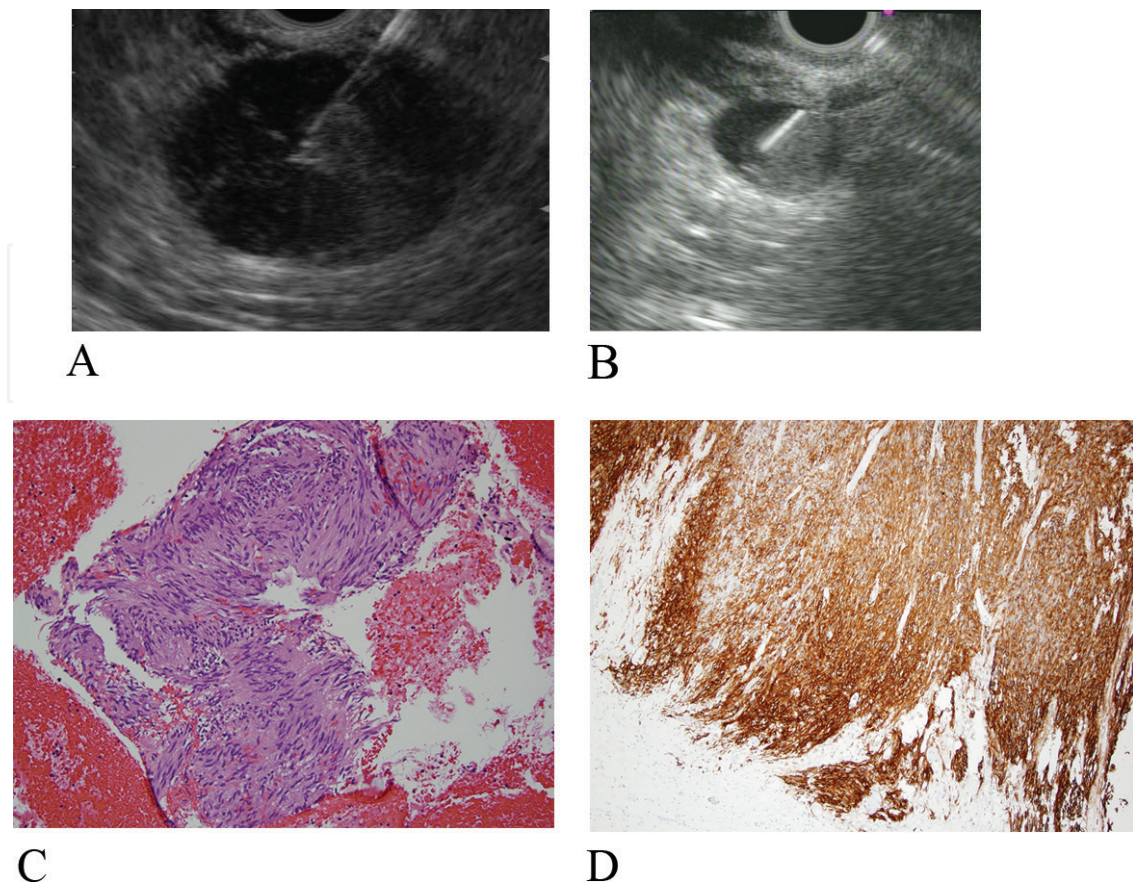
### 5.12. Lymphoma

Primary lymphomas of the GI tract are usually B-cell type lymphomas, including diffuse large B-cell, mantle cell, Burkitt's, and mucosa associated lymphoid tissue (MALT) [99]. Endoscopy with standard biopsies is often not enough for accurate diagnosis. On EUS, a gastrointestinal lymphoma usually appears as a hypoechoic lesion in the deep mucosa or submucosa (second or third EUS layer). EUS is of key importance for diagnosis with FNA can being used for flow cytometry [100].

## 6. Histologic assessment of subepithelial lesions

When the SEL is ulcerated, careful biopsy provides an accurate diagnosis. However, for most SELs, the results of endoscopic biopsy are inconclusive [101]. Trials with a bite-on-bite technique have been undertaken [102, 103]. However, the sensitivity, specificity, and accuracy of cytological evaluations of intramural lesions are all lower than those for SELs in lymph nodes or organs adjacent to the GI tract. It has been reported that the sensitivity of EUS-FNA for mediastinal masses, mediastinal lymph nodes, celiac lymph nodes, pancreatic tumors, and submucosal tumors was 88, 81, 80, 75, and 60%, respectively [104–107]. Subsequent endoscopic resection procedures for these lesions will be difficult. EUS-guided tissue diagnosis is useful for patients with GIST who have metastasis (**Figure 8A, B**). In these studies, no significant difference in diagnostic accuracy was noted according to the size of the FNA needle, but the 25-G needle easily punctured small mobile SELs and the 19-G needle showed excellent differentiation between GIST and leiomyoma by enabling tissue procurement for immunohistochemical studies (**Figure 8C, D**). The average reported accuracy of EUS-FNA in the diagnosis of SELs lesions is approximately 80% [108–110]. The development of new EUS-FNB needles promises better GI SET diagnosis rates [111]. In some later prospective studies, however, the diagnostic yield of EUS-TCB in patients with gastric SELs was not better than that of EUS-FNA, and the tissue core obtained with EUS-TCB was not sufficient to examine for mitotic index in GIST. It is clear though that EUS-TCB can be complementary to EUS-FNA [112]. Complications of EUS-FNA and EUS-TCB are very rare, but can include infection, bleeding and perforation. The newly developed ProCore needle (Cook Endoscopy, Winston-Salem, NC, USA) or Side-Port needle (Olympus, Tokyo, Japan) both appear promising. Core biopsy along with aspiration material is made possible with these types of FNA needles [113]. It is important to note that any form of needle biopsy carries the possibility of sampling error, and a negative finding does not exclude malignancy in GISTs. This diagnostic method should be considered for SETs before determining whether tumors should undergo long-term monitoring or surgical resection.





**Figure 8.** EUS-FNA of a gastric and rectal GIST. (A and B) FNA needle was inserted into the mass and the stylet was removed as the needle was moved back and forth within the lesion. (C) Slide revealed H&E 20× Spindle Cell Neoplasm. (D) Immunohistochemical stains show a positive reaction of the tumor cells for smooth muscle actin and positive of C-KIT.

## 7. Management of subepithelial lesions

Management of SELs can be guided by EUS findings. Extraluminal compression by adjacent organs and benign submucosal lesions such as lipomas or simple cysts do not need further treatment or follow-up. Pancreatic rest and inflammatory fibroid polyps can be followed in situ. Suspicious lesions, such as carcinoid tumors, can be diagnosed with endoscopic biopsy. Biopsy should be avoided in lesions that are suspected varices. For deeply located hypoechoic lesions, EUS-FNA, or EUS-TCB can be performed for tissue diagnosis. If resection is planned, ESD can be used as a therapeutic tool for small mass lesions arising from the submucosal or inner circular muscularis propria layer, instead of surgical resection. Surveillance may be appropriate for SELs without definite tissue diagnosis in patients who are at high operative risk. If the lesion is a suspected GIST, changes in size and echogenicity should be monitored. If the size increases or malignant features (echogenic foci, heterogeneity, internal cystic space, irregularity of extraluminal margins, and adjacent lymphadenopathy) develop, resection should be recommended. The follow-up interval depends on the index of suspicion of the examiner and is usually 1 year. When the characteristics of the lesion do not change on two consecutive follow-up examinations with EUS, a longer follow-up interval may be justified [40, 114, 115].



## 8. Summary

The most common SELs have all been discussed in this chapter. Their characteristics have been summarized and the appropriate diagnostic techniques, therapeutic modalities and immunohistochemical markers used to help in their identification have been reviewed. Most SELs should be referred for EUS evaluation especially if the SEL is more than 1 cm in size. Based on the specific EUS outcomes, majority of the cases a presumptive diagnosis can be made. It is the best test to help and plays an important role in directing further diagnosis and management. EUS-FNA is a good method for tissue diagnosis when a GI SET is suspected. Cytological examination with IHS is essential for the best diagnostic performance in GI SETs. EUS-TCB is good for tissue acquisition, but is associated with some technical challenges. EUS also plays a major role in endoscopic resection because it can enable the examiner to determine the depth and originating wall layer of the lesion. EUS can also be used in the follow-up lesion if it is not resected.

## Author details

Abed Al-Lehibi<sup>1\*</sup> and Khaled Bamakhrama<sup>2</sup>

\*Address all correspondence to: aha0021@gmail.com

1 Gastroenterology and Hepatology Division, King Saud Bin Abdulaziz University-Health Science, Saudi Arabia

2 Dubai Medical College, Rashid Hospital, Dubai, UAE

## References

- [1] Hedenbro JL, Ekelund M, Wetterberg P. Endoscopic diagnosis of submucosal gastric lesions. The results after routine endoscopy. *Surg Endosc.* 1991;5(1):20–3.
- [2] Polkowski M. Endoscopic ultrasound and endoscopic ultrasound-guided fine-needle biopsy for the diagnosis of malignant submucosal tumors. *Endoscopy.* 2005;37(7):635–45.
- [3] Humphris JL, Jones DB. Subepithelial mass lesions in the upper gastrointestinal tract. *J Gastroenterol Hepatol.* 2008 Apr;23(4):556–66.
- [4] Silberhumer GR, Hufschmid M, Wrba F, Gyoeri G, Schoppmann S, Tribl B, Wenzl E, Prager G, Laengle F, Zacherl J. Surgery for gastrointestinal stromal tumors of the stomach. *J Gastrointest Surg.* 2009;13(7):1213–9.
- [5] Park YS, Park SW, Kim TI, Song SY, Choi EH, Chung JB, Kang JK. Endoscopic enucleation of upper-GI submucosal tumors by using an insulated-tip electrosurgical knife. *Gastrointest Endosc.* 2004;59(3):409–15.
- [6] Moon JS. Endoscopic ultrasound-guided fine needle aspiration in submucosal lesion. *Clin Endosc.* 2012;45(2):117–23.

- [7] Sakamoto H, Kitano M, Kudo M. Diagnosis of subepithelial tumors in the upper gastrointestinal tract by endoscopic ultrasonography. *World J Radiol.* 2010;28;2(8):289–97.
- [8] Kim GH, Cho YK, Kim EY, Kim HK, Cho JW, Lee TH, Moon JS; Korean EUS Study Group. Comparison of 22-gauge aspiration needle with 22-gauge biopsy needle in endoscopic ultrasonography-guided subepithelial tumor sampling. *Scand J Gastroenterol.* 2014;49(3):347–54.
- [9] Landi B, Palazzo L. The role of endosonography in submucosal tumours. *Best Pract Res Clin Gastroenterol.* 2009;23(5):679–701.
- [10] Tae HJ, Lee HL, Lee KN, Jun DW, Lee OY, Han DS, Yoon BC, Choi HS, Hahm JS. Deep biopsy via endoscopic submucosal dissection in upper gastrointestinal subepithelial tumors: a prospective study. *Endoscopy.* 2014;46(10):845–50.
- [11] Ji JS, Lee BI, Choi KY, Kim BW, Choi H, Huh M, Chung WC, Chae HS, Chung IS. Diagnostic yield of tissue sampling using a bite-on-bite technique for incidental subepithelial lesions. *Korean J Intern Med.* 2009;24(2):101–5.
- [12] Lee S, Seo DW, Choi JH, Park do H, Lee SS, Lee SK, Kim MH. Evaluation of the feasibility and efficacy of forward-viewing endoscopic ultrasound. *Gut Liver.* 2015;23;9(5):679–84.
- [13] Nesje LB, Laerum OD, Svanes K, Ødegaard S. Subepithelial masses of the gastrointestinal tract evaluated by endoscopic ultrasonography. *Eur J Ultrasound.* 2002;15(1–2):45–54.
- [14] Chak A. EUS in submucosal tumors. *Gastrointest Endosc.* 2002;56(4 Suppl):S43–8.
- [15] Nguyen-Tang T, Shah JN, Sanchez-Yague A, Binmoeller KF. Use of the front-view forward-array echoendoscope to evaluate right colonic subepithelial lesions. *Gastrointest Endosc.* 2010;72(3):606–10.
- [16] Reddymasu SC, Oropeza-Vail M, Pakseresht K, Moloney B, Esfandyari T, Grisolano S, Buckles D, Olyae M. Are endoscopic ultrasonography imaging characteristics reliable for the diagnosis of small upper gastrointestinal subepithelial lesions? *J Clin Gastroenterol.* 2012;46(1):42–5.
- [17] Karaca C, Turner BG, Cizginer S, Forcione D, Brugge W. Accuracy of EUS in the evaluation of small gastric subepithelial lesions. *Gastrointest Endosc.* 2010;71(4):722–7.
- [18] Ji F, Wang ZW, Wang LJ, Ning JW, Xu GQ. Clinicopathological characteristics of gastrointestinal mesenchymal tumors and diagnostic value of endoscopic ultrasonography. *J Gastroenterol Hepatol.* 2008;23(8 Pt 2): e318–24.
- [19] Kwon JG, Kim EY, Kim YS, Chun JW, Chung JT, You SS, Ha HK, Lee CH, Kim HG, Cho CH. [Accuracy of endoscopic ultrasonographic impression compared with pathologic diagnosis in gastrointestinal submucosal tumors]. *Korean J Gastroenterol.* 2005;45(2):88–96.
- [20] Akahoshi K, Sumida Y, Matsui N, Oya M, Akinaga R, Kubokawa M, Motomura Y, Honda K, Watanabe M, Nagaie T. Preoperative diagnosis of gastrointestinal stromal tumor by endoscopic ultrasound-guided fine needle aspiration. *World J Gastroenterol.* 2007;14;13(14):2077–82.

- [21] Polkowski M, Gerke W, Jarosz D, Nasierowska-Guttmejer A, Rutkowski P, Nowecki ZI, Ruka W, Regula J, Butruk E. Diagnostic yield and safety of endoscopic ultrasound-guided trucut [corrected] biopsy in patients with gastric submucosal tumors: a prospective study. *Endoscopy*. 2009;41(4):329–34.
- [22] Chen VK, Eloubeidi MA. Endoscopic ultrasound-guided fine-needle aspiration of intramural and extraintestinal mass lesions: diagnostic accuracy, complication assessment, and impact on management. *Endoscopy*. 2005;37(10):984–9.
- [23] Demetri GD, von Mehren M, Antonescu CR, DeMatteo RP, Ganjoo KN, Maki RG, Pisters PW, Raut CP, Riedel RF, Schuetze S, Sundar HM, Trent JC, Wayne JD. NCCN Task Force report: update on the management of patients with gastrointestinal stromal tumors. *J Natl Compr Canc Netw*. 2010;8(Suppl 2):S1–41.
- [24] Ando N, Goto H, Niwa Y, Hirooka Y, Ohmiya N, Nagasaka T, Hayakawa T. The diagnosis of GI stromal tumors with EUS-guided fine needle aspiration with immunohistochemical analysis. *Gastrointest Endosc*. 2002;55(1):37–43.
- [25] Kida M, Araki M, Miyazawa S, Ikeda H, Takezawa M, Kikuchi H, Watanabe M, Imaizumi H, Koizumi W. Comparison of diagnostic accuracy of endoscopic ultrasound-guided fine-needle aspiration with 22- and 25-gauge needles in the same patients. *J Interv Gastroenterol*. 2011;1(3):102–107.
- [26] Varadarajulu S, Bang JY, Hebert-Magee S. Assessment of the technical performance of the flexible 19-gauge EUS-FNA needle. *Gastrointest Endosc*. 2012;76(2):336–43.
- [27] Polkowski M, Larghi A, Weynand B, Boustière C, Giovannini M, Pujol B, Dumonceau JM, European Society of Gastrointestinal Endoscopy (ESGE). Learning, techniques, and complications of endoscopic ultrasound (EUS)-guided sampling in gastroenterology: European Society of Gastrointestinal Endoscopy (ESGE) Technical Guideline. *Endoscopy*. 2012;44(2):190–206.
- [28] Storch I, Jorda M, Thurer R, Raez L, Rocha-Lima C, Vernon S, Ribeiro A. Advantage of EUS Trucut biopsy combined with fine-needle aspiration without immediate on-site cytopathologic examination. *Gastrointest Endosc*. 2006;64(4):505–11.
- [29] Iglesias-Garcia J, Poley JW, Larghi A, Giovannini M, Petrone MC, Abdulkader I, Monges G, Costamagna G, Arcidiacono P, Biermann K, Rindi G, Bories E, Doglioni C, Bruno M, Dominguez-Muñoz JE. Feasibility and yield of a new EUS histology needle: results from a multicenter, pooled, cohort study. *Gastrointest Endosc*. 2011;73(6):1189–96.
- [30] Shen EF, Arnott ID, Plevris J, Penman ID. Endoscopic ultrasonography in the diagnosis and management of suspected upper gastrointestinal submucosal tumours. *Br J Surg*. 2002;89(2):231–5.
- [31] Goto O, Kambe H, Niimi K, Mochizuki S, Asada-Hirayama I, Minatsuki C, Ono S, Kodashima S, Yamamichi N, Yamaji Y, Fujishiro M, Koike K. Discrepancy in diagnosis of gastric submucosal tumor among esophagogastroduodenoscopy, CT, and endoscopic ultrasonography: a retrospective analysis of 93 consecutive cases. *Abdom Imaging*. 2012;37(6):1074–8.

- [32] Hoteya S, Iizuka T, Kikuchi D, Yahagi N. Endoscopic submucosal dissection for gastric submucosal tumor, endoscopic sub-tumoral dissection. *Dig Endosc*. 2009;21(4):266–9.
- [33] Seo SW, Hong SJ, Han JP, Choi MH, Song JY, Kim HK, Lee TH, Ko BM, Cho JY, Lee JS, Lee MS. Accuracy of a scoring system for the differential diagnosis of common gastric subepithelial tumors based on endoscopic ultrasonography. *J Dig Dis*. 2013;14(12):647–53.
- [34] Hwang JH, Rulyak SD, Kimmey MB; American Gastroenterological Association Institute. American Gastroenterological Association Institute technical review on the management of gastric subepithelial masses. *Gastroenterology*. 2006;130(7):2217–28.
- [35] Larghi A, Fuccio L, Chiarello G, Attili F, Vanella G, Paliani GB, Napoleone M, Rindi G, Larocca LM, Costamagna G, Ricci R. Fine-needle tissue acquisition from subepithelial lesions using a forward-viewing linear echoendoscope. *Endoscopy*. 2014;46(1):39–45.
- [36] Menon L, Buscaglia JM. Endoscopic approach to subepithelial lesions. *Ther Adv Gastroenterol*. 2014;7(3):123–30.
- [37] Hwang JC, Kim JH, Kim JH, Shin SJ, Cheong JY, Lee KM, Yoo BM, Lee KJ, Cho SW. Endoscopic resection for the treatment of gastric subepithelial tumors originated from the muscularis propria layer. *Hepatogastroenterology*. 2009;56(94–95):1281–6.
- [38] Okten RS, Kacar S, Kucukay F, Sasmaz N, Cumhuri T. Gastric subepithelial masses: evaluation of multidetector CT (multiplanar reconstruction and virtual gastroscopy) versus endoscopic ultrasonography. *Abdom Imaging*. 2012;37(4):519–30.
- [39] Zhang QL, Nian WD. Endoscopic ultrasonography diagnosis in submucosal tumor of stomach. *Endoscopy*. 1998;30(Suppl 1):A69–71.
- [40] Hwang JH, Saunders MD, Rulyak SJ, Shaw S, Nietsch H, Kimmey MB. A prospective study comparing endoscopy and EUS in the evaluation of GI subepithelial masses. *Gastrointest Endosc*. 2005;62(2):202–8.
- [41] Rösch T, Kapfer B, Will U, Baronius W, Strobel M, Lorenz R, Ulm K; German EUS Club. Endoscopic ultrasonography. Accuracy of endoscopic ultrasonography in upper gastrointestinal submucosal lesions: a prospective multicenter study. *Scand J Gastroenterol*. 2002;37(7):856–62.
- [42] Futagami K, Hata J, Haruma K, Yamashita N, Yoshida S, Tanaka S, Chayama K. Extracorporeal ultrasound is an effective diagnostic alternative to endoscopic ultrasound for gastric submucosal tumours. *Scand J Gastroenterol*. 2001;36(11):1222–6.
- [43] Oztas E, Oguz D, Kurt M, Etik DO, Cicek B, Kekilli M, Onal IK, Sayilir A, Kacar S, Sahin B. Endosonographic evaluation of patients with suspected extraluminal compression or subepithelial lesions during upper gastrointestinal endoscopy. *Eur J Gastroenterol Hepatol*. 2011;23(7):586–92.
- [44] Miettinen M, Sobin LH, Lasota J. Gastrointestinal stromal tumors of the stomach: a clinicopathologic, immunohistochemical, and molecular genetic study of 1765 cases with long-term follow-up. *Am J Surg Pathol*. 2005;29(1):52–68.



- [45] Kim GH, Park DY, Kim S, Kim DH, Kim DH, Choi CW, Heo J, Song GA. Is it possible to differentiate gastric GISTs from gastric leiomyomas by EUS? *World J Gastroenterol.* 2009;21;15(27):3376–81.
- [46] Jeon SW, Park YD, Chung YJ, Cho CM, Tak WY, Kweon YO, Kim SK, Choi YH. Gastrointestinal stromal tumors of the stomach: endosonographic differentiation in relation to histological risk. *J Gastroenterol Hepatol.* 2007;22(12):2069–75.
- [47] Shah P, Gao F, Edmundowicz SA, Azar RR, Early DS. Predicting malignant potential of gastrointestinal stromal tumors using endoscopic ultrasound. *Dig Dis Sci.* 2009;54(6):1265–9.
- [48] Onishi M, Tominaga K, Sugimori S, Machida H, Okazaki H, Yamagami H, Tanigawa T, Watanabe K, Watanabe T, Fujiwara Y, Arakawa T. Internal hypoechoic feature by EUS as a possible predictive marker for the enlargement potential of gastric GI stromal tumors. *Gastrointest Endosc.* 2012;75(4):731–8.
- [49] Okai T, Minamoto T, Ohtsubo K, Minato H, Kurumaya H, Oda Y, Mai M, Sawabu N. Endosonographic evaluation of c-kit-positive gastrointestinal stromal tumor. *Abdom Imaging.* 2003;28(3):301–7.
- [50] Palazzo L, Landi B, Cellier C, Cuillerier E, Roseau G, Barbier JP. Endosonographic features predictive of benign and malignant gastrointestinal stromal cell tumours. *Gut.* 2000;46(1):88–92.
- [51] Nickl N. Decision analysis of hypoechoic intramural tumor study results. *Gastrointest Endosc.* 2002;56(suppl):S102.
- [52] Kannengiesser K, Mahlke R, Petersen F, Peters A, Ross M, Kucharzik T, Maaser C. Contrast-enhanced harmonic endoscopic ultrasound is able to discriminate benign submucosal lesions from gastrointestinal stromal tumors. *Scand J Gastroenterol.* 2012;47(12):1515–20.
- [53] Sakamoto H, Kitano M, Matsui S, Kamata K, Komaki T, Imai H, Dote K, Kudo M. Estimation of malignant potential of GI stromal tumors by contrast-enhanced harmonic EUS (with videos). *Gastrointest Endosc.* 2011;73(2):227–37.
- [54] DeWitt J, Emerson RE, Sherman S, Al-Haddad M, McHenry L, Cote GA, Leblanc JK. Endoscopic ultrasound-guided Trucut biopsy of gastrointestinal mesenchymal tumor. *Surg Endosc.* 2011;25(7):2192–202.
- [55] Watson RR, Binmoeller KF, Hamerski CM, Shergill AK, Shaw RE, Jaffee IM, Stewart L, Shah JN. Yield and performance characteristics of endoscopic ultrasound-guided fine needle aspiration for diagnosing upper GI tract stromal tumors. *Dig Dis Sci.* 2011;56(6):1757–62.
- [56] Fernández-Esparrach G, Sendino O, Solé M, Pellisé M, Colomo L, Pardo A, Martínez-Pallí G, Argüello L, Bordas JM, Llach J, Ginès A. Endoscopic ultrasound-guided fine-needle aspiration and trucut biopsy in the diagnosis of gastric stromal tumors: a randomized crossover study. *Endoscopy.* 2010;42(4):292–9.

- [57] Sepe PS, Moparty B, Pitman MB, Saltzman JR, Brugge WR. EUS-guided FNA for the diagnosis of GI stromal cell tumors: sensitivity and cytologic yield. *Gastrointest Endosc.* 2009;70(2):254–61.
- [58] Chatzipantelis P, Salla C, Karoumpalis I, Apessou D, Sakellariou S, Doumani I, Papalioudi E, Konstantinou P. Endoscopic ultrasound-guided fine needle aspiration biopsy in the diagnosis of gastrointestinal stromal tumors of the stomach. A study of 17 cases. *J Gastrointest Liver Dis.* 2008;17(1):15–20.
- [59] Hizawa K, Matsumoto T, Kouzuki T, Suekane H, Esaki M, Fujishima M. Cystic submucosal tumors in the gastrointestinal tract: endosonographic findings and endoscopic removal. *Endoscopy.* 2000;32(9):712–4.
- [60] Mochizuki Y, Kodera Y, Fujiwara M, Ito S, Yamamura Y, Sawaki A, Yamao K, Kato T. Laparoscopic wedge resection for gastrointestinal stromal tumors of the stomach: initial experience. *Surg Today.* 2006;36(4):341–7.
- [61] Okubo K, Yamao K, Nakamura T, Tajika M, Sawaki A, Hara K, Kawai H, Yamamura Y, Mochizuki Y, Koshikawa T, Inada K. Endoscopic ultrasound-guided fine-needle aspiration biopsy for the diagnosis of gastrointestinal stromal tumors in the stomach. *J Gastroenterol.* 2004;39(8):747–53.
- [62] Corless CL, Schroeder A, Griffith D, Town A, McGreevey L, Harrell P, Shiraga S, Bainbridge T, Morich J, Heinrich MC. PDGFRA mutations in gastrointestinal stromal tumors: frequency, spectrum and in vitro sensitivity to imatinib. *J Clin Oncol.* 2005;10;23(23):5357–64.
- [63] Hunt GC, Rader AE, Faigel DO. A comparison of EUS features between CD-117 positive GI stromal tumors and CD-117 negative GI spindle cell tumors. *Gastrointest Endosc.* 2003;57(4):469–74.
- [64] Fletcher CD, Berman JJ, Corless C, Gorstein F, Lasota J, Longley BJ, Miettinen M, O’Leary TJ, Remotti H, Rubin BP, Shmookler B, Sobin LH, Weiss SW. Diagnosis of gastrointestinal stromal tumors: a consensus approach. *Hum Pathol.* 2002;33(5):459–65.
- [65] Seremetis MG, Lyons WS, deGuzman VC, Peabody JW Jr. Leiomyomata of the esophagus. An analysis of 838 cases. *Cancer.* 1976;38(5):2166–77.
- [66] Lee LS, Singhal S, Brinster CJ, Marshall B, Kochman ML, Kaiser LR, Kucharczuk JC. Current management of esophageal leiomyoma. *Am Coll Surg.* 2004;198(1):136–46.
- [67] Fernandez MJ, Davis RP, Nora PF. Gastrointestinal lipomas. *Arch Surg.* 1983;118(9):1081–3.
- [68] Parmar JH, Lawrence R, Ridley NT. Submucous lipoma of the ileocaecal valve presenting as caecal volvulus. *Int J Clin Pract.* 2004;58(4):424–5.
- [69] Watanabe F, Honda S, Kubota H, Higuchi R, Sugimoto K, Iwasaki H, Yoshino G, Kanamaru H, Hanai H, Yoshii S, Kaneko E. Preoperative diagnosis of ileal lipoma by endoscopic ultrasonography probe. *J Clin Gastroenterol.* 2000;31(3):245–7.
- [70] Zhou PH, Yao LQ, Zhong YS, et al. Role of endoscopic miniprobe ultrasonography in diagnosis of submucosal tumor of large intestine. *World J Gastroenterol.* 2004;15;10(16):2444–6.

- [71] Buscaglia JM, et al. Diagnostic yield and safety of jumbo biopsy forceps in patients with sub-epithelial lesions of the upper and lower GI tract. *Gastrointest Endosc.* 2012;75(6):1147–52.
- [72] Thompson WM, Kende AI, Levy AD. Imaging characteristics of gastric lipomas in 16 adult and pediatric patients. *AJR Am J Roentgenol.* 2003 Oct;181(4):981–5.
- [73] Garcia M, Buitrago E, Bejarano PA, Casillas J. Large esophageal liposarcoma: a case report and review of the literature. *Arch Pathol Lab Med.* 2004;128(8):922–5.
- [74] Yoshizawa A, Ota H, Sakaguchi N, Kanai S, Nakayama J, Matsuzawa K, Tsuzuki S, Takada R, Miyazawa F, Kasahara H, Katsuyama T. Malignant granular cell tumor of the esophagus. *Virchows Arch.* 2004;444(3):304–6.
- [75] Prematilleke IV, Piris J, Shah KA. Fine needle aspiration cytology of a granular cell tumour of the oesophagus. *Cytopathology.* 2004;15(2):120–1.
- [76] De Ceglie A, Gatteschi B, Bianchi S, Scotto F, Pellicchia A, Conio M. Esophageal granular cell tumor treated by endoscopic mucosal resection. A case report and review of the literature. *Dig Dis Sci.* 2005;50(10):1875–9.
- [77] Jovanovic I, Knezevic S, Micev M, Krstic M. EUS mini probes in diagnosis of cystic dysplasia of duodenal wall in heterotopic pancreas: a case report. *World Gastroenterol.* 2004;1;10(17):2609–12.
- [78] Matsushita M, Hajiro K, Okazaki K, Takakuwa H. Gastric aberrant pancreas: EUS analysis in comparison with the histology. *Gastrointest Endosc.* 1999;49(4 Pt 1):493–7.
- [79] Shalaby M, Kochman ML, Lichtenstein GR. Heterotopic pancreas presenting as dysphagia. *Am J Gastroenterol.* 2002;97(4):1046–9.
- [80] Faigel DO, Gopal D, Weeks DA, Corless C. Cap-assisted endoscopic submucosal resection of a pancreatic rest. *Gastrointest Endosc.* 2001;54(6):782–4.
- [81] Modlin IM, Lye KD, Kidd M. A 5-decade analysis of 13,715 carcinoid tumors. *Cancer.* 2003;15;97(4):934–59.
- [82] Modlin IM, Lye KD, Kidd M. A 50-year analysis of 562 gastric carcinoids: small tumor or larger problem? *Am J Gastroenterol.* 2004;99(1):23–32.
- [83] Soga J. Early-stage carcinoids of the gastrointestinal tract: an analysis of 1914 reported cases. *Cancer.* 2005;15;103(8):1587–95.
- [84] Ichikawa J, Tanabe S, Koizumi W, Kida Y, Imaizumi H, Kida M, Saigenji K, Mitomi H. Endoscopic mucosal resection in the management of gastric carcinoid tumors. *Endoscopy.* 2003;35(3):203–6.
- [85] Kwaan MR, Goldberg JE, Bleday R. Rectal carcinoid tumors: review of results after endoscopic and surgical therapy. *Arch Surg.* 2008;143(5):471–5.
- [86] Kobayashi K, Katsumata T, Yoshizawa S, Sada M, Igarashi M, Saigenji K, Otani Y. Indications of endoscopic polypectomy for rectal carcinoid tumors and clinical usefulness of endoscopic ultrasonography. *Dis Colon Rectum.* 2005;48(2):285–91.

- [87] Modlin IM, Kidd M, Latich I, Zikusoka MN, Shapiro MD. Current status of gastrointestinal carcinoids. *Gastroenterology*. 2005;128(6):1717–51.
- [88] Ramage JK, et al. Guidelines for the management of gastroenteropancreatic neuroendocrine (including carcinoid) tumours. *Gut*. 2005;54(Suppl 4):1–16.
- [89] Romero-Castro R, Pellicer-Bautista FJ, Jimenez-Saenz M, Marcos-Sanchez F, Caunedo-Alvarez A, Ortiz-Moyano C, Gomez-Parra M, Herrerias-Gutierrez JM. EUS-guided injection of cyanoacrylate in perforating feeding veins in gastric varices: results in 5 cases. *Gastrointest Endosc*. 2007;66(2):402–7.
- [90] Levy MJ, Wong Kee Song LM, Kendrick ML, Misra S, Gostout CJ. EUS-guided coil embolization for refractory ectopic variceal bleeding (with videos). *Gastrointest Endosc*. 2008;67(3):572–4.
- [91] Binmoeller KF, Weilert F, Shah JN, Kim J. EUS-guided transesophageal treatment of gastric fundal varices with combined coiling and cyanoacrylate glue injection (with videos). *Gastrointest Endosc*. 2011;74(5):1019–25.
- [92] Ott DJ, Wolfman NT, Wu WC, Chen MY, White WL. Endoscopic ultrasonography of benign esophageal cyst simulating leiomyoma. *J Clin Gastroenterol*. 1992;15:85–7.
- [93] Faigel DO, Burke A, Ginsberg GG, Stotland BR, Kadish SL, Kochman ML. The role of endoscopic ultrasound in the evaluation and management of foregut duplications. *Gastrointest Endosc*. 1997;45(1):99–103.
- [94] Baek YH, Choi SR, Lee BE, Kim GH. Gastric glomus tumor: analysis of endosonographic characteristics and computed tomographic findings. *Dig Endosc*. 2013;25(1):80–3.
- [95] Yan SL, Yeh YH, Chen CH, Yang CC, Kuo CL, Wu HS. Gastric glomus tumor: a hypervascular submucosal tumor on power Doppler endosonography. *J Clin Ultrasound*. 2007;35(3):164–8.
- [96] Tang M, Hou J, Wu D, Han XY, Zeng MS, Yao XZ. Glomus tumor in the stomach: computed tomography and endoscopic ultrasound findings. *World J Gastroenterol*. 2013;28;19(8):1327–9.
- [97] Matsushita M, Hajiro K, Okazaki K, Takakuwa H. Endoscopic features of gastric inflammatory fibroid polyps. *Am J Gastroenterol*. 1996;91(8):1595–8.
- [98] Matsushita M, Hajiro K, Okazaki K, Takakuwa H. Gastric inflammatory fibroid polyps: endoscopic ultrasonographic analysis in comparison with the histology. *Gastrointest Endosc*. 1997;46(1):53–7.
- [99] Brooks JJ, Enterline HT. Primary gastric lymphomas. A clinicopathologic study of 58 cases with long-term follow-up and literature review. *Cancer*. 1983;15;51(4):701–11.
- [100] Bolondi L, Casanova P, Caletti GC, Grigioni W, Zani L, Barbara L. Primary gastric lymphoma versus gastric carcinoma: endoscopic US evaluation. *Radiology*. 1987;165(3):821–6.
- [101] Kim EY. Diagnosis of subepithelial lesion: still “tissue is the issue”. *Clin Endosc*. 2013;46(4):313–4.



- [102] Lee CK, Chung IK, Lee SH, Lee SH, Lee TH, Park SH, Kim HS, Kim SJ, Cho HD. Endoscopic partial resection with the unroofing technique for reliable tissue diagnosis of upper GI subepithelial tumors originating from the muscularis propria on EUS (with video). *Gastrointest Endosc.* 2010;71(1):188–94.
- [103] Pellisé Urquiza M, Fernández-Esparrach G, Solé M, Colomo L, Castells A, Llach J, Mata A, Bordas JM, Piqué JM, Ginès A. Endoscopic ultrasound-guided fine needle aspiration: predictive factors of accurate diagnosis and cost-minimization analysis of on-site pathologist. *Gastroenterol Hepatol.* 2007;30(6):319–24.
- [104] Eckardt AJ, Adler A, Gomes EM, Jenssen C, Siebert C, Gottschalk U, Koch M, Röcken C, Rösch T. Endosonographic large-bore biopsy of gastric subepithelial tumors: a prospective multicenter study. *Eur J Gastroenterol Hepatol.* 2012;24(10):1135–44.
- [105] Çağlar E, Hatemi I, Atasoy D, Şişman G, Sentürk H. Concordance of endoscopic ultrasonography-guided fine needle aspiration diagnosis with the final diagnosis in subepithelial lesions. *Clin Endosc.* 2013;46(4):379–83.
- [106] Rong L, Kida M, Yamauchi H, Okuwaki K, Miyazawa S, Iwai T, Kikuchi H, Watanabe M, Imaizumi H, Koizumi W. Factors affecting the diagnostic accuracy of endoscopic ultrasonography-guided fine-needle aspiration (EUS-FNA) for upper gastrointestinal submucosal or extraluminal solid mass lesions. *Dig Endosc.* 2012;24(5):358–63.
- [107] Suzuki T, Arai M, Matsumura T, Arai E, Hata S, Maruoka D, Tanaka T, Nakamoto S, Imazeki F, Yokosuka O. Factors associated with inadequate tissue yield in EUS-FNA for gastric SMT. *ISRN Gastroenterol.* 2011;2011:619128.
- [108] Mekky MA, Yamao K, Sawaki A, Mizuno N, Hara K, Nafeh MA, Osman AM, Koshikawa T, Yatabe Y, Bhatia V. Diagnostic utility of EUS-guided FNA in patients with gastric submucosal tumors. *Gastrointest Endosc.* 2010;71(6):913–9.
- [109] Hoda KM, Rodriguez SA, Faigel DO. EUS-guided sampling of suspected GI stromal tumors. *Gastrointest Endosc.* 2009;69(7):1218–23.
- [110] Savides TJ, Donohue M, Hunt G, Al-Haddad M, Aslanian H, Ben-Menachem T, Chen VK, Coyle W, Deutsch J, DeWitt J, Dhawan M, Eckardt A, Eloubeidi M, Esker A, Gordon SR, Gress F, Ikenberry S, Joyce AM, Klapman J, Lo S, Maluf-Filho F, Nickl N, Singh V, Wills J, Behling C. EUS-guided FNA diagnostic yield of malignancy in solid pancreatic masses: a benchmark for quality performance measurement. *Gastrointest Endosc.* 2007;66(2):277–82.
- [111] Moon JS. Role of endoscopic ultrasonography in guiding treatment plans for upper gastrointestinal subepithelial tumors. *Clin Endosc.* 2016;49(3):220–5.
- [112] Săftoiu A, Vilman P, Guldhammer Skov B, Georgescu CV. Endoscopic ultrasound (EUS)-guided Trucut biopsy adds significant information to EUS-guided fine-needle aspiration in selected patients: a prospective study. *Scand J Gastroenterol.* 2007;42(1):117–25.
- [113] Kaffes AJ, Chen RY, Tam W, Norton I, Cho S, Devereaux B, Vaughan R. A prospective multicenter evaluation of a new side-port endoscopic ultrasound-fine-needle aspiration in solid upper gastrointestinal lesions. *Dig Endosc.* 2012;24(6):448–51.

- [114] Lee HL. Advances in the management of upper gastrointestinal subepithelial tumor: pathologic diagnosis using endoscopy without endoscopic ultrasound-guided biopsy. *Clin Endosc.* 2016;49(3):216–9.
- [115] Jeong ID, Jung SW, Bang SJ, Shin JW, Park NH, Kim DH. Endoscopic enucleation for gastric subepithelial tumors originating in the muscularis propria layer. *Surg Endosc.* 2011;25(2):468–74.

