

We are IntechOpen, the world's leading publisher of Open Access books Built by scientists, for scientists

6,900

Open access books available

185,000

International authors and editors

200M

Downloads

Our authors are among the

154

Countries delivered to

TOP 1%

most cited scientists

12.2%

Contributors from top 500 universities



WEB OF SCIENCE™

Selection of our books indexed in the Book Citation Index
in Web of Science™ Core Collection (BKCI)

Interested in publishing with us?
Contact book.department@intechopen.com

Numbers displayed above are based on latest data collected.
For more information visit www.intechopen.com



Surgical Techniques for Treatment of Unilateral Cleft Lip

Mustafa Chopan, Lohrasb Sayadi and
Donald R. Laub

Additional information is available at the end of the chapter

<http://dx.doi.org/10.5772/67124>

Abstract

A surgeon intending habilitation of a child with cleft lip should be familiar with the normal anatomy of the lip and nose, the distortions introduced by the cleft deformity, and the many techniques available to employ those best suited to correction of that child's deformity.

Keywords: surgical techniques, cleft lip, cleft surgery

1. Introduction

"Whatever is worth doing at all is worth doing well."

—Philip Stanhope, 4th Earl of Chesterfield

The treatment of children with cleft lip deformity has long challenged surgeons. Numerous surgical techniques have been developed to restore function, symmetry, and aesthetics. Early surgical techniques in treatment of cleft lip deformity involved straight-line repairs were limited in restoring symmetry to the lip of a child with unilateral cleft lip. LeMesurier and Tennyson developed the use of flaps that allowed reconstruction of the cupid's bow of the lip. Millard's technique of "rotation-advancement" brought about the modern era of cleft lip reconstruction. Later refinements by Salyer, Noordhoff, Cutting, and others have allowed the surgeon to more effectively restore function, symmetry, and aesthetics

2. Normal anatomy

"All cleft surgery is merely applied embryology."

—Victor Veau [1]

The pathologic origins of a cleft lip are traceable to distinct embryological events. The fusion failure during gestational weeks 4–7 of facial primordia: the central frontonasal prominence and two lateral maxillary prominences result in a typical cleft lip of a newborn. Advances in developmental science have promoted our knowledge and understanding of this phenomenon, helping to guide diagnosis and surgical reconstruction; however, craniofacial embryology is beyond the scope of this chapter.

It is important to note that cleft lip and palate is considered a distinct entity from isolated cleft palate, the difference chiefly characterized by the location of the cleft palate anterior or posterior to incisive foramen, respectively. Soft-tissue and bony deficiencies are variable with accompanying nasal distortion (**Figure 1**). Surgical management hinges upon the accurate identification of involved structures and methodical attention to detail in surgical techniques in reconstruction.

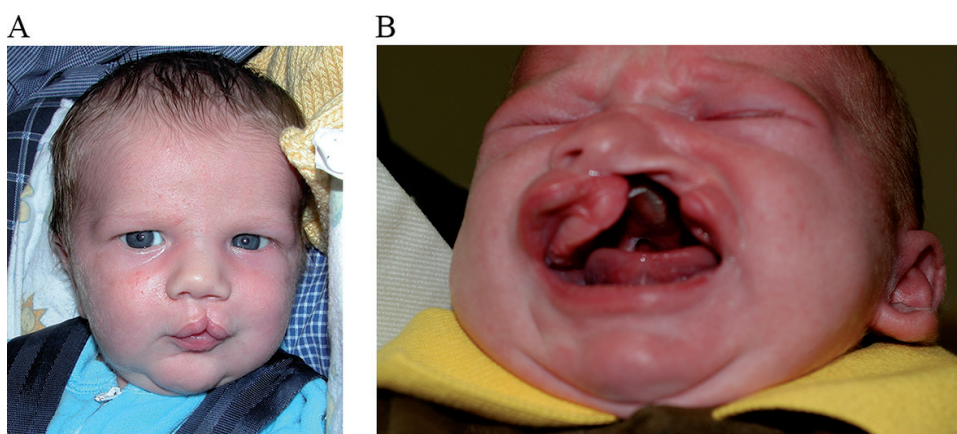


Figure 1. (A) A child with a microform or “forme fruste” cleft lip, demonstrating vermilion notching, scar-like depression. (B) A child with a complete unilateral cleft lip, demonstrating tissue hypoplasia and asymmetry.

2.1. Normal anatomy of the lip

The layers of the lip include the skin, a thin layer of subcutaneous tissue, orbicularis oris and other facial muscles, and mucosa. The vermilion is a unique tissue consisting of modified mucosa, and the white roll is a ridge at the junction of the vermilion and the lip skin. The lips are divided into four aesthetic subunits: the philtrum, two lateral wings (from the philtral columns to the nasolabial folds), and the entire lower lip.

Muscles of the upper lip include orbicularis oris, levator labii superioris alaeque nasi, zygomaticus major and minor, levator labii superioris, and nasalis. The orbicularis oris consists of superficial and deep layers. The deep fibers run circumferentially between modiolus and function as the primary sphincter in feeding. The superficial fibers originate from the ipsilateral modiolus and run obliquely toward midline, interdigitating with the other muscles of facial expression and inserting into the dermis. The superficial fibers are further distinguished into either superior fibers (pars peripheralis) or inferior fibers (pars marginalis) of the upper lip. The pars marginalis courses along the vermilion border connect with the contralateral pars marginalis fibers at midline and inserts into the region of the vermilion tubercle. The pars peripheralis has a flat-fan shape diffusing out from each modiolus, and inserting into the skin of the contralateral philtral ridge [2]. Two other distinct fibers of the pars peripheralis have

also been identified using micro-computed tomography [3]. One bundle terminates at the tissue below the ipsilateral anterior nasal spine, in continuation with depressor septi. The other bundle crosses midline and continues with the alar portion of nasalis muscle. The decussation of fibers creates the philtral columns, and lack of insertion at the midline creates the philtral depression.

Superficial layers of the levator labii superioris alaeque nasi, zygomaticus minor, and levator labii superioris cross the nasolabial groove and migrate toward the superficial orbicularis. The levator labii superioris alaeque nasi originates from the upper face, enters the upper lip superior and lateral to the ipsilateral philtral column, and descends on the medial side of the column. A bundle of fibers terminate in the dermis of the lateral aspect of the ipsilateral philtral column. Another bundle of short and long fibers terminates in the skin of the vermilion border; however, the long fibers interlock with the pars marginalis before their insertion. Thus the lip peak of the vermilion border, which creates cupid's bow, is due to a balance of muscular tension between the pars marginalis and levator labii superioris alaeque nasi.

Superficial reticular fibers of the levator labii superioris alaeque nasi, zygomaticus major and minor, levator labii superioris, and orbicularis oris insert into the medial philtrum ridge. The intersection of these fibers and the contralateral orbicularis oris forms the philtral column. The bulging appearance of the region lateral to the philtral column, however, results from a greater number of muscle insertions into the lateral skin than to the philtral dimple [4] (**Figure 2A**).

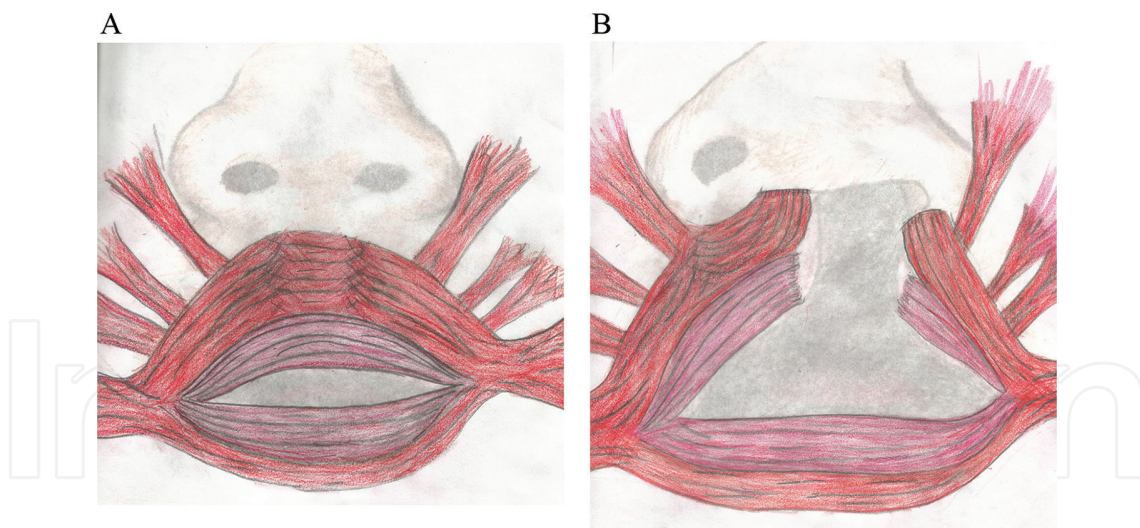


Figure 2. (A) A schematic representation of the orbicularis oris, demonstrating symmetry and continuity. (B) A schematic representation of the orbicularis oris affected by a cleft, demonstrating asymmetry and discontinuity.

2.2. Normal anatomy of the nose

The nose can be divided into anatomical thirds. The proximal third consists of the paired nasal bones and bony septum (vomer, perpendicular plate of ethmoid, nasal crest of maxilla and palatine bone). Upper lateral cartilages and cartilaginous septum comprise the middle third. Lower lateral cartilages, the tip, and caudal cartilaginous septum form the lower third of the nose. The lower lateral cartilages consist of the medial, middle, and lateral crura

(Figure 3A). The scroll area refers to the overlapping of lateral crura with the caudal edge of upper lateral cartilages. The nasalis muscle originates at the incisive fossa and inserts into four different regions. The transverse part courses past the alar base around the lateral side of the nose, and ascends medially to join procerus and the contralateral transverse fibers at midline. Fibers that course around the alar rim and above the lower lateral cartilages are the alar portion of nasalis. The columella and basal parts insert in the membranous septum, medial crura, and nostril sill skin. The columellar part of nasalis is synonymous with depressor septi.

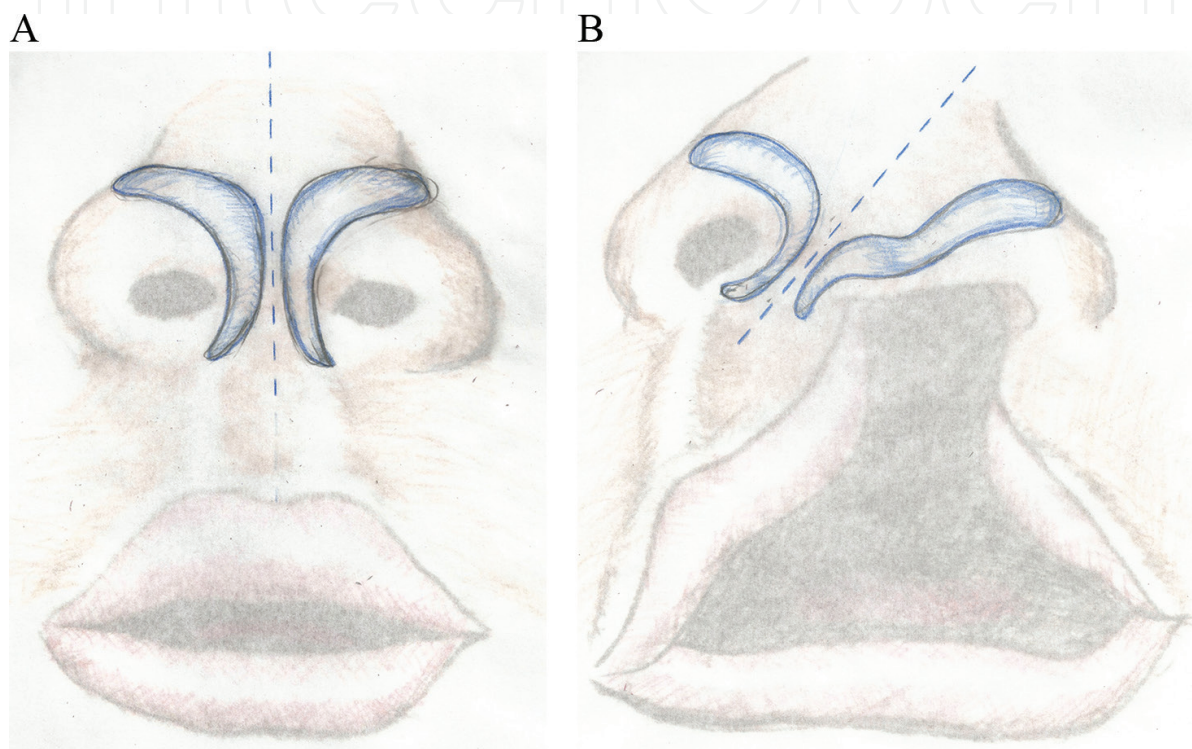


Figure 3. (A) A schematic representation of the lower lateral cartilages demonstrating symmetry. (B) A schematic representation of the lower lateral cartilages demonstrating asymmetry: a short medial crus, an obtuse genu, and a lateral crus that is longer and drawn into an S-shaped fold on the cleft side.

The facial artery is the main blood supply to the upper and lower lips. The facial artery travels through the cheek beneath zygomaticus major and superficial to buccinator muscles, giving rise to the inferior and superior labial arteries. Once the superior labial artery emerges from the zygomaticus major, it may dive into the substance of the orbicularis oris, giving rise to the ipsilateral columellar artery. After giving rise to the superior labial artery, the facial artery terminates as the angular artery. The lateral nasal artery is a branch of the angular artery.

3. Abnormal anatomy of unilateral cleft deformity: muscle imbalance, tissue hypoplasia, and skeletal asymmetry

"If you can articulate a problem, it is 98% solved."

—Edwin Land

The severity of a unilateral cleft lip varies from the microform (**Figure 1A**) to a complete cleft extending into the nasal sill (**Figure 1B**). Varying degrees of nasal deformity and alveolar deficiency may also be present [5, 6]. There is varying degree of absence of central lip, philtral and nasal columella tissue [7].

The unilateral cleft typically results in a disruption of cupid's bow and the absence of one philtral column. The continuity of the orbicularis oris circumferentially is compromised, with abnormal insertions. In the lateral lip element, the upper part of cutaneous orbicularis (Pars Superficialis) inserts in the lateral aspect of the alar base and the nasolabial fold, while the lower part inserts into the nostril base periosteum of the pyriform rim. In the medial lip element, the cutaneous orbicularis (pars superficialis) inserts into the anterior nasal spine and columella. The deep orbicularis (pars marginalis) is simply interrupted by the cleft deficiency and results in a diminished vermillion-cutaneous ridge at the cleft margin (**Figure 2B**).

Anatomical characteristics of unilateral cleft lip include nasal deformities of the tip, columella, nostril, alar base, septum, and skeleton. The lower lateral cartilages on the cleft side have a short medial crus, an obtuse genu, and a lateral crus that is longer and drawn into an S-shaped fold (**Figure 3B**). The caudal septum is deviated toward the noncleft side. The nasal tip is typically directed toward the noncleft side [8]. In addition, the columella is shorter on the cleft side with deviation toward the noncleft side due to the unopposed action of the orbicularis oris. The alar base is more horizontal on the cleft side with deviation of the nasal septum toward the noncleft side. The alar base on the cleft side is positioned laterally, inferiorly, and posteriorly.

Nasal deformities in a unilateral cleft lip-nose arise from this cartilage deformity, muscle imbalance, and skeletal hypoplasia [5]. The various deformities are listed here:

1. Alar base displacement posteriorly and inferiorly, causing a flattening of the dome
2. Lateral crus of the alar cartilage and underlying skin is drawn to an S-shaped fold
3. Short medial crus of the alar cartilage on the cleft side
4. Columellar deviation toward the noncleft side and shortening on the cleft side
5. Nasal tip displacement and asymmetry
6. Caudal septum and anterior nasal spine displacement toward the noncleft side, with deviation to the cleft-side airway causing obstruction
7. Inferior turbinate hypertrophy of the cleft side
8. Hypoplastic maxillary segment and displacement on the cleft side
9. Nasal floor is lowered or absent
10. Nasal pyramid asymmetry

4. Goals of surgical repair

"If you know what you value, then making a decision is easy."

—Walt Disney

The goals of unilateral cleft lip repair are both functional and aesthetic. In order to address these goals, one must understand the anatomical characteristics of unilateral cleft lip. Aesthetically the goals of surgical intervention include formation of lip continuity, establishing symmetry of the cupid's bow and the nose in a manner that places scars in less discernable areas. Recreation of the orbicularis muscle to circumferentially surround the opening of the oral cavity is important for long-lasting cosmetic outcomes and lip and mouth function. Patients with isolated cleft lip rarely have feeding problems, unlike those with cleft palate. However, enrolling the child in a multidisciplinary clinic is advised to address the needs of each patient and family.

5. Preoperative tissue mobilization

"Success depends on preparation, and without preparation, there is failure."

—Confucius

The goal of preoperative tissue mobilization is to lessen the soft tissue and bony cleft and accompanying deformities prior to definitive surgical treatment. Preoperative improvement facilitates surgical repair and results in better outcomes.

5.1. Adhesive tape

Pool and Farnworth advocated the use of adhesive tape for soft tissue mobilization prior to surgical repair of unilateral and bilateral clefts. Long strips were applied from cheek to cheek for 6 weeks prior to surgery (**Figure 4**). They found a 53% average reduction in alveolar gaps, and lip segment narrowing from 40% to complete apposition [9].

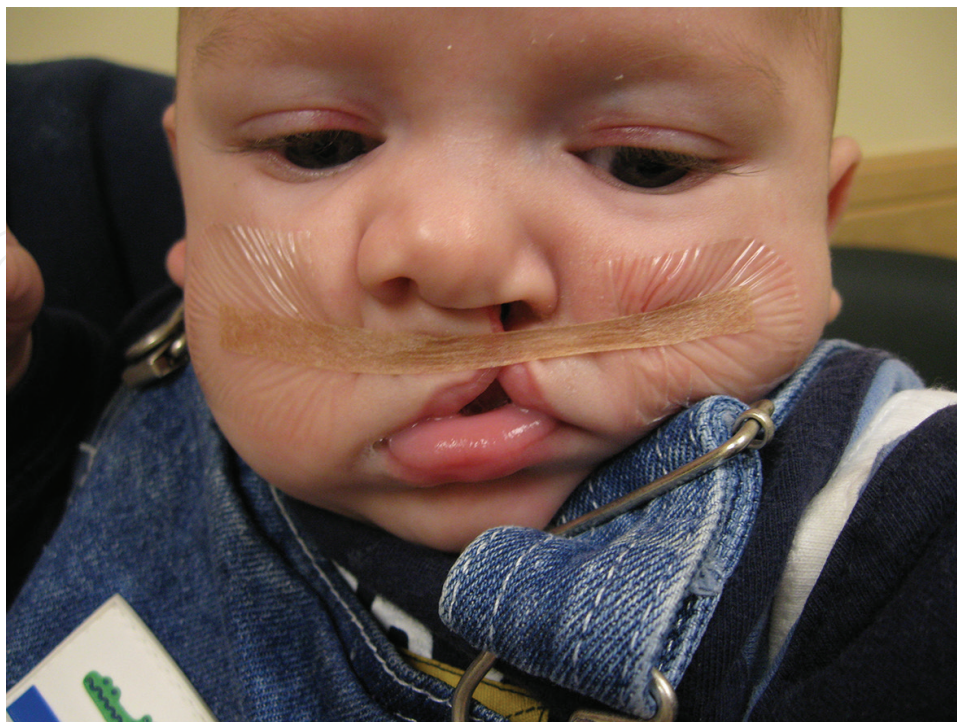

Figure 4. A child with a complete unilateral cleft lip, with adhesive tape therapy in place. This is the same child in **Figure 1B**. Note the mobilization of soft tissue.

5.2. Nasoalveolar molding

Alveolar molding is performed with an intraoral appliance to align the maxillary alveolar segments and narrow the cleft. Latham developed an active orthopedic device consisting of methyl methacrylate bases attached to the palatine bone with metal pins, and connected by a screw [10, 11]. Turning of the screw exerts an anterior force on the cleft-side segment, narrowing the gap.

Grayson and the NYU group employ presurgical molding, using the nasoalveolar molding (NAM), a passive orthodontic appliance [12, 13]. An acrylic orthodontic plate is fitted to cover the entire maxillary arch, with two buttons placed at 45° angle to the occlusal plane. Circular elastics are attached from the buttons and to steristrips on the face bilaterally (**Figure 5**). Every 1–2 weeks the orthodontist adjusts the device small amounts by removing and adding acrylic. Once the alveolar gap measures less than 5 mm, a nasal stent is added to the appliance by wire extending from the plate. The stent is positioned under the soft triangle, and periodically augmented by adding soft acrylic. This tissue-expansion effect molds the alar cartilage and lengthens the columella with the goal of increasing tip projection.

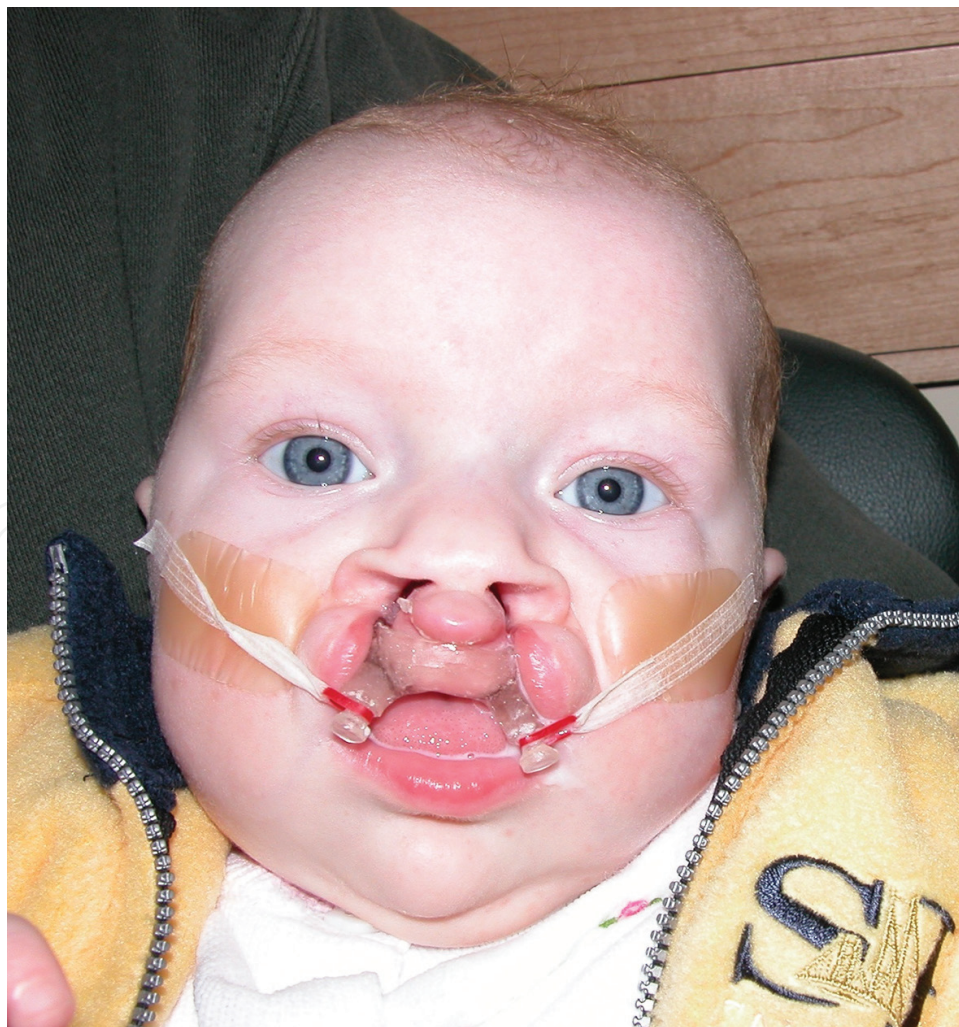

Figure 5. A child with a complete bilateral cleft lip, with an NAM device in place.

5.3. Surgical lip adhesion

Lip adhesion is a first surgical stage in a two-stage reconstruction developed by Randall [14]. A lip after adhesion not only molds the alveolar segments, but also improves nasal contour and vertical lip height of both medial and lateral segments. The disadvantages of a two-stage surgical repair include an additional procedure and scarring, possibly making dissection more difficult during the second, definitive surgery. Randall made incisions on the vermilion of the medial and lateral lip elements. On the lateral lip element, supraperiosteal dissection is performed through a buccal incision. Subcutaneous dissection is performed on the medial segment to the nasal tip, allowing for mobilization of the cleft-side lower lateral cartilage independent from rest of the nose. Mattress sutures are passed through the medial cleft margin incision, through the orbicularis oris and buccal mucosa. The mucosal flaps are then closed in layered fashion.

6. Surgical techniques of unilateral cleft lip repair

“Things done well, and with a care, exempt themselves from fear.”

— William Shakespeare

In unilateral cleft repairs, regardless of the name assigned, except for straight-line techniques, have an oblique medial incision to correct the nasal malposition and drop the cupid's bow into a horizontal posture [15]. If the lateral segment is contoured to interpolate a congruent tissue flap, the repair can be conceptualized as a Z-plasty. We have categorized lip repairs in this chapter by the level at which in the tissue is interpolated.

6.1. Straight-line repairs

6.1.1. Early repairs [16, 17]

Ambroise Paré described a straight-line repair for cleft lip in 1575. He excised the skin margins of the cleft with a razor, freeing the lip elements from the upper jaw and joining them together by transfixing the edges of the cleft with a needle and securing the needle with thread in a figure of eight pattern. In 1570 Gaspar Tagliacozzi of Bologna described excoriating the cleft edges and using interrupted sutures to close the cleft.

6.1.2. Rose-Thompson (et al.) principle

Some of the earliest changes in cleft lip repair were based on modifications to the straight line repair to increase the vertical length of the lip. In 1879, William Rose developed a design for cleft lip closure using curved incisions mutually concave from nostril to vermilion at a 60° angle [18]. This method was significant as it lengthened the union of the two cleft margins (**Figure 6**).

Later, James E. Thompson who aspired to reproduce a natural cupid's bow designed his paring procedure in a shape of a diamond excision. He emphasized the need for accurate markings for precise matching of the cleft sides when brought together [19]. In addition, when the vermilion thickness varied, Thompson altered the angle of his incisions to balance

the vermillion closure [20]. Victor Veau performed a modified straight-line closure, where on the noncleft side he excised the mucosa just distal to the mucocutaneous junction line to achieve a normal length [1]. He was successful in approximation of the muscular elements but rarely achieved a symmetric cupid's bow. The British surgeon Thomas Kilner described a technique of straight-line closure combining methods used by Rose, Thompson, and Veau. Kilner's technique, known for its simplicity, lengthened the lip, and reapproximated the muscle. Kilner believed that a superior cosmetic result could be achieved by secondary surgery to perfect the initial repair. Nakajima and others utilized curved incisions on the noncleft side and but straight incisions on the cleft side to equalize the length and allow a straight line repair [21].

Straight-line repairs have grouped together as the "Rose-Thompson principle." While these techniques have the advantage of simplicity and speed, they often result in an asymmetric cupid's bow, a prominent scar and retrusion of the maxilla.

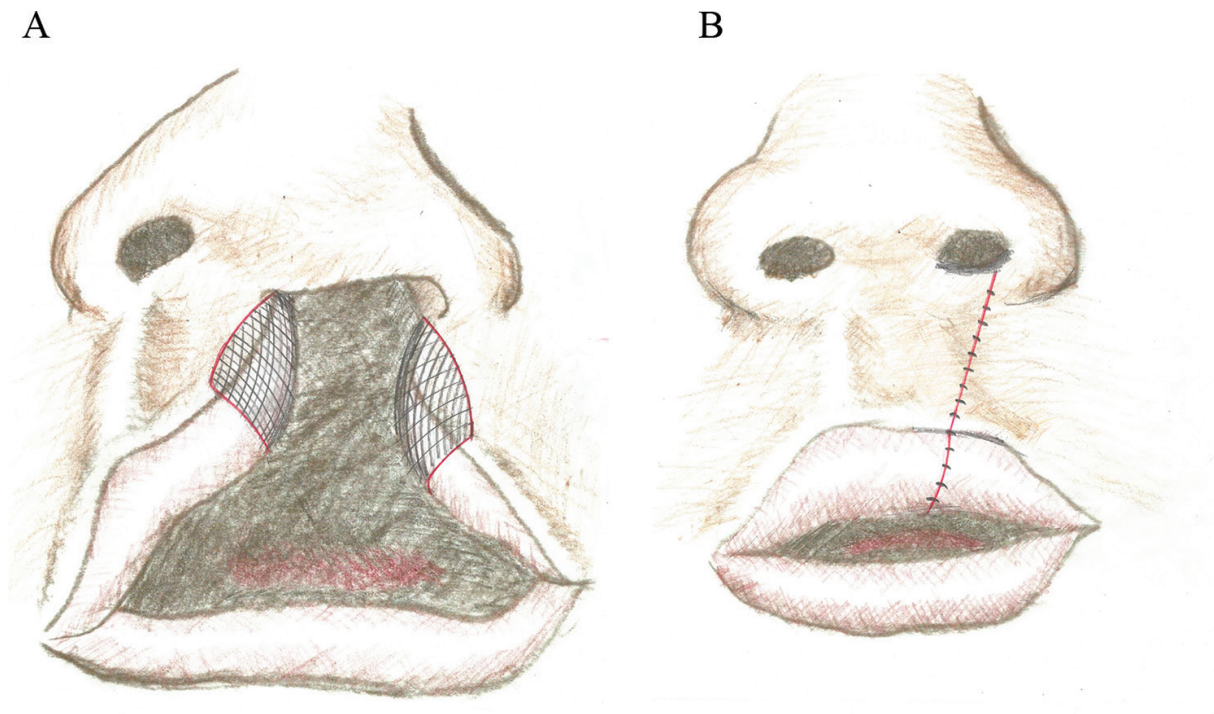


Figure 6. (A) Schematic representation of the incisions for a Rose repair. (B) Schematic representation of the closure of a Rose repair.

6.2. Upper lip flaps

6.2.1. Millard technique

Millard conceptualized his rotation-advancement technique while serving in Korea and first published in 1957 [22]. His technique is the most widely used by cleft surgeons, but has been modified since its inception. Its principles serve as the foundation of many unilateral repairs today.

Millard preserved anatomical landmarks: the cupid's bow and the philtral column. Downward rotation of the medial lip element restores vertical lip height and advancement of the lateral lip element repositions the alar base.

Millard marked the nadir and peaks of cupid's bow on both the lateral and medial lip with methylene blue. The distance from the alar base and the point selected for cupid's peak on the lateral segment should equal that of the noncleft side. His medial segment incision extends from the lateral cupid's peak of the medial element through the columellar-labial junction to the philtral column of the noncleft side. The lateral advancement flap extends from the nasal sill around the alar base. The medial segment with cupid's bow is rotated downward, and the lateral segment flap is advanced into the defect created.

Millard felt that markings served as a guide only, with the actual repair being “cut-as-you-go” individualized surgery (**Figure 7**).

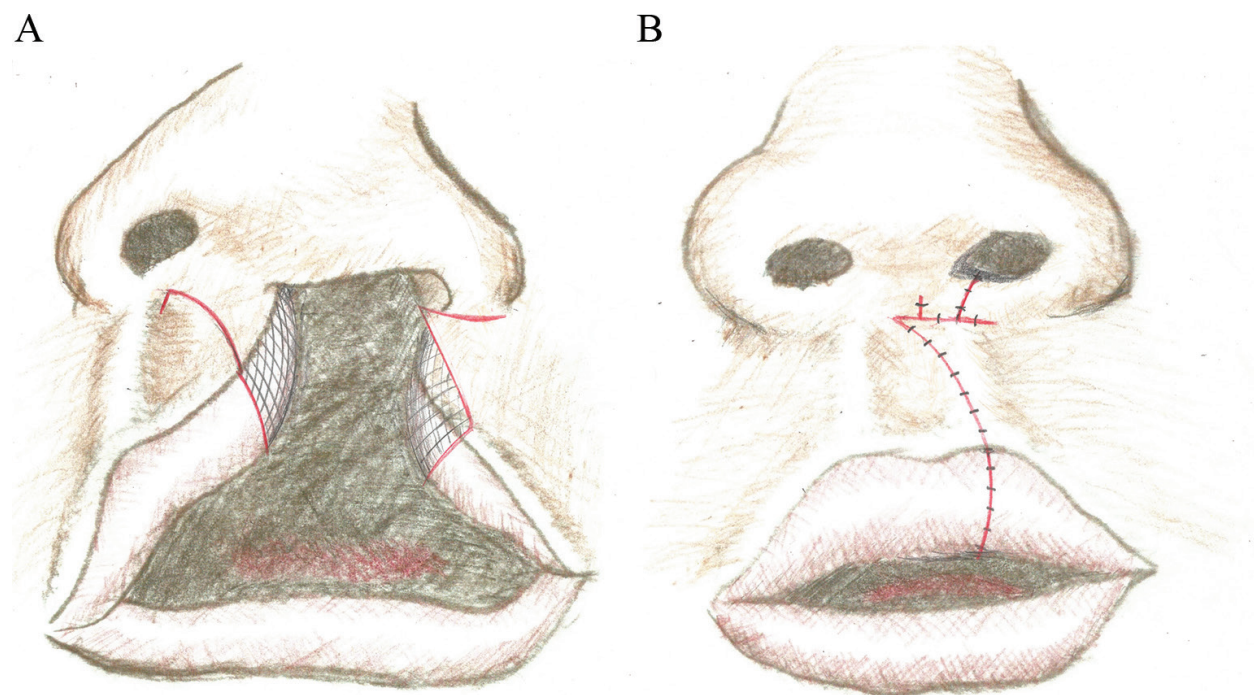


Figure 7. (A) Schematic representation of the incisions for a Millard repair. (B) Schematic representation of the closure of a Millard repair.

6.2.2. Salyer's modification

Salyer modified the rotation advancement with many improvements, most notably by making the transverse incision of the lateral segment B-flap not below the alar rim, but instead intranasally [23].

6.2.3. Mohler technique

Whereas the scar runs obliquely across the philtral column in Millard's repair, Mohler modified the technique to create a “mirror image” of the philtral column on the noncleft side [24]. He accomplished a straight-line closure of the lip by moving the rotation flap up into the

columella. His technique used a back-cut that terminated at the midpoint of the philtral depression. The defect created by the downward rotation was filled by tissue from the lateral element.

6.2.4. Cutting technique (“Extended Mohler”)

Mohler's technique was modified by Cutting who moved the upper end of the incision to just beyond the midline of the columella (about 4/7th of the width on the noncleft side), and extended the back-cut down to the noncleft philtral column [25]. This left a enough columellar tissue to fill in the defect created by downward rotation. A straight-line closure symmetric to the noncleft side philtral ridge is the result. There is then abundant lateral segment tissue that may be used to provide nasal lining, as shown in **Figure 8A** and **B**.

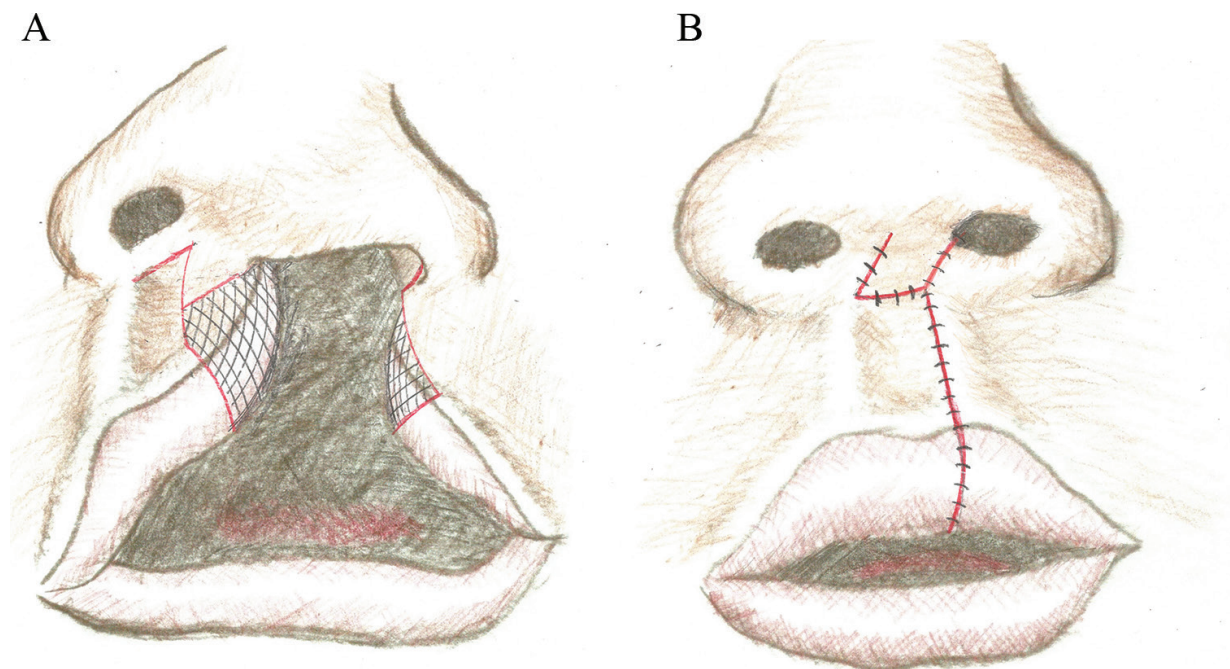


Figure 8. (A) Schematic representation of the incisions for a Cutting repair. (B) Schematic representation of the closure of a Cutting repair.

6.3. Middle lip flaps

6.3.1. LeMesurier technique

In the LeMesurier technique, a quadrilateral shape flap is created on the lateral side of the cleft lip which is rotated to the medial side where a notch is formed by a back cut, as shown in **Figure 9A** and **B** [26].

In addition to creating fullness in the lower lip, an advantage of this technique includes the placement of the suture line down the center of the lip. Thus, the cupid's bow can be made symmetrical. The scar that develops from the LeMesurier technique is a “step line” scar which is unlike most scars associated with cleft lip repair. This may overcome the characteristic appearance of a cleft lip repair and can look like an accidental wound to the observer [27].

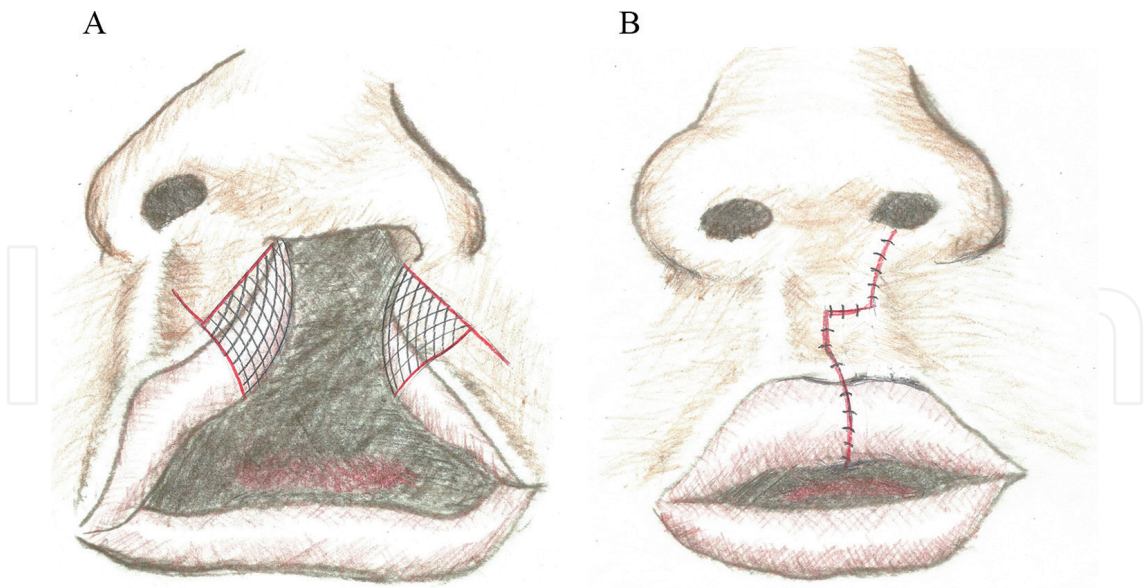


Figure 9. (A) Schematic representation of the incisions for a LeMesurier repair. (B) Schematic representation of the closure of a LeMesurier repair.

6.3.2. *Pool repair*

Pool placed the transverse limb of his Z-plasty repair of the lip approximately 3–4 mm below the alar bases [28]. He found that positioning the incision of the medial segment allowed for complete caudal rotation and proper horizontal positioning of the cupid's bow without the need for back-cuts or secondary flaps, see **Figure 10A** and **B**. He also found that this

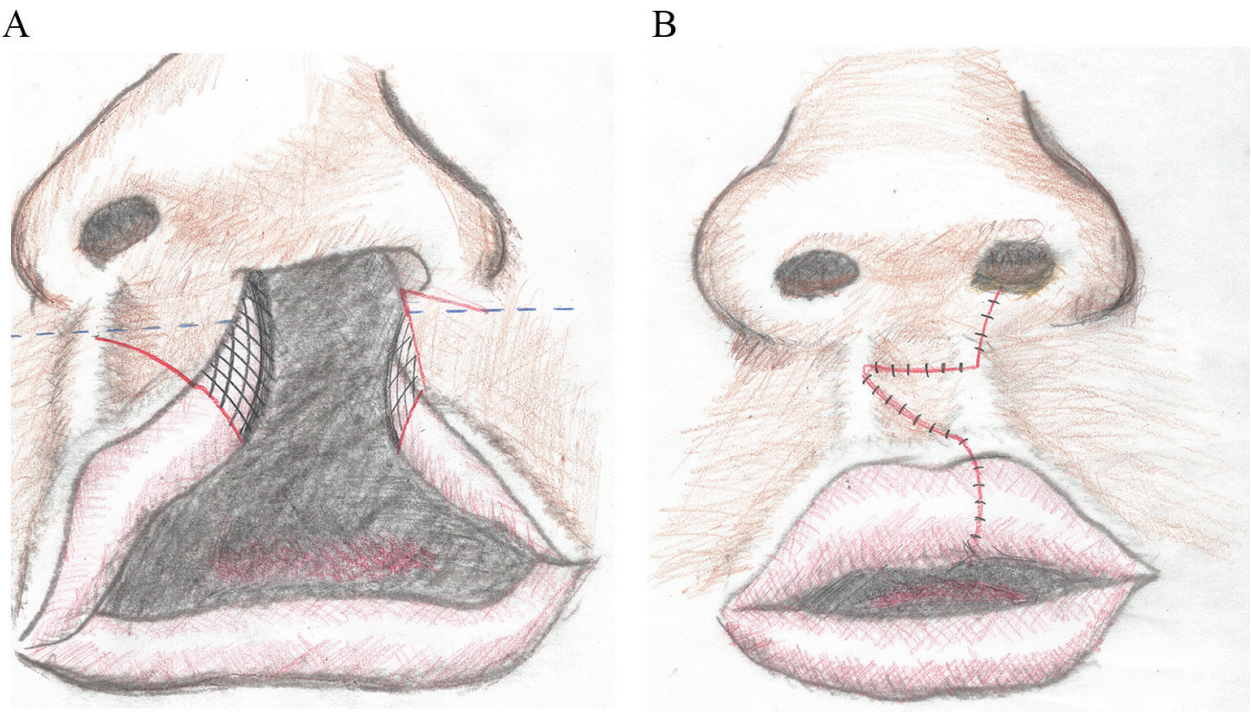


Figure 10. (A) Schematic representation of the incisions for a Pool repair. The blue dotted line represents a horizontal approximately 3 mm below the alar bases for planning the Z-plasty. (B) Schematic representation of the closure of a Pool repair.

technique allowed a better contour of the lip, especially the curve of the columellar-labial juncture, which may be distorted by the transverse scar in higher rotation advancement techniques. The incisions also allow a “cut as you go” adjustment to the alar base for symmetry.

6.4. Lower lip flaps

6.4.1. *Tennison-Randall repair*

In 1952, Charles Tennison proposed a repair based on the Z-plasty principle to gain vertical lip length [29]. His technique, in particular, has proven to be advantageous in wide complete clefts. Peter Randall devised a mathematical system for designing the lip operation [30].

The base of the isosceles triangle of the lateral element is determined by the difference in lengths between the noncleft cupid's peak to the alar base and to the base of the columella. The isosceles triangle side length should equal the length of the 90° back cut of the medial element, as shown in **Figure 11A** and **B**.

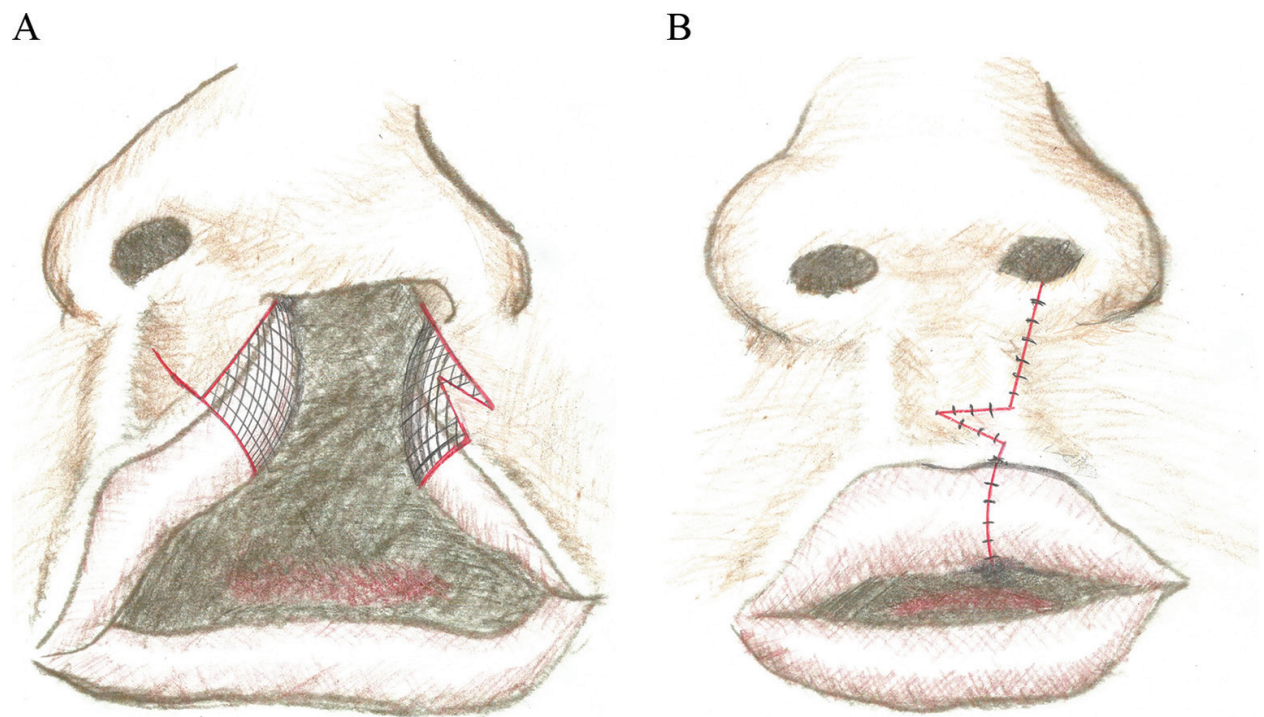


Figure 11. (A) Schematic representation of the incisions for a Tennison-Randall repair. (B) Schematic representation of the closure of a Tennison-Randall repair.

6.4.2. *Fisher “anatomic subunit” repair*

Fisher designed a repair utilizing the Rose-Thompson principle with close attention to the borders of aesthetic subunits of the lip, as well as a small lower lip triangular interpolation flap [31]. Many have found that this technique yields esthetic scars and achieves a natural contour of the upper lip (**Figure 12**).

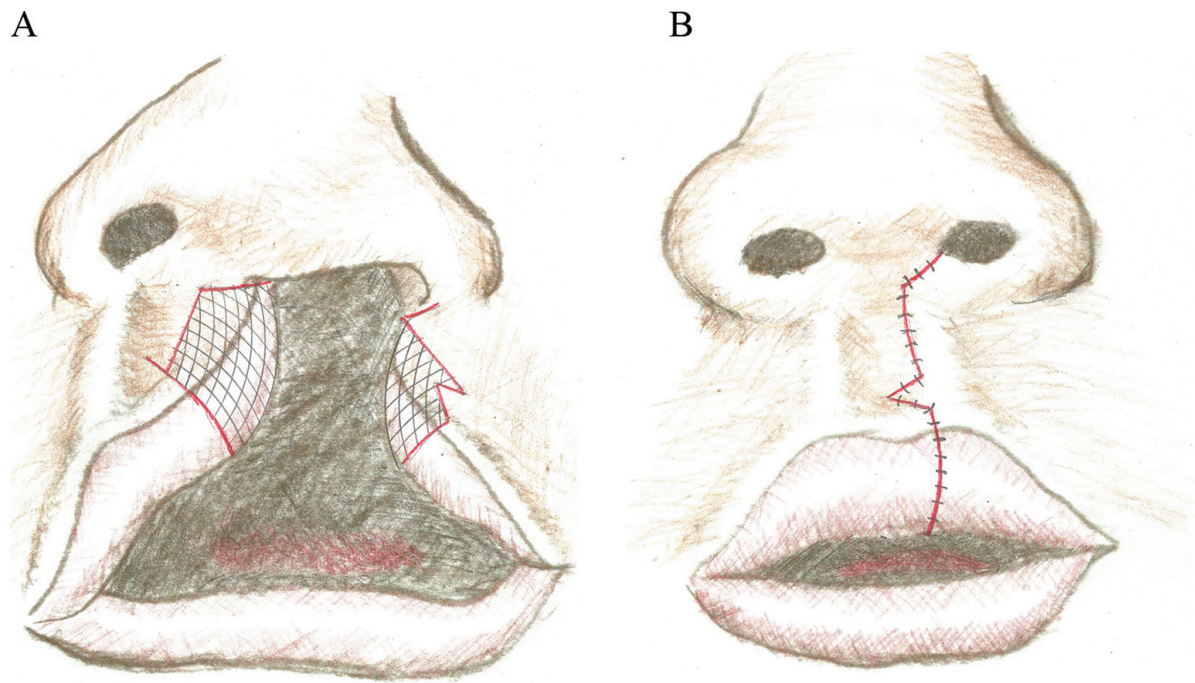


Figure 12. (A) Schematic representation of the incisions for a Fisher repair. (B) Schematic representation of the closure of a Fisher repair.

6.5. Vermilion flaps

6.5.1. Noordhoff technique

The Noordhoff technique utilizes a lateral lip triangular flap to reconstruct the dry vermilion [32]. A triangular flap is made on the lateral side of the cleft, where the vermilion height is the greatest, just before the red line converges to meet the white roll at the cleft edge (Noordhoff's point). The vermilion tissue medial to this triangular marking is used to augment the deficient vermilion underneath the cupid's bow. A straight cut is made on the medial side of the cleft to fit the inset of the lateral triangular flap (**Figure 13**).

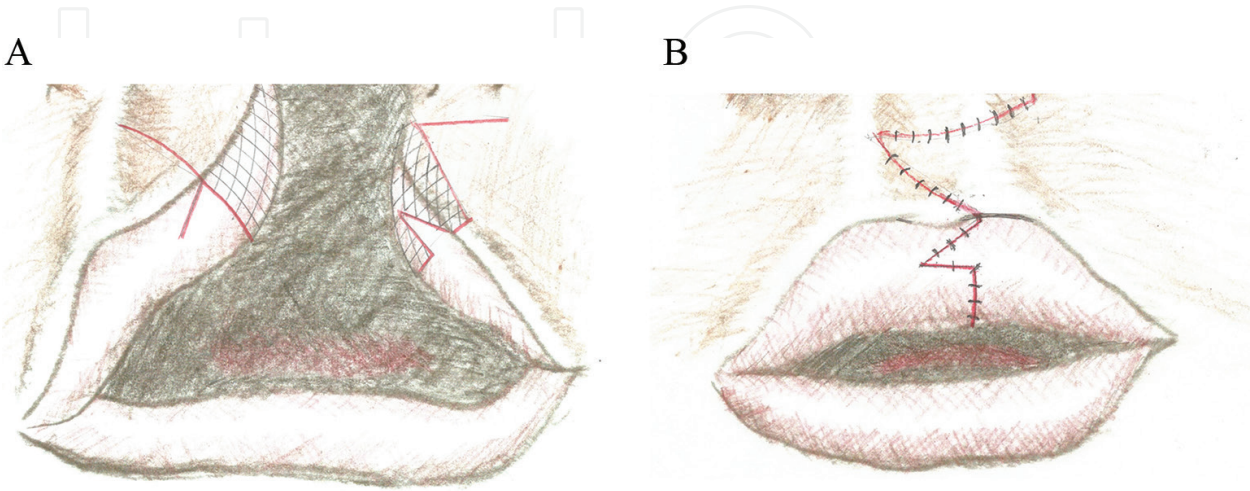


Figure 13. (A) Schematic representation of the incisions for a Noordhoff flap. (B) Schematic representation of the closure of a Noordhoff flap.

6.5.2. Powar technique

The Powar Technique for unilateral cleft lip repair is a modification of the Noordhoff's lateral vermilion flap. The Powar technique not only maintains the parallel relationship of the muco-vermillion "red line" with the white roll but also more accurately matches the vermilion on the noncleft side [33]. In Power's modification, the vermilion deficiency is measured on the medial cleft segment and a custom matching triangular flap is created above the muco-vermillion junction on the lateral slide (**Figure 14**). This avoids the mucosal bulge that often is the result of the Noordhoff triangular flap inset.

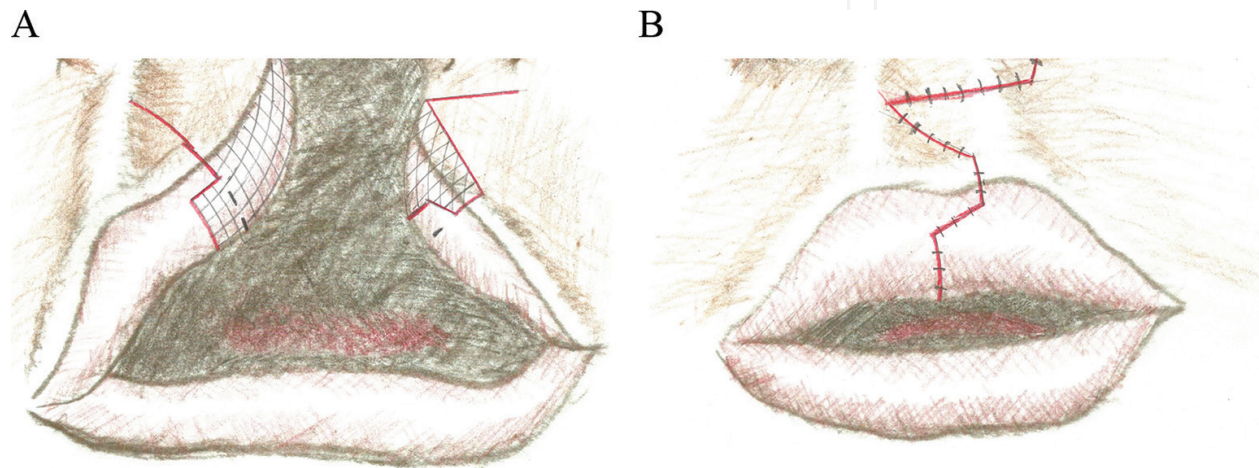


Figure 14. (A) Schematic representation of the incisions for a Powar flap. (B) Schematic representation of the closure of a Powar flap.

6.6. Adjunctive flaps

Creation of the cupid's bow is a critical aesthetic concern in cleft lip surgery and has two major elements: continuity of the white roll and sufficient caudal rotation. It is tempting for the surgeon, when faced with a wide cleft, to preserve as much tissue width as possible. However, preserving lip tissue with attenuated or absent white roll yields unsatisfactory outcomes. The vast majority of patients who present for a revision of cleft lip scar benefit from excision of scar to an accurately determined Noordhoff's point and meticulous suture approximation of the white roll.

A cleft lip repair may be unacceptable if the cupid's bow is not horizontal due to insufficient caudal rotation of the lip. A great advantage in the Pool technique is that it easily provides sufficient caudal rotation. In the case of insufficient rotation, enlarging the Z-plasty flaps, a flap "back cut," or a second Z-plasty may bring cupid's bow horizontal. A second smaller Z-plasty just above the white roll is a very useful tool: the tightness caused by the Z-plasty enhances the prominence of the white roll, and small flaps also break up a long linear scar (**Figure 15**). The Tennison and Fisher techniques employ this principle as part of their initial design.

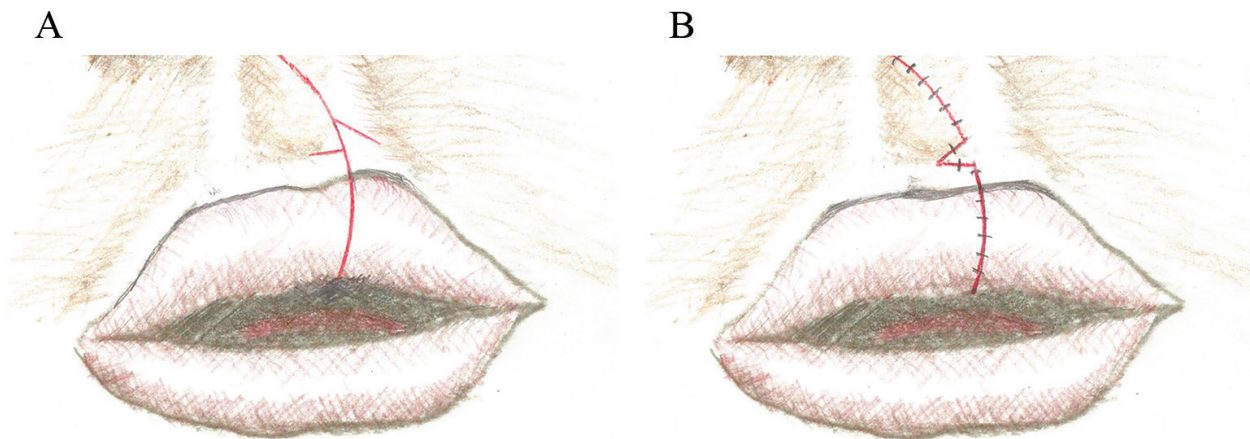


Figure 15. (A) Schematic representation of closure of a cleft repair with the cupid's bow under-rotated. The incisions for a second, smaller Z-plasty above the white roll are planned. (B) Schematic representation of the closure of Z-plasty.

6.7. Hard palate repair at the time of lip repair

Sommerlad advocates the Oslo Protocol for closure of the hard palate: a single-layer mucoperichondrial flap of the vomarine septum simultaneous with primary cleft lip repair [34]. While the lip is incised and retracted, tissue exposure is optimal to the anterior palate. This technique seems not to have unfavorable outcome on maxillofacial growth [35].

6.8. Primary nasal repair

Early nasal reconstruction is important for the patient's self-esteem from a young age, and eliminates the need for correction of worsening nasal deformities as one matures and grows. The reparative success of cleft nasal deformity is dependent on dissection that frees the alar cartilage and its translocation into normal position.

6.8.1. McComb's technique

McComb's technique lifts the alar cartilage with its vestibular lining to shorten the cleft-side nose [36]. Dissection in a subcutaneous plane is performed from the upper buccal sulcus and also through the columella to release the medial and lateral crura. The dissection then is extended from the nostril rim to the tip, dorsum, and nasion. The alar lift is achieved with either one or two mattress sutures through the nasal lining at the intercrural angle, raising the cleft side lower lateral alar cartilages to a symmetrical position.

6.8.2. Anderl's technique

The Anderl technique utilizes the incisions made for cleft lip repair and wide undermining of the nasal skin. The Anderl technique has extensive mobilization by undermining of the nasal dorsum, supraperiosteal dissection on the surface of maxilla from the vestibule to the infraorbital rim and from the piriform aperture to the maxillary tuberosity [37]. This maneuver allows for greater medial excursion of the lateral element during repair of the lip and nose. The cartilaginous septum is also released from its base attachment to the hard palate, straightened and sutured to the anterior nasal spine.

6.8.3. Salyer's technique

Salyer also uses extensive subcutaneous freeing of all elements and floating them above an abnormal skeletal base. He uses two intranasal-transdermal sutures to create the genu of the ala [38]. In the completion of the lip and nasal repair, additional sutures may be used to contour the alar base.

7. Outcomes assessments repair

"It is very difficult to understand the effectiveness of our actions without measurements."

—Steve Killelea

Most outcome studies for unilateral cleft lip-nose repair are single-surgeon experiences with their preferred techniques [39]. Outcomes are measured with postoperative photographs that assess various anatomic landmarks and features. Other studies compare results as surgeon's technique change over time [40, 41].

AmeriCleft, a large, multicenter study in the U.S., validated the use of the Asher-McDade rating scale, to audit four different institutions each with their own protocols [42]. The Asher-McDade system stratifies cleft patients on a seven-point scale in each of the following nasolabial characteristics [43]:

- a. Nasal form
- b. Symmetry of the nose
- c. Shape of the vermillion
- d. Nasal profile including upper lip

The EuroCleft, a large multicenter European study, found that physical metrics correlated poorly with satisfaction [44]. Furthermore, there are few studies that examine the functionality and quality of life of cleft patients postoperatively [45]. Future metric systems should be comprehensive, incorporating all patient-related outcomes in a cleft population.

8. Author's experience

"It is life's tragedy that we get old too soon and wise too late"

—Benjamin Franklin

The senior author (DL) was trained in plastic surgery residency, as many were, to repair unilateral cleft lips with the Millard rotation-advancement technique. Later, while on surgical missions to developing world countries, I had the opportunity and honor to work with Dr. Robert Pool, and learn his midlip Z-plasty technique of lip repair. Moreover, I also observed his meticulous surgical technique and attention to detail that brought the children on whom he operated such excellent results. When I began practice with the Vermont State Cleft/Craniofacial Center, I used the Pool technique.

Still later in my practice, I was quite intrigued by the extended Mohler technique advocated by Dr. Court Cutting. While in New York City attending Dr. Barry Grayson's excellent workshop on nasoalveolar molding, Dr. Cutting graciously invited me to observe him operating on an

infant with unilateral cleft lip. I observe his similar scrupulous attention to detail and excellent technique. I then began using this technique for a period of time. For reasons discussed below, I have returned to a midlip Z-plasty technique for surgical reconstruction of children with unilateral cleft lip.

In my experience, the upper lip techniques of lip reconstruction have the disadvantage of a transverse scar across the columellar-labial junction. The columellar-labial junction naturally has a gentle curved shape, but a transverse scar across this curve will frequently result in a tight, noncurved junction.

Linear scars the entire height of the lip often results in scar hypertrophy (**Figure 16**). The linear Cutting/Mohler surgical linear scar line mimics a natural philtral ridge, however may result in a hypertrophic scar of the vertical limb.

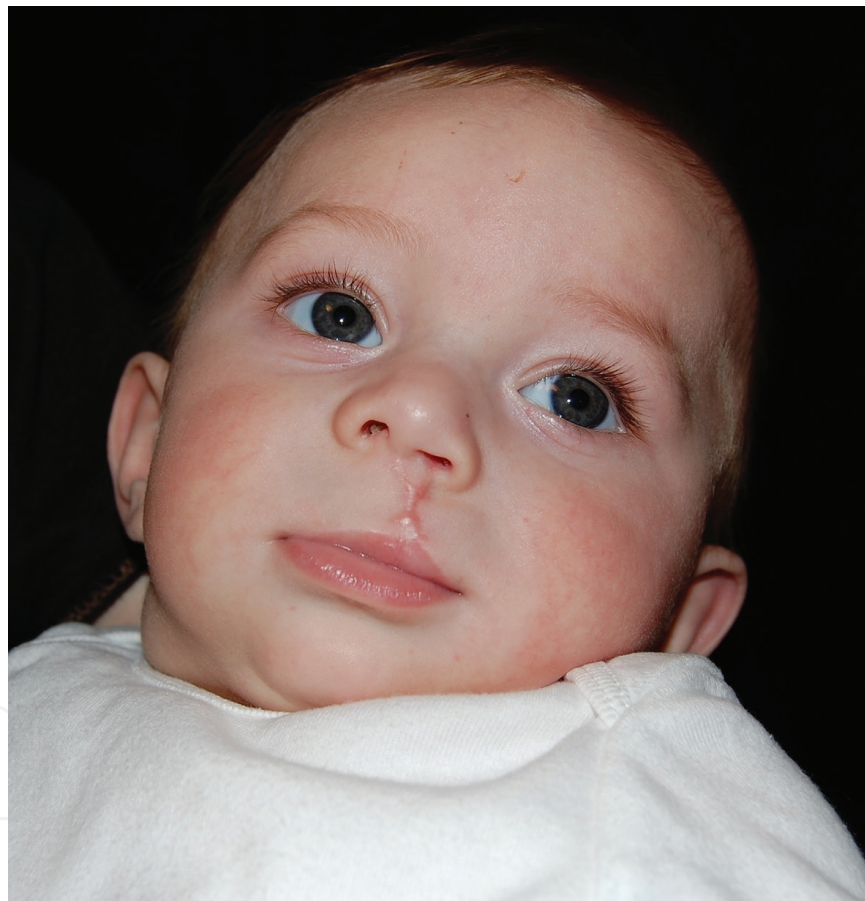

Figure 16. A child 5 months after cleft lip repair by the Cutting “Extended Mohler” technique and Powar vermilion flap. This is the child from **Figure 1B** and **Figure 4**. Note the somewhat hypertrophied straight-line vertical limb of the scar.

Continuity of orbicularis oris is the critical functional concern of cleft lip surgery. Midlip surgical techniques have a great advantage in that the incisions are made over the abnormal muscle bundles, and flap transposition redirects those muscle bundles with less extensive dissection (**Figure 17**).

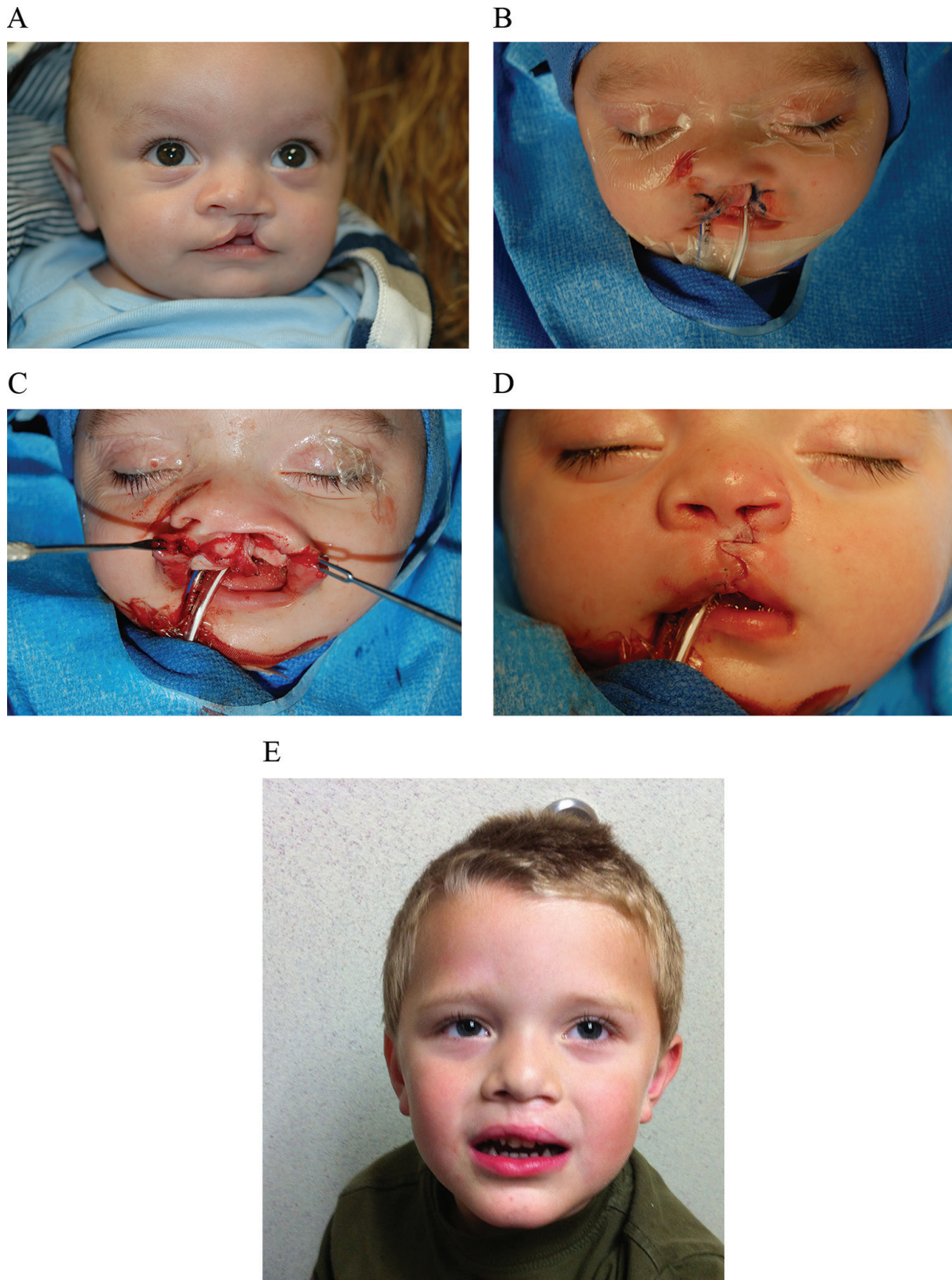


Figure 17. (A) An infant with a complete unilateral cleft lip. (B) The infant in the operating room with markings for a Pool midlip Z-plasty and Noordhoff vermilion flap repair. (C) The infant in the operating room with dissection completed. Because the Z-plasty design and muscles are freed from their abnormal insertions without as much undermining of the skin. (D) The infant in the operating room with surgical repair completed. (E) This child at 3 years of age.

In my opinion, this technique yields very satisfactory results (**Figure 18**).

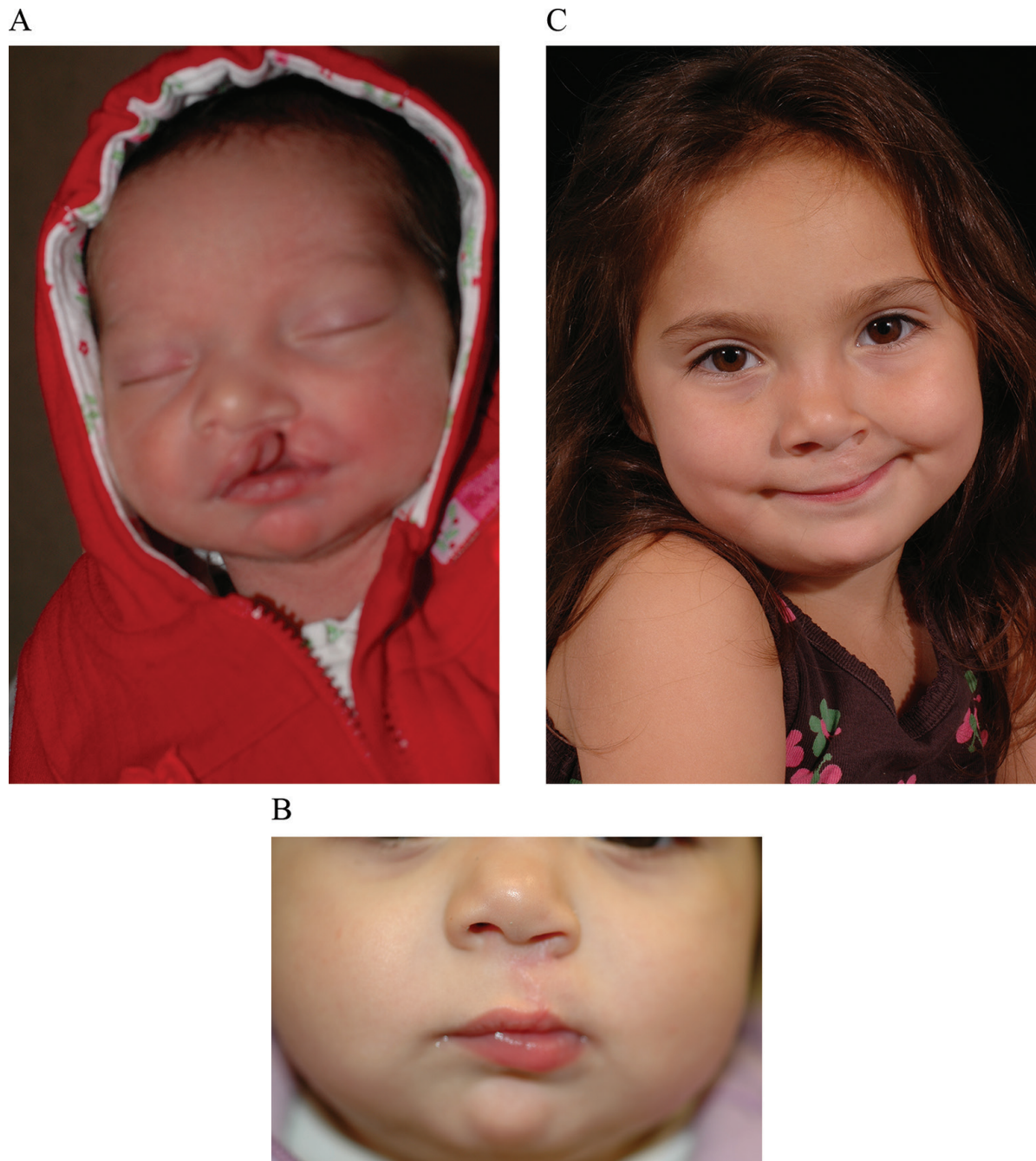

Figure 18. (A) An infant with a wide, yet incomplete unilateral cleft lip. Note the narrow Simonart's band. (B) The infant after a Pool midlip Z-plasty and Powar vermilion flap repair. (C) The same child at 5 years of age.

At Vermont State Cleft/Craniofacial Center, we perform formal NAM presurgical orthopedics only on children with bilateral clefts who have premaxillary protrusion (**Figure 5**). Unfortunately, we have found that the frequent visits and lack of insurance coverage for NAM result in a high burden of care for families in Vermont. Because of this, we have not adopted this modality for children with unilateral clefts. We have found presurgical taping (**Figure 4**) to be an efficacious yet inexpensive modality and it offers an opportunity for parents to play an active role in their child's care.

Thoughtful selection of a surgical method and careful attention to detail in the execution of surgical technique will yield the best results. We hope that this chapter will help surgeons in the care of children with cleft lip.

Author details

Mustafa Chopan, Lohrasb Sayadi and Donald R. Laub*

*Address all correspondence to: Donald.Laub@uvmhealth.org

University of Vermont College of Medicine, Burlington, Vermont, USA

References

- [1] Veau V RJ. *Bec-de-lièvre: formes cliniques, chirurgie* [Hare-lips: clinical forms, surgery] Paris: Masson et Cie; 1938.
- [2] Bo C, Ningbei Y. Reconstruction of upper lip muscle system by anatomy, magnetic resonance imaging, and serial histological sections. *J Craniofac Surg*. 2014; 25(1): 48–54.
- [3] Wu J, Yin N. Detailed anatomy of the nasolabial muscle in human fetuses as determined by micro-CT combined with iodine staining. *Ann Plast Surg*. 2016; 76(1): 111–116.
- [4] Yin N, Wu J, Chen B, Song T, Ma H, Zhao Z, et al. Muscle tension line concept in nasolabial muscle complex-based on 3-dimensional reconstruction of nasolabial muscle fibers. *J Craniofac Surg* 2015; 26(2):469–472.
- [5] Huang MHS, Lee S, Lee, S. Anatomy of Cleft Lip and Palate. In: Losee JE, Kirshner RE, editor. *Comprehensive Cleft Care*. 2nd ed. New York: McGraw-Hill; 2009. pp. 223–239.
- [6] Pool R. The configurations of the unilateral cleft lip, with reference to rotation advancement repair. *Plast Reconstr Surg*. 1966. 37:558–565.
- [7] Liao JY, van Aalst JA, Sadove AM. Understanding and caring for children with cleft lip and palate. In: Coran AG, editor. *Pediatric Surgery*. Philadelphia: Elsevier Saunders; 2012. pp. 699–706.
- [8] Wang TD, Milczuk, H.A. Cleft lip and palate. In: Paul WF, editor. *Cummings Otolaryngology*. Philadelphia: Elsevier Saunders; 2015. pp. 2915–32.e3.
- [9] Pool R, Farnworth TK. Preoperative lip taping in the cleft lip. *Ann Plast Surg*. 1994; 32(3):243–249.
- [10] Cruz C. Presurgical orthopedics appliance: the Latham technique. *Oral Maxillofac Surg Clin North Am*. 2016; 28(2): 161–168.
- [11] Millard DR, Jr., Latham RA. Improved primary surgical and dental treatment of clefts. *Plast Reconstr Surg*. 1990; 86(5): 856–871.
- [12] Aminpour S, Tollefson TT. Recent advances in presurgical molding in cleft lip and palate. *Curr Opin Otolaryngol Head Neck Surg*. 2008; 16(4): 339–46.

- [13] Grayson BH, Santiago PE, Brecht LE, Cutting CB. Presurgical nasoalveolar molding in infants with cleft lip and palate. *Cleft Palate Craniofac J*. 1999; 36(6): 486–498.
- [14] Randall P. A lip adhesion operation in cleft lip surgery. *Plast Reconstr Surg*. 1965; 35:371–376.
- [15] Demke JC, Tatum SA. Analysis and evolution of rotation principles in unilateral cleft lip repair. *J Plast Reconstr Aesthet Surg*. 2011 Mar; 64(3): 313–8.
- [16] Millard DR, Jr. Paring and approximation with needles and/or sutures. *Cleft Craft: The Evolution of its Surgery. I*. Boston: Little & Brown; 1976. pp. 82–87.
- [17] Randall P, Jackson, O. A short history of cleft lip and cleft palate. In: Losee JE, Kirshner RE, editors. *Comprehensive Cleft Care*. 2nd ed. New York: McGraw-Hill; 2009. pp. 187–209.
- [18] Rose, W. *On Harelip and Cleft Palate*. London: HK Lewis; 1891.
- [19] Thompson, JE. An artistic and mathematically accurate method of repairing the defects in cases of harelip. *Surg Gynecol Obstet*. 1912(14): 498–502.
- [20] Millard DR, Jr. Increasing vertical length of cleft edges. *Cleft Craft: The Evolution of its Surgery. I. The Unilateral Deformity*. Boston: Little & Brown; 1976. pp. 90–92.
- [21] Nakajima T, Yoshimura Y, Yoneda K, Nakanishi Y. Primary repair of an incomplete unilateral cleft lip: avoiding an elongated lip and achieving a straight suture line. *Br J Plast Surg* 1998; 51(7): 511–516.
- [22] Millard DR, Jr. A radical rotation in single harelip. *Am J Surg*. 1958; 95(2): 318–322.
- [23] Salyer K, Marchac, A, Cheng, MS, Michienza JW, Genecov, E. Unilatera cleft lip/nose repair. In: Losee JE, Kirshner R, editor. *Comprehensive Cleft Care*. 2 ed. New York: McGraw-Hill; 2009. pp. 299–329.
- [24] Mohler LR. Unilateral cleft lip repair. *Plast Reconstr Surg*. 1987; 80(4): 511–7.
- [25] Cutting C. The extended mohler unilateral cleft lip repair. In: Losee JE KR, editor. *Comprehensive Cleft Care*. 2nd ed. New York: McGraw-Hill; 2009. pp. 286–97.
- [26] LeMesurier A. A method of cutting and suturing the lip in the treatment of complete unilateral clefts. *Plast Reconstr Surg*. 1949; 4(1): 1–12.
- [27] Bauer TB, Trusler HM, Glanz S. Repair of unilateral cleft lip; advantages of LeMesurier technique use of mucous membrane flaps in maxillary clefts. *Plast Reconstr Surg*. (1946). 1953; 11(1): 56–68.
- [28] Pool R. Cleft lip. In: Stark RB, editor. *Plastic Surgery of the Head and Neck*. 1st ed. New York: Churchill-Livingstone; 1987. pp.1179–1189.
- [29] Tennison CW. The repair of the unilateral cleft lip by the stencil method. *Plast Reconstr Surg*. (1946). 1952;9(2): 115–120.
- [30] Randall P. A triangular flap operation for the primary repair of unilateral clefts of the lip. *Plast Reconstr Surg*. 1959; 23(4): 331–347.

- [31] Fisher DM. Unilateral cleft lip repair: an anatomic subunit approximation technique. *Plast Reconstr Surg*. 2005; 116: 61–71.
- [32] Noordhoff MS. Reconstruction of vermilion in unilateral and bilateral cleft lips. *Plast Reconstr Surg*. 1984; 73(1): 52–61.
- [33] Powar RS, Patil S, Kleinman ME. A geometrically sound technique of vermilion repair in unilateral cleft lip. *J Plast Reconstr Aesthet Surg*. 2007; 60(4): 422–425.
- [34] Sommerlad BC. Surgery of the cleft lip and nose—the GOSTA approach. *B-ENT*. 2006; 2 Suppl. 4: 29–31.
- [35] Ferdous KM, Salek AJ, Islam MK, Das BK, Khan AR, Karim MS. Repair of cleft lip and simultaneous repair of cleft hard palate with vomer flap in unilateral complete cleft lip and palate: a comparative study. *Pediatr Surg Int*. 2010 Oct; 26(10): 995–1000.
- [36] McComb H. Primary correction of unilateral cleft lip nasal deformity: a 10-year review. *Plast Reconstr Surg*. 1985; 75(6):791–799.
- [37] Anderl H, Hussl H, Ninkovic M. Primary simultaneous lip and nose repair in the unilateral cleft lip and palate. *Plast Reconstr Surg*. 2008; 121(3): 959–970.
- [38] Salyer KE, Genecov ER, Genecov DG. Unilateral cleft lip-nose repair: a 33-year experience. *J Craniofac Surg*. 2003;14(4): 549–558.
- [39] Al-Omari I, Millett DT, Ayoub AF. Methods of assessment of cleft-related facial deformity: a review. *Cleft Palate Craniofac J*. 2005; 42(2): 145–156.
- [40] Lazarus DD, Hudson DA, van Zyl JE, Fleming AN, Fernandes D. Repair of unilateral cleft lip: a comparison of five techniques. *Ann Plast Surg*. 1998 Dec; 41(6): 587–594.
- [41] Chang CS, Liao YF, Wallace CG, Chan FC, Liou EJ, Chen PK, Noordhoff MS: Long-term comparison of the results of four techniques used for bilateral cleft nose repair: a single surgeon’s experience. *Plast Reconstr Surg*. 2014 Dec; 134(6): 926e–36e.
- [42] Mercado A, Russell K, Hathaway R, Daskalogiannakis J, Sadek H, Long RE, Jr., et al. The Americleft study: an inter-center study of treatment outcomes for patients with unilateral cleft lip and palate part 4. Nasolabial aesthetics. *Cleft Palate Craniofac J*. 2011; 48(3):259–64.
- [43] Asher-McDade C, Roberts C, Shaw WC, Gallagher C. Development of a method for rating nasolabial appearance in patients with clefts of the lip and palate. *Cleft Palate Craniofac J*. 1991;28(4):385–90; discussion 90–1.
- [44] Semb G, Brattstrom V, Molsted K, Prahll-Andersen B, Zuurbier P, Rumsey N, et al. The Eurocleft study: intercenter study of treatment outcome in patients with complete cleft lip and palate. Part 4: relationship among treatment outcome, patient/parent satisfaction, and the burden of care. *Cleft Palate Craniofac J*. 2005; 42(1): 83–92.
- [45] Eckstein DA, Wu RL, Akinbiyi T, Silver L, Taub PJ. Measuring quality of life in cleft lip and palate patients: currently available patient-reported outcomes measures. *Plast Reconstr Surg*. 2011; 128(5): 518e–26e.

