

We are IntechOpen, the world's leading publisher of Open Access books Built by scientists, for scientists

6,900

Open access books available

186,000

International authors and editors

200M

Downloads

Our authors are among the

154

Countries delivered to

TOP 1%

most cited scientists

12.2%

Contributors from top 500 universities



WEB OF SCIENCE™

Selection of our books indexed in the Book Citation Index
in Web of Science™ Core Collection (BKCI)

Interested in publishing with us?
Contact book.department@intechopen.com

Numbers displayed above are based on latest data collected.
For more information visit www.intechopen.com



Umbilical Cord Blood Cells for Perinatal Brain Injury: The Right Cells at the Right Time?

Courtney A. McDonald, Margie Castillo-Melendez,
Tayla R. Penny, Graham Jenkin and
Suzanne L. Miller

Additional information is available at the end of the chapter

<http://dx.doi.org/10.5772/66647>

Abstract

Cerebral palsy (CP) is the most common cause of physical disability in children. CP currently has no cure and there are only few interventions to prevent the development of disability. There are four principal complications of pregnancy or birth that can damage the developing brain and lead to CP: preterm birth, fetal growth restriction, infection during pregnancy and severe hypoxia-ischemia at birth. Umbilical cord blood (UCB) cells are a very promising therapy for the treatment of CP. While UCB therapy for juveniles with CP is currently being assessed in clinical trials, very little is known about their mechanisms of action or which cells found in umbilical cord blood protect against and/or repair brain injury. In this chapter, we first explore the complications that can lead to perinatal brain injury. We then discuss the different cell types found in UCB and the specific properties that make each of them individually attractive therapeutic candidates for treatment of perinatal brain injury. While UCB holds much promise as a therapy for CP, it is imperative that more research is conducted to understand how the different cell types found in UCB can protect against brain injury in order to design more effective and targeted therapies.

Keywords: cerebral palsy, stem cells, hypoxic-ischemic injury, early intervention, neonatal, fetal growth restriction, Intrauterine growth restriction

1. Introduction

Perinatal brain injury is the underlying cause of cerebral palsy (CP), which is a broad term used to describe deficits in motor function and/or posture. CP affects more than 1 in 450 live births in developed countries and the incidence of severe disability is much higher in low

resource countries. There are four principal complications affecting pregnancy or birth that can lead to perinatal brain injury: preterm birth, fetal growth restriction, infection during pregnancy or severe hypoxia-ischemia at birth (birth asphyxia). The time of onset of these complications is different for each condition and other important variables that affect the severity of the resulting brain injury exist. These include the severity of the insult, whether the infant is born preterm or at term and whether complications are compounded (for example, an asphyxic event at birth in a growth restricted infant). Although these complications vary in their fundamental etiology, they share common neuro-pathological features that include hypoxic episodes, inflammation, excitotoxicity and decreased vascular integrity. Umbilical cord blood (UCB)-derived cells demonstrate the potential to mediate these adverse pathways and, thereby, have neuroprotective, neuroregenerative and angiogenic potential for translation into clinical treatments for perinatal brain injury.

UCB is a proven source of hematopoietic stem cells (HSCs) used clinically for treatment of hematological disorders, but it also contains a number of other stem/progenitor cell types, of which mesenchymal stromal cells (MSCs) and endothelial progenitor cells (EPCs), individually or together, offer neuroprotective benefits [1, 2]. Moreover, UCB is also a rich source of immunosuppressive cells, such as T regulatory cells (Tregs) and monocyte-derived suppressor cells (MDSCs) [3]. There is supporting evidence that in isolation, each of these cell types have properties that may prevent the progression of hypoxic and inflammatory cascades that drive brain injury; however, their ability to prevent neonatal brain injury has not been well explored. It is likely that each cell type targets different pathways to reduce or repair tissue injury. The study of the properties of whole UCB, as well as its individual cellular components, in animal models of perinatal brain injury is integral towards the development of tailored cell therapy to prevent or repair brain injury in high risk newborn infants. Furthermore, the importance of the timing of administration needs to be further explored. Current clinical trials are administering UCB cells to children that have established CP, with children ranging from 10 months to 20 years old. In contrast, preclinical evidence suggests that administration of UCB cells at an early stage after injury, and while the brain is still plastic and receptive, should be much more effective than later intervention at protecting the brain and promoting brain repair.

2. Complications associated with perinatal brain injury

2.1. Term hypoxic-ischemic brain injury

In the healthy term-born infant, the brain continues to develop after birth. The formation of neurons and glial cells is mostly complete by term, however cell maturation, myelination and synaptic connection continue well after birth [4]. At term, the brain is very vulnerable to changes in the environment to which it is exposed and a hypoxic-ischemic (HI) insult at this time can induce an inflammatory response, as well as increased excitotoxicity, release of reactive oxygen species, and apoptotic cell death [5]. When term born infants are exposed to a severe hypoxic insult at, or around, the time of birth the resulting pattern of brain injury is seen as a selective disruption of cortical and deep grey matter structures, which include the putamen, ventrolateral thalamus and the cortex [6]. This type of severe HI injury results in the

clinical condition termed hypoxic ischemic encephalopathy (HIE), which manifests in infants as a range of clinical abnormalities that include truncal hypotonia and dystonia, jitteriness, severe comas and seizures [6, 7]. HIE affects approximately 1.5 in 1000 live births each year in developed countries [8] and is the most well understood form of perinatal brain injury with respect to the progression of brain damage and subsequent neurodevelopmental outcomes. The underlying cause of the severe HI episode is not always known, but is most often associated with umbilical cord prolapse, placental abruption, or prolonged labor, while other antenatal insults may also be involved [9].

The development of HIE and cell degeneration after a severe insult at birth progresses over time and has been described as a series of phases originating from the time of the insult [10]. The severity and length of these phases can be useful indicators of the severity of future neurological deficits in the infant [11]. The initial phase is the *insult* or *primary phase*, which describes the period of hypoxic insult often referred to as the phase of primary energy failure. In this phase, there is an acute severe reduction in cerebral perfusion leading to a lack of oxygen and glucose within the brain, with exhaustion of high-energy stores and rapid accumulation of lactic acid and free radicals [12]. In turn, this induces excitotoxic programming of the apoptotic cascade, leading to commencement of primary cell loss [2]. Following the cessation of the insult and oxygen reperfusion, the *latent phase* begins from the onset of reperfusion up to approximately 6 h after injury and gives the appearance of restored metabolic function due to restoration of blood flow and oxygen to the brain [12]. This is associated with reduced oxygen consumption and restoration of normal metabolite levels [13]. However, this phase is short lived and is closely followed by a secondary phase of deterioration and brain injury.

The secondary phase is critical, because, even when the primary phase has been very severe, most neuronal death results from events that occur during the secondary phase [14]. During the secondary phase, the pro-inflammatory pathways become significantly upregulated, which, in turn, contributes to breakdown of the blood brain barrier (BBB). These events are both key contributors to brain damage. As occurs in the primary phase, elevated glutamate is also apparent, resulting in an excitotoxic environment, and exacerbation of cell death [12]. It is during the secondary phase that seizures will commence in those infants with moderate to severe encephalopathy [15]. The secondary phase of insult occurs between 6 h and up to 3 days after the HI insult.

In addition to the neurotoxic events described above, in response to HI, the transcription factor hypoxia inducible factor-1 α (HIF-1 α) is upregulated, which, in turn, upregulates genes such as vascular endothelial growth factor (VEGF) [16]. Increased VEGF leads to increased vascular permeability, causing vascular leakage, which further contributes to the breakdown of the BBB. This increased permeability allows immune cells to infiltrate into the brain parenchyma, where they can secrete growth factors and cytokines that have the ability to activate nearby cells, such as microglia and astrocytes [17]. The first immune cells that are activated by ischemia are the resident microglia and astrocytes, which home to the ischemic area and begin to “clean up” the damaged area, by means of phagocytosis. During this surge of inflammation, there is an increase in pro-inflammatory cytokines, specifically interleukin (IL)-6 and IL-8, which are produced by activated microglia, and an influx of T cells to the site of the

lesion. This increase in IL-6 and IL-8 is known to be associated with the development of cerebral palsy following a HI insult [18]. Microglia and astrocytes add to the production of reactive oxygen species (ROS), causing further oxidative stress [19]. The functional role of T cells following their influx in response to ischemia is not fully known, however, it has been shown that, when T cells are suppressed, there is a reduction in inflammation at the site of the infarct. It has also been noted that, in response to a HI insult, there is reduced recruitment of regulatory T cells (Tregs) to the site of injury [20], Tregs are part of our natural anti-inflammatory defence system and a failure to recruit these cells may contribute to increased inflammation and brain injury.

In addition, during the secondary phase of brain injury, vasogenic edema begins as a result of the breakdown of the BBB and infiltration of blood products. Plasma and serum proteins leak out of the vessels and into the extracellular space of the brain. Brain edema can cause further injury to the brain by compressing surrounding tissues, compressing capillaries causing tissue hypoxia and mediating further cell death. Using magnetic resonance imaging, it has been found that 86% of term neonates that have suffered a perinatal hypoxic-ischemic event also developed brain edemas [17].

2.2. Fetal growth restriction

Fetal growth restriction (FGR) describes the fetus that fails to grow appropriately in utero, most often caused by poor placental function. FGR is associated with high perinatal mortality and long-term morbidities [21]. Normal fetal growth is dependent on the efficient transfer of nutrients and oxygen from the maternal-uterine circulation to the fetus via the placenta. Inefficient placental function, and thereby inadequate oxygen, glucose and essential amino acid transfer to the fetus, negatively affects fetal growth [22]. Chronic hypoxia caused by placental insufficiency has a profound adverse effect on brain development, impacting cell growth and maturation, in the last third of pregnancy in particular, which in turn leads to brain structural alterations and functional impairments [23]. A number of follow-up studies on infants following FGR show that it is associated with significant neurodevelopmental disabilities, including abnormalities in fine and gross motor skills, cognitive function, language, memory, concentration, attention, mood and school performance. FGR infants are also at increased risk of acute adverse neonatal consequences such as preterm birth, perinatal asphyxia and respiratory distress [24], which in turn exacerbate brain injury. Additionally, premature infants born with FGR constitute a very vulnerable population since they are at increased risk for an adverse neurological outcome [25].

The brain injury that is observed in human infants with FGR, and in animal models of FGR, is complex and distinct from other complications of pregnancy or birth. This is likely due to the chronic nature of hypoxia and hypoglycemia that the growth restricted fetus experiences over a critical period of brain development [23]. Specifically, abnormalities such as reduced total neuronal number, decreased axonal and synaptic density and myelin loss have been well described in humans and animal models of FGR [23]. Brain imaging of human FGR newborns also demonstrates that total brain volume, grey matter and white matter volume are all significantly reduced in FGR infants [26, 27]. Chronic hypoxia, caused by placental

insufficiency, induces a redistribution of fetal cardiac output to favor the brain: an adaptive response known as *brain sparing*. Although the fetus is able to adapt to hypoxia, to some degree, this beneficial blood flow redistribution does not ensure normal brain development over a prolonged period. The initial increase in cerebral perfusion seen in FGR fetuses is followed by a pronounced fall in perfusion with progressive fetal deterioration [28]. When hypoxia is chronic, fetal deterioration is characterized by reduced physiological cerebral vascular variability (both vasoconstriction and vasodilatation), followed by an increase in cerebral vascular resistance, which, in turn, exacerbates brain injury [29]. Even in clinically healthy FGR term neonates, higher venous hematocrit and lower cerebral blood flow have been reported during the early neonatal period (48–72 h), with some of these infants showing hypertonia and delayed developmental milestones, along with hypoxic changes observed in magnetic resonance imaging (MRI) of the brain [30].

Neurodevelopmental abnormalities seen in FGR have been described for specific brain areas including the anterior hippocampal-prefrontal network, parahippocampal complex, striatum and thalamus [31, 32]. Magnetic resonance imaging (MRI) studies consistently demonstrate structural brain changes in FGR infants during both the fetal and neonatal period. These changes include decreased volume in cortical grey matter (GM) [26] and the hippocampus [33]; altered cortical development [34]; and abnormal structure of white matter tracts [35]. FGR infants born prematurely show a significant reduction in intra-cranial volume and cerebral cortical grey matter on MRI within the first 2 weeks of life, compared with age-matched premature non-FGR infants [26]. Similarly, FGR infants who are born preterm show a reduction in hippocampal gray matter volume, which is associated with neurobehavioral deficits at term equivalent and at 24 month corrected age [33].

FGR can also lead to a specific pattern of hypoxic-ischemic and/or hemorrhagic white matter lesion that can be observed on ultrasound [36]. FGR infants born prematurely show an increased prevalence of white matter damage on brain ultrasound scans compared to preterm neonates that have not been subjected to FGR, the former being associated with motor and cognitive impairments [35]. It has been suggested that the pathogenesis of brain injury in FGR involves oxidative stress that leads to periventricular white matter injury due to damage to oligodendrocytes, impaired myelination and astrogliosis [37]. Neurocognitive and behavioral deficits seen in FGR infants have also been attributed to suboptimal gray and white matter connectivity. Diffusion-weighted MR imaging and tractography studies also show diffuse white matter injury, which may be caused by disturbances in cortico-thalamic connectivity [26].

In addition to connectivity alterations, significant changes have been described in brain vasculature of FGR neonates. The loss of cerebrovascular autoregulation that occurs in FGR is known to contribute to the development of intraventricular hemorrhage (IVH) and periventricular leukomalacia (PVL) in neonates [38, 39]. Cerebral white matter (WM) is extremely vulnerable to perfusion-related injury because it receives only 25% of the blood flow of cortical grey matter and, during development, is immature in its ability to autoregulate blood flow [40]. Under-perfusion of WM regions of the fetal brain would likely have a significant effect on brain development in the later stages of gestation, when myelination is at its peak

[41]. Fetal cerebral vessels are one of the vascular beds most sensitive to poor substrate delivery caused by pathological conditions during intrauterine life. Despite this, research on the pathogenesis of perinatal brain injury in FGR has focused on excitotoxicity, oxidative stress and inflammatory response, with the response of the developing cerebral vasculature receiving little attention. Although IVH has been thought to occur mainly in preterm infants ≤ 32 weeks of gestation, two large recent population-based studies reported that the incidence of IVH was low in FGR infants born < 28 weeks' gestation compared with non-FGR preterm infants, but there was increased frequency of IVH in FGR infants born 34–40 weeks' gestation [42, 43]. These data confirm that FGR is indeed a significant risk factor for IVH in late-preterm and term infants.

2.3. Chorioamnionitis

Chorioamnionitis describes infection of the fetal membranes during pregnancy, typically results from ascending bacterial contamination from the vagina into the uterus, and is a principal cause of preterm delivery [44]. Chorioamnionitis manifests clinically with maternal fever, uterine tenderness and maternal or fetal tachycardia. There is no specific treatment for this condition aside from antibiotics. Many cases of chorioamnionitis are, however, clinically silent, diagnosed by histological examination for increased infiltration of neutrophils into the fetal membranes after birth [45].

Chorioamnionitis can induce a fetal inflammatory response characterized by an increase in pro-inflammatory cytokines, including interleukin (IL)-6 and IL-1 β that are detectable in the systemic circulation and the brain of neonates, after birth [46]. This rapid increase in cytokines leads to mobilization of immune effector cells into the peripheral circulation. These cells can then cross the blood brain barrier (BBB) and activate microglia, which leads to further release of pro-inflammatory cytokines and reactive oxygen species and initiates cellular excitotoxicity [47]. Animal studies strongly support these findings and have shown that, in models using lipopolysaccharide administration to induce a fetal inflammatory reaction, microglia are activated in the white matter [48] and BBB integrity is compromised [49], allowing further infiltration of immune cells and large molecules into the brain. These processes of inflammation lead to damage to immature oligodendrocytes (the cells that make myelin) within the developing brain, resulting in hypomyelination and profound white matter injury [50]. To support the theory of an excessive pro-inflammatory response leading to white matter injury, maternal administration of anti-inflammatory IL-10 prevents inflammation and white matter injury in a rat chorioamnionitis model [51]. In human studies, chorioamnionitis and a subsequent fetal systemic inflammatory response is strongly associated with the development of cerebral palsy [52].

2.4. Preterm birth

Preterm birth (> 37 weeks of gestation) is the most important cause of neonatal mortality and morbidity, with the smallest and youngest infants at greatest risk of short-term and long-term adverse consequences. In 2010, it was estimated that preterm births complicated 11.1% of all live births worldwide and preterm birth complications are the largest direct cause of neonatal

deaths, accounting for a million infant deaths a year [53]. Improvements in neonatal intensive care have greatly improved survival of preterm infants; however, these infants remain vulnerable to many complications in the perinatal period, including respiratory distress syndrome, chronic lung disease, injury to the intestines, a compromised immune system, cardiovascular disorders, hearing and vision problems and neurological insult. Long-term neurodevelopmental sequelae associated with prematurity are cerebral palsy, mental retardation, learning difficulties and poor health and growth [54]. Advances in neuroimaging now play an important role in the diagnosis and management of the preterm infant. Both cranial ultrasound and conventional MRI techniques are useful in diagnostic and prognostic evaluation of preterm brain development and injury. While both the grey and white matter of the brain are susceptible to altered development and injury in preterm-born infants, it is well recognized that white matter injury is the primary neuropathology associated with preterm birth, particularly those infants born extremely preterm (<28 gestation) [55].

The most common white matter neuropathologies described in preterm infants are intraventricular hemorrhage (IVH) and periventricular leukomalacia (PVL), where both are strongly linked to adverse cognitive and motor outcomes. The pathogenesis of PVL in preterm birth relates to three maturation-dependent processes with the brain: (i) an incomplete state of development of the vascular supply to cerebral white matter; (ii) impairment in regulation of cerebral blood flow to cerebral white matter and (iii) vulnerability of oligodendroglial precursor cells—the major cellular target in PVL [41]. Although white matter injury is the predominant neuropathology of prematurity, this is frequently accompanied by neuronal and axonal injury affecting the thalamus, basal ganglia, cerebral cortex, brain stem and cerebellum and is termed “encephalopathy of prematurity” [55]. Additionally, two types of PVL have been described: cystic PVL, (cavitation and periventricular cyst formation) and non-cystic PVL, which is a more widespread and diffuse injury with glial scar formation. Diffuse white matter injury, together with gray matter and hippocampal abnormalities [56], are now the most common types of cerebral abnormalities associated with prematurity as focal necrotic lesions characteristic of cystic PVL are now rarely observed in premature infants in developed countries [57].

The etiology of cerebral lesions in the preterm infant remains somewhat unclear, but it is generally accepted that hypoxic and inflammatory pathways are involved [58]. Preterm infants have a propensity to develop HI, particularly within the white matter. Intrauterine exposure to infection and fetal inflammation are also related to an increased risk for PVL and cerebral palsy. Cerebral vascular development is incomplete in prematurely born infants, with under-vascularized end-zones in cerebral white matter [59, 60]. Long penetrating vessels, derived mainly from the middle cerebral arteries, terminate in the deep periventricular white matter and are the most sensitive to changes in cerebral perfusion [61]. Active development of the periventricular vasculature occurs in the last 16 weeks of gestation [62], thus the increased vulnerability to ischemia in very premature infants may be related to immaturity of the vascular bed. Physiologically, positron emission tomography (PET) studies show that cerebral blood flow in the white matter of premature infants is very low (only 25% of CBF to the cortex) [40], and white matter, therefore, may be vulnerable to even slight decreases in cerebral perfusion [63].

Germinal matrix hemorrhage (GMH) can be observed in preterm neonates, particularly those born <30 weeks' gestation, and is more common when babies suffer additional complications such as respiratory distress syndrome, pneumothorax, or high blood pressure [64]. GMH is contributed by fragile blood vessels within the germinal matrix of the brain, particularly during the period of high cell proliferation (24–32 weeks' GA) associated with corticogenesis. Over this period of gestation the oxygen and nutrient demand of the germinal matrix is high, and therefore blood flow is relatively high, however, the vessels remain immature and fragile [65]. GMH is associated with bleeding into the brain's ventricles (IVH), principally because of their close proximity. The etiology of GMH and IVH are not well understood but may be linked to deficient autoregulatory capacity and pressure-passive cerebral perfusion, although it is unclear if hypo- or hyper-tension, or increased intravascular pressure, leads to rupture of cerebral vessels [66].

At the cellular level, it is now established that white matter injury in preterm infants is predominantly due to vulnerability of immature oligodendrocytes, which are in a phase of active development during weeks 24–40 of gestation [41, 63]. These pre-oligodendrocytes are exquisitely sensitive to altered intracerebral environment and insults that may include hypoxia, ischemia, inflammation, excitotoxicity and free-radical attack [67]. More recently, experimental animal and human autopsy data have shown that myelination failure is primarily due to arrested maturation of the oligodendrocyte lineage at the pre-oligodendrocyte stage, rather than depletion of the oligodendrocyte pool [68]. Oligodendrocyte maturation from pre-oligodendrocytes to immature and mature myelinating oligodendrocytes occurs between about 24 and 32 weeks of human gestation, which corresponds to a critical period for preterm birth and white matter brain injury [69]. Long-term follow up MRI studies of preterm infants show a long-term reduction in brain cortical surface area, cortical folding and volume of subcortical and white matter regions, in addition to microstructural abnormalities and functional deficits [70–72]. Furthermore, it has been suggested that the neurological deficits apparent in preterm infants are strongly associated with decreased neuronal connectivity, with a significant link between frontal and temporal lobe volumes and thalamic and cortical white matter tract reduction [73], in preterm infants (median 28 weeks' gestation) with further tractography studies revealing reduced connectivity between the thalamus and the cortex [74]. Disruption of early contact between these two brain structures may also disrupt connectivity and result in remodeling of cortical circuitry [75].

3. Umbilical cord blood as a therapy for perinatal brain injury

A number of identified sources of stem cells have been examined for their neuroprotective benefits. Traditionally, stem cells derived from bone marrow have been examined for their use in treatment of hematological diseases and were the first stem cells trialed in most pre-clinical neurological/neurodegenerative studies. Umbilical cord blood (UCB) is a particularly promising source of stem and progenitor cells that is appealing for treatment of perinatal brain injury—UCB is readily available at birth for routine collection, particularly in situations of compromised (preterm or term asphyxia) births; contains large numbers of mononuclear

cells with a heterogeneous population of stem and progenitor cells [76]; has low immunogenicity and low risk of rejection, therefore allowing the potential for allogeneic administration [77]. UCB cells demonstrate high plasticity with an eightfold greater proliferation potential compared to other cell sources such as bone marrow [78]; and can be stored for long periods of time, with studies showing that, after 10+ years of cryopreservation, viable cell recovery is still very high [79].

Principally, the beneficial properties of UCB are dependent on the mononuclear cell composition, with this cell fraction comprising five important cell types (**Figure 1**)—mesenchymal stromal cells (MSCs), endothelial progenitor cells (EPCs), hematopoietic stem cells (HSCs), T regulatory cells (Tregs) and monocyte-derived suppressor cells (MDSCs) [80]. Each of these cell types is readily identifiable in human cord blood by their cell surface markers. In isolation, each of these populations exhibits properties that could contribute to preventing the cascade of brain injury that transpires after perinatal hypoxia-ischemia.

3.1. Umbilical cord blood—mononuclear cells

UCB mononuclear cells are the fraction of cells that are collected after gradient separation of red blood cells and plasma. This fraction of cells includes lymphocytes, monocytes and all stem and progenitor cells. Most studies investigating the potential of UCB use this mononuclear fraction. Initial neuroprotection studies were performed in adult stroke models, induced via middle cerebral artery ligation in rats [81, 82]. Interestingly, factors released from injured brain tissue increased the chemo-attraction of UCB cells compared to exposure to normal brain tissue, indicative that UCB cells do indeed have the ability to home to sites of injury [82]. Another study administered mononuclear cells intravenously at 48-h post-stroke and showed

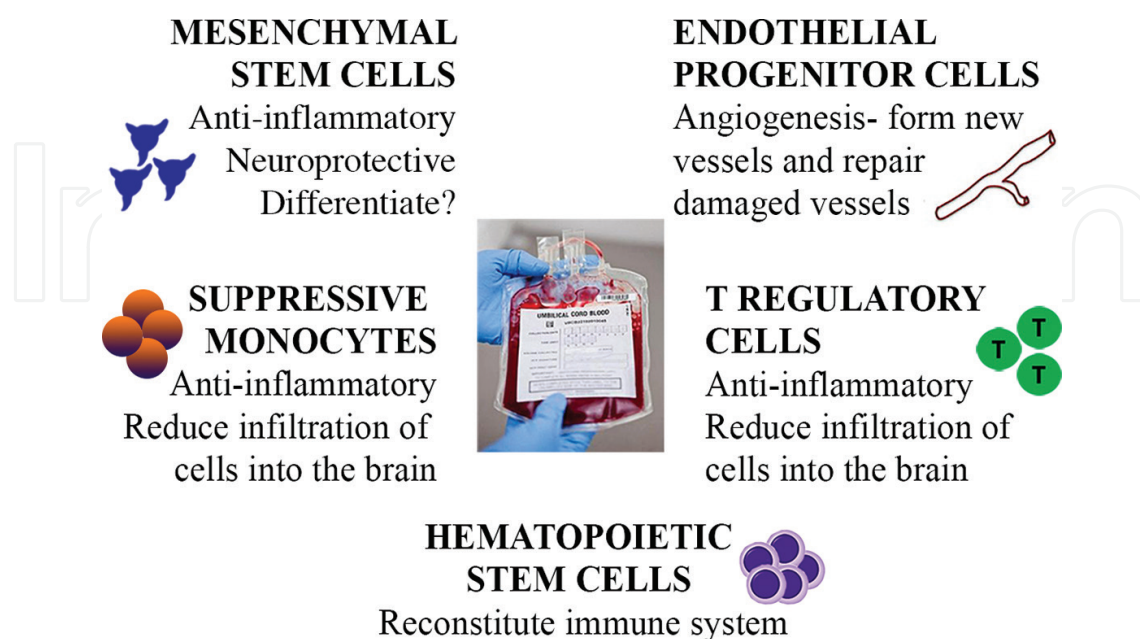


Figure 1. Potential therapeutic cell types found in umbilical cord blood.

white matter protection [81] and, *in vitro*, UCB cells were able to protect oligodendrocytes by reducing the expression of caspase-3 and lactate dehydrogenase.

A number of studies have since investigated the potential of UCB mononuclear cells for the treatment of neonatal brain injury, using a modified adaptation of the Rice-Vannucci model [83] for induction of hypoxic-ischemic brain injury in day 7 neonatal rat pups. Administration of 2 million UCB mononuclear cells at 3 h after HI reduced neuronal degeneration and caspase-3 expression by 25% and, at 7 days, microglial activation was significantly reduced in the cortex [84]. UCB given 24-h post-neonatal HI injury normalized toe spread and forepaw symmetry, increased sensorimotor electrophysiology and decreased spastic paresis [84, 85]. Wang et al. [86] administered UCB cells directly into the ventricles, 24-h post-HI injury, and showed a decrease in neuronal loss in the cortex and CA1 region of the hippocampus. This was associated with an increase in neural stem cells within the subventricular zone and an increase in sonic hedgehog (Shh) and its effector Gli-1. We were the first to publish preclinical data evaluating the efficacy of UCB cells in large animal models of fetal and neonatal HI brain injury [87, 88]. Using a term birth asphyxia sheep model, we showed that UCB therapy at 12-h post-HI insult reduced neuronal cell death, astrogliosis and inflammation [87]. We have recently demonstrated that UCB cells reduce white matter brain injury in preterm sheep when cells are administered at 12-h post-HI, and to a lesser extent when administered at 5 days after HI, acting to reduce neuroinflammation and protecting oligodendrocytes [88]. UCB mononuclear cells are also now being used in human clinical trials for established cerebral palsy, but this is discussed in detail later in the chapter.

3.2. UCB-derived hematopoietic stem cells

UCB was first investigated due to its rich population of hematopoietic stem cells (HSCs). HSCs are positive for CD34 and characterized by their ability to self-renew, and to repopulate the immune system, and thus are used clinically for the treatment of many hematological disorders. In recent years, CD34+ cells from UCB and other sources have been investigated as therapies for non-hematological diseases. In an adult stroke model, transplantation of CD34+ cells 24-h post-stroke has been shown to significantly improve motor function, but this is highly dependent on administration timing as, when cells are given at 7 days, they were not as effective [82]. When stroke was induced in adult immuno-compromised mice and CD34+ cells were given 48 h later, there was improved neovascularization, increased migration of neural progenitor cells to the injured area and improved functional recovery [89]. In a neonatal HI model in postnatal day 12 mice, administration of CD34+ cells increased neurogenesis in the dentate gyrus 14 days later, but this effect was sex-specific and only seen in males [90]. Another study by Tsuji and colleagues [91] found that when CD34+ cells were given to postnatal day 12 mice following a middle cerebral artery occlusion, there was no change in cerebral blood flow, no difference in tissue loss at 9-day post-injury and no difference in behavioral outcomes, although at 7 weeks post-stroke, there was an improvement in tissue loss [91]. When comparing mononuclear cells, CD34+ cells or CD34- cells, all cell fractions reduced neurofunctional deficits and reduced lesion volume in a rodent stroke model, but UCB-derived mononuclear cells (with all cell types present), were more beneficial than the other cells fractions alone [92]. This study suggests that while CD34+ cells may play a role in

the neuroprotective benefits of UCB, there are other cells present in cord blood that may also contribute to protection against brain injury.

3.3. UCB-derived mesenchymal stromal cells

Mesenchymal stromal cells (MSCs) can be isolated from a number of sources including bone marrow, fat, umbilical cord tissue and dental pulp. MSCs have the ability to differentiate into mesodermal lineages to produce osteocytes, myocytes and adipocytes [93]. MSCs from UCB have been postulated to provide the principal neuroprotective benefit of UCB [94]. Initially, this proposal was based on the ability for MSCs to differentiate into a variety of cell types in response to cues from the microenvironment, including oligodendrocyte progenitor-like cells [2, 95]. More recent evidence suggests that the neuroprotective actions of MSCs are not due to engraftment or differentiation of MSCs within the brain. Rather, MSCs adapt and mediate the local response to HI via anti-inflammatory effects and secretion of growth and differentiation factors [96]. Using a neonatal stroke model in postnatal day 10 rats, UCB-MSCs were administered intravenously within 6 h of the insult. After 28 days, there was decreased lesion volume, cell death, microglial activation, astrogliosis and functional improvement was observed in the rotarod and cylinder test [97]. Another study induced HI at postnatal day 7 and injected UCB-MSCs directly to the brain 3 days after the HI injury, to show that labeled cells were detectable in the brain 7 days after administration and appeared to express glial fibrillary acidic protein (GFAP), an astrocyte marker. By day 28, there was reduced neuronal loss in the cortex and improved behavioral outcomes compared to controls [98].

Interestingly, however, it is now evident that MSCs are not present in all UCB samples. For example, one study reports as little as 10–30% success rate for isolation of MSCs from term UCB samples [99], and this percent is further reduced with cryopreservation [99]. Given the low frequency of MSCs in UCB, we postulate that other cell types are more likely to contribute to the anti-inflammatory and neuroprotective effect observed with UCB treatment. Nevertheless, given the potent anti-inflammatory properties of MSCs, many studies have investigated the potential of UCB-derived MSCs for perinatal brain injury.

The current treatment for neonates that have suffered a severe HI injury at birth is hypothermia, where the neonates are cooled to approximately 33–34°C within the first 6 h of life. Interestingly, a rodent study that examined severe neonatal HI brain injury, administered MSCs and hypothermia within 6 h of the HI insult and found that co-therapy was far more effective at reducing cell death, inflammation and behavioral deficits than either MSC or hypothermia treatment alone [100]. This finding is important, since hypothermia is now standard care for HIE in high resource countries and therefore any additional therapy would need to work synergistically with cooling.

3.4. UCB-derived endothelial progenitor cells

Endothelial progenitor cells (EPCs) were first identified in human peripheral blood [101]. EPCs are essential for vascular growth and homeostasis and play an integral role in tissue repair and regeneration. While there remains much controversy over the classification of EPCs, in this review, we will discuss any cell from UCB that has endothelial potential,

including CD133+ cells, endothelial colony-forming cells and late- and early-outgrowth endothelial cells. It is well understood that EPCs are mobilized into the peripheral blood after traumatic, inflammatory or ischemic injuries and they can home to sites of injury and participate in neovascularization [102]. EPCs primarily work in two ways: (1) by physical incorporation into new blood vessels within the target tissue, therefore improving oxygenation and nutrient delivery into the injured area [103]; and (2) in a paracrine manner, by secreting factors that create a niche environment that can support differentiation of other progenitor cells [104, 105]. Umbilical cord blood (UCB) is a rich source of EPCs.

Studies have shown that circulating EPC levels are predictive of severe neurological impairment after acute stroke, and increased EPC levels are correlated with good functional outcome and reduced infarct size [106]. Despite recruitment of *endogenous* EPCs from bone marrow following injury cues, these mechanisms are easily overwhelmed and tissue regeneration fails. Systemic administration of expanded bone marrow-derived EPCs to adult mice after stroke results in significant protection against brain injury; reducing infarct volume, decreasing neutrophil infiltration, and increasing focal blood flow at 48 h after ischemia [106]. In a mouse model of focal ischemia, bone marrow-derived EPC administration induces blood vessel sprouting at the boundary of the ischemic lesion. This closely corresponded to elevated cerebral blood flow detected on perfusion-weighted MRI, indicating the presence of neovascularization, while cells positive for markers of mature endothelial cells were incorporated into the vasculature [107]. UCB-derived EPCs accumulated in the stroke-affected hemisphere of rats, and acted to reduce stroke volume [108].

An *in vitro* study, using neural cells isolated from 3 day-old rats, cocultured the neural cells with EPCs in an hypoxic environment, and showed that the presence of EPCs increased cortico-spinal axonal growth by threefold, and decreased hypoxia-induced apoptosis [109], suggesting that EPCs play a direct role in neuroprotection. Ding and colleagues transfected EPCs with luciferin to enable live cell tracking after injection of the EPCs at 24-h post-stroke in adult mice and labelled EPCs were widely detected in the brain at 1 and 4 days after injection. At day 7, there was a faint signal, but the cells could not be detected at 14 days, despite a significant decrease in the infarct size, an increase in neural progenitor cells in the subventricular zone and increased vascular density in the EPC-treated mice [110]. Recently, a study investigated the potential of EPCs for neonatal HI brain injury in severe combined immunodeficient (SCID) mice [111]. EPCs were administered 24-h post-HI-injury and, after 48 h, they had migrated towards the brain and motor function was improved.

3.5. UCB-derived T regulatory cells

T regulatory cells (Tregs) play an essential role in modulating the immune response, and infusion of Tregs is beneficial for treatment of inflammatory disorders [112]. UCB is a rich source of highly naïve Tregs that demonstrate enhanced proliferation and functional potential compared to Tregs isolated from adult blood [113]. To date, the main therapeutic use of Treg cells has been focused on preventing graft-versus-host-disease (GVHD). This research has been very promising and, as a result, groups have been developing cell expansion technologies as a way to increase cell yield and immunosuppressive function of Tregs isolated from UCB,

making them a more viable clinical and commercial therapy [114]. A recent clinical trial successfully used expanded Tregs from UCB to prevent the incidence of GVHD following transplantation of UCB [115]. The results from this trial were very promising with no reported adverse events and a reduced incidence of GVHD in the Treg-treated group.

Given the potent immunosuppressive ability of Tregs, they may play a very important role in suppressing neuroinflammation associated with hypoxia-ischemia, but, to date, no studies have examined the therapeutic potential of Tregs in neonatal brain injury. However, in an adult stroke model, intravenous Treg therapy significantly decreased cerebral inflammation, decreased brain infarct size and improved long-term neurological function [116]. Treg cells also reduced the neutrophil-mediated production of matrix metalloproteinase 9 (MMP9) and subsequently protected the integrity of the blood brain barrier [116]. A further study showed that administered Tregs were present *in vivo* for >12 days, they reduced expression of inflammatory cytokines in the plasma and improved immune function after stroke [117], where immuno-compromise is considered a very serious side effect following stroke.

3.6. UCB-derived monocyte derived suppressor cells

A recently discovered subset of immunosuppressive cells that are being keenly investigated are monocyte-derived suppressor cells (MDSCs)—a heterogeneous population of cells that include immature macrophages, granulocytes, dendritic cells and other myeloid cells [118, 119]. MDSCs are present in significantly higher number in UCB compared to adult peripheral blood, but cell number falls dramatically in the months after birth [3]. MDSCs can significantly suppress T cell proliferation, T helper (Th)1, Th2 and Th17 cytokine production and activation of natural killer (NK) cells [120]. The mechanisms by which MDSCs elicit this effect is cell-contact dependent and also involves the secretion of soluble factors such as IFN- γ , iNOS and Arginase-1 [3, 121–123]. The therapeutic potential for MDSCs have been mostly investigated in relation to cancer, however emerging data suggests they may play a role in other inflammatory conditions. For example, in a multiple sclerosis mouse model, endogenous MDSCs were found in demyelinating lesions and their presence correlated with the time course of the disease. *In vitro*, these cells could significantly suppress T-cell responses, suggesting that indeed MDSCs may play a role in reducing neuroinflammation [123].

While the role of MDSCs have not been studied in neonatal brain injury, a recent study showed that depleting monocytes from UCB acted to decrease motor improvement and microglial suppression in an adult stroke animal model, suggesting that UCB-monocytes may actively mediate neuroprotective benefits of UCB [124]. Whether this function is directly due to MDSCs is yet to be elucidated, but these cells may be promising as a potential therapeutic target for suppressing inflammation in perinatal brain injury.

3.7. What is known about the mechanisms of how UCB cells protect against brain injury

Given the heterogeneity of cells with UCB, there are many potential mechanisms by which UCB could protect against perinatal brain injury, ranging from a receptor-mediated response to stimulation of factors released from the injured brain, to protecting against blood brain barrier and vascular damage, to anti-inflammatory potential through the secretion of specific cytokines.

A potential mechanism by which UCB cells respond to and protect against brain injury is via stromal derived factor (SDF)-1. SDF-1 is upregulated in the neonatal brain 7-day post-HI injury and is derived from astrocytic end-feet processes along blood vessels and from endothelial cells [125]. UCB mononuclear cells express the SDF-1 receptor, CXCR4 and inhibition of SDF-1 reduces migration of UCB cells to the lesion site following neonatal HI injury [126]. In addition, monocyte chemoattractant protein (MCP)-1 and macrophage inflammatory protein (MIP)-1 receptors are expressed on UCB cells and could be other potential receptors that allow migration of UCB cells to the injured brain [127].

Cytokines and chemokines play a central role in inflammation, and UCB cells have been shown to secrete MCP-1, interleukin (IL)-6, IL-8, IL-10, angiogenin, vascular endothelial growth factor, brain derived neurotrophic factor and platelet derived growth factor, which all have protective potential to mediate inflammation, apoptosis, cell survival and angiogenesis [128, 129]. Furthermore, coculture of UCB cells with neural cultures exposed to oxygen and glucose deprivation for over 3 days showed that UCB upregulated the expression of chemokines CCL5, CCL3 and CXCL10 and subsequently reduced neuronal apoptosis to levels observed in normoxic cultures [130].

Sonic hedgehog (Shh) has also been postulated to play an important role in the neuroprotective potential of UCB cells. It was shown that, following UCB administration, there was reduced neonatal brain injury in the cortex and this was accompanied by an increased expression of both Shh and Gli-1 [86]. Furthermore, when cyclopamine, an inhibitor of Shh, was administered prior to the UCB treatment, neuroprotection was abolished [86].

Another aspect that is frequently discussed in relation to cell therapies for brain injury is the necessity of cells to enter the brain to elicit an effect, and whether the blood brain barrier (BBB) needs to be disrupted for this to happen. A study in neonatal rats that received a HI injury used mannitol, a drug that can increase BBB permeability, followed by administration of UCB cells [131]. They found that expression of neurotrophic factors was increased in the animals that received both UCB cells and mannitol, compared to either therapy alone, and neurobehavioral outcomes were improved at 7- and 14-day post-HI. Interestingly, mannitol did not increase the rate of UCB engraftment within the brain, but clearly disrupting the BBB increased the effectiveness of UCB therapy. This could be important as it suggests that mannitol could extend the therapeutic window for UCB treatment after birth.

4. UCB in clinical trials

The first successful UCB transplantation was performed in 1988 in which the cells were able to reconstitute the immune system of a patient with Fanconi's anemia [132]. Since then, over 20,000 UCB transplants have been performed with more than 3000 UCB transplants now conducted each year [133]. UCB is routinely used in the clinic for acute leukemia, aplastic anemia, lymphomas, hemoglobinopathy and sickle cell disease [134–136]. Initially, there was concern that UCB therapies may struggle to translate to adult conditions as the number of

cells present in UCB units is generally limited and less than required to treat adult conditions or when multiple doses are required. However, it is now been shown that it is feasible to use two independent UCB units at once to overcome insufficient cells present in a single UCB unit [137]. Furthermore, with rapid advances in technology for the expansion of stem cells, it is likely that expanded stem cells isolated from UCB units will allow administration of larger cell doses from a single UCB unit [133].

Cerebral palsy (CP) is the most well-recognized condition resulting from perinatal brain injury. It is a clinically described complex of motor symptoms, with disability ranging from mild motor coordination dysfunction through to significant hemiplegia or quadriplegia, reflecting variable injury to the young brain. The motor disabilities that define CP are also often coexistent with other serious deficits—1 in 2 children with CP have intellectual disabilities including cognition, memory, learning and behavior deficits; 1 in 4 have epilepsy; 1 in 4 cannot talk; 1 in 4 are incontinent [138]. Parents of infants with CP are actively seeking new treatment options, including the use of stem cell therapies, particularly UCB therapy [139]. Cerebral palsy is currently ranked as the second most commonly treated condition with stem cells, and Australia is the third highest ranked country of patient origin for overseas treatments [140].

There are now a number of registered clinical trials, and a few completed trials, investigating UCB cell treatment for CP in children ranging from 10 months to 20 years old (**Table 1**). Two randomized control trials (RCT) have published results; Min and colleagues [139] investigated allogeneic UCB in combination with erythropoietin (EPO) vs. EPO and rehabilitation or rehabilitation alone. Their cohort was treated between 10 months and 10 years of age after diagnosis of CP, and children received an average 30 million cells per kg. At 6 months after treatment, improvements in gross motor function measure and cognitive scores were observed using the Bayley Scale. Unfortunately, however, this trial did not assess the efficacy of UCB alone. The second RCT treated CP patients between 6- and 20-year old with allogeneic UCB and they received up to 20 million cells per kg [141]. At 1- and 3-month posttreatment, muscle strength improved and by 6 months improvements were observed on gross motor function measure. Interestingly, they noted that the higher the cell dose given to the patient the better the outcome, suggesting that cell dose is critical for efficacy. This is confirmed by a further study in which administration of greater number of allogeneic UCB cells was associated with better outcome at 36 months [142]. A handful of smaller, non-RCT trials have also added to our knowledge on the efficacy of UCB for treating established CP [142–144]. CP patients with diplegic or hemiplegic deficits improved more after receiving autologous UCB cells, than children with quadriplegic disorders [143]. A Duke University trial has been conducted for administration of fresh autologous UCB to infants diagnosed with hypoxic ischemic encephalopathy and undergoing hypothermia treatment [144]. While this study has not yet reported neuroprotective efficacy, it is the first to show safety and feasibility for the early use of UCB cells as a prevention/early intervention therapy, rather than a reparative therapy for established CP. The same group at Duke University have a number of clinical trials registered (**Table 1**) investigating both autologous and sibling matched UCB transplantation, while reports are encouraging, we still await results from these trials.

Study title	Main objective	Institution	Treatment	Current status	Trial identifier
Allogenic umbilical cord blood and erythropoietin combination therapy for cerebral palsy	To determine efficacy of umbilical cord blood and erythropoietin combination therapy for children with cerebral palsy	Sung Kwang Medical Foundation, Korea	Umbilical cord blood and erythropoietin combination	*Completed Has results <i>Min et al. Stem Cells: Translational and Clinical Research, 2013 3:581</i>	NCT01193660
Umbilical cord blood therapy for cerebral palsy	To evaluate the efficacy of umbilical cord blood therapy for children with cerebral palsy	Bundang CHA Hospital, Republic of Korea	Donated umbilical cord blood units	Completed	NCT01528436
A randomized study of autologous umbilical cord blood reinfusion in children with cerebral palsy	To determine the efficacy of a single intravenous infusion of autologous umbilical cord blood for the treatment of pediatric patients with spastic cerebral palsy	Duke University Medical Centre, United States	Autologous umbilical cord blood	Completed	NCT01147653
Umbilical cord blood therapy for children with cerebral palsy	To evaluate the efficacy of umbilical cord blood therapy for children with cerebral palsy	Bundang CHA Hospital, Republic of Korea	Donated umbilical cord blood units	Completed	NCT01639404
Assessment of the safety of allogeneic umbilical cord blood infusions in children with cerebral palsy	A single site, phase I, prospective study of the safety of intravenous sibling cord blood infusion	Duke University Medical Centre, United States	Sibling umbilical cord blood	Active, not recruiting	NCT02599207
Allogeneic umbilical cord blood therapy in children with CP	To analyze cytokines related to clinical outcomes of allogeneic umbilical cord blood therapy for children with cerebral palsy	Bundang CHA Hospital, Republic of Korea	Allogeneic umbilical cord blood	Unknown	NCT02025972
Safety and effectiveness of banked cord blood or bone marrow stem cells in children with cerebral palsy (CP). (ACT for CP)	To compare the safety and effectiveness of two types of stem cells, (either banked cord blood or bone marrow), in children between the ages of 2–10 years with CP	University of Texas Health Science Centre, Houston, USA	Autologous umbilical cord blood or bone marrow	Currently recruiting	NCT01988584
Safety and effectiveness of cord blood stem cell infusion for the treatment of cerebral palsy in children	To test the safety and effectiveness of a cord blood infusion in children who have motor disability due to cerebral palsy. The subjects will be children whose parents have saved their infant's cord blood, who have non-progressive motor disability, and whose parents intend to have a cord blood infusion	Georgia Regents University, United States	Infusion of red-cell depleted, mononuclear cell enriched cord blood	Currently recruiting	NCT01072370

Study title	Main objective	Institution	Treatment	Current status	Trial identifier
Characterization of the cord blood stem cell in situation of neonatal asphyxia (NEOCORD)	To characterize cord blood stem cells of neonates with neonatal asphyxia and to compare them with those from healthy newborn	Assistance Publique Hopitaux De Marseille	Autologous umbilical cord blood reinfusion	Completed	NCT01284673
Autologous stem cells in newborns with oxygen deprivation	To determine if the plasticity of autologous intravenous administration of cord blood stem cells would improve the clinical course of asphyxiated newborns	Hospital Universitario, Monterrey, Mexico	IV infusion of autologous cord and placental cord blood	Unknown	NCT01506258
Allogeneic UCB therapy with EPO in children with CP	A randomized controlled study aims to evaluate the efficacy and safety of allogeneic umbilical cord blood therapy combined with erythropoietin for children with cerebral palsy	CHA Bundang Medical Centre Korea	Allogeneic umbilical cord blood	Unknown	NCT01991145
G-CSF and autologous cord blood infusion in cerebral palsy	To reveal the safety and feasibility of combination therapy with autologous cord blood mononuclear cells (CB) and G-CSF as well as repeated administration of G-CSF for children with cerebral palsy	Hanyang University Seoul, Korea	Autologous umbilical cord blood	Recruiting	NCT02866331
Combination therapy of cord blood and G-CSF for patients with brain injury or neurodegenerative disorders	To investigate the efficacy and safety of the combination therapy of allogeneic umbilical cord blood (UCB) and granulocyte-colony stimulating factor (G-CSF) for patients with brain injury or neurodegenerative disorders	CHA Bundang Medical Centre Korea	Allogeneic umbilical cord blood	Unknown	NCT02236065
Autologous umbilical cord blood transfusion for preterm neonates	To test feasibility of collection, preparation and infusion of autologous umbilical cord blood in the first 14 days after birth if the baby is born premature <35 weeks of gestation	Ain Shams University, Cairo, Egypt	Autologous cord blood transfusion	Unknown	NCT01121328
Autologous cord blood cells for brain injury in term newborns	To test feasibility and safety of collection, preparation and infusion of autologous umbilical cord blood during the first 3 days of age if the baby is born with signs of brain injury	National University Hospital, Singapore	Autologous cord blood	***Unknown	NCT01649648

Study title	Main objective	Institution	Treatment	Current status	Trial identifier
Cord blood for neonatal hypoxic-ischemic encephalopathy	A pilot study to test feasibility of collection, preparation and infusion of a baby's own umbilical cord blood in the first 14 days after birth if the baby is born with signs of brain injury	Duke University, United States	Infusions autologous volume reduced cord blood cells	Active, not recruiting	NCT00593242
Efficacy of stem cell transplantation compared to rehabilitation treatment of patients with cerebral paralysis (CP)	To compare the efficacy of cell therapy and rehabilitation treatments for cerebral palsy patients	General Hospital of Chinese Armed Police Forces, Beijing China	Mesenchymal stem cells derived from umbilical cord blood	Recruiting	

Information obtained from ClinicalTrials.gov.

Table 1. Current clinical trials being conducted, or recently completed, using umbilical cord blood in regenerative medicine therapies for the management of cerebral palsy and ischemic brain injury in the newborn.

A meta-analysis on the efficacy of all reported stem cell trials for children with CP was recently performed, demonstrating a statistically significant intervention effect when patients were followed short-term to 6 months following treatment [145]. Furthermore, the effect was greatest in the trials using UCB, and overall, the treatment effect highly favors the use of UCB with or without rehabilitation to treat children with CP (**Figure 2**).

The first autologous transplant of UCB for pediatric ischemic stroke has recently been reported [146]. The work reports a child with right spastic hemiplegia who received 250 million UCB mononuclear cells at 5 years of age. At 3 months after treatment, there was an improvement in motor control, and further improvements were observed at 18 months, however, no change was

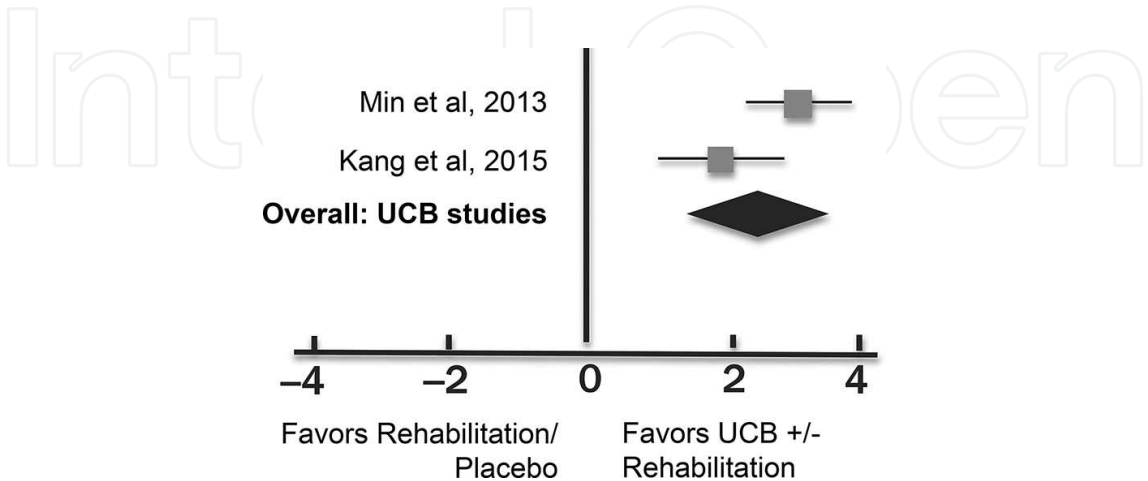


Figure 2. Forest plot showing the gross motor function changes from UCB transplantation for treatment of established cerebral palsy (adapted with permission from Novak et al. [145]).

observed on MRI. Another recent trial investigated the use of UCB for congenital hydrocephalus, where patients received multiple doses of autologous UCB with a median cell dose of 19 million cells/kg/infusion. No adverse events were reported while the UCB was also well-tolerated [147].

5. Future challenges for translation of umbilical cord blood therapies

Almost all available evidence supports that UCB cell therapy provides neuroprotective and/or neuroregenerative benefits in response to perinatal brain injury and established cerebral palsy. There do, however, remain a number of important questions around the *best practice* treatment with UCB cells to provide optimized outcomes for infants with perinatal brain injury. These questions are principally centered around whether whole cord blood (mononuclear cells) provides the best strategy, or whether individual cells (or combinations of cells) from cord blood should be expanded and subsequently administered to improve cell yield. Using this approach, cell therapy could be individualized depending on the pregnancy or birth complication. It is also not yet known what dose of cells is optimal, and when the cells should be administered relative to insult and diagnosis to provide the best outcome. All of these questions are best answered using animal models of chorioamnionitis, preterm birth, fetal growth restriction or birth asphyxia. A critical aim of designing novel therapies for perinatal brain injury is extending the treatment window so that cell therapy could be utilized for days to weeks after birth, not just within the 6 h of birth, as is necessary for hypothermia commencement in newborns with hypoxic ischemic encephalopathy. Ideally, cell therapy must be effective at mediating a spectrum of adverse events that occur within the perinatal brain, such as reducing glial scar formation, inflammation and neuronal cell death. In this review, we reveal that many cells derived from UCB have the potential to suppress inflammation and reduce brain injury when they are administered within 3-day post-injury. These results are encouraging, but it is important to appreciate that a successful and effective cell therapy will combine anti-inflammatory and neuroprotective abilities that will allow the ultimate goal of novel therapies for cerebral palsy, permitting a longer therapeutic window.

6. Conclusions

Cerebral palsy is caused by injury to the developing brain, with the timing and severity of the insult underlying the heterogeneity of CP. Clinical trials are already underway to treat established CP with UCB mononuclear cells with some positive results, however. It is widely appreciated that treating brain injury as early as possible will demonstrate the most profound benefits. Given the good safety profile of UCB therapies, with the low incidence of transplant rejection, due to the increased number of immature progenitor cells and naïve immune cells, it is clear that UCB is a safe source of cells for transplantation. Preclinical data are accumulating exciting evidence for the mechanisms of neuroprotection by stem cells, and meta-analysis of clinical trials shows that UCB cells mediate significant improvement for children with CP. The immediate imperative is to optimize the benefits of UCB therapy by conducting well-planned strategic animal studies followed by human clinical trials that can further inform the use of

targeted neuroprotective cell therapies for the prevention or repair of perinatal brain injury in order to provide long-term improvements for children after compromised pregnancy or birth.

Author details

Courtney A. McDonald¹, Margie Castillo-Melendez¹, Tayla R. Penny¹, Graham Jenkin^{1,2} and Suzanne L. Miller^{1,2*}

*Address all correspondence to: suzie.miller@monash.edu

1 The Ritchie Centre, Hudson Institute of Medical Research, Clayton, Australia

2 Department of Obstetrics and Gynecology, Monash University, Clayton, Australia

References

- [1] Li J, McDonald CA, Fahey MC, Jenkin G, Miller SL. Could cord blood cell therapy reduce preterm brain injury? *Frontiers in Neurology*. 2014;5:200.
- [2] Castillo-Melendez M, Yawno T, Jenkin G, Miller SL. Stem cell therapy to protect and repair the developing brain: a review of mechanisms of action of cord blood and amnion epithelial derived cells. *Frontiers in Neuroscience*. 2013;7:194.
- [3] Gervassi A, Lejarcegui N, Dross S, Jacobson A, Itaya G, Kidzeru E, et al. Myeloid derived suppressor cells are present at high frequency in neonates and suppress in vitro T cell responses. *PLoS One*. 2014;9(9):e107816.
- [4] Stiles J, Jernigan TL. The basics of brain development. *Neuropsychology Review*. 2010;20(4):327–48.
- [5] Hagberg H, Gressens P, Mallard C. Inflammation during fetal and neonatal life: implications for neurologic and neuropsychiatric disease in children and adults. *Annals of Neurology*. 2012;71(4):444–57.
- [6] Johnston MV, Hoon AH, Jr. Cerebral palsy. *Neuromolecular Medicine*. 2006;8(4):435–50.
- [7] Barkovich AJ, Hajnal BL, Vigneron D, Sola A, Partridge JC, Allen F, et al. Prediction of neuromotor outcome in perinatal asphyxia: evaluation of MR scoring systems. *AJNR American Journal of Neuroradiology*. 1998;19(1):143–9.
- [8] Kurinczuk JJ, White-Koning M, Badawi N. Epidemiology of neonatal encephalopathy and hypoxic-ischaemic encephalopathy. *Early Human Development*. 2010;86(6):329–38.
- [9] Paolo T. The high-risk newborns. *The Journal of Maternal-Fetal & Neonatal Medicine: the Official Journal of the European Association of Perinatal Medicine, the Federation of Asia and Oceania Perinatal Societies, the International Society of Perinatal Obstet.* 2012;25(Suppl 1):6–7.

- [10] Ferriero DM. Neonatal brain injury. *The New England Journal of Medicine*. 2004;351(19):1985–95.
- [11] Blumberg RM, Cady EB, Wigglesworth JS, McKenzie JE, Edwards AD. Relation between delayed impairment of cerebral energy metabolism and infarction following transient focal hypoxia-ischaemia in the developing brain. *Experimental Brain Research*. 1997;113(1):130–7.
- [12] Gunn AJ, Thoresen M. Hypothermic neuroprotection. *NeuroRx: the Journal of the American Society for Experimental NeuroTherapeutics*. 2006;3(2):154–69.
- [13] Zehendner CM, Librizzi L, Hedrich J, Bauer NM, Angamo EA, Curtis Md, et al. Moderate hypoxia followed by reoxygenation results in blood-brain barrier breakdown via oxidative stress-dependent tight-junction protein disruption. *PLoS One*. 2013;8(12): e82823.
- [14] Inder TE, Volpe JJ. Mechanisms of perinatal brain injury. *Seminars in Neonatology*. 2000;5(1):3–16.
- [15] Glass HC. Neonatal seizures: advances in mechanisms and management. *Clinics in Perinatology*. 2014;41(1):177–90.
- [16] Fan X, Heijnen CJ, van der Kooij MA, Groenendaal F, van Bel F. The role and regulation of hypoxia-inducible factor-1alpha expression in brain development and neonatal hypoxic-ischemic brain injury. *Brain Research Reviews*. 2009;62(1):99–108.
- [17] Ferrari DC, Nesic O, Perez-polo JR. Perspectives on neonatal hypoxia/ischemia-induced edema formation. *Neurochemical Research*. 2010;35(12):1957–65.
- [18] Dammann O, O'Shea TM. Cytokines and perinatal brain damage. *Clinics in Perinatology*. 2008;35(4):643–63, v.
- [19] Li JM CA, Fahey MC, Jenkin G, and Miller SL. Could cord blood stem cell therapy reduce preterm brain inflammation. *Frontiers in Neurology*. 2014;5: 200.
- [20] Winerdal M, Winerdal ME, Kinn J, Urmaliya V, Winqvist O, Ådén U. Long lasting local and systemic inflammation after cerebral hypoxic ischemia in newborn mice. *PLoS One*. 2012;7(5):e36422.
- [21] Low JA, Galbraith RS, Muir D, Killen H, Pater B, Karchmar J. Intrauterine growth retardation: a study of long-term morbidity. *American Journal of Obstetrics & Gynecology*. 1982;142(6 Pt 1):670–7.
- [22] McMillen IC, Adams MB, Ross JT, Coulter CL, Simonetta G, Owens JA, et al. Fetal growth restriction: adaptations and consequences. *Reproduction (Cambridge, England)*. 2001;122(2):195–204.
- [23] Miller SL, Huppi PS, Mallard C. The consequences of fetal growth restriction on brain structure and neurodevelopmental outcome. *The Journal of Physiology*. 2016;594(4):807–23.
- [24] Rosenberg A. The IUGR newborn. *Seminars in Perinatology*. 2008;32(3):219–24.

- [25] Reveillon M, Urben S, Barisnikov K, Borradori Tolsa C, Huppi PS, Lazeyras F. Functional neuroimaging study of performances on a Go/No-go task in 6- to 7-year-old preterm children: impact of intrauterine growth restriction. *Neuroimage Clinical*. 2013;3:429–37.
- [26] Tolsa CB, Zimine S, Warfield SK, Freschi M, Sancho Rossignol A, Lazeyras F, et al. Early alteration of structural and functional brain development in premature infants born with intrauterine growth restriction. *Pediatric Research*. 2004;56(1):132–8.
- [27] Ramenghi LA, Martinelli A, De Carli A, Brusati V, Mandia L, Fumagalli M, et al. Cerebral maturation in IUGR and appropriate for gestational age preterm babies. *Reproductive Sciences (Thousand Oaks, Calif)*. 2011;18(5):469–75.
- [28] Hernandez-Andrade E, Figueroa-Diesel H, Jansson T, Rangel-Nava H, Gratacos E. Changes in regional fetal cerebral blood flow perfusion in relation to hemodynamic deterioration in severely growth-restricted fetuses. *Ultrasound in Obstetrics & Gynecology: the Official Journal of the International Society of Ultrasound in Obstetrics and Gynecology*. 2008;32(1):71–6.
- [29] Salihagic-Kadic A, Medic M, Jugovic D, Kos M, Latin V, Kusan Jukic M, et al. Fetal cerebrovascular response to chronic hypoxia—implications for the prevention of brain damage. *The Journal of Maternal-Fetal & Neonatal Medicine: the Official Journal of the European Association of Perinatal Medicine, the Federation of Asia and Oceania Perinatal Societies, the International Society of Perinatal Obstet*. 2006;19(7):387–96.
- [30] Basu S, Dewangan S, Barman S, Shukla RC, Kumar A. Postnatal changes in cerebral blood flow velocity in term intra-uterine growth-restricted neonates. *Paediatrics and International Child Health*. 2014;34(3):189–93.
- [31] Geva R, Eshel R, Leitner Y, Fattal-Valevski A, Harel S. Memory functions of children born with asymmetric intrauterine growth restriction. *Brain Research*. 2006;1117(1):186–94.
- [32] Geva R, Eshel R, Leitner Y, Valevski AF, Harel S. Neuropsychological outcome of children with intrauterine growth restriction: a 9-year prospective study. *Pediatrics*. 2006;118(1):91–100.
- [33] Lodygensky GA, Seghier ML, Warfield SK, Tolsa CB, Sizonenko S, Lazeyras F, et al. Intrauterine growth restriction affects the preterm infant's hippocampus. *Pediatric Research*. 2008;63(4):438–43.
- [34] Dubois J, Benders M, Borradori-Tolsa C, Cachia A, Lazeyras F, Ha-Vinh Leuchter R, et al. Primary cortical folding in the human newborn: an early marker of later functional development. *Brain*. 2008;131(Pt 8):2028–41.
- [35] Padilla-Gomes NF, Enriquez G, Acosta-Rojas R, Perapoch J, Hernandez-Andrade E, Gratacos E. Prevalence of neonatal ultrasound brain lesions in premature infants with and without intrauterine growth restriction. *Acta Paediatrica (Oslo, Norway: 1992)*. 2007;96(11):1582–7.
- [36] Padilla N, Enriquez G, Hernandez-Andrade E, Arranz A, Acosta-Rojas R, Gratacos E. Brain lesions in intrauterine growth restriction assessed by ultrasound imaging: focus

- on US technique and periventricular lesions. In: Preedy RV, editor. *Handbook of Growth and Growth Monitoring in Health and Disease*. New York, NY: Springer New York; 2012. pp. 263–74.
- [37] Tolcos M, Bateman E, O'Dowd R, Markwick R, Vrijksen K, Rehn A, et al. Intrauterine growth restriction affects the maturation of myelin. *Experimental Neurology*. 2011;232(1):53–65.
 - [38] Volpe JJ. Brain injury in the premature infant: overview of clinical aspects, neuropathology, and pathogenesis. *Seminars in Pediatric Neurology*. 1998;5(3):135–51.
 - [39] Funato M, Tamai H, Noma K, Kurita T, Kajimoto Y, Yoshioka Y, et al. Clinical events in association with timing of intraventricular hemorrhage in preterm infants. *The Journal of Pediatrics*. 1992;121(4):614–9.
 - [40] Borch K, Greisen G. Blood flow distribution in the normal human preterm brain. *Pediatric Research*. 1998;43(1):28–33.
 - [41] Back SA, Riddle A, McClure MM. Maturation-dependent vulnerability of perinatal white matter in premature birth. *Stroke; A Journal of Cerebral Circulation*. 2007;38(2 Suppl):724–30.
 - [42] Gilbert WM, Danielsen B. Pregnancy outcomes associated with intrauterine growth restriction. *American Journal of Obstetrics & Gynecology*. 2003;188(6):1596–9; discussion 9–601.
 - [43] Ortigosa Rocha C, Bittar RE, Zugaib M. Neonatal outcomes of late-preterm birth associated or not with intrauterine growth restriction. *Obstetrics and Gynecology International*. 2010;2010:231842.
 - [44] Gravett MG, Rubens CE, Nunes TM. Global report on preterm birth and stillbirth (2 of 7): discovery science. *BMC Pregnancy and Childbirth*. 2010;10(Suppl 1):S2.
 - [45] Goldenberg RL, Hauth JC, Andrews WW. Intrauterine infection and preterm delivery. *The New England Journal of Medicine*. 2000;342(20):1500–7.
 - [46] Viscardi RM, Muhumuza CK, Rodriguez A, Fairchild KD, Sun CC, Gross GW, et al. Inflammatory markers in intrauterine and fetal blood and cerebrospinal fluid compartments are associated with adverse pulmonary and neurologic outcomes in preterm infants. *Pediatric Research*. 2004;55(6):1009–17.
 - [47] Gotsch F, Romero R, Kusanovic JP, Mazaki-Tovi S, Pineles BL, Erez O, et al. The fetal inflammatory response syndrome. *Clinical Obstetrics and Gynecology*. 2007;50(3):652–83.
 - [48] Nitsos I, Rees SM, Duncan J, Kramer BW, Harding R, Newnham JP, et al. Chronic exposure to intra-amniotic lipopolysaccharide affects the ovine fetal brain. *Journal of the Society for Gynecologic Investigation*. 2006;13(4):239–47.
 - [49] Yan E, Castillo-Melendez M, Nicholls T, Hirst J, Walker D. Cerebrovascular responses in the fetal sheep brain to low-dose endotoxin. *Pediatric Research*. 2004;55(5):855–63.

- [50] Favrais G, van de Looij Y, Fleiss B, Ramanantsoa N, Bonnin P, Stoltenburg-Didinge G, et al. Systemic inflammation disrupts the developmental program of white matter. *Annals of Neurology*. 2011;70(4):550–65.
- [51] Rodts-Palenik S, Wyatt-Ashmead J, Pang Y, Thigpen B, Cai Z, Rhodes P, et al. Maternal infection-induced white matter injury is reduced by treatment with interleukin-10. *American Journal of Obstetrics & Gynecology*. 2004;191(4):1387–92.
- [52] Yoon BH, Romero R, Park JS, Kim CJ, Kim SH, Choi JH, et al. Fetal exposure to an intra-amniotic inflammation and the development of cerebral palsy at the age of three years. *American Journal of Obstetrics & Gynecology*. 2000;182(3):675–81.
- [53] Blencowe H, Cousens S, Chou D, Oestergaard M, Say L, Moller AB, et al. Born too soon: the global epidemiology of 15 million preterm births. *Reproductive Health*. 2013;10(Suppl 1):S2.
- [54] Myers E, Ment LR. Long-term outcome of preterm infants and the role of neuroimaging. *Clinics in Perinatology*. 2009;36(4):773–89, vi.
- [55] Volpe JJ. Brain injury in premature infants: a complex amalgam of destructive and developmental disturbances. *The Lancet Neurology*. 2009;8(1):110–24.
- [56] Brown NC, Inder TE, Bear MJ, Hunt RW, Anderson PJ, Doyle LW. Neurobehavior at term and white and gray matter abnormalities in very preterm infants. *The Journal of Pediatrics*. 2009;155(1):32–8, 8.e1.
- [57] Volpe JJ. Cerebral white matter injury of the premature infant-more common than you think. *Pediatrics*. 2003;112(1 Pt 1):176–80.
- [58] Perlman JM. White matter injury in the preterm infant: an important determination of abnormal neurodevelopment outcome. *Early Human Development*. 1998;53(2):99–120.
- [59] De Reuck JL. Cerebral angioarchitecture and perinatal brain lesions in premature and full-term infants. *Acta Neurologica Scandinavica*. 1984;70(6):391–5.
- [60] Nakamura Y, Okudera T, Hashimoto T. Vascular architecture in white matter of neonates: its relationship to periventricular leukomalacia. *Journal of Neuropathology and Experimental Neurology*. 1994;53(6):582–9.
- [61] Inage YW, Itoh M, Takashima S. Correlation between cerebrovascular maturity and periventricular leukomalacia. *Pediatric Neurology*. 2000;22(3):204–8.
- [62] Ballabh P, Braun A, Nedergaard M. Anatomic analysis of blood vessels in germinal matrix, cerebral cortex, and white matter in developing infants. *Pediatric Research*. 2004;56(1):117–24.
- [63] Volpe JJ. Neonatal encephalitis and white matter injury: more than just inflammation? *Annals of Neurology*. 2008;64(3):232–6.
- [64] Ballabh P. Intraventricular hemorrhage in premature infants: mechanism of disease. *Pediatric Research*. 2010;67(1):1–8.

- [65] Braun A, Xu H, Hu F, Kocherlakota P, Siegel D, Chander P, et al. Paucity of pericytes in germinal matrix vasculature of premature infants. *Journal of Neuroscience*. 2007;27(44):12012–24.
- [66] Pryds O, Greisen G, Lou H, Friis-Hansen B. Heterogeneity of cerebral vasoreactivity in preterm infants supported by mechanical ventilation. *The Journal of Pediatrics*. 1989;115(4):638–45.
- [67] Khwaja O, Volpe JJ. Pathogenesis of cerebral white matter injury of prematurity. *Archives of Disease in Childhood Fetal and Neonatal Edition*. 2008;93(2):F153–61.
- [68] Buser JR, Maire J, Riddle A, Gong X, Nguyen T, Nelson K, et al. Arrested preoligodendrocyte maturation contributes to myelination failure in premature infants. *Annals of Neurology*. 2012;71(1):93–109.
- [69] Back SA, Riddle A, Dean J, Hohimer AR. The instrumented fetal sheep as a model of cerebral white matter injury in the premature infant. *Neurotherapeutics: The Journal of the American Society for Experimental NeuroTherapeutics*. 2012;9(2):359–70.
- [70] Rathbone R, Counsell SJ, Kapellou O, Dyet L, Kennea N, Hajnal J, et al. Perinatal cortical growth and childhood neurocognitive abilities. *Neurology*. 2011;77(16):1510–7.
- [71] Woodward LJ, Anderson PJ, Austin NC, Howard K, Inder TE. Neonatal MRI to predict neurodevelopmental outcomes in preterm infants. *The New England Journal of Medicine*. 2006;355(7):685–94.
- [72] Mullen KM, Vohr BR, Katz KH, Schneider KC, Lacadie C, Hampson M, et al. Preterm birth results in alterations in neural connectivity at age 16 years. *Neuroimage*. 2011;54(4):2563–70.
- [73] Ball G, Boardman JP, Rueckert D, Aljabar P, Arichi T, Merchant N, et al. The effect of preterm birth on thalamic and cortical development. *Cerebral Cortex (New York, NY: 1991)*. 2012;22(5):1016–24.
- [74] Ball G, Boardman JP, Aljabar P, Pandit A, Arichi T, Merchant N, et al. The influence of preterm birth on the developing thalamocortical connectome. *Cortex; A Journal Devoted to the Study of the Nervous System and Behavior*. 2013;49(6):1711–21.
- [75] Molnar Z, Higashi S, Lopez-Bendito G. Choreography of early thalamocortical development. *Cerebral Cortex (New York, NY: 1991)*. 2003;13(6):661–9.
- [76] Javed MJ, Mead LE, Prater D, Bessler WK, Foster D, Case J, et al. Endothelial colony forming cells and mesenchymal stem cells are enriched at different gestational ages in human umbilical cord blood. *Pediatric Research*. 2008;64(1):68–73.
- [77] Sirchia G, Rebulli P. Placental/umbilical cord blood transplantation. *Haematologica*. 1999;84(8):738–47.
- [78] Broxmeyer HE, Douglas GW, Hangoc G, Cooper S, Bard J, English D, et al. Human umbilical cord blood as a potential source of transplantable hematopoietic stem/progenitor

- cells. *Proceedings of the National Academy of Sciences of the United States of America*. 1989;86(10):3828–32.
- [79] Kurita N, Frassoni F, Chiba S, Podesta M. Impact of length of cryopreservation and origin of cord blood units on hematologic recovery following cord blood transplantation. *Bone Marrow Transplant*. 2015;50(6):818–21.
 - [80] Broxmeyer HE. Biology of cord blood cells and future prospects for enhanced clinical benefit. *Cytotherapy*. 2005;7(3):209–18.
 - [81] Hall AA, Guyer AG, Leonardo CC, Ajmo CT, Jr., Collier LA, Willing AE, et al. Human umbilical cord blood cells directly suppress ischemic oligodendrocyte cell death. *Journal of Neuroscience Research*. 2009;87(2):333–41.
 - [82] Chen J, Sanberg PR, Li Y, Wang L, Lu M, Willing AE, et al. Intravenous administration of human umbilical cord blood reduces behavioral deficits after stroke in rats. *Stroke; A Journal of Cerebral Circulation*. 2001;32(11):2682–8.
 - [83] Rice JE, 3rd, Vannucci RC, Brierley JB. The influence of immaturity on hypoxic-ischemic brain damage in the rat. *Annals of Neurology*. 1981;9(2):131–41.
 - [84] Pimentel-Coelho PM, Magalhaes ES, Lopes LM, deAzevedo LC, Santiago MF, Mendez-Otero R. Human cord blood transplantation in a neonatal rat model of hypoxic-ischemic brain damage: functional outcome related to neuroprotection in the striatum. *Stem Cells and Development*. 2010;19(3):351–8.
 - [85] Meier C, Middelani J, Wasielewski B, Neuhoﬀ S, Roth-Haerer A, Gantert M, et al. Spastic paresis after perinatal brain damage in rats is reduced by human cord blood mononuclear cells. *Pediatric Research*. 2006;59(2):244–9.
 - [86] Wang XL, Zhao YS, Hu MY, Sun YQ, Chen YX, Bi XH. Umbilical cord blood cells regulate endogenous neural stem cell proliferation via hedgehog signaling in hypoxic ischemic neonatal rats. *Brain Research*. 2013;1518:26–35.
 - [87] Aridas JD, McDonald CA, Paton MC, Yawno T, Sutherland AE, Nitsos I, et al. Cord blood mononuclear cells prevent neuronal apoptosis in response to perinatal asphyxia in the newborn lamb. *The Journal of Physiology*. 2016;594(5):1421–35.
 - [88] Li J, Yawno T, Sutherland A, Loose J, Nitsos I, Bischof R, et al. Preterm white matter brain injury is prevented by early administration of umbilical cord blood cells. *Experimental Neurology*. 2016;283(Pt A):179–87.
 - [89] Taguchi A, Soma T, Tanaka H, Kanda T, Nishimura H, Yoshikawa H, et al. Administration of CD34+ cells after stroke enhances neurogenesis via angiogenesis in a mouse model. *The Journal of Clinical Investigation*. 2004;114(3):330–8.
 - [90] Verina T, Fatemi A, Johnston MV, Comi AM. Pluripotent possibilities: human umbilical cord blood cell treatment after neonatal brain injury. *Pediatric Neurology*. 2013;48(5):346–54.

- [91] Tsuji M, Taguchi A, Ohshima M, Kasahara Y, Sato Y, Tsuda H, et al. Effects of intravenous administration of umbilical cord blood CD34(+) cells in a mouse model of neonatal stroke. *Neuroscience*. 2014;263:148–58.
- [92] Boltze J, Reich DM, Hau S, Reymann KG, Strassburger M, Lobsien D, et al. Assessment of neuroprotective effects of human umbilical cord blood mononuclear cell subpopulations in vitro and in vivo. *Cell Transplant*. 2012;21(4):723–37.
- [93] Pittenger MF, Mackay AM, Beck SC, Jaiswal RK, Douglas R, Mosca JD, et al. Multilineage potential of adult human mesenchymal stem cells. *Science*. 1999;284(5411):143–7.
- [94] Carroll J. Human cord blood for the hypoxic-ischemic neonate. *Pediatric Research*. 2012;71(4 Pt 2):459–63.
- [95] Luo YC, Zhang HT, Cheng HY, Yang ZJ, Dai YW, Xu RX. Differentiation of cryopreserved human umbilical cord blood-derived stromal cells into cells with an oligodendrocyte phenotype. *In Vitro Cellular & Developmental Biology Animal*. 2010;46(7):585–9.
- [96] van Velthoven CT, Kavelaars A, Heijnen CJ. Mesenchymal stem cells as a treatment for neonatal ischemic brain damage. *Pediatric Research*. 2012;71(4 Pt 2):474–81.
- [97] Kim ES, Ahn SY, Im GH, Sung DK, Park YR, Choi SH, et al. Human umbilical cord blood-derived mesenchymal stem cell transplantation attenuates severe brain injury by permanent middle cerebral artery occlusion in newborn rats. *Pediatric Research*. 2012;72(3):277–84.
- [98] Xia G, Hong X, Chen X, Lan F, Zhang G, Liao L. Intracerebral transplantation of mesenchymal stem cells derived from human umbilical cord blood alleviates hypoxic ischemic brain injury in rat neonates. *Journal of Perinatal Medicine*. 2010;38(2):215–21.
- [99] Kogler G, Sensken S, Wernet P. Comparative generation and characterization of pluripotent unrestricted somatic stem cells with mesenchymal stem cells from human cord blood. *Experimental Hematology*. 2006;34(11):1589–95.
- [100] Park WS, Sung SI, Ahn SY, Yoo HS, Sung DK, Im GH, et al. Hypothermia augments neuroprotective activity of mesenchymal stem cells for neonatal hypoxic-ischemic encephalopathy. *PLoS One*. 2015;10(3):e0120893.
- [101] Asahara T, Murohara T, Sullivan A, Silver M, van der Zee R, Li T, et al. Isolation of putative progenitor endothelial cells for angiogenesis. *Science*. 1997;275(5302):964–7.
- [102] Melero-Martin JM, Khan ZA, Picard A, Wu X, Paruchuri S, Bischoff J. In vivo vasculogenic potential of human blood-derived endothelial progenitor cells. *Blood*. 2007;109(11):4761–8.
- [103] Yoder MC, Mead LE, Prater D, Krier TR, Mroueh KN, Li F, et al. Redefining endothelial progenitor cells via clonal analysis and hematopoietic stem/progenitor cell principals. *Blood*. 2007;109(5):1801–9.

- [104] Liu Y, Teoh SH, Chong MS, Lee ES, Mattar CN, Randhawa NK, et al. Vasculogenic and osteogenesis-enhancing potential of human umbilical cord blood endothelial colony-forming cells. *Stem Cells*. 2012;30(9):1911–24.
- [105] Lin RZ, Dreyzin A, Aamodt K, Li D, Jaminet SC, Dudley AC, et al. Induction of erythropoiesis using human vascular networks genetically engineered for controlled erythropoietin release. *Blood*. 2011;118(20):5420–8.
- [106] Ohta T, Kikuta K, Imamura H, Takagi Y, Nishimura M, Arakawa Y, et al. Administration of ex vivo-expanded bone marrow-derived endothelial progenitor cells attenuates focal cerebral ischemia-reperfusion injury in rats. *Neurosurgery*. 2006;59(3):679–86; discussion -86.
- [107] Zhang ZG, Zhang L, Jiang Q, Chopp M. Bone marrow-derived endothelial progenitor cells participate in cerebral neovascularization after focal cerebral ischemia in the adult mouse. *Circulation Research*. 2002;90(3):284–8.
- [108] Iskander A, Knight RA, Zhang ZG, Ewing JR, Shankar A, Varma NR, et al. Intravenous administration of human umbilical cord blood-derived AC133+ endothelial progenitor cells in rat stroke model reduces infarct volume: magnetic resonance imaging and histological findings. *Stem Cells Translational Medicine*. 2013;2(9):703–14.
- [109] Tanaka N, Kamei N, Nakamae T, Yamamoto R, Ishikawa M, Fujiwara H, et al. CD133+ cells from human umbilical cord blood reduce cortical damage and promote axonal growth in neonatal rat organ co-cultures exposed to hypoxia. *International Journal of Developmental Neuroscience: The Official Journal of the International Society for Developmental Neuroscience*. 2010;28(7):581–7.
- [110] Ding J, Zhao Z, Wang C, Wang CX, Li PC, Qian C, et al. Bioluminescence imaging of transplanted human endothelial colony-forming cells in an ischemic mouse model. *Brain Research*. 2016;1642:209–18.
- [111] Kidani Y, Miki Y, Nomimura N, Minakawa S, Tanaka N, Miyoshi H, et al. The therapeutic effect of CD133(+) cells derived from human umbilical cord blood on neonatal mouse hypoxic-ischemic encephalopathy model. *Life Sciences*. 2016;157:108–15.
- [112] Wood KJ, Bushell A, Hester J. Regulatory immune cells in transplantation. *Nature Reviews Immunology*. 2012;12(6):417–30.
- [113] Milward K, Issa F, Hester J, Figueroa-Tentori D, Madrigal A, Wood KJ. Multiple unit pooled umbilical cord blood is a viable source of therapeutic regulatory T cells. *Transplantation*. 2013;95(1):85–93.
- [114] Lin SJ, Lu CH, Yan DC, Lee PT, Hsiao HS, Kuo ML. Expansion of regulatory T cells from umbilical cord blood and adult peripheral blood CD4(+)CD25 (+) T cells. *Immunologic Research*. 2014;60(1):105–11.
- [115] Brunstein CG, Miller JS, McKenna DH, Hippen KL, DeFor TE, Sumstad D, et al. Umbilical cord blood-derived T regulatory cells to prevent GVHD: kinetics, toxicity profile, and clinical effect. *Blood*. 2016;127(8):1044–51.

- [116] Li P, Gan Y, Sun BL, Zhang F, Lu B, Gao Y, et al. Adoptive regulatory T-cell therapy protects against cerebral ischemia. *Annals of Neurology*. 2013;74(3):458–71.
- [117] Li P, Mao L, Zhou G, Leak RK, Sun BL, Chen J, et al. Adoptive regulatory T-cell therapy preserves systemic immune homeostasis after cerebral ischemia. *Stroke; A Journal of Cerebral Circulation*. 2013;44(12):3509–15.
- [118] Bronte V, Apolloni E, Cabrelle A, Ronca R, Serafini P, Zamboni P, et al. Identification of a CD11b(+)/Gr-1(+)/CD31(+) myeloid progenitor capable of activating or suppressing CD8(+) T cells. *Blood*. 2000;96(12):3838–46.
- [119] Gallina G, Dolcetti L, Serafini P, De Santo C, Marigo I, Colombo MP, et al. Tumors induce a subset of inflammatory monocytes with immunosuppressive activity on CD8+ T cells. *The Journal of Clinical Investigation*. 2006;116(10):2777–90.
- [120] Rieber N, Gille C, Kostlin N, Schafer I, Spring B, Ost M, et al. Neutrophilic myeloid-derived suppressor cells in cord blood modulate innate and adaptive immune responses. *Clinical & Experimental Immunology*. 2013;174(1):45–52.
- [121] Bronte V, Zanovello P. Regulation of immune responses by L-arginine metabolism. *Nature Reviews Immunology*. 2005;5(8):641–54.
- [122] Highfill SL, Rodriguez PC, Zhou Q, Goetz CA, Koehn BH, Veenstra R, et al. Bone marrow myeloid-derived suppressor cells (MDSCs) inhibit graft-versus-host disease (GVHD) via an arginase-1-dependent mechanism that is up-regulated by interleukin-13. *Blood*. 2010;116(25):5738–47.
- [123] Moline-Velazquez V, Cuervo H, Vila-Del Sol V, Ortega MC, Clemente D, de Castro F. Myeloid-derived suppressor cells limit the inflammation by promoting T lymphocyte apoptosis in the spinal cord of a murine model of multiple sclerosis. *Brain Pathology (Zurich, Switzerland)*. 2011;21(6):678–91.
- [124] Womble TA, Green S, Shahaduzzaman M, Grieco J, Sanberg PR, Pennypacker KR, et al. Monocytes are essential for the neuroprotective effect of human cord blood cells following middle cerebral artery occlusion in rat. *Molecular and Cellular Neurosciences*. 2014;59:76–84.
- [125] Miller JT, Bartley JH, Wimborne HJ, Walker AL, Hess DC, Hill WD, et al. The neuroblast and angioblast chemotactic factor SDF-1 (CXCL12) expression is briefly up regulated by reactive astrocytes in brain following neonatal hypoxic-ischemic injury. *BMC Neuroscience*. 2005;6:63.
- [126] Rosenkranz K, Meier C. Umbilical cord blood cell transplantation after brain ischemia—from recovery of function to cellular mechanisms. *Annals of Anatomy—Anatomischer Anzeiger: Official Organ of the Anatomische Gesellschaft*. 2011;193(4):371–9.
- [127] Jiang L, Newman M, Saporta S, Chen N, Sanberg C, Sanberg PR, et al. MIP-1alpha and MCP-1 induce migration of human umbilical cord blood cells in models of stroke. *Current Neurovascular Research*. 2008;5(2):118–24.

- [128] Neuhoﬀ S, Moers J, Rieks M, Grunwald T, Jensen A, Dermietzel R, et al. Proliferation, differentiation, and cytokine secretion of human umbilical cord blood-derived mono-nuclear cells in vitro. *Experimental Hematology*. 2007;35(7):1119–31.
- [129] Newman MB, Willing AE, Manresa JJ, Sanberg CD, Sanberg PR. Cytokines produced by cultured human umbilical cord blood (HUCB) cells: implications for brain repair. *Experimental Neurology*. 2006;199(1):201–8.
- [130] Hau S, Reich DM, Scholz M, Naumann W, Emmrich F, Kamprad M, et al. Evidence for neuroprotective properties of human umbilical cord blood cells after neuronal hypoxia in vitro. *BMC Neuroscience*. 2008;9:30.
- [131] Yasuhara T, Hara K, Maki M, Xu L, Yu G, Ali MM, et al. Mannitol facilitates neuro-trophic factor up-regulation and behavioural recovery in neonatal hypoxic-ischaemic rats with human umbilical cord blood grafts. *Journal of Cellular and Molecular Medicine*. 2010;14(4):914–21.
- [132] Gluckman E, Broxmeyer HA, Auerbach AD, Friedman HS, Douglas GW, Devergie A, et al. Hematopoietic reconstitution in a patient with Fanconi’s anemia by means of umbilical-cord blood from an HLA-identical sibling. *The New England Journal of Medicine*. 1989;321(17):1174–8.
- [133] Tiwari A, Tursky ML, Kirkland MA, Pande G. Expansion of human hematopoietic stem/progenitor cells on decellularized matrix scaffolds. *Current Protocols in Stem Cell Biology*. 2014;28:Unit 1C.15.
- [134] Fruchtmann SM, Hurlet A, Dracker R, Isola L, Goldman B, Schneider BL, et al. The successful treatment of severe aplastic anemia with autologous cord blood transplantation. *Biology of Blood and Marrow Transplantation*. 2004;10(11):741–2.
- [135] Locatelli F, Rocha V, Reed W, Bernaudin F, Ertem M, Grafakos S, et al. Related umbilical cord blood transplantation in patients with thalassemia and sickle cell disease. *Blood*. 2003;101(6):2137–43.
- [136] Rocha V, Cornish J, Sievers EL, Filipovich A, Locatelli F, Peters C, et al. Comparison of outcomes of unrelated bone marrow and umbilical cord blood transplants in children with acute leukemia. *Blood*. 2001;97(10):2962–71.
- [137] Stanevsky A, Shimoni A, Yerushalmi R, Nagler A. Double umbilical cord blood transplant: more than a cell dose? *Leukemia & Lymphoma*. 2010;51(6):975–82.
- [138] Novak I, Hines M, Goldsmith S, Barclay R. Clinical prognostic messages from a systematic review on cerebral palsy. *Pediatrics*. 2012;130(5):e1285–312.
- [139] Min K, Song J, Kang JY, Ko J, Ryu JS, Kang MS, et al. Umbilical cord blood therapy potentiated with erythropoietin for children with cerebral palsy: a double-blind, randomized, placebo-controlled trial. *Stem Cells*. 2013;31(3):581–91.
- [140] Zarzeczny A, Rachul C, Nisbet M, Caulfield T. Stem cell clinics in the news. *Nature Biotechnology*. 2010;28(12):1243–6.

- [141] Kang M, Min K, Jang J, Kim SC, Kang MS, Jang SJ, et al. Involvement of immune responses in the efficacy of cord blood cell therapy for cerebral palsy. *Stem Cells and Development*. 2015;24(19):2259–68.
- [142] Romanov YA, Tarakanov OP, Radaev SM, Dugina TN, Ryaskina SS, Darevskaya AN, et al. Human allogeneic AB0/Rh-identical umbilical cord blood cells in the treatment of juvenile patients with cerebral palsy. *Cytotherapy*. 2015;17(7):969–78.
- [143] Lee YH, Choi KV, Moon JH, Jun HJ, Kang HR, Oh SI, et al. Safety and feasibility of countering neurological impairment by intravenous administration of autologous cord blood in cerebral palsy. *Journal of Translational Medicine*. 2012;10:58.
- [144] Cotten CM, Murtha AP, Goldberg RN, Grotegut CA, Smith PB, Goldstein RF, et al. Feasibility of autologous cord blood cells for infants with hypoxic-ischemic encephalopathy. *The Journal of Pediatrics*. 2014;164(5):973–9.e1.
- [145] Novak I, Walker K, Hunt RW, Wallace EM, Fahey M, Badawi N. Concise review: stem cell interventions for people with cerebral palsy: systematic review with meta-analysis. *Stem Cells Translational Medicine*. 2016;5(8):1014–25.
- [146] Jensen A, Hamelmann E. First autologous cord blood therapy for pediatric ischemic stroke and cerebral palsy caused by cephalic molding during birth: individual treatment with mononuclear cells. *Case Reports in Transplantation*. 2016;2016:1717426.
- [147] Sun JM, Grant GA, McLaughlin C, Allison J, Fitzgerald A, Waters-Pick B, et al. Repeated autologous umbilical cord blood infusions are feasible and had no acute safety issues in young babies with congenital hydrocephalus. *Pediatric Research*. 2015;78(6):712–6.

